





Radiotherapy in the management of glottic squamous cell carcinoma

William M. Mendenhall MD¹  | Primož Strojjan MD, PhD²  |
Anne W.M. Lee MD³ |
Alessandra Rinaldo MD, FRCSEd ad hominem, FRCS (Eng, Ir) ad eundem, FRCSGlasg, FACS⁴  | Avraham Eisbruch MD⁵ | Wai Tong Ng MD⁶ |
Robert Smee MB, BS, FRANZ⁷ |
Alfio Ferlito MD, FRCSEd ad hominem, FRCS (Eng, Glasg, Ir) ad eundem, FDSRCS ad eundem, FACS, FHKCORL, FRCPath, FASCP, IFCAP⁸ 

¹Department of Radiation Oncology, University of Florida College of Medicine, Gainesville, Florida

²Department of Radiation Oncology, Institute of Oncology, Ljubljana, Slovenia

³Department of Clinical Oncology, University of Hong Kong Shenzhen Hospital, University of Hong Kong, Hong Kong, China

⁴University of Udine, School of Medicine, Udine, Italy

⁵Department of Radiation Oncology, University of Michigan Medicine, Ann Arbor, Michigan

⁶Department of Clinical Oncology, LKS Faculty of Medicine, The University of Hong Kong, Hong Kong, China

⁷Department of Radiation Oncology, The Prince of Wales Cancer Centre, Sydney, New South Wales, Australia

⁸International Head and Neck Scientific Group, Padua, Italy

Correspondence

William M. Mendenhall, MD, Department of Radiation Oncology, University of Florida College of Medicine, 2000 SW Archer Rd., PO Box 100385, Gainesville, FL 32610-0385.
Email: mendwm@shands.ufl.edu

Section Editor: Michael Samuels

Abstract

Introduction: Our purpose is to review the role radiotherapy (RT) in the treatment of glottic squamous cell carcinoma (SCC).

Methods: A concise review of the pertinent literature.

Results: RT cure rates are Tis- T1N0, 90% to 95%; T2N0, 70% to 80%; low-volume T3-T4a, 65% to 70%. Concomitant cisplatin is given for T3-T4a SCCs. Severe complications occur in 1% to 2% for Tis-T2N0 and 10% for T3-T4a SCCs. Patients with high-volume T3-T4 SCCs undergo total laryngectomy, neck dissection, and postoperative RT. Those with positive margins and/or extranodal extension receive concomitant cisplatin. The likelihood of local-regional control at 5 years is 85% to 90%. Severe complications occur in 5% to 10%.

Conclusions: RT is a good treatment option for patients with Tis-T2N0 and low-volume T3-T4a glottic SCCs. Patients with higher volume T3-T4 cancers are best treated with surgery and postoperative RT.

KEYWORDS

extranodal extension, glottis, head and neck, radiotherapy, squamous cell carcinoma

1 | INTRODUCTION

Squamous cell carcinoma (SCC) of the glottic larynx is treated with surgery, radiotherapy (RT), or a combination of the two modalities depending on the extent of the disease and the condition and wishes of the patient.¹⁻⁶ Concomitant cisplatin is often given with definitive RT for those with T3-T4 cancers as well as in the postoperative setting for patients with positive margins and/or extranodal extension (ENE).⁷⁻¹² Following is a concise discussion of the role of RT in the treatment of patients with glottic SCC that reflects the philosophy of the authors and not solely the institutional policies of the first author. Patients were staged according to the recommendations of the American Joint Commission on Cancer (AJCC) staging system.^{13,14} Patients with T1 tumors were stratified into those with SCC involving one (T1a) vs both (T1b) vocal cords. Patients with T2 SCCs were stratified into those with normal mobility (T2a) and those with impaired mobility (T2b). T3 denotes vocal cord fixation; a recent modification of the AJCC staging system upstages T2 lesions to T3 based solely on paraglottic space invasion which, in our estimation, results in stage migration.¹³⁻¹⁵

2 | CARCINOMA IN SITU (TIS)

The preferred treatment for patients with glottic Tis is transoral CO₂ laser excision of the lesion provided that the lesion is suitable for complete resection with such a procedure.¹⁶ Patients with Tis of both vocal cords plus the anterior commissure may not be candidates for transoral surgery and are treated with RT using fields encompassing only the larynx with parallel opposed fields or intensity modulated RT (IMRT).^{17,18} The National Comprehensive Cancer Network (NCCN) guidelines include 60.75 Gy at 2.25 Gy per fraction or 66 Gy at 2 Gy per fraction. An alternative would be to use the same dose fractionation schedule used for T1N0 SCCs which is 63 Gy at 2.25 Gy per once daily fraction. The field borders for parallel opposed fields are mid thyroid notch superiorly, the bottom of the cricoid cartilage inferiorly, falling off anteriorly, and 1 cm posterior to the thyroid ala posteriorly (Figure 1). The fields are weighted 3:2 toward the side of the lesion if it is lateralized. Most Tis and T1 cancers are usually in the anterior one-third of the cord. The standard technique is using lateral wedges, typically 30°, to achieve a homogeneous dose distribution across the glottis. However, shifting the hot spot anteriorly by under-wedging or even omitting the wedges may be beneficial, increasing the tumor dose and decreasing the dose to the posterior noninvolved cord and arytenoids.

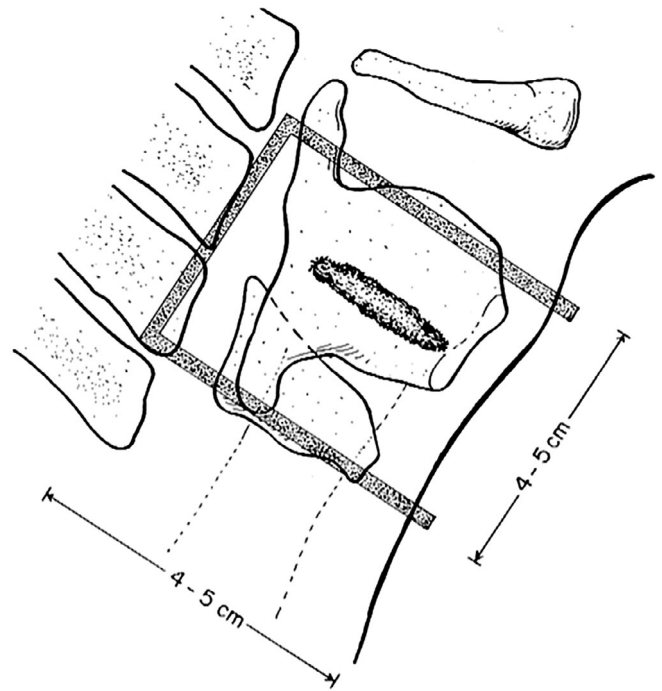


FIGURE 1 Schematic diagram of a typical lateral field (reprinted from Million et al¹⁹)

Alternatively, the gross tumor volume-clinical target volume-planning target volume concept, according to the International Commission on Radiation Units recommendation and recently reached international consensus,^{20,21} can be followed and patients can be treated with more sophisticated RT techniques, that is, IMRT or volumetric arc therapy to reduce the dose to the carotid arteries and lower the likelihood of accelerating atherosclerosis.²²⁻²⁴ There are data suggesting that if IMRT is employed that the image-guidance protocols should match to laryngeal tissue rather than bone.^{17,18} The potential disadvantages include an increased risk of a marginal miss if the target volume is too tight and increased dose heterogeneity which could increase the risk of a complication. Also, the utility of this approach is unknown, taking into account the relatively short length of the irradiated artery in glottic cancer. For example, the Madison group²⁵ found no differences in vascular events between elderly early glottic patients with cancer who received standard RT or surgery. On the other hand, treating single cord in T1 glottic cancer using image-guided RT (IGRT) has a potential to reduce edema and improve voice quality. The Erasmus Cancer Center in Rotterdam conducted a careful study of laryngeal movement during respiration and designed single-cord RT plans using each patient's glottic movements based on cone-beam CT to define margins around the treated cord.²⁶ Using hypofractionation (to reduce the logistic

complexity of the treatment), they reported good results and no complications in 30 patients.²⁷ However, the complexity of this treatment, the high biological equivalent dose, and the generally excellent outcome of standard RT makes this approach questionable. It should not be considered outside of a careful clinical study. Patients with recurrent Tis after one or more prior excisions are treated with RT because additional excisions are likely to cause additional deterioration of voice quality.

Sengupta et al reported on 37 patients treated at the University of Florida (UF) between 1967 and 2005; 23 of 37 (62%) had one or more prior vocal cord strippings.⁵ All patients were treated with once daily fractionation to a median dose of 60 Gy (range, 56.25-66.5 Gy) at a median dose per fraction of 2.25 Gy (range, 2.2-2.6 Gy). Mean follow-up for all patients was 9.5 years (range, 8 months to 25 years) and mean follow-up for survivors was 8.6 years (range, 2.5-25 years).

Four patients developed a local recurrence at 6 months, 12 months, 48 months, and 13 years. The 5-year local control rate after RT was 91%. It is possible and, perhaps likely, that the “recurrence” at 13 years was a second primary cancer. One patient was salvaged with transoral CO₂ laser resection and two patients were salvaged with a total laryngectomy (TL). The patient who developed a recurrence at 13 years declined salvage. No patient developed a regional or distant recurrence. The 5-year overall and cause specific survival rates were 83% and 100%, respectively. No patient developed a severe complication. The outcomes from six additional institutions are outlined in Table 1. Ultimate local control is defined as successful surgical salvage after a local recurrence. The local control rates are essentially the same as what one would expect after RT for T1N0 glottic SCC.

3 | T1-T2N0 SCC

The treatment of T1-T2N0 glottic SCCs is either transoral laser excision or RT.³⁴ The treatment of choice varies with the extent of the lesion, the philosophy and

expertise of the treating physicians, and the desires of the patient. In general, the more extensive the lesion, the more likely that RT will be selected. Patients with T1 SCCs were stratified into those involving one cord (T1a) and two cords (T1b). Patients with T2 cancers are those with extension off of the vocal cords and/or impaired vocal cord mobility. Although not part of the AJCC staging system, some stratify T2 lesions into those with normal (T2a) and impaired (T2b) vocal cord mobility.³⁵ The reason for this stratification is because those with impaired vocal cord mobility are more likely to recur locally after RT and may benefit from more aggressive treatment.

The RT treatment volume includes the primary site; the likelihood of regional lymph-node metastases is low and elective neck irradiation is not employed.^{6,36} The treatment technique for T1N0 SCCs is the same as described above for Tis lesions. The treatment volumes for T2N0 SCCs are modified depending on the extent of the lesions. As previously discussed, IMRT may considered to reduce the dose to the carotid arteries.^{6,22} As previously noted, if partial laryngeal IMRT is employed, it is important match to the soft tissues rather than the cervical spine for precise targeting because the larynx moves relative to the bone and because spinal cord dose is low and away from the high dose target so that adjusting to vocal cord position would be unlikely to result in vocal cord overdose.¹⁸ The NCCN guidelines for T1N0 SCCs include 63 Gy at 2.25 Gy per fraction (preferred), 66 Gy at 2 Gy per fraction, 50 Gy at 3.12 Gy per fraction, or 52 Gy at at 3.28 Gy per fraction. There are data suggesting that 66 Gy at 2 Gy per fraction yields inferior outcomes compared moderately hypofractionated schedules.³⁷ NCCN guidelines for T2N0 SCCs include 65.25 Gy at 2.25 Gy per fraction and 70 Gy at 2 Gy per fraction. There are data from the Christie Hospital suggesting that 52 Gy at 3.28 Gy per fraction is another reasonable alternative.³⁸ The DAHANCA 6 randomized trial comparing 5 vs 6 fractions per week to 62 to 68 Gy at 2 Gy per fraction showed significantly improved local-regional control for the accelerated arm.³⁹

TABLE 1 Carcinoma in situ outcomes after radiotherapy

Series	Study years	Number of patients	5-y local control (%)	5-y ultimate local control (%)
Spayne et al ²⁸	1980-1994	67	98	100
Le et al ²⁹	1958-1998	54	79	100
Smitt and Goffinet ³⁰	1958-1990	29	92	97
Kalter et al ³¹	1963-1981	62	100	100
Pene and Fletcher ³²	1952-1973	79	86	99
Smee et al ³³	1967-2006	24	75	88

Chera et al reported on 585 patients treated with definitive RT at UF between 1964 and 2006 for T1-T2N0 glottic SCCs.⁶ Stage distribution was: T1a, 253 patients; T1b, 72 patients; T2a, 165 patients; and T2b, 95 patients. All patients had a minimum potential follow-up of 2 years. Patients were excluded if they had synchronous primaries or received adjuvant chemotherapy which was essentially not recommended during this time period. No patient received elective neck irradiation. The median and mean follow-up for living patients were 12.3 years and 14.3 years, respectively. Fourteen patients were lost to follow-up. Three patients were lost to follow-up less than 3 years from RT and were coded as dead with disease. The remaining 11 patients lost to follow-up had been followed for at least 5 years and were continuously disease-free.

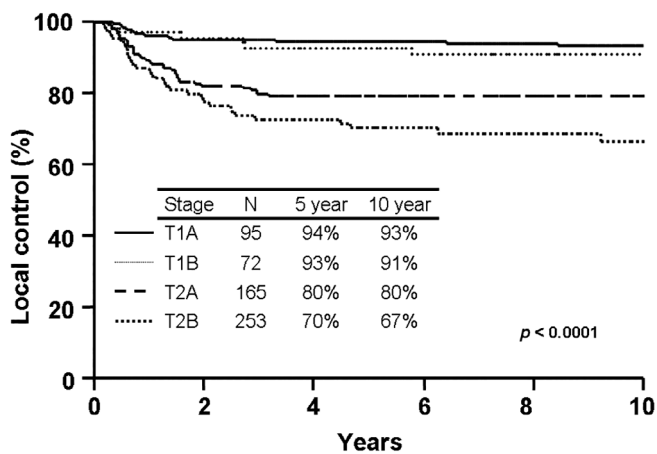


FIGURE 2 Local control after radiation at 5 and 10 years (N = number of patients) (reprinted from Chera et al⁶)

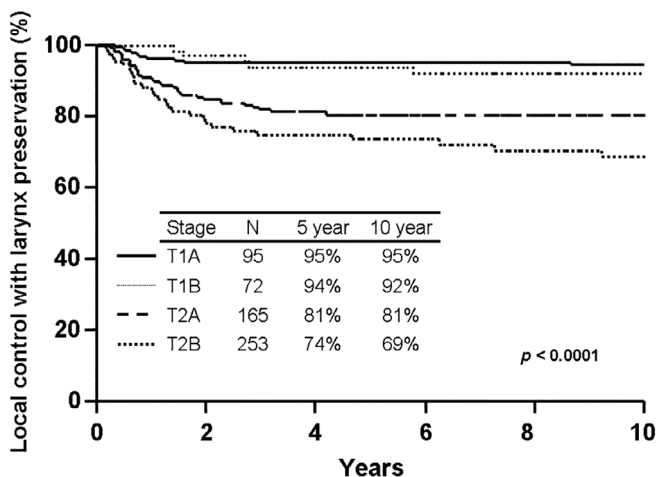


FIGURE 3 Ultimate local control with larynx preservation at 5 and 10 years (N = number of patients) (reprinted from Chera et al⁶)

The local control rates after RT and the ultimate local control rates including patients successfully salvaged after a local recurrence are depicted in Figures 2 and 3. The 5-year neck control rates for patients who remained continuously disease-free at the primary site were: T1a, 100%; T1b, 100%; T2a, 98%; and T2b, 94%. The 5-year rates of distant metastases-free survival were: T1a, 99%; T1b, 99%; T2a, 99%; and T2b, 94%. The 5-year cause specific survival rates were: T1a, 97%; T1b, 99%; T2a, 94%; and T2b, 90%. The 5-year overall survival rates were: T1a, 82%; T1b, 83%; T2a, 76%; and T2b, 78%. Ten patients (1.7%) experienced severe or fatal complications. One patient was hospitalized briefly during twice daily RT for severe mucositis. Two patients underwent a TL for suspected local recurrence and no tumor was found in the specimen. Three patients with T2 tumors developed severe laryngeal edema necessitating a permanent tracheostomy. One patient who developed a local recurrence and underwent a salvage TL experienced a pharyngo-cutaneous fistula. Two patients required permanent gastrostomies. One patient developed a fatal carotid artery angiosarcoma.

Robert et al reported on patients with T1-T2N0 SCCs treated with RT between 1987 and 2015 at four institutions in Western France.⁴⁰ The 5-year outcomes were: local control, 87%; cause-specific survival, 95%; and laryngectomy-free survival, 88%. Two patients (0.8%) required a tracheostomy for tracheal stenosis. Cho et al reported on 160 patients with T1N0 SCCs treated between 2005 and 2016 with IMRT (23 patients) or three-dimensional conformal RT (3DCRT) (137 patients) at the Memorial Sloan Kettering Cancer Center and observed the following 3-year local control rates: IMRT, 94%; 3DCRT, 91%; and overall, 91%.²³ Trotti et al reported on the Radiation Therapy Oncology Group (RTOG) 9512 trial where 239 patients with T2 glottic SCCs were stratified by substage (T2a vs T2b) and randomized to receive hyperfractionated RT (HFX) 79.2 Gy at 1.2 Gy twice daily or standard fractionation (SFX) 70 Gy in 35 once daily fractions.⁴¹ Median follow-up was 7.9 years. The 5-year local control rates were 78% after HFX and 70% after SFX ($P = 0.14$). Late effects were similar.

Rock et al reported on 139 patients with T2N0 SCCs treated between 2006 and 2013 with hypofractionated IMRT 60 Gy in 25 fractions over 5 weeks or moderately accelerated IMRT 66 to 70 Gy in 33 to 35 fractions over 5.5 to 6 weeks since 2010.¹⁸ The IGRT surrogate changed from cervical bone to laryngeal soft tissue in 2008. The 3-year local control rates for three sequential cohorts were: hypofractionated RT matched to bone, 70%; hypofractionated RT matched to larynx, 80%; and accelerated RT matched to larynx, 89% ($P = 0.02$).

Bhateja et al reported on 84 patients treated for T2-T3 glottic SCCs.⁴² Patients with T2a-T2b lesions received RT

TABLE 2 T1-T2 squamous cell carcinoma (SCC): 5-year local control rates

Series	Study years	Follow-up	N	T1a (%)	T1b (%)	T2a (%)	T2b (%)
Chera et al ⁶	1964-2006	Median 12 y	585	94	93	80	70
Groome et al ⁴⁵	1982-1995	Median 5.9 y	704	82	82	63	63
Cellai et al ⁴⁶ and Frata et al ⁴⁷	1970-1999	Median 9.3 y	831	84	81	ND	ND
Warde et al ⁴⁸	1981-1989	Median 6.8 y	735	91	82	69	69
Le et al ⁴⁹	1970-1998	Median 9.7 y	398	85	85	70	70
Garden et al ⁵⁰	1970-1998	Median 6.8 y	230	ND	ND	74	70
Smee et al ³³	1967-2006	Median 7.6 y	498	83	83	72	72

Abbreviations: N, number of patients; ND, no data; y, years.

alone while those with T2b-3N0-2 SCCs received chemoradiation (CRT). The 3-year local control rates were: T2aN0, 95%; T2bN0, 73% after RT alone; and CRT, 92%. There are limited data pertaining to stereotactic ablative body radiosurgery which appears no better, depending on the fractionation schedule, than conventionally fractionated RT.^{43,44} The outcomes after RT from seven additional institutions are depicted in Table 2.

4 | T3-T4 SCC

The treatment of T3-T4 glottic SCCs are either surgery, which usually consists of a TL and neck dissection, followed by postoperative RT or definitive RT and concomitant cisplatin (chemoRT).^{1-4,11,12,51} Patients with T3 SCCs are those with vocal cord fixation and almost all have subglottic extension and are at risk for level 6 lymph-node metastases which are not routinely resected as part of a laryngectomy. Although some patients with low volume tumors may be suitable for a partial laryngectomy, these patients are also good candidates for chemoRT and, because some patients undergoing a partial laryngectomy would likely require postoperative RT, the functional outcome after successful chemoRT would probably be better. Patients who are suitable for chemoRT are those with unilateral cord involvement, low volume (3.5 cc or less calculated diagnostic contrast enhanced computed tomography), and a good airway.⁵² Patients with more advanced T3-T4 SCCs are best treated with TL and neck dissection followed by postoperative RT/chemoRT.² However, those without destruction of cartilage framework, significant base of tongue involvement, and no baseline laryngeal dysfunction can also be candidates for organ preservation treatment provided that the tumor shrinks significantly and/or mobility of the larynx restores after a few cycles of induction chemotherapy, confirming its sensitivity to chemotherapeutics and also RT. In case of insufficient

response to chemotherapy, such patients must be treated with TL.^{53,54} Patients with a clinically negative neck who will require postoperative RT may have the neck dissection omitted because the neck (levels 2-4) will be irradiated as well as the primary site (base of tongue and neopharynx) and level 6 nodes with a high likelihood of local-regional control and less facial edema.⁵⁵ NCCN guidelines for postoperative RT are 60 to 66 Gy at 2 Gy per fraction to high risk areas and 44 to 50 Gy at 2 Gy per fraction or 53 to 63 Gy at 1.6 to 1.8 Gy per fraction to low to intermediate risk areas. Alternatively, postoperative RT doses employed by some are 60 Gy for negative margins, 64 to 66 Gy for close (< 5 mm) or positive margins and areas of ENE, and 70 Gy for gross residual disease at 2 Gy per once daily fraction. Patients with pathologically positive nodes receive RT to the retropharyngeal nodes on the involved side(s). IMRT may employed to reduce the dose to the swallowing muscles and lower the likelihood of long-term swallowing problems.⁵⁵ Patients with extranodal spread, four or more positive nodes, and/or positive margins receive concomitant cisplatin with postoperative RT.^{9,56}

NCCN guidelines for definitive RT include 66 to 70 Gy at 2 Gy per fraction, concomitant boost to 72 Gy in 42 fractions over 30 treatment days, and hyperfractionation to 79.2 to 81.6 Gy at 1.2 Gy per twice daily fraction. NCCN guidelines recommend 70 Gy at 2 Gy per fraction if concomitant chemotherapy is employed likely based, at least in part, on the outcomes of the Radiation Therapy Oncology Group 0129 trial where patients with stages III and IV SCCs of the oral cavity, oropharynx, hypopharynx or larynx were randomized to receive 70 Gy in 35 fractions over 7 weeks or 72 Gy in 42 fractions over 6 weeks with 2 or 3 cycles of cisplatin 100 mg/M2 every 3 weeks.⁵⁷ When combined with cisplatin, there was no improvement in outcome with the accelerated concomitant boost RT compared with standard fractionation. That said, other altered fractionation schedules may be considered.^{7,8} Two schedules often preferred are

hyperfractionation 74.4 Gy at 1.2 Gy per twice daily fraction in 31 treatment days and 70 Gy at 2 Gy per fraction in 30 treatment days giving two twice daily fractions once weekly as employed in a DAHANCA trial. The fields are reduced once at approximately 45 to 50 Gy and again at 60 Gy. An alternative with the DAHANCA schedule is to employ simultaneous-integrated boost to deliver 70 Gy to the gross disease, 63 Gy to the intermediate-risk volume for high-risk subclinical disease, and 56 Gy to the standard-risk subclinical disease. The M. D. Anderson concomitant boost schedule of 72 Gy in 42 fractions over 30 treatment days with twice daily fractions of 1.8 and 1.5 Gy given during the last 12 treatment days is included as an option in the NCCN guidelines. Although the local-regional control rates with the latter schedule are equivalent to those observed after hyperfractionation, the risk of late complications is increased.^{58,59} Additionally, patients treated with hyperfractionation had improved overall survival compared with those treated with standard fractionation. Patients treated with accelerated concomitant boost had no improvement in overall survival. Therefore, hyperfractionation is preferred by some with the DAHANCA schedule as a second choice if the former is not feasible. Regardless of the schedule chosen, the RT is delivered in a continuous course. Patients receive concomitant cisplatin 30 to 40 mg/m² per week or 100 mg/m² every 3 weeks. The former is likely better tolerated and is preferred by many clinicians.⁸ As the risk of subclinical disease in clinically uninvolved nodes is 15% to 20% and levels 2-4 and 6 are electively irradiated bilaterally.

Percutaneous gastrostomy (PEG) placement is placed only if needed to maintain weight and hydration during RT because it has been shown to be associated with worse long-term swallowing. Dentulous patients are evaluated by a dentist prior to initiating RT; teeth that are likely to require future extraction are removed and fluoride trays are fashioned for use with fluoride gel following RT to reduce the risk of dental caries. Prophylactic extraction of healthy teeth prior to RT does not reduce the risk of osteoradionecrosis (ORN) and is not recommended.^{52,60} This is usually not an issue for patients

with laryngeal cancer because the oral cavity is usually not irradiated.

Hinerman et al reported on 109 patients with previously untreated T3 (87 patients) and T4 (22 patients) managed with definitive RT (99 patients) or RT combined with chemotherapy at UF between 1966 and 2002.³ These patients were selected with low volume disease and do not include patients with advanced, high-volume T3-T4 SCCs. The neck was clinically negative in 85 patients (77%). All living patients had a 2-year minimum follow-up. Median follow-up for all patients was 5.7 and 10.6 years for living patients. The local control rates at 5 years were 81% for T4 SCCs and 63% for T3 lesions. The ultimate 5-year local control rate for T3-T4 cancers, including those successfully salvaged after a local recurrence, was approximately 87%. The 5-year local-regional control rates were 78% for stage IVa and 62% for stage III. The 5-year distant metastases-free survival rates were 100% for stage IVa and 97% for those with stage III cancers. The 5-year cause specific survival rates were 87% for stage IVa patients and 83% for stage III patients. The 5-year overall survival rates were 67% for patients with stage IVa SCCs and 52% for those with stage III cancers. Severe complications occurred in 13 patients (12%) and included cartilage necrosis (7 patients), permanent PEG (2 patients), edema requiring a tracheotomy (2 patients), stricture and dysphagia (1 patient), and aspiration/cardiac arrest (1 patient). Two complications were fatal.

The experiences reported from three additional institutions are depicted in Table 3. All of these patients were staged during a time period when T3 was defined as vocal cord fixation. Harwood et al reported on 39 patients treated with RT at the Princess Margaret Cancer Center for T4 glottic SCCs.⁶⁴ Local control after RT was obtained in 22 patients (56%). Similarly, Karim et al reported local control after RT at Free University between 1974 and 1984 for patients with T4 glottic SCCs in 24 of 38 patients (63%).⁶⁵ The local control rates after RT alone or combined with chemotherapy for patients with T4 SCCs from five additional institutions are depicted in Table 4.

Hinerman et al reported on 295 patients with previously untreated SCC of the larynx (199 patients),

TABLE 3 T3 squamous cell carcinoma (SCC)—local control after radiotherapy

Series	Study years	Number of Patients	Minimum Follow-up	Local control (%)	Ultimate local control (%)
Harwood et al ⁶¹	1963-1977	112	3 y	51	77
Wang et al ⁶²	1970-1994	65	NS	57	ND
Stewart and Jackson ⁶³	1955-1965	67	10 y	57	67

Abbreviations: ND, no data; NS, not started; y, years.

TABLE 4 T4 laryngeal carcinoma-treated under definitive radiotherapy (RT) or chemoRT

Series	Number of patients	Cohort years	Percent glottic (%)	Local control (%)
Knab et al ⁶⁶	32	1996-2002	9	71 ^a (4 y)
Parsons et al ⁶⁷	43	1964-1994	26	52 (5 y)
Vengalil et al ⁶⁸	65	2003-2010	40	63 (3 y)
Wick et al ⁶⁹	24	1998-2012	50	75 ^a (ND)
Worden et al ⁷⁰	27 ^b	ND	33	45 (10 y)

Abbreviations: ND, no data; y, years.

^aLocal-regional control.

^bTwenty-seven of 36 patients who received induction chemotherapy.

hypopharynx (80 patients), and oropharynx (16 patients) treated with surgery and postoperative RT at UF between 1964 and 2001.² Patients were treated before the era of transoral robotic surgery (TORS). Patients were staged pathologically according the AJCC staging system. All living patients had a 2-year minimum follow-up. Four patients were lost follow-up at 2.2, 3.1, 8.3, and 13.7 years, respectively. The mean and median follow-up times were 5.3 and 3.6 years, respectively. The primary site was glottic larynx in 95 patients. For patients with laryngeal cancer, margins were positive in 13 patients (6.5%) and close/equivocal in 32 patients (16%). Four or more positive nodes were present in 33 patients (16.5%) with laryngeal cancer. For patients with laryngeal cancer, the presence of ENE was as follows: present, 39 patients (20%); absent, 22 patients (11%); and no data, 138 patients (69%). The 5-year local-regional control rates were 89% for stage III larynx and 85% for stage IVa larynx ($P = 0.33$). The 5-year distant metastases-free survival rates for laryngeal cancer patients were: stage III, 90%; and stage IVa, 74% ($P = 0.03$). The 5-year cause specific survival rates for laryngeal cancer patients were: stage III, 84%; and stage IVa, 66% ($P = 0.043$). The 5-year overall survival rates for patients with laryngeal cancer were: stage III, 57%; and stage IVa, 44% ($P = 0.70$). For the entire group, 23 patients (7.7%) experienced a severe post RT complication including: fistula, 11 patients; permanent PEG, 5 patients; ORN, 3 patients; wound dehiscence, 1 patient; stricture, 1 patient; stomal necrosis, 1 patient; and soft tissue necrosis, 1 patient.

Rosenthal et al reported on 221 patients with T4 laryngeal SCC treated at the M. D. Anderson Cancer Center between 1983 and 2011.⁷¹ The primary site distribution was: glottis, 43 patients (19%); subglottis, 3 patients (1%); supraglottis, 125 patients (57%); and transglottic, 30 patients (33%). Positive nodes were present in 147 patients (67%). TL, neck dissection, and postoperative RT or chemoRT was performed in 161 patients (73%) and larynx preservation (LP) with RT or chemoRT was performed in 60 patients (27%). Median follow-up was 47 months. Median overall survival for both groups of

patients was 64 months ($P = 0.7$). The 5-year local-regional control rate after initial treatment was 84% after TL and 63% after LP ($P < 0.007$). However, taking into account the successful surgical salvage of local-regional recurrences after LP, the ultimate 5 local-regional control rate was 80% which was not significantly different from that observed after TL. The 5-year disease specific survival rate was 60% after TL and 48% after LP ($P = 0.1$). During follow-up, 45% of the LP group had a tracheostomy, at some point in time, and 23% had aspiration.

Mendenhall et al reported on 173 patients who underwent a TL with or without a partial or total pharyngectomy followed by postoperative RT at UF between 1983 and 1998.⁷² Data pertaining to voice rehabilitation were available at 2 to 3 years and longer for 118 patients and for 5 years and longer for 69 patients. The methods of voice rehabilitation at 2 to 3 years and longer and 5 years and longer were: tracheoesophageal, 27% and 19%; artificial larynx, 50% and 57%; esophageal, 1% and 3%; nonvocal, 17% and 14%; and no data, 5% and 7%, respectively.

5 | CONCLUSIONS

Patients with early and moderately advanced laryngeal SCC have a relatively high chance of cure with LP after RT or chemoRT that is related to extent of disease. Patients with more advanced cancers are best treated with surgery and postoperative RT alone or combined with concomitant chemotherapy. Although many patients undergoing TL may be rehabilitated with tracheoesophageal speech, the majority are rehabilitated with an artificial larynx.

CONFLICT OF INTEREST

The authors declare no potential conflict of interest.

ORCID

William M. Mendenhall  <https://orcid.org/0000-0002-6592-2810>

Primož Strojjan  <https://orcid.org/0000-0002-0445-112X>

Alessandra Rinaldo  <https://orcid.org/0000-0001-7956-6709>

Alfio Ferlito  <https://orcid.org/0000-0002-8247-8002>

REFERENCES

- Mendenhall WM, Dagan R, Bryant CM, Amdur RJ, Mancuso AA. Definitive radiotherapy for squamous cell carcinoma of the glottic larynx. *Cancer Control*. 2016;23(3):208-212.
- Hinerman RW, Morris CG, Amdur RJ, et al. Surgery and postoperative radiotherapy for squamous cell carcinoma of the larynx and pharynx. *Am J Clin Oncol*. 2006;29(6):613-621.
- Hinerman RW, Mendenhall WM, Morris CG, Amdur RJ, Werning JW, Villaret DB. T3 and T4 true vocal cord squamous carcinomas treated with external beam irradiation: a single institution's 35-year experience. *Am J Clin Oncol*. 2007;30(2):181-185.
- Mendenhall WM, Mancuso AA, Hinerman RW, et al. Multidisciplinary management of laryngeal carcinoma. *Int J Radiat Oncol Biol Phys*. 2007;69(2 suppl):S12-S14.
- Sengupta N, Morris CG, Kirwan J, Amdur RJ, Mendenhall WM. Definitive radiotherapy for carcinoma in situ of the true vocal cords. *Am J Clin Oncol*. 2010;33(1):94-95.
- Chera BS, Amdur RJ, Morris CG, Kirwan JM, Mendenhall WM. T1N0 to T2N0 squamous cell carcinoma of the glottic larynx treated with definitive radiotherapy. *Int J Radiat Oncol Biol Phys*. 2010;78(2):461-466.
- Mendenhall WM, Riggs CE, Vaysberg M, Amdur RJ, Werning JW. Altered fractionation and adjuvant chemotherapy for head and neck squamous cell carcinoma. *Head Neck*. 2010;32(7):939-945.
- Newlin HE, Amdur RJ, Riggs CE, Morris CG, Kirwan JM, Mendenhall WM. Concomitant weekly cisplatin and altered fractionation radiotherapy in locally advanced head and neck cancer. *Cancer*. 2010;116(19):4533-4540.
- Bernier J, Cooper JS. Chemoradiation after surgery for high-risk head and neck cancer patients: how strong is the evidence? *Oncologist*. 2005;10(3):215-224.
- Forastiere AA, Zhang Q, Weber RS, et al. Long-term results of RTOG 91-11: a comparison of three nonsurgical treatment strategies to preserve the larynx in patients with locally advanced larynx cancer. *J Clin Oncol*. 2013;31(7):845-852.
- Trifiletti DM, Smith A, Mitra N, et al. Beyond positive margins and extracapsular extension: evaluating the utilization and clinical impact of postoperative chemoradiotherapy in resected locally advanced head and neck cancer. *J Clin Oncol*. 2017;35(14):1550-1560.
- Strojan P, Haight M Jr, Bradford CR, et al. Chemoradiotherapy vs. total laryngectomy for primary treatment of advanced laryngeal squamous cell carcinoma. *Oral Oncol*. 2013;49(4):283-286.
- American Joint Committee on Cancer. *AJCC Cancer Staging Handbook*. 5th ed. Philadelphia, PA: Lippincott-Raven; 1997.
- American Joint Committee on Cancer. *AJCC Cancer Staging Handbook*. 6th ed. New York, NY: Springer Verlag; 2002.
- Dagan R, Morris CG, Bennett JA, et al. Prognostic significance of paraglottic space invasion in T2N0 glottic carcinoma. *Am J Clin Oncol*. 2007;30(2):186-190.
- Aaltonen LM, Rautiainen N, Sellman J, et al. Voice quality after treatment of early vocal cord cancer: a randomized trial comparing laser surgery with radiation therapy. *Int J Radiat Oncol Biol Phys*. 2014;90(2):255-260.
- Tiong A, Huang SH, O'Sullivan B, et al. Outcome following IMRT for T2 glottic cancer: the potential impact of image-guidance protocols on local control. *J Radiat Oncol*. 2014;3(3):267-275.
- Rock K, Huang SH, Tiong A, et al. Partial laryngeal IMRT for T2N0 glottic cancer: impact of image guidance and radiation therapy intensification. *Int J Radiat Oncol Biol Phys*. 2018;102(4):941-949.
- Million RR, Cassisi NJ, Mancuso AA. Larynx. In: Million RR, Cassisi NJ, eds. *Management of Head and Neck: A Multidisciplinary Approach*. 2nd ed. Philadelphia, PA: Lippincott; 1994:431-497.
- Gregoire V, Evans M, Le QT, et al. Delineation of the primary tumour clinical target volumes (CTV-P) in laryngeal, hypopharyngeal, oropharyngeal and oral cavity squamous cell carcinoma: AIRO, CACA, DAHANCA, EORTC, GEORCC, GORTEC, HKNPCSG, HNCIG, IAG-KHT, LPRHHT, NCIC CTG, NCRI, NRG oncology, PHNS, SBRT, SOMERA, SRO, SSHNO, TROG consensus guidelines. *Radiation Oncol*. 2018;126(1):3-24.
- International Commission on Radiation Units and Measurements (ICRU). *Prescribing, Recording, and Reporting Photon Beam Therapy. ICRU Report 50*. Bethesda, MD: ICRU; 1993.
- Chera BS, Amdur RJ, Morris CG, Mendenhall WM. Carotid-sparing intensity-modulated radiotherapy for early-stage squamous cell carcinoma of the true vocal cord. *Int J Radiat Oncol Biol Phys*. 2010;77(5):1380-1385.
- Cho EI, Sasaki CT, Haffty BG. Prognostic significance of pretreatment hemoglobin for local control and overall survival in T1-T2N0 larynx cancer treated with external beam radiotherapy. *Int J Radiat Oncol Biol Phys*. 2004;58(4):1135-1140.
- Wegner RE, Abel S, Bergin JJ, Colonias A. Intensity-modulated radiation therapy in early stage squamous cell carcinoma of the larynx: treatment trends and outcomes. *Radiat Oncol J*. 2020;38(1):11-17.
- Hong JC, Kruser TJ, Gondi V, et al. Risk of cerebrovascular events in elderly patients after radiation therapy versus surgery for early-stage glottic cancer. *Int J Radiat Oncol Biol Phys*. 2013;87(2):290-296.
- Osman SO, Astreinidou E, de Boer HC, et al. IMRT for image-guided single vocal cord irradiation. *Int J Radiat Oncol Biol Phys*. 2012;82(2):989-997.
- Al-Mamgani A, Kwa SL, Tans L, et al. Single vocal cord irradiation: image guided intensity modulated hypofractionated radiation therapy for T1a glottic cancer: early clinical results. *Int J Radiat Oncol Biol Phys*. 2015;93(2):337-343.
- Spayne JA, Warde P, O'Sullivan B, et al. Carcinoma-in-situ of the glottic larynx: results of treatment with radiation therapy. *Int J Radiat Oncol Biol Phys*. 2001;49(5):1235-1238.
- Le QT, Takamiya R, Shu HK, et al. Treatment results of carcinoma in situ of the glottis: an analysis of 82 cases. *Arch Otolaryngol Head Neck Surg*. 2000;126(11):1305-1312.
- Smitt MC, Goffinet DR. Radiotherapy for carcinoma-in-situ of the glottic larynx. *Int J Radiat Oncol Biol Phys*. 1994;28(1):251-255.
- Kalter PO, Lubsen H, Delemarre JF, Snow GB. Squamous cell hyperplasia of the larynx (a clinical follow-up study). *J Laryngol Otol*. 1987;101(6):579-588.

32. Pene F, Fletcher GH. Results in irradiation of the in situ carcinomas of the vocal cords. *Cancer*. 1976;37(6):2586-2590.
33. Smee RI, Meagher NS, Williams JR, Broadley K, Bridger GP. Role of radiotherapy in early glottic carcinoma. *Head Neck*. 2010;32(7):850-859.
34. Forner D, Rigby MH, Corsten M, Trites JR, Pyne J, Taylor SM. Oncological and functional outcomes after repeat transoral laser microsurgery for the treatment of recurrent early glottic cancer. *J Laryngol Otol*. 2020;134(2):169-173.
35. American Joint Committee on Cancer. *AJCC Cancer Staging Manual*. 8th ed. New York, NY: Springer; 2018.
36. Okumura M, Motegi A, Zenda S, et al. Efficacy and safety of accelerated fractionated radiotherapy without elective nodal irradiation for T3N0 glottic cancer without vocal cord fixation. *Head Neck*. 2020;42:1775-1782.
37. Yamazaki H, Nishiyama K, Tanaka E, Koizumi M, Chatani M. Radiotherapy for early glottic carcinoma (T1N0M0): results of prospective randomized study of radiation fraction size and overall treatment time. *Int J Radiat Oncol Biol Phys*. 2006;64(1):77-82.
38. Dixon LM, Douglas CM, Shaukat SI, et al. Conventional fractionation should not be the standard of care for T2 glottic cancer. *Radiat Oncol*. 2017;12(1):178.
39. Lyhne NM, Primdahl H, Kristensen CA, et al. The DAHANCA 6 randomized trial: effect of 6 vs 5 weekly fractions of radiotherapy in patients with glottic squamous cell carcinoma. *Radiother Oncol*. 2015;117(1):91-98.
40. Robert A, Pointreau Y, Janoray G, et al. A large French multicenter retrospective series of T1-T2N0 vocal cords carcinomas treated with exclusive irradiation. *Cancer Radiother*. 2017;21(4):286-290.
41. Trotti A 3rd, Zhang Q, Bentzen SM, et al. Randomized trial of hyperfractionation versus conventional fractionation in T2 squamous cell carcinoma of the vocal cord (RTOG 9512). *Int J Radiat Oncol Biol Phys*. 2014;89(5):958-963.
42. Bhateja P, Ward MC, Hunter GH, et al. Impaired vocal cord mobility in T2N0 glottic carcinoma: suboptimal local control with radiation alone. *Head Neck*. 2016;38(12):1832-1836.
43. Sher DJ, Timmerman RD, Nedzi L, et al. Phase 1 fractional dose-escalation study of equipotent stereotactic radiation therapy regimens for early-stage glottic larynx cancer. *Int J Radiat Oncol Biol Phys*. 2019;105(1):110-118.
44. Mendenhall WM, Holtzman AL, Dagan R, Bryant CM, Hitchcock KE, Amdur RJ. In regard to Sher et al. *Int J Radiat Oncol Biol Phys*. 2020;106(1):220-221.
45. Groome PA, O'Sullivan B, Mackillop WJ, et al. Compromised local control due to treatment interruptions and late treatment breaks in early glottic cancer: population-based outcomes study supporting need for intensified treatment schedules. *Int J Radiat Oncol Biol Phys*. 2006;64(4):1002-1012.
46. Cellai E, Frata P, Magrini SM, et al. Radical radiotherapy for early glottic cancer: results in a series of 1087 patients from two Italian radiation oncology centers. I. The case of T1N0 disease. *Int J Radiat Oncol Biol Phys*. 2005;63(5):1378-1386.
47. Frata P, Cellai E, Magrini SM, et al. Radical radiotherapy for early glottic cancer: results in a series of 1087 patients from two Italian radiation oncology centers. II. The case of T2N0 disease. *Int J Radiat Oncol Biol Phys*. 2005;63(5):1387-1394.
48. Warde P, O'Sullivan B, Bristow RG, et al. T1/T2 glottic cancer managed by external beam radiotherapy: the influence of pretreatment hemoglobin on local control. *Int J Radiat Oncol Biol Phys*. 1998;41(2):347-353.
49. Le QT, Fu KK, Kroll S, et al. Influence of fraction size, total dose, and overall time on local control of T1-T2 glottic carcinoma. *Int J Radiat Oncol Biol Phys*. 1997;39(1):115-126.
50. Garden AS, Forster K, Wong PF, Morrison WH, Schechter NR, Ang KK. Results of radiotherapy for T2N0 glottic carcinoma: does the "2" stand for twice-daily treatment? *Int J Radiat Oncol Biol Phys*. 2003;55(2):322-328.
51. Mendenhall WM, Amdur RJ, Hinerman RW, Villaret DB, Siemann DW. Postoperative radiation therapy for squamous cell carcinoma of the head and neck. *Am J Otolaryngol*. 2003;24(1):41-50.
52. Dziegielewski PT, Reschly WJ, Morris CG, et al. Tumor volume as a predictor of survival in T3 glottic carcinoma: a novel approach to patient selection. *Oral Oncol*. 2018;79:47-54.
53. Forastiere AA, Ismaila N, Lewin JS, et al. Use of larynx-preservation strategies in the treatment of laryngeal cancer: American Society of Clinical Oncology clinical practice guideline update. *J Clin Oncol*. 2018;36(11):1143-1169.
54. Wolf GT, Bellile E, Eisbruch A, et al. Survival rates using individualized bioselection treatment methods in patients with advanced laryngeal cancer. *JAMA Otolaryngol Head Neck Surg*. 2017;143(4):355-366.
55. Wang X, Hu C, Eisbruch A. Organ-sparing radiation therapy for head and neck cancer. *Nat Rev Clin Oncol*. 2011;8(11):639-648.
56. Cooper JS, Pajak TF, Forastiere AA, et al. Postoperative concurrent radiotherapy and chemotherapy for high-risk squamous-cell carcinoma of the head and neck. *N Engl J Med*. 2004;350(19):1937-1944.
57. Nguyen-Tan PF, Zhang Q, Ang KK, et al. Randomized phase III trial to test accelerated versus standard fractionation in combination with concurrent cisplatin for head and neck carcinomas in the radiation therapy oncology group 0129 trial: long-term report of efficacy and toxicity. *J Clin Oncol*. 2014;32(34):3858-3866.
58. Beitler JJ, Zhang Q, Fu KK, et al. Final results of local-regional control and late toxicity of RTOG 9003: a randomized trial of altered fractionation radiation for locally advanced head and neck cancer. *Int J Radiat Oncol Biol Phys*. 2014;89(1):13-20.
59. Feigenberg S, Patel K, Amdur RJ, Mendenhall WM. RTOG 9003: the untold story. *Int J Radiat Oncol Biol Phys*. 2014;90(2):251-252.
60. Chang DT, Sandow PR, Morris CG, et al. Do pre-irradiation dental extractions reduce the risk of osteoradionecrosis of the mandible? *Head Neck*. 2007;29(6):528-536.
61. Harwood AR, Beale FA, Cummings BJ, Hawkins NV, Keane TJ, Rider WD. T3 glottic cancer: an analysis of dose time-volume factors. *Int J Radiat Oncol Biol Phys*. 1980;6(6):675-680.
62. Wang CC. Carcinoma of the larynx. In: Wang CC, ed. *Radiation Therapy for Head and Neck Neoplasms*. 3rd ed. New York, NY: Wiley-Liss, Inc.; 1997:221-255.
63. Stewart JG, Jackson AW. The steepness of the dose response curve both for tumor cure and normal tissue injury. *Laryngoscope*. 1975;85(7):1107-1111.
64. Harwood AR, Beale FA, Cummings BJ, Keane TJ, Payne D, Rider WD. T4NOMO glottic cancer: an analysis of dose-time

- volume factors. *Int J Radiat Oncol Biol Phys*. 1981;7(11):1507-1512.
65. Karim AB, Kralendonk JH, Njo KH, Tierie AH, Hasman A. Radiation therapy for advanced (T3T4N0-N3M0) laryngeal carcinoma: the need for a change of strategy: a radiotherapeutic viewpoint. *Int J Radiat Oncol Biol Phys*. 1987;13(11):1625-1633.
66. Knab BR, Salama JK, Solanki A, et al. Functional organ preservation with definitive chemoradiotherapy for T4 laryngeal squamous cell carcinoma. *Annal Oncol*. 2008;19(9):1650-1654.
67. Parsons JT, Mendenhall WM, Stringer SP, Cassisi NJ. T4 laryngeal carcinoma: radiotherapy alone with surgery reserved for salvage. *Int J Radiat Oncol Biol Phys*. 1998;40(3):549-552.
68. Vengalil S, Giuliani ME, Huang SH, et al. Clinical outcomes in patients with T4 laryngeal cancer treated with primary radiotherapy versus primary laryngectomy. *Head Neck*. 2016;38(suppl 1):E2035-E2040.
69. Wick CC, Rezaee RP, Wang T, et al. Use of concurrent chemoradiation in advanced staged (T4) laryngeal cancer. *Am J Otolaryngol*. 2017;38(1):72-76.
70. Worden FP, Moyer J, Lee JS, et al. Chemoselection as a strategy for organ preservation in patients with T4 laryngeal squamous cell carcinoma with cartilage invasion. *Laryngoscope*. 2009;119(8):1510-1517.
71. Rosenthal DI, Mohamed AS, Weber RS, et al. Long-term outcomes after surgical or nonsurgical initial therapy for patients with T4 squamous cell carcinoma of the larynx: a 3-decade survey. *Cancer*. 2015;121(10):1608-1619.
72. Mendenhall WM, Morris CG, Stringer SP, et al. Voice rehabilitation after total laryngectomy and postoperative radiation therapy. *J Clin Oncol*. 2002;20(10):2500-2505.

How to cite this article: Mendenhall WM, Strojan P, Lee AWM, et al. Radiotherapy in the management of glottic squamous cell carcinoma. *Head & Neck*. 2020;1–10. <https://doi.org/10.1002/hed.26419>