

# Four Lessons Learned from Complications in Head and Neck Microvascular Reconstructions and Prevention Strategies

Luís Vieira, MD\*†

Daniel Isacson, MD, PhD\*†

Eleonora O. F. Dimovska, MBBS,  
MRCS, Msc\*†

Andres Rodriguez-Lorenzo, MD,  
PhD\*†

**Background:** Free flap reconstruction in the head and neck region is a complex field in which patient comorbidities, radiation therapy, tumor recurrence, and variability of clinical scenarios make some cases particularly challenging and prone to devastating complications. Despite low free flap failure rates, the impact of flap failure has enormous consequences for the patients.

**Methods:** Acknowledging and predicting high risk intra- and postoperative situations and having planned strategies on how to deal with them can decrease their rate and improve the patient's reconstructive journey.

**Results:** Herein, the authors present 4 examples of significant complications in complex microvascular head and neck cancer reconstruction, encountered for the last 10 years: compression and kinking of the vascular pedicle, lack of planning of external skin coverage in osteoradionecrosis, management of the vessel-depleted neck, and vascular donor site morbidity after fibula harvest.

**Conclusion:** The authors reflect on the causes and propose preventative strategies in each peri-operative stage. (*Plast Reconstr Surg Glob Open* 2021;9:e3329; doi: 10.1097/GOX.0000000000003329; Published online 22 January 2021.)

## INTRODUCTION

The advent of microvascular free flaps has expanded the potential population of patients with primary or recurrent head and neck cancer who might be considered candidates for curative surgery.<sup>1-4</sup> In addition, successful free tissue transfer allows for a decreased morbidity and better cost-effective aesthetic and functional outcome.<sup>5,6</sup> Reconstructions can, however, be a challenging and complex endeavor because anatomy in the head and neck encompasses multiple tissue types and functional areas.<sup>7</sup>

Head and neck cancer patients receiving ablation and reconstructive surgery are usually at a higher risk for developing peri-operative medical and surgical complications<sup>8-10</sup> related to a higher number of comorbidities,<sup>10-15</sup> malnutrition,<sup>10,12,16</sup> alcohol abuse,<sup>10,17,18</sup> smoking,<sup>15</sup> advanced disease,<sup>18</sup> and previous chemoradiotherapy.<sup>13,16</sup>

Total complication rates in head and neck free flap reconstruction vary greatly between studies. The largest current review on complications in head and neck free flap reconstruction by Eskander et al found a total complication rate of 54%.<sup>12</sup> Patel et al found reconstructive and systemic complications as high as 30% and 21%, respectively, in a particularly difficult subpopulation of recurrent head and neck squamous cell carcinoma undergoing resection and reconstruction.<sup>19</sup> Nevertheless, free flap reconstruction for head and neck cancer compares favorably to the other options of locoregional flaps in terms of medical and surgical complications.<sup>20</sup>

Free flap transfer is a reliable procedure with consistent success rates over 95%.<sup>1,10,12,16,21-23</sup> We reported a failure rate of 2% at our institution in 100 consecutive anterolateral thigh flaps in head and neck reconstruction.<sup>24</sup> Despite low free flap failure rates, the impact of flap failure has enormous consequences for the patients: longer ICU stays, longer hospital stays, poorer functional outcomes, and more surgical interventions under general anesthesia for an already frail population.<sup>10,18</sup> Delay in adjuvant therapy, amongst other factors, may result in failure of oncological treatment, and ultimately higher mortality rates.<sup>18,20,25</sup> In oncological salvage surgery with free flap reconstruction, free flap failure may severely decrease quality of life in an already low overall survival expectancy.

\*From the Department of Plastic and Maxillofacial Surgery, Uppsala University Hospital, Uppsala, Sweden; and †Department of Surgical Sciences, Uppsala University, Uppsala, Sweden.

Received for publication July 20, 2020; accepted October 28, 2020.

Presented in part at the 10th Congress of World Society for Reconstructive Microsurgery, June 12-15, 2019, Bologna, Italy.

Copyright © 2021 The Authors. Published by Wolters Kluwer Health, Inc. on behalf of The American Society of Plastic Surgeons. This is an open-access article distributed under the terms of the Creative Commons Attribution-Non Commercial-No Derivatives License 4.0 (CCBY-NC-ND), where it is permissible to download and share the work provided it is properly cited. The work cannot be changed in any way or used commercially without permission from the journal.

DOI: 10.1097/GOX.0000000000003329

**Disclosure:** The authors have no financial interest to declare in relation to the content of this article. No funding was received for this study.

Highlighting surgical steps of high-risk scenarios and standardizing their execution can provide reliable reconstructive solutions, and thus decrease the burden of surgical complications on overall patient treatment. Although many factors play a role, one should not forget that free flap outcome is primarily the result of surgical technique. Strategies to predict microsurgical complications by thorough preoperative patient evaluation and further optimizing surgical techniques are important.<sup>16</sup>

In this article, the authors analyzed 4 major surgical complications related to free flap surgery encountered by the senior author (ARL) in the last 10 years, performing head and neck microvascular reconstruction. We reflected on the causes of complications and described preventative measures recommended in preoperative planning,

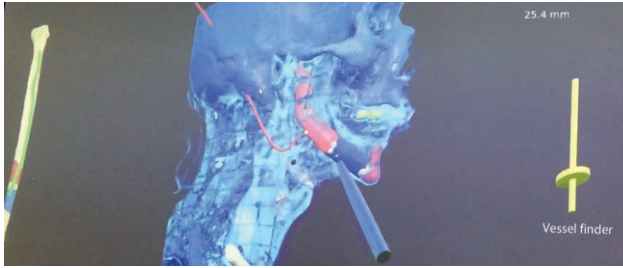
intraoperative execution, and postoperative recovery to avoid the following pitfalls (Table 1):

1. Kinking and compression of the vascular pedicle;
2. Lack of external skin in osteoradionecrosis;
3. Late vascular thrombosis in long vein graft in the radiated and vessel-depleted neck;
4. Ischemic events after fibula harvesting in morbid patients.

The article is presented in a descriptive manner, with details on the authors' own reflections and analysis of the complications. Written consent was obtained to use patient images for publication, and patient data were handled in accordance to our institutions' research ethics policies (ethical approval number: Dnr 2017/207).

**Table 1. Summary of Prevention Strategies to Avoid Complications in Head and Neck Microvascular Reconstruction**

Complication/Problem	Prevention Strategies		
	Preoperative	Intraoperative	Postoperative
Kinking and compression of the vascular pedicle	<ul style="list-style-type: none"> <li>- VSP and visualization of the vascular pedicle's position and curvature in relation to the recipient vessels</li> </ul>	<ul style="list-style-type: none"> <li>- Flap inseting before microvascular anastomosis to adjust pedicle length and curvature</li> <li>- Potential compression points' release such as posterior belly of digastric muscle and sternocleidomastoid muscle</li> <li>- When using superficial temporal vessels, perform anastomosis in the intraparotid segment after proper release</li> <li>- If pedicle is tunneled, use the "2-fingers rule" to assess the width of the tunnel</li> <li>- Strict hemostasis control under patients' normal blood pressure</li> <li>- Double check pedicle curvature before final closure and avoid tight closure of the neck</li> </ul>	<ul style="list-style-type: none"> <li>- Control the neutral position of the neck and avoid external compression</li> <li>- Sedation of the patient the first 24 h postoperative</li> <li>- Intensive microsurgical education to staff for flap monitoring and patient positioning</li> </ul>
Lack of external skin in surgical approaches to the radiated neck	<p>When faced with a reconstructive case having been subjected to previous radiation therapy, plan to include a separate soft tissue component in the flap, either skin paddle or muscle plus skin graft for external coverage of the created defect in the neck</p>		
Late vascular thrombosis after use of long vein grafts in radiated neck	<ul style="list-style-type: none"> <li>- VSP of the vascular pedicle's required length to reach the recipient vessels and proper donor site selection</li> <li>- In fibula flap, preoperative imaging provides information on the leg with the most proximal peroneal artery bifurcation</li> </ul>	<ul style="list-style-type: none"> <li>- Select donor sites with long pedicles (anterolateral thigh, subscapular system, and fibula)</li> <li>- In fibula flap: harvest distal osseous segment and skin paddle; proximal pedicle dissection</li> <li>- Recipient vessels in the base of the neck: transverse cervical, thoracoacromial, and internal mammary</li> <li>- "Carrier vessel" free flap, such as radial free flap</li> <li>- Alternative regional flaps: pectoralis major and supraclavicular</li> </ul>	
Vascular donor site morbidity in fibula flap in morbid patients	<ul style="list-style-type: none"> <li>- Computer tomographic angiography for all patients</li> <li>- Proper patient selection</li> <li>- Favor other donor sites in comorbid patients (scapula tip free flap)</li> <li>- Consider soft tissue only reconstruction</li> </ul>	<ul style="list-style-type: none"> <li>- Standardize surgical technique</li> <li>- "4 parts surgical approach": aim to control and preserve tibialis anterior and posterior pedicles</li> <li>- Peroneal vessels clamping before pedicle division</li> <li>- Expedient flap harvest: short tourniquet period</li> <li>- Donor site closure: avoid fascial closure, liberal use of skin grafts, active drainage in submuscular and subcutaneous planes</li> </ul>	<ul style="list-style-type: none"> <li>- Close surveillance of donor site for early hematoma or compartment syndrome</li> <li>- Avoid raquianesthesia</li> <li>- Early mobilization</li> <li>- Intermittent elevation</li> </ul>



**Fig. 1.** VSP allows preoperative prediction of reconstruction requirements and coordination of soft tissue and bony tissue in relation to the vascular pedicle.

### KINKING AND COMPRESSION OF THE VASCULAR PEDICLE

Free flap failure is today a relatively uncommon event; however, emergency surgical re-exploration shows a 10% prevalence in complex head and neck reconstructions.<sup>16,21,22,26</sup> Excluding intra-luminal thrombotic events, extra-luminal mechanical complications such as pedicle kinking, compression, or twisting are described in the literature, as ranging between 68%–83% of re-exploration cases.<sup>1,16,21,26,27</sup> Unrelated to the microvascular anastomosis technique, the higher prevalence of mal- and displacement of the vascular pedicle in head and neck cases could occur from unwanted neck mobility, contractions of neck musculature, postoperative swelling, pedicle placed in narrow anatomical spaces, twisted vessel ends at the time of the anastomosis, and lengthy pedicle or hematoma formation.<sup>23,27,28</sup>

#### Preventative Strategies

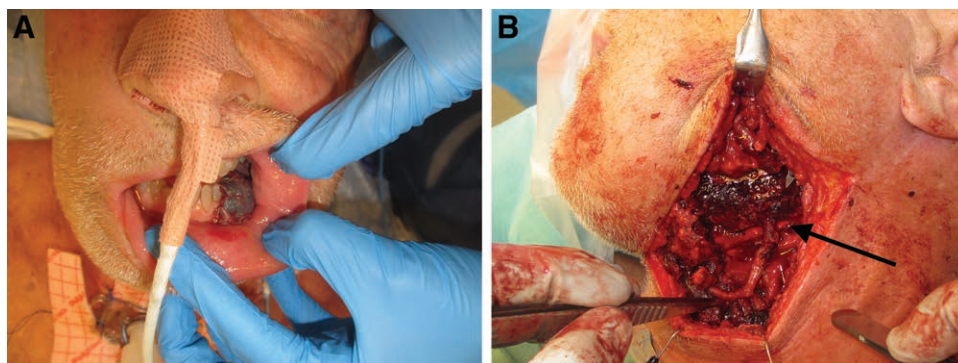
To avoid malpositioning of the pedicle, it is advised to plan the position and curvature of the pedicle preoperatively in relation to the recipient vessel (Table 1). Virtual surgical planning (VSP) tools allow for prediction of the course of the pedicle in relation to the selected recipient vessels (Fig. 1).<sup>29</sup> Optimal preoperative planning can additionally co-ordinate soft tissue and osseous tissue and thereby better integrate the route for the pedicle around the reconstruction. Intraoperatively, it is important to always perform the flap inseting before the microvascular anastomosis to assess an adequate pedicle length and

the curvature of the vessels to avoid kinking. It is vital to liberally release possible compression points such as the posterior belly of digastric muscle when using the facial vessels as recipient or the sternocleidomastoid muscles by either resecting parts of the muscle or suspending it to the nearby tissue using sutures (Fig. 2). If placing the pedicle through the floor of the mouth or through the cheek, create a wide-spaced tunnel. Typically the authors use the “2-fingers-width” rule. Regularly control hemostasis under patient normal blood pressure and double check for pedicle kinking by, for example, marking the surface of the pedicle with surgical ink or stabilizing the pedicle length with intraoperative glue.<sup>27</sup> Finally, avoid closure of the neck skin under tension.

At the postoperative phase, it is important to control the position of the neck to avoid compression and kinking of the pedicle, specially the first 72 hours postoperative.<sup>28</sup> Avoid pillows that can create an excessive angulation between the neck and the thorax. Keeping the patient sedated until the next postoperative day could be required to prevent unnecessary movements or coughing, which could cause direct pedicle compromise or hematoma. A close working team of both doctors and nurses is necessary for free flap success, with enrollment of the entire department in the microsurgical environment by, for example, training of the nursing staff.

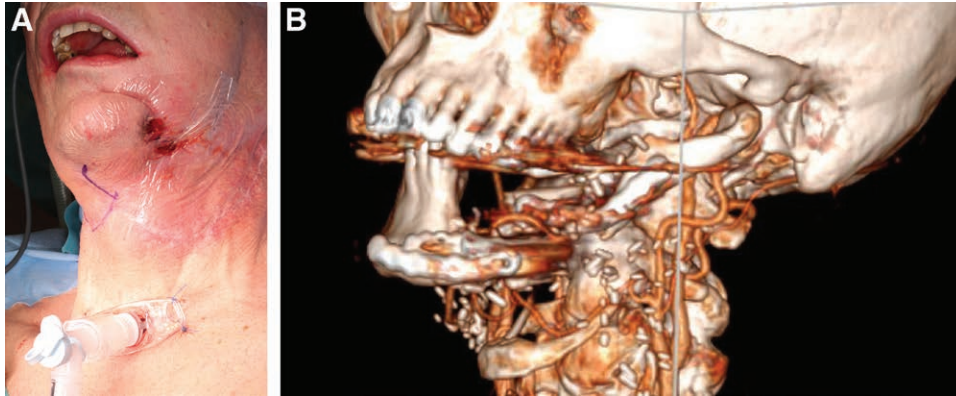
### LACK OF EXTERNAL SKIN AFTER SURGICAL APPROACHES IN THE RADIATED NECK

Osteoradionecrosis (ORN) is defined as a complication from radiation therapy characterized by exposed bones failing to heal by conservative measures over a 3-month period, in the absence of residual or recurrent tumor.<sup>30</sup> The anatomical distribution of ORN is largely predominant in the mandible, but it has been described in the scalp and maxilla.<sup>31,32</sup> Microscopically, radiation injury can be seen in different tissues such as the endothelium, bone, periosteum, and fibrous connective tissue of skin and mucosa, and as a macroscopic consequence, irradiated skin, and adjacent soft tissue turns fibrotic and hard, thereby complicating extensive surgical manipulation.<sup>33,34</sup> A large 30-year retrospective review by Reuther et al found an overall 8.2% incidence of all stages of ORN with a 3-fold



**Fig. 2.** Intraoperative image of a failing free fibula flap (A) due to compression of the vascular pedicle by the posterior belly of the digastric muscle (B, black arrow).





**Fig. 3.** Orocutaneous fistula in a patient reconstructed with a free fibula flap after preoperative radiotherapy and hemi-mandibulectomy due to a gingival cancer (A). The lack of skin paddle in the neck resulted in tight skin closure of the neck skin flaps, which developed marginal necrosis and wound breakdown with consequent flap necrosis (B).

higher percentage in men.<sup>32</sup> However, Sandel and Davison described a large series where the ORN rate in the head and neck region was found to vary from 10% to 15%.<sup>31</sup>

Understandably, ORN free flap reconstruction is a high-risk endeavor, with several factors contributing to increased complication rates. As reviewed by Lee et al, ORN reconstructions showed a flap failure rate of 9.8% and 39.7% postoperative complications rate, with the most common being fistula formation (8.4%), hardware plate exposure (7.1%), and wound infections (6.5%).<sup>35</sup>

Late effects of radiotherapy are insufficient flap perfusion, tissue rigidity, delayed healing, low resistance to swelling, difficult tissue handling, and distortion of surgical planes. Our experience shows that direct closure of the irradiated neck skin flaps often leads to skin flap necrosis, wound breakdown, and even free flap compromise (due to compression) (Fig. 3).

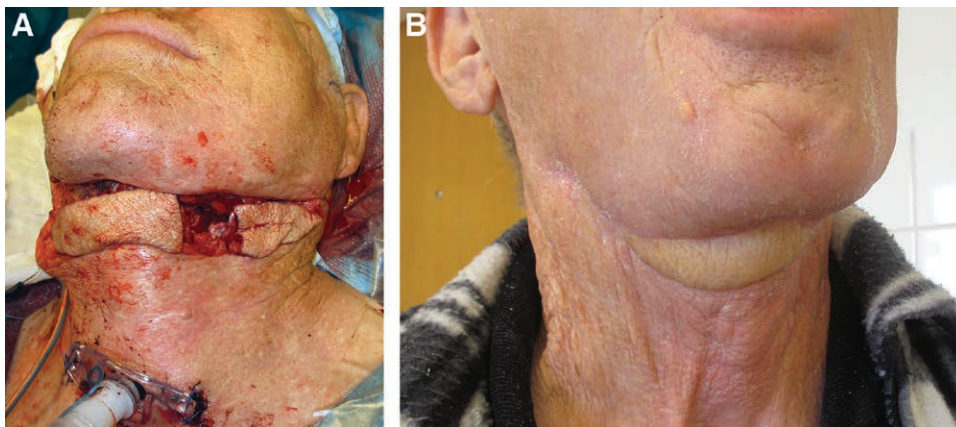
#### Preventative Strategies

Regardless of the surgical indication, when faced with a reconstructive case having been subjected to previous radiation therapy, our recommendation is to always plan to

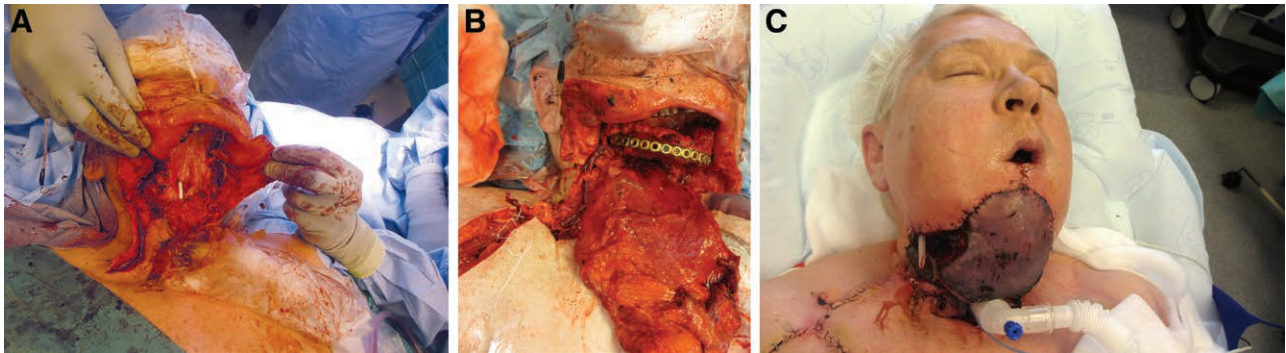
include a separate external soft tissue component in the flap, either skin paddle or muscle plus skin graft (Fig. 4) for coverage of the defect created in the neck (Table 1). The patient should be consented for this requirement, which is necessary to ensure healing, despite a potentially early suboptimal aesthetic outcome. In the mid- or long-term postoperative period, aesthetic refinements can be added to the reconstruction, namely by judicious excision of the skin paddle.

#### LATE VASCULAR THROMBOSIS WHEN USING LONG VEIN GRAFTS IN RADIATED AND VESSEL-DEPLETED NECK

A recent review by Maricevich et al found a 7.4% rate of vein grafts' use and an associated 5-fold increase in flap compromise in head and neck microsurgical reconstruction.<sup>36</sup> Re-exploration is also more common, especially when using unplanned interposition vein grafts.<sup>37,38</sup> Vessel-depleted necks occur in around 7% of patients and the main causes are previously irradiated tissue and previous neck dissections with free flap anastomoses, with 70% of the cases being secondary reconstructions.<sup>37,38</sup>



**Fig. 4.** Intraoperative image of a patient with mandible ORN reconstructed using a free fibula flap with two skin islands, one for the intraoral defect, and the other for the external skin, allowing tensionless skin suture (A). Postoperative image at 6 weeks (B).



**Fig. 5.** Excision of recurrence of squamous cell carcinoma in a previously irradiated patient, and free flap reconstructed glossectomy defect resulted in a complex segmental mandibulectomy, glossectomy, and neck skin defect (A). Reconstruction was achieved with a free chimeric scapula tip and a latissimus dorsi flap anastomosed to the thoracoacromial artery and cephalic vein by means of a long vascular loop (B). Total flap necrosis caused by thrombosis in the long vein graft segment (C).

Long vein grafts are considered more prone to thrombosis in this setting for several reasons: higher number of anastomosis, higher risk of kinks and twist, flow disturbance in the vein graft segment related to graft handling and flow-resistance,<sup>38,39</sup> and the poor vascular bed in the radiated field, which could yield to vessel necrosis and thrombosis (Fig. 5).

#### Preventative Strategies

A thorough preoperative study of the case, both clinically and radiologically, is a vital first step. The use of VSP is again advised.<sup>29</sup> This allows prediction of the pedicle length needed and proper selection of donor site (Table 1).

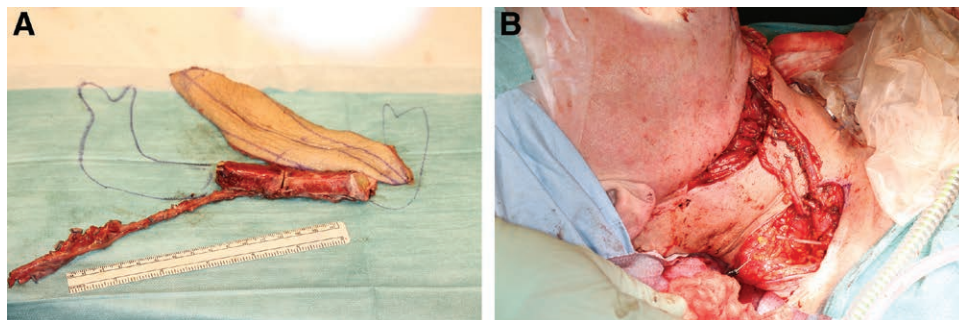
To overcome the intraoperative difficulties in vessel-depleted necks, we anticipated the need for distant anastomoses and thus planned to reconstruct with flaps providing long pedicles, avoiding as much as possible long vein grafts. As an example, the senior author used a free fibula flap, and ensured a long pedicle by choosing a distal osseous part for the osseous reconstruction (with an associated skin paddle) and performed a long proximal dissection of the peroneal pedicle to have enough length to reach the base of the neck without tension (Fig. 6). Preoperative imaging of both lower legs allows the selection of the leg with the most proximal peroneal artery

bifurcation from the tibialis posterior artery or from the tibio-peroneal trunk.

Distant anastomoses can be performed to recipient vessels in the base of the neck/upper thorax, such as the transverse cervical, the thoracoacromial trunk, and the internal mammary. Vascular loops using the cephalic vein are a last resource when planning these cases. An alternative to the use of long vein grafts is the use of a carrier vessel free flap, in which case the radial forearm free flap is an excellent solution.<sup>40</sup> Furthermore, it can occasionally be necessary to descend the reconstructive ladder/elevator in vessel-depleted neck scenarios and consider classical pedicled flaps, such as the workhorse pectoralis major flap. Such reconstructions can shorten operative time and provide immediate reconstruction and early initiation of adjuvant therapy, albeit sometimes at the expense of the optimal final functional and aesthetic result.

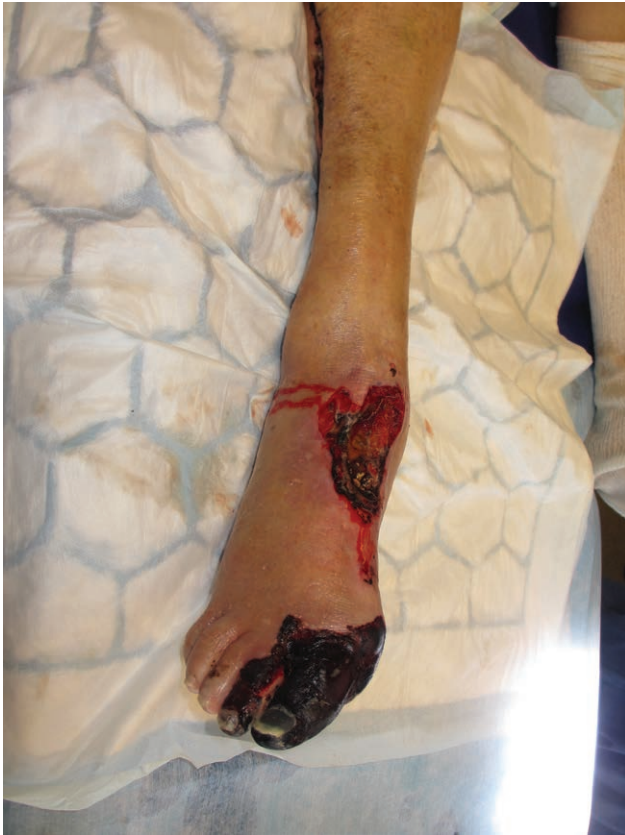#### VASCULAR DONOR SITE MORBIDITY IN FIBULA FLAP IN MORBID PATIENTS

Although the fibula free flap is the preferred flap for bony head and neck reconstruction in most centers, donor site morbidity remains a concern.<sup>41–43</sup> Traditionally, this morbidity is classified as an either postoperative-wound-related



**Fig. 6.** Secondary left-sided body of the mandible defect reconstruction with a free fibula osteosseotomocutaneous flap in a previously irradiated patient (A). Anastomosis in the base of the contralateral neck without vein graft interposition was made possible by: distal osseous segment and skin paddle, and proximal dissection of the pedicle (B).





**Fig. 7.** An 84-year-old woman presented with a T4N0M0 carcinoma of mandibular gingiva. Previous medical history included hypertension, chronic obstructive pulmonary disease, hyperlipidemia, and chronic renal failure. Doppler signals could be heard in the 3 vascular axes of the limb. The patient went on to have a mandibulectomy, neck dissection, and reconstruction with a free fibula flap. On the postoperative period, delayed wound healing developed and critical limb ischemia was noted. This subsequently resulted in a below-knee amputation after failed attempts at endovascular revascularization of the tibialis anterior artery.

complication, or long-term “orthopedic” sequela. Wound-related complication rate reaches 31% and comprises, in order of frequency, partial or total skin graft loss, cellulitis, wound dehiscence, and abscess.<sup>41</sup>

Factors related to early donor site complications have been described, such as larger skin paddle area,<sup>16,41,43</sup> neoadjuvant chemotherapy,<sup>41</sup> longer operating time under tourniquet control,<sup>44</sup> and smoking.<sup>45</sup> Even though the above early and late complications are distressing for patients, major complications such as compartment syndrome, donor site necrosis, necrotizing infections, and limb ischemia are probably underreported in the literature<sup>45–48</sup> (Fig. 7).

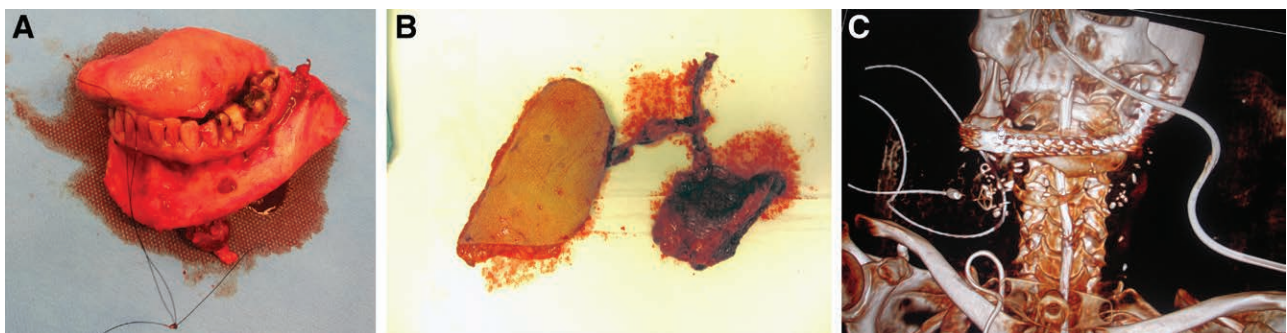**Preventative Strategies**

To prevent major complications in the free fibula flap donor site in the postoperative period, the authors propose several strategies (Table 1). Accounting for the high rate of vascular comorbidities in this patient group, careful patient selection is key. A preoperative computer tomography angiogram should certainly be encouraged considering the non-negligible rate of vascular congenital variations described as ranging from 5% to 15%.<sup>49–53</sup>

It is important to standardize the fibula free flap harvest to make it safe. Peroneal pedicle clamping for some minutes after flap harvest and before pedicle division is valuable for prediction of foot perfusion. Furthermore, an expeditious flap harvest is beneficial in terms of tourniquet duration and the risk for possible reperfusion injury.

Concerning donor site closure, it is recommended to avoid fascial closure, performing gentle muscle approximation only, performing flexor hallucis longus suspension to the interosseous membrane remnant, having active drainage in both submuscular and subcutaneous planes, and liberal use of skin grafts to avoid closure under tension and skin necrosis. Close postoperative surveillance of the donor site, and early stepwise mobilization with intermittent lower limb elevation for edema control should take place. Because head and neck patients are usually under sedation in the early postoperative period, an active surveillance of the donor site is recommended, and any slight sign of complication should be highlighted.

Another important measure has been the shift to other bone free flaps in comorbid patients, namely to the subscapular vascular axis and the scapula tip free flap (Fig. 8). Compared with the fibula free flap, the scapula tip free flap saves 1 vascular axis of an extremity; the vascular pedicle is



**Fig. 8.** In comorbid patients, composite flaps from the subscapular system are the first option for bony and soft tissue reconstruction in head and neck. In this case, a complex defect caused by mandibulectomy and glossectomy (A) was successfully reconstructed with a composite flap (B) from the subscapular system, using scapula tip for bony reconstruction (C), teres major for inner lining, and scapular fasciocutaneous flap for extraoral coverage.

usually spared from atherosclerosis, has less wound-healing issues, and allows earlier mobilization—important factors when treating comorbid patients.<sup>54,55</sup> In addition to its favorable donor site, the versatile vascular axis allows the fabrication of chimeric flaps at the expense of a sometimes more limited bone stock. Finally, when none of the previous is possible, we prefer to compromise bone reconstruction and combine reconstruction plates with soft tissue free flaps, as sometimes downgrading the reconstructive goals is the best option for some patients, and has in the literature not been shown to compromise oromandibular function in smaller hemi-mandibulectomy resections.<sup>56</sup>

## CONCLUSIONS

Free flap reconstruction of head and neck cancer patients is nowadays the gold standard after ablative surgery. This often highly comorbid patient population is prone to postoperative complications. Acknowledging and predicting high-risk intra- and postoperative situations and having planned strategies on how to deal with them can decrease their rate and improve the patient's reconstructive journey. Niels Bohr, the 1922 Nobel laureate in Physics, once said, "An expert is a person who has made all the mistakes which can be made, in a narrow field." However, by sharing our experience of these difficult reconstructive head and neck cases, we hope to challenge this statement and to reinforce the contrary concept of "learning from other people's mistakes."

Luis Vieira, MD

Department of Plastic and Maxillofacial Surgery  
Uppsala University Hospital  
Uppsala, Sweden  
E-mail: luisgvieira.lv@gmail.com

## PATIENT CONSENT

Patients provided written consent for the use of their images.

## REFERENCES

1. Wong C-H, Wei F-C. Microsurgical free flap in head and neck reconstruction. *Head Neck*. 2014;36:1391.
2. Urken ML, Weinberg H, Buchbinder D, et al. Microvascular free flaps in head and neck reconstruction. *Arch Otolaryngol Head Neck Surg*. 1994;120:633-640.
3. Ho AS, Kraus DH, Ganly I, et al. Decision making in the management of recurrent head and neck cancer. *Head Neck*. 2014;36:1391.
4. Kim AJ, Suh JD, Sercarz JA, et al. Salvage surgery with free flap reconstruction: factors affecting outcome after treatment of recurrent head and neck squamous carcinoma. *Laryngoscope*. 2007;117:1019-1023.
5. Gao LL, Basta M, Kanchwala SK, et al. Cost-effectiveness of microsurgical reconstruction for head and neck defects after oncologic resection. *Head Neck*. 2017;39:541-547.
6. Goodwin WJ Jr. Salvage surgery for patients with recurrent squamous cell carcinoma of the upper aerodigestive tract: when do the ends justify the means? *Laryngoscope*. 2000;110(3 Pt 2 suppl 93):1-18.
7. Hsieh TY, Bewley A. Use of multiple free flaps in head and neck reconstruction. *Curr Opin Otolaryngol Head Neck Surg*. 2019;27:392-400.
8. Lin HW, Bhattacharyya N. Contemporary assessment of medical morbidity and mortality in head and neck surgery. *Otolaryngol Head Neck Surg*. 2012;146:385-389.
9. Abt NB, Xie Y, Puram SV, et al. Frailty index: intensive care unit complications in head and neck oncologic regional and free flap reconstruction. *Head Neck*. 2017;39:1578-1585.
10. Patel RS, McCluskey SA, Goldstein DP, et al. Clinicopathologic and therapeutic risk factors for perioperative complications and prolonged hospital stay in free flap reconstruction of the head and neck. *Head Neck*. 2010;36:1345-1353.
11. Carniol ET, Marchiano E, Brady JS, et al. Head and neck microvascular free flap reconstruction: an analysis of unplanned readmissions. *Laryngoscope*. 2017;127:325-330.
12. Eskander A, Kang S, Tweel B, et al. Predictors of complications in patients receiving head and neck free flap reconstructive procedures. *Otolaryngol Head Neck Surg*. 2018;158:839-847.
13. Joo YH, Cho KJ, Park JO, et al. Surgical morbidity and mortality in patients after microvascular reconstruction for head and neck cancer. *Clin Otolaryngol*. 2018;43:502-508.
14. Katna R, Kalyani N, Agarwal S, et al; Mumbai Oncology Group – Head and Neck. Impact of comorbidities on perioperative outcomes for carcinoma of oral cavity. *Ann R Coll Surg Engl*. 2020;102:232-235.
15. Schimansky S, Lang S, Beynon R, et al. Association between comorbidity and survival in head and neck cancer: results from head and neck 5000. *Head Neck*. 2019;41:1053-1062.
16. Lo SL, Yen YH, Lee PJ, et al. Factors influencing postoperative complications in reconstructive microsurgery for head and neck cancer. *J Oral Maxillofac Surg*. 2017;75:867-873.
17. Howard MA, Cordeiro PG, Disa J, et al. Free tissue transfer in the elderly: incidence of perioperative complications following microsurgical reconstruction of 197 septuagenarians and octogenarians. *Plast Reconstr Surg*. 2005;116:1659-1668.
18. Lahtinen S, Koivunen P, Ala-Kokko T, et al. Complications and outcome after free flap surgery for cancer of the head and neck. *Br J Oral Maxillofac Surg*. 2018;56:684-691.
19. Patel VM, Stern C, Miglani A, et al. Evaluation of the relationship between age and outcome after microvascular reconstruction among patients with recurrent head and neck squamous cell carcinoma. *J Reconstr Microsurg*. 2017;33:336-342.
20. Jones NF, Jarrahy R, Song JJ, et al. Postoperative medical complications—not microsurgical complications—negatively influence the morbidity, mortality, and true costs after microsurgical reconstruction for head and neck cancer. *Plast Reconstr Surg*. 2007;119:2053-2060.
21. Yu P, Chang DW, Miller MJ, et al. Analysis of 49 cases of flap compromise in 1310 free flaps for head and neck reconstruction. *Head Neck*. 2009;31:45-51.
22. Yang X, Li S, Wu K, et al. Surgical exploration of 71 free flaps in crisis following head and neck reconstruction. *Int J Oral Maxillofac Surg*. 2016;45:153-157.
23. Chiu YH, Chang DH, Perng CK. Vascular complications and free flap salvage in head and neck reconstructive surgery: analysis of 150 cases of reexploration. *Ann Plast Surg*. 2017;78(3 suppl 2):S83-S88.
24. Driessen C, van Hout N, van Kuppenveld P, et al. Usefulness of a template-based anterolateral thigh flap for reconstruction of head and neck defects. *Microsurgery*. 2020;40:776-782.
25. Ch'ng S, Choi V, Elliott M, et al. Relationship between postoperative complications and survival after free flap reconstruction for oral cavity squamous cell carcinoma. *Head Neck*. 2014;36:55-59.
26. Chen KT, Mardini S, Chuang DC, et al. Timing of presentation of the first signs of vascular compromise dictates the salvage outcome of free flap transfers. *Plast Reconstr Surg*. 2007;120:187-195.

27. Kim JT, Kim YH, Kim SW. Effect of fibrin sealant in positioning and stabilizing microvascular pedicle: a comparative study. *Microsurgery*. 2017;37:406–409.
28. Cariatì P, Cabello Serrano A, Monsalve Iglesias F, et al. Unfavorable outcomes in microsurgery: possibilities for improvement. *J Plast Surg Hand Surg*. 2019;53:279–287.
29. Olsson P, Nysjö F, Rodríguez-Lorenzo A, et al. Haptics-assisted virtual planning of bone, soft tissue, and vessels in fibula osteocutaneous free flaps. *Plast Reconstr Surg Glob Open*. 2015;3:1–9.
30. Marx RE. Osteoradionecrosis: a new concept of its pathophysiology. *Growth (Lakeland)*. 1983;41:283–288.
31. Sandel HD IV, Davison SP. Microsurgical reconstruction for radiation necrosis: an evolving disease. *J Reconstr Microsurg*. 2007;23:225–230.
32. Reuther T, Schuster T, Mende U, et al. Osteoradionecrosis of the jaws as a side effect of radiotherapy of head and neck tumour patients—a report of a thirty year retrospective review. *Int J Oral Maxillofac Surg*. 2003;32:289–295.
33. Posch NA, Mureau MA, Dumans AG, et al. Functional and aesthetic outcome and survival after double free flap reconstruction in advanced head and neck cancer patients. *Plast Reconstr Surg*. 2007;120:124–129.
34. Hirsch DL, Bell RB, Dierks EJ, et al. Analysis of microvascular free flaps for reconstruction of advanced mandibular osteoradionecrosis: a retrospective cohort study. *J Oral Maxillofac Surg*. 2008;66:2545–2556.
35. Lee M, Chin RY, Eslick GD, et al. Outcomes of microvascular free flap reconstruction for mandibular osteoradionecrosis: a systematic review. *J Craniomaxillofac Surg*. 2015;43:2026–2033.
36. Maricevich M, Lin LO, Liu J, et al. Interposition vein grafting in head and neck free flap reconstruction. *Plast Reconstr Surg*. 2018;142:1025–1034.
37. Furr MC, Cannady S, Wax MK. Interposition vein grafts in microvascular head and neck reconstruction. *Laryngoscope*. 2011;121:707–711.
38. Inbal A, Silva AK, Humphries LS, et al. Bridging the gap: a 20-year experience with vein grafts for free flap reconstruction. The odds for success. *Plast Reconstr Surg*. 2018;142:786–794.
39. Schanzer A, Hevelone N, Owens CD, et al. Technical factors affecting autogenous vein graft failure: observations from a large multicenter trial. *J Vasc Surg*. 2007;46:1180–90; discussion 1190.
40. Ciudad P, Agko M, Date S, et al. The radial forearm free flap as a “vascular bridge” for secondary microsurgical head and neck reconstruction in a vessel-depleted neck. *Microsurgery*. 2018;38:651–658.
41. Momoh AO, Yu P, Skoracki RJ, et al. A prospective cohort study of fibula free flap donor-site morbidity in 157 consecutive patients. *Plast Reconstr Surg*. 2011;128:714–720.
42. Ling XF, Peng X, Samman N. Donor-site morbidity of free fibula and DCIA flaps. *J Oral Maxillofac Surg*. 2013;71:1604–1612.
43. Vittayakittipong P. Donor-site morbidity after fibula free flap transfer: a comparison of subjective evaluation using a visual analogue scale and point evaluation system. *Int J Oral Maxillofac Surg*. 2013;42:956–961.
44. van Gemert JTM, Abbink JH, van Es RJJ, et al. Early and late complications in the reconstructed mandible with free fibula flaps. *J Surg Oncol*. 2018;117:773–780.
45. Fodor L, Dinu C, Fodor M, Ciuce C. Severe compartment syndrome following fibula harvesting for mandible reconstruction. *Int J Oral Maxillofac Surg*. 2011;40:434–437.
46. Klein S, Hage JJ, Woerdeman LA. Donor-site necrosis following fibula free-flap transplantation: a report of three cases. *Microsurgery*. 2005;25:538–542.
47. Hwang JH, Kim KS, Lee SY. A case of nonisland pedicled foot fillet flap for below-knee amputation stump wound: treatment option for compartment syndrome after fibular free flap surgery. *J Korean Med Sci*. 2014;29:305–308.
48. Kerrary S, Schouman T, Cox A, et al. Acute compartment syndrome following fibula flap harvest for mandibular reconstruction. *J Craniomaxillofac Surg*. 2011;39:206–208.
49. Rosson GD, Singh NK. Devascularizing complications of free fibula harvest: peronea arteria magna. *J Reconstr Microsurg*. 2005;21:533–538.
50. Rahmel BB, Snow TM, Batstone MD. Fibular free flap with arteria peronea magna: the role of preoperative balloon occlusion. *J Reconstr Microsurg*. 2011;27:169–172.
51. Abou-Foul AK, Borumandi F. Anatomical variants in fibula free flap: systematic review and implications in fibula free flap: systematic review and critical analysis. *Microsurgery*. 2016;36:165–172.
52. Abou-Foul AK, Fasanmade A, Prabhu S, et al. Anatomy of the vasculature of the lower leg and harvest of a fibular flap: a systematic review. *Br J Oral Maxillofac Surg*. 2017;55:904–910.
53. Schuderer JG, Meier JK, Klingelhöffer C, et al. Magnetic resonance angiography for free fibula harvest: anatomy and perforator mapping. *Int J Oral Maxillofac Surg*. 2020;49:176–182.
54. Clark JR, Vesely M, Gilbert R. Scapular angle osteomyogenous flap in postmaxillectomy reconstruction: defect, reconstruction, shoulder function, and harvest technique. *Head Neck*. 2008;30:10–20.
55. Choi N, Cho JK, Jang JY, et al. scapular tip free flap for head and neck reconstruction. *Clin Exp Otorhinolaryngol*. 2015;8:422–429.
56. Dimovska EOF, Clibbon J, Heaton M, et al. Challenging the orthodoxy of mandibular reconstructions comparing functional outcomes in osseous versus soft tissue reconstructions of the posterolateral mandible. *J Reconstr Microsurg*. 2020;36:21–27.