

International Consensus Statement on Allergy and Rhinology: Sinonasal Tumors

Edward C. Kuan MD, MBA¹  | Eric W. Wang MD²  | Nithin D. Adappa MD³ | Daniel M. Beswick MD⁴  | Nyall R. London Jr. MD, PhD^{5,6} | Shirley Y. Su MBBS⁷ | Marilene B. Wang MD⁴  | Waleed M. Abuzeid MD⁸ | Borislav Alexiev MD⁹ | Jeremiah A. Alt MD, PhD¹⁰  | Paolo Antognoni MD¹¹ | Michelle Alonso-Basanta MD, PhD¹² | Pete S. Batra MD¹³ | Mihir Bhayani MD¹³ | Diana Bell MD¹⁴ | Manuel Bernal-Sprekelsen MD, PhD¹⁵ | Christian S. Betz MD, PhD¹⁶ | Jean-Yves Blay MD¹⁷ | Benjamin S. Bleier MD¹⁸  | Juliana Bonilla-Velez MD⁸ | Claudio Callejas MD^{19,20}  | Ricardo L. Carrau MD, MBA²⁰ | Roy R. Casiano MD²¹ | Paolo Castelnuovo MD, FACS, FRCS(Ed)²² | Rakesh K. Chandra MD, MMHC²³ | Vasileios Chatzinakis MD, MSc²⁴ | Simon B. Chen MD²⁵ | Alexander G. Chiu MD²⁶ | Garret Choby MD²⁷  | Naweed I. Chowdhury MD²³ | Martin J. Citardi MD²⁸ | Marc A. Cohen MD, MPH²⁹ | Roi Dagan MD, MS³⁰ | Gianluca Dalfino MD²²  | Iacopo Dallan MD, PhD³¹ | Camila Soares Dassi MD³² | John de Almeida MD, MSc, FRCSC³³ | Angelo P. Dei Tos MD³⁴ | John M. DelGaudio MD³⁵ | Charles S. Ebert MD, MPH³⁶ | Ivan H. El-Sayed MD³⁷ | Jean Anderson Eloy MD³⁸  | James J. Evans MD³⁹ | Christina H. Fang MD⁴⁰  | Nyssa F. Farrell MD⁴¹  | Marco Ferrari MD, PhD⁴²  | Nancy Fischbein MD⁴³ | Adam Folbe MD⁴⁴ | Wytske J. Fokkens MD, PhD⁴⁵ | Meha G. Fox MD⁴⁶ | Valerie J. Lund MS, FRCS, FRCS(Ed)⁴⁷ | Gary L. Gallia MD, PhD⁴⁸ | Paul A. Gardner MD⁴⁹ | Mathew Geltzeiler MD⁵⁰ | Christos Georgalas PhD, DLO, MRCS(Ed), FRCS(ORL-HNS)⁵¹  | Anne E. Getz MD⁵² | Satish Govindaraj MD⁵³ | Stacey T. Gray MD⁵⁴ | Jessica W. Grayson MD⁵⁵  | Bradley A. Gross MD⁴⁹ | Jordon G. Grube DO⁵⁶ | Ruifeng Guo MD, PhD⁵⁷ | Patrick K. Ha MD³⁷ | Ashleigh A. Halderman MD⁵⁸ | Ehab Y. Hanna MD⁷ | Richard J. Harvey MD⁵⁹  | Stephen C. Hernandez MD⁶⁰ | Adam L. Holtzman MD⁶¹ | Claire Hopkins MD, PhD⁶²  | Zhigang Huang MD⁶³ | Zhenxiao Huang MD, PhD⁶³ | Ian M. Humphreys DO⁸  | Peter H. Hwang MD⁶⁴  | Alfred M. Iloreta MD⁵³ | Masaru Ishii MD, PhD⁵ | Michael E. Ivan MD, MBS, FAANS⁶⁵ | Aria Jafari MD⁸  |

This is an open access article under the terms of the Creative Commons Attribution-NonCommercial-NoDerivs License, which permits use and distribution in any medium, provided the original work is properly cited, the use is non-commercial and no modifications or adaptations are made.

© 2023 The Authors. *International Forum of Allergy & Rhinology* published by Wiley Periodicals LLC on behalf of American Academy of Otolaryngic Allergy and American Rhinologic Society.

David W. Kennedy MD³ | Mohemmed Khan MD⁵³ | Adam J. Kimple MD, PhD³⁶ |
Todd T. Kingdom MD⁵² | Anna Knisely MD⁶⁶ | Ying-Ju Kuo MD⁶⁷ |
Devyani Lal MD²⁷ | Eric D. Lamarre MD⁶⁸ | Ming-Ying Lan MD, PhD⁶⁹ |
Hien Le MD⁷⁰ | Matt Lechner MD, PhD⁷¹ | Nancy Y. Lee MD⁷² |
Jivianne K. Lee MD⁷³ | Victor H. Lee MD, FRCR⁷⁴ | Corinna G. Levine MD, MPH²¹ |
Jin-Ching Lin MD, PhD⁷⁵ | Derrick T. Lin MD⁵⁴ | Brian C. Lobo MD⁷⁶ |
Tran Locke MD⁴⁶ | Amber U. Luong MD, PhD²⁸ | Kelly R. Magliocca DDS, MPH⁷⁷ |
Svetomir N. Markovic MD, PhD⁷⁸ | Gesa Matnjani MD⁷⁹ | Erin L. McKean MD, MBA,
FACS⁸⁰ | Cem Meço MD^{81,82} | William M. Mendenhall MD³⁰ |
Loren Michel MD⁸³ | Shorook Na'ara MD, PhD³⁷ | Piero Nicolai MD⁴² |
Daniel W. Nuss MD⁶⁰ | Gurston G. Nyquist MD⁸⁴ | Gretchen M. Oakley MD¹⁰ |
Kazuhiro Omura MD, PhD⁸⁵ | Richard R. Orlandi MD, MBA¹⁰ |
Nobuyoshi Otori MD, PhD⁸⁵ | Peter Papagiannopoulos MD¹³ | Zara M. Patel MD⁶⁴ |
David G. Pfister MD⁸³ | Jack Phan MD, PhD⁸⁶ | Alkis J. Psaltis MD, PhD⁸⁷ |
Mindy R. Rabinowitz MD⁸⁴ | Murugappan Ramanathan Jr. MD⁵ |
Ryan Rimmer MD⁸⁸ | Marc R. Rosen MD⁸⁴ | Olabisi Sanusi MD⁸⁹ |
Zoukaa B. Sargi MD²¹ | Philippe Schafhausen MD⁹⁰ | Rodney J. Schlosser MD⁹¹ |
Ahmad R. Sedaghat MD, PhD⁹² | Brent A. Senior MD³⁶ | Raj Shrivastava MD⁹³ |
Raj Sindwani MD⁶⁸ | Timothy L. Smith MD⁵⁰ | Kristine A. Smith MD, FRCSC⁹⁴ |
Carl H. Snyderman MD, MBA¹ | C. Arturo Solares MD³⁵ | Satyan B. Sreenath MD⁹⁵ |
Aldo Stamm MD, PhD³² | Katharina Stölzel MD¹⁶ | Baran Sumer MD⁵⁸ |
Pavol Surda MD⁶² | Bobby A. Tajudeen MD¹³ | Lester D. R. Thompson MD⁹⁶ |
Brian D. Thorp MD³⁶ | Charles C. L. Tong MD³ | Raymond K. Tsang MS, FRCSEd⁹⁷ |
Justin H. Turner MD, PhD²³ | Mario Turri-Zanoni MD, PhD²² | Aaron M. Udager MD,
PhD⁹⁸ | Thibaut van Zele MD, PhD⁹⁹ | Kyle VanKoeving MD²⁰ |
Kevin C. Welch MD¹⁰⁰ | Sarah K. Wise MD, MSCR³⁵ | Ian J. Witterick MSc, MD¹⁰¹ |
Tae-Bin Won MD, PhD¹⁰² | Stephanie N. Wong FRCSEd¹⁰³ |
Bradford A. Woodworth MD⁵⁵ | Peter-John Wormald MD⁸⁷ |
William C. Yao MD²⁸ | Chien-Fu Yeh MD, PhD⁶⁹ | Bing Zhou MD⁶³ |
James N. Palmer MD³

¹Departments of Otolaryngology–Head and Neck Surgery and Neurological Surgery, University of California, Irvine, Orange, California, USA

²Department of Otolaryngology, University of Pittsburgh Medical Center, Pittsburgh, Pennsylvania, USA

³Department of Otorhinolaryngology–Head and Neck Surgery, Perelman School of Medicine, University of Pennsylvania, Philadelphia, Pennsylvania, USA

⁴Department of Otolaryngology–Head and Neck Surgery, University of California Los Angeles, Los Angeles, California, USA

⁵Department of Otolaryngology–Head and Neck Surgery, Johns Hopkins University School of Medicine, Baltimore, Maryland, USA

⁶Sinonasal and Skull Base Tumor Program, Surgical Oncology Program, Center for Cancer Research, National Cancer Institute, National Institutes of Health, Bethesda, Maryland, USA

⁷Department of Head and Neck Surgery, The University of Texas MD Anderson Cancer Center, Houston, Texas, USA

⁸Department of Otolaryngology–Head and Neck Surgery, University of Washington, Seattle, Washington, USA

- ⁹Department of Pathology, Northwestern University Feinberg School of Medicine, Northwestern Memorial Hospital, Chicago, Illinois, USA
- ¹⁰Department of Otolaryngology–Head and Neck Surgery, University of Utah, Salt Lake City, Utah, USA
- ¹¹Division of Radiation Oncology, University of Insubria, ASST Sette Laghi Hospital, Varese, Italy
- ¹²Department of Radiation Oncology, University of Pennsylvania, Perelman School of Medicine, Philadelphia, Pennsylvania, USA
- ¹³Department of Otorhinolaryngology–Head and Neck Surgery, Rush University Medical Center, Chicago, Illinois, USA
- ¹⁴Department of Pathology, City of Hope Comprehensive Cancer Center, Duarte, California, USA
- ¹⁵Otorhinolaryngology Department, Surgery and Medical-Surgical Specialties Department, Faculty of Medicine and Health Sciences, Universitat de Barcelona, Barcelona, Spain
- ¹⁶Department of Otorhinolaryngology, University Medical Center Hamburg-Eppendorf, Hamburg, Germany
- ¹⁷Department of Medical Oncology, Centre Léon Bérard, UNICANCER, Université Claude Bernard Lyon I, Lyon, France
- ¹⁸Department of Otolaryngology–Head and Neck Surgery, Harvard Medical School, Boston, Massachusetts, USA
- ¹⁹Department of Otolaryngology, Pontificia Universidad Católica de Chile, Santiago, Chile
- ²⁰Department of Otolaryngology–Head and Neck Surgery, The Ohio State University, Columbus, Ohio, USA
- ²¹Department of Otolaryngology–Head and Neck Surgery, University of Miami Miller School of Medicine, Miami, Florida, USA
- ²²Division of Otorhinolaryngology, Department of Biotechnology and Life Sciences, University of Insubria, ASST Sette Laghi Hospital, Varese, Italy
- ²³Department of Otolaryngology–Head and Neck Surgery, Vanderbilt University Medical Center, Nashville, Tennessee, USA
- ²⁴Department of Head, Neck and Skull Base Surgery, Hygeia Hospital, Athens, Greece
- ²⁵Department of Pathology, Stanford University, Stanford, California, USA
- ²⁶Department of Otolaryngology–Head and Neck Surgery, University of Kansas Medical Center, Kansas City, Kansas, USA
- ²⁷Department of Otolaryngology–Head and Neck Surgery, Mayo Clinic, Rochester, Minnesota, USA
- ²⁸Department of Otorhinolaryngology–Head & Neck Surgery, McGovern Medical School, The University of Texas Health Science Center at Houston, Houston, Texas, USA
- ²⁹Department of Surgery, Head and Neck Service, Memorial Sloan Kettering Cancer Center, New York, New York, USA
- ³⁰Department of Radiation Oncology, University of Florida College of Medicine, Jacksonville, Florida, USA
- ³¹Department of Otolaryngology–Head and Neck Surgery, Pisa University Hospital, Pisa, Italy
- ³²São Paulo ENT Center (COF), Edmundo Vasconcelos Complex, São Paulo, Brazil
- ³³Department of Otolaryngology–Head and Neck Surgery, University Health Network, University of Toronto, Toronto, Ontario, Canada
- ³⁴Section of Pathology, Department of Medicine, University of Padua, Padua, Italy
- ³⁵Department of Otolaryngology–Head and Neck Surgery, Emory University School of Medicine, Atlanta, Georgia, USA
- ³⁶Department of Otolaryngology–Head and Neck Surgery, University of North Carolina at Chapel Hill, Chapel Hill, North Carolina, USA
- ³⁷Department of Otolaryngology–Head and Neck Surgery, University of California, San Francisco, California, USA
- ³⁸Department of Otolaryngology–Head and Neck Surgery, Rutgers New Jersey Medical School, Newark, New Jersey, USA
- ³⁹Department of Neurological Surgery and Otolaryngology–Head and Neck Surgery, Thomas Jefferson University, Philadelphia, Pennsylvania, USA
- ⁴⁰Department of Otorhinolaryngology–Head and Neck Surgery, Montefiore Medical Center, The University Hospital for Albert Einstein College of Medicine, Bronx, New York, USA
- ⁴¹Department of Otolaryngology–Head and Neck Surgery, Washington University in St. Louis, St. Louis, Missouri, USA
- ⁴²Section of Otorhinolaryngology–Head and Neck Surgery, Department of Neurosciences, University of Padua, Padua, Italy
- ⁴³Department of Radiology, Stanford University, Stanford, California, USA
- ⁴⁴Department of Otolaryngology–Head and Neck Surgery, Oakland University William Beaumont School of Medicine, Royal Oak, Michigan, USA
- ⁴⁵Department of Otorhinolaryngology, Amsterdam UMC, Amsterdam, The Netherlands
- ⁴⁶Department of Otolaryngology–Head and Neck Surgery, Baylor College of Medicine, Houston, Texas, USA
- ⁴⁷Ear Institute, University College London, London, UK
- ⁴⁸Department of Neurosurgery, Johns Hopkins University School of Medicine, Baltimore, Maryland, USA
- ⁴⁹Department of Neurological Surgery, University of Pittsburgh Medical Center, Pittsburgh, Pennsylvania, USA
- ⁵⁰Department of Otolaryngology–Head and Neck Surgery, Oregon Health and Science University, Portland, Oregon, USA
- ⁵¹Department of Otorhinolaryngology–Head and Neck Surgery, University of Nicosia Medical School, Nicosia, Cyprus
- ⁵²Department of Otolaryngology–Head and Neck Surgery, University of Colorado, Aurora, Colorado, USA
- ⁵³Department of Otolaryngology–Head and Neck Surgery, Icahn School of Medicine at Mount Sinai, New York, New York, USA
- ⁵⁴Department of Otolaryngology–Head and Neck Surgery, Massachusetts Eye and Ear Infirmary, Boston, Massachusetts, USA
- ⁵⁵Department of Otolaryngology–Head and Neck Surgery, University of Alabama at Birmingham, Birmingham, Alabama, USA
- ⁵⁶Department of Otolaryngology–Head and Neck Surgery, Albany Medical Center, Albany, New York, USA

- ⁵⁷Department of Laboratory Medicine and Pathology, Mayo Clinic, Rochester, Minnesota, USA
- ⁵⁸Department of Otolaryngology–Head and Neck Surgery, The University of Texas Southwestern Medical Center, Dallas, Texas, USA
- ⁵⁹Rhinology and Skull Base Research Group, Applied Medical Research Centre, University of South Wales, Sydney, New South Wales, Australia
- ⁶⁰Department of Otolaryngology–Head and Neck Surgery, LSU Health Sciences Center, New Orleans, Louisiana, USA
- ⁶¹Department of Radiation Oncology, Mayo Clinic Florida, Jacksonville, Florida, USA
- ⁶²Department of Otolaryngology–Head and Neck Surgery, Guys and St Thomas' Hospital, London, UK
- ⁶³Department of Otolaryngology–Head and Neck Surgery, Beijing Tongren Hospital, Capital Medical University, Key Laboratory of Otolaryngology–Head and Neck Surgery, Ministry of Education, Beijing, China
- ⁶⁴Department of Otolaryngology–Head and Neck Surgery, Stanford University School of Medicine, Stanford, California, USA
- ⁶⁵Department of Neurological Surgery, University of Miami Miller School of Medicine, Miami, Florida, USA
- ⁶⁶Department of Otolaryngology, Head and Neck Surgery, Swedish Medical Center, Seattle, Washington, USA
- ⁶⁷Department of Pathology, Taipei Veterans General Hospital, Taipei, Taiwan
- ⁶⁸Head and Neck Institute, Cleveland Clinic Lerner College of Medicine, Cleveland Clinic, Cleveland, Ohio, USA
- ⁶⁹Department of Otorhinolaryngology–Head and Neck Surgery, Taipei Veterans General Hospital, Taipei, Taiwan
- ⁷⁰Department of Radiation Oncology, Royal Adelaide Hospital, Adelaide, South Australia, Australia
- ⁷¹UCL Division of Surgery and Interventional Science and UCL Cancer Institute, University College London, London, UK
- ⁷²Department of Radiation Oncology, Memorial Sloan Kettering Cancer Center, New York, New York, USA
- ⁷³Department of Head and Neck Surgery, University of California, Los Angeles David Geffen School of Medicine, Los Angeles, California, USA
- ⁷⁴Department of Clinical Oncology, School of Clinical Medicine, LKS Faculty of Medicine, The University of Hong Kong, Hong Kong SAR, China
- ⁷⁵Department of Radiation Oncology, Changhua Christian Hospital, Changhua, Taiwan
- ⁷⁶Department of Otolaryngology–Head and Neck Surgery, University of Florida, Gainesville, Florida, USA
- ⁷⁷Department of Pathology and Laboratory Medicine, Emory University School of Medicine, Atlanta, Georgia, USA
- ⁷⁸Division of Medical Oncology, Department of Oncology, Mayo Clinic, Rochester, Minnesota, USA
- ⁷⁹Department of Radiation Oncology, University Medical Center Hamburg-Eppendorf, Hamburg, Germany
- ⁸⁰Department of Otolaryngology–Head and Neck Surgery, University of Michigan, Ann Arbor, Michigan, USA
- ⁸¹Department of Otorhinolaryngology, Head and Neck Surgery, Ankara University Medical School, Ankara, Turkey
- ⁸²Department of Otorhinolaryngology Head and Neck Surgery, Salzburg Paracelsus Medical University, Salzburg, Austria
- ⁸³Department of Medicine, Memorial Sloan Kettering Cancer Center, New York, New York, USA
- ⁸⁴Department of Otolaryngology–Head and Neck Surgery, Thomas Jefferson University, Philadelphia, Pennsylvania, USA
- ⁸⁵Department of Otorhinolaryngology, The Jikei University School of Medicine, Tokyo, Japan
- ⁸⁶Department of Radiation Oncology, The University of Texas MD Anderson Cancer Center, Houston, Texas, USA
- ⁸⁷Department of Otolaryngology–Head and Neck Surgery, Queen Elizabeth Hospital, Adelaide, South Australia, Australia
- ⁸⁸Department of Otolaryngology–Head and Neck Surgery, Yale University, New Haven, Connecticut, USA
- ⁸⁹Department of Neurosurgery, Oregon Health and Science University, Portland, Oregon, USA
- ⁹⁰Department of Hematology and Oncology, University Medical Center Hamburg-Eppendorf, Hamburg, Germany
- ⁹¹Department of Otolaryngology–Head and Neck Surgery, Medical University of South Carolina, Charleston, South Carolina, USA
- ⁹²Department of Otolaryngology–Head and Neck Surgery, University of Cincinnati College of Medicine, Cincinnati, Ohio, USA
- ⁹³Department of Neurosurgery and Otolaryngology–Head and Neck Surgery, Icahn School of Medicine at Mount Sinai, New York, New York, USA
- ⁹⁴Department of Otolaryngology–Head and Neck Surgery, University of Manitoba, Winnipeg, Manitoba, Canada
- ⁹⁵Department of Otolaryngology–Head and Neck Surgery, Indiana University, Indianapolis, Indiana, USA
- ⁹⁶Head and Neck Pathology Consultations, Woodland Hills, California, USA
- ⁹⁷Department of Otolaryngology–Head and Neck Surgery, Yong Loo Lin School of Medicine, National University of Singapore, Singapore, Singapore
- ⁹⁸Department of Pathology, Michigan Center for Translational Pathology, Rogel Cancer Center, University of Michigan, Ann Arbor, Michigan, USA
- ⁹⁹Department of Otorhinolaryngology, Ghent University Hospital, Ghent, Belgium
- ¹⁰⁰Department of Otolaryngology–Head and Neck Surgery, Northwestern University Feinberg School of Medicine, Chicago, Illinois, USA
- ¹⁰¹Department of Otolaryngology–Head and Neck Surgery, University of Toronto, Toronto, Ontario, Canada
- ¹⁰²Department of Otorhinolaryngology–Head and Neck Surgery, Seoul National University Hospital, Seoul National University College of Medicine, Seoul, South Korea

¹⁰³Division of Otorhinolaryngology, Department of Surgery, School of Clinical Medicine, LKS Faculty of Medicine, The University of Hong Kong, Hong Kong SAR, China

Consultant Authors

Arash Abiri, MS¹, Carrie D. Adams, MA, LIS², Noel F. Ayoub, MD, MBA³, Benjamin F. Bitner, MD⁴, Jacob T. Boyd, MD, PhD⁵, Michael T. Chang, MD⁶, Nikita Chapurin, MD, MHS⁷, Mark B. Chaskes, MD, MBA⁸, Andy Chua, MD⁹, Sei Y. Chung, MD¹⁰, Kevin J. Contrera, MD, MPH¹¹, Katelyn K. Dilley, BS¹², André Zanette Dutra, MD¹³, Jacob G. Eide, MD¹⁴, Rachel Fenberg, BS¹⁵, Neal R. Godse, MD¹⁶, Basit Jawad, MD¹⁷, Jared Johnson, MD¹⁸, B. Jake Johnson, MD¹⁹, Ryan Judd, MD²⁰, Sarah Khalife, MD²¹, Pooya Khosravi, BS²², Mirko Manojlovic Kolarski, MD²³, Keonho A. Kong, MD²⁴, Rijul S. Kshirsagar, MD²⁵, Joseph S. Lee, MD²⁶, Tian-Yun Lin, MD²⁷, Justin P. McCormick, MD²⁸, Katie Melder, MD²⁹, Elliot Morse, MD, MHS³⁰, Theodore V. Nguyen, BS³¹, Timothy G. Norwood, MD³², Jonathan C. Pang, MS³³, Sean M. Parsel, DO³⁴, Prayag S. Patel, MD³⁵, Barak Ringel, MD³⁶, Alexander L. Schneider, MD³⁷, Daniel B. Spielman, MD³⁸, Todd Spock, MD³⁹, Milind Vasudev, BS⁴⁰

Consultant Author Affiliations

¹Otolaryngology–Head and Neck Surgery, Department of Otolaryngology–Head and Neck Surgery, University of California, Irvine, Orange, CA, USA; ²Library Sciences, University of Florida Health Science Center Library, Jacksonville, FL, USA; ³Otolaryngology–Head and Neck Surgery, Department of Otolaryngology–Head and Neck Surgery, Stanford University School of Medicine, Stanford, CA, USA; ⁴Otolaryngology–Head and Neck Surgery, Department of Otolaryngology–Head and Neck Surgery, University of California, Irvine, Orange, CA, USA; ⁵Otolaryngology–Head and Neck Surgery, Department of Otolaryngology–Head and Neck Surgery, University of Colorado, Aurora, CO, USA; ⁶Otolaryngology–Head and Neck Surgery, Department of Otolaryngology–Head and Neck Surgery, Stanford University School of Medicine, Stanford, CA, USA; ⁷Otolaryngology–Head and Neck Surgery, Department of Otolaryngology–Head and Neck Surgery, Medical University of South Carolina, Charleston, SC, USA; ⁸Otolaryngology–Head and Neck Surgery, Department of Otolaryngology, Zucker School of Medicine at Hofstra/Northwell, Babylon, NY, USA; ⁹Otolaryngology–Head and Neck Surgery, Department of Otorhinolaryngology, Sengkang General Hospital, Singapore, Singapore; ¹⁰Otolaryngology–Head and Neck Surgery, Department of Otolaryngology–Head and Neck Surgery, The University of Texas Southwestern Medical Center, Dallas, TX, USA; ¹¹Otolaryngology–Head and Neck Surgery, Department of Head and Neck Surgery, The University of Texas MD Anderson Cancer Center, Houston, TX, USA; ¹²Otolaryngology–Head and Neck Surgery, Department of Otolaryngology–Head and Neck Surgery, University of California, Irvine, Orange, CA, USA; ¹³Otolaryngology–Head and Neck Surgery, Center (COF), Edmundo Vasconcelos Complex, São Paulo ENT, São Paulo, Brazil; ¹⁴Otolaryngology–Head and Neck Surgery, Department of Otolaryngology, Henry Ford Health, Detroit, MI, USA; ¹⁵Otolaryngology–Head and Neck Surgery, Albert Einstein College of Medicine, Bronx, NY, USA; ¹⁶Otolaryngology–Head and Neck Surgery, Department of Otolaryngology, University of Pittsburgh Medical Center, Pittsburgh, PA, USA; ¹⁷Otolaryngology–Head and Neck Surgery, Department of Otolaryngology–Head and Neck Surgery, The Ohio State University, Columbus, OH, USA; ¹⁸Otolaryngology–Head and Neck Surgery, Department of Otolaryngology–Head and Neck Surgery, University of Miami Miller School of Medicine, Miami, FL, USA; ¹⁹Otolaryngology–Head and Neck Surgery, Department of Otolaryngology–Head and Neck Surgery, Mayo Clinic, Rochester, MN, USA; ²⁰Otolaryngology–Head and Neck Surgery, Department of Otolaryngology–Head and Neck Surgery, The Ohio State University, Columbus, OH, USA; ²¹Otolaryngology–Head and Neck Surgery, Division of Otolaryngology–Head and Neck Surgery, Department of Surgery, McMaster University, Hamilton, ON, Canada; ²²Otolaryngology–Head and Neck Surgery, Department of Otolaryngology–Head and Neck Surgery, University of California, Irvine, Orange, CA, USA; ²³Otolaryngology–Head and Neck Surgery, Department of Otolaryngology–Head and Neck Surgery, University of Toronto, Toronto, ON, Canada; ²⁴Otolaryngology–Head and Neck Surgery, Department of Otolaryngology–Head and Neck Surgery, University of Mississippi Medical Center, Jackson, MS, USA; ²⁵Otolaryngology–Head and Neck Surgery, Department of Head and Neck Surgery, Kaiser Permanente Redwood City Medical Center, Redwood City, CA, USA; ²⁶Otolaryngology–Head and Neck Surgery, Department of Otolaryngology–Head and Neck Surgery, The Ohio State University, Columbus, OH, USA; ²⁷Otolaryngology–Head and Neck Surgery, Department of Otorhinolaryngology –Head and Neck Surgery, Taichung Veterans General Hospital, Taichung, Taiwan; ²⁸Otolaryngology–Head and Neck Surgery, Department of Otolaryngology–Head and Neck Surgery, Rutgers Robert Wood Johnson Medical School, New Brunswick, NJ, USA; ²⁹Otolaryngology–Head and Neck Surgery, Department of Otolaryngology–Head and Neck Surgery, Oregon Health and Science University, Portland, OR, USA; ³⁰Otolaryngology–Head and Neck Surgery, Department of Surgery, Head and Neck Service, Memorial Sloan Kettering Cancer Center, New York, NY, USA; ³¹Otolaryngology–Head and Neck Surgery, Department of Otolaryngology–Head and Neck Surgery, University of California, Irvine, Orange, CA, USA; ³²Otolaryngology–Head and Neck Surgery, Department of Otolaryngology–Head and Neck Surgery, University of Alabama at Birmingham, Birmingham, AL, USA; ³³Otolaryngology–Head and Neck Surgery, Department of Otolaryngology–Head and

Neck Surgery, University of California, Irvine, Orange, CA, USA; ³⁴Otolaryngology–Head and Neck Surgery, Department of Otolaryngology–Head and Neck Surgery, Thomas Jefferson University, Philadelphia, PA, USA; ³⁵Otolaryngology–Head and Neck Surgery, Division of Otolaryngology–Head and Neck Surgery, Maimonides Medical Center, Brooklyn, NY, USA; ³⁶Otolaryngology–Head and Neck Surgery, Department of Otolaryngology–Head and Neck Surgery, Massachusetts Eye and Ear Infirmary, Boston, MA, USA; ³⁷Otolaryngology–Head and Neck Surgery, Department of Otolaryngology–Head and Neck Surgery, Northwestern University Feinberg School of Medicine, Chicago, IL, USA; ³⁸Otolaryngology–Head and Neck Surgery, Department of Otolaryngology–Head and Neck Surgery, New York Presbyterian Hospital, New York, NY, USA; ³⁹Otolaryngology–Head and Neck Surgery, Department of Otolaryngology–Head and Neck Surgery, Icahn School of Medicine at Mount Sinai, New York, NY, USA; ⁴⁰Otolaryngology–Head and Neck Surgery, Department of Otolaryngology–Head and Neck Surgery, University of California, Irvine, Orange, CA, USA

Correspondence

Edward C. Kuan, Departments of Otolaryngology–Head and Neck Surgery and Neurological Surgery, University of California, Irvine, 101 The City Dr South, Orange, CA 92868, USA.
Email: eckuan@uci.edu

Abstract

Background: Sinonasal neoplasms, whether benign and malignant, pose a significant challenge to clinicians and represent a model area for multidisciplinary collaboration in order to optimize patient care. The International Consensus Statement on Allergy and Rhinology: Sinonasal Tumors (ICSNT) aims to summarize the best available evidence and presents 48 thematic and histopathology-based topics spanning the field.

Methods: In accordance with prior International Consensus Statement on Allergy and Rhinology documents, ICSNT assigned each topic as an Evidence-Based Review with Recommendations, Evidence-Based Review, and Literature Review based on the level of evidence. An international group of multidisciplinary author teams were assembled for the topic reviews using the Preferred Reporting Items for Systematic Reviews and Meta-Analyses format, and completed sections underwent a thorough and iterative consensus-building process. The final document underwent rigorous synthesis and review prior to publication.

Results: The ICSNT document consists of four major sections: general principles, benign neoplasms and lesions, malignant neoplasms, and quality of life and surveillance. It covers 48 conceptual and/or histopathology-based topics relevant to sinonasal neoplasms and masses. Topics with a high level of evidence provided specific recommendations, while other areas summarized the current state of evidence. A final section highlights research opportunities and future directions, contributing to advancing knowledge and community intervention.

Conclusion: As an embodiment of the multidisciplinary and collaborative model of care in sinonasal neoplasms and masses, ICSNT was designed as a comprehensive, international, and multidisciplinary collaborative endeavor. Its primary objective is to summarize the existing evidence in the field of sinonasal neoplasms and masses.

KEYWORDS

adenocarcinoma, adenoid cystic carcinoma, adjuvant therapy, angiofibroma, biopsy, chemotherapy, concurrent, endoscopic endonasal approach, esthesioneuroblastoma, evidence-based medicine, head and neck cancer, head and neck oncology, immunotherapy, induction chemotherapy, inverted papilloma, lymphoma, margins, metastases, mucosal melanoma, nasopharyngeal carcinoma, neoadjuvant therapy, neuroectodermal carcinoma, neuroendocrine carcinoma, olfactory neuroblastoma, open approach, orbit, papilloma, quality of life, radiation, resectability, rhabdomyosarcoma, risk factors, sarcoma, sinonasal cancer, sinonasal malignancy, sinonasal neoplasm, sinonasal oncology, sinonasal papilloma, sinonasal

tumor, sinonasal undifferentiated carcinoma, skull base, squamous cell carcinoma, surgery, surveillance, survival, survivorship

Table of contents

I. EXECUTIVE SUMMARY	158	B. Anatomic imaging	217
A. Introduction	158	C. Functional imaging	217
B. Methods	158	D. Biopsy	223
C. Results	159	X. SURGICAL APPROACH	224
Section 1: General principles	159	A. Squamous cell carcinoma	224
Section 2: Benign lesions and neoplasms.	165	B. Olfactory neuroblastoma.	224
Section 3: Malignant neoplasms	168	C. Adenocarcinoma.	225
Section 4: Morbidity, QOL, and surveillance.	183	D. Sinonasal sarcoma	225
D. Discussion	186	E. Sinonasal mucosal melanoma	225
II. INTRODUCTION	187	F. Overall outcomes.	227
III. METHODS	188	G. Approaches to the maxillary sinus.	233
A. Topic development.	188	XI. MANAGEMENT OF THE ORBIT	237
B. Iterative review.	189	A. Orbital structures and grading orbital invasion	237
C. ICSNT statement development	189	B. Orbital preservation versus orbital	
D. Limitations	191	exenteration	238
SECTION I: GENERAL PRINCIPLES.	191	C. Management of the nasolacrimal system and	
IV. INCIDENCE AND EPIDEMIOLOGY.	191	role of dacryocystorhinostomy.	242
V. GENERAL RISK FACTORS	193	D. Advancements in endoscopic orbital	
A. Age	193	approaches and role for open orbital	
B. Genetic sex.	193	approaches.	242
C. Ethnicity	193	XII. MARGIN ANALYSIS	243
D. Occupational exposure.	194	A. Techniques.	244
E. Smoking	197	B. Frozen sections for margin analysis	253
F. Link to viral infections	197	C. Margin status and survival.	255
G. Genetic and other inherited traits	197	XIII. MANAGEMENT OF RECURRENT	
VI. PRINCIPLES OF SURGICAL TREATMENT	201	MALIGNANCY	256
A. En Bloc versus debulking/piecemeal resection	201	A. Diagnosis of recurrent tumor	256
B. Treatment of sites of attachment.	203	B. Role of salvage surgery.	258
C. Differences between benign and malignant		C. Role of re-irradiation.	260
pathologies.	205	D. Role of palliative therapies.	260
D. Risk of tumor seeding	205	E. Differences in outcomes between primary	
VII. BIOPSY	206	and salvage treatment	262
A. Role of in-office biopsies for sinonasal lesions	207	XIV. RADIATION MODALITIES FOR	
B. Indications.	207	TREATMENT OF SINONASAL	
C. Technical considerations.	208	MALIGNANCIES	264
D. Order of imaging and biopsy.	209	A. Intensity-modulated radiotherapy	264
VIII. RESECTABILITY	209	B. Proton beam therapy.	270
A. Resectability of sinonasal tumors	209	C. Fast neutron radiotherapy	270
B. Orbital apex involvement	210	D. Carbon ion radiotherapy.	273
C. Carotid artery involvement	210	SECTION II: BENIGN LESIONS AND NEOPLASMS	279
D. Skull base involvement	211	XV. BENIGN MASS-OCCUPYING LESIONS	279
E. Pterygopalatine and infratemporal fossa		A. Hamartomas.	279
involvement	213	1. Respiratory epithelial adenomatoid	
IX. WORKUP OF REGIONAL AND DISTANT		hamartoma	279
DISEASE.	213	2. Chondro-osseous respiratory epithelial	
A. Retropharyngeal lymphadenopathy	216	adenomatoid hamartoma	280
		3. Nasal chondromesenchymal hamartoma.	280

B. Nasolabial cysts	280	A. De novo sinonasal squamous cell carcinoma	334
C. Antrochoanal polyps.	281	1. Background and epidemiology	334
XVI. SINONASAL PAPILLOMAS	281	2. Pathologic features	335
A. Exophytic papilloma.	282	3. Staging and imaging	336
B. Oncocytic papilloma	282	4. Treatment and outcomes	336
C. Inverted papilloma.	282	B. Inverted papilloma-transformed squamous	
D. Dysplasia and risk of malignant		cell carcinoma	343
transformation.	282	1. Survival outcomes of IP-SCC versus	
E. Role of orbital or skull base bony resection .	291	DN-SCC	343
F. Role of radiation or medical therapy	293	2. Imaging to predict malignant	
G. Treatment of site of attachment	293	transformation.	344
H. Recurrence and surveillance.	298	3. Histopathology and molecular and genetic	
XVII. BENIGN VASCULAR NEOPLASMS AND		studies	344
LESIONS.	302	XXII. MINOR SALIVARY GLAND TUMORS OF	
A. Juvenile nasopharyngeal angiofibroma . . .	302	THE SINONASAL TRACT.	347
1. Open versus endoscopic approaches . . .	303	A. Intestinal-type adenocarcinoma	347
2. Staging systems.	305	1. Tumor subtypes and grade	347
3. Patterns of recurrence and natural history	305	B. Role of surgery	350
4. Trigeminal function	308	1. Role of adjuvant therapy	351
5. Techniques for hemostasis	310	2. Surveillance, recurrence, and outcomes .	351
6. Role of nonsurgical therapy	310	C. Nonintestinal-type adenocarcinoma	355
B. Vascular malformations, hemangiomas, and		1. Clinical presentation, epidemiology, risk	
paragangliomas	310	factors	355
1. Hemangioma	310	2. Histopathology	356
2. Arteriovenous malformations	312	3. IHC and molecular profiling	356
3. Venous malformations	314	4. Renal cell-like adenocarcinoma	356
4. Paragangliomas.	314	5. Role of surgery	356
XVIII. CONGENITAL MIDLINE NASAL MASSES	315	6. Role of chemoradiation therapy	358
A. Introduction	315	7. Recurrence and survival	358
B. Dermoid and epidermoid cysts.	316	D. Adenoid cystic carcinoma	360
C. Nasal glial heterotopia	316	1. Role and extent of surgery	360
D. Meningoencephaloceles	316	2. Role of radiation therapy	364
E. Role of imaging	317	3. Role of chemotherapy	365
F. Management	318	E. Other salivary gland malignancies.	365
XIX. BENIGN ORBITAL TUMORS AND LESIONS	318	1. Mucoepidermoid carcinoma	365
A. Benign orbital lesions—infraconal	318	2. Acinic cell carcinoma.	367
1. Efficacy of tumor resection	320	XXIII. SINONASAL SARCOMA	368
2. Complications	324	A. Rhabdomyosarcoma	368
B. Other benign orbital lesions	324	1. Classification and staging.	369
1. IgG4-related ophthalmic disease	324	2. Role of surgery in pediatric	
2. Tolosa–Hunt syndrome.	329	rhabdomyosarcoma	369
XX. OTHER RARE BENIGN NEOPLASMS AND		3. Role of radiation therapy in pediatric	
LESIONS.	329	rhabdomyosarcoma	369
A. Rosai–Dorfman disease	329	4. Role of chemotherapy in pediatric	
B. Lipomas	330	rhabdomyosarcoma	370
C. Pleomorphic adenoma.	330	5. Role of surgery in adult	
D. Phosphaturic mesenchymal tumors	331	rhabdomyosarcoma	374
E. Solitary fibrous tumor	331	6. Role of chemoradiation therapy in adult	
F. Glomangiopericytoma	332	rhabdomyosarcoma	374
G. Eosinophilic angiocentric fibrosis	333	7. Induction chemotherapy for sinonasal	
SECTION III: MALIGNANT NEOPLASMS	334	rhabdomyosarcoma	377
XXI. SINONASAL SQUAMOUS CELL		B. Sinonasal chondrosarcoma and osteosarcoma	377
CARCINOMA	334	1. Chondrosarcoma	378

2. Osteosarcoma	380	9. Role of concurrent chemoradiation therapy	439
C. Other sarcomas	384	10. Role of induction/neoadjuvant chemotherapy	442
1. Fibrosarcoma	385	11. Role of adjuvant chemotherapy	444
2. Biphenotypic sinonasal sarcoma	385	12. Treatment for metastatic disease	446
3. Leiomyosarcoma	385	B. Low-grade nasopharyngeal papillary adenocarcinoma	451
4. Angiosarcoma	386	XXVI. SINONASAL LYMPHOMA	453
5. Ewing sarcoma	386	A. B and T cell lymphomas	453
6. Synovial sarcoma	386	B. Diagnostic considerations	453
7. Malignant peripheral nerve sheath tumor	386	C. Imaging for lymphoma	460
XXIV. SINONASAL NEUROECTODERMAL AND NEUROENDOCRINE CARCINOMAS	387	D. Histopathology	460
A. Olfactory neuroblastoma	387	E. B-cell sinonasal lymphoma treatment	461
1. Impact of Hyams grade on outcomes	387	1. Role of chemotherapy	461
2. Staging systems	387	2. Role of radiation therapy	464
3. Management of the neck	390	3. Role of immunotherapy	465
4. Management of the orbit	393	F. Extranodal natural killer/T-cell sinonasal lymphoma treatment	466
5. Unilateral resection and smell preservation	394	G. Extramedullary plasmacytoma	472
6. Role of radiation therapy	395	1. Presentation	472
7. Role of systemic therapy	395	2. Workup	473
B. Sinonasal undifferentiated carcinoma and variants	401	3. Treatment	473
1. Sinonasal undifferentiated carcinoma	401	4. Prognosis and outcomes	473
2. NUT carcinoma	403	XXVII. METASTATIC TUMORS	474
3. SWI/SNF complex-deficient sinonasal carcinomas	406	XXVIII. OTHER MALIGNANT LESIONS	475
C. Neuroendocrine carcinoma	408	A. Germ cell tumors	475
1. Clinical presentation, epidemiology, and specific risk factors	408	B. Carcinosarcoma	476
2. Molecular profiling, histologic subtypes, and impact of grade	408	C. Teratocarcinosarcoma	476
3. Workup and staging	408	SECTION IV: MORBIDITY, QUALITY OF LIFE, AND SURVEILLANCE	477
4. Treatment strategies	409	XXIX. RISK FACTORS FOR SURGICAL COMPLICATIONS	477
5. Recurrence and survival	409	A. Primary surgery	477
D. Sinonasal mucosal melanoma	410	B. Patient and demographic factors	478
1. Survival and prognostic factors	411	C. Types of approach	478
2. Histopathologic findings	411	D. Salvage surgery	478
3. Surgical resection	411	XXX. QUALITY OF LIFE INSTRUMENTS	478
4. Impact of cutaneous melanoma markers and genetic mutations	415	A. Skull base QOL instruments	481
5. Impact of PD-L1 and immunotherapy	415	B. Head and neck cancer QOL instruments	482
6. Role of neck treatment	419	C. Nasopharyngeal carcinoma QOL instruments	482
7. Role of radiation therapy	421	XXXI. QUALITY OF LIFE FOR SINONASAL NEOPLASMS	483
XXV. NASOPHARYNGEAL MALIGNANCIES	423	A. Quality of life for benign neoplasms	483
A. Nasopharyngeal carcinoma	423	1. Baseline and postoperative QOL differences	483
1. WHO subtypes	423	2. Differences between benign and malignant neoplasms	489
2. The role of EBV in NPC	424	3. Morbidity related to extended maxillary approaches	489
3. The role of HPV in NPC	428	B. Quality of life for malignant neoplasms	491
4. Role of surgery in NPC	430	1. Baseline QOL	491
5. Primary radiation therapy of the primary site	432	2. Postoperative QOL	491
6. Elective radiation treatment of the N0 neck	437		
7. Adaptive radiotherapy	438		
8. Role of proton therapy	438		

3. Morbidity related to orbital resection or orbitotomy	491
4. Morbidity related to intradural resection	496
XXXII. QOL AFTER MULTIMODALITY TREATMENT FOR SINONASAL MALIGNANCIES	496
A. General QOL following multimodality treatment	498
B. Morbidity following surgical treatment	501
C. Morbidity following radiation treatment.	506
D. Morbidity following proton therapy	507
E. Osteoradionecrosis.	507
F. Morbidity following chemotherapy	512
G. Morbidity following immunotherapy	513
XXXIII. SURVEILLANCE	513
A. Timing and schedule	513
B. Role of assessment based on physical exam, signs, and symptoms.	518
C. Role of endoscopy	519
D. Role of imaging	520
E. Differences in surveillance practices based on histology	521
F. Surveillance of sinonasal malignancies	521
G. Surveillance of inverted papilloma.	521
XXXIV. RESEARCH OPPORTUNITIES AND FUTURE DIRECTIONS	522
A. Basic/translational research opportunities	523
B. Clinical and outcomes research opportunities	524
C. Public health/policy	524
D. Diagnosis, workup, and staging	524
E. Treatment strategies	525
F. Survivorship, QOL, and long-term care	525
XXXV. CONCLUSION	526
ACKNOWLEDGMENTS	526
CONFLICT OF INTEREST STATEMENT.	526
ORCID.	526
REFERENCES.	527

I | EXECUTIVE SUMMARY

A | Introduction

Sinonasal tumors, although traditionally rare, are now increasingly recognized as a highly morbid disease. These tumors pose unique challenges due to frequent involvement of critical neurovascular structures, nonspecific signs and symptoms, and late-stage detection. Over the past decade, the field of sinonasal neoplasms and masses has grown rapidly, enhancing our knowledge of these diverse diseases. While previous literature mainly consisted of single-institution, retrospective reports, recent efforts have focused on multi-institutional studies and clinical trials,

leading to improved evidence quality. This progress has been made possible by the collaboration and knowledge sharing among various specialists, including otolaryngologists, rhinologists, head and neck oncologists, medical and radiation oncologists, pathologists, radiologists, and neurosurgeons.

In accordance with previously published consensus statements in the field of rhinology,^{1–5} the International Consensus Statement on Allergy and Rhinology: Sinonasal Tumors (ICSNT) aims to bring together a globally representative group of experts from different disciplines to provide an up-to-date summary and critical appraisal of the current evidence regarding the diagnosis, treatment, prognosis, and outcomes of benign and malignant sinonasal tumors. ICSNT serves as a complementary resource to the 2019 International Consensus Statement on Endoscopic Skull Base Surgery (ICSB)⁵ and updates the highly regarded 2010 European Position Paper (EPOS) on Endoscopic Management of Tumours of the Nose, Paranasal Sinuses and Skull Base.⁶ It is important to note that ICSNT does not serve as practice guidelines but instead offers recommendations based on the best available evidence. Ultimately, individual treatment plans will depend on the expertise and preferences of the medical and surgical team, as well as patient factors and preferences. The goal of ICSNT is to provide clinicians with a valuable resource to enhance their understanding of specific tumors and aid in the development of tailored treatment plans.

B | Methods

Using the established methodology of the prior International Consensus Statement on Allergy and Rhinology (ICAR) statements, topics encompassing the breadth of sinonasal neoplasms and masses were developed by the editorial team (JNP, ECK, EWW, NDA, DMB, NRL, SYS, MBW). These 48 topics were broadly classified under four sections: General Principles; Benign Lesions and Neoplasms; Malignant Neoplasms; and Morbidity, Quality of Life, and Surveillance. An effort was made to center on histopathology given its central role. International multidisciplinary expert authors then assembled teams and were assigned these topics. Areas of overlap with ICSB were updated and cross-referenced accordingly within the document.⁵ A rigorous systematic review process was then undertaken, which included literature review, evidence-based review (EBR), and evidence-based review with recommendations (EBRR) based on available literature (following the guidelines outlined by Rudmik and Smith⁷). All authors were instructed to follow the Preferred Reporting Items for Systematic Reviews and Meta-Analyses (PRISMA) guidelines,⁸ and an aggregate grade of evidence

was determined using the American Academy of Pediatrics Steering Committee on Quality Improvement and Management (AAP SCQIM) guidelines.⁹ Each topic underwent iterative review by at least two members of the editorial team, as well as the primary and senior editors, to ensure completeness of the literature and appropriateness of the recommendations. The compiled topics were then synthesized and distributed for review by all authors for consensus, resulting in the ICSNT document.

C | Results

Section 1: General principles

Incidence and epidemiology

Among benign sinonasal tumors, osteomas are the most common, followed by sinonasal papillomas.

Sinonasal malignancy (SNM) comprises approximately 3%–5% of all head and neck cancers and <1% of all malignancies overall. The estimated incidence of SNM in the United States is <1 case per 100,000 population per year.

Malignant epithelial neoplasms account for 75% of all SNM, with the most common being squamous cell carcinoma (SCC), followed by adenocarcinoma, olfactory neuroblastoma (esthesioneuroblastoma) (ONB), and adenoid cystic carcinoma (ACC).

General risk factors

There are various well-established risk factors for development of both benign and malignant sinonasal tumors. Careful history taking and ordering appropriate genetic and molecular tests, whenever applicable, may provide insights for patient counseling and treatment planning.

Assessment of risk factors for sinonasal tumors

Aggregate grade of evidence	<p>C for all risk factors</p> <ul style="list-style-type: none"> • Level 4: eight studies (age) • Level 3: two studies; Level 4: seven studies (genetic sex) • Level 2: one study; Level 3: five studies; Level 4: four studies (occupational exposure) • Level 3: three studies (smoking) • Level 2: two studies; Level 3: one study; Level 4: one study (link to viral infections) • Level 3: two studies; Level 4: nine studies (genetic factors)
Benefit	Understanding and screening of risk factors for tumorigenesis provide prognostic information and opportunities for prevention.

(Continued)

Harm	Recall bias of risk factors, variable risk of tumorigenesis across different individuals and populations.
Cost	No studies assessing cost, but likely low costs of screening by history. Molecular testing may be costly.
Benefits–harm assessment	Preponderance of benefits over harms.
Value judgments	Many risk factors are nonmodifiable. There is a need for further research into the role of molecular and genomic testing.
Policy level	Recommendation.
Intervention	Routine history taking and screening for risk factors such as age, sex, ethnicity, occupational exposure, and smoking may provide clinically useful prognostic information and prevention opportunities. Testing for genetic and viral etiologies may be considered, especially if there are actionable mutations.

Principles of surgical treatment

Common oncologic principles apply in surgical treatment of sinonasal tumors. Traditionally, en bloc resection of the entire tumor with negative margins, often via an open approach, comprised the standard of care, but this is challenging to perform within the confines of the sinonasal tract, especially without confirmation of tumor invasion versus abutment of structures. Consideration should be given to preserving quality of life (QOL) and critical neurovascular structures if oncologically possible. To that end, in lieu of an open approach, an alternative is endoscopic piecemeal resection and debulking of the tumor with definitive en bloc resection of the sites of attachment and assessing margins thereafter. The risk of tumor seeding is low overall.

En bloc versus debulking/piecemeal resection

Aggregate grade of evidence	C (Level 3: seven studies; Level 4: two studies)
Benefit	Piecemeal resection has the benefit of improved visualization of the tumor attachment site and determining invasion into surrounding structures. En bloc resection, whenever possible, permits gross visualization of clear margins around the resection
Harm	Piecemeal resection has the theoretical risk of tumor seeding in the cavity via violation of the tumor capsule. En bloc resection is potentially invasive and disfiguring.

(Continued)

Cost	Cost comparison analyses have not been undertaken.
Benefits-harm assessment	Balance of benefits and harms.
Value judgments	No studies have demonstrated a clear benefit of either en bloc or piecemeal resection. Since no study has found worse outcomes for piecemeal resection and improved visualization is accomplished with piecemeal resection in endoscopic endonasal approach (EEA), it is reasonable to resect sinonasal tumors in a piecemeal fashion when necessary for tumor visualization.
Policy level	Option.
Intervention	Use of en bloc versus piecemeal resection is an option based on tumor extension and sites of involvement. The decision on whether to proceed with en bloc versus piecemeal resection of sinonasal tumors should be made on a case-by-case basis. En bloc resection of the site of attachment/tumor origin should be attempted whenever possible.

Treatment of sites of attachment

Aggregate grade of evidence	C (Level 2: two studies; Level 3: one study; Level 4: three studies; Level 5: one study)
Benefit	Attachment-oriented surgery allows for accurate clearance of disease with successful oncologic outcomes while sparing uninvolved structures. Minimizing morbidity is an especially important consideration in benign sinonasal tumors. Additionally, this technique may allow for shorter operating times and facilitates observation and follow-up aimed at the pedicle attachment site.
Harm	Not all tumors are amenable to attachment-oriented surgery and the decision must be done on a case-by-case basis. It is highly surgeon dependent to accurately assess the sites of involvement or attachment. If negative margins are unable to be achieved, an open or combined approach may be necessary, especially in cases of malignant or aggressive pathologies.
Cost	Cost comparison analyses have not been undertaken.
Benefits-harm assessment	Preponderance of benefits over harms.

Value judgments	Attachment-oriented surgery is beneficial to the treatment of benign as well as malignant sinonasal tumors in select cases where adequate surgical margins can be obtained safely. In cases of locally advanced lesions, utilizing an attachment-oriented technique must be balanced with the risk of leaving residual disease or needing to convert to an open or combined approach.
Policy level	Recommendation.
Intervention	Endoscopic attachment-oriented surgery should be considered to minimize morbidity when feasible and when negative margins can likely be achieved. In cases of locally advanced disease, an open or combined approach may be necessary for disease clearance.

Risk of tumor seeding

Aggregate grade of evidence	C (Level 2: one study; Level 3: two studies; Level 5: one study)
Benefit	Careful dissection technique and close inspection can minimize risk of tumor seeding.
Harm	Spread of tumor via seeding presents a significant challenge in management often requiring aggressive surgery and/or adjuvant treatment of a separate site.
Cost	Cost comparison analyses have not been undertaken.
Benefits-harm assessment	Balance of benefits and harms.
Value judgments	Since reports are limited to case series, there is no evidence to suggest that tumor seeding is impacted by surgical approach. Piecemeal resection could theoretically have a higher risk of tumor seeding due to tumor capsule violation, while open surgery may expose uninvolved soft tissues to tumor.
Policy level	Option.
Intervention	Consideration of approach and technique based on tumor seeding is an option. There is no evidence that an open or endoscopic approach to sinonasal tumors carries a higher risk of tumor seeding. Given the lack of case reports, either approach appears to have a low risk of tumor seeding. Upfront recognition and prevention are key to minimize this risk.

(Continued)

Biopsy

In-office biopsies for sinonasal lesions appear to be a safe alternative to operative biopsies in appropriately selected patients, though patient selection is important. There is a moderate risk of a false-negative diagnosis given tumor heterogeneity or surrounding sinonasal inflammation obscuring the target. No studies have specifically examined the appropriate order of imaging and biopsy. The level of evidence (LOE) is low in this area and largely based on expert opinion.

Resectability

- There is variability in the literature regarding what features make tumors resectable based on surgeon experience and institutional preference.
- Orbital apex: Orbital apex involvement portends a poor prognosis and is deemed unlikely to be able to obtain true-negative surgical margins.
- Carotid artery: Despite increasing experience with treatment of tumors involving the carotid artery, ranging from nonsurgical therapy to carotid resection, there remains no strong evidence to indicate a survival benefit even with the most aggressive of treatments.
- Skull base: Poor prognosis is predicted by brain parenchymal and cavernous sinus involvement even if gross total resection (GTR) may be achieved.
- Pterygopalatine and infratemporal fossae: Newer evidence suggests that involvement of these areas does not independently predict worse prognosis, as long as negative margins can be achieved.

Workup for regional and distant disease

A complete physical examination with palpation of the neck and imaging with computed tomography (CT) and/or magnetic resonance imaging (MRI) is recommended for evaluation of regional lymphadenopathy. Whole-body positron emission tomography (PET)/CT may be utilized to assess regional and distant metastases but has known limitations, including false positives (e.g., inflammation). Retropharyngeal lymphadenopathy is commonly underrecognized and should be considered in the workup.

Workup of regional and distant disease

Aggregate grade of evidence	C (Level 3: four studies; Level 4: 16 studies; Level 5: 12 studies)
-----------------------------	---

(Continued)

Benefit	CT and MRI are complementary for regional and distant disease workup. Functional imaging such as PET/CT has high sensitivity and negative predictive value (NPV), allows for baseline imaging, and is a single imaging technique for rapid simultaneous qualitative evaluation of the primary, regional, and distant metastasis.
Harm	CTs expose patients to radiation. Workup of regional and distant metastasis and false-positive PET/CT may lead to additional (and potentially unnecessary) investigations, patient anxiety, and increased costs without a change in treatment. In a healthcare setting with limited resources, this may further increase delays in diagnosis and strain on the system.
Cost	There is potential cost-benefit of hybrid PET scans since they can combine PET/CT or PET/MRI into a single exam and reduce the number and duration of hospital visits.
Benefits-harm assessment	Preponderance of benefits over harms.
Value judgments	CT and MRI are both useful modalities for regional and distant disease assessment. CT is faster, better tolerated, and more readily available than MRI, but does incur radiation exposure. MRI does not subject patients to ionizing radiation, but takes longer to perform, has a risk of motion artifact, and is contraindicated in patients with noncompatible ferromagnetic devices. Hybrid PET imaging allows for more rapid and accurate diagnosis of regional and/or metastatic disease, especially for high-grade tumors and/or those tumors prone to metastases (e.g., sinonasal undifferentiated carcinoma, melanoma). However, there is potential for false-positive results, and thus it may be more useful for restaging than initial staging. It may not be as useful for tumors with low FDG avidity.
Policy level	Recommendation.
Intervention	CT and MRI remain the conventional imaging modalities. Hybrid PET or other full-body imaging should be considered in the investigation of regional and distant metastases in SNM. Presence of enlarged retropharyngeal lymph nodes should always be evaluated on CT or MRI.

Surgical approach

With growing utilization and experience, research, and advanced understanding of indications and limitations of the endoscopic approach, many tumors, both benign and malignant, may be oncologically treated via minimally invasive means. The open approach remains of critical importance for those tumors that may not be fully resectable via an endoscopic approach (e.g., involvement of skin and soft tissue, gross orbital invasion, bony facial skeleton). Regardless of the choice of open, endoscopic, or combined approaches, the principles, margin status, and overall extent of tumor resection should remain the same and should be selected based on patient factors and surgical team experience. In many cases, the endoscopic approach is associated with shorter recovery times and lower morbidity, with generally comparable oncologic outcomes.

Open versus endoscopic approach for sinonasal tumors

Aggregate grade of evidence	C (Level 2: one study; Level 3: nine studies; Level 4: 45 studies)
Benefit	Compared to open surgical approaches, endoscopic surgical approaches generally yield reduced morbidity and shorter recovery times with similar oncologic outcomes in low-stage tumors (stage T1–2; Kadish A–B) and certain high-stage tumors (stage T3–4; Kadish C–D)
Harm	Failure to achieve GTR with negative margins in extensive or high-stage tumors, which could lead to tumor progression or invasion of surrounding structures. Potential for higher risk of cerebrospinal fluid (CSF) leak.
Cost	Reduction in cost is possible with EEA related to reduced operative times, shorter hospital length of stay (LOS), and reduced morbidity.

(Continued)

Benefits–harm assessment	A preponderance of benefit over harm exists for the use of endoscopic surgery approaches in low-stage tumors. For high-stage tumors, benefits of endoscopic surgical approaches when negative surgical margins can be achieved, including reduced morbidity and shorter recovery time, may outweigh potential harms depending on the comfort and experience of the surgical team.
Value judgments	Current conclusions are primarily based on limited data. Many studies have small sample sizes and cannot adjust for tumor stage, patient comorbidities, covariates, or tumor type. The above recommendations are based on data quality, evaluation of surgical outcomes, outcomes grouped by tumor stage, and systematic reviews that demonstrate consistent findings across many studies. Most studies include a heterogenous grouping of SNM, preventing clear recommendations for approach by tumor type or tumor location. Larger prospective studies are needed to develop clear recommendations for surgical approach, particularly in late-stage tumors where data on endoscopic approach outcomes are lacking.
Policy level	Recommendation for EEA for low-stage tumors. Option for EEA for high-stage tumors.
Intervention	In most low-stage sinonasal tumors, endoscopic surgery should be considered the first-line surgical approach to reduce morbidity and recovery times while achieving similar oncologic outcomes to open surgery. In advanced-stage tumors (such as T3–4) endoscopic SNM surgery approaches should be considered on a case-by-case basis according to the tumor location, surgeon experience, patient preference, and tumor grade, with consideration of the risk–benefit ratio of alternative treatment options.

With the advent of extended maxillary sinus approaches such as medial maxillectomy, modified Denker maxillectomy, and the prelacrima approach, tumors involving all walls of the maxillary sinus, including the anterior wall, may now be accessed via a minimally invasive approach with generally low morbidity. Such approaches have increasingly become the first-line choice for managing benign maxillary neoplasms (e.g., inverted papilloma [IP]), and may also have value for surgical treatment of malignancies.

Extended endoscopic approaches to the maxillary sinus

Aggregate grade of evidence	C (Level 4: 12 studies)
Benefit	Compared to open maxillary surgical approaches, endoscopic maxillary surgical approaches generally yield improved morbidity and shorter recovery times with comparable or even improved outcomes based on the IP literature.
Harm	Potential for failure to achieve GTR with negative margins in extensive or high-stage tumors, particularly those with bony maxillary wall and/or palatal invasion, which could result in tumor progression or surrounding structure invasion.
Cost	Reduction in cost is possible with EEA related to reduced operative times, shorter hospital LOS, and reduced morbidity.
Benefits-harm assessment	Preponderance of benefits over harms.
Value judgments	Current conclusions are primarily based on limited data focused on inverted papilloma (IP) resection. It is unclear how these data will translate to treatment of other primary maxillary neoplasms, including malignancies, especially those with bony invasion. Moreover, many studies have small sample sizes and cannot adjust for patient comorbidities, covariates, or tumor stage. Larger prospective cohort studies are needed to develop clear recommendations for maxillary surgical approach in malignancies.

(Continued)

Policy level	Recommendation for EEA for IP and other benign lesions. Option for EEA for malignant tumors based upon anatomical involvement and at the discretion and comfort of the surgeon.
Intervention	EEA should be the first-line surgical technique for the resection of most IP confined to the maxillary sinus to reduce morbidity and recovery times while achieving similar outcomes to open surgery. Endoscopic maxillary surgical approaches should be considered on a case-by-case basis for malignancies and other benign tumors in the maxillary according to the tumor location, surgeon experience, patient preference, and tumor grade, with consideration of the risk-benefit ratio of alternative treatment options.

Management of the orbit

- Various grading systems exist for staging orbital invasion by sinonasal tumors.
- Orbital resection, whether partial or complete (e.g., exenteration) or via endoscopic or open approaches, should be guided by oncologic principles. Limited peri-orbital involvement by tumor may often be locally resected with favorable outcomes and functional preservation, but involvement of the extraocular muscles, optic nerve, and intraconal space may be more effectively treated with exenteration. Consideration should be given to orbital preservation whenever possible, but only if negative margins can be achieved. There is emerging evidence to suggest that orbital preservation may be possible with induction chemotherapy, though currently no upfront predictors of response are known.
- The nasolacrimal system may undergo stenosis or scarring after surgical and/or radiation therapy. Posttreatment epiphora, which is estimated to occur in up to 15% of cases, should be routinely assessed.

Margin analysis

Obtaining negative surgical margins remains the key goal of surgical resection for most SNM, and careful planning

should be undertaken before surgery to prioritize the goals of resection while selecting the appropriate approach and reconstruction. For ACC with perineural invasion (PNI), gross total resection (GTR) without negative margins may be an acceptable alternative. Frozen sections may be used to guide margin status intraoperatively, although it is not reliable for all histologies (i.e., mucosal melanoma). To date, there is no consistent definition of adequacy or “wideness” of margins.

Margin analysis in sinonasal tumors

Aggregate grade of evidence	C (Level 2: one study; Level 3: 12 studies; Level 4: 61 studies)
Benefit	Negative margins are associated with significant improvements in overall survival (OS), disease-specific survival (DSS), and recurrence-free survival (RFS) in a majority of studies for all tumor subtypes.
Harm	Potential harm of taking aggressive margins includes injury to critical neurovascular structures that would otherwise not be sacrificed, leading to increased morbidity or mortality to the patient. Inaccurate frozen section margins intraoperatively could change the operative plan and either compromise definitive resection requiring a return to the operating room or adjuvant chemoradiation or could lead to more aggressive resection than is truly warranted. The potential harm to not achieving negative margins comes at the cost of survival for several tumor subtypes.
Cost	Frozen section use is associated with increased costs, but this must be weighed against the potential cost of a second surgery, intensification of adjuvant treatment, and reduced survival that could otherwise have been avoided if complete resection with negative margins had been achieved.
Benefits-harm assessment	Preponderance of benefits over harms.
Value judgments	“Wide surgical margins” should be more clearly defined and uniformly reported within the literature.
Policy level	Recommendation for most malignancies. Option for ACC with perineural invasion.

(Continued)

Intervention	All attempts should be made to resect SNM to negative margins except for when resecting to negative margins would put critical neurovascular structures at risk for injury that would otherwise not be at risk. GTR may be acceptable for ACC for local control. Frozen section analysis should not be used on mucosal melanoma due to inaccuracy. For all other tumor types evaluated (SCC, adenocarcinoma, ONB, SNUC) frozen section analysis should be used intraoperatively to define the resection margins and ensure definitive/negative margin resection.
--------------	--

Management of recurrent malignancy

Outcomes of salvage surgery are dependent on histology, primary site, and stage. Although there may be a survival benefit, there is a higher risk of morbidity and mortality associated with salvage surgery. Palliative treatments, including surgery, radiation therapy (RT), or chemotherapy, may be considered for symptomatic and QOL management without curative intent.

Radiation modalities for treatment of sinonasal malignancies

RT is an important definitive and adjuvant modality for management of SNM (and some benign tumors in limited indications). Intensity-modulated radiation therapy (IMRT) has become the most commonly utilized modality with demonstrated efficacy and generally acceptable safety profile. Particle beam therapy has an emerging role and should be considered if available.

Radiation modalities for treatment of sinonasal malignancies

Aggregate grade of evidence	IMRT: B (Level 2: three studies; Level 3: one study; Level 4: 50 studies) Proton beam radiotherapy (PBT): C (Level 2: two studies; Level 3: one study; Level 4: 23 studies); five level 4 carbon ion radiotherapy (CIRT) series include single modality PBT patients Fast neutron therapy (NRT): C (Level 4: 10 studies) CIRT: C (Level 2: two studies; Level 3: two studies; Level 4: 23 studies)
-----------------------------	---

(Continued)

Benefit	IMRT provides locoregional control (LRC) and benefits in PFS and OS rates as either primary or adjuvant therapy for SNM with absolute benefits dependent on patient- and pathology-specific factors.
Harm	RT morbidity is related to the extent and site of the tumor, including soft tissue, bone, vascular, and neural injury. Aside from IMRT, the other modalities may not be widely available, and patients may need to travel to specialized facilities for care.
Cost	Limited to two series. PBT provided extra quality-adjusted life-year (QALY) compared to IMRT and was cost-effective in patients ≤ 56 years old, and CIRT increased costs compared to IMRT despite survival benefits.
Benefits-harm assessment	Preponderance of benefits over harms.
Value judgments	All modalities should be considered for improving LRC rates. The absolute benefit to LRC rates for SNM depends on patient- and pathology-specific factors and should be weighed against the risk of treatment toxicity. NRT/CIRT should be considered for salivary glands or radioresistant histologies with gross residual disease at the time of treatment.
Policy level	Recommendation.
Intervention	IMRT should be considered for improving LRC, disease-free survival (DFS), and OS rates when weighed for patient-specific and tumor features. Evidence suggests that PT, particularly PBT, could be considered when available.

Section 2: Benign lesions and neoplasms

Sinonasal papillomas

- Exophytic papilloma has a strong association with low-risk human papillomavirus (HPV) subtypes, with rare malignant transformation risk.
- Oncocytic papillomas have comparable malignant transformation risk as IPs but may be distinguished through pathologic and molecular features.
- IPs, which are the most common sinonasal papillomas, demonstrate somatic mutations in *EGFR* and association with low-risk HPV subtypes.

- Dysplasia is a harbinger of progression to malignant transformation in IP and oncocytic papillomas. Papilloma-associated malignancies tend to be associated with low-risk HPV, while high-risk HPV seems more prevalent in de novo sinonasal SCC.

Assessment of dysplasia and HPV in sinonasal papillomas

Aggregate grade of evidence	B (Level 2: seven studies; Level 3: 17 studies; Level 4: 22 studies)
Benefit	Proper histopathologic assessment is crucial to appropriately characterize IP grade and clinical behavior. The surgeon should consider assessment of <i>EGFR</i> and <i>KRAS</i> mutations and HPV in diagnostically challenging cases, particularly when there is concern for dysplasia or malignant transformation.
Harm	There is potential negative impact to patient care when an incorrect pathologic diagnosis (e.g., understaging) is made.
Cost	No studies currently discuss healthcare costs related to the diagnostic workup of IP and genomic or viral testing.
Benefits-harm assessment	Preponderance of benefits over harms.
Value judgment	Appropriate evaluation of tissue specimens allows for improved treatment stratification. Given the potentially high risk of recurrence and morbidity from inappropriate treatment, a correct diagnosis is critical for sinonasal papillomas.
Policy level	Recommendation.
Intervention	The surgeon should engage with the head and neck pathologist to appropriately diagnose sinonasal papillomas and determine presence of dysplasia. <i>EGFR</i> mutations appear to be the dominant factor in IP development. Although low-risk HPV may be found in exophytic and inverted subtypes, there are limited data to support the involvement of high-risk HPV in sinonasal papillomas.

- Whenever possible, all IP sites of attachment should be definitively treated with mucosal resection followed by drilling and/or cauterization of the hyperostotic focus

for improved local control. Careful review of preoperative imaging may allow for identification of the hyperostotic focus that usually represents the dominant site of origin. There is evidence to suggest that the same principles apply to attachment sites along the orbit and skull base.

Imaging of the site of attachment in inverted papilloma

Aggregate grade of evidence	C (Level 3: two studies; Level 4: five studies)
Benefit	Imaging is useful for accurate identification of IP pedicle for preoperative planning.
Harm	Mild radiation associated with CT imaging as well as contrast burden for CT and MRI images.
Cost	Associated costs with imaging studies.
Benefits-harm assessment	Preponderance of benefits over harms.
Value judgments	Determining site of attachment is imperative for effective surgery and to reduce local recurrence.
Policy level	Recommendation.
Intervention	Utilize preoperative CT (as evidenced by osteitis) with or without MRI for accurate identification of IP attachment site, which can also be used to guide surgical approach.

Treatment of the site of attachment in inverted papilloma

Aggregate grade of evidence	C (Level 4: seven studies)
Benefit	Lower recurrence rates with reduced morbidity.
Harm	Baseline risk of epistaxis and postoperative pain.
Cost	Associated costs with surgery.
Benefits-harm assessment	Preponderance of benefits over harms.
Value judgments	The surgeon must attempt to identify the attachment site in order to properly resect this region to minimize risk of recurrence.
Policy level	Recommendation.
Intervention	Perform pedicle-oriented resection via any surgical approach in order to definitively address primary site and reduce recurrence risk. Definitive treatment may entail cauterization or drilling of the pedicle following mucosal resection.

Role of orbital resection for inverted papilloma

Aggregate grade of evidence	C (Level 4: six studies)
Benefit	Lower recurrence rates with improved orbital preservation.
Harm	Small potential for orbital injury. Baseline risk of epistaxis and postoperative pain.
Cost	Associated costs with surgery.
Benefits-harm assessment	Preponderance of benefits over harms.
Value judgments	Determining involvement of orbit on preoperative imaging is helpful for preoperative planning and patient counseling. There are limited data to suggest that lamina resection may lead to orbital soft tissue seeding/recurrence.
Policy level	Recommendation.
Intervention	Perform resection or drilling of hyperostotic focus for orbital IP with lamina papyracea involvement.

Role of skull base resection for inverted papilloma

Aggregate grade of evidence	C (Level 4: six studies)
Benefit	Lower recurrence rates with reduced morbidity.
Harm	Small potential for intracranial and/or dural injury and CSF leak. Baseline risk of epistaxis and postoperative pain.
Cost	Associated costs with surgery.
Benefits-harm assessment	Preponderance of benefits over harms.
Value judgments	Determining involvement of skull base on preoperative imaging is helpful for preoperative planning and patient counseling, especially if at risk for CSF leak. There are limited data comparing judicious cautery (e.g., bipolar) versus direct resection of the skull base. Furthermore, there are limited data to suggest that skull base resection may lead to intracranial seeding/recurrence.
Policy level	Recommendation.
Intervention	Perform endoscopic and/or open resection of skull base IP with bony resection, drilling, or cauterization of mucosal rests to adequately address pedicle.

- The indications for RT into treating IP are limited, and are considered for unresectable disease, poor surgical

candidates, multiply recurrent lesions, or IP associated with malignancy.

Role of radiation therapy for inverted papilloma

Aggregate grade of evidence	C (Level 4: four studies)
Benefit	Potential for improved disease control in patients in whom surgery has failed or is not possible.
Harm	Nearly all patients experience minor (mucositis, conjunctivitis, xerostomia, epiphora, anorexia) adverse effects from toxicity, some with major (central nervous system [CNS], radionecrosis, visual changes, etc.) effects that can be life threatening.
Cost	Procedural costs, as well as radiation-associated morbidity.
Benefits-harm assessment	Balance of benefits and harms.
Value judgments	Role of RT is well established but limited to specific circumstances in management of IP.
Policy level	Option.
Intervention	Consider RT for patients who meet limited indications or special conditions such as unresectable disease, poor surgical candidates, multiply recurrent lesions, or IP associated with malignancy.

- IP should be under surveillance given its propensity for local recurrence and known risks of malignant transformation. The optimal timing is variable, but there are now data to suggest that recurrence may occur far after 5 years, which would necessitate longer surveillance periods.

Recurrence risk and surveillance in inverted papilloma

Aggregate grade of evidence	Recurrence: B (Level 2: three studies, Level 3: two studies, Level 4: 14 studies) Surveillance: C (Level 4: six studies)
Benefit	Prognosis for recurrence can be determined by identification of risk factors (multifocal attachment, prior surgery, high-risk HPV, STR such as disease overlying carotid, etc.). Prolonged surveillance allows for prompt identification of IP recurrence.
Harm	Potential for under- or oversurveillance and early discharge from surveillance, which would preclude detection of later recurrences.

(Continued)

Cost	Clinical charges associated with assessment of risk factors including clinic visits for history and physical, imaging, endoscopy, and operative cost for intra/postoperative risk factor assessment.
Benefits-harm assessment	Preponderance of benefits over harms.
Value judgments	Risk factors for recurrence are wide ranging and need to be assessed on a patient-specific basis. Determining presence of recurrence as soon as evident will allow for more timely intervention of a less extensive tumor and potential mitigation of malignant transformation risk. Though endoscopy may be utilized for most surveillance visits, imaging may be considered for specific cases (e.g., maxillary sinus following prelacrima approach, lateral frontal sinus).
Policy level	Recommendation.
Intervention	Recommend identification of evidence-based risk factors that will increase risk of recurrence for IP and prolonged follow-up for surveillance of IP patients due to propensity for delayed recurrence. Close clinical follow-up for all patients due to risk for recurrence even after 5 years.

Benign vascular neoplasms and lesions

This section covers updated evidence surrounding management of nasopharyngeal angiofibroma (formerly juvenile nasopharyngeal angiofibroma [JNA]) since ICSB 2019,⁵ as well as sinonasal vascular malformations, hemangiomas, and paragangliomas.

Open versus endoscopic approaches for JNA

Aggregate grade of evidence	B (Level 2: one study; Level 4: seven studies)
Benefit	Endoscopic approaches demonstrate comparable and possibly reduced tumor recurrence rates along with lower patient morbidity and intraoperative bleeding.
Harm	Endoscopic approach is associated with low complication rates and morbidity.
Cost	Endoscopic management is associated with favorable costs when compared to costs from open surgery.
Benefits-harm assessment	Preponderance of benefits over harms.

(Continued)

Value judgments	Endoscopic intervention requires familiarity with endoscopic surgery and endoscopic equipment including tools for hemostasis.
Policy level	Recommendation.
Intervention	In experienced institutions, endoscopic and combined approaches are the preferred surgical approaches for management of JNA.

Techniques for hemostasis in JNA

Aggregate grade of evidence	C (Level 4: eight studies)
Benefit	Preoperative embolization reduces intraoperative bleeding and may reduce LOS, surgical duration, and need for perioperative blood transfusion.
Harm	Risk of inadvertent embolization of ICA-supplied structures via internal-external anastomosis, puncture site hematoma, contrast exposure.
Cost	Possible additional cost of ~\$36,500 and need for prehospitalization for procedural planning.
Benefit-harm assessment	The procedural risks of embolization are significantly less than the perioperative benefit of reduced bleeding and improved visualization; the procedural cost may be offset by reduced LOS and need for blood products.
Value judgments	Choices for or against specific embolic agents or instruments for intraoperative hemostasis should be guided by surgeon/interventionalist experience and preference.
Policy level	Recommendation.
Intervention	For advanced tumors, and possibly for locally limited tumors, preoperative embolization of ECA feeder vessels reduces perioperative bleeding, may reduce LOS and need for transfusion, and should be considered.

Congenital midline nasal masses

Congenital midline nasal masses (CMNMs) are relatively rare (estimated to occur in between 1:20,000 and 1:40,000 births). They are composed of dermoid and epidermoid cysts, glial heterotopia, and meningoencephaloceles. Early treatment is indicated for aesthetic concerns and to prevent infection and intracranial complications. Many lesions may be approached endoscopically, including those that extend intracranially, though some lesions extend through the skin and may benefit from a combined approach.

Benign orbital lesions and neoplasms

This section covers updated evidence surrounding endoscopic management of benign intraconal tumors since ICSB 2019.⁵ Since then, the Orbital Resection By Intranasal Technique (ORBIT) classification was developed to classify surgical complexity of intraconal orbital lesions. Inflammatory conditions of the orbit, such as IgG4-related ophthalmic disease (formerly orbital pseudotumor) and Tolosa-Hunt syndrome (THS), are also part of the differential diagnosis of oculo-orbital symptoms and are discussed in this section as well.

Endoscopic resection of intraconal orbital lesions

Aggregate grade of evidence	C (Level 2: two studies; Level 4: nine studies)
Benefit	Higher rates of GTR with reduced local morbidity relative to open approaches among patients with lesions medial to optic nerve and/or inferior to POR.
Harm	Risk of diplopia related to necessity for translamellar approach.
Cost	Associated costs with surgery and preoperative evaluations.
Benefits-harm assessment	Balance of benefits and harms.
Value judgments	No study to date has compared endoscopic and open approaches directly. However, in appropriately selected patients (e.g., tumor medial to the optic nerve and/or inferior to POR), endoscopic orbital surgery was preferred to traditional open approaches with reduced external morbidity. Not all patients are candidates for an endoscopic orbital approach, with tumors lateral and superior to POR and/or concern for invasion of local structures.
Policy level	Option.
Intervention	Endoscopic orbital surgery approach may be offered in lieu of open surgery by trained multidisciplinary orbital teams following appropriate workup and candidacy determination.

Section 3: Malignant neoplasms

Table I.1 provides a summary of the LOE surrounding histopathology-based management of SNM.

Sinonasal squamous cell carcinoma

De novo sinonasal SCC is the most common SNM, accounting for 40%–50% of cases. This section includes

TABLE I.1 Summary of aggregate grades of evidence surrounding histopathology-based management of sinonasal malignancies.

Category	Histopathology	Treatment modality	AGE	Recommendation	Specific indications
Squamous cell carcinoma	DN-SCC	IC	C	Option	Locally advanced disease (e.g., orbit or skull base invasion)
		Sx	C ^a	Recommendation ^a	Primary modality Endoscopic surgery option
		aRT	C	Recommendation	Locally advanced disease High-grade tumors CRT considered for extranodal extension and/or positive margins
		dCRT	C	Option	Select early-stage disease Unresectable disease Poor surgical candidates
		END/ENI	C	Option	Advanced T stage tumors (particularly maxillary sinus primary)
Adenocarcinoma and salivary gland malignancies	ITAC	IC	C	Option	Functional P53 protein
		Sx	B	Recommendation	Primary modality
		aRT	C	Option	Advanced-stage disease (pT3–4) High-grade tumors Positive surgical margins
	Non-ITAC	Sx	C	Recommendation	Primary modality
		aRT	C	Recommendation	Advanced-stage disease High-grade tumors IC considered for functional P53 protein
	ACC	Sx	C	Recommendation	Primary modality GTR acceptable in place of negative margins
		aRT	C	Recommendation	Advanced-stage disease Positive margins Perineural invasion
	Sarcoma	Pediatric rhabdomyosarcoma	Sx	D	No recommendation
RT			B	Recommendation	Primary modality
C			B	Recommendation	
Adult rhabdomyosarcoma		Sx	D	No recommendation	Salvage setting
		CRT	C	Option	Primary modality Abstracted from pediatric literature
		IC	C	Option	Locally advanced disease

(Continues)

TABLE I.1 (Continued)

Category	Histopathology	Treatment modality	AGE	Recommendation	Specific indications
Neuroendocrine or neuroectodermal tumors	ONB	IC	C	Option	Locally advanced disease
		Sx	C ^a	Recommendation ^a	Primary modality Endoscopic surgery option
		aRT	C	Option	Hyams grades III/IV Kadish stages C/D Positive margins
		END/ENI	C	Option	Hyams grades III/IV Kadish stages C/D
	SNUC	IC	B	Recommendation	IC followed by CRT for responders IC followed by salvage surgery for nonresponders
	SNEC	IC	C	Recommendation	Locally advanced disease High-grade tumors
		Sx aRT			Primary modality
	SNMM	Sx	C	Recommendation	Primary modality
		aRT	C	Option	Local control, but no OS benefit
		Immunotherapy	C	Option	Locally advanced disease Metastatic disease
END/ENI		C	Option	Regional control, but no OS benefit	
Nasopharyngeal malignancies	NPC	IC	A	Strong recommendation	Advanced-stage disease
		dCRT	A	Strong recommendation	Advanced-stage disease Consider for stage II patients with bulky nodal disease
		RT	A	Strong recommendation	Early-stage disease IMRT standard of care
		END/ENI	B	Option	Option to limit RT to lower neck lymphatics if no radiographic nodal metastases or if unilateral nodal disease
Lymphoma	BCL	C	B	Recommendation	Primary modality CHOP or CHOP-like therapy
		RT	B	Option	Symptomatic (e.g., cranial nerve palsies) Bulky disease Advanced-stage disease
		Immunotherapy	B	Recommendation	Rituximab
	ENKTL	C	C	Recommendation	Primary modality
		RT	C	Recommendation	LRC benefits

Abbreviations: AGE, aggregate grade of evidence; aRT, adjuvant RT; dCRT, definitive CRT; END/ENI, elective neck dissection/irradiation; IC, induction chemotherapy; Sx, surgery.

^aAbstracted from ICSB 2019.⁵

^bAll surgical treatment is predicated on achieving negative margins for curative intent, with exception of some cases of ACC.

other important considerations regarding management of sinonasal SCC that were not discussed in ICSB 2019.⁵ Definitive management entails surgical resection with the goal to obtain negative margins, followed by adjuvant therapy for advanced-stage disease and poorly differentiated tumors. Induction chemotherapy (IC) for locally advanced sinonasal SCC is an option, especially for orbit preservation. Elective neck treatment should be considered for patients with advanced-stage tumors, particularly maxillary sinus primaries.

IP-transformed sinonasal SCC is biologically distinct from de novo sinonasal SCC and appears to be associated with improved prognosis.

Role of induction/neoadjuvant chemotherapy in sinonasal SCC

Aggregate grade of evidence	C (Level 3: one study; Level 4: four studies)
Benefit	Patients who respond to induction chemotherapy demonstrate improved OS and DFS.
Harm	There are systemic toxicities related to neoadjuvant therapy. Selective intraarterial neoadjuvant chemotherapy seems to reduce the rate and severity of toxicity. Additionally, inappropriate patient selection may lead to less favorable outcomes. Progression of disease during the neoadjuvant treatment period may lead to less favorable outcomes.
Cost	Insufficient data to make recommendation regarding long-term costs of neoadjuvant therapy.
Benefits-harm assessment	Balance of benefits and harms.
Value judgments	The stage of tumor at presentation and the goals of the patient with respect to orbit preservation should be carefully considered. It is important to consider that negative margin resection remains the primary goal with most cases of SNSCC.
Policy level	Option.
Intervention	Patients with locally advanced disease (i.e., orbit or intracranial invasion) may have benefit from neoadjuvant chemotherapy. Response to neoadjuvant chemotherapy offers prognostic information.

Role of adjuvant therapy in sinonasal SCC

Aggregate grade of evidence	C (Level 4: four studies)
Benefit	Surgery followed by postoperative RT demonstrate improved LRC and OS compared to patients treated with definitive radiation therapy (RT)/chemoradiation therapy (CRT) or surgery alone.
Harm	Associated with treatment-specific toxicities.
Cost	Insufficient data to make recommendation regarding long-term costs of adjuvant therapy.
Benefits-harm assessment	Preponderance of benefits over harms.
Value judgments	The stage of tumor at presentation, the specific histologic subtype, and the goals of the patient should be carefully considered.
Policy level	Recommendation.
Intervention	Patients with locally advanced disease or poorly differentiated histologies would benefit from postoperative RT. The role of CRT is not clearly defined specifically for SNSCC but should be considered when positive margins or extranodal extension is present.

Role of definitive chemoradiotherapy in sinonasal SCC

Aggregate grade of evidence	C (level 4: four studies)
Benefit	In cases of unresectable tumors, nonsurgical therapies offer an alternative to palliative treatments. Additionally, in early-stage cancers, nonsurgical therapy may confer equivalent outcomes as compared to surgery ± adjuvant therapy.
Harm	There are systemic and local toxicities related to nonsurgical therapies.
Cost	Insufficient data to make recommendation regarding long-term costs of adjuvant therapy.
Benefits-harm assessment	Balance of benefits and harms.

(Continued)

Value judgments	Definitive CRT/RT could be considered in the setting of unresectable tumors, for patients who are poor surgical and chemotherapy candidates, and in patients who decline surgery. Additionally, for early-stage tumors, definitive CRT/RT can be considered, although there are limited studies evaluating this.
Policy level	Option.
Intervention	Patients with unresectable or early-stage disease, patients who are poor surgical candidates, and patients who do not desire surgery may be considered for definitive CRT/RT.

Elective management of the NO neck in sinonasal SCC

Aggregate grade of evidence	C (Level 2: two studies, Level 3: two studies; Level 4: two studies)
Benefit	Elective neck treatment may decrease the rate of regional recurrence.
Harm	There are morbidities associated with elective neck treatment, both for surgical treatment and elective irradiation.
Cost	Insufficient data to make recommendations regarding long-term costs of elective neck treatment.
Benefits-harm assessment	Balance of benefits and harms.
Value judgments	Patient with advanced T-stage tumors may benefit from elective neck treatment. Maxillary sinus SCC has a higher risk of neck metastasis than nasal cavity SCC.
Policy level	Option.
Intervention	Strong consideration should be given to elective neck treatment in cases of advanced T stage tumors, especially if it is a maxillary sinus primary and if primary surgery is undertaken. Elective treatment may be in the form of elective irradiation or END.

Sinonasal adenocarcinoma

Sinonasal adenocarcinomas comprise a group of glandular neoplasms, of which intestinal-type adenocarcinoma (ITAC) is more common in European countries and is associated with exposure to hardwood dusts. Certain subtypes (signet ring cell type) and higher tumor grade are associated with worse prognosis. The mainstay of treatment is surgical resection with negative margins, with adjuvant RT considered for positive margins, advanced tumor stage, and high-grade tumor histology.

Role of surgery in ITAC

Aggregate grade of evidence	B (Level 2: two studies; Level 3: one study; Level 4: seven studies)
Benefit	Oncologic resection is possible with endoscopic approaches in many cases. Reduced complication rate, improved QOL, and better survival outcomes have been described as direct benefit of a multimodal treatment strategy including surgery.
Harm	Insufficient tumor excision with positive surgical margins, leading to increased risk of local or distant recurrences, and morbidity and complication risks related to surgery.
Cost	Although no studies have examined the issue of costs in sinonasal ITAC treatment, short hospitalization period and fast patient recovery associated with minimally invasive surgery could translate to lower costs.
Benefits-harm assessment	Preponderance of benefits over harms.
Value judgments	All studies to date have suggested equivalent or better outcomes of endoscopic surgery as compared to traditional craniofacial surgery. There is no significant argument for or against bilateral ethmoid resection as routine procedure for patients with occupational exposure.
Policy level	Recommendation.
Intervention	Multidisciplinary management of sinonasal ITAC with primary surgery and achieving negative margins currently represents the standard of care.

Role of adjuvant therapy in ITAC

Aggregate grade of evidence	C (Level 2: one study; Level 3: one study; Level 4: four studies)
Benefit	Additional oncologic control in cases of positive margins or locally advanced/metastatic tumors.
Harm	The risk of osteoradionecrosis, mucositis, and other RT- and chemotherapy-induced complications should be discussed with the patient when adjuvant treatments are planned.
Cost	No dedicated studies on cost. Multidisciplinary management with multiple healthcare workers involved in the treatment may increase the economic burden.

(Continued)

Benefits-harm assessment	Balance of benefits and harms.
Value judgments	For patients with functional <i>P53</i> , neoadjuvant chemotherapy may improve survival rates. Adjuvant RT should be administered in advanced-stage and/or poorly differentiated tumors, though there are no dedicated studies on this. Biological studies to better understand the genetic and molecular profile of such rare cancers will be crucial to better stratify patients according to prognosis and discover potential new drug targets for precision medicine.
Policy level	Option.
Intervention	Adjuvant RT should be considered for ITAC treatment following surgery if pathology demonstrates positive surgical margins, for advanced-stage tumors (pT3-4), and/or for poorly differentiated grade. The role of chemotherapy and timing of administration is less clear.

Sinonasal non-ITAC is a diagnosis of exclusion and may represent multiple tumor types. Sinonasal renal cell-like adenocarcinoma is an important subtype of non-ITAC and must be distinguished from metastatic renal cell carcinoma. Similar to ITAC, the recommended treatment modalities include surgery with adjuvant RT for high-grade and advanced-stage disease.

Role of surgery in non-ITAC

Aggregate grade of evidence	C (Level 2: one study; Level 3: two studies; Level 4: four studies)
Benefit	Surgical resection, either endoscopic or open approach, with negative margins may be associated with improved OS and DSS.
Harm	Procedural related, depending on the approach.
Cost	Cost comparison analyses have not been undertaken.
Benefits-harm assessment	Preponderance of benefits over harms.
Value judgments	Surgical resection with negative margins is beneficial to improve OS and DSS.
Policy level	Recommendation.
Intervention	Endoscopic transnasal resection with goal of negative margins is the primary treatment of choice for non-ITAC. Due to increased morbidity, open (craniofacial) resection should be considered when negative postoperative margins cannot be achieved otherwise.

Role of adjuvant therapy in non-ITAC

Aggregate grade of evidence	C for both RT and chemotherapy <ul style="list-style-type: none"> Level 3: two studies (RT) Level 3: two studies (chemotherapy)
Benefit	There is some evidence that adjuvant RT improves DSS of non-ITAC patients, especially for high-grade tumors. No strong data on chemotherapy outside the palliative setting are available, except in the presence of functional p53 protein.
Harm	Possible side effects of RT include mucositis, nasal discharge, osteoradionecrosis/osteomyelitis, and hyposmia.
Cost	Cost comparison analyses have not been undertaken.
Benefits-harm assessment	Preponderance of benefits over harms (RT). No strong evidence (chemotherapy).
Value judgments	Adjuvant RT should be considered to improve DSS of non-ITAC patients. The role of chemotherapy is not established in the management of non-ITAC patients except in presence of functional p53 protein and as part of topical treatment.
Policy level	Recommendation for adjuvant RT. Option for adjuvant chemotherapy.
Intervention	Adjuvant RT should be considered for all patients with high-grade and/or advanced-stage non-ITAC. Concerning low-grade tumors, the potential benefit should be weighed against the side effects. The role of chemotherapy is established in cases of a functional p53 protein or for palliative therapy.

Sinonasal adenoid cystic carcinoma

Sinonasal ACC is a locally invasive salivary gland malignancy with propensity for PNI and distant metastasis. Management principles were previously discussed in ICSB 2019⁵ and the current section provides an updated literature review. Given low likelihood of long-term distant control, surgery with goal of GTR followed by RT may achieve favorable local control rates. Human papillomavirus (HPV)-related multiphenotypic sinonasal carcinoma is a histologic mimic of ACC and must be excluded through additional HPV-specific testing due to the different long-term outcomes.

Role of surgery in sinonasal ACC

Aggregate grade of evidence	C (Level 2: one study; Level 3: two studies; Level 4: 10 studies)
Benefit	Surgical resection is superior to any other modality in terms of local control and long-term survival.

(Continued)

Harm	Damage to vital structures or important organs (eye, carotid artery, brain, oral cavity), postoperative complications, and cranial nerve deficits.
Cost	No studies directly assessed cost. However, improved local control implies decreased future cost in terms of hospitalization, imaging, systemic therapy, etc.
Benefits-harm assessment	Preponderance of benefits over harms.
Value judgments	Endoscopic resection is associated with lower complication rates and improved QOL over the long term in select cases and is comparable to open approaches in terms of survival outcomes. Achieving negative margins will improve local control as well as improve OS. There is a high distant recurrence rate and risk of skip lesions in perineural invasion. Given the high overall local control rate, a strategy of GTR and postoperative RT while preserving function provides QOL without reduction of survival.
Policy level	Recommendation.
Intervention	Surgical resection should be attempted as the first line of treatment when feasible, with the goal to achieve GTR (with negative surgical margins whenever possible) while preserving vital structures.

Role of adjuvant radiation therapy in sinonasal ACC

Aggregate grade of evidence	C (Level 2: one study; Level 3: two studies; Level 4:10 studies)
Benefit	Postoperative RT improves local control rates and survival outcomes.
Harm	Acute and late toxicities.
Cost	No studies directly assessed cost. However, improved local control implies decreased future cost in terms of hospitalization, imaging, systemic therapy, and so forth.
Benefits-harm assessment	Preponderance of benefits over harms.
Value judgments	In patients with adverse features and positive surgical margins, adjuvant RT effect on local control is crucial. While RT as the primary treatment was not extensively studied and was usually reserved for unresectable cases, adjuvant RT shows clear survival benefit and a better local control trend in all patients, especially with positive surgical margins.
Policy level	Recommendation.
Intervention	Adjuvant postoperative RT should be recommended in all cases, with special importance in cases of advanced-stage disease, positive margins, and PNI.

Sinonasal sarcoma

Management options for sinonasal rhabdomyosarcoma (RMS) have largely been dictated by research in the pediatric population, where chemotherapy and RT remain the first-line treatment. Given the rarity of adult RMS cases, much of the evidence has been abstracted from the pediatric literature. The quality of evidence surrounding surgical treatment is low and appears to apply to salvage cases, and thus no recommendation can be made. Most other subtypes of sinonasal sarcoma are rare and are covered in the form of literature reviews.

Role of surgery in pediatric rhabdomyosarcoma

Aggregate grade of evidence	D (Level 4: three studies)
Benefit	Possibility of additional survival benefit with upfront or salvage surgery.
Harm	Risk of surgical complications including anesthetic risks, blood loss, infection, CSF leak, and orbital injury. Potential for significant morbidity and disfigurement for locally advanced tumors.
Cost	Additional cost of surgery and perioperative care.
Benefits-harm assessment	Balance of benefits and harms.
Value judgments	Minimally invasive endoscopic approaches are limited by pediatric sinonasal anatomy. Studies do not differentiate between upfront and salvage surgery.
Policy level	No recommendation.
Intervention	There is limited evidence to support routine upfront surgical intervention. May consider in salvage setting.

Role of radiation therapy in pediatric rhabdomyosarcoma

Aggregate grade of evidence	B (Level 2: one study, Level 3: three studies)
Benefit	Improved survival with use of RT in primary treatment modality.
Harm	Acute and long-term radiation complications. Risk of secondary malignancy for pediatric patients.
Cost	Additional cost of RT.
Benefits-harm assessment	Preponderance of benefits over harms.

(Continued)

Value judgments	Vast majority of sinonasal RMS are higher risk (Intergroup Rhabdomyosarcoma Study Group 2 or 3) and unlikely to have complete tumor clearance with surgery alone. Failure to show survival benefit with use of whole-brain radiation despite hypothetical benefit of reducing local recurrence.
Policy level	Recommendation.
Intervention	Primary RT, with or without chemotherapy, for pediatric sinonasal RMS is first-line therapy. Whole-brain radiation for high-risk parameningeal RMS is not recommended.

Role of chemotherapy in pediatric rhabdomyosarcoma

Aggregate grade of evidence	B (Level 2: six studies; Level 3: nine studies)
Benefit	Gradual improvement in survival in more recent studies with vincristine–dactinomycin–cyclophosphamide (VAC) or vincristine–dactinomycin–ifosfamide (VAI) protocol.
Harm	Chemotherapy side effects including pancytopenia and stomatitis. Some studies show higher rates of grade 3 and 4 toxicities with more aggressive chemotherapy regimens.
Cost	Cost of chemotherapy administration.
Benefits–harm assessment	Preponderance of benefits over harms.
Value judgments	There are no direct comparisons between chemotherapy and nonchemotherapy treatments. Failure to show survival benefit with addition of intrathecal chemotherapy.
Policy level	Recommendation
Intervention	Administer VAC- or VAI-based chemotherapy protocols in treatment of sinonasal RMS. Intrathecal chemotherapy for sinonasal RMS is not recommended.

Role of surgery in adult rhabdomyosarcoma

Aggregate grade of evidence	D (Level 4: six studies)
Benefit	Comparable survival between surgical and nonsurgical approaches.
Harm	Risk of surgical complications including anesthetic risks, blood loss, infection, CSF leak, and orbital injury. Potential disfiguring surgery for locally advanced cases.

(Continued)

Cost	Additional costs of surgery, perioperative care, and long-term postoperative care.
Benefits–harm assessment	Balance of benefits and harms.
Value judgments	Patients treated with upfront surgery or surgery alone are likely to be highly selected for less aggressive, resectable tumors. Most studies do not differentiate between upfront and salvage surgery.
Policy level	No recommendation.
Intervention	May consider surgery in highly selected patients with resectable tumors and in salvage setting.

Role of chemoradiation therapy in adult rhabdomyosarcoma

Aggregate grade of evidence	C (Level 4: nine studies)
Benefit	Definitive treatment option for local, regional, and distant disease.
Harm	Acute and long-term CRT side effects.
Cost	Cost of CRT administration.
Benefits–harm assessment	Balance of benefits and harms
Value judgments	No direct comparison between different treatment approaches. Low quality studies demonstrating response with poor long-term survival. Protocols for adult RMS have generally been adapted from pediatric RMS; however, these tumors have different biology, and their treatment likely has different side effect profiles.
Policy level	Option.
Intervention	Further evidence needed to determine role of specific chemotherapy protocols in adult RMS. Consider RT for adults with sinonasal RMS, especially patients with unresectable disease.

Induction chemotherapy for sinonasal rhabdomyosarcoma

Aggregate grade of evidence	C (Level 3: two studies)
Benefit	OS appears to be lower than that of patients treated with non-induction protocols from the same studies.
Harm	Chemotherapy side effects and additional risk of tumor progression while receiving induction.
Cost	Cost of chemotherapy administration, unlikely to be significantly different from non-induction chemotherapy costs.

(Continued)

Benefits-harm assessment	Balance of benefits and harms.
Value judgments	Treatment with induction chemotherapy may identify subset of patients who will or will not benefit from definitive CRT. No direct comparison of induction to other protocols.
Policy level	Option.
Intervention	Induction chemotherapy protocols for sinonasal RMS is an option for bulky and locally advanced disease.

Sinonasal neuroendocrine and neuroectodermal tumors
ONB was previously covered in ICSB 2019⁵ and an updated review on nonoverlapping topics is presented. There is increasing recognition of the prognostic value of Hyams grading, elective management of the neck, balancing functional/olfactory preservation and oncologic resection, and the limitations of historical staging systems. ONB is also known to demonstrate delayed recurrence, making long-term surveillance a cornerstone of management.

Impact of Hyams grade on outcomes

Aggregate grade of evidence	B (Level 2: three studies; Level 4: five studies)
Benefit	Understanding Hyams grade provides prognostic information that may guide adjuvant therapy and treatment of the neck.
Harm	Grading may be prone to misinterpretation and requires pathologist expertise.
Cost	There are no studies investigating the costs of histological grading of ONB.
Benefits-harm assessment	Preponderance of benefits over harms.
Value judgments	High-grade tumors appear to have more aggressive biological behavior (more prone to recurrence, nodal metastases) and may require more aggressive upfront treatment.
Policy level	Recommendation.
Intervention	Hyams grading should be routinely assessed when sampling tissue for ONB cases, as knowledge of the grade may impact treatment strategies.

Staging systems in ONB

Aggregate grade of evidence	B (Level 2: three studies; Level 4: 13 studies)
Benefit	Staging ONB extent provides prognostic information that may guide adjuvant therapy and allow for ease of communication to multidisciplinary and cross-institutional teams.

(Continued)

Harm	There are multiple staging systems with unique criteria, with overlapping and sometimes conflicting prognostic value.
Cost	There are no studies investigating the costs of ONB staging.
Benefits-harm assessment	Preponderance of benefits over harm.
Value judgments	Some staging systems (i.e., Kadish) were initially developed in the pre-endoscopic era and may not take into consideration all relevant prognosticators. Newer staging systems have not been fully validated.
Policy level	Recommendation.
Intervention	ONB staging systems are a useful measure for describing tumors, prognostication, and treatment planning, though other important tumor factors (e.g., grade, dural invasion) must also be considered.

Elective management of the N0 neck in ONB

Aggregate grade of evidence	C (Level 2: two studies; Level 4: eight studies).
Benefit	Treatment of clinically positive neck disease assists in disease control. Delayed regional involvement in the neck is common with a median time to recurrence of approximately 5 years. Elective treatment of the neck with irradiation, particularly in patients with high-stage/grade disease, shows significantly reduced evidence of nodal recurrence but does not significantly impact OS.
Harm	Neck dissection can lead to complications including hematoma, infection, cranial nerve palsies, chyle leak, among others. RT of the neck is associated with xerostomia, skin changes, and long-term toxicity.
Cost	There are no studies investigating the costs of upfront or delayed treatment of the N0 neck.
Benefits-harm assessment	Preponderance of benefits over harms (N+ neck). Balance of benefits and harms (N0 neck).
Value judgments	Elective treatment of the N0 neck is likely to prevent long-term regional recurrence in ONB patients with high-stage/grade disease and may lead to improved DFS.
Policy level	Recommendation for treating N+ neck. Option for treating N0 neck.
Intervention	In a node-positive neck, the role of surgical treatment and adjuvant radiation for ONB patients is well established. However, in patients with a clinically N0 neck and high Hyams grade (III/IV) or Kadish C/D stage, ENI should be considered. Long-term surveillance (>5 years) of the neck is recommended.

Management of the orbit in ONB

Aggregate grade of evidence	C (Level 2: one study; Level 4: three studies)
Benefit	Potential for orbital preservation with induction chemotherapy approaches.
Harm	Orbital invasion is associated with decreased OS.
Cost	Not evaluated in current studies.
Benefits-harm assessment	Balance of benefits and harms.
Value judgments	There are some data to suggest that orbital preservation may be feasible in select cases.
Policy level	Option.
Intervention	Consider induction chemotherapy for advanced cases with significant local or orbital invasion, especially if high-grade tumors. Further studies are necessary to determine the balance between orbital exenteration and orbital preservation approaches for ONB.

Unilateral resection and smell preservation in ONB

Aggregate grade of evidence	D (Level 4: three studies)
Benefit	Potential for some smell preservation if unilateral structures are preserved.
Harm	Not achieving a R0 resection given more limited approach. Possibility of smell loss regardless of unilateral approach given contralateral intracranial dissection or RT side effect.
Cost	There are no studies investigating cost.
Benefits-Harms Assessment	Preponderance of benefits over harms if negative margins can be obtained through unilateral resection.
Value judgments	Smell preservation must not compromise oncologic resection.
Policy level	Option.
Intervention	Unilateral resection in an attempt to preserve olfactory function may be an option in select cases of limited extent unilateral tumors with negative margin resections.

Role of radiation therapy in ONB

Aggregate grade of evidence	C (Level 2: two studies; Level 4: 14 studies)
Benefit	Improved OS at 3 and 5 years when used as adjuvant therapy.
Harm	Generally safe, especially with newer modalities, with some late toxicities.

(Continued)

Cost	There are no studies investigating cost.
Benefits-Harms Assessment	Preponderance of benefits over harms.
Value judgments	Current conclusions based on limited high-quality studies. Larger studies are needed.
Policy level	Option.
Intervention	Postoperative adjuvant RT is effective, especially in cases with positive margins and higher grade or Kadish stage tumors.

Role of systemic therapy in ONB

Aggregate grade of evidence	C (Level 2: three studies; Level 4: 10 studies)
Benefit	Potential benefit for neoadjuvant chemotherapy in locally advanced or unresectable cases.
Harm	Possible side effects from systemic therapy. Etoposide may be associated with bone marrow suppression, leading to pancytopenia, while platinum-based agents may lead to renal, neurological, and otologic impairment.
Cost	Not evaluated in current studies.
Benefits-Harms Assessment	Balance of benefits and harms.
Value judgments	There are some data to suggest that neoadjuvant chemotherapy may be of value in select cases. No current ability to select for possible responders before treatment.
Policy level	Option.
Intervention	Consider neoadjuvant chemotherapy for locally advanced cases. Further studies are necessary to determine the benefit of other systemic treatment approaches for ONB.

A major recent paradigm shift is having improved evidence for the role of IC as a means to “bioselect” sinonasal undifferentiated carcinoma (SNUC) patients based on response. Responders may benefit from definitive chemoradiation therapy (CRT), while nonresponders may be offered salvage surgery.

Treatment of SNUC

Aggregate grade of evidence	B (Level 2: three studies; Level 3: six studies; Level 4: 24 studies)
Benefit	Bimodality, and more so trimodality, therapy is beneficial over single modality. Elective neck treatment is associated with lower regional recurrence rates, most commonly with levels I-III.

(Continued)

Harm	Single-modality treatment yields poorer OS and RFS. Greater regional recurrence rates occur in patients without elective neck treatment.
Cost	Not evaluated in current studies.
Benefits-harm assessment	Preponderance of benefits over harms.
Value judgments	While early studies suggested the greatest benefit was associated with surgery with adjuvant therapy, more recent studies have supported trimodality treatment or neoadjuvant chemotherapy followed by CRT in responders, especially in patients who cannot be resected with negative margins or without significant morbidity.
Policy level	Recommendation.
Intervention	Multimodal treatment with elective neck treatment for SNUC is recommended. Neoadjuvant chemotherapy response as a guide for treatment can be considered.

New classification schemes for sinonasal neuroendocrine carcinoma (SNEC) (i.e., small cell and large cell types) have recently been introduced. However, to date, the evidence suggests that surgery and RT remain the mainstay of therapy, though IC may play a larger role over time.

Treatment strategies for SNEC

Aggregate grade of evidence	C (Level 2: one study; Level 3: two studies; Level 4: five studies)
Benefit	In aggregate, surgery and RT confer survival benefit for both small-cell neuroendocrine carcinomas (ScNEC) and large-cell neuroendocrine carcinomas (LcNEC).
Harm	Morbidity of treatment should be factored into the clinical decision-making process.
Cost	No cost studies have been performed.
Benefits-harm assessment	Preponderance of benefits over harms.
Value judgments	There may be an emerging role for neoadjuvant chemotherapy in management of SNEC, likely in higher grade tumors.
Policy level	Recommendation.
Intervention	Surgery and RT remain the mainstay for primary management of SNEC. Induction chemotherapy may be considered for patients with locally advanced disease, metastases, and/or high-grade tumors.

Sinonasal mucosal melanoma remains a highly challenging disease with overall poor prognosis. Surgery

remains first-line treatment, while there is emerging evidence regarding the role of immunotherapy and its impact on survival. RT and treatment of the neck appear to impact local and regional disease control, respectively, without clear survival benefit.

Role of surgery for sinonasal mucosal melanoma

Aggregate grade of evidence	C (Level 2: one study; Level 4: 16 studies)
Benefit	Surgical resection with negative margins appears to be associated with improved OS and potentially RFS. When possible, it appears that endoscopic resection has equivalent results to open resection for OS and DSS.
Harm	Surgical morbidity is largely related to selection of surgical approach and site of the tumor.
Cost	Cost comparison analyses have not been undertaken.
Benefits-harm assessment	Preponderance of benefits over harms.
Value judgments	Surgical resection with negative margins is beneficial to improve OS.
Policy level	Recommendation.
Intervention	Surgical resection is the first-line therapy for SNMM when resection with negative margins can be achieved; when feasible, endoscopic resection should be considered. In cases of locally advanced or metastatic SNMM, the morbidity of radical surgical resection should be weighed against the poor survivability of this tumor; nonsurgical options may be considered in these cases.

Role of immunotherapy in sinonasal mucosal melanoma

Aggregate grade of evidence	C (Level 1: one study; Level 4: seven studies)
Benefit	Immunotherapy has proven efficacy as an adjuvant therapy for metastatic cutaneous melanoma. Early experience has also demonstrated efficacy as an adjunctive therapy for advanced or metastatic SNMM and may improve OS, although the robust responses do not equal the efficacy noted for metastatic cutaneous melanoma.
Harm	The potential harm of immunotherapy includes rash, fever, nausea, and more severe immune-related adverse events including enterocolitis, pneumonitis, and hepatitis, particularly when used in combination therapy.

(Continued)

Cost	Immunotherapy is expensive; however, cost comparison analyses have not been undertaken.
Benefits-harm assessment	Balance of benefits and harms.
Value judgments	OS is likely improved in advanced and metastatic SNMM with adjuvant immunotherapy, but the duration and clinical significance are not well defined. In addition, the cost and adverse events associated with immunotherapy must be considered.
Policy level	Option.
Intervention	Adjuvant immunotherapy should be considered as a treatment option in advanced or metastatic SNMM.

Treatment of the neck in sinonasal mucosal melanoma

Aggregate grade of evidence	C (Level 2: one study; Level 4: six studies)
Benefit	Neck dissection may reduce risk of regional recurrence (low-level evidence) but has not been shown to be associated with OS.
Harm	Potential harm of neck dissection includes cranial nerve injury, shoulder dysfunction, and vascular injury.
Cost	Cost comparison analyses have not been undertaken.
Benefits-harm assessment	Balance of benefits and harms.
Value judgments	Neck dissection for clinically positive lymph nodes may be considered but must be weighed against other options including immunotherapy.
Policy level	Option.
Intervention	Neck dissection for clinically positive cervical lymph nodes may be considered within the context of the patient's overall treatment plan.

Role of radiation therapy in sinonasal mucosal melanoma

Aggregate grade of evidence	C (Level 1: one study; Level 3: two studies; Level 4: eight studies)
Benefit	There is evidence that adjuvant RT improves local control of SNMM; however, RT has not been consistently associated with improved OS.

(Continued)

Harm	Potential harm of RT includes cost, mucositis, osteoradionecrosis, nasal synechia, hyposmia, dysgeusia, and diminished vision.
Cost	Cost comparison analyses have not been undertaken.
Benefits-harm assessment	Balance of benefits and harms.
Value judgments	Adjuvant RT should be considered to improve local control.
Policy level	Option.
Intervention	Adjuvant RT should be considered for patients with SNMM as part of multimodality therapy. The benefit to local control should be weighed against the side effects of RT treatment.

Nasopharyngeal malignancies

Traditionally thought of as a nonsurgical malignancy, nasopharyngeal carcinoma (NPC) is commonly associated with Epstein-Barr virus (EBV), with recurrence and treatment response able to be monitored through measurement of EBV DNA. There is very high LOE for chemotherapy and RT for NPC, and this remains first-line treatment for NPC. The advent of endoscopic nasopharyngectomy and advanced vascular surgery has provided an additional treatment modality for select recurrent cases.

Role of EBV assessment in NPC

Aggregate grade of evidence	A (Level 1: 10 studies; Level 2: two studies; Level 3: four studies; Level 4: seven studies)
Benefit	A blood test for quantification of circulating EBV DNA is an ideal biomarker for the clinical management of patients with NPC. It has high sensitivity and specificity for the detection of NPC and correlates with tumor burden, patient survival, diagnosis of recurrence/remission, and early prediction of treatment response.
Harm	Need for repeat blood draws; EBV not associated with every NPC subtype.
Cost	The EBV DNA blood test has a lower cost than other diagnostic interventions, such as MRI and PET scan.
Benefits-harm assessment	Preponderance of benefits over harms.

(Continued)

Value judgments	Cumulative evidence suggests that EBV DNA serum testing can provide valuable information to guide clinical decision-making. However, elevated circulating EBV DNA levels during posttreatment follow-up only suggested tumor relapse and did not indicate the tumor location. Diagnostic imaging studies such as CT, MRI, and PET may aid to localize the exact site and extent of the recurrence. Another problem is that PCR-based techniques may produce discrepancies in different laboratories, even when using the same primer/probe sets and experimental conditions. Harmonization between international laboratories, which involves the standardization of buffers and calibrators, is feasible and significantly reduces the variability.
Policy level	Recommendation.
Intervention	The EBV DNA serum test should be used as a routine clinical test for patients with NPC for screening, diagnosis, and monitoring treatment response.

Role of nasopharyngectomy for NPC

Aggregate grade of evidence	C (Level 2: two studies; Level 4: 17 studies)
Benefit	Endoscopic nasopharyngectomy (ENPG) has become an effective treatment for patients with early local recurrent NPC, demonstrating good survival outcomes and low complication rates. It avoids not only the severe side effects caused by re-irradiation but also complications (e.g., functional problems and cosmetic morbidities) that may be encountered during traditional open approaches.
Harm	Positive margins, especially around critical neurovascular structures; risk of ICA injury, leading to intraoperative and postoperative hemorrhage; wound infection; injury to surrounding critical neurovascular structures.

(Continued)

Cost	ENPG may have a lower cost than re-irradiation because of the relatively shorter treatment duration and ensuring faster recovery.
Benefits-harm assessment	Balance of benefits and harms.
Value judgments	Current data suggest that ENPG is a promising treatment option for most patients with early-stage local recurrent NPC, with minimal complications. However, only one RCT has been conducted. Although selected patients with advanced-stage recurrent NPC may benefit from ENPG, long-term follow-up is needed to evaluate the eventual morbidity from and efficacy of the procedure.
Policy level	Option.
Intervention	ENPG is a good option for early local recurrent NPC (rT1 and rT2 and select rT3 lesions), with limited complications and promising outcomes. Meticulous preoperative evaluation and a full understanding of the surgical anatomy are important to prevent significant complications such as ICA injury.

Role of IMRT in treatment of NPC

Aggregate grade of evidence	A (Level 1: two studies; Level 3: one study)
Benefit	IMRT improves OS and LRC in locally advanced NPC and reduces long-term toxicities including xerostomia, trismus, and temporal lobe neuropathy in all stages.
Harm	IMRT has no additional harm compared to conventional two-dimensional RT.
Cost	IMRT significantly increases the time needed for radiotherapy planning and the direct cost of RT. However, reduction in late toxicities translates to long-term cost savings, which would be very hard to measure. Exact cost comparison analyses accounting for those would be very difficult to perform.
Benefits-harm assessment	Preponderance of benefits over harms.
Value judgments	Patients should be treated with IMRT whenever possible.
Policy level	Strong recommendation.
Intervention	IMRT is the current standard of care for primary radiation treatment of NPC.

Role of concurrent chemoradiation therapy in treatment of advanced-stage NPC

Aggregate grade of evidence	A (Level 1: one meta-analysis of 4800 patients in 19 trials)
Benefit	The addition of concurrent chemotherapy to radiation in advanced-stage NPC improves OS (HR 0.79), and absolute increase in OS at 5 years is 6.3%.
Harm	Increased acute toxicities with CRT.
Cost	Addition of chemotherapy incurs increase in treatment cost. Cost comparison analyses have not been undertaken.
Benefits-harm assessment	Preponderance of benefits over harms.
Value judgments	Addition of concurrent chemotherapy is justified in advanced-stage NPC, unless patient has reduced performance status.
Policy level	Strong recommendation.
Intervention	Concurrent chemotherapy with cisplatin is recommended for advanced-stage NPC. There is no difference in survival outcomes for weekly cisplatin regimen versus every 3 weeks dosing.

Role of concurrent chemoradiation therapy in treatment of early-stage NPC

Aggregate grade of evidence	A (Level 1: two studies; Level 2: one study)
Benefit	Addition of concurrent chemotherapy during RT improves survival in advanced-stage NPC, but the benefit is less clear in earlier stage disease.
Harm	Addition of concurrent chemotherapy significantly increase the risk of acute grade 3–4 neutropenia.
Cost	Addition of chemotherapy increases treatment cost. Cost comparison analyses have not been undertaken.
Benefits-harm assessment	Preponderance of harms over benefits.
Value judgments	Except for T2N1 disease with bulky lymph node metastasis, addition of chemotherapy may not improve survival especially for patients receiving IMRT. Routine CRT is not routinely recommended in stage II NPC as it is associated with increased toxicity with unclear survival benefits.
Policy level	Recommendation against.
Intervention	CRT with cisplatin should only be considered in stage II patients with bulky nodal disease.

Role of induction chemotherapy in treatment of NPC

Aggregate grade of evidence	A (Level 1: one study; Level 2: five studies)
Benefit	Induction chemotherapy improves most survival parameters, with GP for three cycles having the best OS followed by TPF.
Harm	Use of IC increases grade 3 and 4 adverse events with TPF having the highest number of adverse events. However, long-term QOL may be similar or even better than CRT alone.
Cost	Cost comparison analyses have not been undertaken.
Benefits-harm assessment	Preponderance of benefits over harms.
Value judgments	For patients with high performance status and minimal co-morbidity, IC would improve the survival. However, IC increases the toxicity of treatment and may not be tolerated by patients with less-than-optimal performance status or comorbidities. Nevertheless, IC with gemcitabine and cisplatin (GC) regimen has survival benefits, which justifies the increased cost and toxicity during treatment.
Policy level	Strong recommendation.
Intervention	IC with GP or TPF, for three cycles before definitive CRT, should be considered for advanced-stage NPC (stage III–IVB, excluding T3N0) in patients who can tolerate the treatment.

Lymphoma

Sinonasal lymphoma is commonly underrecognized, and accurate classification of disease type through histopathology, immunohistochemistry (IHC), flow cytometry, and molecular studies is important for treatment planning. Diffuse large B-cell lymphoma (DLBCL) is the most common variety, while extranodal NK/T-cell lymphoma (ENKTL) has worse prognosis. DLBCL is treated primarily with chemotherapy and immunotherapy with or without RT, while ENKTL is treated with chemoradiation.

Role of chemotherapy: B-cell lymphoma

Aggregate grade of evidence	B (Level 3: four studies; Level 4: eight studies)
Benefit	Chemotherapy has been associated with improved survival in patients with sinonasal BCL.

(Continued)

Harm	Risks of morbidity from chemotherapeutic regimens, including R-CHOP for three or six cycles, and any potential morbidity from CNS prophylaxis regimens.
Cost	There have been no clinical studies examining the cost of chemotherapy in the treatment of sinonasal lymphoma.
Benefits-harm assessment	Preponderance of benefits over harms.
Value judgments	When considering chemotherapeutic treatment, clinicians should have a detailed conversation with their patients about the risks and benefits of the treatment along with a realistic discussion of potential treatment outcomes. CNS prophylaxis may be considered, and some studies have shown a potential survival benefit.
Policy level	Recommendation.
Intervention	Chemotherapy is the preferred option in the treatment of sinonasal BCL. The most common regimens include CHOP or CHOP-like therapy.

Role of radiation therapy: B-cell lymphoma

Aggregate grade of evidence	C (Level 3: one study; Level 4: eight studies)
Benefit	RT may help reduce the disease burden in patients with bulky disease, partial chemotherapeutic response, and extranodal involvement. Some studies have shown improved survival in sinonasal DLBCL patients who received RT in addition to chemotherapy.
Harm	Potential morbidity from radiation treatment.
Cost	There are no studies examining the cost of RT in sinonasal BCL.
Benefits-harm assessment	Balance of benefits and harms.
Value judgments	RT should be considered in the treatment of sinonasal lymphoma as an adjunct to chemotherapy in patients with bulky, symptomatic disease, advanced stage, or a partial response to chemotherapy. Patients should be counseled regarding the potential morbidity of RT as well as the uncertain impact on survival.
Policy level	Option.
Intervention	The addition of RT to chemotherapeutic regimens should be considered for sinonasal BCL patients who are symptomatic (i.e., cranial nerve palsies), have bulky disease, or are in an advanced stage.

Role of immunotherapy: B-cell lymphoma

Aggregate grade of evidence	B (Level 3: two studies; Level 4: two studies)
Benefit	The addition of rituximab to CHOP treatment regimens significantly improves survival for patients with sinonasal BCL.
Harm	Potential morbidity, including infusion-related reactions and severe skin and mouth reactions, from the addition of immunotherapy to chemotherapeutic treatment regimens.
Cost	There are no clinical studies addressing the cost of immunotherapeutics in the treatment of sinonasal lymphoma.
Benefits-harm assessment	Preponderance of benefits over harms.
Value judgments	Patients should be counseled on the risks of rituximab treatment as well as the potential benefits including improved OS.
Policy level	Recommendation.
Intervention	Rituximab should be added to CHOP for the treatment of sinonasal BCL given survival benefits.

Role of chemotherapy: Extranodal NK/T-cell lymphoma

Aggregate grade of evidence	C (Level 4: 24 studies)
Benefit	Chemotherapy is a cornerstone to ENKTL treatment, and current evidence suggests a survival benefit with treatment.
Harm	Chemotherapeutics are known to be toxic with common side effects including hematologic disturbances (e.g., pancytopenia), which can be severe and life-threatening.
Cost	Cost of treatment is significant, especially if several cycles of therapy are required for effect.
Benefits-harm assessment	Preponderance of benefits over harms.
Value judgments	In patients with severe comorbidities, RT alone or enrollment in clinical trials can be considered.
Policy level	Recommendation.
Intervention	Chemotherapy, as the first-line treatment, should be offered to patients with ENKTL if they are able to tolerate treatment, despite its known toxicities.

Role of radiation therapy: Extranodal NK/T-cell lymphoma

Aggregate grade of evidence	C (Level 4: 24 studies)
Benefit	RT has been demonstrated to improve LRC and recommended for almost all treatment paradigms outside clinical trials.
Harm	RT has significant potential morbidity in terms of damage to adjacent tissue, including risks of vision loss and brain necrosis in extreme cases.
Cost	There is significant cost to the intervention including institutional costs for equipment and patient time and morbidity from treatment.
Benefits-harm assessment	Preponderance of benefits over harms.
Value judgments	Patients who have received previous head and neck radiation deserve careful consideration of the morbidity of reirradiation given increased side effects.
Policy level	Recommendation.
Intervention	RT should be offered to all patients undergoing treatment for ENKTL for LRC benefits.

Metastatic tumors

Metastatic tumors to the sinonasal tract are rare. The most common primary tumor is renal cell carcinoma. Although systemic therapies play a dominant role in treatment of metastatic disease, surgical resection or targeted RT to a solitary lesion may be an option for palliation.

Section 4: Morbidity, QOL, and surveillance

Risk factors for surgical complications

- Advanced age, comorbidities, history of RT, and advanced stage have been previously cited as risk factors for complications; however, there is no consensus based on the literature.
- The endoscopic approach is associated with shorter recovery times as compared to the open approach and may have a lower complication profile.
- Salvage surgery seems to be associated with higher morbidity and complication risk than primary surgery.

Quality of life instruments

With improved survival, consideration of morbidity and secondary outcomes such as QOL becomes increasingly important. There are numerous validated QOL instru-

ments that have been used to assess outcomes for sinonasal tumors, though no specific instrument has been developed solely for sinonasal tumors.

Assessment of QOL in sinonasal tumors

Aggregate level of evidence	B (Level 1: two studies; Level 2: eight studies; Level 3: nine studies; Level 4: one study)
Benefit	QOL outcomes for patients with sinonasal tumors have been studied with reliable instruments that have been validated for sinonasal disorders or head and neck malignancies.
Harm	No consensus has been made for the best instrument for assessing QOL in sinonasal tumors.
Cost	Time (interviewer, patient, data entry, and data analysis); survey fatigue especially with multiple instruments
Benefits-harm assessment	Preponderance of benefits over harms.
Value judgments	Since there is no well-defined superior metric, multiple metrics may be needed for full evaluation of QOL outcomes. More studies directly comparing QOL metrics should be performed specific to sinonasal tumor outcomes.
Policy level	Recommendation.
Intervention	QOL surveys should be utilized during the management of patients with sinonasal tumors to monitor patient outcomes, as they have the potential to provide valid and reliable information on outcomes for patients with sinonasal tumors.

Quality of life for benign and malignant neoplasms

- QOL scores tend to improve from baseline after treatment. Benign tumors are associated with higher QOL at baseline when compared to malignancies. QOL after treatment of SNM may be modified by adjuvant therapy (i.e., RT).
- Extended maxillary sinus approaches do not seem to worsen long-term QOL.
- Overall rates of orbital preservation in the literature, when attempted, are high (60%–90%). Intradural resection tends to mainly affect olfaction-related QOL.

Morbidity/QOL following multimodality treatment

All treatment modalities carry the risk of complications, morbidity, and negative impact on QOL. QOL is generally worst in the first few weeks following treatment, but improves and stabilizes over time. RT is associated

with both acute and late toxicities, with radiation necrosis being an important consideration in patients with sinonasal tumors, particularly those involving the skull base. Chemotherapy-related adverse events (AEs) are highly common, with up to half of patients having severe events during treatment.

General QOL following multimodality treatment

Aggregate level of evidence	C (Level 1: one study; Level 3: six studies; Level 4: two studies)
Benefit	Treatment of SNM is critical to long-term survival and disease control.
Harm	SNM treatment affects multiple aspects of QOL, including physical aspects, such as sinonasal symptoms, as well as emotional aspects, with increased rates of mental health disorders and neurocognitive deficits. Most studies show that QOL is worse in the first several months after treatment but improves with time.
Cost	Cost comparison analyses have not been undertaken.
Benefit-harm assessment	Preponderance of benefits over harms.
Value judgments	Treatment of SNM does cause long-term side effects and decreased QOL; however, most symptoms improve with time after treatment. Most patients have persistently decreased sinonasal QOL, as well as a long-term elevated risk of mental health disorders and neurocognitive deficits.
Policy level	Recommendation.
Intervention	QOL is expected to decrease following treatment for SNM, and treating providers should counsel patients on this accordingly. Patients should expect to have worse symptoms, particularly with regard to sinonasal symptoms, in the first several months, but these should gradually improve with time. Providers should be aware of increased rates of cognitive deficits and mental health disorders in this population.

Morbidity following surgical treatment

Aggregate level of evidence	C (Level 2: one study; Level 3: 13 studies; Level 4: four studies)
Benefit	Endoscopic surgical approaches are associated with decreased postoperative complications and faster recovery compared to open surgical approaches.

(Continued)

Harm	Surgical treatment of SNM has been found to cause long-term sinonasal symptoms and decreased sinonasal-specific QOL. Sinonasal symptoms are worst in the first month after surgery but improve with time, back to or exceeding the presurgical baseline.
Cost	Cost comparison analyses have not been undertaken.
Benefits-harm assessment	Preponderance of benefits over harms.
Value judgments	Surgical treatment of SNM is associated with long-term side effects and morbidity. While overall serious complications and morbidity are lower with the endoscopic approach, the endoscopic approach does cause increased sinonasal morbidity, which has been shown to affect sinonasal-specific and general QOL.
Policy level	Recommendation to attempt endoscopic surgical approach when feasible in order to preserve QOL. Recommendation to anticipate the QOL implications of surgical treatment when treating SNM.
Intervention	Endoscopic surgical resection of SNM is associated with decreased postoperative QOL, particularly in sinonasal domains. Open surgical resection is associated with higher rates of serious postoperative complications. QOL tends to improve with time after surgery and returns to baseline in many studies.

Morbidity following radiation treatment including osteoradionecrosis

Aggregate level of evidence	C (Level 2: one study; Level 3: 12 studies; Level 4: six studies)
Benefit	RT is associated with improved disease control for most pathologies and stages of SNM. Proton beam may reduce RT morbidity, but data are mixed.
Harm	SNM RT is associated with both early and late toxicities, including mucositis, dermatitis, nasal morbidity, xerostomia, and dysphagia. Severe side effects, such as blindness and brain necrosis, are proportional to the volume and dose of RT, and the morbidity of RT is intensified in the re-irradiation setting. Skull base osteoradionecrosis (ORN) is rare and management is primarily surgical.
Cost	Cost comparison analyses have not been undertaken.

(Continued)

Benefit-harm assessment	Preponderance of benefits over harms.
Value judgments	Treatment of SNM with RT is frequently indicated for improved disease control; however, it does cause both short- and long-term morbidities. Proton beam RT may be considered to reduce side effects. For ORN, medical management may be attempted but management is typically surgical.
Policy level	Recommendation.
Intervention	RT is associated with improved local control and survival for many tumors but leads to impaired QOL, principally affecting sinonasal symptoms. Acute symptoms are common, as are long-term toxicities. Proton therapy can be considered for a reduction in morbidity. Skull base ORN can be managed medically or surgically, with growing evidence suggesting safety and efficacy.

Morbidity following chemotherapy and immunotherapy

Aggregate level of evidence	B (Level 1: two studies; Level 2: nine studies. Level 3: eight studies)
Benefit	Chemotherapy, either in the induction or adjuvant setting, is indicated for many sinonasal malignancies (SNMs) to improve disease control. Immunotherapy and intra-arterial chemotherapy both attempt to reduce toxicity while improving disease control.
Harm	Adverse events (AEs) from systemic chemotherapy are very common, with almost all patients having at least low-grade AEs and more severe AEs occurring in approximately half of patients, depending on the study and agent. Intra-arterial chemotherapy spares some systemic toxicity but may increase local toxicity. Immunotherapy has less side effects than conventional chemotherapy and can have both immune-related side effects and non-immune-related side effects.
Cost	Cost comparison analyses have not been undertaken.
Benefits-harm assessment	Preponderance of benefits over harms.
Value judgments	Chemotherapy may improve survival in many SNMs but is associated with adverse side effects that impact QOL. Specific side effects vary by agent.

(Continued)

Policy level	Recommendation.
Intervention	Chemotherapy in the induction or adjuvant setting is associated with decreased QOL, with specific AEs varying by specific agent. While many of the AEs are short term, long-term toxicities that impact QOL are common. It is important to weigh the effects of chemotherapy on QOL against the potential benefits for disease control.

Surveillance

To date, much of the literature on surveillance has been based on principles abstracted from mucosal cancers of the head and neck. In contrast, sinonasal tumors represent a highly diverse group of diseases with variable biologic behavior. Late recurrences (>5 years) are possible with many tumors, specifically IP, ONB, and ACC. Surveillance is conducted using a combination of patient history and exam, endoscopy, and imaging, with long-term monitoring (perhaps even lifelong) a strong consideration for many tumors at high risk for recurrence.

Role of assessment based on physical exam, signs, and symptoms

Aggregate grade of evidence	C (Level 3: three studies)
Benefit	Early detection of recurrent tumors with possibility of timely intervention.
Harm	Missing a diagnosis of a recurrent or persistent tumor given relatively low rates of detection.
Cost	Direct costs: consultation fees and travel costs.
Benefits-harm assessment	Preponderance of benefits over harms.
Value judgments	Physical examination of the paranasal sinuses is difficult given the anatomic location. Exam findings should focus on cranial neuropathies, ocular findings, and new-onset lymphadenopathy.
Policy level	Recommendation.
Intervention	Symptoms and physical exam findings often present in advanced disease. A complete history and physical examination should be performed at each posttreatment examination. Screening of symptoms should include presence of new onset epistaxis, intractable facial pain, and cranial neuropathies.

Role of endoscopy for surveillance

Aggregate grade of evidence	C (Level 3: two studies; level 4: one study).
Benefit	Detection of a primary tumor recurrence, assess extent of involvement, and evaluation for feasibility of resection.
Harm	Risk of local tissue trauma and potential to miss recurrence deep to mucosa.
Cost	Direct costs: procedure fees and consultation fees.
Benefits-harm assessment	Preponderance of benefits over harms.
Value judgments	Direct visualization of the paranasal sinuses with rigid or flexible endoscopes should be performed, especially for postsurgical patients.
Policy level	Recommendation.
Intervention	Nasal endoscopy should be performed at each surveillance visit to assess for local tumor recurrence within the sinonasal tract, as well as to assess mucosal health and side effects (e.g., crusting).

Role of imaging for surveillance

Aggregate grade of evidence	C (Level 3: seven studies; level 4: one study).
Benefit	Detection of recurrent disease that cannot be detected through physical exam or nasal endoscopy (e.g., lateral frontal sinus, submucosal, intracranial, intraorbital).
Harm	Minimal harm of radiation and allergic reaction from radioisotopes. Potential for unnecessary testing leading to financial consequences.
Cost	Direct costs: variable cost depending on institution and imaging protocols.
Benefits-harm assessment	Preponderance of benefits over harms.
Value judgments	FDG-PET/CT should be used for evaluation of regional or distant metastases, while MRI is the treatment of choice for surveillance of the primary site (i.e., superior soft tissue definition). CT can be considered but has less sensitivity compared to MRI.
Policy level	Recommendation.

(Continued)

Intervention	Posttreatment imaging should be performed to detect residual or recurrent disease. MRI and/or FDG-PET/CT should be the modality of choice. Multiple scans provide for adequate comparison of changes across time. The timing is left to provider discretion, but FDG-PET/CT should be performed 12 weeks following completion of treatment, and MRI should be performed within 8–10 weeks following treatment.
--------------	--

Differences in surveillance practices based on histology

Aggregate grade of evidence	D (no dedicated studies)
Benefit	Detection of recurrent or residual sinonasal tumors.
Harm	Missing late or early recurrence of disease; unnecessary testing or examinations.
Cost	None.
Benefits-harm assessment	Insufficient evidence.
Value judgments	Sinonasal tumors behave differently from other head and neck tumors. Surveillance should be tailored to specific tumor histology and biologic behavior.
Policy level	No recommendation.
Intervention	Tumor histology should be taken into consideration when determining the appropriate surveillance protocols. Most tumors recur within the first 5 years; however, certain pathologies (e.g., IP, ONB) have propensity for recurrence greater than 10 years following definitive treatment.

Figure I.1 provides a sample diagnosis through management through survivorship paradigm based on ICSNT findings.

D | Discussion

Oncologic care is highly individualized, and while guidelines may not always be practical, it is crucial to utilize evidence-based medicine to inform patient care. The ICSNT aims to address this need and bridge the gap. Given the relative rarity of sinonasal tumors, the LOE available for most topics remains low, primarily consisting of aggregate grade C evidence derived from observational studies

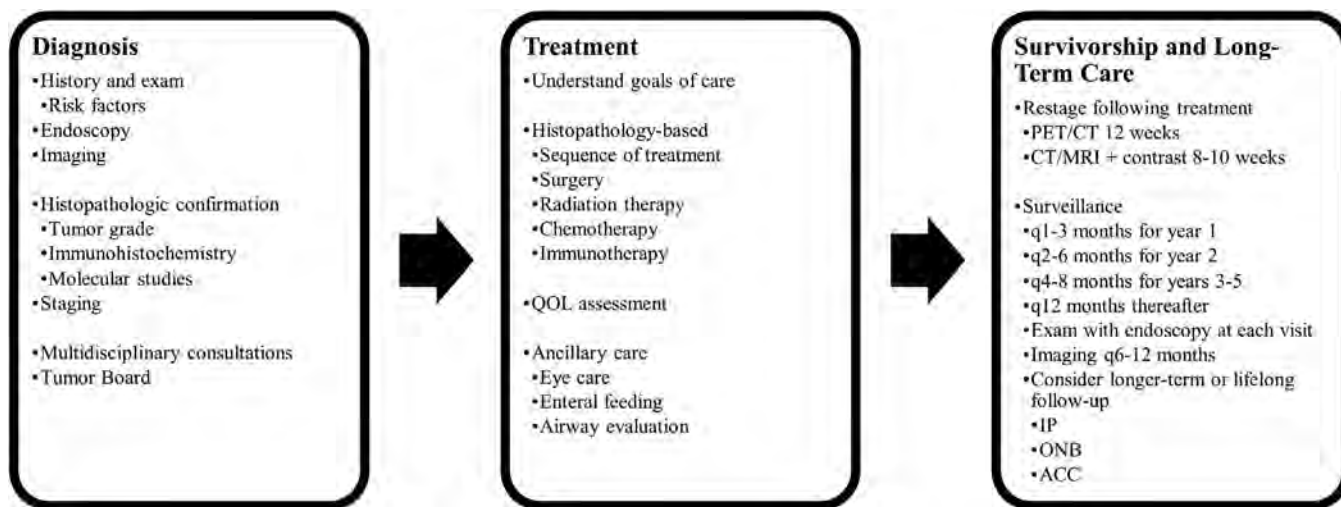


FIGURE I.1 Sample paradigm for sequence of diagnosis, management, and survivorship/surveillance for sinonasal tumor patients based on International Consensus Statement on Allergy and Rhinology: Sinonasal Tumors (ICSNT) evidence.

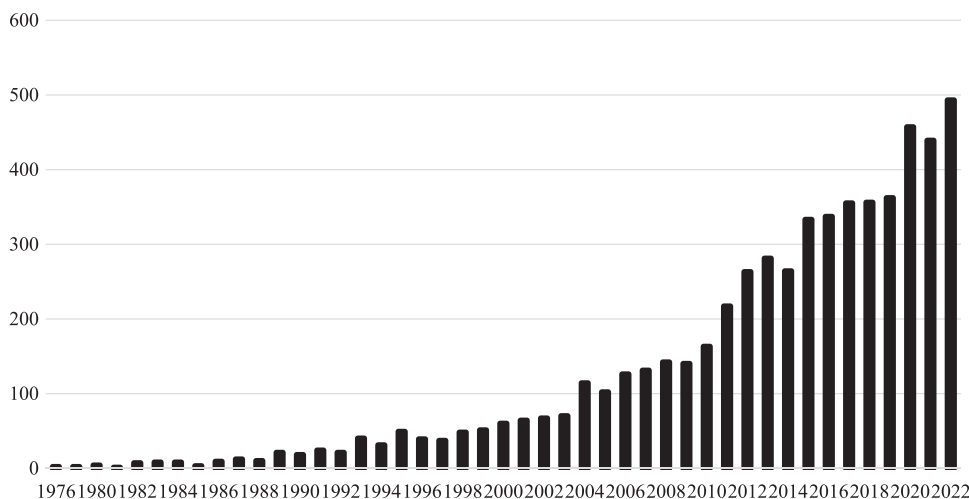


FIGURE I.2 Number of annual PubMed-indexed publications from 1976 to 2022 on sinonasal tumors. The search query used was “sinonasal tumors OR sinonasal malignancy.”

like case-control and cohort designs. This highlights the urgent call for further research and investigations in this underresearched field, especially considering the growing interest (Figure I.2). Traditionally, rhinology and head and neck oncology have developed separately, focusing on different primary disease processes, namely, QOL and elective treatment versus diseases that cause potential harm and mortality. However, there is an opportunity for these specialties to unite and better serve patients. Multidisciplinary collaboration, such as tumor boards, has been a cornerstone of oncologic care, and we can similarly learn a great deal from medical and radiation oncologists who have set higher standards in the literature. In fact, some of the highest levels of evidence within ICSNT are for conditions that are nonsurgically managed, such

as NPC and lymphoma. The future holds promise with prospective, multi-institutional studies that define consistent interventions and outcome measures, as well as a deeper understanding of tumor biology and its applications in precision medicine. It is anticipated that future versions of this document will identify new research questions and eventually accrue enough evidence to formulate new recommendations.

II | INTRODUCTION

Sinonasal tumors have traditionally been considered rare among head and neck neoplasms, accounting for fewer than 5% of cases.¹⁰ Due to the potential involvement of

critical neurovascular structures, nonspecific signs and symptoms, and common presentation at an advanced stage, sinonasal tumors pose unique challenges for even the most experienced clinical teams. Nevertheless, the subfield of “sinonasal oncology” has grown rapidly over the past decade as our understanding of this diverse and heterogeneous group of diseases has improved.

While much of the literature on sinonasal tumors in otolaryngology has been limited to retrospective, single-institutional reports, there have been recent efforts to study this topic in a multi-institutional fashion. Several excellent textbooks by world experts have been written about this topic.^{11–13} Only recently have there been more concerted efforts to study this topic in a multi-institutional fashion.^{14–16} The only other major collaborative project on sinonasal tumors involving international experts was the EPOS document on Endoscopic Management of Tumours of the Nose, Paranasal Sinuses and Skull Base published in 2010.⁶

Just as comprehensive care of the sinonasal tumor patient often involves a multidisciplinary team, the spirit of the ICSNT is to engage the expertise and experiences of a wide number of specialists spanning multiple disciplines (otolaryngology including rhinology and head and neck surgery, medical oncology, radiation oncology, neurosurgery, pathology, and radiology) in order to provide a state-of-the-art, up-to-date summation of the current LOE regarding diagnosis, treatment, and prognostication of sinonasal neoplasms. The individual sections were composed by authorship “teams,” simulating the teams-based environment of sinonasal tumor care, encompassing members of institutional clinical, consortium, and/or research collaborations. The document is organized based on four major sections and is largely histopathology driven. The content is complementary to that presented in ICSB 2019 and serves as an update to the celebrated EPOS 2010 document. Importantly, the ICSNT represents a summary of the evidence and does not serve as clinical guidelines or represent “standard of care.” Instead, it is intended to be a tool for clinicians to utilize evidence-based medicine in developing clinical decisions for patients.

Given the rarity of each individual condition and the focus on histopathology-driven sections, the overall evidence level of each section is variable, with some sections largely dictated by randomized controlled trials, while others are limited to small case series. Based on this variability, the editorial team has attempted to select the best and most informative format by which to present each condition. One major windfall of this document is the valuable opportunity for otolaryngologists to learn from medical and radiation oncology colleagues who have driven the field forward in a parallel and complementary direction,

where the LOE is greatly elevated by the use of creative and thoughtful clinical trials.

In conclusion, the ICSNT represents an effort toward advancing our field’s understanding of sinonasal tumor management principles. Just as comprehensive care of the sinonasal tumor patient often involves a multidisciplinary team, by engaging the expertise and experiences of a wide range of specialists, it aims to provide a valuable resource for clinicians seeking to develop individualized workup and treatment plans for their patients. Furthermore, the ICSNT offers a valuable opportunity for otolaryngologists to learn from colleagues in other specialties and to leverage evidence-based medicine in developing the best possible outcomes for their patients.

III | METHODS

A | Topic development

Similar to prior ICAR documents, the main objective of the ICSNT document was to focus on the current LOE within the available literature, as opposed to expert opinion or experiential accounts, for the core topics facing the field of sinonasal tumors.^{1–5} Also similar across other ICAR projects, the methodology for developing evidence-based recommendations was adapted from Rudmik and Smith.⁷

Sinonasal tumors is an extremely broad topic, spanning multiple disciplines, and with ever evolving evidence being generated across simultaneous fronts. The initial topic outline was developed by the senior editor (JNP), the primary editor (ECK), chief associate editor (EWW), and the associate editors (NDA, DMB, NRL, SYS, MBW) and aimed to classify all topics into four major topic areas: (1) General Principles; (2) Benign Lesions and Neoplasms; (3) Malignant Neoplasms; and (4) Morbidity, Quality of Life, and Surveillance. Within each major topic area, subtopics were developed based on well-established oncologic principles as applied to sinonasal tumors and a histopathology-driven approach based on the World Health Organization (WHO) classification, as befitting of such a diverse set of diseases with individual biologic behaviors, treatment options, and outcomes.¹⁷ The list of topics was also carefully reviewed to avoid significant overlap with topics covered in ICSB given recent summation of the evidence, and the ICSNT was designed to cross reference the ICSB in areas with common ground.⁵ Some overlapping sections of particular relevance (e.g., ONB, SNEC) were updated with the most recent literature from the prior ICSB in order to reflect critical new work in these areas. This full outline of 48 sections was then reviewed by the editorial staff, consulted with the editorial leadership of *International Forum of Allergy*

& *Rhinology*, and revised accordingly until approved by all parties.

Naturally, the LOE was highly variable across sections. For lesser researched concepts and/or very rare pathologies, a literature review was designated as appropriate. For topics with moderate, but nevertheless limited, LOE, an EBR without recommendations was assigned. Finally, for those topics with sufficient evidence to inform clinical care, an EBRR was assigned.

Following this, a primary contributing author who is a recognized expert on the topic was assigned to author each section. Contributing authors were selected based on publication history and track record of academic contributions to the field of sinonasal tumors. To emphasize the multidisciplinary and collaborative spirit of this field and thus this document, the primary contributing author representing an institution and/or consortium was permitted to invite a predetermined, section-specific number of team members and collaborators to contribute to the section. The team members could recommend any relevant specialty (e.g., rhinology, head and neck surgery, radiation oncology, medical oncology), needed not be from the same institution, and the author was recommended to invite collaborators in a particular area in which the point person is familiar with their work. Each author team was permitted to include one or two consultant authors to help with drafting the section.

Following commitment to the project, instructions for completing the sections were distributed to the authors, again with a focus on assessing the available literature as opposed to providing expert opinion. The specific section methodology follows that of a systematic review using the PRISMA standardized guidelines.⁸ The recommended search for each topic was conducted using Ovid MEDLINE (National Library of Medicine, 1946—November 2021), EMBASE (Elsevier, 1947—November 2021), and the Cochrane review database (1993—November 2021). Consistent with PRISMA guidelines and the prior ICAR statements, the systematic review of each topic began with the identification of prior published systemic reviews or guidelines. Authors were instructed to identify the highest levels of evidence first (systematic reviews and meta-analyses, randomized controlled trials), then consider descending levels (observational, then case series) as appropriate based on what exists in the literature. Authors were also asked to submit PRISMA flow diagrams for their section prior to drafting their sections, which was then reviewed by the editorial team to ensure that the literature search followed the proposed methodology. For histopathology-specific sections, appropriate inclusion of background information, such as those related to epidemiology, imaging, and histopathology, was requested in

order to add context to the individual biological entities for the readership. Additionally, authors were recommended to include only studies with a minimum sample size to ensure consistency in evidence quality, though this was dependent on the rarity of the tumor and/or technique. Specifically, unless of highly unusual but relevant value, case reports and case series with $n < 5$ were excluded. On the other hand, if there was sufficient literature to support a high standard (e.g., SCC), it was deemed reasonable to exclude case series of low sample size or even all case series.

In EBR and EBRR sections, all included studies were presented in a standardized table format per prior ICAR guidelines (study with name of lead author, year of publication, LOE, study design, study groups, clinical endpoints, and conclusion). The 2011 Oxford Level of Evidence (Levels 1–5) was utilized to grade the quality of each study (Table III.1).¹⁸ LOE was determined by authors and may be downgraded based on numerous factors, and this was secondarily reviewed by the editorial leadership to ensure appropriate reasoning and consistency across the entire document, whenever possible. Once this was complete, an aggregate grade of evidence (A–D) was determined based upon the guidelines from the AAP SCQIM, and the number of studies of each LOE utilized to make this determination was reported (Table III.2).⁹ For EBRR sections, a standardized reporting of recommendations based on benefits, harms, costs, and other relevant judgments was included after each subtopic review (Table III.3).

B | Iterative review

Once the section was completed and submitted per instructions, it then underwent a two-stage iterative review process by two associate editors. Associate editors were tasked to review each section for accurate and comprehensive inclusion of relevant literature, appropriateness of aggregate grade of evidence (AGE) and recommendations, adherence to the methodology and formatting, and coherence and flow throughout the document. Following review by both associate editors, the section was returned to the author team for revisions, and this process continued across all parties until all changes were agreed upon (consensus).

C | ICSNT statement development

Once the section was iteratively reviewed and consensus was reached, the primary editor (ECK) reviewed the section and synthesized all sections into the ICSNT document.

TABLE III.1 2011 Oxford levels of evidence.¹⁸

Question	Step 1 (Level 1 ^a)	Step 2 (Level 2 ^a)	Step 3 (Level 3 ^a)	Level 4 (Level 4 ^a)	Step 5 (Level 5)
How common is the problem?	Local and current random sample surveys (or censuses)	Systematic review of surveys that allow matching to local circumstances ^b	Local nonrandom sample ^b	Case series ^b	Not applicable
Is this diagnostic or monitoring test accurate? (Diagnosis)	Systematic review of cross-sectional studies with consistently applied reference standard and blinding	Individual cross-sectional studies with consistently applied reference standard and blinding	Nonconsecutive studies, or studies without consistently applied reference standards ^b	Case-control studies or poor ^a or nonindependent reference standard ^b	Mechanism-based reasoning
What will happen if we do not add a therapy? (Prognosis)	Systematic review of inception cohort studies	Inception cohort studies	Cohort study or control arm of randomized trial ^{er}	Case series or case-control studies, or poor-quality prognostic cohort study ^b	Not applicable
Does the intervention help? (Treatment Benefits)	Systematic review of randomized trials or <i>n</i> -of-1 trial	Randomized trial or observational study with dramatic effect	Nonrandomized controlled cohort/follow-up study ^b	Case series, case-control studies, or historically controlled studies ^b	Mechanism-based reasoning
What are the COMMON harms? (Treatment Harms)	Systematic review of randomized trials, systematic review of nested case-control studies, <i>n</i> -of-1 trial with the patient you are raising the question about, or observational study with dramatic effect	Individual randomized trial or (exceptionally) observational study with dramatic effect	Nonrandomized controlled cohort/follow-up study (postmarketing surveillance), provided there are sufficient numbers to rule out a common harm. (For long-term harms, the duration of follow-up must be sufficient.) ^b	Case series, case-control, or historically controlled studies ^b	Mechanism-based reasoning
What are the RARE harms? (Treatment Harms)	Systematic review of randomized trials or <i>n</i> -of-1 trial	Randomized trial or (exceptionally) observational study with dramatic effect			
Is this (early detection) test worthwhile? (Screening)	Systematic review of randomized trials	Randomized trial	Nonrandomized controlled cohort/follow-up study ^b	Case series, case-control, or historically controlled studies ^b	Mechanism-based reasoning

^aLevel may be graded down on the basis of study quality, imprecision, indirectness (study PICO does not match questions PICO), inconsistency between studies, or very small absolute effect size; level may be graded up if there is a large or very large effect size.

^bAs always, a systematic review is generally better than an individual study.

TABLE III.2 Aggregate grade of evidence (AGE) and recommendation development guidelines.⁹

Evidence quality (AGE)	Preponderance of benefit over harm	Balance of benefit and harm	Preponderance of harm over benefit
A. Well-designed randomized controlled trials (RCTs)	Strong Recommendation	Option	Strong Recommendation Against
B. RCTs with minor limitations; Overwhelmingly consistent evidence from observational studies	Recommendation		
C. Observational studies (case control and cohort design)			Recommendation Against
D. Expert opinion, case reports, Reasoning from first principles	Option	No Recommendation	

TABLE III.3 Reporting guidelines for aggregate grade of evidence (AGE) with evidence-based recommendations.

Items	Explanation
Aggregate grade of evidence	*The final aggregate grade of evidence. *In parentheses, it is helpful to state the total number of individual studies for each research quality level of evidence. **For example, the “Aggregate Grade of Evidence” section would state: B (<i>Level 1: three studies; Level 2: two studies</i>)
Benefit	Explicitly state the benefits offered by the clinical intervention
Harm	Explicitly state the potential harm of using the clinical intervention
Cost	May include the following: 1. Direct costs: monetized value for any relevant interventions 2. Indirect costs: time off work, time for daily therapy.
Benefits-Harm assessment	The authors’ decision for the balance of benefit to harm
Value Judgments	A statement that the authors feel is important for the readers to understand while evaluating the clinical topic
Policy level	*Clearly defined recommendation level: using the AAP recommendation strategy *Categorized as: <i>Strong Recommendation, Recommendation, Option, Recommendation Against, Strong Recommendation Against, No Recommendation</i>
Intervention	A clinical practice, supported by the evidence, which can be implemented by the reader in a clinical situation.

This assembled document was then sent out to all contributing authors for final review to ensure consensus prior to submission for publication.

D | Limitations

There are noted limitations to any large-scale, multiauthor, multidisciplinary document spanning the breadth and depth of a topic such as sinonasal tumors. First, there is wide variability in the quality of literature across topics, and authors in different disciplines may have different frameworks of what literature states about a particular topic. Yet, with a large number of contributing authors and editorial members, it is not possible or practical to assess inherent bias in interpreting the literature or reviewing the sections. Second, case reports, case series, and studies with low sample size ($n < 5-10$) were purposely excluded, and thus it is challenging to provide a truly comprehensive assessment of studies. Third, despite efforts to be consistent with assigning LOE per the Oxford 2011 guidelines, the process remains somewhat subjective, and different articles may be interpreted with varying LOE by different readers. Fourth, the editorial team encouraged each author team to freely interpret the literature and complete the evidence tables as they determined fit, and thus there may be some variability in table formatting across sections. Finally, with a rapidly growing field such as sinonasal tumors, where new discoveries can completely change tumor classification schemes (i.e., the recent update of the WHO Classification of Tumors to its 5th edition in 2022¹⁷), the editorial team recognizes that not all relevant topics may be included in the current document.

SECTION I: GENERAL PRINCIPLES

IV | INCIDENCE AND EPIDEMIOLOGY

Benign and malignant sinonasal tumors are a clinically and pathologically heterogeneous group of neoplasms.^{17,19} As described in the WHO classification system, it is helpful to divide sinonasal tumors into categories based on the

tissue of origin and benign versus malignant histology.¹⁷ Given the large variability in pathology and epidemiology of benign neoplasms, this section will predominantly focus on malignant neoplasms. Malignant tumors of the nasal cavity and paranasal sinuses are relatively rare compared to other malignancies of the head and neck region. SNM is approximated to comprise 3%–5% of all head and neck cancers and less than 1% of all malignancies overall.^{20–22} Due to low incidence and large variety of histologic subtypes, true incidence and prevalence estimates have been difficult to accurately measure until recently, with the introduction of large national epidemiologic surveillance programs. Some of the largest studies to date have utilized the Surveillance, Epidemiology, and End Results (SEER) database (population-based) through the U.S. National Program of Cancer Registries and the Center of Disease Control's National Cancer DataBase (NCDB) (hospital-based).^{23,24} Comparable programs exist in Europe and have been similarly utilized to study epidemiology of sinonasal tumors, such as European Cancer Registry (EUROCARE) and Italian Network of Cancer Registries (AIRTUM).^{25–27} Despite these efforts, our understanding of the epidemiology of SNM continues to be limited by the lack of accurate, granular, disease-specific, and reliable cancer data in many countries.^{22,26,28}

Based on the SEER dataset epidemiologic studies, the estimated incidence of SNM in the United States is approximately 0.6–0.8 cases per 100,000 population per year during the 1973–2011 period.^{23,29,30} Globally, of the countries for which incidence data on sinonasal cancer were available, the average reported annual incidence was comparable, with 0.1–0.5 per 100,000 in males and 0.2–0.5 per 100,000 in females.²⁸ Incidence appears to be higher in Asia and Africa than in the United States and Europe, especially among Japanese men.^{31–34} Examination of gender demographics across continents revealed a predominance of male cases within every region.²⁶

Osteomas are the most common benign tumors of the sinonasal tract and are reportedly present on 1% of routine sinus radiographic studies.³⁵ Other fibrous tumors, such as fibrous dysplasia and ossifying fibroma, are also relatively common, with estimated incidence of 1 per 10,000 patients.¹⁹ Benign sinonasal papillomas, which make up to 4% of all sinonasal tumors, have a higher but relatively comparable estimated annual incidence to sinonasal malignancies of 0.7–2.3 per 100,000 patients.^{36,37} IPs, the most aggressive subtype of benign nasal papillomas, frequently present in the fifth and sixth decades of life and are more common in male subjects, with a 3 to 1 male to female ratio.³⁵ Vascular benign sinonasal tumors include JNA (estimated incidence of 1 per 150,000), lobular capillary hemangiomas, and sinonasal glomangiopericytomas.^{19,38} There are numerous

other rarer benign neoplasms and their epidemiology is under active investigation.¹⁷

Malignant sinonasal tumors appears to be more common among males across all populations and subsites, with age-normalized incidence rate ratio of males to females varying from 1.3 to 2.5.^{26,28–30} Multiple population-based studies for SNM have confirmed the increasing incidence with age, with mean at diagnosis of 62–66 years in men and 66–70 years in women, but the range varies widely.^{29,39} Within the US population, these tumors were most common in White individuals (80%–82%), followed by Black patients (9%).^{29,40} Understanding the racial and demographic differences in SNM is important because racial differences and age appear to be associated with the rates of nodal metastasis, as well as overall survival (OS) and disease-specific survival (DSS).^{41–43} Compared with White patients, Black patients and American Indian/Alaskan Natives exhibit increased mortality when controlling for other factors, and non-White patients were more likely to be diagnosed at a younger age in the United States. Race and ethnic background also appear to be associated with the patient's likelihood to receive surgical intervention when recommended.⁴⁴

Malignant epithelial neoplasms are the most frequent subtypes across all demographics and subsites, representing over 75% of all SNM. Sinonasal SCC represents the vast majority of cancers (reported range 33%–52%), followed by adenocarcinoma (13%–24%), ONB (6%–10%), and ACC (6%–17%).^{28,30,39,45} Until recently, most research has focused on SCC and adenocarcinoma. Rarer histological subtypes like SNUC, SNEC, and sarcomas subtypes are under active investigation. The estimated prevalence of these tumors is highly variable—assessed to be around 13% for sarcoma subtypes, 7%–9% for melanoma, 10% for lymphoma, and 3%–14% for SNUC.^{22,30,46–49} The majority of all SNM appear to localize to the nasal cavity (reported range 44%–46%), followed by maxillary sinus (29%–40%) and ethmoid cavity (5%–10%).^{29,30,39} With some variation, these trends by histology and anatomic location seem to be consistent across North and South America, Europe, and Asia.^{28,50}

Over the last 30–40 years, the overall global incidence of SNM has remained stable or showed incremental decrease.^{28,30,39} However, it does appear that there is variation based on histologic subtypes and region. For example, in the United States there was an observed modest but statistically significant decline in the overall incidence of SCC, but not overall or other SNM, between 1973 and 2009.³² During the same timeframe, many countries in Europe and Hong Kong reported a decrease in overall incidence.²⁸ One major epidemiologic study showed that, while the incidence of sinonasal SCC has decreased over time, the incidence of other cancers, including mucosal

sinonasal melanoma and ONB, has gradually increased between 1973 and 2006.³⁰ It is possible that the gradual increase in rarer histologies is associated with improved detection.³⁰

Mortality rates for SNM across all subtypes have also been decreasing over time in most of the countries for which reliable data were available, especially with the increased implementation of multimodal therapy.^{28,45,51–53} Decreased incidence and improved survival can be explained by several other factors, including the underlying pathophysiology and improved understanding for environmental contributors to disease development.^{39,54} Robust evidence for increased risk of SNM development exists with occupational exposure to formaldehyde, hydrocarbons, industrial textiles, construction (woodworking in particular), and nickel and chromium compounds, especially for adenocarcinoma.^{34,54–56} Cigarette smoking and tobacco use are also established risk factors for development of SNM, especially for SCC.^{57,58} Pooled analysis of the European studies showed an odds ratio (OR) of 1.7 (95% confidence interval [CI] 1.2–2.6) for current smokers developing SNSCC.⁵⁸ With smoking rates decreasing in many developed countries since the 1970s, it is plausible to presume that reduction in incidence of SCC may be attributed to decreased tobacco consumption.^{28,59} With sinonasal adenocarcinoma attributed to possible occupational hazards, public efforts to reduce environmental and occupational exposures in the Netherlands, for example, led to the overall reduction of adenocarcinoma incidence between 1973 and 2009.^{34,60}

The potential role of HPV in the development of sinonasal SCC is an area of active investigation. It is approximated that about 20%–30% of SNSCC are HPV associated, and HPV occurs only rarely in other sinonasal cancers.^{61,62} However, it does appear that HPV association may be associated with improved survival.^{61,63,64} Currently, only a minority of patients with SNSCC are tested for HPV, but testing is becoming more routine.⁶² Routine HPV testing in the future may improve our understanding of role of human papillomavirus in development of SNM and impact on survival.^{61,64,65} Increased efforts in cancer detection and surveillance, improved understanding of pathophysiology and treatment modalities, and further public health efforts may continue to reduce the incidence of sinonasal tumors and improve survival of these rare but aggressive malignancies.

V | GENERAL RISK FACTORS

Sinonasal tumors are relatively rare, but they have the second highest occupational attributable fraction (AF) of all types of cancer.⁶⁶ Predisposing factors include exposure to

wood dust, industrial carcinogens, leather, textiles, organic fibers, and heavy metals such as nickel and chromium. The role of alcohol and tobacco in sinonasal cancer is less than other head and neck malignancies.^{67,68}

A | Age

SNM is a condition affecting patients of any age (Table V.1). However, the majority are older, with two thirds being over 50 years of age at diagnosis (e.g., mucosal melanoma more often affecting the elderly).¹⁶ The incidence increases from 0.1 to 0.3 cases per 100,000 population in the first decade of life to 7 per 100,000 in the eighth decade.^{32,54,60}

Initial reports on ONB describe bimodal age distribution, while others reported a unimodal distribution.^{69–71} However, according to the latest nationwide population-based data analysis results on 876 patients, the incidence of ONBs is steadily rising with a peak in the fifth to sixth decades, suggesting a unimodal age distribution.⁷²

The United States showed the highest proportion of patients under 55 years of age with SNM diagnoses at over 30%, followed by Eastern Europe at around 27%. One factor that may explain the increased proportion of younger patients, particularly in Eastern Europe, is the greater prevalence of tobacco use among minors in this region.²⁶

B | Genetic sex

SNM is twice as common in males as females, where males (58.6%) outnumbered females at every anatomical site (Table V.2).¹⁶ This may be attributable to the etiological association with occupational exposure to wood and leather dust particles in male-dominated trades.²⁹ The exception is ACC, where female predominance is reported.^{30,73–79} It is hypothesized that ACC may be hormonally influenced, with studies showing significant estrogen receptor (ER) or progesterone receptor (PR) expression.^{30,74} In contrast, others noted the ER-beta subtype or PR expression alone.^{80,81}

C | Ethnicity

The prevalence is eightfold higher in Caucasians, who accounted for 70%–80% of cases and outnumbered all other races at every anatomical site.^{29,67,68} This trend appears to be similar in the pediatric population.⁸²

AF is a proportion of all cases in the population that can be attributed to exposure (e.g., AF for wood dust is 0.2 or 20%). Values of AF close to 1 (100%) indicate that both the relative risk is high and the risk factor is prevalent. In such

TABLE V.1 Evidence surrounding age as a risk factor for sinonasal malignancies.

Study	Year	LOE	Study design	Study groups	Clinical endpoints	Conclusion
Ferrari et al. ¹⁶	2022	4	Retrospective national database review	European centers database of SNM (MUSES, 1995–2021 <i>n</i> = 1360)	OS	Male-to-female ratio was 2.1 and average age was 61.2
Yin et al. ⁷²	2018	4	Retrospective national database review	ONB patients in NCDB 1973–2014 (<i>n</i> = 876)	1. OS 2. DSS	1. Median age was 54 years 2. Unimodal age distribution most frequently occurred in the fifth to sixth decades of life 3. Age >60 years was associated with poor OS
Unsal et al. ¹¹⁹	2017	4	Retrospective national database review	SNM patients in EUROCORE and SEER database 1990–2007 (<i>n</i> = 16,853)	1. OS 2. DSS	The United States showed the highest proportion of patients under the age of 55 at over 30%, followed by Eastern Europe at over 27%
Mensi et al. ⁵⁴	2013	4	Retrospective regional database review	SNM patients in Lombardy Region registry database 2008–2011 (<i>n</i> = 210)	1. OS 2. Occupational exposure profile	1. Median age was around 68 years in either gender 2. Age-specific rates had a peak over 60 years of age in both genders; however, rates began to increase at lower ages (25 years of age)
Ansa et al. ³²	2013	4	Retrospective national database review	SNM patients in SEER database 1973–2015 (<i>n</i> = 2553)	1. OS 2. DSS	1. 49.4% patients were 60–79 years old 2. 4.3% patients were <40 years old 3. 15.8% patients were ≥80 years old
Ow et al. ⁷¹	2013	4	Retrospective national database review	SNM patients in SEER database 1973–2015 (<i>n</i> = 328)	1. OS 2. DSS	Increased age was associated with poor survival
Kuijpers et al. ⁶⁰	2012	4	Retrospective national database review	SNM patients in Netherlands Cancer Registry (<i>n</i> = 3329)	1. OS 2. Occupational exposure profile	1. The median age of male SNM patients was 67 years 2. The median ages of SCC and adenocarcinoma were 68 and 65 years, respectively 3. The incidence in males rose sharply after the age of 45 years 4. Incidence in women rose steadily with age
Elkon et al. ⁷⁰	1979	4	Retrospective case series	ONB patients in single institution (<i>n</i> = 97)	1. OS 2. DSS 3. Margin status effect on OS	Increased age and distant metastasis were associated with decreased survival

Abbreviations: DSS, disease-specific survival; NCDB, National Cancer DataBase; ONB, olfactory neuroblastoma; OS, overall survival; SCC, squamous cell carcinoma; SEER, Surveillance, Epidemiology, and End Results; SNM, sinonasal malignancy.

cases, removing the risk factor will greatly reduce the number of incidents in the population. The values of AF close to 0 indicate that the relative risk is low or that the factor is not prevalent, or both. Removal of such elements from the population will have little effect.⁸³

D | Occupational exposure

Occupational exposures, including wood dust, metal, textile, and leather industries, have been attributed to tumorigenesis in around 40% of all SNM, 30% of sinonasal SCC,

TABLE V.2 Evidence surrounding gender as a risk factor for sinonasal malignancies.

Study	Year	LOE	Study design	Study groups	Clinical endpoints	Conclusion
Amit et al. ⁷⁵	2013	3	Systematic review of retrospective case series	520 ACC patients from 15 studies (1985–2011)	1. OS 2. DSS	Patients were aged 20–91 years (median 55 years) and included 44 males (44%)
Husain et al. ⁷³	2013	3	Systematic review of retrospective case series	366 ACC patients from 55 studies (1960–2012)	1. OS 2. DSS	ACC occurred more commonly in men than women (1.3:1)
Ferrari et al. ¹⁶	2022	4	Multicenter retrospective database review	European centers database of SNC (MUSES, <i>n</i> = 1360)	OS	Male-to-female ratio was 2.1 and average age was 61.2 (median: 64; IQR: 52–73)
Dutta et al. ²⁹	2015	4	Retrospective national database review	SEER database 1973–2011 (<i>n</i> = 13,295)	1. OS 2. DSS	Males comprised 58.6% of SNM cases
Marcinow et al. ⁷⁸	2014	4	Retrospective case series	SNACC patients at a single institution, 1992–2009 (<i>n</i> = 87)	1. OS 2. DSS 3. DFS	M:F ratio was 40:47
Sanghvi et al. ⁷⁴	2013	4	Retrospective national database review	SEER database 1973–2009 (<i>n</i> = 412)	1. OS 2. DSS	57.5% of 412 SNACC patients were female
Thompson et al. ⁷⁷	2013	4	Armed forces database review	AFIP database of ACC, 1970–1998 (<i>n</i> = 86)	1. OS 2. DSS	1. Cohort aged from 12 to 91 years (mean 54.4 years, median 58 years, mode 60 years) included 52% females 2. There was no significant difference in OS between the genders
Ellington et al. ⁷⁶	2011	4	Retrospective national database review	SEER database of ACC, 1973–2007 (<i>n</i> = 3026)	1. OS 2. DSS	Men and women represented 40.98% (<i>n</i> = 1240) and 59.02% (<i>n</i> = 1786) of the sample, respectively
Turner and Reh ³⁰	2011	4	Retrospective national database review	SEER database of SNM, 1973–2006 (<i>n</i> = 6739)	OS	M:F ratio was 1.8:1

Abbreviations: ACC, adenoid cystic carcinoma; DFS, disease-free survival; DSS, disease-specific survival; OS, overall survival; SEER, Surveillance, Epidemiology, and End Results; SNM, sinonasal malignancy.

and 90% of ITAC specifically (Tables V.3 and V.4).^{67,68} In contrast, wood dust exposure shows no significant association with non-ITAC tumorigenesis. It should be noted, however, that current disease rates may relate to distant past exposures. The mean latent period (time of first exposure to time of cancer incidence) has been estimated to be 43 years (range 27–69).³⁴ Following termination of exposure, the risk of SNM may persist for many years.³⁴

Professionals working with wood have up to 500–900 times and 20 times increased risk of developing ITAC and SCC, respectively, as compared with the general

population.⁸⁴ The AF of occupational exposure to wood dust was estimated at around 20% for both genders.^{58,85} The association was first recognized in the 1960s when a cluster of new nasal cancer cases among British woodworkers was observed.⁸⁶ The European Union has set an exposure limit for inhalable hardwood dust (5 mg/m³ as an 8-h time-weighted average). In male workers exposed to levels above the limit, the risk of ITAC increases 12-fold.⁵⁸ Data from Canada showed that 29% of woodworkers are exposed to levels above the limit.⁸⁷ Furthermore, the risk for ITAC doubles every 5 years of exposure

TABLE V.3 Evidence surrounding occupational exposure as a risk factor for sinonasal malignancies.

Study	Year	LOE	Study design	Study groups	Clinical endpoints	Conclusion
Binazzi et al. ⁵⁵	2015	2	Systematic review and meta-analysis	63 studies after 1985 with case-control or cohort design	RR for development of SNM	Exposure to wood dust, leather dust, or formaldehyde was associated with increased risk of SNM.
Bonzini et al. ⁸⁹	2013	3	Case-control	Single hospital case-control study of 65 SNM (ITAC and SCC)	1. OS 2. Occupational exposure profile	Occupational exposure was recognized for 39 out of 65 cases
Greiser et al. ⁹⁴	2012	3	Case-control	Bavaria registry (<i>n</i> = 2828 men only; 427 cases and 2401 controls)	1. OS 2. Occupational exposure profile	Increased risk of SNM in men after exposure to: - Nasal snuff - Smoking - Hardwood dust for ≥1 year
d'Errico et al. ⁸⁸	2009	3	Case-control	Multicenter cohort of ACC, Piedmont region (<i>n</i> = 449; 113 cases and 336 controls)	1. OS 2. Occupational exposure profile	1. The risk of ACC was increased with exposure to: - Wood dust - Leather dust - Organic solvents 2. The risk of SNSCC was increased with exposure to: - Welding fumes - Arsenic
't Mannetje et al. ⁵⁸	1999	3	Case-control	European multicenter cohort of SNM patients (<i>n</i> = 1854; 555 cases and 1705 controls)	1. OS 2. Occupational exposure profile	1. Increased risk of SNM in men after exposure to wood dust 2. Exposure to leather dust increased SNM risk in both genders
Comba et al. ⁸⁵	1992	3	Case-control	Multicenter cohort of SNM (<i>n</i> = 332; 78 cases and 254 controls)	1. OS 2. Occupational exposure profile	Significantly increased risks were associated (in males) with work in the wood and leather industries
Mofidi et al. ⁸⁷	2022	4	Retrospective national database review	Canadian national registry, SNM (2011, <i>n</i> = 245)	1. OS 2. Occupational exposure profile	4.6% (11 cases) and 4.4% (11 cases) were attributed to occupational exposure to wood dust, respectively
Rushton et al. ¹²⁰	2012	4	Retrospective national database review	National registry (<i>n</i> = 13,598 deaths, 164 ITAC)	1. OS 2. Occupational exposure profile	The overall AF was 32.7% (males 43.3%, females 19.8%) due to occupational exposures
Pippard and Acheson ¹²¹	1985	4	Retrospective national database review	NHS Central Register (<i>n</i> = 5017, 3434 dead)	1. OS 2. Occupational exposure profile	The anticipated excess of deaths from nasal cancer (10 observed, 1.87 expected) was found to be significant for workers in the finishing room (exposure: shoe manufacturing)
Acheson et al. ⁸⁶	1968	4	Retrospective case series	Regional registry review (<i>n</i> = 58)	Occupational exposure profile	Relative increase in incidence in High Wycombe woodworkers was 500-fold when compared to the general population

Abbreviations: ACC, adenoid cystic carcinoma; OS, overall survival; SEER, Surveillance, Epidemiology, and End Results; SNM, sinonasal malignancy.

TABLE V. 4 List of known occupational exposures surrounding sinonasal malignancies.

Agent	Occupation	AF	ITAC (RR)	SCC (RR)
Wood dust	Logging and sawmill workers; pulp and paper, and paperboard industry; woodworking trades (e.g., furniture industries, cabinet making, carpentry, and construction); used as a filler in plastic and linoleum production	20% ^{58,85}	29.43	1.46
Leather dust	Shoe manufacturers (scouring, roughing, buffing, spitting, skiving, cutting, trimming)	3%–13% ¹²⁰	35.26	2.09
Formaldehyde	Production; pathologists; medical laboratory technicians; plastics; textile industry	0.31% ¹²⁰	3.81	2.37
Mineral oils	Production; used as lubricant by metal workers, machinists, engineers, printing industry (ink formulation); used in cosmetic, medicinal, and pharmaceutical preparations	13.84% (total) ¹²⁰	3.50	0.85
Chromium	Chromate production plants dyes and pigments; plating and engraving; chromium ferro-alloy production; stainless-steel welding; in wood preservatives; leather tanning; water treatment; inks; photography; lithography; drilling muds; synthetic perfumes; pyrotechnics; corrosion resistance	5.7% ¹²⁰	0	66.3

Abbreviations: AF, attributable fraction; RR, relative risk.

period to wood dust and significantly increases for low-intensity exposure.⁸⁸ Efforts to limit exposure to wood dust and other potentially causal substances in the workplace appear to be impacting the incidence and mortality of SNM at the population level, with significantly decreasing rates evident over recent years, predominantly in developed countries.²⁸ Based on this evidence, in many European countries, ITAC is officially considered a professional disease.⁸⁹ Additionally, a significant dose–response relationship was found between adenocarcinoma risk and exposure period to leather dust: the risk increased among workers over 5 years' exposure by almost 60-fold as compared to those unexposed.⁵⁵

Similarly, an association between exposure to formaldehyde and SNM has been observed. Formaldehyde has wide use as an adhesive and binder for wood products, pulp and paper manufacture, the production of plastics and coatings, and textile finishing. High-formaldehyde-exposure occupations include textile operations and wood product manufacture/processing (with co-exposure to wood dust); short-term high-exposure episodes have been reported for embalmers, pathologists, and paper industry workers.⁹⁰

Apart from wood, leather dust, and formaldehyde, chemical substances such as glues, chrome, nickel, and various compounds used in the textile industry have been associated with sinonasal carcinomas, mainly SCC.

E | Smoking

Cigarette smoking and environmental tobacco smoke are established risk factors principally for SCC (Table V.5).^{58,91}

Evidence suggests that smoking tobacco has an increased risk for development of SCC with increasing number of pack-years up to twofold to threefold.^{92,93} The risk peaked at OR of 4.11 in exposure to 21.75 pack-years or more.⁹⁴ In smokers quitting within 15 years, there was an obvious decrease from OR 1.11 to OR 0.44 as compared to those who quit 28 or more years ago.⁹⁴

F | Link to viral infections

HPV types 16 and 18 have been associated with SCC, which is also discussed in Section XXI (Table V.6). HPV infection is more prevalent in nonkeratinizing (50%) than in keratinizing SCC (16%–19%).^{65,95} The role of HPV in SNM is still debated. Interestingly, a meta-analysis found that 39% of patients with IP tested positive for HPV, where malignant transformation occurs in 2%–27%.^{95–97} The association of EBV with NPC is also well-established and is covered in Section XXV.A.II.

G | Genetic and other inherited traits

Sinonasal SCC and ITAC have aneuploid genomes—harboring multiple genetic aberrations—that are distinct from each other and from histologically similar tumors (head and neck SCC and colorectal adenocarcinoma, respectively; Table V.7).⁹⁸ *TP53* is the most frequently mutated gene (40%–86%), while *APC*, *KRAS*, and *BRAF* mutations are less common.⁹⁹ Similarly, *TP53* mutation is detected up to 70% in SCC.^{100–102} In addition, several

TABLE V.5 Evidence surrounding smoking as a risk factor for sinonasal malignancies.

Study	Year	LOE	Study design	Study groups	Clinical endpoints	Conclusion
Greiser et al. ⁹⁴	2012	3	Case-control	Bavaria registry (<i>n</i> = 2828 men only; 427 cases and 2401 controls)	1. OS 2. Occupational exposure profile	1. Smoking increased SNM risk and peaked after 21.75 pack-years 2. Smokers who quit ≥ 28 years ago were at lower risk than those who quit < 15 years ago
Comba et al. ⁸⁵	1992	3	Case-control	Multicenter cohort of SNM (<i>n</i> = 332; 78 cases and 254 controls)	1. OS 2. Occupational exposure profile	Smoking significantly increased SNM risk in males
Brinton et al. ⁹²	1984	3	Case-control	Multicenter case-control series (160 SNM, 290 controls, 1970–180)	1. OS 2. Occupational exposure profile	Smoking tobacco increased the risk of SCC two- to threefold

Abbreviations: OS, overall survival; SNM, sinonasal malignancy.

TABLE V.6 Evidence surrounding viral infections as a risk factor for sinonasal malignancies.

Study	Year	LOE	Study design	Study groups	Clinical endpoints	Conclusion
Ferrelli et al. ⁹⁷	2022	2	Systematic review and meta-analysis	31 studies included 163 malignant and 961 nonmalignant IPs	Risk of malignancy	1. HPV infection increased the risk for IP malignancy 2. High-risk HPV types were associated with greater malignancy risk
Syrjänen and Syrjänen ⁹⁵	2013	2	Systematic review and meta-analysis	1956 sinonasal papillomas from 90 studies between 1950 and 2012	HPV status	38.8% cases tested HPV positive
Sahnane et al. ⁹⁶	2019	3	Retrospective cohort	Single center study on 54 patients (25 IPs, five oncocytic papillomas, and 35 SNSCC)	HPV status	High risk HPV was detected in 13% of IP-SCC and 8% de novo-SCC
Bishop et al. ⁶⁵	2013	4	Retrospective case series	Single center study on 161 SNM	HPV status	1. 21% SCC were positive for high-risk HPV DNA, including type 16 (82%), types 31/33 (12%), and type 18 (6%) 2. HPV was detected in nonkeratinizing SCC (34%), but none in keratinizing SCC group

Abbreviations: IP-SCC, inverted papilloma-associated squamous cell carcinoma; SCC, squamous cell carcinoma; SNM, sinonasal malignancy.

studies have demonstrated *EGFR* overexpression in about 40% of SCCs and in 20%–33% of ITACs, which is lower than that in histologically similar head and neck and colorectal cancers.^{103–105}

ACC is the most common salivary-type sinonasal tumor.¹⁰⁶ *ENI*, *DLX6*, and *OTX1* represent potential drivers and therapeutic targets for ACC.¹⁰⁷ *NOTCH1* mutations were identified in poorly differentiated ACC and associ-

ated with poorer prognosis, higher tendency to metastasize to liver and bone, and possible responsiveness to NOTCH1 inhibitors.¹⁰⁸ In addition, *EGFR* and *c-Kit* genetic abnormalities have been observed in sporadic cases.¹⁰⁹

Even though numerous studies report ONB cytogenetic and genomic alterations, common findings include the positive association of chromosome 11 deletion and chromosome 1p gain with poor ONB survival and *TP53* gene

TABLE V. 7 Evidence surrounding genetic and other inherited traits as risk factors for sinonasal malignancies.

Study	Year	LOE	Study design	Study groups	Clinical endpoints	Conclusion
Bell et al. ¹⁰⁷	2016	3	Case-control	42 ACCs and five controls	Mutation profile	The highly expressed developmental genes <i>ENI</i> , <i>DLX6</i> , and <i>OTXI</i> stand out as drivers for ACC
Takahashi et al. ¹⁰³	2014	3	Case-control	70 SNSCC specimens and 28 matched-pair controls	1. OS 2. DFS 3. Mutation profile	82.1% SCCs were <i>EGFR</i> positive and its expression was associated with significantly shorter DFS
Lechner et al. ¹¹¹	2021	4	Retrospective case series	404 ONB patients from multicenter database (12 institutions in the United States of America, the United Kingdom, and Europe)	1. OS 2. DFS 3. Mutation profile	82.4% of the cohort were positive for <i>SSTR2</i>
Colombino and Paliogiannis ¹²²	2019	4	Retrospective case series	Sinonasal mucosal melanoma patients with tissue available for 25-gene panel ($n = 25$)	1. Mutation profile 2. DNA damage 3. Genetic mutation correlation with high mitotic rate	1. <i>BRAF</i> (32%) was the most common mutation, followed by <i>KIT</i> and <i>RAS</i> 2. 28% had evidence of UV damage versus 90% in cutaneous melanoma 3. Nine out of 11 (82%) patients with high mitotic rate had pathologic mutation
Ferrarotto et al. ¹⁰⁸	2017	4	Retrospective case series	102 ACCs	1. Mutation profile 2. OS 3. RFS	<i>NOTCH1</i> mutations were identified in ACC and associated with higher likelihood of solid subtype, advanced-stage disease at diagnosis, higher rate of liver and bone metastasis, shorter RFS, and shorter OS when compared with <i>NOTCH1</i> wild-type tumors
Turri-Zanoni et al. ¹²³	2013	4	Retrospective case series	Sinonasal mucosal melanoma patients with tissue available for IHC, FISH, and DNA sequencing ($n = 32$)	1. OS 2. Mutation profile	1. <i>NRAS</i> (22%) and <i>KIT</i> (13%) were most common 2. Amplification of <i>RREB1</i> (100%) and loss of <i>MYB</i> (765) in many cases 3. <i>KIT</i> protein expression in 97% cases 4. <i>MAPK</i> and <i>PI3K/Akt</i> pathways were activated in all cases (100%) 5. No mutational profile was associated with OS difference
Zebary et al. ¹²⁴	2013	4	Retrospective case series	Sinonasal mucosal melanoma patients with tissue available for mutation screening ($n = 56$)	1. OS 2. Mutation profile	1. No difference in OS based on mutation 2. <i>NRAS</i> (14%) was most common mutation, followed by <i>BRAF</i> and <i>KIT</i> (4% each) 3. More likely to have mutation (<i>NRAS</i> , <i>KIT</i> , or <i>BRAF</i>) in paranasal sinus primary 4. Worse OS in paranasal sinus primary

(Continues)

TABLE V. 7 (Continued)

Study	Year	LOE	Study design	Study groups	Clinical endpoints	Conclusion
Bossi et al. ¹⁰²	2012	4	Retrospective case series	Single center database (<i>n</i> = 74)	1. OS 2. Mutation profile	<i>TP53</i> mutations were positive in 47% (surgery group) versus 39% (induction chemotherapy + surgery group)
Holmila et al. ¹⁰¹	2010	4	Retrospective case series	358 SNM were collected from three European national registries between 1989 and 2002 (Denmark, Finland, and France)	1. OS 2. Mutation profile	1. 77% adenocarcinomas were <i>TP53</i> mutation-positive 2. Wood exposure was associated with mutation positivity
Franchi et al. ¹⁰⁵	2008	4	Retrospective case series	Single hospital case series of 55 ITACs	1. OS 2. DFS 3. Mutation profile	1. 32.7% tumors (<i>n</i> = 18) were <i>EGFR</i> positive 2. <i>EGFR</i> overexpression was higher in patients working in the wood industry
Perrone et al. ¹⁰⁰	2003	4	Retrospective case series	<i>H-ras</i> mutations was investigated in 21 consecutive and untreated ITACs cases	Mutation profile	<i>TP53</i> mutations were present in 44% of ITAC cases

Abbreviations: ACC, adenoid cystic carcinoma; DFS, disease-free survival; FISH, fluorescence in situ hybridization; IHC, immunohistochemistry; ITAC, intestinal-type adenocarcinoma; ONB, olfactory neuroblastoma; OS, overall survival; RFS, recurrence-free survival; SCC, squamous cell carcinoma.

alterations that account for the tumor's most frequent mutations.¹¹⁰ ONB can express somatostatin receptor (SSTR), specifically SSTR-2 (82%) and SSTR-5 (7.5%). Since both show the highest affinity with somatostatin analogues, they can be used for diagnosis, especially in metastatic disease, using octreotide (¹¹¹In-pentetreotide) SPECT/CT and, more recently, Gallium-68 (⁶⁸Ga) PET/CT. Advantages are restricted time of image acquisition, better resolution, and lower radiation dose.^{99,111}

Classe et al. investigated ONB by looking at its molecular features and found two major subtypes: basal and neural subtypes.¹¹² Basal ONB had a high presence of a mutation in the *IDH2* gene. This *IDH2* mutation was also seen in other types of cancer, where it was found to lead to DNA hypermethylation and a failure of differentiation into the neuronal lineage.^{113,114} These findings provide insights into the molecular basis of ONB and suggest that the *IDH2* mutation could play a role in the development of ONB. The basal type is generally more aggressive and has a higher likelihood of distant disease.

The neural type ONB is characterized by distinct pathological, transcriptomic, proteomic, and immune features and shows genome-wide reprogramming with loss of DNA methylation at the enhancers of axonal guidance genes.¹¹² The prevalence of *IDH2* mutations, which have signifi-

cant implications for therapy with IDH inhibitors, is not as high in the neural ONB subtype compared to the basal subtype.¹¹⁵ It is generally considered to be a more benign type of ONB, with a better prognosis and a lower likelihood of spreading.¹¹²

One notable feature of sinonasal mucosal melanomas is their low tumor mutational burden, which refers to the number of genetic mutations present in the cancer cells. The well-known mutated genes involved in cutaneous melanoma tumorigenesis have only a marginal role in mucosal melanoma, reporting variable frequencies of mutations, as follows: 7%–30% in *NRAS*, 0%–25% in *c-KIT*, 8%–11% in *TERT*, 3%–10% in *BRAF* (only in one study, 36%), 7% in *SF3B1*, and *KRAS* mutations reported only in anecdotal cases.^{99,116,117} This low mutational burden has implications for treatment, as some of the newer immunotherapy treatments for cancer, such as checkpoint inhibitors, rely on the presence of certain genetic mutations to be effective.¹¹⁸ Given the low tumor mutational burden in mucosal melanomas, the role of checkpoint inhibitors in their treatment remains less defined. While some studies have shown promising results with the use of checkpoint inhibitors in this type of melanoma, further research is needed to fully understand the efficacy and optimal use of these treatments in this patient population.

Assessment of risk factors for sinonasal tumors

Aggregate grade of evidence	C for all risk factors <ul style="list-style-type: none"> Level 4: eight studies (age) Level 3: two studies; Level 4: seven studies (genetic sex) Level 2: one study; Level 3: five studies; Level 4: four studies (occupational exposure) Level 3: three studies (smoking) Level 2: two studies; Level 3: one study; Level 4: one study (link to viral infections) Level 3: two studies; Level 4: nine studies (genetic factors)
Benefit	Understanding and screening of risk factors for tumorigenesis provide prognostic information and opportunities for prevention.
Harm	Recall bias of risk factors, variable risk of tumorigenesis across different individuals and populations.
Cost	No studies assessing cost, but likely low costs of screening by history. Molecular testing may be costly.
Benefits-harm assessment	Preponderance of benefits over harms.
Value Judgments	Many risk factors are nonmodifiable. There is a need for further research into the role of molecular and genomic testing.
Policy level	Recommendation.
Intervention	Routine history taking and screening for risk factors such as age, sex, ethnicity, occupational exposure, and smoking may provide clinically useful prognostic information and prevention opportunities. Testing for genetic and viral etiologies may be considered, especially if there are actionable mutations.

VI | PRINCIPLES OF SURGICAL TREATMENT

The anatomic complexities of the sinonasal cavity, including its close proximity to important structures, notably the skull base and orbit, make surgical resection and clearance of cancer to negative margins particularly challenging. Traditionally, open craniofacial approaches with the goal of total en bloc resection were considered the standard of care.¹²⁵ However, advances in endoscopic sinus and anterior skull base surgery shifted this paradigm toward piecemeal or multibloc resection.¹²⁵

A | En Bloc versus debulking/piecemeal resection

Traditional surgical principles held that tumors should be resected en bloc to prevent tumor spillage into the surrounding environment (seeding) and thereby prevent local recurrence (Table VI.1).¹²⁶ In head and neck surgical oncology, the resection of sinonasal carcinoma, frayed with anatomic restrictions due to surrounding critical structures within tight confines, challenged this principle. In 1970, a novel trimodality protocol (surgery, RT, chemotherapy) was suggested, in which surgery involved debulking of tumors in the maxillary sinus rather than complete maxillectomy, as had previously been the standard of care.¹²⁷ Nineteen of the initial 57 patients treated with this protocol had residual tumor; however, all were successfully treated with subsequent partial maxillectomy or RT. Compared to the patients previously treated with the standard en bloc resection, the trimodality patients had lower rates of local recurrence and earlier return to function. This marked the beginning of a gradual acceptance of “tumor debulking” or “piecemeal” resection of sinonasal tumors as an acceptable alternative. Similar findings have since been reported in several other studies.^{128,129} In a recent series, survival was retrospectively compared in 27 patients with definitive en bloc resection to seven patients with debulking surgery (endoscopic endonasal approach [EEA], piecemeal resection) performed to minimize the radiation field.¹³⁰ The debulking group had lower OS and DFS, although this series is limited by selection bias. Patel et al. described the use of a microdebrider in a variety of anterior skull base malignancies including 14 SNMs.¹³¹ GTR or near-total resection was achieved in nearly 90%, but local recurrence and survival were not reported. Another study reviewed 41 patients treated with craniofacial resection (CFR) for SNM, where a majority of patients were noted to have T4 disease (81% and 42%, 37%, and 17% invading the orbit, meninges, and brain at presentation, respectively).¹³² They found that en bloc resection was significantly associated with improved recurrence-free survival (RFS) compared to piecemeal resection (78% vs. 45% at 10 years). But this difference was not significant on recursive partition analysis, suggesting confounding by tumor involvement of adjacent structures.

With the advent of EEA, approaches often necessitate piecemeal resection of at least part of the intranasal tumor to fully visualize the attachment site. Based on the historic principles of tumor spillage discussed above, some authors have argued that EEA is substandard treatment for aggressive skull base malignancies. Omura et al. report that seven

TABLE VI.1 Evidence surrounding en bloc versus debulking/piecemeal resection.

Study	Year	LOE	Study design	Study groups	Clinical endpoints	Conclusion
Sato et al. ¹²⁷	1970	3	Retrospective cohort	“Trimodality protocol” (<i>n</i> = 57; maxillary debridement, RT, and regional CT) versus en bloc resection with pre- or postoperative RT (<i>n</i> = 97)	Local recurrence	En bloc is not the only surgical technique with sound oncologic results in sinonasal tumor resection
Konig et al. ¹³²	2018	3	Retrospective cohort	41 patients with CFR for advanced SNM; en bloc versus piecemeal resection	Disease-free survival	En bloc resection was associated with improved DFS on univariate but not recursive partition analysis.
de Almeida et al. ¹³⁰	2014	3	Retrospective cohort	34 patients with EEA for sinonasal tumor (27 with definitive resection and seven with debulking)	1. DFS 2. OS	Debulking surgery was associated with lower survival
Patel et al. ¹³¹	2014	3	Retrospective case series	Anterior skull base lesions treated with EEA and resected with microdebrider (<i>n</i> = 32)	N/A	Gross and near total resection are feasible with piecemeal resection
Tosun et al. ¹³⁴	2014	3	Retrospective cohort	20 patients with EEA for SNM divided by resection type (en bloc vs. piecemeal)	Local recurrence	No local recurrence in patients who underwent achieved negative margins after piecemeal resection of the intranasal tumor and tumor base
Samant et al. ¹²⁹	2004	3	Retrospective cohort	19 patients with advanced SNM treated with preoperative CRT and “organ-preserving” surgical resection	OS	Organ-preserving surgery can be utilized even in advanced SNM
Knegt et al. ¹²⁸	2001	3	Retrospective cohort	70 patients with adenocarcinoma of the ethmoids treated with surgical debulking and topical CT	DFS	High DFS can be obtained with surgical debulking and adjuvant treatment.
Kilic et al. ¹³⁵	2017	4	Retrospective database (NCDB)	1483 patients with sinonasal SCC	1. Margin positivity 2. OS	No difference in margin positivity between open versus endoscopic approaches
Omura et al. ¹³³	2017	4	Retrospective case series	Eight patients with benign, unilateral sinonasal tumors endoscopically resected with wide transseptal exposure	Ability to achieve en bloc resection	En bloc resection may be possible for certain anatomically limited sinonasal tumors

Abbreviations: CRT, chemoradiation therapy; DFS, disease-free survival; EEA, endoscopic endonasal approach; NCDB, National Cancer DataBase; OS, overall survival; SCC, squamous cell carcinoma; SNM, sinonasal malignancy.

of eight sinonasal tumors were able to be resected en bloc using a contralateral transseptal approach, but it should be noted that all were benign unilateral pathologies.¹³³ In cases of extensive tumors where the attachment site cannot be readily visualized, piecemeal resection is often required. Tosun et al. divided 20 patients with SNM treated with EEA into four categories by type of resection: en bloc ($n = 5$), piecemeal resection of intranasal and en bloc resection of the tumor origin site ($n = 6$), piecemeal resection of both intranasal and tumor origin sites with curative intent ($n = 4$), and resection with palliative intent or removal with a positive margin ($n = 5$).¹³⁴ Local recurrence was observed only in the final group at mean follow-up of 4 years, suggesting that piecemeal resection does not lead to an increase in local recurrence. Perhaps the strongest evidence for the oncologic validity of the piecemeal resection method utilized by most surgeons during EEA is large reviews showing similarities in outcomes between open and endoscopic approaches to skull base malignancy. For example, there is a large review of 1483 patients using the NCDB, of which 24% underwent endoscopic resection of sinonasal SCC.¹³⁵ Following propensity score matching, there was no significant difference in margin status or OS by surgical approach. However, large series, which mainly consist of database studies at the present, are limited in making conclusions about resection method, particularly for the vastly different pathologies that affect the sinonasal tract.

En bloc versus debulking/piecemeal resection

Aggregate grade of evidence	C (Level 3: seven studies; Level 4: two studies)
Benefit	Piecemeal resection has the benefit of improved visualization of the tumor attachment site and determining invasion into surrounding structures. En bloc resection, whenever possible, permits gross visualization of clear margins around the resection
Harm	Piecemeal resection has the theoretical risk of tumor seeding in the cavity via violation of the tumor capsule. En bloc resection is potentially invasive and disfiguring.
Cost	Cost comparison analyses have not been undertaken.
Benefits-harm assessment	Balance of benefits and harms.

(Continued)

Value judgments	No studies have demonstrated a clear benefit of either en bloc or piecemeal resection. Since no study has found worse outcomes for piecemeal resection and improved visualization is accomplished with piecemeal resection in EEA, it is reasonable to resect sinonasal tumors in a piecemeal fashion when necessary for tumor visualization.
Policy level	Option.
Intervention	Use of en bloc versus piecemeal resection is an option based on tumor extension and sites of involvement. The decision on whether to proceed with en bloc versus piecemeal resection of sinonasal tumors should be made on a case-by-case basis. En bloc resection of the site of attachment/tumor origin should be attempted whenever possible.

B | Treatment of sites of attachment

Identifying the attachment site for the treatment of a sinonasal neoplasm was first described for the surgical resection of sinonasal IP, where even advanced and large lesions were often found to have relatively small attachment sites.¹³⁶ Initial identification of these attachment sites allows for more accurate clearance of disease with successful oncologic outcomes while minimizing morbidity by sparing uninvolved structures (Table VI.2).^{136,137} Pedicle-oriented surgery was also found to have shorter operating times and facilitates observation and follow-up aimed at the pedicle attachment site.¹³⁷ Furthermore, the use of intraoperative frozen sections to obtain evidence of clear margins at attachment sites was found to significantly reduce rates of recurrence in IP and can likely be inferred for other sinonasal lesions.¹³⁸

Castelnuovo et al. describe a multilayer centripetal technique to approach the resection of sinonasal malignant tumors with successful oncologic results.¹³⁹ Most endoscopic resections for sinonasal lesions begin with tumor debulking in order to identify the tumor attachment sites and any areas of potential tumor involvement or invasion. During this initial stage, it is important to preserve the surrounding normal anatomic structures if possible for orientation and to minimize the necessary margin sections to follow. The tumor is then removed starting from the periphery of the tumor attachment site along with a wide margin and working circumferentially toward the center. Complete resection of all tumor attachment sites is crucial for an adequate oncologic resection. Although the tumor capsule is violated during this process, the

TABLE VI. 2 Evidence surrounding treatment of sites of attachment.

Study	Year	LOE	Study design	Study groups	Clinical endpoints	Conclusion
Trent et al. ¹³⁸	2022	2	Systematic review	Patients with IP treated with attachment-site-oriented surgery	1. Anatomic attachment sites and techniques 2. Recurrent rates	1. Most common technique to address attachment involved resecting mucosa and drilling tumor base 2. Use of intraoperative frozen sections is associated with decreased recurrence
Goudakos et al. ¹⁴²	2018	2	Systematic review of LOE four studies	2451 patients with resection of IP (1526 endoscopic, 925 open)	Recurrence rate	Recurrence was higher in the open approach group
Landsberg et al. ¹³⁶	2021	3	Prospective cohort	Patients undergoing endoscopic IP excision via attachment-oriented approach (<i>n</i> = 33)	1. Attachment diameter 2. Attachment location 3. Persistent/recurrent disease	1. IPs typically have small attachment sites 2. Identification of attachment sites facilitates efficacious resection with minimal morbidity
Nakamaru et al. ¹⁴⁰	2021	4	Retrospective case series	SNSCC patients (<i>n</i> = 15) undergoing endoscopic surgery without an open approach	1. OS 2. DSS 3. LRC	Endoscopic surgery alone was effective in select cases of SNSCC with adequate visualization of tumor attachment site
Pagella et al. ¹³⁷	2014	4	Retrospective case series	1. IP patients undergoing standard ESS (<i>n</i> = 37) 2. IP patients undergoing pedicle-oriented endoscopic surgery (<i>n</i> = 36)	1. Recurrence rates 2. Operative times 3. Postoperative complications	Pedicle-oriented endoscopic surgery offers adequate control of disease with shorter operating times, avoids unnecessary surgery, and facilitates follow-up aimed at pedicle attachment
Castelnuovo et al. ¹³⁹	2006	4	Retrospective case series	Patient with treated malignant sinonasal carcinoma (<i>n</i> = 67)	2-year OS rate	2-year OS rate higher than 80% in all histologic types of tumors except for melanomas
Homma et al. ¹⁴¹	2021	5	Literature review	Patients with IP and sinonasal carcinoma undergoing endoscopic and open treatment	1. Recurrence rates 2. Survival times 3. Margin status	Indications for the endoscopic approach to sinonasal carcinomas has been expanding and can be effective in select cases

Abbreviations: DSS, disease-specific survival; ESS, endoscopic sinus surgery; IP, inverted papilloma; LRC, locoregional control; OS, overall survival; SNSCC, sinonasal squamous cell carcinoma; SNM, sinonasal malignancy.

normal tissue planes of the tumor are not affected since the tumor sits in an air-filled cavity. Once the visible tumor is resected, an additional layer of tissue, deep to the involved attachment site, should be resected. For example, mucosal lesions should have the underlying bone or cartilage resected, and tumors abutting the orbit may require resection of the lamina papyracea and periorbita. Extensive frozen margin sections should be performed systematically to ensure clearance of disease, especially along

the previously identified attachment sites. Resection is continued until negative margins are obtained. Nakamaru et al. similarly describe an attachment-oriented approach for sinonasal SCC. As this tumor is more aggressive than IP, wider surgical margins should be obtained and additional frozen sections utilized prior to resecting the mucosa surrounding the tumor.^{140,141} If negative margins are not possible through an endoscopic and attachment-oriented approach, conversion to an open approach should be

considered if that would facilitate the clearance of tumor (i.e., negative margins).

Treatment of sites of attachment

Aggregate grade of evidence	C (Level 2: two studies; Level 3: one study; Level 4: three studies; Level 5: one study)
Benefit	Attachment-oriented surgery allows for accurate clearance of disease with successful oncologic outcomes while sparing uninvolved structures. Minimizing morbidity is an especially important consideration in benign sinonasal tumors. Additionally, this technique may allow for shorter operating times and facilitates observation and follow-up aimed at the pedicle attachment site.
Harm	Not all tumors are amenable to attachment-oriented surgery and the decision must be done on a case-by-case basis. It is highly surgeon dependent to accurately assess the sites of involvement or attachment. If negative margins are unable to be achieved, an open or combined approach may be necessary, especially in cases of malignant or aggressive pathologies.
Cost	Cost comparison analyses have not been undertaken.
Benefits-harm assessment	Preponderance of benefits over harms.
Value judgments	Attachment-oriented surgery is beneficial to the treatment of benign as well as malignant sinonasal tumors in select cases where adequate surgical margins can be obtained safely. In cases of locally advanced lesions, utilizing an attachment-oriented technique must be balanced with the risk of leaving residual disease or needing to convert to an open or combined approach.
Policy level	Recommendation.
Intervention	Endoscopic attachment-oriented surgery should be considered to minimize morbidity when feasible and when negative margins can likely be achieved. In cases of locally advanced disease, an open or combined approach may be necessary for disease clearance.

C | Differences between benign and malignant pathologies

In general, the principles of oncologic resection apply to both malignant and benign lesions. In benign lesions,

the need for complete surgical resection should be balanced with functionality and cosmesis. While no studies have directly compared surgical oncological principles between benign and malignant sinonasal neoplasms, expert opinion and standard modern practice favor endoscopic approaches for benign lesions whenever possible. Regarding oncologic outcomes, Goudakos et al. performed a systematic review to compare open and endoscopic resection of IP between 1974 and 2016.¹⁴⁰ Recurrence rates were significantly lower in the endoscopic resection group compared to the open resection group (14.9% vs. 18.8%). While this study did not control for disease location or extent, it is likely that endoscopic resection is at least as effective as open approaches at achieving local control. Additionally, in the years since this study was published, cumulative experience with endoscopic resection has exponentially grown, suggesting that recurrence rates following endoscopic resection have likely improved.¹⁴²

Namely, complete surgical extirpation offers the patient the best chance of cure and is always the desired outcome. This is particularly true in the case of IP, where there is a small risk of progression to malignancy. However, in the setting of purely benign disease, complete oncologic resection with the removal of excess normal surrounding tissue should be balanced with the preservation of aesthetics and function. An additional consideration is the risk of tumor seeding to surrounding cavities. Furthermore, resection of the dura or periorbita theoretically removes a natural barrier to spread, and recurrence due to seeding in the brain or orbit could necessitate a much more aggressive surgery for a benign process. For these reasons, EEA is recommended for benign tumors unless there is gross involvement of the premaxillary soft tissue or skin or surgically inaccessible territories of the paranasal sinuses.

D | Risk of tumor seeding

Tumor resection carries the theoretical risk of tumor seeding in any site in the body if microscopic (or even macroscopic) fragments are left behind and unrecognized (Table VI.3). Tumor seeding has been reported following both open and endoscopic resection of sinonasal tumors. Nguyen et al. conducted a systematic review of recurrence attributed to tumor seeding of all skull base lesions.¹⁴³ Of the 69 reported cases, three (4%) were sinonasal tumors. One was an individual case report and one was a retrospective cohort study.¹⁴⁴ Pathologies were SCC ($n = 2$) and ACC ($n = 1$). All three recurrences occurred following open approaches. In their review of 70 patients with SNM, Moore et al. found two (3%) of recurrences attributed to seeding. One occurred at the transfacial incision after excision of a maxillary sinus tumor and the other along the

TABLE VI.3 Evidence surrounding risk of tumor seeding.

Study	Year	LOE	Study design	Study groups	Clinical endpoints	Conclusion
Nguyen et al. ¹⁴³	2018	2	Systematic review	69 patients with recurrent skull base lesions attributed to seeding	Recurrence attributed to seeding	Tumor recurrence attributed to seeding in endonasal approaches is rarely reported
Yu et al. ¹⁴⁶	2018	3	Retrospective cohort	38 ONB patients	1. Dural recurrence 2. Local recurrence	Dural recurrence can occur in the absence of local recurrence
Moore et al. ¹⁴⁴	2011	3	Retrospective cohort	70 patients with locally advanced SNM	Recurrence attributed to seeding	Tumor recurrence attributed to seeding is rare
Miller et al. ¹⁴⁵	2006	5	Case report	One patient with ACC treated with maxillectomy and RT	Recurrence at the tracheostoma	Distant recurrence following resection may be attributed to locoregional seeding intraoperatively

Abbreviations: ACC, adenoid cystic carcinoma; ONB, olfactory neuroblastoma; RT, radiation therapy; SNM, sinonasal malignancy.

dura at the site of a craniotomy. Both died due to disease, one secondary to the local recurrence and the other secondary to distant metastasis. Miller et al. reported an atypical site for recurrence of ACC of the maxillary sinus: at the tracheostoma following a transfacial approach.¹⁴⁵ Yu et al. reviewed a series of 20 ONB patients to identify patterns of recurrence. Recurrence was most common at the dura (65%).¹⁴⁶ There were six cases where isolated dural recurrence occurred in the absence of local recurrence, leading the authors to suggest that the dura was seeded with tumor intraoperatively. In their series, surgical approach was not significantly associated with DFS. Taken together, tumor seeding following resection of sinonasal tumors appears to be a rare event as the literature is limited to small case series. While these reports appear to have a preponderance toward open resection, the small sample size and lack of a true comparator group do not allow any conclusions to be made about risk with certain surgical approaches.

Risk of tumor seeding

Aggregate grade of evidence	C (Level 2: one study; Level 3: two studies; Level 5: one study)
Benefit	Careful dissection technique and close inspection can minimize risk of tumor seeding.
Harm	Spread of tumor via seeding presents a significant challenge in management often requiring aggressive surgery and/or adjuvant treatment of a separate site.

(Continued)

Cost	Cost comparison analyses have not been undertaken.
Benefits–harm assessment	Balance of benefits and harms.
Value judgments	Since reports are limited to case series, there is no evidence to suggest that tumor seeding is impacted by surgical approach. Piecemeal resection could theoretically have a higher risk of tumor seeding due to tumor capsule violation, while open surgery may expose uninvolved soft tissues to tumor.
Policy level	Option.
Intervention	Consideration of approach and technique based on tumor seeding is an option. There is no evidence that an open or endoscopic approach to sinonasal tumors carries a higher risk of tumor seeding. Given the lack of case reports, either approach appears to have a low risk of tumor seeding. Upfront recognition and prevention are key to minimize this risk.

VII | BIOPSY

The necessity of histopathological tissue diagnosis in the management of sinonasal lesions is well established.^{147–149} Tissue diagnosis is required to identify appropriate treatment options for patients with sinonasal tumors. Incorrect or delayed diagnoses adversely affect patient outcomes and survival, highlighting the need for accurate and timely diagnosis.^{150–152} Previously, tissue diagnosis often required an operative setting. As rigid endoscopy with high-quality

cameras and monitors becomes increasingly available in office settings, the ability to perform in-office sinonasal procedures has grown rapidly, including tumor biopsies. Strict adherence to operative biopsies is commonly regarded as unnecessary. In this section, the role of in-office biopsies, indications, and technical considerations will be reviewed, as well as the order of sinonasal imaging and biopsy.

A | Role of in-office biopsies for sinonasal lesions

In-office biopsies provide opportunities to avoid the risks associated with general anesthesia, as well as the convenience of performing a biopsy in the office with increased flexibility and accessibility versus the operating room. However, in-office biopsies may be limited by vascularity and accessibility of the lesion, and the close proximity to nearby critical structures. Much of the available literature discussing the role of in-office biopsies for sinonasal lesions is based on expert opinion. There have been six retrospective chart reviews on this topic. Five of these studies conclude in-office biopsies may be a useful alternative to surgical biopsies, with one study recommending against in-office biopsies (Table VII.1). Three studies commented on the safety of in-office biopsies, with no major complications reported. Lee reviewed 121 patients with unilateral sinus disease, including 35 patients with large polypoid or mass lesion who underwent in-office punch biopsy. The results of the in-office biopsies were congruent in 33 of 35 cases (94.3%). The two cases with inaccurate in-office biopsies were a lymphoma and an IP with malignant change.¹⁵² Han et al. reviewed 521 patients who underwent in-office biopsies, which were then compared to surgical pathology reports. A total of 302 patients had nonneoplastic lesions, 159 had benign neoplastic lesions, and 60 had malignant sinonasal lesions. They did report 33 false negatives for malignancy, with the majority of the false negatives being reported as nonneoplastic lesions. In their review, they did not identify any complications (i.e., bleeding).¹⁵³

Tabaee et al. reviewed 61 patients, with a total of 69 in-office biopsies. They reported two patients had experienced mild, self-limited epistaxis postbiopsy and five patients (7%) had nondiagnostic biopsies. No major complications were seen. Twenty-five patients ultimately underwent surgery, and histopathologic agreement with in-office biopsy results was present in 82% of cases. Four of the incongruent cases involved biopsies that initially reported inflammatory change, but were upgraded to malignant or benign neoplasms following surgery.¹⁵⁴ Segal et al. reviewed 46 patients who underwent in-office biopsies for unilateral sinonasal lesions. Surgical pathology

was consistent with in-office biopsies in 86.8% of cases, with three of the inconsistent cases being upgraded from benign inflammation to a benign or malignant lesion. No complications were reported.¹⁵⁵ Gomes et al. reviewed 150 patients who underwent punch biopsies of sinonasal lesions, reporting a high correlation with surgical pathology (correlation coefficient 0.883, $p < 0.001$).¹⁵⁶

In contrast, Paz Silva et al. presented their 15-year experience with unilateral sinonasal disease ($n = 191$), reporting that only two in-office biopsies were performed over this time period. The results of the biopsies did not change the clinical management in either case (IP and adenocarcinoma). They recommended against the use of in-office biopsies for unilateral sinonasal lesions, arguing that the biopsies do not change clinical management, must be confirmed by surgical biopsies, and incur additional unnecessary cost to the healthcare system.¹⁵⁷

In summary, in-office biopsies in patients with sinonasal lesions appear to be a safe alternative to operative biopsies in appropriately selected patients. There is a moderate risk of a false-negative diagnosis. One potential explanation for the false-negative results may relate to the tendency of sinonasal lesions to develop overlying polypoid edema, which may mask the underlying lesion.¹⁵⁵ A high degree of clinical suspicion may help clinicians identify cases of inaccurate diagnosis and prompt a surgical biopsy.

Aggregate grade of evidence: C (Level 3: five studies; Level 4: one study) for diagnostic role of in-office biopsy and C (Level 3: three studies) for safety of in-office biopsy

B | Indications

There are no studies specifically discussing the indications for in-office biopsy in sinonasal lesions. However, some criteria can be summarized from the studies presented above. Lesions should be easily visualized with a nasal speculum or endoscope within the nasal cavity, or accessible sinuses.^{153,154} Lesions that are suspected to be vascular or in continuity with the intracranial space (i.e., encephaloceles) are considered to be contraindicated for in-office biopsies.^{153,155} Unilateral vascular sinonasal lesions in adolescent and young adult males should be treated with particular caution, given the specific risk of JNA, which would be contraindicated due to risk of severe hemorrhage. Deep-seated lesions within the sinonasal cavity (i.e., beyond the middle turbinate) and submucosal lesions may be more technically challenging, or pose an increased risk of bleeding and were not included in the studies presented.^{152–155} Patient selection may be as important as the anatomical considerations. For example, patients on antiplatelet or anticoagulation therapy or those who are highly anxious or pain intolerant are not the ideal

TABLE VII.1 Evidence surrounding in-office biopsies for sinonasal lesions.

Study	Year	LOE	Study design	Study groups	Clinical endpoints	Conclusion
Gomes et al. ¹⁵⁵	2020	3	Retrospective cohort	85 patients underwent in-office punch biopsy followed by surgery	Diagnosis of USD	In-office biopsy has a high correlation with final surgical pathology
Segal et al. ¹⁵⁶	2014	3	Retrospective cohort	46 patients with USD underwent in-office biopsies, followed by surgery	Diagnosis of USD	1. In-office biopsy is an accurate and safe method of diagnosis 2. No complication of in-office biopsy
Tabaee et al. ¹⁵⁴	2011	3	Retrospective cohort	61 patients underwent in-office biopsy, 25 patients then underwent surgery	Diagnosis of USD	1. In-office biopsy is a safe diagnostic tool 2. In-office biopsy may provide diagnostic information, but may be limited by accuracy
Han et al. ¹⁵³	2010	3	Retrospective cohort	521 patients underwent in-office biopsy, followed by surgery	Diagnosis of USD	1. In-office biopsy is safe 2. In-office biopsy is accurate for benign lesions, with limited sensitivity (43.7%) for malignancy
Lee ¹⁵²	2008	3	Retrospective cohort	35 patients with USD underwent in-office biopsy, followed by surgery	Diagnosis of USD	In-office biopsy is highly accurate for histopathological diagnosis
Par Silva et al. ¹⁵⁷	2015	4	Retrospective cohort	191 patients with USD Two patients underwent in-office biopsies, followed by surgery	Diagnosis of USD	1. In-office biopsies were not recommended 2. In-office biopsy may incur additional health care costs

Abbreviation: USD, unilateral sinus disease.

candidates for in-office biopsies. Thoughtful patient selection and shared decision-making may help clinicians identify appropriate candidates for in-office sinonasal biopsies.

Aggregate grade of evidence: D (Level 5: expert opinion, reasoning from first principles)

C | Technical considerations

Some of the above studies also report their biopsy techniques, which are summarized below.^{152–155} Prior to considering an in-office biopsy, complete history, nasal endoscopy, and review of available sinonasal imaging should be performed.^{152–155} If an in-office biopsy is pursued, patient vital signs should be assessed prior to, during, and following the procedure. Equipment setup should include the necessary instruments and materials to manage postbiopsy bleeding that could be severe. After informed consent is obtained from the patient, topical anesthetics and decongestants can be atomized into

the nose and/or applied on soaked neuropledgets, and local anesthetic may be injected into the biopsy site under direct or endoscopic visualization. If the vascularity of the lesion is a concern, the severity of the bleeding caused by the needle at the injection site may give clinicians an indication of the bleeding risk. Significant bleeding following the injection may indicate a highly vascular lesion and may deter in-office biopsy. For the biopsy, through-cutting instruments were used by several of the study authors, citing a potential risk of increased bleeding and injury to the surrounding tissue with excessive tissue manipulation. The biopsy site may then be cauterized or packed with absorbable material. If significant bleeding is encountered, nonabsorbable packing material may be required. Clinicians may consider sending both fresh tissue (approximately 1 cm³ for flow cytometry and IHC to evaluate for lymphoma) and formalin-fixed tissue.

Aggregate grade of evidence: D (Level 5: expert opinion, reasoning from first principles)

D | Order of imaging and biopsy

Given the proximity of the sinonasal cavity to the orbit and the intracranial space, it is important to evaluate sinonasal lesions for potential invasions into these adjacent spaces. This is usually done with a combination of CT and MRI, which are superior for evaluating bony anatomy and soft tissue, respectively. The details of imaging for sinonasal tumors will be discussed in Section IX. When considering biopsy for sinonasal tumors, classic teaching describes obtaining both a CT and MRI prior to considering a biopsy. No specific studies have examined the necessity of CT and MRI prior to a sinonasal biopsy. This approach is based on expert opinion, with the goal of avoiding potential consequences of performing a biopsy on an ill-defined sinonasal lesion and causing intracranial, intraorbital, or bleeding complications.

There may be cases where a biopsy could be considered prior to bimodal imaging, to avoid delays in diagnosis and treatment initiation. The goal of imaging prior to tissue sampling is to allow the clinician to evaluate the barriers of the nasal cavity and the extent of the lesion. When this is possible without imaging, it may be appropriate to consider a biopsy prior to bimodal imaging. Sinonasal lesions located inferiorly in the nasal cavity, with clear separation from the entire skull base and orbit, may not necessitate imaging prior to biopsy. Similarly, lesions that can be completely visualized with endoscopy and have an identifiable and accessible attachment site may not require imaging prior to biopsy. Clinicians should also consider whether a biopsy obtained prior to imaging may impact the subsequent imaging and radiologic interpretation. For example, packing or cautery within the sinonasal cavity as well as an inflammatory reaction from the biopsy can complicate the interpretation of sinonasal imaging. Clinicians should include these considerations in their assessment of the appropriateness of a preimaging biopsy. These considerations are based on expert opinion only, and clinicians should be cautious when considering a biopsy prior to complete imaging to avoid potential complications and patient harm.

Aggregate grade of evidence: D (Level 5: expert opinion, reasoning from first principles)

VIII | RESECTABILITY

A | Resectability of sinonasal tumors

In the context of treatment planning, the term *resectable* refers to the ability to surgically extirpate tumor in an oncologically acceptable manner, while avoiding significant morbidity, deterioration of QOL, or mortality. Tumors

are generally considered unresectable if their location or involvement of critical structures prevents the surgeon from achieving GTR with negative surgical margins. A critical evaluation of resectability is frequently necessary in SNM due to their characteristically late stage of presentation and proximity of sinonasal subsites to critical neurovascular structures (e.g., carotid artery, cavernous sinus) as well as orbital and intracranial contents (e.g., dura, brain parenchyma). The American Joint Committee on Cancer (AJCC) staging guidelines attempt to delineate locally advanced tumors as resectable (T4a) or unresectable (T4b).¹⁵⁸ Tumors arising from the nasal cavity, maxillary sinus, or ethmoid sinus are staged T4b if they involve the orbital apex, dura, brain parenchyma, middle cranial fossa, cranial nerves other than V2, nasopharynx, or clivus. As an oncological principle, surgical extirpation is rarely considered acceptable in the presence of known distant metastases, unless the pathology tends toward indolent behavior (e.g., ACC) and there is potential for significant local morbidity (e.g., pain, fungating wound, threat to vision).

In a review of the NCDB for SNM, Robin et al. found that increasing T stage was inversely correlated with the likelihood of achieving GTR with negative margins. The odds ratio for obtaining negative margins in T4-staged tumors is 0.189, compared to 0.824 in T2-staged tumors, though this was partially mitigated by the use of neoadjuvant CRT (OR 2.641).¹⁵⁹ Furthermore, studies of large SNM cohorts demonstrate that a negative margin resection is an independent predictor of OS, DSS, and rates of local recurrence compared to those with positive surgical margins remaining.¹⁶⁰ When stratifying positive margins as either microscopically positive or macroscopically positive (grossly visible at the resection margins), Jafari et al. found a sequential deterioration in median OS for negative margins, micro-positive margins, macro-positive margins, and nonsurgical therapy (90.5, 56.7, 38.4, and 36.4 months, respectively).¹⁶¹ For these reasons, current National Comprehensive Cancer Network (NCCN) guidelines recommend RT (with or without concurrent systemic therapy) or IC for unresectable tumors for patients with performance status 0–1.¹⁶²

Despite this guidance, there is disagreement regarding the absolute contraindications to resection of sinonasal tumors due to substantial variability in surgeon experience, institutional preference, and the emergence of EEAs, which allow for higher resolution visualization and decreased postoperative morbidity. The evolution of endonasal surgery also leads to heterogeneity in study designs that tend to incorporate open, endoscopic, and combined approaches. Randomized clinical trials or robust prospective studies specifically evaluating surgery as the primary modality of treating classically unresectable

TABLE VIII.1 Evidence surrounding resectability of sinonasal tumors.

Author	Year	LOE	Study design	Study groups	Clinical endpoints	Conclusion
Jafari et al. ¹⁶¹	2019	4	Retrospective database (NCDB)	7808 patients with sinonasal SCC	OS	<ol style="list-style-type: none"> Degree of tumor extirpation correlates with OS Macro-PSM did not improve OS compared to nonsurgical therapy
Cracchiolo et al. ¹⁶⁰	2018	4	Retrospective database (NCDB)	4770 patients with sinonasal SCC	OS	<ol style="list-style-type: none"> NSM were associated with improved OS compared to micro- and macro-PSM T4a and T4b tumors benefited from adjuvant RT Advanced T-stage predicted nonsurgical therapy
Robin et al. ¹⁵⁹	2017	4	Retrospective database (NCDB)	11,160 patients with SNM	OS	<ol style="list-style-type: none"> Adjuvant RT, CRT, and neoadjuvant therapy improved OS compared to surgery alone Neoadjuvant CRT improved the likelihood of NSM Nonsurgical therapy portended worse OS
de Almeida et al. ¹³⁰	2015	4	Retrospective case series	34 patients with sinonasal SCC treated with EEA	<ol style="list-style-type: none"> DFS OS 	PSM predicted worse OS and DSS
Mine et al. ¹⁸⁵	2011	4	Retrospective case series	32 patients with SNM	<ol style="list-style-type: none"> DFS OS LRC 	PSM portended worse DFS, OS, and LRC

Abbreviations: DFS, disease-free survival; LRC, locoregional control; NCDB, National Cancer DataBase; NSM, negative surgical margin; OS, overall survival; PSM, positive surgical margin; SCC, squamous cell carcinoma.

advanced SNM were not encountered in this systematic review (Table VIII.1). Therefore, select studies of smaller patient series, studies of nonsinonasal tumor locations, or those evaluating salvage surgeries have been included to illustrate the clinical parameters of resectability.

Aggregate grade of evidence: C (Level 4: three studies)

B | Orbital apex involvement

Sinonasal tumors that infiltrate the orbital apex surround critical neurovascular structures transcending corridors to the intracranial cavity and cavernous sinus, making negative margin resection unfeasible. Studies have shown that orbital invasion, particularly, orbital apex involvement, is independently associated with decreased OS compared to invasion of the anterior two thirds of the orbital compartment.^{163–165} In 2015, Sugawara et al. reported their results of 15 patients with recurrent SNM with orbital apex involvement that underwent salvage surgery via extended orbital exenteration. The described technique included an anterior CFR with orbital exenteration followed by middle

fossa exploration and resection of orbital apex and sphenoid disease to achieve negative margins.¹⁶⁶ They noted an OS of 86% at a mean follow-up of 3 years in this limited sample with short follow-up. A retrospective review of 163 patients with sinonasal cancers with orbital invasion found that, even when employing both histologically appropriate neoadjuvant chemotherapy and extended orbital exenteration, those with orbital apex involvement still exhibited 5-year OS of 14.6% ± 7.5%, DSS of 0%, and 10-year OS of 0%.¹⁶⁵ With the dismal prognosis of tumors involving the orbital apex, nonsurgical multimodality therapy is preferred given the low likelihood of obtaining negative margins with orbital exenteration, even with extended intracranial dissection, as it does not appear to change survival (Table VIII.2).

Aggregate grade of evidence: C (Level 4: three studies)

C | Carotid artery involvement

Tumors abutting or encasing the internal carotid artery (ICA) exhibit an overall poor prognosis and carry

TABLE VIII.2 Evidence surrounding resectability of tumors involving the orbital apex.

Author	Year	LOE	Study design	Study groups	Clinical endpoints	Conclusion
Li et al. ¹⁶⁴	2020	4	Retrospective case series	88 patients with T4 sinonasal SCC who underwent RT ± surgery	Survival outcomes	Grade 3 orbital invasion was associated with shorter 5-year OS, LRFS, PFS, and DMFS
Turri-Zanoni et al. ¹⁶⁵	2019	4	Retrospective case series	163 patients with sinonasal cancers with orbital invasion	1. DSS 2. OS	Orbital apex invasion was a negative prognosticator in 5-year OS and DSS
Sugawara et al. ¹⁶⁶	2015	4	Retrospective case series	15 patients with orbital apex extension of SNM	N/A	Extended orbital apex exenteration via middle cranial fossa approach may be feasible in accomplishing a negative-margin GTR with tumors involving orbital apex

Abbreviations: DMFS, distant metastasis-free survival; DSS, disease-specific survival; GTR, gross total resection; LRFS, locoregional failure/recurrence-free survival; OS, overall survival; PFS, progression-free survival; RT, radiation therapy; SCC, squamous cell carcinoma; SNM, sinonasal malignancy.

considerable oncologic and operative risks that decrease the feasibility of resection. Surgical attempts to dissect or sacrifice the ICA risk arterial rupture and hemorrhagic or embolic stroke, which may be neurologically devastating or lethal. Therefore, the decision to pursue surgery must consider the probability of NMR against the risk of life-threatening AEs. Extrapolating from studies of head and neck cancer patients, several parameters are associated with an inability to separate tumor from the ICA. Several groups have demonstrated that cervical carotid artery encasement by 270° or greater on preoperative imaging is 83%–88% sensitive and 100% specific for histologic vessel invasion (tumor ≤1.8 mm from the elastic lamina).^{167,168} In contrast to open approaches to the cervical ICA, visualization of tumors involving the skull base ICA segments may be impaired by tumor location (posterolateral aspect of the ICA) or in areas of significant bony coverage. In a heterogenous group of ventral skull base tumors with ICA involvement, Zhang et al. found that the rate of GTR was significantly associated with the degree of tumor encasement, a posterior location of tumor relative to ICA, the involvement of two or more ICA segments, and robust enhancement on postcontrast T1-weighted MRI sequences.¹⁶⁹ To address the limitations of resecting tumors invading the ICA, multiple groups have examined the role of cerebral revascularization or ICA bypass to facilitate carotid resection and augment the probability of NMR. Early studies of patients with skull base tumors undergoing ICA revascularization prior to GTR were cautious to recommend this paradigm due to higher vascular complications rates (incidence 20%–33% perioperatively), including stroke, subdural hemorrhage, bypass occlusion, and death.^{170,171} However, at a high-volume center, Yang et al. found that, in patients with intracranial nonsinonasal tumors, high-flow cerebral revasculariza-

tion allowed for 72% GTR rate with fewer perioperative complications than previously described and mean OS of 46.4 months (range 12–81 months).¹⁷² Furthermore, Ferrari et al. reported 10 patients with skull base cancer invasion of the ICA who were treated with ICA resection (two with bypass), with mean OS 27.2 months and 2-year PFS of 88.9%, and 10% perioperative mortality.¹⁷³

With careful evaluation of patient and tumor characteristics, several strategies are often described to address tumors involving the carotid artery: (1) primary nonsurgical therapy (radiation and/or chemotherapy), (2) GTR with separation of tumor from the ICA when vessel invasion is not suspected, or (3) GTR with sacrifice of ICA (with or without perioperative cerebral revascularization in cases with suspected vessel invasion). To date, no long-term, definitive data have demonstrated a survival advantage with radical resection that includes ICA sacrifice compared to primary nonsurgical therapy for SNM. There is no clear consensus on the benefits of carotid resection; however, revascularization of the carotid artery, if feasible, may allow GTR but is associated with significant perioperative risks (Table VIII.3).

Aggregate grade of evidence: C (Level 4: seven studies)

D | Skull base involvement

The detrimental effects of intracranial extension of SNM on OS, DSS, and RFS compared to tumors without intracranial involvement have been demonstrated across multiple large-scale case series.^{174–176} Brain parenchymal invasion, in particular, is a remarkably potent predictor of worse survival despite aggressive multimodality therapy.^{175,177–181} CFR (either via open, endoscopic, or

TABLE VIII. 3 Evidence surrounding the resectability of tumors involving the carotid artery.

Author	Year	LOE	Study design	Study groups	Clinical endpoints	Conclusion
Ferrari et al. ¹⁷³	2022	4	Retrospective case series	10 patients with skull base cancer with ICA invasion treated with surgery Two patients underwent bypass	1. OS 2. PFS 3. Mortality	ICA resection is feasible with fair outcomes (mean OS 27.2 months, 2-year OS/PFS of 88.9%, 10% perioperative mortality) with properly selected patients
Zhang et al. ¹⁶⁹	2021	4	Retrospective case series	46 EEA patients with recurrent or persistent ventral cranial base tumors	Effect of ICA related tumor characteristics on ability to achieve GTR	1. Recommend 5S ICA grading scale and ICA grading strategy to obtain maximum total resection rate 2. Treatment strategy is guided by ICA 3. BOT testing with either bypass (if BOT is failed) or ICA embolization and ligation (if BOT is passed) followed by GTR
Yang et al. ¹⁷²	2014	4	Retrospective case series	18 patients with skull base tumors of nonsinonasal origin who underwent 20 high flow bypasses	Descriptive clinical data	In experienced hands, high flow bypass for cerebral revascularization may be an option
Kalani et al. ¹⁷⁰	2013	4	Retrospective case series	18 patients with advanced head and neck cancer requiring ICA sacrifice and cerebral revascularization	1. Adverse events 2. Survival	There was a high rate of periprocedural complications and poor patient survival
Yoo et al. ¹⁶⁷	2000	4	Retrospective case series	34 patients with advanced head and neck SCC who underwent carotid artery resection	1. CT and histologic findings 2. OS	1. Histologic invasion predicted survival 2. Clinical assessment was as predictive as CT for tumor invasion
Lawton and Spetzler ¹⁷¹	1996	4	Retrospective case series	10 anterior skull base tumor patients with ICA encasement requiring sacrifice	N/A	ICA revascularization prior to malignant skull base tumor extirpation was feasible with 20% risk of vascular complication
Yousem et al. ¹⁶⁸	1995	4	Retrospective case series	49 patients with head and neck neoplasms and clinical evidence of carotid wall invasion	Correlation between MR imaging findings and tumor resectability	>270-degree encasement of the ICA on MRI was 100% specific and 88% sensitive for unresectable disease

Abbreviations: BOT, balloon occlusion testing; EEA, endoscopic endonasal approach; GTR, gross total resection; OS, overall survival; PFS, progression-free survival; SCC, squamous cell carcinoma; SDH, subdural hemorrhage.

combined approaches) is aimed at addressing both the sinonasal and intracranial aspects of tumors (dural or brain parenchymal components) and is a commonly used modality for addressing SNM with intracranial spread. Ganly et al. analyzed 344 patients undergoing CFR from an international collaborative study and found that 5-year OS decreased from 57.3% to 37.8% with dural involve-

ment and decreased to 26.6% with brain involvement ($p < 0.001$), while DSS decreased from 64.1% to 45.0% and 28.4%, respectively ($p < 0.001$).¹⁷⁴ Despite the staging and survival implications of intracranial involvement, the reviewed studies included patients in which tumor was dissected from the dura and brain parenchymal components without reported independent increases in positive

margins or surgical complications. Indeed, it appears that successful achievement of negative margins when resecting tumors involving the skull base is predictive of improved survival regardless of the extent of intracranial extension.^{130,132,174,178,181–185} However, it should be noted that, in the studies examined, patients with extensive brain parenchymal involvement were often excluded from surgical therapy and therefore an assessment of their resectability is not feasible.

Sinonasal tumors may invade the cavernous sinus along several pathways: through the orbital apex (via superior or inferior orbital fissures), through the paranasal sinuses or pterygopalatine fossa (PPF) (via foramen rotundum or ovale), along the course of the ICA, or by direct invasion. Therefore, evaluating resectability of tumors involving the cavernous sinus is frequently considered in tandem with involvement of the orbital apex, carotid artery, or PPF. Data from 40 patients with maxillary sinus carcinomas found that invasion of the cavernous sinus was an independent predictor of poor OS and led to a decrease in 5-year OS from 72.4% to 20% ($p = 0.012$), even with attempted en bloc resection.¹⁸⁶ Once tumors involve the cavernous sinus, en bloc or negative margin resection may require sacrifice of the cavernous ICA or multiple cranial nerves, first described by Saito et al. in 1999.¹⁸⁷ However, the rate of severe complications may be unacceptably high. Studies by Saito et al. and Couldwell et al. both report two surgery-related deaths among other morbid AEs (stroke, sepsis, CSF leak) in small case series.^{187,188} No large-scale studies evaluating the resectability of sinonasal tumors with cavernous sinus involvement were found (Table VIII.4).

Aggregate grade of evidence: C (Level 3: three studies; Level 4: 12 studies)

E | Pterygopalatine and infratemporal fossa involvement

The proximity to cranial nerves and other vital structures has made the PPF and infratemporal fossa (ITF) historically challenging to access and resect. Several authors have reported that the rate of negative margin resection of tumors involving the PPF and ITF ranges from 56% to 77%.^{189–192} He et al. found that close or positive margins within the PPF or ITF were associated with worse 5-year RFS (hazard ratio [HR] 6.158, $p = 0.001$) and OS (HR 21.961, $p = 0.006$).¹⁹¹ Similar effects were reported by Konig et al., where retromaxillary involvement was associated with worse survival at 2, 5, and 10 years (35%, 29%, and 17%, respectively).¹⁹³ In contrast, others found that PPF or ITF involvement was not an independent risk factor for worse outcome when compared to T4b tumors.¹⁹⁴ Based on the limited data available, tumors involving the PPF or ITF

may be accessible surgically and their isolated involvement may not be an independent risk factor for worse prognosis, but in keeping with other subsites, positive surgical margins portend a poorer OS (Table VIII.5).

Aggregate grade of evidence: C (Level 3: one study; Level 4: five studies)

In nearly all subsections above, there were no high-quality, prospective studies evaluating the feasibility of GTR as a primary treatment paradigm for nonrecurrent, very advanced SNM. The preponderance of literature evaluating T4b sinonasal tumors addresses patient outcomes undergoing primary nonsurgical therapy, surgery following neoadjuvant systemic therapy, or the role of surgical debulking prior to definitive radiation. For the purposes of this consensus statement, this review excluded histologic subtypes in which surgery is not considered first-line treatment. Lymphoma and NPC, for example, are considered curable utilizing nonsurgical therapy. In addition, the examination of (1) the role of neoadjuvant systemic therapy prior to surgical extirpation and (2) the role of surgical debulking prior to definitive radiotherapy is discussed in other sections of this consensus statement. Overall, the constraints of resectability continue to evolve and are driven by a complex interplay of patient characteristics, tumor histology and invasion, surgeon experience, institutional preference, and adjuvant or neoadjuvant therapy.

IX | WORKUP OF REGIONAL AND DISTANT DISEASE

Staging in head and neck malignancies is essential to guide surgical oncologists, radiation oncologists, and medical oncologists toward the most successful treatment options for these tumors. Status of regional and distant metastasis prior to treatment is essential after establishing diagnosis of a malignant primary lesion, as it helps determine prognosis and may change treatment options. Presence of nodal metastasis has been associated with up to 50% decrease in survival.¹⁹⁵ Although cervical metastasis can be clinically apparent on physical examination in advanced cancers, metastasis may also be discovered on initial staging radiological imaging.¹⁹⁵ NCCN Head and Neck guidelines recommend CT or MRI of the neck to evaluate cervical nodal metastasis.¹⁹⁶ They specify using either modality as indicated for evaluation of the primary site. CT chest or PET/CT is recommended for “high-grade tumors, multistation, or lower neck nodal involvement.”¹⁹⁶ PET/CT is recommended when available in surgically resectable tumors near midline and in the workup of distant metastasis in patients with advanced cancer including T3, T4, and N1 or higher nodal status.¹⁹⁶

TABLE VIII. 4 Evidence surrounding resectability of tumors involving the skull base.

Author	Year	LOE	Study design	Study groups	Clinical endpoints	Conclusion
Patel et al. ¹⁸¹	2012	3	Retrospective cohort	151 patients who underwent CFR for ONB	1. OS 2. DSS 3. RFS	Intracranial extension and PSM are predictors of worse OS, DSS, and RFS
Ganly et al. ¹⁷⁴	2005	3	Retrospective cohort	334 patients with SNM (excluding ONB)	1. OS 2. DSS 3. RFS	Surgical margins, histology, and extent of intracranial involvement were predictors of OS, DSS, and RFS
Patel et al. ¹⁸⁰	2003	3	Retrospective cohort	1307 patients who underwent CFR for malignancies affecting the skull base	1. OS 2. DSS 3. RFS	Brain involvement negatively predicted OS, DSS, and RFS
Mehta et al. ¹⁷⁹	2021	4	Retrospective case series	225 patients with SNM involving the anterior skull base	1. Progression 2. Survival 3. Treatment-related complications	Brain invasion was present in 19% of patients at the time of surgery and was associated with worse OS
Abdelmeguid et al. ¹⁸²	2020	4	Retrospective case series	239 patients with SNM who underwent endoscopic resection	1. Survival 2. Surgical complications	1. 25% rate of intracranial extension 2. NSM achieved in 87.4% patients
Mattavelli et al. ¹⁸⁴	2019	4	Retrospective case series	19 patients undergoing endoscopic resection with transnasal craniectomy and subpial dissection for nasoethmoidal malignancies with brain invasion	Complications	1. Six (54.5%) cases with PSM, five of which had dura involvement and one had brain invasion 2. 10.5% complication rate
Konig et al. ¹³²	2018	4	Retrospective case series	41 patients with SNM involving the anterior skull base undergoing CFR	Survival	1. 37% dural invasion, 7% brain parenchymal invasion 2. NSM achieved in 59% of patients, correlated with improved OS and RFS
Nishio et al. ¹⁸⁶	2015	4	Retrospective case series	40 patients with T4 staged maxillary sinus carcinoma treated with CFR	OS	1. Cavernous sinus involvement correlated with worse OS 2. PSM correlated with worse OS if no cavernous sinus invasion present
Kim et al. ¹⁸³	2015	4	Retrospective case series	17 patients with anterior skull base malignancies treated with CFR	1. Tumor characteristics 2. Survival	GTR achieved in 100% of patients despite intracranial involvement in 65% of patients
Couldwell et al. ¹⁸⁸	2014	4	Retrospective case series	Eight patients undergoing complete resection of the cavernous sinus	Description of adverse events	Four patients experienced complications (two CSF leaks), one stroke leading to death, and one sepsis leading to death

(Continues)

TABLE VIII.4 (Continued)

Author	Year	LOE	Study design	Study groups	Clinical endpoints	Conclusion
Cantu et al. ¹⁶³	2012	4	Retrospective case series	366 patients with malignant paranasal sinus tumors treated with CFR	1. DSS 2. OS 3. RFS	1. 13.1% of patients had orbital apex involvement 2. 60.1% had some form of intracranial involvement 3. 10.7% had frank intradural/brain parenchyma involvement 4. Local recurrence was correlated with orbital apex involvement or dural involvement 5. Intradural spread was not associated with increased local relapse 6. 74% achieved NSM
Feiz-Erfan et al. ¹⁷⁸	2007	4	Retrospective case series	28 patients with cranial base malignancies and transdural spread who underwent CFR	1. OS 2. PFS	1. GTR with NSM positively predicts OS 2. Brain parenchymal invasion negatively predicts PFS
Howard et al. ¹⁷⁵	2006	4	Retrospective case series	308 patients who underwent CFR for sinonasal neoplasms	OS	1. 5-year OS of 59% for malignant tumors 2. Orbital involvement, brain involvement, and histology were primary predictors of OS
Saito et al. ¹⁸⁷	1999	4	Retrospective case series	25 malignant skull base tumors with cavernous sinus invasion underwent en bloc resection	N/A	1. All resection types included severing of nerves travelling through orbital apex 2. Advanced tumors requiring resection of the entire cavernous sinus exhibited major morbidity and mortality
Lund et al. ¹⁷⁶	1998	4	Retrospective case series	209 patients who underwent CFR for sinonasal neoplasms	1. OS 2. DSS	1. 6% exhibited frontal lobe tumor infiltration 2. 14% had resectable dural involvement 3. Malignant histology, brain involvement, and orbital involvement portended worse OS

Abbreviations: CFR, craniofacial resection; DSS, disease-specific survival; GTR, gross total resection; NSM, negative surgical margins; ONB, olfactory neuroblastoma; OS, overall survival; PFS, progression-free survival; PSM, positive surgical margins; RFS, recurrence-free survival; SNM, sinonasal malignancy.

Although head and neck cancer guidelines are well explored and continue to evolve with the growing literature in the field of head and neck oncology, recommendations for workup of regional and distant metastasis specific to SNM are lacking. This is in part due to the rarity of these tumors, accounting for 3%–6% of all head and neck cancers.^{197,198} In addition, regional metastasis in sinonasal tumors ranges between 3% and 33% and distant metastasis occurs in less than 7% of cases.¹⁹⁹ Since the latter is uncommon even in advanced T stage, there is no agreement on the need for routine imaging, the most ideal imaging modality, or its cost-effectiveness at initial staging to identify the

presence of regional or distant metastasis.^{199,200} Despite this lack of consensus, when regional or distant metastasis is identified, treatment options are significantly altered; surgical resection may no longer be recommended, and RT or systemic treatment options not initially considered may become indicated. Palliative therapy may be considered in certain cases to prioritize comfort and to avoid potential morbidities associated with treatments with curative intent in the presence of metastatic disease. High-risk histopathology of the primary sinonasal tumor or suspected nodal metastasis should prompt imaging to rule out regional or distant metastasis. Undoubtedly, presence of

TABLE VIII.5 Evidence surrounding resectability of tumors involving the pterygopalatine fossa or infratemporal fossa.

Author	Year	LOE	Study design	Study groups	Clinical endpoints	Conclusion
Konig et al. ¹⁹³	2020	3	Prospective cohort	72 patients treated for SCC of the paranasal sinuses	Survival outcomes	<ol style="list-style-type: none"> Retromaxillary involvement portended worse 2-, 5-, and 10-year OS PSM associated with worse survival
Yafit et al. ¹⁸⁹	2019	4	Retrospective case series	63 patients with tumors involving the ITF	<ol style="list-style-type: none"> Margins OS 	<ol style="list-style-type: none"> 68% achieved NSM 3- and 5-year OS for malignancy were 82% and 66%, respectively
He et al. ¹⁹¹	2015	4	Retrospective case series	80 patients with malignancies involving PPF or ITF who underwent resection	<ol style="list-style-type: none"> Margins OS 	<ol style="list-style-type: none"> 56.2% achieved NSM Close or positive surgical margins portended worse 5-year RFS
Kano et al. ¹⁹⁴	2014	4	Retrospective case series	118 patients with locally advanced maxillary sinus cancer	<ol style="list-style-type: none"> OS LRC 	PPF and ITF extension were not associated with worse 5-year OS or LRC compared to T4b tumors
Givi et al. ¹⁹⁰	2013	4	Retrospective case series	43 patients who underwent anterolateral approach to tumors with ITF resection	<ol style="list-style-type: none"> Margins OS 	<ol style="list-style-type: none"> 70% achieved NSM. Median OS of 40 months and 3-year survival of 59.6%
Hentschel et al. ¹⁹²	2010	4	Retrospective case series	52 patients with anterolateral skull base neoplasms (75% involving ITF)	Patient demographics, tumor characteristics, treatment, and outcomes	<ol style="list-style-type: none"> 77% achieved GTR 2- and 5-year OS of 81% and 53%, respectively

Abbreviations: ITF, infratemporal fossa; GTR, gross total resection; LRC, locoregional control; NSM, negative surgical margins; OS, overall survival; PSM, positive surgical margins; RFS, recurrence-free survival; SCC, squamous cell carcinoma.

metastatic disease has significant therapeutic implications for the individual patient and may therefore warrant routine radiographic imaging, such as PET/CT or CT neck and chest, which are most commonly used in clinical practice.

A | Retropharyngeal lymphadenopathy

Physical exam with neck palpation of patients diagnosed with SNM should always be performed. Although this was not a main research focus and was stated in only three of the included articles, findings of enlarged cervical nodes on examination raise the suspicion of more advanced disease, are associated with worse prognosis, and prompt further investigation by imaging to rule out regional and distant metastasis.¹⁹⁹ Retropharyngeal lymph nodes (RPLNs) may be encountered for several SNM. In contrast to cervical lymphadenopathy, enlarged RPLNs are not easily identifiable on physical exam. They are also more difficult to treat surgically due to their location, and their presence may therefore lead to a change in treatment

for these patients. In addition, metastatic RPLNs have been reported in as high as 30.6% of patients with sinonasal cancers.^{201,202} Six articles report the incidence of pathologic RPLNs, including 30.6% in a heterogeneous group of sinonasal carcinomas, 0% specific to adenocarcinoma, 8.2% for ONB, 16% for a mix of maxillary sinus carcinomas, and 20.6% for maxillary sinus SCC.^{201–205} One study identified that 43% of patients with ONB who had positive cervical nodes had enlarged RPLNs as well, and therefore recommended evaluation for RPLN involvement in all patients with this histopathological diagnosis.²⁰⁶ With the potentially high rate of RPLN and the difficulty of identifying these on physical exam, it is important to look for the presence of enlarged RPLN on imaging. Two studies suggested CT with contrast to detect RPLN, one of which specifies <5-mm cuts.^{205,207} More recent studies suggest MRI as a superior modality to identify RPLN.^{201,202} MRI accuracy in the measurement of axial diameters of RPLN ≥ 5 mm was reported as 94.1% in one study.²⁰² Nevertheless, despite a trend toward MRI as a superior modality, there are insufficient data to recommend one modality

over another. In addition, the criteria used to diagnose malignant RPLN on imaging is not clear for sinonasal cancers, nor is it easy to confirm due to inability to verify with pathological diagnosis. Enlarged nodes have previously been noted as having a longitudinal diameter of ≥ 8 mm on CT in maxillary sinus carcinoma or axial diameter of ≥ 5 mm on MRI.^{202,205} One study defined its criteria of metastatic RPLNs as ≥ 6 mm diameter, presence of central necrosis, ill-defined margins or extracapsular spread, enhancement, and/or more than two ipsilateral or medial RPLNs.²⁰¹ This same study found RPLNs to be associated with worse OS, thus further reinforcing the need to look for RPLNs on initial imaging.²⁰¹

B | Anatomic imaging

Ultrasound of the neck has very limited value in the investigation of regional metastasis in sinonasal cancers. A single study discusses its usefulness in identifying cervical lymph nodes in the context of sinonasal tumors extending to the oral cavity and those with aggressive histology, such as SNUC or high-grade ONB.^{199,208}

With more detailed and improved imaging modalities, CT and MRI have become the mainstay of conventional imaging in sinonasal cancers and are both reported to be accurate and complementary to one another.^{198,207,209,210} CT is ideal for assessment of bony landmarks for surgery, bone erosion, and central necrosis of nodal metastasis, while MRI is ideal for locoregional invasion, including intracranial, perineural, and orbital invasion as well as brain metastasis.^{198,208,211} In patients with mucosal melanoma, MRI brain is recommended to rule out brain metastasis.^{212,213} Criteria for cervical metastasis on CT imaging include size of lymph node ≥ 1.5 cm, nonenhancing, irregularity, conglomerate of three or more lymph nodes with poorly defined contour, obliteration of soft tissue planes, and/or central necrosis with decreased density on imaging.²⁰⁷ Compared to MRI, CT is faster to perform, better tolerated by patients, and more readily available even in more resource-constrained settings.²⁰⁸ However, one must take into consideration the risk of radiation with CT. While MRI does not subject patients to ionizing radiation, it has its own disadvantages, including longer examination time, risk of motion artifact, and contraindication in patients with noncompatible metallic devices.⁴

In addition to its use in the head and neck, CT is a useful modality to assess for distant metastasis. CT chest is most commonly used to rule out lung metastasis.^{209,210,213–215} One study specified the following criteria to consider requesting a CT chest: at least three cervical lymph nodes, bilateral lymph nodes, size ≥ 6 cm, or lymph nodes in the lower jugular region.²⁰⁹ In ONB and mucosal melanoma patients, additional imaging with CT

abdomen/pelvis is recommended as metastasis can be seen in this region.^{213,214}

C | Functional imaging

Hybrid PET scans include PET/CT and PET/MRI. PET/CT has been the most studied in literature for head and neck malignancies and has been shown to have a higher sensitivity in the assessment of regional and distant metastasis.¹⁹⁶ However, a consensus on the benefit of its use in staging of SNM has yet to be achieved.^{200,215,98}

In a 2012 study by Lamarre et al., PET/CT for SNM was noted to have specificity of 92% and negative predictive value (NPV) of 100% for cervical metastasis and a sensitivity and NPV of 100% for distant metastasis.¹⁹⁷ Similarly, Meerwein et al. found hybrid PET has shown a sensitivity and NPV of 100% for both regional and distant metastasis.¹⁹⁸ In addition to its excellent accuracy, the benefits of hybrid PET are numerous as this imaging modality allows for a single exam to identify the primary site, cervical metastasis, and distant metastasis, thus saving time, reducing patient distress, and lowering costs.²¹⁶ Seventeen studies comment on the usefulness of PET imaging in the context of metastatic staging of sinonasal tumors.^{68,197,198,204,206,208–214,217–221} Two additional studies recommend its usage when metastasis is clinically suspected.^{98,222} Two studies recommend that PET/CT use is tailored to the histopathological diagnosis, notably in aggressive pathologies or when a sinonasal lesion is suspected to be a metastatic lesion.^{68,200} Sinonasal SCC, ONB, SNUC, SNEC, and mucosal melanoma are among histopathological diagnoses that warrant use of PET/CT to workup distant metastasis.²⁰⁰ Adenocarcinoma, on the other hand, is reported to have lower risk of regional and distant metastasis and therefore the use of PET/CT in this diagnosis requires further contemplation.²⁰⁰

Although the many benefits of PET/CT apply to overall staging, three studies have noted it is clinically more advantageous in the setting of restaging, particularly for regional disease.^{198,216,221} Despite the latter, many studies still recommend hybrid PET in the initial staging, as this can verify fluorodeoxyglucose (FDG) avidity and allow for baseline imaging for comparison of future PET/CT in the posttreatment setting and can potentially improve management of disease.²¹⁶

However, two articles raised caution to the possibility of false-positive results with PET/CT, for example, in the context of inflammation.^{197,204} In addition, one must be cognizant of the fact that PET imaging may not identify tumors < 1 cm in size, brain metastasis due to the high FDG uptake of the brain, and scenarios where tumors may not have a high metabolic rate at baseline.²¹⁶ Some examples of possible low baseline uptake include ONB, malignant

TABLE IX.1 Evidence surrounding the workup of regional and distant metastasis.

Study	Year	LOE	Study design	Study groups	Clinical endpoints	Conclusion
Maurer et al. ¹⁹⁸	2021	3	Retrospective cohort	75 patients diagnosed with malignant sinonasal tumors; 96 regionalized MRI and hybrid PET scans	<ol style="list-style-type: none"> 1. Additional radiological information (ARI) 2. Clinically relevant information (CRI) 	<ol style="list-style-type: none"> 1. 46.9% hybrid PET exams revealed ARI 2. 33.3% hybrid PET exams revealed CRI 3. Hybrid PET imaging provides ARI and CRI in addition to regional sinonasal/neck MRI
Meerwein et al. ²¹⁷	2021	3	Retrospective cohort	Patients diagnosed with sinonasal cancer and undergoing hybrid PET imaging for initial staging (<i>n</i> = 65)	Diagnostic accuracy of hybrid PET imaging	<ol style="list-style-type: none"> 1. Hybrid PET imaging is excellent at identifying regional and distant metastasis 2. Lymph node metastases: 100% sensitivity, 91.7% specificity 3. Distant metastases: 100% sensitivity, 98.3% specificity
Lamarre et al. ¹⁹⁷	2012	3	Retrospective cohort	PET scans from patients with sinonasal neoplasms (<i>n</i> = 31)	Utility of PET for tumor staging	<ol style="list-style-type: none"> 1. Negative PET/CT was predictive of absence of disease 2. Positive PET/CT can be falsely positive and should be viewed with clinical vigilance 3. PET/CT had an overall sensitivity and specificity of 90% 4. PET/CT specificity of 92% and NPV of 100% for initial staging of cervical metastasis 5. PET/CT sensitivity of 100% and specificity of 92% for initial staging of distant metastasis
Gil et al. ²¹⁶	2007	3	Prospective cohort	Patients undergoing skull base tumor excision (<i>n</i> = 47, preoperative PET/CT = 23)	Value of PET-CT to evaluate cervical lymph nodes and distant metastases	Pretreatment PET/CT is useful as a baseline to assess response posttreatment and allows for faster identification of cervical and distant metastasis using one imaging modality
Kosugi et al. ²⁰²	2021	4	Retrospective case series	Patients who underwent MRI before and after treatment of maxillary sinus SCC (<i>n</i> = 16)	Radiologic criteria of metastatic RPLN	Minimal axial diameter of 5 mm on MRI is most appropriate for identifying metastatic RPLN
Chweya et al. ²⁰³	2021	4	Retrospective database (SEER)	325 patients with ACC	<ol style="list-style-type: none"> 1. OS 2. DSS 	<ol style="list-style-type: none"> 1. 9.5% cervical node involvement 2. 6.5% distant metastasis 3. Distant metastatic workup should be considered regardless of regional nodal status 4. Distant metastasis portends worse survival

(Continues)

TABLE IX.1 (Continued)

Study	Year	LOE	Study design	Study groups	Clinical endpoints	Conclusion
Dagan et al. ²²⁸	2019	4 ^a	Retrospective cohort	Patients with nonmetastatic sinonasal cancer (<i>n</i> = 120)	<ol style="list-style-type: none"> 1. Distant metastasis 2. Leptomeningeal metastasis 	<ol style="list-style-type: none"> 1. High-grade histology was associated with distant metastasis and leptomeningeal metastasis 2. Neuroendocrine histology and intracranial invasion were associated with leptomeningeal metastasis 3. Recommend adding CSF cytology and MRI spine and brain in the workup of patients with high-risk features
Meerwein et al. ²¹⁸	2019	4 ^a	Retrospective cohort	Patients diagnosed with SNMM who had hybrid PET (<i>n</i> = 34)	<ol style="list-style-type: none"> 1. Cervical node involvement 2. Distant metastasis 3. Use of hybrid PET 	<ol style="list-style-type: none"> 1. 6% cervical node involvement 2. 6% distant metastasis 3. Initial cervical PET/ MRI may be useful for initial staging and restaging, and provides information on all sites
Marinelli et al. ²⁰⁴	2018	4 ^a	Retrospective cohort	Patients diagnosed with ONB (<i>n</i> = 61)	<ol style="list-style-type: none"> 1. Cervical node involvement 2. Laterality of cervical disease 	<ol style="list-style-type: none"> 1. 15% cervical node involvement 2. 21% delayed cervical node involvement posttreatment 3. 92% ipsilateral, 63% contralateral cervical disease 4. PET/CT useful to detect occult nodal spread and enable earlier metastasis detection
Felix-Ravelo et al. ²⁰⁰	2017	4 ^a	Retrospective cohort	Patients with an SNM who had PET/CT (<i>n</i> = 50)	<ol style="list-style-type: none"> 1. FDG uptake at primary site 2. Use of PET/CT by tumor type 	<ol style="list-style-type: none"> 1. The average SUVmax was highest for SNUC compared to other histologies 2. PET/CT may be useful in assessing regional and distant metastasis in sinonasal SCC, ONB, SNEC, and SNMM 3. PET/CT use is debatable for SNAC
Gangl et al. ²⁰¹	2017	4 ^a	Retrospective cohort	Patients with sinonasal carcinoma who had CT or MRI (<i>n</i> = 36)	<ol style="list-style-type: none"> 1. Presence of RPLN 2. OS 	<ol style="list-style-type: none"> 1. RPLN portended worse OS 2. Imaging, preferably with MRI, should be performed for assessment of RPLN
Ahn et al. ²²⁹	2016	4	Retrospective database (SEER)	Patients with sinonasal SmCC and SNUC (<i>n</i> = 141)	Cervical node involvement	<ol style="list-style-type: none"> 1. Cervical node involvement at diagnosis: 22% overall (24.1% SNUC, 13.8% sinonasal SmCC) 2. The neck and potential sites of distant metastases should be worked up in patients with SNUC or sinonasal SmCC.
Dubal et al. ²³⁰	2016	4	Retrospective database (SEER)	Patients with maxillary sinus SCC (<i>n</i> = 854)	<ol style="list-style-type: none"> 1. Cervical node involvement 2. Distant metastasis 	<ol style="list-style-type: none"> 1. 22% cervical node involvement 2. 4% distant metastasis

(Continues)

TABLE IX.1 (Continued)

Study	Year	LOE	Study design	Study groups	Clinical endpoints	Conclusion
Ramakrishnan et al. ²²²	2013	4 ^a	Retrospective cohort	Patients with SNM (<i>n</i> = 51)	<ol style="list-style-type: none"> 1. Regional metastasis 2. Distant metastasis 	<ol style="list-style-type: none"> 1. SUVmax of primary tumor did not correlate with T staging or metastasis 2. PET for SNM may be limited to cases with a high suspicion of metastatic disease
Haerle et al. ²¹²	2012	4	Retrospective case series	Patients with SNMM (<i>n</i> = 10)	N/A	<ol style="list-style-type: none"> 1. PET/CT is more sensitive and specific than CT for the detection of metastasis 2. PET/CT is valuable for staging and re-staging SNMM to evaluate expansion of the primary tumor, LCR, and distant metastasis
Howell et al. ²⁰⁶	2011	4	Retrospective case series	Patients diagnosed with ONB (<i>n</i> = 48)	<ol style="list-style-type: none"> 1. Cervical nodal metastasis 2. Nodal imaging characteristics 	<ol style="list-style-type: none"> 1. Level II is the first site of cervical metastasis in ONB 2. Levels I and III and RPLNs are often involved. 3. RPLN is present in 43% of patients with cervical lymphadenopathy 4. Cervical metastatic nodes are solid, enhance with contrast, and have moderate to high FDG avidity 5. Retropharyngeal space should be examined in all patients with ONB
Wild et al. ²²¹	2006	4	Retrospective case series	Patients diagnosed with sinonasal, orbital, and pterygopalatine or infratemporal fossa tumors undergoing PET/CT (<i>n</i> = 21)	PET/CT use in identifying regional and distant metastasis	<ol style="list-style-type: none"> 1. PET/CT, MRI, and CT were concordant in initial staging for regional LNs 2. PET/CT is useful for assessing distant metastasis in initial staging and restaging 3. PET/CT may be more useful in assessing regional metastasis in restaging than in staging 4. PET/CT is of limited value in patients moderate FDG uptake of their primary tumor
Helsel et al. ²²⁵	2003	4	Retrospective case series	FNAB cytology from primary and metastatic sites of patients diagnosed with sinonasal cancers (<i>n</i> = 20)	Value of FNAB cytology to diagnose sinonasal tumors and their metastasis	FNAB cytology is useful and accurate in the diagnosis of both primary sinonasal tumors and regional and distant metastatic sites
Watarai et al. ²⁰⁵	1993	4	Retrospective case series	Patients with maxillary sinus carcinoma (<i>n</i> = 25)	Incidence and use of CT in detecting RPLN	<ol style="list-style-type: none"> 1. Incidence of RPLN ≥ 8 mm in long axis on CT: four out of 25 (16%) 2. CT (with <5-mm cuts): useful to detect RPLN

(Continues)

TABLE IX.1 (Continued)

Study	Year	LOE	Study design	Study groups	Clinical endpoints	Conclusion
Weber and Stanton ²⁰⁷	1984	4 ^a	Retrospective cohort	Patients with malignant paranasal sinus tumors (<i>n</i> = 200, 144 carcinoma, 56 noncarcinoma)	<ol style="list-style-type: none"> 1. Incidence of cervical LN and/or distant metastasis 2. Imaging criteria in workup of cervical LN metastasis 	<ol style="list-style-type: none"> 1. Regional and/or distant metastasis: 33% in carcinomas, 37% in noncarcinomas 2. CT is useful to detect RPLN and cervical LN metastasis
Ferrari et al. ²³¹	2021	5	Review/expert opinion	Sinonasal SCC	N/A	PET/CT should be performed in advanced head and neck SCC to assess the primary site, regional metastasis, and distant metastasis
Dumont et al. ²¹⁴	2020	5	Review/expert opinion	ONB	N/A	<ol style="list-style-type: none"> 1. Clinical exam, cervical MRI and CT scan, and PET should be used to assess cervical lymphadenopathy 2. PET should be used to assess distant metastasis 3. Chest and abdominal CT and/or hepatic ultrasound should be done when specifically investigating lung and liver metastasis
Virarkar et al. ²¹⁹	2020	5	Review/expert opinion	Imaging in NUT midline carcinoma	N/A	<ol style="list-style-type: none"> 1. CT, MRI, and PET/CT: essential for staging of NUT midline carcinoma 2. Occasional involvement of cervical LN, nonnecrotic 3. Distant metastasis: bone most common
Abdelmeguid et al. ²¹⁰	2019	5	Review/expert opinion	SNUC	N/A	<ol style="list-style-type: none"> 1. CT and MRI to assess cervical adenopathy 2. PET and CT chest to assess distant metastasis
Bossi et al. ¹⁹⁹	2016	5	Review/expert opinion	SNM	N/A	<ol style="list-style-type: none"> 1. Neck palpation should be performed on physical exam to look for enlarged cervical adenopathy 2. Neck US for sinonasal tumors with the high-risk features 3. FNAC for cervical adenopathy
Lund et al. ⁶⁸	2016	5	Review/expert opinion/guidelines	Nose and paranasal sinus tumors	N/A	<ol style="list-style-type: none"> 1. Use MRI to assess invasion of orbital contents, dura, brain, and cavernous sinus 2. Use PET-CT to: <ul style="list-style-type: none"> - assess for distant metastasis in primary tumors with aggressive histopathology - rule out a primary tumor elsewhere in the body if a sinonasal tumor is suspected to be a metastasis

(Continues)

TABLE IX.1 (Continued)

Study	Year	LOE	Study design	Study groups	Clinical endpoints	Conclusion
Abraham ²⁰⁸	2015	5	Review/expert opinion	Head and neck cancer patients	N/A	In sinonasal tumors: 1. MRI to assess orbital and intracranial extension 2. US use is limited 3. PET/CT for staging and to assess cervical adenopathy
Antoniou ²¹¹	2014	5	Review/expert opinion	SNM	N/A	1. MRI to assess orbital and intracranial extension 2. PET/CT for systemic staging and cervical adenopathy has superior sensitivity and specificity for nodal staging than anatomic modalities
Gilain et al. ²¹³	2014	5	Review/expert opinion	Nasal and paranasal SNMM	N/A	1. Neck palpation should be performed on physical exam to look for enlarged cervical lymphadenopathy 2. MRI to assess brain metastasis 3. CT chest, abdomen, and pelvis and PET/CT to assess distant metastasis
Llorente et al. ⁹⁸	2014	5	Review/expert opinion	Sinonasal carcinoma	N/A	PET-CT: Indications not clearly defined. Useful for patients with suspected metastasis.
Jegoux et al. ²¹⁵	2013	5	Review/expert opinion	Paranasal sinus cancers	N/A	1. Neck palpation should be performed on physical exam to look for enlarged cervical adenopathy 2. CT neck and chest is indicated for staging of regional and distant metastasis 3. No consensus on PET/CT, but can be used for initial staging
Rankin ²⁰⁹	2003	5	Review/expert opinion	Imaging in malignant sinus tumors	N/A	1. Cervical nodal metastasis: - CT: NPV 84%, PPV 50% - MRI: NPV 79%, PPV 52% - PET: sensitivity 80%–96%; specificity 90%–94% 2. CT and MRI are similar in accuracy in identifying cervical nodal metastasis 3. PET: Useful for staging regional and distant metastasis

Abbreviations: CT, computed tomography; FNAB, fine-needle aspiration biopsy; LN, lymph node; MRI, magnetic resonance imaging; NPV, negative predictive value; ONB, olfactory neuroblastoma; OS, overall survival; PET, positron emission tomography; PPV, positive predictive value; RPLN, retropharyngeal lymph nodes; SCC, squamous cell carcinoma; SEER, Surveillance, Epidemiology, and End Results; SNM, sinonasal malignancy; US, ultrasound.

^aLOE downgraded for lack of controlling for confounding factors.

peripheral nerve sheath tumor, ACC, adenocarcinoma, and metastatic lesions.^{216,223}

Maurer et al. demonstrated that use of hybrid PET results in both additional radiological and clinically relevant information, suggesting that hybrid PET imaging should be used in staging all sinonasal cancers.¹⁹⁸ If PET/CT is used, it should be combined with additional MRI.¹⁹⁸ Thus, further studies on the use of hybrid PET/MRI have the potential to make it the imaging modality of choice in the future, combining both high-yield imaging techniques into one test.

Gallium-69 Dotatate PET/CT imaging is another functional imaging modality in somatostatin receptor overexpressing sinonasal tumors, such as ONB and SNEC.²²⁴ It has the potential to be very useful in detecting small tumors and metastasis that may not have been identified with traditional imaging methods due to its strong affinity to the receptor. However, one must be aware that meningiomas, reactive lymph nodes, and other inflammatory processes, as well as some organs (liver, spleen, adrenal glands, pancreas, thyroid, and salivary glands), may also present with uptake despite being benign processes.²²⁴

D | Biopsy

When cervical adenopathy is identified on physical exam and/or imaging, fine-needle aspiration biopsy (FNAB) should be performed to confirm histopathology and diagnosis of cervical metastasis. FNAB with image guidance (ultrasound or CT) is preferred.¹⁹⁶ The use of FNAB for histopathological diagnosis of primary and distant metastasis is also described.^{196,199,225} FNAB provides a rapid cytopathologic diagnosis of regional and, in many cases, distant metastasis. However, the RPLN can be a challenging location for FNAB due to anatomic constraints of the facial bones and the proximity of carotid sheath. Some providers have described endoscopic ultrasound-guided needle biopsy approach to the RPLN, but the value of such a procedure over imaging-based diagnosis has not been fully studied.^{226,227}

In cases of recurrent/metastatic disease, large volumes of tissues are required, and core needle biopsy is a useful office-based procedure for this tissue acquisition. Advanced genomic sequencing allows providers an opportunity to incorporate targeted therapies as part of a patient's treatment, but such testing requires a larger volume of tissue that can be acquired via core needle biopsy.

Based on this review, physical examination with palpation of the neck and imaging with CT and/or MRI should be requested in search of regional cervical and RPLN metastasis. RPLNs appear to be more prevalent than previously thought and should always be investigated, preferably with MRI. Hybrid PET has shown increased

usefulness in staging of sinonasal tumors and should be considered in primary workup due to its many benefits. However, clinicians should remain aware of the limitations of this imaging modality. PET/MRI shows promise as an imaging modality that should be further investigated. Table IX.1 summarizes evidence surrounding the workup of regional and distant metastasis.

Workup of regional and distant disease

Aggregate grade of evidence	C (Level 3: four studies; Level 4: 16 studies; Level 5: 12 studies)
Benefit	CT and MRI are complementary for regional and distant disease workup. Functional imaging such as PET/CT has high sensitivity and NPV, allows for baseline imaging, and is a single imaging technique for rapid simultaneous qualitative evaluation of the primary, regional, and distant metastasis.
Harm	CTs expose patients to radiation. Workup of regional and distant metastasis and false-positive PET/CT may lead to additional (and potentially unnecessary) investigations, patient anxiety, and increased costs without a change in treatment. In a healthcare setting with limited resources, this may further increase delays in diagnosis and strain on the system.
Cost	There is potential cost-benefit of hybrid PET scans since they can combine PET/CT or PET/MRI into a single exam and reduce the number and duration of hospital visits.
Benefits-harm assessment	Preponderance of benefits over harms.
Value judgments	CT and MRI are both useful modalities for regional and distant disease assessment. CT is faster, better tolerated, and more readily available than MRI, but does incur radiation exposure. MRI does not subject patients to ionizing radiation, but takes longer to perform, has a risk of motion artifact, and is contraindicated in patients with noncompatible ferromagnetic devices. Hybrid PET imaging allows for more rapid and accurate diagnosis of regional and/or metastatic disease, especially for high-grade tumors and/or those tumors prone to metastases (e.g., SNUC, melanoma). However, there is potential for false-positive results, and thus it may be more useful for restaging than initial staging. It may not be as useful for tumors with low FDG avidity.
Policy level	Recommendation.

(Continued)

Intervention	CT and MRI remain the conventional imaging modalities. Hybrid PET or other full-body imaging should be considered in the investigation of regional and distant metastases in SNM. Presence of enlarged RPLNs should always be evaluated on CT or MRI.
--------------	---

X | SURGICAL APPROACH

Over the past two decades, the approach to treating SNM has transitioned from radical open surgeries to more minimally invasive approaches.^{30,232} In 1963, Ketcham et al. introduced the transfacial and transcranial (CFR) procedures to address SNM.^{233,234} The approach was found to improve survival, and CFR was subsequently deemed the gold standard for SNM treatment.²² While CFR has traditionally allowed for en bloc GTR of tumors, this approach was associated with a high rate of complications including CSF leaks, increased hospital length of stay (LOS), poor cosmesis, and perioperative mortality.¹⁷⁴

Endoscopic endonasal sinus surgery was introduced in 1986 as a means to treat chronic sinusitis.²³⁵ Proponents found that it offered better visualization, reduced recovery times, and precluded the need for external incisions.^{236,237} Over time, adaptation of endoscopic techniques to EEA was successfully used to address benign sinonasal lesions. Bolstered by early retrospective cases series indicating similar survival and decreased morbidity using EEA for SNM as compared to published rates for open approaches,^{238,239} EEA began gaining traction as a main approach to address SNM.

An important concern with EEA was increased risk for recurrence.²³⁹ En bloc GTR was the gold standard for resection of malignant tumors. Alternatively, EEA utilizes progressive resection, moving from the distal aspects of the mass proximally toward its site of origin/attachment, with the goal of resecting the tumor pedicle en bloc with wide margins.²⁴⁰ Frozen sections are used to assess margin status. Early studies showed no association between positive margin status and type of surgical approach.^{241–243} Furthermore, the development of the nasoseptal flap (NSF) for more effective skull base reconstruction led to increased use of EEA to address SNM.^{244,245}

The efficacy of EEA as compared to open approaches to address SNM is still debated, especially for locally advanced and recurrent neoplasms. Additionally, the rare nature and heterogeneity of these tumors make randomized, adequately powered studies difficult to perform. This section reviewed the available literature to compare outcomes after EEA, endoscopic-assisted, and open procedures for the surgical resection of SNM. To mean-

ingfully compare outcomes between surgical approaches, only studies with at least 20 total subjects were included.

A | Squamous cell carcinoma

Current data investigating open versus EEA of sinonasal SCC are limited to retrospective studies (Table X.1). Kilic et al. queried the NCDB for cases of sinonasal SCC without metastases treated surgically between 2010 and 2014.¹³⁵ They found that using open approaches was associated with longer hospital LOS (open 4.7 vs. EEA 2.5 mean days; $p < 0.0001$). Five-year OS was not significantly different between the two approaches (OS: open 56.5% vs. EEA 46.0%; $p = 0.953$). The findings were confirmed using propensity score-matched cohorts ($n = 326$ in each group). In these cohorts, the 5-year OS was not significantly different between the open and EEA groups (56% vs. 51%; $p = 0.850$). Mortality at 30 and 90 days did not differ significantly between the groups.²⁴⁶ The authors concluded that EEA is an effective alternative to open surgery, even after accounting for confounding factors, and is also associated with a shorter hospital LOS. Torabi et al. queried the NCDB and found that EEA was not associated with an increased rate of positive margins in 2968 cases of sinonasal SCC.²⁴¹ Additionally, Karligiotis et al. found that, in 34 patients treated for SCC arising from IP, OS, DFS, and RFS rates were comparable to traditional open approaches.²⁴⁷

B | Olfactory neuroblastoma

A number of studies have compared outcomes between EEA and open approaches for anterior skull base (ASB) resection of ONB, though most studies examined small retrospective cohorts (Table X.2).^{246,248–254} One of the earliest studies comparing open versus EEA was a systematic review by Devaiah et al. in 2009 demonstrating significantly improved OS in the EEA group. Since then, two systematic reviews, containing primarily level 4 studies, showed no significant difference in rate of GTR or complication rates between open and EEA.^{255–257} Fu et al., in another systematic review, showed that EEA was associated with improved OS regardless of stage or grade ($p = 0.001$), and in patients with Kadish C or D tumors ($p = 0.04$) or with Hyams grade III/IV disease ($p = 0.001$).²⁵⁸ Additionally, the rates of distant metastasis, cause-specific mortality, and overall mortality were significantly lower in EEA. Barinsky et al. presented a large ONB cohort study of 533 cases comparing 267 open approaches to 257 EEA.²⁵⁴ Cases denoted as endoscopic converted to open were included in the open approach cohort. There were no differences between the cohorts in

TABLE X.1 Evidence surrounding open versus endoscopic approach for squamous cell carcinoma.

Study	Year	LOE	Study design	Study groups	Clinical endpoints	Conclusion
Karligkiotis et al. ²⁴⁷	2016	3	Retrospective cohort	34 IP-SCC patients	1. 5-year OS 2. 5-year DSS 3. 5-year RFS	EEA has similar oncologic outcomes for sinonasal IP-SCC to those observed with traditional open approaches
Torabi et al. ²⁴¹	2020	4	Retrospective database (NCDB)	1329 SCC patients EEA (<i>n</i> = 216) Open (<i>n</i> = 1113)	1. Positive margins 2. OS	No association between positive margins and surgical approach
Kilic et al. ¹³⁵	2017	4	Retrospective database (NCDB)	1483 SCC patients EEA (<i>n</i> = 353) Open (<i>n</i> = 1130)	1. OS 2. 30- and 90-mortality 3. LOS	1. EEA is comparable to open approaches, even accounting for confounding factors 2. EEA is associated with a shorter hospital LOS

Abbreviations: DSS, disease-specific survival; EEA, endoscopic endonasal approach; IP, inverted papilloma; LOS, length of stay; OS, overall survival; RFS, recurrence-free survival; SCC, squamous cell carcinoma.

demographics, disease characteristics, or treatment modalities. The EEA overall had a shorter hospital LOS (3.8 vs. 7.0 days; $p < 0.001$) and a greater 5-year OS (81.9% vs. 75.6%; $p = 0.03$). After multivariate regression, there was a trend toward greater survival benefit from EEA, but this did not reach significance. Patients undergoing EEA were more likely Kadish stage C (45.9%), followed by stages A (32.2%), B (14.4%), and D (7.4%). Taken together, the current level 4 evidence indicates that EEA achieves comparable control rates and survival, along with decreased complication rates, compared to open approaches for ONBs.

C | Adenocarcinoma

Meccariello et al. published a systematic review on 1826 patients comparing EEA versus open approach for sinonasal adenocarcinoma ($n = 431$ EEA, $n = 31$ endoscopic-assisted, $n = 1270$ open).²⁵⁹ They found a significantly shorter hospital LOS in the EEA group as compared to the endoscopic-assisted or open groups. The incidence of local failure was lower in the EEA group as compared to the open group (17.8% vs. 38.5%; $p < 0.01$). The EEA and endoscopic-assisted groups showed lower rates of major complications (6.6% EEA and 25.9% endoscopic-assisted) as compared with the open group (36.4% open; $p < 0.01$). In a single-institutional retrospective study, Mortuaire et al. compared open ($n = 23$) to EEA ($n = 20$) approaches for resection of ITAC of the ethmoid sinus.²⁶⁰ The two groups were comparable in terms of age, occupational dust exposure, histopathological subtypes, and pathologic T stage. No major complication was observed in the EEA group. DFS was not different between the open and EEA groups over a mean follow-up period of

6.6 years. The LOS was significantly less for the EEA versus the open approach (endoscopic 4.4 ± 1.5 days vs. open 7.0 ± 1.3 days; $p = 0.01$). Local recurrences were observed in nine patients (five from the open group and four from the EEA group). Other individual retrospective cohort studies published similar findings showing comparable outcomes between EEA and open approaches for adenocarcinoma of the paranasal sinuses (Table X.3).^{259–264}

D | Sinonasal sarcoma

Limited data are available on the outcomes of open surgery versus EEA of sinonasal sarcomas (Table X.4). Gore et al. performed a systematic review of sinonasal sarcoma studies. They reported that 5-year OS was not statistically different between cohorts (68.5% EEA, $n = 24$; 100% endoscopic-assisted open, $n = 3$; 77.8% open, $n = 57$; $p = 0.80$).²⁶⁵ Overall, the data suggest that open surgery and EEA have similar survival in sinonasal sarcoma, but additional large studies are needed to control for confounders.^{265,266}

E | Sinonasal mucosal melanoma

Sinonasal mucosal melanoma (SNMM) universally portends a poor prognosis. Numerous studies have looked specifically at EEA for sinonasal SNMM,^{267–279} of which most have been smaller cohort studies. Most show similar outcomes between EEA and open approaches when adjusting for disease severity. It should be noted that advances in adjunctive oncologic treatments have probably influenced many of these outcomes in both surgical approaches, as SNMM patients typically receive

TABLE X.2 Evidence surrounding open versus endoscopic approach for olfactory neuroblastoma.

Study	Year	LOE	Study design	Study groups	Clinical endpoints	Conclusion
Morgenstern et al. ²⁵⁶	2019	2	Systematic review	EEA TCA Number of studies or cases was not given	1. GTR rate 2. CSF leak rate	1. Similar rates of GTR and CSF leak between open and EEA 2. Selection of surgical approach for ONB is influenced by the extent of disease 3. Kadish A/B lesions are more commonly treated with EEA
Fu et al. ²⁵⁸	2016	2	Systematic review and meta-analysis	609 ONB patients from 36 studies	1. OS 2. DSS 3. LRC 4. Complications	1. EEA associated with improved OS and DSS 2. EEA have comparable control rates to open approaches 3. Open approaches have greater risks of intracranial and total complications, but similar rates of CSF leak rates
Komotar et al. ²⁵⁷	2013	2	Systematic review	453 patients CFR (<i>n</i> = 134) EEA (<i>n</i> = 54) CN (<i>n</i> = 12)	1. GTR 2. Margins 3. Complications 4. Recurrence	In well-selected cases, CN and EEA have similar or better GTR, negative margin rates, and lower recurrence rates
Devaiah and Andreoli ²⁵⁵	2009	2	Systematic review and meta-analysis	361 patients from 23 studies Open (<i>n</i> = 214) EEA (<i>n</i> = 40) Endoscopic-assisted (<i>n</i> = 57)	OS	1. OS was greater for EEA compared to open approaches 2. EEA are valid treatment options with comparable to survival to open approaches
Kim et al. ²⁵³	2019	3	Retrospective cohort	28 ONB patients CFR (<i>n</i> = 14) EEA (<i>n</i> = 14)	1. PFS 2. OS 3. LRC	No significant difference between open and EEA in PFS, OS, and LRC
Mays et al. ²⁵²	2018	3	Retrospective cohort	35 ONB patients Open (<i>n</i> = 11) EEA (<i>n</i> = 24)	DFS	DFS was not significantly different between surgical approach
Petruzzelli et al. ²⁵¹	2015	3	Retrospective cohort	31 ONB patients CFR (<i>n</i> = 20) EEA (<i>n</i> = 9) Maxillectomy (<i>n</i> = 2)	1. Complications 2. Recurrence	1. No surgical complications or recurrent disease was observed in the EEA or open medial maxillectomy cohorts 2. Surgical complications and recurrence were higher in the open approach group
Tajudeen et al. ²⁴⁹	2015	3	Retrospective cohort	36 ONB patients Transfacial approach without craniotomy (<i>n</i> = 20) EEA (<i>n</i> = 8) CFR (<i>n</i> = 8)	1. OS 2. RFS 3. Complications 4. LOS	1. Comparable survival and complication rates among all approaches 2. Decreased LOS in EEA
Rimmer et al. ²⁴⁶	2014	3	Retrospective cohort	95 ONB patients CFR (<i>n</i> = 65) EEA (<i>n</i> = 30)	1. OS 2. DFS	OS and DFS were improved in EEA group, but this group also was less likely to have advanced disease or orbital/dural involvement

(Continues)

TABLE X.2 (Continued)

Study	Year	LOE	Study design	Study groups	Clinical endpoints	Conclusion
Song et al. ²⁵⁰	2012	3	Retrospective cohort	35 ONB patients Open CFR (<i>n</i> = 12) Endoscopic CFR with craniotomy (<i>n</i> = 11) Transnasal endoscopic resection without craniotomy (<i>n</i> = 5)	1. DFS 2. Complications 3. Operation time	1. Less blood loss and shorter operation time in endoscopic groups 2. Endoscopic approaches for advanced ONB showed comparable survival results compared to open approaches
Barinsky et al. ²⁵⁴	2021	4	Retrospective database (NCDB)	533 ONB patients Open (<i>n</i> = 267) EEA (<i>n</i> = 257)	1. LOS 2. OS	1. Increased OS in EEA patients compared to open approach, regardless of Kadish stage 2. EEA reduced hospital LOS
Wertz et al. ²⁴⁸	2018	4	Retrospective case series	41 ONB patients EEA (<i>n</i> = 6) Combined open and endoscopic (<i>n</i> = 1) Open approach (<i>n</i> = 34)	Major complications	No significant difference in major complications between open and EEA

Abbreviations: CN, craniotomoscopic; EEA, endoscopic endonasal approach; GTR, gross total resection; LRC, locoregional control; NCDB, National Cancer DataBase; ONB, olfactory neuroblastoma; OS, overall survival; PFS, progression-free survival; RFS, recurrence-free survival; TCA, transcranial approach.

postoperative RT and/or immunotherapy. Almutuawa et al. in 2020 presented a retrospective cohort study on the outcomes of 20 SNMMs comparing 10 open approaches to 10 EEA.²⁷⁷ The EEA group had overall improved median (31.67 vs. 11.17 months) and 1-year survival (80% vs. 30%, $p = 0.032$). Multivariate analysis adjusting for potential confounders showed an increased risk of mortality for the open approach compared to EEA.

Farber et al. compared EEA and open approaches by querying the NCDB for nonmetastatic SNMM initially managed with definitive surgery.²⁷⁸ Cohorts of 240 EEA and 240 open approaches were matched 1:1 on all significant demographic and clinicopathologic variables. The 1-, 3-, and 5-year OS rates were comparable ($p > 0.05$) for EEA (78.1%, 50.5%, and 38%, respectively) and open approach (77.4%, 43.6%, and 34.7%, respectively). There were absolute differences in LOS (1.4 vs. 3.0 days), 30-day readmission rate (4.8% vs. 0%), and 30-day (0% vs. 1.3%) and 90-day (0.7% vs. 3.2%) mortality for the EEA versus open groups, though only LOS and readmissions reached significance. Hur et al. also conducted a systematic review showing that 5-year OS was significantly longer in patients undergoing EEA versus open approach, but there was no difference in DFS.²⁷⁹ More than 85% of the studies reviewed reported no difference in the average disease stage between the EEA and open groups, suggesting the results may apply to tumors of all stages. Despite the overall poor prognosis of SNMM, EEA appears to offer similar survival rates to open approaches in level 4 studies (Table X.5).

F | Overall outcomes

Numerous studies have shown comparable outcomes between EEA and open approaches when adjusting for tumor type, stage, margins, and other prognostic factors.^{14,182,264,265,280–299} Husain et al. queried the NCDB and compared a cohort of 2292 cases, of which 645 underwent EEA and 1647 open approach.²⁸⁸ The 5-year OS for the open versus EEA groups was 59.6% and 60.8%, respectively ($p = 0.106$). The mean LOS for the EEA was significantly lower than for the open approach (3.13 vs. 5.52 days, $p < 0.05$). The 30-day readmission rate was not different between groups ($p = 0.804$). There were no significant differences in mortality rates.

Rutland et al. reviewed their 10-year experience with EEA versus transcranial approach for skull base malignancies. This single-institution retrospective review consisted of 30 open approaches versus 30 EEA.²⁸² There were no significant differences in age, sex, T stage, or Kadish stage between groups. GTR for open approach (76.7%) and EEA (90.0%) was not significantly different ($p = 0.30$). Blood loss was 247% higher and LOS was 251% longer in open approaches, which persisted after controlling for age, sex, T stage, tumor volume, and histopathology. Local recurrence rates were higher after open approaches (41.4% vs. 13.3%). The 5-year OS was higher for the EEA group (71.3% vs. 26.7%).

Beswick et al. performed a prospective multicenter cohort study comparing complications rates between EEA and open approaches for SNM treated primarily with

TABLE X.3 Evidence surrounding open versus endoscopic approach for adenocarcinoma.

Study	Year	LOE	Study design	Study groups	Clinical endpoints	Conclusion
Meccariello et al. ²⁵⁹	2016	2	Systematic review	1826 patients from 39 studies EEA (<i>n</i> = 431) Endoscopic-assisted approach (<i>n</i> = 31) Open approach (<i>n</i> = 1270)	1. LOS 2. Local failure 3. Complications	EEA and endoscopic-assisted surgery showed low rates of major complications, lower rates of local failure, and shorter LOS as compared to open approaches
Mortuaire et al. ²⁶⁰	2016	3	Retrospective cohort	43 patients Open (<i>n</i> = 23) EEA (<i>n</i> = 20)	1. LOS 2. DFS	LOS was shorter in the EEA group with similar rates of DFS to open procedures
Grosjean et al. ²⁶⁴	2015	3	Retrospective cohort	74 patients EEA (<i>n</i> = 43) Transfacial resection (<i>n</i> = 31)	1. OS 2. DSS 3. LRC 4. LOS 5. Complications	1. 3-year OS, DSS, and LRC were not different between groups 2. Morbidity was significantly lower with EEA for all criteria 3. EEA group exhibited a shorter LOS
Vergez et al. ²⁶¹	2012	3	Retrospective cohort	48 patients EEA (<i>n</i> = 24) Open (<i>n</i> = 24)	1. OS 2. LOS 3. DFS 4. Complications	1. OS and disease-free rates were not significantly different between approaches 2. Median LOS was significantly shorter in the EEA group 3. The rate of early complications was identical in both groups
Nicolai et al. ²⁶²	2011	3	Retrospective cohort	67 patients EEA (<i>n</i> = 12) EEA with transnasal craniectomy (ERTC, <i>n</i> = 17) Cranioendoscopic (CN, <i>n</i> = 9) External approaches (<i>n</i> = 11) CFR (<i>n</i> = 18)	1. OS 2. Complications 3. LOS	EEA in properly selected patients was associated with improved 3-year OS and a reduction in both complication rate and LOS

Abbreviations: CN, cranioendoscopic; DFS, disease-free survival; DSS, disease-specific survival; EEA, endoscopic endonasal approach; GTR, gross total resection; LOS, length of stay; LRC, locoregional control; OS, overall survival; RFS, recurrence-free survival.

TABLE X.4 Evidence surrounding open versus endoscopic approach for sinonasal sarcoma.

Study	Year	LOE	Study design	Study groups	Clinical endpoints	Conclusion
Gore ²⁶⁵	2018	3	Retrospective cohort	198 patients (EEA vs. open approaches)	1. OS 2. DFS	No significant difference in survival between open and EEA approaches
Guo et al. ²⁶⁶	2014	3	Retrospective cohort	23 patients Open (<i>n</i> = 15) EEA (<i>n</i> = 8)	Mean interval to recurrence	Mean interval of recurrence was not statistically different between open approach and EEA groups

Abbreviations: DFS, disease-free survival; EEA, endoscopic endonasal approach; OS, overall survival.

surgery for curative intent.¹⁴ In this study, the open approach group included endoscopic-assisted open cases (98 EEA vs. 44 open approach). Complication rates were similar between the EEA and open approaches, without

controlling for other factors. Regression analysis showed that the open approach was associated with increased odds of experiencing a complication (OR 3.34; 95% CI: 1.06–11.19). No difference was found in Charlson(–Deyo)

TABLE X.5 Evidence surrounding open versus endoscopic approach for sinonasal mucosal melanoma.

Study	Year	LOE	Study design	Study groups	Clinical endpoints	Conclusion
Hur et al. ²⁷⁹	2019	2	Systematic review and meta-analysis	510 patients from nine studies EEA (<i>n</i> = 232) Open (<i>n</i> = 253) Combined approach (<i>n</i> = 25)	1. OS 2. DSS	1. EEA group exhibited higher OS than open group 2. EEA has similar DFS as open approaches
Almutuawa et al. ²⁷⁷	2020	3	Retrospective cohort	20 patients EEA (<i>n</i> = 10) Open (<i>n</i> = 10)	1. OS 2. Complications	EEA had improved OS compared to open approach and lower risk of death
Lundberg et al. ²⁷⁴	2019	3	Retrospective cohort	58 patients EEA (<i>n</i> = 10) Open (<i>n</i> = 30)	1. DSS 2. LRC	LRC and DSS were comparable between surgical approaches
Yin et al. ²⁶⁸	2019	3	Retrospective cohort	54 patients EEA (<i>n</i> = 27) Open (<i>n</i> = 27)	1. Local recurrence 2. Distant metastasis 3. LOS 4. Intraoperative bleeding 5. Operative time	1. No difference in local recurrence or distant metastasis between surgical approaches 2. EEA had shorter LOS, less blood loss, and shorter operative time compared to open approaches
Cao et al. ²⁶⁷	2017	3	Retrospective cohort	33 patients EEA (<i>n</i> = 15) Open (<i>n</i> = 18)	1. Local control 2. OS 3. DFS	OS, DFS, and local control did not differ by surgical approach
Sayed et al. ²⁷¹	2017	3	Retrospective cohort	72 patients Open maxillectomy (<i>n</i> = 38) CFR (<i>n</i> = 14) EEA (<i>n</i> = 20)	1. RFS 2. OS	Surgical approach was not associated with OS or RFS
Ledderose and Leunig ²⁷⁶	2015	3	Retrospective cohort	22 patients EEA (<i>n</i> = 10) Open (<i>n</i> = 12)	1. DFS 2. RFS 3. LOS 4. Postoperative pain	1. DFS and RFS were not affected by surgical technique 2. LOS was shorter and postop pain was lower in EEA group
Lund and Wei ²⁷⁵	2015	3	Retrospective cohort	115 patients Open (<i>n</i> = 35) EEA (<i>n</i> = 16)	OS	EEA had improved OS compared to open approach
Swegal et al. ²⁷⁰	2014	3	Retrospective cohort	25 patients EEA (<i>n</i> = 12) Open (<i>n</i> = 13)	1. OS 2. DSS 3. LOS 4. Postoperative bleed 5. CSF leak 6. Recurrence	1. Similar survival and morbidity outcomes between EEA versus open approach 2. No difference in complications or LOS between the two approaches
Farber et al. ²⁷⁸	2019	4	Retrospective database (NCDB)	686 patients EEA (<i>n</i> = 317) Open (<i>n</i> = 369)	1. OS 2. LOS 3. Readmission	1. Open approach was associated with longer LOS 2. EEA had higher rates of unplanned readmission 3. Surgical approach did not influence OS

(Continues)

TABLE X.5 (Continued)

Study	Year	LOE	Study design	Study groups	Clinical endpoints	Conclusion
Miglani et al. ²⁷²	2017	4 ^a	Retrospective cohort	22 patients EEA (<i>n</i> = 9) Open (<i>n</i> = 13)	1. Negative margins 2. Complications 3. LOS 4. OS 5. DFS	EEA offers comparable survival outcomes to open surgery with similar rates of complications and negative margins
Won et al. ²⁶⁹	2015	4 ^a	Retrospective cohort	133 patients EEA (<i>n</i> = 59) Combined approach (<i>n</i> = 11) Open (<i>n</i> = 63)	1. Recurrence 2. OS	Endoscopic-inclusive surgical approaches exhibited improved local control and survival
Meng et al. ²⁷³	2014	4 ^a	Retrospective cohort	69 patients Open (<i>n</i> = 41) EEA (<i>n</i> = 28)	OS	OS was similar between surgical approaches

Abbreviations: DFS, disease-free survival; DSS, disease-specific survival; EEA, endoscopic endonasal approach; LOS, length of stay; LRC, locoregional control; NCDB, National Cancer DataBase; OS, overall survival; RFS, recurrence-free survival.

^aLOE downgraded for lack of controlling for confounding factors.

comorbidity index scores between the EEA and open approach groups ($p > 0.05$).

Jiang et al. performed a systematic review and meta-analysis of 23 studies comparing EEA ($n = 653$) versus open approaches ($n = 720$).²⁹⁸ The authors performed a pooled analysis that included 130 EEA and 118 open approach patients. The OS in EEA was 31.7% compared to 21.1% in the open approach group ($p < 0.05$). DFS for EEA was 19.9% and for open surgery was significantly lower at 15.5% ($p < 0.05$). Pooled analysis revealed significant differences in OS, favoring EEA (HR 0.72, 95% CI: 0.58–0.88, $p = 0.002$). However, the quality assessment of the included studies was low and the assessment of certainties was very low. The data consistently suggest that survival outcomes for EEA are comparable or, in some cases, better than the open approach. Data for low-stage tumors are stronger than the data for high-grade tumors.

All studies included in this review compared an open approach to EEA. The results published by most of the studies currently available are limited due to their small sample sizes, which are often unpowered and without adjustment for comorbidities and covariates, and subject to type 2 error. Nearly all utilize retrospective data with some variability in the outcomes measured. There is also selection bias whereby patients undergoing a more minimally invasive approach have more favorable tumor stage, histologic types, and prognostic factors. However, there are some conclusions that can be drawn from the currently available evidence presented in most of these studies (Table X.6).

Open versus endoscopic approach for sinonasal tumors

Aggregate grade of evidence	C (Level 2: one study; Level 3: nine studies; Level 4: 45 studies)
Benefit	Compared to open surgical approaches, endoscopic surgical approaches generally yield reduced morbidity and shorter recovery times with similar oncologic outcomes in low-stage tumors (stage T1–2; Kadish A–B) and certain high-stage tumors (stage T3–4; Kadish C–D)
Harm	Failure to achieve GTR with negative margins in extensive or high-stage tumors, which could lead to tumor progression or invasion of surrounding structures. Potential for higher risk of CSF leak.
Cost	Reduction in cost is possible with EEA related to reduced operative times, shorter hospital LOS, and reduced morbidity.
Benefits–harm assessment	A preponderance of benefit over harm exists for the use of endoscopic surgery approaches in low-stage tumors. For high-stage tumors, benefits of endoscopic surgical approaches when negative surgical margins can be achieved, including reduced morbidity and shorter recovery time, may outweigh potential harms depending on the comfort and experience of the surgical team.

(Continued)

TABLE X.6 Evidence surrounding overall outcomes in open versus endoscopic approach for sinonasal malignancies.

Study	Year	LOE	Study design	Study groups	Clinical endpoints	Conclusion
Jiang et al. ²⁹⁸	2022	2	Systematic review and meta-analysis	1373 patients from 23 studies EEA (<i>n</i> = 653) Open (<i>n</i> = 720)	1. OS 2. DFS	EEA survival was comparable or better than the open approach
Higgins et al. ³¹²	2011	2	Systematic review and meta-analysis	226 patients from 15 studies EEA (<i>n</i> = 56) Open (<i>n</i> = 101) Other (<i>n</i> = 69, not included in analysis)	1. OS 2. DFS 3. LRC	1. EEA is comparable to open approach for low-stage disease 2. In late-stage malignancies, 5-year survival and LRC rates were highly variable in EEA
Lu et al. ³¹³	2019	2	Systematic review and meta-analysis	900 patients from 10 studies EEA (<i>n</i> = 399) Open (<i>n</i> = 501)	1. Complications 2. LOS 3. Recurrence	Compared to open resection, EEA exhibits complications and disease recurrence and may result in a shorter LOS
Caballero-Garcia et al. ²⁹⁴	2022	3	Retrospective cohort	50 patients EEA (<i>n</i> = 25) Open (<i>n</i> = 25)	1. LRC 2. OS 3. PFS 4. Operative time 5. LOS 6. Complications	1. Compared to open approach, EEA improved 3-year LRC, OS, and PFS 2. EEA reduced need for transfusion, surgical time, cost, and LOS
Beswick et al. ¹⁴	2021	3	Prospective cohort	142 patients EEA (<i>n</i> = 98) Open (<i>n</i> = 44, open resection with or without an endoscopic component)	Complications	Compared to EEA, open resection with or without an endoscopic component was associated with increased odds of developing a complication
Rutland et al. ²⁸²	2021	3	Retrospective cohort	60 patients EEA (<i>n</i> = 30) Open (<i>n</i> = 30)	1. GTR 2. Intraoperative blood loss 3. Operative time 4. LOS 5. Complications	EEA had shorter surgeries, lower intraoperative blood loss, and shorter LOS with similar GTR and complication rates
Hagemann et al. ²⁹⁰	2019	3	Retrospective cohort	225 patients EEA (<i>n</i> = 123) Open (<i>n</i> = 102)	1. OS 2. DSS	Similar OS and DSS between EEA and open approaches for low-stage tumors (T1–2) and locally extensive high-stage tumors (T4), with better survival in the EEA group for T3 tumors
Fu et al. ²⁹¹	2017	3	Retrospective cohort	106 patients EEA (<i>n</i> = 15) Open (<i>n</i> = 91)	1. Operative time 2. LOS 3. CSF leak	EEA has a longer operative time, more CSF leaks, and longer ICU stay than the open group without free flap reconstruction
Farquhar et al. ²⁹²	2016	3	Retrospective cohort	124 patients EEA (<i>n</i> = 82) Open (<i>n</i> = 42)	1. OS 2. DFS 3. LOS	EEA may provide improved OS and DFS and shorter LOS
Naunheim et al. ²⁸⁵	2016	3	Retrospective cohort	67 patients EEA (<i>n</i> = 10) Cranioendoscopic resection (<i>n</i> = 12) Open (<i>n</i> = 45)	1. OS 2. DSS 3. Complications	1. OS, DSS, and most complications were similar between approaches 2. Open transfacial incisions predisposed patients to surgical site infection

(Continues)

TABLE X.6 (Continued)

Study	Year	LOE	Study design	Study groups	Clinical endpoints	Conclusion
Saedi et al. ²⁸¹	2014	3	Retrospective cohort	160 patients EEA (<i>n</i> = 72) Open (<i>n</i> = 88)	1. Surgical complications 2. Recurrence 3. OS 4. DFS	1. EEA for SNM can achieve comparable outcomes to conventional CFR if the tumor is early stage 2. No correlation between surgical approach and the rates of recurrence, complications, and survival
Suh et al. ²⁸⁰	2013	3	Retrospective cohort	49 patients EEA (<i>n</i> = 36) Open (<i>n</i> = 13, including endoscopic-assisted approach)	1. Complications 2. DFS 3. OS 4. LOS	1. EEA had fewer surgical and medical complications, shorter LOS, and better DFS 2. OS is similar between EEA and open approaches
Arnold et al. ²⁹⁷	2012	3	Retrospective cohort	83 patients EEA (<i>n</i> = 28) Open (<i>n</i> = 55)	1. DSS 2. RFS 3. Margin status 4. Complications	EEA outcomes are comparable to the open approach for SNM, but with lower complication rates
Parida and Gupta ²⁸³	2008	3	Retrospective cohort	28 patients EEA (<i>n</i> = 13) Open (<i>n</i> = 15)	1. Recurrence 2. Complications	EEA and open maxillectomy approaches had similar disease recurrence and complications
Kim et al. ²⁸⁷	2008	3	Retrospective cohort	46 IP patients EEA (<i>n</i> = 10) Open (<i>n</i> = 36)	1. LOS 2. Operative time	EEA group had lower LOS and operative time
Batra et al. ³¹⁴	2005	3	Retrospective cohort	34 patients EEA (<i>n</i> = 9) Open (<i>n</i> = 25)	1. Complications 2. Recurrence 3. Mortality 4. Operative time 5. LOS	EEA was similar to open approach for complication rate, recurrence rate, mortality, operative time, blood loss, and LOS
Povolotskiy et al. ³¹⁵	2020	4	Retrospective database (NCDB)	1595 patients with non-SCC sinonasal cancer EEA (<i>n</i> = 673) Open (<i>n</i> = 922)	1. LOS 2. OS	Non-SCC sinonasal cancer managed with EEA has a shorter LOS and similar OS to open approach
Abdelmeguid et al. ¹⁸²	2020	4	Retrospective case series	239 patients EEA (<i>n</i> = 167) Endoscopic-assisted combo (<i>n</i> = 72)	1. OS 2. DSS 3. Margin status 4. Intracranial complications 5. CSF leak	1. OS, DSS, negative margins, and rate of intracranial complications were all similar between EEA and combo approaches 2. EEA had descriptively higher rates of CSF leaks
Husain et al. ²⁸⁸	2019	4	Retrospective database (NCDB)	2292 patients EEA (<i>n</i> = 645) Open (<i>n</i> = 1647)	1. 90-day mortality 2. OS	EEA and open approaches had comparable 90-day mortality and 5-year OS
Krischek et al. ²⁸⁶	2014	4 ^a	Retrospective cohort	30 patients EEA (<i>n</i> = 9) Open (<i>n</i> = 16) EEA combined with frontal craniotomy combo (<i>n</i> = 5)	1. GTR 2. Recurrence 3. Complications	Open and EEA had similar proportions of GTR and recurrent disease
Hanna et al. ²⁸⁹	2009	4 ^a	Retrospective cohort	120 patients EEA (<i>n</i> = 93) Open (<i>n</i> = 27)	1. OS 2. DFS	No difference in OS or DFS between approaches

(Continues)

TABLE X.6 (Continued)

Study	Year	LOE	Study design	Study groups	Clinical endpoints	Conclusion
Nicolai et al. ³¹⁶	2008	4 ^a	Retrospective cohort	184 patients EEA (<i>n</i> = 134) Open (<i>n</i> = 50)	DSS	5-year DSS was lower in open approach than EEA
Buchmann et al. ²⁹⁵	2006	4	Retrospective case series	63 patients Open (<i>n</i> = 27) Endoscopic (<i>n</i> = 36)	1. Disease-free status 2. Mortality	Endoscopic techniques are comparable to open techniques in terms of disease-free status and mortality
Castelnuovo et al. ¹³⁹	2006	4 ^a	Retrospective cohort	67 patients EEA (<i>n</i> = 49) Open (<i>n</i> = 18)	1. OS 2. Complications	EEA had better OS and fewer complications

Abbreviations: CFR, craniofacial resection; DFS, disease-free survival; DSS, disease-specific survival; EEA, endoscopic endonasal approach; GTR, gross total resection; LOS, length of stay; NCDB, National Cancer DataBase; OS, overall survival; PFS, progression-free survival; RFS, recurrence-free survival; SNM, sinonasal malignancy.

^aLOE downgraded for lack of controlling for confounding factors.

Value judgments	Current conclusions are primarily based on limited data. Many studies have small sample sizes and cannot adjust for tumor stage, patient comorbidities, covariates, or tumor type. The above recommendations are based on data quality, evaluation of surgical outcomes, outcomes grouped by tumor stage, and systematic reviews that demonstrate consistent findings across many studies. Most studies include a heterogenous grouping of SNM, preventing clear recommendations for approach by tumor type or by tumor location. Larger prospective studies are needed to develop clear recommendations for surgical approach, particularly in late-stage tumors where data on endoscopic approach outcomes are lacking.
Policy level	Recommendation for EEA for low-stage tumors. Option for EEA for high-stage tumors.
Intervention	In most low-stage sinonasal tumors, endoscopic surgery should be considered the first-line surgical approach to reduce morbidity and recovery times while achieving similar oncologic outcomes to open surgery. In advanced-stage tumors (such as T3–4), endoscopic SNM surgery approaches should be considered on a case-by-case basis according to the tumor location, surgeon experience, patient preference, tumor grade, and with consideration of the risk–benefit ratio of alternative treatment options.

G | Approaches to the maxillary sinus

The maxillary sinus is the largest of the paranasal sinuses and is the primary site of a number of malignant and benign tumors, with much of the tumor literature in this area focusing on IP. Historically, approaching maxillary sinus tumors utilized open approaches (e.g., Caldwell-Luc) to gain wide access and good visibility for resection. These open approaches often resulted in significant morbidity, including pain, facial scarring, dental and/or facial numbness, paresthesia, and devitalization of dentition. In the last several decades, there have been many advances in endoscopic transnasal techniques to approach the maxillary sinus, with improved endoscopic access, faster healing, and lesser morbidity. This review examines the primary literature on extended maxillary sinus approaches and compares the clinical outcomes across a variety of maxillary surgical techniques.

Multiple heterogenous studies compare open to endoscopic-assisted and pure endoscopic surgical techniques for maxillary tumor resection (Table X.7). While the granular surgical approaches and extent of tumor involvement varied among publications, the studies that compared endoscopic to open approaches generally found similar rates of recurrence for maxillary IP after both techniques. Moreover, Durucu et al. and Kim et al. demonstrated that endoscopic and endoscopic-assisted techniques, as compared to open approaches, had lower rates of complications and shorter LOS after surgery.^{300,301}

A number of case series were published on the use of isolated maxillary approaches for IP and other tumors involving the maxillary sinus (Table X.8). Recurrence rates

TABLE X.7 Evidence surrounding open versus endoscopic maxillary sinus approaches.

Study	Year	LOE	Study design	Study groups	Clinical endpoints	Conclusion
Lawson and Patel ³¹⁷	2009	3	Retrospective cohort	200 IP patients	Recurrence	<ol style="list-style-type: none"> 1. IP should be addressed endoscopically when possible 2. When access is limited via endoscopic approach, external approaches should be used to ensure complete tumor control
Kim et al. ³⁰¹	2008	3	Retrospective cohort	136 IP patients Endo + endo-assisted (<i>n</i> = 94) Open (<i>n</i> = 42)	<ol style="list-style-type: none"> 1. Recurrence 2. Complications 3. LOS 4. Operative time 	<ol style="list-style-type: none"> 1. Endo-based approaches can be performed in a majority of IP cases, with recurrence rates similar to open approaches 2. Endo-based approaches take less operative time, have shorter LOS, and have fewer complications
Nakayama et al. ³¹⁸	2020	4 ^a	Retrospective cohort	45 IP patients	<ol style="list-style-type: none"> 1. Recurrence 2. Complications 	PLA reduces recurrence and has similar rates of complications in maxillary IP
Yu et al. ³⁰⁹	2018	4 ^a	Retrospective cohort	71 patients with maxillary IP	<ol style="list-style-type: none"> 1. Recurrence 2. Complications 	<ol style="list-style-type: none"> 1. Endoscopic approaches achieved similar or better recurrence and complication than open approaches 2. PLA is a minimally invasive, safe, and effective method for maxillary sinus IP
Nikakhlagh et al. ³¹⁹	2015	4	Retrospective case series	38 IP patients	Recurrence	Endoscopic approaches alone can access most IP tumors and achieve low recurrence rates
Lombardi et al. ³²⁰	2010	4 ^a	Retrospective cohort	212 IP patients Endo (<i>n</i> = 198) Endo + open (<i>n</i> = 14)	Recurrence	Endo and endo-assisted approaches can be tailored to the tumor extent with low IP recurrence rates
Durucu et al. ³⁰⁰	2009	4 ^a	Retrospective cohort	56 IP patients Endo (<i>n</i> = 23) Endo-assisted (<i>n</i> = 14) Open (<i>n</i> = 19)	<ol style="list-style-type: none"> 1. Recurrence 2. Complications 	<ol style="list-style-type: none"> 1. Endo approaches were primarily used in lower stage tumors 2. Endo approaches had low recurrent rates in early-stage tumors 3. Combined internal and external approaches were used in advanced cases and cannot be compared to endoscopic approaches 4. Endo approaches had lower complication rates
Sham et al. ³²¹	2009	4 ^a	Retrospective cohort	27 IP patients	Recurrence	<ol style="list-style-type: none"> 1. 30% patients with maxillary sinus IP had recurrence requiring additional procedures 2. Anterior wall maxillary IP are more likely to recur than posterior locations within the sinus

Abbreviations: IP, inverted papilloma; LOS, length of stay; PLA, prelacrimal approach.

^aLOE downgraded for lack of controlling for confounding factors.

TABLE X.8 Evidence surrounding isolated maxillary sinus approaches for sinonasal tumor resection.

Study	Year	LOE	Study design	Study groups	Clinical endpoints	Conclusion
Lee et al. ³⁰⁶	2020	4	Retrospective cohort	22 IP patients	1. Recurrence 2. Complications	1. The MD technique is effective for resection of primary and recurrent maxillary IPs involving the anterior wall. 2. The MD often eliminates the need for an adjunctive sublabial or transeptal incision while providing exposure for postoperative surveillance.
Stavrakas et al. ³⁰⁸	2021	4	Retrospective case series	22 patients with maxillary sinus tumors	1. Recurrence 2. Complications	1. Endoscopic MD provides excellent exposure to the anterior maxillary sinus as well as the PPF and ITF. 2. Endoscopic MD is associated with low rates of complications and low recurrence rates in a variety of sinonasal pathology.
Wu et al. ³⁰⁵	2018	4	Retrospective case series	28 IP patients	1. Recurrence: 2. Tumor characteristics	1. IPs originating from the maxillary sinus frequently had multifocal attachments, but this did not impact disease recurrence. 2. Maxillary sinus IPs can be effectively managed via a purely endoscopic approach.
Yu et al. ³⁰⁹	2018	4	Retrospective case series	71 maxillary sinus IP patients	1. Recurrence 2. Complications	PLA is a safe and effective method for excising primary or recurrent IP with low postoperative complication and recurrence rates
Suzuki et al. ³²²	2017	4	Retrospective case series	51 IP patients	1. Recurrence 2. Complications	1. PLA was highly effective in resecting maxillary sinus IP. 2. No atrophy was noted in the IT in any patients on follow-up. 3. PLA was associated with few complications.
Wang et al. ³⁰⁴	2017	4	Retrospective case series	22 IP patients	1. Recurrence 2. Complications	MM with an IT-reversing approach is a safe and effective approach for maxillary IP
Dean et al. ³⁰³	2015	4	Retrospective case series	35 IP patients	N/A	MM ± transeptal approach provides excellent surgical access to anterolateral maxillary sinus IPs
Pagella et al. ³⁰⁷	2011	4	Retrospective case series	20 IP patients	1. Recurrence 2. Complications	Endoscopic MM and MD are excellent approaches for maxillary sinus IP offering low recurrence rates and minimal complications
Lund et al. ⁶	2010	4	Retrospective case series	33 IP patients	1. Recurrence 2. Complications	MM with or without NLD sacrifice is an effective and safe method for resecting more advanced maxillary sinus IPs

Abbreviations: IP, inverted papilloma; IT, inferior turbinate; ITF, infratemporal fossa; MD, modified Denker maxillectomy; MM, medial maxillectomy; NLD, nasolacrimal duct; PLA, prelacrimal approach; PPF, pterygopalatine fossa.

ranged from 0% to 12.5% for maxillary IP tumors. The most common approach was endoscopic medial maxillectomy with or without trans-septal access and transection of the nasolacrimal duct. Liu et al., Dean et al., Wang et al., and Wu et al. each reported small series of IP cases, together totaling 118 patients treated with endoscopic medial maxillectomy with only three recurrences (2.5%) during the duration of study.^{302–305} Reported complications were rare (range 0%–17%) and included dry nose, epistaxis, numbness of the front maxillary teeth, and epiphora.

Other common maxillary tumor approaches include endoscopic modified Denker maxillectomy and prelacrimal approaches. Both allow the surgeon to gain better access to the anterior maxillary wall and the anterior inferior and anterior lateral disease. Additionally, these approaches provide improved angles for accessing the pterygopalatine and infratemporal fossa in endoscopic surgery. In this review, we are unable to draw clear conclusions about the advantage of one approach over the other for maxillary sinus tumors. Lee et al., Pagella et al., and Stavrakas et al. all reported on the endoscopic modified Denker approach.^{306–308} In the combined 59 patients, two patients developed recurrent tumors during the course of study. The permanent complications reported after modified endoscopic Denker included bleeding requiring surgical treatment ($n = 1$), epiphora ($n = 2$), and facial numbness ($n = 3$). Data on the prelacrimal approach also demonstrate low rates of tumor recurrence and complications. Yu et al. describe a case series of 71 patients with Krouse stage T3 IP resected via the prelacrimal approach, with a 7% recurrence rate and 7% of patients experiencing facial numbness or mild alar collapse.³⁰⁹ Suzuki et al. also reported similar favorable outcomes with the prelacrimal approach for IP with a 2% recurrence rate and 14% incidence of transient upper lip numbness.³¹⁰

The available literature is limited by significant heterogeneity of the population, tumor type/extent, and surgical approach. This is compounded by the lack of prospective data, variable follow-up timeframe, and inconsistency of variables collected by the researchers. Moreover, most of the studies looking at clinical outcomes after maxillary surgical approaches occur in benign tumors, which may not be translatable to malignant tumors in the same location. Therefore, only the most basic of conclusions can be drawn about surgical outcomes from areas of consistency across many studies.

In conclusion, endoscopic maxillary sinus approaches appear to have similar or better rates of recurrence in IP and other benign tumors to the recurrence rates for open approaches. It is not possible to advocate for one approach over another. It is also not clear whether the experience in

benign tumors translates to a similar experience in more aggressive malignancies. For instance, the presence of maxillary sinus floor infiltration (involving mucosa/bone) is a known negative prognosticator for primary maxillary sinus malignancies.³¹¹ Thus, this is currently up to the discretion of the surgeon to tailor the surgery to the tumor pathology, location, and extent to ensure the best patient outcomes. Furthermore, this review highlights multiple gaps in the literature where prospective cohort studies and randomized controlled trials to compare surgical approaches could lead to better understanding of when to employ specific open and endoscopic maxillary surgical approaches.

Extended endoscopic approaches to the maxillary sinus

Aggregate grade of evidence	C (Level 4: 12 studies)
Benefit	Compared to open maxillary surgical approaches, endoscopic maxillary surgical approaches generally yield improved morbidity and shorter recovery times with comparable or even improved outcomes based on the IP literature.
Harm	Failure to achieve GTR with negative margins in extensive or high-stage tumors, particularly those with bony maxillary wall and/or palatal invasion, which could result in tumor progression or surrounding structure invasion.
Cost	Reduction in cost is possible with EEA related to reduced operative times, shorter hospital LOS, and reduced morbidity.
Benefits–harm assessment	Preponderance of benefits over harms.
Value judgments	Current conclusions are primarily based on limited data focused on IP resection. It is unclear how these data will translate to treatment of other primary maxillary neoplasms, including malignancies, especially those with bony invasion. Moreover, many studies have small sample sizes and cannot adjust for patient comorbidities, covariates, or tumor stage. Larger prospective cohort studies are needed to develop clear recommendations for maxillary surgical approach in malignancies.
Policy level	Recommendation for EEA for IP and other benign lesions. Option for EEA for malignant tumors based upon anatomical involvement and at the discretion and comfort of the surgeon.

(Continued)

Intervention	EEA should be the first-line surgical technique for the resection of most IP confined to the maxillary sinus to reduce morbidity and recovery times while achieving similar outcomes to open surgery. Endoscopic maxillary surgical approaches should be considered on a case-by-case basis for malignancies and other benign tumors in the maxillary according to the tumor location, surgeon experience, patient preference, and tumor grade, with consideration of the risk–benefit ratio of alternative treatment options.
--------------	--

XI | MANAGEMENT OF THE ORBIT

Benign and malignant pathology of the nasal cavity, paranasal sinuses, and skull base often involves the orbit, which can significantly impact surgical management options. Malignancies of the sinonasal cavity have been shown to involve the orbit to some degree in 40%–80% of cases.^{174,175,323,324} Historically, orbital invasion portends a worse overall prognosis with respect to RFS and DFS; however, given its critical function, there remains some debate over the optimal management of sinonasal tumors with orbital involvement.^{175,177,325,326} With advancements in surgical techniques, improved understanding of orbital anatomy, and innovation in nonsurgical treatments, strategies for orbital management in treating sinonasal tumors have continued to evolve. This section presents the current evidence on general principles in management of cases of orbital involvement from sinonasal and skull base tumors, as well as growing experience in minimally invasive endoscopic approaches to orbital management in the treatment of sinonasal tumors. Histopathology-specific management of specific orbital pathologies is covered in Section XIX.

A | Orbital structures and grading orbital invasion

Given the proximity of the orbital compartment to the nasal cavity and paranasal sinuses, it is imperative to understand the orbital structures and contents in considering surgical management. Though many of the specific nuances of orbital anatomy is beyond the scope of this section, this represents an overview of the relevant elements when considering orbital management.^{327–331} The orbit is a conical-shaped cavity that is encased by a sheath of periorbita, which is a connective tissue membrane that inserts at the orbital apex and serves as a support structure for

blood supply to the orbital bones. Orbital contents include the globe, extraocular muscles (EOMs), and a myriad of neurovascular structures contained within the fat-filled space. The EOMs, arising from attachment at the orbital apex, divide the orbital compartment into intraconal and extraconal spaces, wherein the intraconal space contains the complex neurovascular network leading to the globe including the optic nerve. With regard to the medial and inferior extraconal versus intraconal spaces, these regions are of notable importance when considering orbital invasion from sinonasal tumors, since the depth of invasion often dictates the feasibility of surgical approach.^{327,328,332} Lastly, though the bones of the orbit and periorbita serve as robust barriers to orbital invasion, orbital involvement from sinonasal tumors can proceed via direct invasion, extension through existing foramina or fissures, and perineural spread.¹⁶⁴ It is worth noting that most sinonasal tumors gain access into the orbit in the medial aspect, where the lamina papyracea of the ethmoid bone may be breached.

There has been a progression of grading systems for staging orbital involvement of sinonasal tumors (Table XI.1). In 1996, McCary et al. graded orbital involvement from A to D, with A classifying tumors adjacent to or abutting the orbit and D classifying tumors with full-thickness periorbital invasion.³²⁵ Subsequently in 2005, Iannetti et al. graded orbital involvement from 1 to 3, with grade 1 being erosion of the medial orbital wall and grade 3 displaying invasion of EOMs, optic nerve, or eyelid skin.³²⁴ In 2019, Turri-Zanoni et al. expanded on the criteria laid forth by Iannetti et al. by including four grades of orbital invasion, with grade 4 defined by involvement of the orbital apex.¹⁶⁵

Clinically, although ocular symptoms such as epiphora, diplopia, and visual changes can indicate orbital involvement, the absence of clinical findings does not necessarily rule out orbital invasion, which emphasizes the importance of imaging. Both CT and/or MRI of the paranasal sinuses and orbits are critical for delineating the presence and degree of orbital invasion.^{333,334} Though CT is often the preferred assessment tool for evaluation of the bony orbital compartment, determining the status of the periorbita and extraconal fat is often critical in determining feasibility of orbital preservation. Normal periorbital lining is hypointense on T1 and T2 sequences on MRI, and can often be considered intact in cases where this lining is preserved and a visible delineation between tumor and orbital fat is seen.³³³ Unfortunately, despite the substantial improvement in MRI and CT resolution since the mid-1990s, imaging can sometimes overestimate EOM or intraconal involvement, highlighting the importance of intraoperative examination and use of frozen sections.^{220,325,333,334}

TABLE XI.1 Proposed grading systems for staging orbital involvement by sinonasal tumors.

Study	Year	Grading scheme
McCary et al. ³²⁵	1996	Grade A: Tumor adjacent to orbit, no bony erosion Grade B: Tumor erosion of the orbital wall without ocular bulb displacement Grade C: Tumor infiltration of the orbital wall without periorbital invasion Grade D: Tumor with invasion of the periorbital
Iannetti et al. ³²⁴	2005	Grade 1: Erosion or destruction of medial orbital bone Grade 2: Extraconal invasion of periorbital fat Grade 3: Invasion of extraocular muscle (EOM), optic nerve, or eyelid skin
Neel et al. ³⁴¹	2017	Grade 1: Tumor adjacent to orbit, no significant periorbital involvement Grade 2: Tumor invasion of the periorbital layer Grade 3: Invasion of the extrinsic ocular muscles, optic nerve, ocular bulb Grade 4: Tumor invasion of the nasolacrimal sac, eyelids Grade 5: Tumor invasion of the cavernous sinus, optic canal, or intracranial extension
Turri-Zanoni et al. ¹⁶⁵	2019	Grade 1: Orbital bone erosion Grade 2: Invasion of the periorbital layer and/or periorbital fat Grade 3: Invasion of the extrinsic extraocular muscles, optic nerve, or ocular bulb Grade 4: Involvement of the orbital apex

B | Orbital preservation versus orbital exenteration

In the era of multimodal therapy and minimally invasive surgical corridors, there is a push to improve perioperative patient morbidity while maintaining oncologic outcomes. Given the significant morbidity from either orbital exenteration or a nonfunctional preserved eye, there has been extensive study on the long-term outcomes of patients undergoing orbital preservation, orbital exenteration, or limited periorbital or orbital resection when sinonasal tumors involve the orbit (Table XI.2).^{164,165,220,323–326,335–344} Orbital preservation is defined as maintaining the globe with the goal of preserving a functional eye and associated orbital contents. Orbital exenteration, also known

as orbital clearance, is defined by complete removal of the orbital contents up to the orbital apex and, when appropriate, removal of the eyelid skin or bones of the orbit.^{342,344,345} Lastly, approaches for limited resection, which falls under orbital preservation surgery, include either resection of involved periorbital with a visual margin or limited resection of extraconal orbital contents. These approaches have been studied in relation to OS and DFS, as they often balance functional outcomes with macroscopic tumor clearance.

In the late 1990s, McCary et al. and Carrau et al. described some of the foundational literature on selective orbital preservation versus exenteration for cases of SNM involving the orbit.^{323,325} Through a retrospective, single-institutional case review on malignant sinonasal neoplasms with orbital involvement, McCary et al. found that selective periorbital resection with adjuvant chemoradiation was an acceptable alternative to orbital exenteration with respect to local control (i.e., orbital recurrence) rates, even in cases where there is orbital bony erosion on imaging.³²⁵ With regard to OS, Carrau et al. found that orbital exenteration does not increase survival odds in malignant sinonasal tumors without full-thickness involvement of the periorbital based on an institutional case series.³²³ Since these discoveries, other retrospective case series have confirmed and expanded on these original findings on indications when orbital preservation may be more appropriate.^{164,165,220,339} Of note, selective periorbital resection is often a defining element in orbital preservation surgery and, if attainable based on pathology, allows for oncologic control with functional visual outcomes.^{164,220,325,337–339} Importantly, both Imola et al. and Essig et al. found that patients who underwent orbital preservation surgery in cases of orbital bone and/or periorbital involvement (without orbital fat or EOM involvement) demonstrated stable visual acuity in the majority of cases.^{337,338} Specifically, in Imola et al. and Essig et al., 91% (49/54) and 97% (35/36) of patients, respectively, who undergo orbital preservation surgery maintain a functional, seeing eye postoperatively.^{337,338} Conversely, other studies have confirmed indications for more aggressive orbital interventions, such that patients with tumors involving the EOMs, optic nerve, or intraconal space have improved OS and DSS when orbital exenteration is performed compared to orbital preservation.^{164,165,220,324,339,343}

Although much of the available literature and recommendations are based on level 4 evidence, with the majority of studies being retrospective case series, two systematic reviews and several literature reviews exist on the topic of management of orbital involvement in SNM.³⁴² Based on the two studies with the highest LOE, orbital preservation can be considered in cases of purely periorbital

TABLE XI.2 Evidence surrounding orbital preservation versus orbital exenteration.

Study	Year	LOE	Study design	Study groups	Clinical endpoints	Conclusion
Castelnuovo et al. ³³⁵	2021	2	Systematic review	21 studies Benign lesions (<i>n</i> = 84) Malignant lesions (<i>n</i> = 2449)	1. OS 2. DSR	1. Benign tumors allow for invariable orbital sparing 2. Malignant tumors allow for orbital sparing pending the extent of infiltration and the grading of the tumor 3. Multimodal therapy is typically required in malignant tumors
Muscatello et al. ³⁴⁰	2016	2	Systematic review	14 studies (<i>n</i> = 3146) Group A—Orbital bone erosion Group B: Periorbital involvement Group C: Soft tissue involvement	1. OS 2. DFS	1. Orbital exenteration is not necessary with bone erosion alone, optional in cases of periorbital involvement 2. In cases of limited soft tissue involvement, can consider orbital preservation if fat can be macroscopically cleared
Carrau et al. ³²³	1999	2	Systematic review and meta-analysis with retrospective case series	Group A: Orbital bone invasion without Soft Tissue invasion (<i>n</i> = 37) Group B: Orbital soft tissue invasion (<i>n</i> = 21)	OS	Orbital exenteration does not increase survival odds, in tumors where there is no full thickness invasion of the periorbita
Safi et al. ³⁴³	2017	3	Retrospective cohort	Orbital invasion beyond the periosteum treated with either exenteration (<i>n</i> = 29) or preservation with adjuvant radiation (<i>n</i> = 23)	OS	1. 5-year OS was significantly higher in patients with exenteration compared to those who had orbital preservation with adjuvant radiation 2. Exenteration only recommended if curative intent possible
Lisan et al. ³³⁹	2016	3	Retrospective cohort	Surgical (<i>n</i> = 58) versus nonsurgical treatment (<i>n</i> = 25) options based on degree of orbital invasion Orbital exenteration versus orbital preservation dictated by radiographic examination for orbital invasion	1. LR 2. OS 3. Distant metastases 4. Functional orbital and globe outcomes, including diplopia, epiphora, and visual loss	1. Greater OS in patients treated with surgery than those who did not undergo surgery 2. Similar local and orbital control rates in those undergoing preservation versus exenteration 3. Only patients with grade 2 or lower underwent orbital preservation
Imola and Schramm ³³⁸	2002	3	Retrospective cohort	Orbital preservation cohort (<i>n</i> = 54) versus orbital exenteration cohort (<i>n</i> = 12)	1. OS 2. LR 3. Eye function in preservation cohort	1. Long-term survival outcome was mostly related to tumor histology, and not related to type of orbital surgery 2. Local recurrence and eye functionality were not affected by orbital preservation

(Continues)

TABLE XI.2 (Continued)

Study	Year	LOE	Study design	Study groups	Clinical endpoints	Conclusion
Ferrari et al. ²²⁰	2021	4	Retrospective case series	Cohort was divided into six different groups (A–F) based on radiologic characteristics of orbital invasion using Iannetti ³²⁴ and Turri-Zanoni ¹⁶⁵ criteria Orbital preservation surgery ($n = 76$) or orbital ablation ($n = 47$)	1. Surgical management (orbital sparing, orbital clearance/exenteration) 2. Diagnostic accuracy of MRI in determining staging of orbital invasion	1. Orbital sparing surgery can be considered when there is no intraconal fat or EOM disease 2. MRI can often mis-stage orbital invasion particularly in case of prior surgery or CRT 3. Involvement of extraconal fat shows decreased DFS
Li et al. ¹⁶⁴	2020	4	Retrospective case series	Grade I: Orbital bone erosion ($n = 27$) Grade II - Invasion of extraconal fat ($n = 36$) Grade III - Involvement of EOMs, eye globe, orbital apex, or optic nerve ($n = 30$)	1. OS 2. LRFS 3. 5-year PFS	Grade III orbital invasion was associated with significantly worse OS, LRFS, and PFS, but did not contraindicate orbit-preserving surgery after RT
Turri-Zanoni et al. ¹⁶⁵	2019	4	Retrospective case series	Grade 1: Orbital bone erosion ($n = 44$) Grade 2: Invasion of the periorbital layer and/or periorbital fat ($n = 46$) Grade 3: Invasion of the extrinsic ocular muscles, optic nerve, ocular bulb ($n = 49$) Grade 4: Involvement of the orbital apex ($n = 24$)	1. OS 2. DFS	1. Orbital invasion is a significant prognostic factor 2. DFS and OS relatively unaffected by degree of invasion, implying organ preservation is critical when possible 3. Induction chemo can downstage tumors
Christianson et al. ³³⁶	2015	4	Retrospective case series	Single cohort ($n = 41$) separated into orbital invasion categories: (1) Loss of fat plane between tumor and EOMs. (2) Irregular, nodular tumor margin along the periorbita. (3) Invasion of EOMs (4) Invasion of the optic nerve	1. Analysis of operative techniques 2. LR	1. Orbital involvement excluding categories 3 and 4 was managed with orbital preservation 2. No significant increase was seen in local or regional recurrence 3. Local control was key in treatment

(Continues)

TABLE XI.2 (Continued)

Study	Year	LOE	Study design	Study groups	Clinical endpoints	Conclusion
Essig et al. ³³⁷	2007	4	Retrospective case series	All patients underwent craniofacial resection of sinonasal tumor with orbital preservation and preop RT with or without chemotherapy (<i>n</i> = 59)	Visual and ophthalmologic outcomes pre- and postsurgery	<ol style="list-style-type: none"> 1. Most common pretreatment symptoms were motility issues, afferent defects, and eyelid malposition 2. Using functional scale previously established, 35 patients of the 36 available for long-term follow-up retained functional vision with mild impairment
Iannetti et al. ³²⁴	2005	4	Retrospective case series	Ethmoidal sinus tumors (<i>n</i> = 29): Grade 1: Orbital bone erosion Grade 2: Invasion of periorbital fat Grade 3: Invasion of EOMs or orbital apex	<ol style="list-style-type: none"> 1. OS 2. DSR 	Orbital exenteration demonstrates improved local control and OS rate in patients with grade 3 orbital invasion
McCary et al. ³²⁵	1996	4	Retrospective case series	<p>Group A: Tumor abutting the orbit but did not erode or thin the bone (<i>n</i> = 8)</p> <p>Group B: Orbital bone erosion without globe displacement (<i>n</i> = 5)</p> <p>Group C: Orbital bone erosion with globe displacement but no periorbital invasion (<i>n</i> = 13)</p> <p>Group D: Tumor invading the orbit with periorbital invasion. (<i>n</i> = 7)</p>	<ol style="list-style-type: none"> 1. OS 2. LR 	Selective periorbital resection with preoperative radiotherapy ± adjuvant chemotherapy is an acceptable alternative to orbital exenteration, in Groups A–C

Abbreviations: CRT, chemoradiation therapy; DFS, disease-free survival; DSR, disease specific recurrence; EOM, extraocular muscle; LR, local recurrence; LRFS, locoregional failure/recurrence-free survival; MRI, magnetic resonance imaging; OS, overall survival; PFS, progression-free survival.

involvement or if extraconal fat can be macroscopically cleared from neoplastic pathology.^{335,340} Additionally, as noted by Turri-Zanoni et al., neoadjuvant chemotherapy or RT can often downstage some locally advanced SNM and may impact consideration for orbital preservation.¹⁶⁵ Lastly, it should be highlighted that MRI can often overestimate or upstage orbital invasion, particularly in cases of prior surgery or CRT.^{220,336} Thus, it is very important to clinically assess orbital involvement at the time of surgery in situations where the indications for orbital exenteration are not fully clear based upon preoperative imaging.^{220,336} To date, there are no randomized controlled trials (RCTs) evaluating orbital clearance versus orbital preservation

surgery and its impact on locoregional recurrence, OS, and eye function. Future directions for research could be targeted at reaching consensus, through multi-institutional collaborative study, on a single grading schema for orbital invasion that would drive consistent surgical and non-surgical management. The present literature suggests that significant consideration should be given to orbital preservation surgery based on both clinical and radiographic parameters, and that multimodal therapy is critical given its impact on modifying orbital invasion staging in the perioperative setting.

Aggregate grade of evidence: C (Level 2: three studies; Level 3: three studies; Level 4: seven studies)

C | Management of the nasolacrimal system and role of dacryocystorhinostomy

Management of the nasolacrimal system, including the nasolacrimal duct (NLD) and consideration of dacryocystorhinostomy (DCR), is an important consideration when sinonasal masses affect the orbit and paranasal sinuses. A few important concepts arise when discussing the management strategies for the nasolacrimal system: (1) oncologic principles when tumor involves the NLD and lacrimal sac and (2) the role of a formal DCR or NLD stenting at the time of surgery to prevent postoperative dysfunction. Regarding sinonasal tumor involvement of this region, there are no well-controlled studies or retrospective reviews specifically on the role of resection of the nasolacrimal system in these cases, though oncologic principles should be applied regardless. To this end, complete resection of the NLD and/or the lacrimal sac may be performed depending on extent of tumor involvement.

While there is a large body of literature detailing management of the nasolacrimal system in the setting of IP and when endoscopic medial maxillectomies (EMMs) are performed, there is a paucity of peer-reviewed publications examining outcomes of sinonasal tumors specifically involving the orbit (Table XI.3).^{320,346–348} In fact, these have often been exclusionary criteria in many studies. As the number of EMMs performed has increased, and with increasing availability of powered endoscopic instrumentation, the literature has become more informative on the reality that sharp transection of the NLD during EMM for benign sinonasal tumors will generally result in duct patency, and most cases do not require a formal DCR or stenting.^{320,346–348} Additionally, while novel techniques like total duct preservation are of technical interest, the rate of posttreatment epiphora when performing EMM is sufficiently low to obviate performing such techniques, ranging from 0% to 15% following EMM in most reports.^{310,346–349} One major caveat to this approach in the setting of SNM, however, is the potential for NLD scarring post-RT. Thus, if postoperative RT is planned or likely, this may factor into the decision-making with regard to DCR or stenting at the time of surgery, though further investigation is needed on this topic.

Aggregate grade of evidence: C (Level 3: two studies; Level 4: two studies)

D | Advancements in endoscopic orbital approaches and role for open orbital approaches

In the past decade, significant advances in EEA to the orbit have revolutionized the treatment paradigm when con-

sidering orbital dissection. To date, multiple clinical and anatomic studies have been performed to better characterize the endoscopic corridors in approaching both extraconal and intraconal orbital pathology.^{328–332} Through the use of angled endoscopes and novel endonasal instrumentation, endoscopic dissection of periorbital tissue allows for improved visualization and delineation of the periorbita, EOMs, and intraconal neurovascular structures, facilitating tumor resection and orbital preservation surgery.^{328–332} Importantly, bimanual dissection via the two-surgeon, endonasal approach, as employed for endoscopic skull base surgery, has also greatly impacted our ability to more effectively chase disease beyond the periorbita.

With regard to comparing endoscopic versus open craniofacial surgery, there have been several studies evaluating the long-term outcomes and indications for endoscopic versus open surgery for SNM.^{312,350,351} For sinonasal tumors with orbital invasion, there have been limited studies directly comparing endoscopic approaches versus open techniques. In most cases, the location of the tumor within the sinonasal cavity and extent of invasion with respect to the orbit and extraconal structures impact consideration for the feasibility of the endoscopic approach for orbital management. Based on descriptions provided above and orbital grading schema described by Turri-Zanoni et al., the authors propose that grade 1 orbital involvement is generally amenable to the endoscopic approach.¹⁶⁵ Grade 2 orbital invasion with periorbital tumor invasion or involvement of extraconal fat often requires resection of involved periorbital tissue and fat, which can be accomplished endoscopically, depending on the type of pathology and the experience of the surgeon with the endoscopic orbital approach. In contrast, grades 3 and 4 orbital invasion generally will require open approaches given the potential need for orbital exenteration in many instances and dissection of the orbital apex in grade 4 orbital invasion.^{165,324} Overall, when considering endoscopic versus open techniques, a robust multidisciplinary collaborative effort is strongly advocated for the management of sinonasal tumors with orbital involvement. Given the relative novelty and nuances in operative technique, endoscopic orbital approaches in orbital preservation surgery require detailed knowledge of the endoscopic corridor and experience with manipulating orbital structures through endonasal technique.^{165,331,336,352}

Lastly, with advancements in endoscopic instrumentation and improved understanding of orbital anatomy with respect to endonasal approaches, transorbital endoscopic (TOE) approaches and transorbital neuroendoscopic surgery for the management of sinonasal and skull base pathology are now adopted by many centers and have continued to evolve (Table XI.4).^{353–357} Though many

TABLE XI.3 Evidence surrounding management of the nasolacrimal system and role of dacryocystorhinostomy.

Study	Year	LOE	Study design	Study groups	Clinical endpoints	Conclusion
Rotsides et al. ³⁴⁷	2019	3	Retrospective cohort	All patients underwent endoscopic medial maxillectomy with NLD transection (<i>n</i> = 13) versus NLD marsupialization (<i>n</i> = 16)	Rate of postop epiphora	Overall, very low rate of epiphora in either group, and no difference noted between transection and marsupialization
Sadeghi and Joshi ³⁴⁸	2012	3	Prospective cohort	Endoscopic medial maxillectomy with concurrent DCR (<i>n</i> = 5) versus without DCR (<i>n</i> = 7)	Rate of postop epiphora	<ol style="list-style-type: none"> 1. No significant difference between maxillectomy with and without DCR with respect to epiphora 2. Concurrent DCR not indicated during endoscopic medial maxillectomy and NLD transection
Lombardi et al. ³²⁰	2011	4	Retrospective case series	All patients either went purely endoscopic or combined open/endoscopic resection of sinonasal IP (<i>n</i> = 212)	<ol style="list-style-type: none"> 1. Rate of postop epiphora 2. Tumor recurrence 	<ol style="list-style-type: none"> 1. During endoscopic procedures, NLD stenting is not required 2. No increased incidence of epiphora 3. Recurrence most common within the first 2 years postoperatively
Imre et al. ³⁴⁶	2010	4	Retrospective case series	All patients underwent endoscopic medial maxillectomy with transection of the NLD (<i>n</i> = 12)	Rate of postop epiphora	<ol style="list-style-type: none"> 1. No evidence of epiphora postoperatively 2. Concurrent DCR or NLD may not be required after medial maxillectomy

Abbreviations: DCR, dacryocystorhinostomy; NLD, nasolacrimal duct.

TOE approaches are characterized for multiportal surgery in the management of intracranial tumors, with respect to sinonasal tumors, orbital transposition and periorbital suspension in TOE surgery were described for the management of frontal sinus tumors.^{358,359} Through retrospective and prospective case series done by Karligkiotis et al. and Tilak et al., respectively, periorbital suspension or orbital transposition allows for improved access to far lateral and superior frontal sinus tumors through a combined transnasal and transorbital corridor with minimal orbital and globe morbidity.^{358,359}

Aggregate grade of evidence: C (Level 4: three studies)

Orbital management in the setting of sinonasal tumor pathology is a critical component of surgical planning and has continued to evolve with improvements in anatomical understanding and endoscopic instrumentation. Further investigation should target the specific roles of endoscopic and open craniofacial techniques when considering surgery in the setting of orbital involvement by sinonasal tumors.

XII | MARGIN ANALYSIS

An essential tenet of oncologic surgery is achieving negative margins whenever possible. For sinonasal neoplasms, this is true for malignancies, and may apply to some benign tumors such as IP.^{106,130,135,140,160,174,181,186,240,241,243,254,360–377}

Numerous studies have shown an association between negative surgical margins and improved recurrence and survival in SNM, underscoring the practical importance of this concept (Table XII.1).^{106,130,140,160,161,174,181,186,240,241,243,254,360–367,370–378}

Several considerations factor into the process of obtaining negative margins including the optimal techniques, location and size of margins, role of frozen section analysis, and when to defer to permanent sections upfront.

When endoscopic approaches were first introduced as a potential technique for tumor removal, this was met with concerns that endoscopic approaches cannot achieve en bloc resections and were therefore not oncologically sound. Certainly, it is the case that endoscopic resections are more likely to be piecemeal

TABLE XI.4 Evidence surrounding advancements in endoscopic orbital approaches and role for open orbital approaches.

Study	Year	LOE	Study design	Study groups	Clinical endpoints	Conclusion
Tilak et al. ³⁵⁹	2022	4	Retrospective case series	All patients underwent endoscopic endonasal surgery with endonasal periorbital suspension for access to pathology of the lateral frontal sinus ($n = 30$)	1. Orbital/visual outcomes 2. Successful removal of targeted lesion or skull base reconstruction	1. No intraoperative or postoperative orbital complications were encountered with normal vision postop 2. Complete removal was obtained in all cases of tumor resection
Ramakrishna et al. ³⁵⁵	2016	4	Retrospective case series	All patients ($n = 45$) underwent combined endonasal and TONES for sinonasal tumors	1. Orbital/visual outcomes 2. Successful tumor resection	1. TONES associated with minimal morbidity including low risk of visual loss or diplopia postoperatively 2. High success for complete tumor resection
Karligkiotis et al. ³⁵⁸	2015	4	Retrospective case series	All patients ($n = 24$) underwent an endoscopic endonasal surgery with endonasal orbital transposition for access to the far-lateral frontal sinus	1. Orbital/visual outcomes 2. Successful removal of targeted lesion	1. Complete tumor removal was obtained in all cases of IP and fibro-osseous lesions, and all mucoceles resolved 2. No intraoperative or postoperative orbital complications were encountered with normal visual outcomes

Abbreviation: TONES, transorbital neuroendoscopic surgery.

resections. However, studies have demonstrated endoscopic tumor resection to be oncologically equivalent to open en bloc resections, without any significant differences in survival metrics or the ability to obtain negative margins (Table XII.2).^{135,182,254,268,272,297,312,361,379,380} Additionally, endoscopic surgery allows for excellent visualization of the sinonasal region, a limitation with open approaches due to the inherent anatomy of the paranasal sinuses, skull base, and orbit. The endoscope not only provides magnified visualization, but also better illumination and range of motion than the operating microscope.^{182,316,381} Further, endoscopic approaches have been shown to have lower morbidity and hospitalization time than open approaches.^{278,280,297,314}

Endoscopic endonasal resection of sinonasal tumors typically begins with tumor debulking. This, alongside dissection of uninvolved sinuses, allows for visualization to assess the extent of the tumor.^{140,316,382} Some authors recommend a centripetal dissection moving from the periphery or free edge of the tumor toward the epicenter/origin site.³¹⁶ Ideally, circumferential exposure around the site of tumor origin or attachment can be achieved, allowing for clear visualization of the gross tumor margins, key anatomical landmarks, and improved planning of resection margins.

A | Techniques

Some authors prefer to sample margins prior to tumor resection, while others complete margin sampling after resection.^{140,382,383} In an example of the former, following identification of the tumor attachment site, Nakamura et al. favor a 6- to 8-point biopsy of tissue 1 cm from the macroscopic tumor margin for malignant tumors.¹⁴⁰ Once negative margins are confirmed, mucosal incisions for resection of the tumor are made in pathologically confirmed tumor-negative areas.¹⁴⁰ Typically, these margins are sent for intraoperative frozen section analysis. Aside from the attachment site, margins must be cleared circumferentially around the tumor as dictated by the tumor's three-dimensional anatomy.

Alternatively, margins are taken from the periphery of the tumor resection site following identification of the tumor attachment. Chiu et al. resected tumors with a 1-cm margin of normal mucosa around the tumor attachment.²⁸⁰ There is a paucity of information regarding the specific size of margins for SNM. While there is no consensus for adequate margins, some authors define adequate margins as ≥ 5 mm.^{140,272,384,385} This appears to be extrapolated from the head and neck literature.^{140,386–388} Complicating the consensus on what constitutes an ade-

TABLE XII.1 Evidence surrounding margin analysis for sinonasal tumors.

Study	Year	LOE	Study design	Study groups	Clinical endpoints	Conclusions
Adenocarcinoma						
Bignami et al. ³⁶³	2018	4	Retrospective case series	Patients with non-ITAC with PM (<i>n</i> = 2) versus NM (<i>n</i> = 20)	1. 5-year OS 2. 5-year DSS 3. 5-year RFS	1. 5-year OS and DSS were 100% for NM versus 50% ± 3.54% for PM 2. NM group had a better RFS 3. Margins were an independent prognostic factor for OS
Schreiber et al. ³⁷⁴	2018	4	Case-control	Patients who underwent either uEEATC (<i>n</i> = 27) or bEEATC (<i>n</i> = 27, control) for ITAC with PM (<i>n</i> = 3) versus NM (<i>n</i> = 51)	1. OS 2. DFS 3. RFS	Margins status associated with OS and DSS
Antognoni et al. ³⁶²	2015	4	Retrospective case series	Patients with ITAC with PM (<i>n</i> = 7) versus NM (<i>n</i> = 23)	1. 5-year OS 2. 5-year DFS	Margin status was significantly associated with 5-year OS and 5-year DFS
Hordijk and Brons ³⁸⁹	1985	4	Retrospective case series	Patients with SCC or adenocarcinoma of the maxillary sinus with PM (<i>n</i> = 20) versus NM (<i>n</i> = 44)	LR	LR detected in 15 out of 20 patients with PM versus one out of 44 patients with NM
Adenoid cystic carcinoma						
Shay et al. ³⁷⁵	2020	4	Retrospective database review (NCDB)	Patients with ACC with PM (<i>n</i> = 140) versus NM (<i>n</i> = 381)	OS	MS was a predictor of OS
Volpi et al. ¹⁰⁶	2019	4	Retrospective case series	Patients with ACC treated with radical surgical intent with PM (<i>n</i> = 7) versus NM (<i>n</i> = 27)	5-year OS and DSS	5-year OS and DSS were both 94% ± 6% for NM versus 42% ± 3% for PM
Trope et al. ³⁷⁶	2019	4	Retrospective database review (NCDB)	Patients with ACC with PM (<i>n</i> = 259) versus NM (<i>n</i> = 225)	OS	PM were associated with worse OS
Mays et al. ³⁹⁸	2018	4	Retrospective case series	Patients with ACC treated with curative intent with PM (<i>n</i> = 40) versus NM (<i>n</i> = 38)	1. OS 2. DFS	MS was not associated with OS or DFS
Seong et al. ³⁹⁹	2014	4	Retrospective case series	Patients with ACC treated with surgery ± adjuvant therapy with PM (<i>n</i> = 19) versus NM (<i>n</i> = 5)	1. DFS 2. DSS	PM did not significantly affect DSS or DFS
Michel et al. ⁴⁰⁸	2013	4	Retrospective case series	Patients with ACC with PM (<i>n</i> = 11) versus NM (<i>n</i> = 6)	Survival	MS was not significantly associated with OS or DFS

(Continues)

TABLE XII.1 (Continued)

Study	Year	LOE	Study design	Study groups	Clinical endpoints	Conclusions
Wiseman et al. ³⁷⁷	2002	4	Retrospective case series	Patients with ACC with PM ($n = 19$) versus NM ($n = 11$)	1. LR 2. 10-year OS	1. LR was more common in patients with PM 42% versus NM 22% 2. 10-year OS for PM 43% versus 75% for NM
Inverted papilloma						
Lee et al. ³⁶⁹	2020	4 ^a	Retrospective cohort	Patients with IP with recurrence versus no recurrence ($n = 76$)	Impact of margins on recurrence	Incomplete resection (including PM) was significantly associated with recurrence
Miglani et al. ⁴⁰⁹	2018	4	Retrospective case series	Patients with IP who underwent surgical resection until NM were achieved on IFSH ($n = 22$)	1. PPV and NPV for IFSH 2. Recurrence	1. PPV and NPV were 100% for IFSH 2. No recurrences occurred during the study period
Healy et al. ⁴¹⁰	2016	4	Retrospective case series	Patients with IP or oncocytic papilloma with EEA with either unconfirmed margins on frozen sections ($n = 73$) or confirmed NM on frozen sections ($n = 54$)	Recurrence	Intraoperative confirmation of NM by frozen sections did not improve recurrence rates
Melanoma						
Almutuawa et al. ²⁷⁷	2020	3	Retrospective cohort	Patients with SNMM who underwent either EEA ($n = 10$) or OR ($n = 10$)	OS	No difference in hazard of death between PM and NM
Sayed et al. ²⁷¹	2017	3	Retrospective cohort	Patients with SNMM treated with surgical curative intent with PM ($n = 32$) versus NM ($n = 40$)	1. 3-year OS 2. LRFS 3. DFS	1. MS was not associated with OS 2. Absolute 3-year difference between patients with NM and those with PM was 18% for LRFS, 5% for DFS, and 15% for OS
Ledderose and Leunig ²⁷⁶	2015	3	Retrospective cohort	Patients with recurrent SNMM treated with either EEA ($n = 12$; PM = 10, NM = 2) or OR ($n = 10$; PM = 6, NM = 4)	1. MS 2. DM 3. LR	1. NM obtained in 40% OR versus 16.6% EEA but this did not influence the course of disease 2. DM and LR occurred in 60%–70% regardless of MS
Roth et al. ³⁷³	2010	3	Retrospective cohort	Patients with SNMM who underwent primary surgery with curative intent (NM = 16) versus noncurative (PM = 3)	Differences in survival	Median survival rate 31 months for NM versus 15 months for PM

(Continues)

TABLE XII.1 (Continued)

Study	Year	LOE	Study design	Study groups	Clinical endpoints	Conclusions
Elsamna et al. ³⁶⁵	2021	4	Retrospective database review (NCDB)	Patients with SNMM with PM (<i>n</i> = 120), no surgery (<i>n</i> = 63), versus NM (<i>n</i> = 263)	One-, 2-, 3-, and 5-year OS	<ol style="list-style-type: none"> 1-year OS rates were 87%, 72%, and 47% for NM, PM, and no surgery, respectively 2-year OS rates were 72%, 36%, and 16% 3-year OS rates were 55%, 16%, and 8% Only patients in NM group were alive at 5 years (39%) Propensity score matching demonstrated a difference between NM and PM
Ganti et al. ³⁶⁶	2020	4	Retrospective database review (NCDB)	Patients with SNMM with PM (<i>n</i> = 355) versus NM (<i>n</i> = 812)	OS	<ol style="list-style-type: none"> 1. Improved survival was associated with surgical resection only when NM 2. MS was a predictor of survival
Caspers et al. ³⁶⁴	2018	4	Retrospective case series	Patients with SNMM with PM (<i>n</i> = 11) versus NM (<i>n</i> = 15)	<ol style="list-style-type: none"> 1. DMFS 2. OS 	<ol style="list-style-type: none"> 1. DMFS reduced in patients with PM 2. OS was negatively influenced by PM 3. PM status was associated with decreased DMFS
Konuthula et al. ³⁶⁸	2017	4	Retrospective database review (NCDB)	Patients with SNMM with PM (<i>n</i> = 127) versus NM (<i>n</i> = 300)	5-year survival	NM associated with improved survival
Vandenhende et al. ⁴⁰²	2012	4	Retrospective case series	Patients with SNMM treated with surgical curative intent with PM (<i>n</i> = 4) versus NM (<i>n</i> = 12)	3-year OS	MS did not impact 3-year OS
Moreno et al. ²³²	2010	4	Retrospective case series	Patients with SNMM who underwent primary surgery with PM (<i>n</i> = 12) versus NM (<i>n</i> = 44)	<ol style="list-style-type: none"> 1. Two- and 5-year OS 2. LR 	<ol style="list-style-type: none"> 1. Nonsignificant difference in 2-year (NM 64% versus PM 42%) and 5-year (NM 44% versus PM 25%) survival 2. Nonsignificant increase in LR in PM 42% versus NM 20%
Bachar et al. ⁴⁰⁰	2008	4 ^b	Retrospective cohort	Patients with SNMM with PM (<i>n</i> = 18) versus NM (<i>n</i> = 13)	<ol style="list-style-type: none"> 1. LR 2. RR 3. DM 	MS was not a significant predictor of LR, RR, or DM
Kingdom and Kaplan ⁴⁰¹	1995	4	Retrospective case series	Patients with SNMM with PM (<i>n</i> = 5) versus NM (<i>n</i> = 8)	<ol style="list-style-type: none"> 1. OS 2. LRC 	NM do not appear to predict a better OS or LRC
Mixed tumor						
Dulguerov et al. ²²	2001	2	Systematic review of retrospective case series	Patients with SNM (<i>n</i> = 156) with PM versus NM	Two- and 5-year actuarial LRC	Two- and 5-year actuarial LRC rates were 59% ± 9% and 45% ± 9% for PM versus 70% ± 7% and 65% ± 7% for NM

(Continues)

TABLE XII.1 (Continued)

Study	Year	LOE	Study design	Study groups	Clinical endpoints	Conclusions
Resto et al. ³⁷¹	2008	3	Retrospective cohort	Patients with locally advanced SNM treated with surgery with complete resection (NM = 20), STR (PM = 50), and biopsy only (PM = 32) followed by proton + photon beam RT	LRC, DFS, 5-year OS, DMF	<ol style="list-style-type: none"> MS/extent of surgery did not impact LRC MS/extent of surgery did impact DFS, 5-year OS, and DMF
Ganly et al. ¹⁷⁴	2005	3	Retrospective cohort	Patients with SNM who underwent CFR with PM (<i>n</i> = 95) versus NM (<i>n</i> = 234)	<ol style="list-style-type: none"> 5-year DSS 5-year OS 5-year RFS 	MS was an independent predictor of OS and DSS
Al-Qurayshi et al. ³⁶⁰	2022	4	Retrospective database review (NCDB)	Patients with non-SCC malignancies with PM (<i>n</i> = 263) versus NM (<i>n</i> = 311)	<ol style="list-style-type: none"> Impact of neoadjuvant therapy on MS OS 	<ol style="list-style-type: none"> Neoadjuvant therapy was associated with a lower prevalence of PM Patients with SNUC had the highest reduction in the risk of PM NM was associated with improved OS
Lehrich et al. ³⁷⁸	2021	4	Retrospective database review (NCDB)	Patients with SNM who underwent either primary surgery (<i>n</i> = 2804; PM = 826, NM = 1552) versus salvage surgery (<i>n</i> = 207; PM = 54, NM = 115)	OS	<ol style="list-style-type: none"> MS impacted survival in SS Survival analysis demonstrated significantly worse OS outcomes for SS patients with PM
Povolotskiy et al. ³¹⁵	2020	4	Retrospective database review (NCDB)	Patients with non-SCC malignancies who underwent definitive primary surgery either EEA (<i>n</i> = 673; PM = 148, NM = 303) or OR (<i>n</i> = 922; PM = 258, NM = 443)	OS	MS was not found to be a predictor of mortality
Fu et al. ³⁸⁰	2018	4	Retrospective case series	Patients with non-SCC malignancies who underwent neoadjuvant RT + surgery (<i>n</i> = 23) versus surgery + RT (<i>n</i> = 61)	Margin control	Neoadjuvant RT significantly reduced the risk of PM even after controlling for T stage and treatment (OR + EEA vs. EEA) factors

(Continues)

TABLE XII.1 (Continued)

Study	Year	LOE	Study design	Study groups	Clinical endpoints	Conclusions
Lepera et al. ³⁷⁰	2018	4	Retrospective case series	Patients who underwent EEA for SNM and ASB malignancies who were either younger (<70 years) (<i>n</i> = 397; PM = 42, NM = 355) or elderly (≥70 years) (<i>n</i> = 206; PM = 26, NM = 180)	1. Five- and 10-year 2. OS 3. DSS 4. RFS	1. No difference in PM between younger and elderly 2. Five- and 10-year OS and DSS of elderly were comparable to younger and poorer when compared with elderly with NM 3. Margins (PM vs. NM) were independent predictive factors for OS, DSS, and RFS
Nishio et al. ¹⁸⁶	2015	4	Retrospective case series	Patients with locally advanced T4 maxillary sinus carcinoma who underwent open CFR with PM (<i>n</i> = 9) versus NM (<i>n</i> = 26)	5-year OS	5-year OS rate significantly lower in cases with PM (45%) versus NM (80%)
Chiu and Ma ³⁸⁴	2013	4	Retrospective case series	SNM with EEA (<i>n</i> = 31)	Accuracy of intraoperative frozen sections	1. Overall false-negative rate for intraoperative frozen sections was 6.5%, both were SNMM 2. False-negative rate for SNMM was 25% versus 0% for all other histological subtypes examined
Cantu et al. ¹⁶³	2012	4	Retrospective case series	Patients who underwent open CFR approach for resection of ASBM with PM (<i>n</i> = 95) versus NM (<i>n</i> = 271)	1. LR 2. DSS	PM impacted LR and DSS
Hoppe et al. ³⁹⁵	2007	4	Retrospective case series	Patient with SNM treated with surgery + RT with PM (<i>n</i> = 32) versus NM (<i>n</i> = 53)	1. LPFS 2. RPFS 3. DMFS 4. OS	MS was not predictive of LPFS, RPFS, DMFS, or OS
Qureshi et al. ⁴⁰⁵	2006	4	Retrospective case series	Patients with non-SCC malignancies of the maxillary sinus treated with curative intent with PM (<i>n</i> = 15) versus NM (<i>n</i> = 18)	OS	Survival was not significantly different depending on MS
Suarez et al. ¹⁷⁷	2004	4	Retrospective case series	Patients who underwent CFR for SNM (<i>n</i> = 100)	OS	Survival was not affected in patients with PM versus NM
Bilsky et al. ⁴⁰³	1997	4	Retrospective case series	Patients with ASB malignancies with intracranial involvement with PM (<i>n</i> = 12) versus NM (<i>n</i> = 14)	1. DSS 2. LRC	1. Difference in DSS between NM and PM 2. No difference in local control LRC (58%) versus PM (55%)

(Continues)

TABLE XII.1 (Continued)

Study	Year	LOE	Study design	Study groups	Clinical endpoints	Conclusions
Rutter et al. ⁴⁰⁶	1998	4	Retrospective case series	Patients who underwent CFR of ASBM with PM (<i>n</i> = 5) versus NM (<i>n</i> = 14)	Survival	Four out of five (80%) patients with PM developed recurrence versus four out of 14 (20%) with NM, <i>p</i> = 0.11
Spiro et al. ⁴⁰⁷	1995	4	Retrospective case series	Patients with NSCCSM (<i>n</i> = 110)	LR	1. NM was of no obvious benefit on LR 2. >50% of patients with NM still experienced LR
Kraus et al. ⁴⁰⁴	1992	4	Retrospective case series	Patients with primary ethmoid sinus malignancies with PM (<i>n</i> = 4) versus NM (<i>n</i> = 15)	Long-term survival	1. Nine out of 15 patients with NM had long-term survival versus two out of four with PM 2. A trend toward improved prognosis is associated with NM
Mucoepidermoid carcinoma						
Auger et al. ⁴¹¹	2020	4	Retrospective database review (NCDB)	Patients with MEC with PM (<i>n</i> = 55) versus NM (<i>n</i> = 114)	OS	1. PM was not found to be a significant predictor of survival 2. 5-year survival and median survival were higher in NM group 3. PM more likely to have higher stage of malignancy 4. Adjuvant RT was associated with improved survival in patients with NM
Olfactory neuroblastoma						
Harvey et al. ²⁴³	2017	3	Retrospective cohort	Patients with ONB treated with either EEA (<i>n</i> = 67; PM = 8, NM = 59) or OR (<i>n</i> = 42; PM = 20, NM = 22)	DFS	MS was a major predictor of survival for the whole group
Abdelmeguid et al. ⁴¹²	2022	4	Retrospective case series	Patients with ONB with PM (<i>n</i> = 14) versus NM (<i>n</i> = 76)	1. OS 2. DSS	MS was not significantly associated with OS or DSS
Barinsky et al. ²⁵⁴	2021	4	Retrospective database review (NCDB)	Patients in the NCDB with ONB treated with either EEA (<i>n</i> = 257; PM = 53, NM = 130) or OR (<i>n</i> = 276; PM = 59, NM = 123)	5-year OS	PM conferred increased risk of mortality
Sun et al. ³⁹⁶	2020	4	Retrospective case series	Patients with ONB with PM (<i>n</i> = 50) versus NM (<i>n</i> = 38)	1. 5-year OS 2. LRC 3. DMFS	1. Orbital invasion and intracranial invasion were associated with PM 2. MS did not impact 5-year OS, LRC, or DMFS
Joshi et al. ⁴¹³	2019	4	Retrospective database review (NCDB)	Patients in the NCDB with ONB with PM (<i>n</i> = 107) versus NM (<i>n</i> = 273)	Factors associated with PM	PM associated with treatment at community hospital, increasing T stage, and positive nodal metastasis

(Continues)

TABLE XII.1 (Continued)

Study	Year	LOE	Study design	Study groups	Clinical endpoints	Conclusions
Ishii et al. ³⁸⁵	2017	4	Retrospective case series	Diagnostic accuracy of intraoperative frozen sections obtained during ONB surgery for 459 specimens from 33 patients	Sensitivity, specificity, accuracy, likelihood ratio, prevalence, PPV, and NPV	1. Sensitivity 89%, specificity 96%, accuracy 95%, likelihood ratio 24.4, prevalence 0.2, PPV 86%, and NPV 97% 2. Crushed artifacts and inadequate specimen size were major sources of incorrect reads
Patel et al. ¹⁸¹	2012	4	Retrospective case series	Patients with ONB who underwent CFR with PM (<i>n</i> = 23) versus NM (<i>n</i> = 102)	1. OS 2. DSS 3. RFS	PM was independent predictor of worse DSS, OS, and RFS
Zafereo et al. ³⁹⁷	2008	4	Retrospective case series	Patients with ONB with PM (<i>n</i> = 2) versus NM (<i>n</i> = 13)	1. DSS 2. RFS	PM was associated with lower DSS and RFS
Chao et al. ³⁹⁴	2001	4	Retrospective case series	Patients with ONB with PM (<i>n</i> = 5) versus NM (<i>n</i> = 10)	1. DFS 2. LRC	1. With adjuvant RT, LRC was achieved in four out of five patients with PM and nine out of 14 patients with NM, close, or unknown margins 2. PM status did not adversely affect DFS
Resto et al. ³⁷²	1999	4	Retrospective review	Patients with ONB with PM (<i>n</i> = 6) versus NM (<i>n</i> = 10)	1. Recurrence 2. RFS 3. OS	1. PM had an HR for recurrence of 10.1 respective of combination of treatment regimen used compared to NM 2. Survival analysis identified better outcome on RFS and OS with NM
Sinonasal undifferentiated carcinoma						
Khan et al. ³⁶⁷	2017	4	Retrospective database review (NCDB)	Patients with SNUC with PM (<i>n</i> = 22) versus NM (<i>n</i> = 37)	5-year OS	NM + adjuvant CRT had a significantly better 5-year survival than those undergoing definitive CRT
Squamous cell carcinoma						
Ackall et al. ⁴¹⁴	2021	4	Retrospective database review (NCDB)	Patients with poorly differentiated SCC who underwent surgery with PM (<i>n</i> = 233) versus NM (<i>n</i> = 393)	OS	Patients with PM treated with adjuvant RT or CRT trended toward worse OS than patients with NM treated with adjuvant RT or CRT
Nakamura et al. ¹⁴⁰	2021	4	Retrospective case series	Patients with SCC who underwent EEA with PM (<i>n</i> = 4) versus NM (<i>n</i> = 11)	DSS	Patients with NM had better DSS rate than those with PM

(Continues)

quate margin is the proximity to critical neurovascular structures, limiting the feasibility of wide surgical margins.

An understanding of the three-dimensional anatomy of the tumor is essential for successfully clearing margins. This understanding is initially shaped by preoperative

imaging and either confirmed or clarified intraoperatively. Samples from 360° around the margins of the surgical resection must be taken including anteriorly, posteriorly, laterally, medially, inferiorly, and superiorly with the goal to resect one tissue layer deeper than what is involved.³⁷

TABLE XII.1 (Continued)

Study	Year	LOE	Study design	Study groups	Clinical endpoints	Conclusions
Torabi et al. ²⁴¹	2020	4	Retrospective database review (NCDB)	Patients with SCC with PM (<i>n</i> = 807) versus NM (<i>n</i> = 2161)	1. Factors associated with PM 2. survival	1. PM status was associated with treatment at LVF, T stage ≥ 3 , poorly differentiated tumor, and location in ethmoid sinuses 2. PM associated with decreased OS versus NM 3. No difference in PM status between EEA versus open surgery
Jafari et al. ¹⁶¹	2019	4	Retrospective database review (NCDB)	Patients with SCC with micro-PM (<i>n</i> = 511) versus macro-PM (<i>n</i> = 521) versus NM (<i>n</i> = 2289)	1. Factors associated with PM 2. OS	1. Propensity-score-matched results showed NM and micro-PM improved OS over nonsurgical treatment, while macro-PM did not 2. Macro-PM were significantly higher when primary tumor was in the primary surgery versus NC and advanced T classification
Cracchiolo et al. ¹⁶⁰	2018	4	Retrospective database review (NCDB)	Patients with SCC with PM (<i>n</i> = 475) versus NM (<i>p</i> = 1212)	5-year OS	1. Patients with NM had improved survival compared to PM 2. Micro-PM versus NM, and macro-PM versus NM were associated with worse survival
Kilic et al. ¹³⁵	2018	4	Retrospective database review (NCDB)	Patients with SCC treated with EEA (<i>n</i> = 353; PM = 74, NM = 169) versus OR (<i>n</i> = 1130; PM = 267, NM = 749)	1. MS 2. OS	1. The rate of PM between EEA and open surgery was comparable except greater PM rate in EEA for IVB tumors 2. MS was associated with poorer survival
Robin et al. ¹⁵⁹	2017	4	Retrospective database review (NCDB)	Patients in the NCDB with SCC who underwent surgery with or without adjuvant therapy with PM (<i>n</i> = 537) versus NM (<i>n</i> = 1422)	Likelihood of achieving NM	Increasing T stage less likely to have NM (T3 and T4), neoadjuvant CRT associated with increased likelihood of achieving NM
Karligkiotis et al. ²⁴⁷	2016	4	Retrospective case series	Patients treated for IP-SCC at two institutions with PM (<i>n</i> = 2) versus NM (<i>n</i> = 32)	OS	MS was not associated with OS
de Almeida et al. ¹³⁰	2015	4	Retrospective case series	Patients with SCC with PM (<i>n</i> = 5) versus NM (<i>n</i> = 22)	1. LRC 2. DFS 3. 5-year OS	1. LRC and DFS with NM were 74% at 5 years versus 0% at 5 years for PM 2. 5-year OS was 93% in NM versus 0% PM

(Continues)

TABLE XII.1 (Continued)

Study	Year	LOE	Study design	Study groups	Clinical endpoints	Conclusions
Janecka et al. ⁴¹⁵	1994	4	Retrospective review	Patients with SCC treated with CBS with PM (33%) versus NM (77%)	No evidence of disease status	The ability to achieve NM in SCC is directly related to no evidence of disease status
Hordijk and Brons ³⁸⁹	1985	4	Retrospective review	Patients with SCC or adenocarcinoma of the maxillary sinus with PM (<i>n</i> = 20) versus NM (<i>n</i> = 44)	LR	LR was detected in 15 out of 20 patients with PM versus one out of 44 patients with NM

Abbreviations: AC, adenocarcinoma; bEEATC, bilateral endoscopic resection with transnasal craniectomy; CRT, chemoradiation therapy; DM, distant metastasis; DSS, disease-specific survival; IFSH, intraoperative frozen section histopathology; LR, local recurrence; LRC, locoregional control; macro-PM, macroscopic positive margins; micro-PM, microscopic positive margins; MS, margin status; NM, negative margins; NPV, negative predictive value; OR, open resection; OS, overall survival; PFS, progression-free survival; PM, positive margins; PPV, positive predictive value; RPFS, regional progression-free survival; RR, regional recurrence; SCC, squamous cell carcinoma; SS, salvage surgery; uEEATC, unilateral endoscopic resection with transnasal craniectomy.

^aLOE downgraded as study most consistent with retrospective case series with secondary analysis of margin status.

^bLOE downgraded as study most consistent with retrospective case series with multiple subanalyses/comparison groups.

Preoperative planning and counseling of the patient are essential whenever there is suspicion of involvement of either the orbit or the skull base given the potential consequences of clearing margins along either of these vital structures. With the orbit, if the lamina papyracea is invaded, periorbita should be sampled as a margin.^{316,335} Should this be positive, orbital fat/orbital contents would need to be assessed.^{316,335} If the bone of the skull base is invaded, dura would need to be sampled as a margin.^{316,382} Any areas with positive margins should be re-resected until they are negative unless prohibited by proximity to critical neurovascular structures where biopsy may result in significant morbidity or mortality.

B | Frozen sections for margin analysis

Frozen sections can play several roles in endoscopic tumor resection. Given sinonasal tumors often occur within close proximity to or involve the nasal septum, it is recommended that frozen sections of septal mucosa be taken from along the course of the planned NSF to confirm no malignant cells are present prior to using the NSF for reconstructive purposes.³⁸² Several authors endorse continuous intraoperative assessment of surgical margins by way of frozen section analysis during tumor resection.^{106,140,182,289,316,365} Given SNM can have submucosal, subperiosteal, and perineural spread, relying on gross identification of tumor for defining the extent of resection is insufficient.¹⁰⁶ Continual assessment with frozen section allows the surgeon to enlarge the resection until margins are cleared (when possible), thereby achieving definitive resection.^{106,130,182,289} One caveat to this is PNI. Surgery is considered inadequate for clear-

ing PNI, especially given the frequency of “skip lesions.” Therefore, the use of intraoperative frozen analysis to clear PNI is not considered effective. This is particularly salient in ACC, a tumor with a propensity for PNI. Indeed, several series on ACC have shown margin status to not correlate with survival metrics.^{247,377,389} When definitive resection is not feasible, frozen section analysis can be used during debulking surgeries to achieve negative margins near vital structures in an effort to reduce RT dose.¹³⁰

Few studies have evaluated the accuracy of frozen section margins in sinonasal tumors. One study showed 100% accuracy of frozen sections for several histologic subtypes including SCC, adenocarcinoma, ONB, ACC, and SNUC.³⁸⁴ For the entire cohort, which included mucosal melanoma, the overall false-negative rate was 6.5% and both false negatives occurred in melanoma cases.³⁸⁴ With an overall false-negative rate of 25% for melanoma, the authors concluded that intraoperative frozen sections are not reliable for this tumor type.³⁸⁴ A second study focusing on the accuracy of frozen section in ONB found it to be an accurate tool for the assessment of intraoperative margins with a positive predictive value (PPV) of 86% and NPV of 97%.³⁸⁵

The inadequacy of frozen section analysis for melanoma is well reported.^{271,373,384,390} The reason is likely due to the variability of melanoma appearance on both gross and histological evaluations. Up to 41% of tumors in one study were amelanotic, thereby increasing the difficulty of gross examination.³⁷³ Histologically, tumor cells can appear in both different configurations and shapes.³⁹¹ Immunohistochemical staining is required to differentiate tumor cells from normal tissue and currently, there are no frozen section immunohistochemical stains that have been studied

TABLE XII.2 Evidence surrounding impact of approach on margin status.

Study	Year	LOE	Study design	Study groups	Clinical endpoints	Conclusions
Almutuawa et al. ²⁷⁷	2020	3	Retrospective cohort	Patients with SNMM who underwent either EEA ($n = 10$) or open surgery ($n = 10$)	1. Impact of EEA on MS 2. OS	1. No significant difference in MS between EEA and OR 2. No significant difference in hazard of death between PM and NM
Abdelmeguid et al. ¹⁸²	2019	3	Retrospective cohort	EEA of SNM ($n = 167$) versus endoscopic-assisted resection of SNM ($n = 72$)	MS differences between approaches	No significant difference in MS between EEA and endoscopic-assisted resection
Yin et al. ²⁶⁸	2018	3	Retrospective cohort	Patients with SNMM who underwent either EEA (PM = 2, NM = 25) or open surgery (PM = 3, NM = 24)	MS differences between approaches	No difference in ability to obtain NM via EEA versus open surgery
Harvey et al. ²⁴³	2017	3	Retrospective cohort	Patients with ONB treated with either EEA ($n = 67$; PM = 8, NM = 59) or open surgery ($n = 42$; PM = 20, NM = 22)	1. MS differences between approaches 2. Five- and 10-year DFS	1. The ability to achieve NM was better in EEA versus open surgery for both Kadish B and C stage tumors 2. MS was a major predictor of survival for the group as a whole
Arnold et al. ²⁹⁷	2012	3	Retrospective cohort	Patients with SNM who underwent EEA ($n = 28$) versus open surgery ($n = 55$)	MS	No significant difference in PM between EEA and open surgery
Kilic et al. ¹³⁵	2018	4	Retrospective database review (NCDB)	Patients in the NCDB with SCC treated with EEA ($n = 353$; PM = 74, NM = 169) versus OR ($n = 1130$; (PM = 267, NM = 749)	1. MS 2. OS	1. The rate of PM between EEA and OR was comparable when all tumor states were considered 2. There was a significantly greater PM rate in the EEA group for IVB tumors 3. MS was associated with poorer survival
Miglani et al. ²⁷²	2017	4	Retrospective case series	Patients with mucosal melanoma who underwent either EEA ($n = 9$) or open surgery ($n = 13$)	MS differences between approaches	No difference between EEA versus open surgery on MS

Abbreviations: EEA, endoscopic endonasal approach; MS, margin status; NCDB, National Cancer DataBase; NM, negative margins; ONB, olfactory neuroblastoma; PM, positive margins; SCC, squamous cell carcinoma; SNMM, sinonasal mucosal melanoma; SNM, sinonasal malignancy.

in melanoma.^{384,392,393} For these reasons, surgeons should consider deferring to permanent pathology for analysis of margins.^{271,384} Other instances where it would be reasonable to defer to permanent pathology are times when intraoperative findings dictate a more aggressive surgical resection that has not previously been discussed with the patient.

Several studies have shown the rate of positive margins after surgical treatment of SNM to be between 13%

and 30%.^{160,161,174} Options for positive margins include returning to the operating room for re-resection versus adjuvant treatment in the form of chemotherapy, RT, or CRT.^{140,141,161,289,363–365,372,394–396} The choice of how to address positive margins is complex and depends upon several factors including whether it is feasible for negative margins to be achieved and the volume of tumor that is left behind. This decision must be made on a case-by-case basis.

C | Margin status and survival

The literature on the impact of margin status on survival is mixed. This is potentially due to several issues. In general, studies are lower levels of evidence, consisting of retrospective reviews and database analyses. Several studies evaluated a mixed tumor type population, and the heterogeneity of these populations may have led to confounding. Finally, several studies evaluating the impact of margins on SNM are small and likely underpowered.

For adenocarcinoma, ONB, and SCC, the majority of studies have demonstrated improved outcomes with negative margins. Regarding adenocarcinoma, several series show margin status significantly impacts OS, DFS, DSS, RFS, and LRC.^{247,362,363,374} In ONB, margin status appears to significantly impact OS, DSS, and RFS, but the effect on DFS and distant metastasis-free survival (DMFS) is less clear.^{181,243,254,372,394,396,397} Finally, for SCC, a majority of studies do show margin status to significantly impact OS with a few studies supporting an impact on DFS, DSS, and LRC.^{130,140,160,161,241,247,389}

For other pathologies, the literature is less conclusive. The data for ACC are fairly mixed with studies showing an impact on OS but not DFS.^{106,362,363,374–377,389,398,399} For melanoma, the literature is similarly mixed regarding the impact of margins on OS; however, margin status more consistently does not appear to impact LRC.^{232,271,277,364–366,368,373,400–402} IP is yet another pathology where the literature shows conflicting results on the impact of margin status on recurrence.^{276,369} Finally, several studies reported on a mixed tumor population, which is problematic for several reasons. As stated above, the inclusion of multiple different tumor types introduces significant confounding, which limits both the interpretation of the results and the applicability to specific tumor types. Overall, in mixed tumor studies, the impact of margin status on OS is unclear; however, there does appear to be a benefit to DSS and RFS but little evidence to suggest a benefit for either LRC or DMFS.^{22,163,174,177,186,315,360,370,371,378,395,403–407}

In summary, the majority of studies demonstrate margin status to impact various survival metrics for most tumor subtypes. For some pathologies such as adenocarcinoma, ONB, and SCC, the benefit of negative margins is fairly well established. However, for other pathologies such as ACC and SNMM, controversies remain. Further studies could potentially provide clarification and better guidance on the importance of margin status in these tumor types.

Margin analysis in sinonasal tumors

Aggregate grade of evidence	C (Level 2: one study; Level 3: 12 studies; Level 4: 61 studies)
Benefit	Negative margins are associated with significant improvements in OS, DSS, and RFS in a majority of studies for all tumor subtypes.
Harm	Potential harm of taking aggressive margins includes injury to critical neurovascular structures that would otherwise not be sacrificed, leading to increased morbidity or mortality to the patient. Inaccurate frozen section margins intraoperatively could change the operative plan and either compromise definitive resection requiring a return to the operating room or adjuvant chemoradiation or could lead to more aggressive resection than is truly warranted. The potential harm to not achieving negative margins comes at the cost of survival for several tumor subtypes.
Cost	Frozen section use is associated with increased costs, but this must be weighed against the potential cost of a second surgery, intensification of adjuvant treatment, and reduced survival that could otherwise have been avoided if complete resection with negative margins had been achieved.
Benefits–harm assessment	Preponderance of benefits over harms.
Value judgments	“Wide surgical margins” should be more clearly defined and uniformly reported within the literature.
Policy level	Recommendation for most malignancies. Option for ACC with perineural invasion.
Intervention	All attempts should be made to resect SNM to negative margins except for when resecting to negative margins would put critical neurovascular structures at risk for injury that would otherwise not be at risk. GTR may be acceptable for ACC for local control. Frozen section analysis should not be used on mucosal melanoma due to inaccuracy. For all other tumor types evaluated (SCC, adenocarcinoma, ONB, SNUC), frozen section analysis should be used intraoperatively to define the resection margins and ensure definitive/negative margin resection.

XIII | MANAGEMENT OF RECURRENT MALIGNANCY

Advances in surgery, RT, and systemic therapies have improved outcomes of SNM, but recurrences remain common. Historically, recurrences have been estimated to occur with an average rate around 50%, although recent series of experienced teams report recurrences in the order of 20%–30%.^{22,33,416–419} Local recurrence represents the main form of failure and mortality for all types of SNM. Regional and distant metastases are less frequent and vary according to histological subtype and initial grade and stage. For instance, the rate of regional recurrences is significant in ONB, while distant metastatic rate is significant in SNUC, mucosal melanoma, and ACC. Due to the low incidence of SNM and histological variability, there is a paucity of literature concerning the treatment of recurrent disease.

A | Diagnosis of recurrent tumor

Early detection of recurrent SNM is critical for successful salvage treatment. Posttreatment surveillance is therefore vital to maximize long-term survival. However, identification of recurrent disease in a previously treated region can be challenging. Clinical follow-up and imaging are conventionally used for surveillance after successful treatment of SNM. In-office endoscopy forms the mainstay of clinical surveillance. Although it has a low sensitivity as it only identifies superficial local recurrences, it is inexpensive and easy to perform. Recurrences identified via endoscopy are often amenable to salvage therapy given their early detection.^{418,419} Khalili et al. showed a sensitivity of 25%, specificity of 89%, PPV of 43%, and NPV of 78% for endoscopy.⁴¹⁸

Imaging is critical for ongoing surveillance in patients treated for SNM with most recurrences being detected through imaging (Table XIII.1).^{418,419} MRI demonstrates the highest PPV (84%) compared to PET/CT (46%) or CT alone (44%) for detecting recurrent disease and should be the mainstay of local surveillance.⁴¹⁸ PET/CT has a significant false-positive rate that is probably the consequence of treatment-related inflammatory changes and the propensity for the sinonasal cavity to develop inflammatory and infective pathologies.^{197,216,420,421} Similar issues have also been identified with PET imaging of the neck, especially following neck irradiation to treat regional disease in head and neck cancer.^{422–425} Importantly, evidence shows that PET should be performed no sooner than 3 months after treatment due to the possibility of treatment-induced changes confounding the results. PET/CT is, however, extremely valuable for the detection of distant metas-

tases. That being said, Fakhry et al. did not observe better accuracy of PET in the detection of distant metastases in head and neck SCC when compared to CT and Spector et al. did not show improved life expectancy when PET was used over other imaging modalities to detect distant metastases.^{426,427}

Surveillance recommendations for SNM were often generalized based on research for all head and neck cancers, but it is becoming increasingly clear that SNMs are distinct entities requiring different surveillance regimens. First, late recurrences beyond 5 years have been widely reported for SNM, with a recent study showing these to account for 11.7% of all recurrent disease.⁴²⁸ These figures vary depending on the histology and, in some subtypes as ACC, ONB, and melanoma, recurrences even after 10 years have been described.^{428–430} For this reason, surveillance beyond 5 years is recommended for SNM and possibly lifelong follow-up should be considered for specific histological subtypes.^{6,196} Second, recurrences are frequently detected in asymptomatic patients (51%–94%) and consequently a routine examination and imaging protocol is recommended.^{419,431} Finally, the appropriate follow-up interval remains controversial; however, there is a consensus that it should be more intensive during the first 2–3 years posttreatment, given the high risk of recurrence during this time period. Two experienced teams have assessed their surveillance programs for SNM. Using an intensive surveillance program consisting of (1) clinical follow-up every 2 months for year 1, every 3 months for year 2, every 6 months for years 3–5, and annually thereafter; (2) surveillance MRI every 4 months for year 1, every 6 months for years 2–5, and annually thereafter; and (3) screening for distant metastases annually with CT/PET, Zocchie et al. demonstrated that 94% of all recurrences could be detected in asymptomatic patients.⁴¹⁹ Seventy-four percent of recurrences were detected in the first 3 years posttreatment and, importantly, they showed that 61.5% of recurrences detected in this manner could be treated with curative intent. Khalili et al. found similar results with their surveillance program consisting of initial follow-ups at 1–3 monthly intervals for the first 2 years, 3- to 6-month intervals for the next 3 years, and then annually afterward.⁴¹⁸ At each visit, a standard history and physical examination including nasal endoscopy was performed, with MRI, CT, and/or PET/CT scans performed at 3- to 6-month intervals for the first 2 years, then every 6 months to yearly intervals thereafter. Using this surveillance program, they found that 63% first recurrences were detected in the first 24 months after treatment and 87% of first recurrences could be treated with curative intent. Interestingly, all recurrences diagnosed by endoscopy ($n = 6$) underwent retreatment and were alive at last follow-up. Three out of 17 patients with local recurrence diagnosed by imaging were

TABLE XIII.1 Evidence surrounding diagnostic value of PET in recurrent sinonasal malignancy in previously treated tissue.

Study	Year	LOE	Study design	Study groups	Clinical endpoints	Conclusion
Diagnosis of recurrence at primary site (SN and/or SB)						
Lamarre et al. ¹⁹⁷	2012	3	Retrospective cohort	78 PET/CT analyzed for surveillance following surgery or RT ± chemotherapy	LR	<ol style="list-style-type: none"> To detect local recurrence, negative studies are effective in predicting absence of disease Positive studies need to be viewed cautiously given the high rate of false-positive studies
Harvey et al. ⁴²⁰	2009	3	Retrospective cohort	34 patients with SB malignancy treated with surgery, RT, chemotherapy, or a combination	LR	<ol style="list-style-type: none"> PET/CT is a highly sensitive test for malignant disease The mucosal lining of the reconstructed skull base is a common source for inflammatory pathologies that may lead to false-positive PET/CT
Gil et al. ²¹⁶	2007	3	Prospective cohort	47 patients with SB malignancy requiring surgical resection ± RT or CRT with routine posttreatment PET/CT surveillance imaging	Recurrence	PET/CT enables early detection of tumor recurrence and guides endoscopic biopsies in patients with skull base neoplasms
Diagnosis of recurrence in previously irradiated neck						
Rogers et al. ⁴²²	2004	4	Prospective case series	12 patients with N+ head and neck SCC treated with RT with postop imaging including CT or MRI and PET 1 month after RT followed by ND afterward	Persistent cervical nodal disease	The presence of a positive PET/CT 1 month after RT accurately indicated the presence of residual disease in all cases; however, a negative PET indicated absence of disease in only 14%
Sagardoy et al. ⁴²⁵	2016	4	Retrospective case series	43 N+ SCC patients treated with CRT followed by postop PET/CT at 3 months and then only when suspicious symptoms or exam	Recurrent/persistent cervical nodal disease	FDG PET-CT seems effective in detecting recurrent/persistent neck disease within the first 2 years of follow-up after nonsurgical treatment of head and neck SCC
Brkovich et al. ⁴²⁴	2006	4	Prospective case series	19 patients with advanced head and neck SCC with N+ necks treated with CRT and complete response in the primary site with posttreatment PET/CT followed by salvage neck dissection (<i>n</i> = 21)	Persistent cervical nodal disease	<ol style="list-style-type: none"> PET/CT imaging lacks adequate sensitivity and specificity to reliably predict the presence of residual cervical metastatic disease after completion of CRT A negative PET scan appears to be a reliable predictor of the absence of residual tumor (NPV 91.7%)

(Continues)

TABLE XIII.1 (Continued)

Study	Year	LOE	Study design	Study groups	Clinical endpoints	Conclusion
Yao et al. ⁴²³	2005	4	Retrospective case series	53 N+ patients with head and neck SCC treated with CRT, followed by surveillance PET/CT and salvage neck dissection for (1) persistent N+ and positive PET or (2) persistent N+ and negative PET	LR	<ol style="list-style-type: none"> For patients who have no evidence of residual lymphadenopathy and a negative FDG PET scan 12 weeks after definitive radiation, neck dissection can be safely withheld In cases with residual lymphadenopathy on exam and negative PET/CT, neck dissection may be withheld

Abbreviations: CRT, chemoradiation therapy; CT, computed tomography; FDG, fluorodeoxyglucose; LR, locoregional recurrence; ND, neck dissection; PET, positron emission tomography; SB, skull base; SCC, squamous cell carcinoma; SN, sinonasal.

deemed untreatable and did not undergo salvage therapy, and, of the remaining 14 patients, seven were deceased by the end of the study period.

Aggregate grade of evidence: C (Level 3: three studies; Level 4: four studies)

B | Role of salvage surgery

Salvage surgery is typically recommended for patients with more favorable histological subtypes where surgical resection can be safely performed without injury to critical neurovascular structures (Table XIII.2). A study performed with a hospital-based US database showed that patients with SNM undergoing salvage surgery had significantly longer postoperative hospital stays and increased rates of 30- and 90-day mortality compared to patients undergoing primary surgery.³⁷⁸ Based on their analysis of 42 patients with recurrent SNM, Kaplan et al. reported prognostic factors that negatively affected survival. These included high-risk histologic subtypes (melanoma, SNUC, adenocarcinoma, SNEC, sarcoma, SCC), high-grade/poorly differentiated tumors, and tumors with orbital and skull base involvement.⁴¹⁷ For recurrent tumors with these features and not located in the ethmoid sinus, they recommended against salvage surgery. A retrospective study of 118 patients undergoing salvage surgery for recurrent SNM reported a 5-year OS of 56%, with 57% achieving negative margins.⁴³²

Two recent studies, both from Japan, have assessed the role of salvage surgery for the treatment of local persistent/recurrent advanced maxillary sinus SCC treated initially with RADiation and intraarterial cisPLATin (RAD-PLAT). In both series, patients in whom negative surgical margins could be achieved with SS had a significant improvement in their 2- and 5-year survival rates and local disease control.^{433,434} However, salvage treat-

ment of advanced epithelial malignancies involving other sinonasal sites seems less effective. Orlandi et al., in a series of 69 locally advanced (T3 and T4) sinonasal epithelial carcinomas (keratinizing and nonkeratinizing SCC, SNEC, SNUC) treated with multimodal therapy consisting of IC followed by surgery and RT or definitive CRT, observed that 44 patients presented with recurrences after primary treatment. Forty-eight percent were local and 45% had distant metastases with or without locoregional recurrence. Median OS after recurrence was 13 months and patients who underwent salvage surgery had a median survival of 29.5 months compared to 4.6 months for those who did not undergo salvage surgery (i.e., received chemotherapy alone).⁴³⁵

Gore et al. performed a systematic review and pooled analysis of 678 patients with ONB from 35 surgical series. They reported a local recurrence rate of 28.5% after primary treatment. Of the 101 patients who underwent salvage treatment for local recurrence, the success of salvage treatment, defined as a DFS of at least 1 year following treatment, was 42.6% with no observed difference between the different treatment modalities of salvage surgery, reirradiation, or a combination of both. Most documented failures were locoregional (23/28) with only a small percentage (5/28) failing with distant metastases.⁴³⁶ These results need to be interpreted with caution, however, given the low sample size.

The largest analysis for the role of salvage surgery for the treatment of neck recurrence was for regionally recurrent ONB. In a pooled analysis performed by Gore et al. of 678 patients from 35 studies, the rate of overall cervical metastases was 20.2%, with a 12.4% rate of late neck metastases. Salvage surgery was only attempted in 45 patients presenting with late neck metastases, with a 1-year DFS of 31.2% posttreatment. The addition of RT to salvage surgery conferred a statistically significant increase in the rate of successful salvage in patients with late neck metastases.⁴³⁷

TABLE XIII.2 Evidence surrounding role of salvage surgery for recurrent sinonasal malignancy.

Study	Year	LOE	Study design	Study groups	Clinical endpoints	Conclusions
Gore and Zanation ⁴³⁶	2011	2	Systematic review and meta-analysis	35 studies with 678 patients with ONB of which 189 experienced local recurrence; 101 were treated with salvage treatment (SS, RT, or CRT)	1. Recurrence 2. DFS	Reasonable rate of successful salvage of local ONB recurrence using surgery, RT, or combined surgery and RT
Gore and Zanation ⁴³⁷	2009	2	Systematic review and meta-analysis	33 studies with 678 patients ONB including 79 patients with late neck metastasis (>6 months after primary diagnosis), 45 had SS	Successful salvage of late neck metastasis (DFS >1 year)	Treatment of neck metastases occurring 6 or more months after an initial diagnosis of ONB with combined surgery and RT provides a statistically significant survival advantage versus single-modality therapy
Mattavelli et al. ⁴³²	2022	3	Retrospective cohort	118 patients with locally recurrent sinonasal cancers treated with salvage surgery	OS	Predictors of OS included primary treatment modality, histology, pT class, margin status, PNI, and adjuvant RT
Kaplan et al. ⁴¹⁷	2016	3	Retrospective cohort	42 patients with locally recurrent SNM underwent SS ± adjuvant therapy with curative intent	1. 6-, 12-, and 60-month OS 2. Recurrence 3. DFI 4. Postoperative complications 5. LOS	1. High-risk histologic subtype, grade and orbital and skull base involvement negatively affected OS and/or DFI 2. Improved stratification of patients can be used to guide decision making for patients with recurrent SNM and to avoid inappropriate surgery
Tsushima et al. ⁴³⁴	2022	4	Retrospective case series	45 patients who had recurrence following RADPLAT	OS	1. Patients who did not undergo SS had more advanced disease than those who did 2. Prognosis of the patients who underwent SS were naturally better than those for patients who did not 3. Survival rates of the patients undergoing SS was sufficiently high for SS to be recommended
Lehrich et al. ³⁷⁸	2021	4	Retrospective database review (NCDB)	3011 SNM treated with curative intent with primary surgery (<i>n</i> = 2804) versus SS (<i>n</i> = 207)	1. 30-day and 90-day mortality 2. OS 3. LOS	1. Primary surgery resulted in improved OS compared to SS 2. Within the SS group, late stage and positive margins had worse OS
Orlandi et al. ⁴³⁵	2020	4	Retrospective case series	69 locally advanced (T3 and T4) SNM treated with multimodal treatment of which 19 patients with recurrent disease were treated with SS	OS	1. In the recurrent setting, feasibility of SS and clinical benefit from palliative chemotherapy are associated with longer OS 2. A multimodal treatment strategy with induction chemotherapy seems to offer improved OS

(Continues)

TABLE XIII.2 (Continued)

Study	Year	LOE	Study design	Study groups	Clinical endpoints	Conclusions
Ono et al. ⁴³³	2019	4	Retrospective case series	Patients with maxillary carcinoma who received SS (<i>n</i> = 14) versus chemotherapy or palliative care (<i>n</i> = 10) after failing primary CRT followed by sequential RADPLAT (<i>n</i> = 60) or maxillectomy ± neck dissection (<i>n</i> = 16)	1. LRC 2. DFS 3. OS	1. SS for locally persistent or recurrent maxillary sinus cancer is a feasible treatment 2. Patients with positive surgical margins are more prone to local relapse

Abbreviations: CRT, chemoradiation therapy; DFI, disease free interval; DFS, disease-free survival; LOS, length of stay; LRC, locoregional control; LRFS, locoregional failure/recurrence-free survival; MRI, magnetic resonance imaging; ONB, olfactory neuroblastoma; OS, overall survival; PFS, progression-free survival; PNI, perineural invasion; RT, radiation therapy; SNM, sinonasal malignancy; SS, salvage therapy.

Aggregate grade of evidence: C (Level 2: two studies; Level 3: two studies; Level 4: four studies)

C | Role of re-irradiation

Although several studies have assessed the role of reirradiation regimens for the treatment of local recurrences of various head and neck tumors, few are specific for recurrent SNM (Table XIII.3).^{438–444} The heterogeneity of the studies in terms of tumor site, histology, and the use of reirradiation alone or as an adjuvant therapy to salvage surgery, as well as the short follow-up, makes it difficult to draw meaningful conclusions. From the limited data available, reirradiation of local SNM recurrences appears to be feasible, but it is typically associated with a significant rate of toxicity, reaching above 20% of grade 3 or higher toxicities.^{439,440} This may limit its use for recurrent SNM. To better understand the role of reirradiation for recurrent SNM, further studies are needed with longer term follow-up. Focus purely on tumors of the sinonasal cavity with analysis according to histological subtype based on different radiosensitivities is required.

Aggregate grade of evidence: C (Level 3: two studies; Level 4: five studies)

D | Role of palliative therapies

Studies evaluating the role of palliative therapy for recurrent SNM are few and of low-level evidence. Of the studies reported, most are concerned with the effect of palliative therapy on symptom control and QOL. Cited

examples of this include improvement of nasal obstruction and subjective breathing, epistaxis control, decompression of neurovascular structures, or pain.⁶ Of all the treatment modalities, RT is the best studied in this setting and has been shown to have a role in alleviating cranial nerve dysfunction and trigeminal pain due to skull base involvement by malignant tumors (metastases, recurrence, or advanced disease). However, the magnitude of its effect and associated morbidity requires further study (Table XIII.4).^{445–450} The role of palliative surgery and chemotherapy for recurrent SNM is less clear. One case series describing the role of surgical palliation in head and neck cancer included eight patients with chronic bleeding due to maxillary cancer ulceration, requiring regular admissions and blood transfusions. These patients were successfully managed with total maxillectomy, which reduced their rates of hospital admission and need for transfusions.⁴⁵¹

Recently, Farber et al. published their review of the NCDB aimed at assessing the impact of palliative treatment on survival in SNM.⁴⁵² In their review of 380 patients undergoing palliative therapy for SNM, they reported superior OS in patients undergoing palliative surgery. Specifically, 1-year OS (74.7% vs. 35.3%) and median OS were significantly higher in surgery compared to pain management (22.8 vs. 4.6 months). It should be noted that, of all patients analyzed, only 37 patients (9.7%) had palliative surgery as the sole treatment, with RT and multimodality treatments more commonly performed. Furthermore, the study did not assess QOL or report on the clinical decision-making behind choice of treatment, making it difficult to draw firm conclusions on the superiority of different palliative treatments.

TABLE XIII.3 Evidence surrounding re-irradiation of sinonasal tumors.

Study	Year	LOE	Study design	Study groups	Clinical endpoints	Conclusion
Fan et al. ⁴⁴²	2020	3	Retrospective cohort	86 patients with SNM (68 RT-naïve and 18 re-RT) received either 3DCPT or IMPT	1. 2-year LC 2. DC 3. DFS 4. OS 5. Toxicity	1. Re-irradiated patients had worse LC, DC, DFS, and OS compared to RT-naïve patients 2. Posttreatment radionecrosis was more common and appeared earlier in re-irradiated patients compared to RT-naïve patients
Bahig et al. ⁴⁴³	2020	3	Prospective cohort	39 patients with recurrent SB tumors with prior history of RT treated with varying modalities of re-RT	1. 1- and 2-year LC 2. HRQoL (MDASI-BT and ASBQ)	Although conformal skull base re-RT is associated with immediate deterioration in physical function, recovery is rapid and sustained
Yamazaki et al. ⁴⁴⁴	2021	4	Retrospective case series	78 recurrent SN tumors treated with re-RT (SBRT 68, IMRT 8, 3D-CRT 2)	1. 2-year OS 2. LC 3. Toxicity	1. Re-RT of SN tumors is significantly associated with adverse events, including significant disease-related toxicities 2. Incidence of distant metastasis was relatively high after reirradiation
Gao et al. ⁴³⁹	2019	4	Retrospective case series	141 locoregionally recurrent malignancies treated with re-RT (CIRT)	1. 1-year OS 2. LC 3. RC 4. DMFS 5. Toxicity	Treatment adverse effects and response are favorable with CIRT and patients previously treated with radiation
Gogineni et al. ⁴⁴⁰	2019	4	Retrospective case series	60 recurrent head and neck malignancies treated with re-RT (SBRT)	1. 1 and 2-year OS 2. LC 3. RC 4. DC 5. QoL (MDADI and MDASI) 6. Toxicity	SBRT re-RT shows comparable OS and LC to other re-RT treatment modalities with potential for lower toxicities and maintained QOL
Hayashi et al. ⁴⁴¹	2019	4	Retrospective case series	48 recurrent head and neck malignancies treated with re-RT (CIRT) after primary CIRT	1. 2-year OS 2. LC 3. LRC 4. PFS 5. Toxicity	re-RT using CIRT maybe superior to other re-RT modalities with tolerable toxicity for patients with recurrent head and neck malignancies after CIRT
Iwata et al. ⁴³⁸	2012	4	Retrospective case series	51 recurrent SN carcinomas, all M0 treated with re-RT (SRS)	1. 1-year OS 2. LC 3. Toxicity	1. CK re-RT is feasible and effective for local control of recurrent SN carcinomas 2. Late complications not determined by tumor volume or interval from the previous radiotherapy 3. Severe complications in the skin and soft tissue commonly occurred

Abbreviations: 3DCPT, three-dimensional conformal proton technique; ASBQ, anterior skull base surgery quality of life; CK, CyberKnife; CIRT, carbon ion radiotherapy; CRT, chemoradiation therapy; DC, distant control; DFS, disease-free survival; DMFS, distant metastasis-free survival; HRQOL, health-related quality of life; IMPT, intensity-modulated proton therapy; LC, local control; MDASI-BT, MD Anderson Symptom Inventory Brain Tumor; PFS, progression-free survival; PT, proton therapy; RC, regional control; re-RT, re-irradiation; SB, skull base; SBRT, stereotactic body radiotherapy; SN, sinonasal; SRS, stereotactic radiosurgery; SS, salvage surgery.

TABLE XIII.4 Evidence surrounding palliative use of radiotherapy to treat skull base involvement of advanced or recurrent sinonasal malignancies.

Study	Year	LOE	Study design	Study groups	Clinical endpoints	Conclusion
Phan et al. ⁴⁵⁰	2018	4	Retrospective case series	26 patients with recurrent SB malignancy treated with GKRS for trigeminal pain palliation	Symptom/pain palliation	GKRS is useful for the palliation of trigeminal pain secondary to recurrent malignant SB tumors with a significant decrease in patient reported pain and opioid requirement
Dröge et al. ⁴⁴⁹	2014	4	Retrospective case series	30 patients with SB metastases treated with EBRT	1. Neurological outcomes 2. OS 3. Toxicity	EBRT for SB metastases with CN deficits shows good therapeutic success in neurological outcomes with low toxicity rates
Clump et al. ⁴⁴⁸	2013	4	Retrospective case series	21 SB metastases in 18 patients treated with SRS	1. Neurological outcomes 2. OS 3. LC	SRS for palliation shows improvement in cranial neuropathies and pain with acceptable local control despite poor OS
Kano et al. ⁴⁴⁷	2009	4	Retrospective case series	37 CS invasion (metastasis or extension) treated with palliative SRS	1. 1- and 2-year OS 2. PFS 3. Neurological outcomes	1. SRS is a viable palliative option for symptomatic treatment of cancers that have invaded the cavernous sinus 2. SRS early after diagnosis was significantly associated with improvement of CN dysfunction
Pollock et al. ⁴⁴⁶	2000	4	Prospective case series	Eight recurrent/persistent SB malignancies treated with SRS (GKRS to tumor, not CNV)	Trigeminal neuralgia/painful neuropathy response	1. Radiosurgery was effective in improving tumor-related trigeminal pain 2. Recurrence of trigeminal pain was frequent and was related to tumor progression
Firlik et al. ⁴⁴⁵	1996	4	Retrospective case series	12 recurrent/persistent head and neck cancer involving SB treated with SRS	1. Clinical response 2. Radiographic response	Radiosurgery is associated with low risk of worsening cranial neuropathies with effective local control for recurrent cancer of the SB

Abbreviations: CNV, cranial nerve 5; CS, cavernous sinus; EBRT, external beam radiation therapy; GKRS, Gamma Knife radiosurgery; LC, local control; OS, overall survival; PFS, progression-free survival; SB, skull base; SRS, stereotactic radiosurgery; SN: sinonasal.

Orlandi et al. reported on the results of palliative chemotherapy for patients with recurrent locally advanced sinonasal epithelial carcinomas (keratinizing and nonkeratinizing SCC, SNEC, SNUC) initially treated with multimodal therapy. Of the 14 patients who received palliative chemotherapy, those who objectively responded had a median OS of 29.2 months compared to the nonresponders who had a median OS of 4.4 months.⁴³⁵ Another systemic therapy studied in the setting of palliation is peptide receptor radionuclide therapy (PRRT) for ONB. In a series of seven recurrent or metastatic ONBs deemed unsuitable for further conventional therapies and high somatostatin receptors expression, PRRT showed some benefit, with four patients showing partial response and two with disease stabilization.⁴⁵³

Aggregate grade of evidence: C (Level 4: six studies)

E | Differences in outcomes between primary and salvage treatment

It is well accepted that outcomes of primary treatment are superior to those of salvage treatment. However, review of the literature fails to identify any studies that directly compare the outcomes of these treatments. Furthermore, the studies that do report on the outcomes of salvage treatment do not provide a breakdown based on histological subtype, but rather report generally on all SNMs or group them according to their biological behavior due to the low number of cases available for analysis.

TABLE XIII.5 Evidence surrounding neck management in N0 olfactory neuroblastoma.

Study	Year	LOE	Study design	Study groups	Clinical endpoints	Conclusion
Peacock et al. ⁴²⁹	2017	3	Retrospective cohort	52 ONB treated with either SART or SA without elective neck dissection	1. RFS 2. Cervical LN RFS 3. DMRFS 4. ARFS 5. OS	1. Radiotherapy significantly reduces local recurrence 2. Treatment of the N0 neck is not recommended and can be observed for clinical evidence of cervical disease
Jiang et al. ⁴⁵⁵	2015	3	Retrospective cohort	71 ONB modified Kadish A/B/C ENI+ (<i>n</i> = 22) versus ENI- (<i>n</i> = 49)	1. OS 2. PFS 3. LRC 4. DM	1. No difference in OS and DFS with or without ENI 2. ENI resulted in improved regional control 3. Rescue treatment of neck is effective
Song et al. ⁴⁵⁷	2020	4	Retrospective case series	217 ONB treated with combination of RT, chemotherapy and/or surgical resection	1. OS 2. PFS 3. RFS 4. DMFS 5. Incidence and location of lymph node metastasis	1. N+ at presentation was an independent prognostic factor for a poor OS 2. No difference in OS and PFS with or without ENI 3. ENI reduced the regional failure significantly 4. No difference in DMFS with or without ENI 5. Rescue treatment of neck is effective
Yin et al. ⁴⁵⁶	2015	4	Retrospective case series	80 ONB modified Kadish B/C ENI+ (<i>n</i> = 50) versus ENI- (<i>n</i> = 30)	OS DFS RRFS DMFS	1. No difference in OS and DFS with or without ENI 2. ENI reduced the regional failure significantly 3. No difference in DMFS with or without ENI

Abbreviations: ARFS, any recurrence-free survival; DMRFS, distant metastasis recurrence-free survival; ENI, elective neck irradiation; ENI+, receiving elective neck irradiation; ENI-, not receiving elective neck irradiation; LN, lymph node; LNM, late neck metastases; ND, neck dissection; OS, overall survival; PFS, progression-free survival; RFS, recurrence-free survival; RRFS, regional recurrence free; SA, surgery alone; SART, surgery and adjuvant radiotherapy.

Two histological subtypes that have treatment outcomes compared, though not within the same cohorts, between primary and salvage therapy are maxillary sinus SCC and ONB. Homma et al. reported a 5-year OS of 67.6% in 54 patients primarily treated with RADPLAT for maxillary SCC.⁴⁵⁴ Similar survival rates have also been seen for recurrent maxillary SCC initially treated with RADPLAT, with a study reporting a 5-year OS of 68% for salvage surgery for these tumors.⁴³⁴ However, survival outcomes were lower in a study by Ono et al. who observed a 2-year OS of 45.8% of patients undergoing salvage surgery and 11.1% for patients treated only with chemotherapy or palliation.⁴³³

The management of the N0 neck in patients with ONB has also been well studied. Interestingly, although there is significant evidence showing that elective neck irradiation (ENI) decreases the rate of late neck metastasis, three studies have failed to show that this translates into improved OS (Table XIII.5).^{455–457} Whether forgoing ENI in ONB patients and only treating recurrent neck disease when it

occurs is something that warrants further study. This is supported by the series from Peacock et al. that included 58 ONB patients with a mean follow-up of 13.8 years.⁴²⁹ They showed a 4-year regional RFS of 70% after neck salvage surgery with or without RT and concluded that, although delayed cervical lymph node metastasis is common, it is generally indolent and can be managed effectively with salvage treatment in most patients.

Aggregate grade of evidence: C (Level 3: two studies; Level 4: two studies)

Recurrent SNM disease creates various treatment challenges with limited research available and thus eligible patients should be assessed systematically by a multidisciplinary team with experience in surgical salvage, reirradiation, chemotherapy, systemic therapies, and palliative care. Where possible, treatment should be based on prognostic indicators as well as the morbidity associated with the different treatment modalities. SNM presents a significant rate of failure after initial successful treat-

ment, with local recurrence being the main reason. Due to the rarity of these tumors and histological variability, there is a paucity of studies specifically addressing salvage treatment for the different types of SNMs. Although the evidence available is limited and of low quality, it does suggest that salvage treatment may improve the outcome of patients with locoregional recurrences. When possible, salvage surgery, with the aim of obtaining negative surgical margins, and adjuvant RT (including reirradiation) appear to be the best option. In cases where further surgery is not feasible, reirradiation with curative intent remains an alternative, although further research in this area is required. Studies with longer follow-up, focusing particularly on the different histological subtypes of SNM sharing similar radiosensitivities, are required to better judge its efficacy. Toxicity varies according to the method employed but, in general, appears acceptable. Due to the rarity of these malignancies and the diverse range of histological types with different behaviors, large prospective studies remain difficult to conduct. For this reason, large-scale collaborative multicenter studies with pooling of resources remain the most likely source of future evidence.

XIV | RADIATION MODALITIES FOR TREATMENT OF SINONASAL MALIGNANCIES

Technical advances have accelerated the development of highly conformal, image-guided (IG) external beam radiotherapy (EBRT). IG-EBRT can be delivered with multiple treatment modalities, including conventional photons such as static or rotational IMRT and particle therapy (PT).

These techniques allow dose escalation and geometric conformity, which are critical for the safe and effective treatment of SNM. Cancers of this anatomic region portend a high risk of tumor recurrence as well as treatment complications from intense multimodality therapies that include surgery, radiation, and chemotherapy. SNMs are often situated immediately adjacent to sensitive neurovascular tissues (optic apparatus, brainstem, spinal cord, brain parenchyma, auditory structures, mandible, aerodigestive tract mucosa, and/or salivary glands), all of which provide vital functions for daily living and maintaining QOL. Thus, IMRT has been a major advancement in sparing these normal tissues and is the current standard for clinical practice worldwide.^{22,458,459}

PT is an emerging clinical tool using neutrons, protons, or carbon ions for therapeutic intervention. Because of the physical properties of particle dosimetry, other than neutrons, these modalities can reduce the integral dose, specifically low and moderate radiotherapy doses, to surrounding normal tissues. Proton beam therapy (PBT) is

the most widespread of this category, showing an association of improved oncologic control for treating SNM over IMRT.⁴⁵⁸ Fast neutron therapy (NRT) and carbon ion radiotherapy (CIRT) involve heavy particles with a higher relative biological effectiveness (RBE), potentially allowing for biologic therapy intensification for those with residual disease of radioresistant pathologies.^{458,460–463}

Significant heterogeneity in literature across patient demographics, stage, pathologies, and treatment status (including prior intervention and extent of residual disease at the time of radiotherapeutic intervention) makes direct comparisons challenging. Furthermore, even among similar modalities, differences in practice patterns and technical operations exist. This section aims to summarize the evidence on the role of RT and different modalities on management of SNM. Of note, this section does not cover radiation treatment of chordoma or skull base chondrosarcoma, which is covered in ICSB 2019 Sections IX.A.6 and IX.B.1, respectively.⁵ Section XXX.II covers morbidity related to RT.

A | Intensity-modulated radiotherapy

Commercially available since the early 2000s, IMRT has quickly become the primary radiation delivery method in advanced centers. Benefits are multifactorial, with short treatment times and the ability to deliver multiple noncoplanar beam angles by rotational arcs with high dose rates and sophisticated multileaf collimation. IMRT can thus generate steep dose gradients and high dose conformity, which is essential for treating SNM.

When compared to two-dimensional and three-dimensional conformal radiotherapy techniques (2DCRT and 3DCRT, respectively), retrospective case series show that IMRT has reduced toxicity and local control (LC) and OS benefits (Table XIV.1). Al-Mamgani et al. reviewed 82 patients with SNM and reported that, though late grade 2 toxicity was seen in over 25% of patients 5 years after treatment, it was significantly lower when using IMRT compared to 3DCRT (17% vs. 52%, $p < 0.0001$). Not only was visual preservation improved using IMRT (88% vs. 65%; $p = 0.01$), but it also demonstrated LC advantages (80% vs. 64%; $p = 0.2$).⁴⁶²

Furthermore, Duprez et al. reviewed 130 SNM patients treated with IMRT. While they observed late grade 3 ocular toxicity in 11 patients, no radiation-induced blindness was observed. Actuarial 5-year LC and OS rates were 59% and 52%, respectively. They concluded that IMRT could deliver high therapeutic doses and minimize ocular complications and should be the SNM treatment standard.⁴⁶⁴ The adoption of IMRT and multimodality therapy was further corroborated in a phase-4 national study in Denmark.

TABLE XIV.1 Evidence surrounding IMRT in treatment of sinonasal tumors.

Study	Year	LOE	Study design	Study groups	Clinical endpoints	Conclusion
Zhang et al. ⁴⁷⁴	2020	2	Systematic review and meta-analysis	44 cohorts comparing 2282 patients treated with CIRT, PBT or IMRT (IMRT, $n = 772$)	1. 3-year LC 2. 3-year OS	1. LC 68% 2. OS 64% 3. LC and OS were significantly higher after CIRT than PBT or IMRT 4. No significant difference between PRT and IMRT for OS and LC was observed
Liang et al. ⁴⁷⁵	2018	2	Systematic review	20 studies evaluating IMRT for SNM ($n = 1274$)	Clinical outcomes	IMRT has contributed to the substantial improvement in clinical outcomes of these patients, both in terms of primary tumor control and avoidance of toxicities
Patel et al. ⁴⁵⁸	2014	2	Systematic review and meta-analysis	41 studies evaluating SNM patients undergoing either particle or photon radiotherapy ($n = 1472$; IMRT therapy $n = 187$ for DFS and $n = 212$ for OS)	1. Longest follow-up LRC 2. 5-year DFS 3. 5-year OS	1. LRC 0.64 (95% CI: 0.57–0.72) 2. DFS 0.5 (95% CI: 0.38–0.67) 3. OS 0.48 (95% CI: 0.38–0.60) 4. PBT showed significantly higher DFS at 5-year and LRC at longest follow-up compared to IMRT
Patel et al. ⁴⁷⁶	2020	3	Retrospective cohort	SNM at a single institution ($n = 60$)	Toxicity	10.4% ($n = 12$) of patients had postoperative complications, and 21.0% ($n = 22$) had high-grade (grade 3–5) RT toxicity
Filtborg et al. ⁴⁶⁵	2021	4	Retrospective database review (DAHANCA)	SNM across multi-institutional national database ($n = 331$)	1. Guideline compliance 2. 5-year OS	1. Noncompliance was associated with LRF 2. 5-year OS was 56% in patients treated with curative intent 3. Combined treatment strategy showed reduced LRF
Klymenko et al. ⁴⁷⁷	2021	4	Retrospective case series	SNM at a single institution ($n = 53$)	OS	1. OS 33 months 2. Pretherapeutic GTV was prognostic (cutoff 75 cm ³)
Korra et al. ⁴⁷⁸	2021	4	Retrospective case series	ONB at a single institution ($n = 13$)	1. 5-year OS 2. RFS	Induction chemotherapy followed by radiation gives the best outcomes
Laskar et al. ⁴⁷⁹	2021	4	Retrospective case series	SNM at a single institution ($n = 214$)	1. 5-year LC 2. 5-year PFS 3. 5-year OS	1. LC 67% 2. PFS 59% 3. OS 74%
Owin et al. ⁴⁸⁰	2021	4	Retrospective case series	SNM at a single institution ($n = 104$; IMRT $n = 88$, 3DCRT $n = 13$; NRT $n = 3$)	1. LRC 2. Tox	1. The locoregional recurrence rate was 18% following IMRT versus 31% in the two/three-dimensional conventional RT group ($p = 0.09$) 2. IMRT was associated with a lower inner ear toxicity rate (8% vs. 20%, respectively; $p = 0.045$)
Slevin et al. ⁴⁸¹	2021	4	Retrospective case series	SNM across four institutions ($n = 56$)	1. 5-year PFS 2. 5-year OS	1. PFS 24% 2. OS 30%

(Continues)

TABLE XIV.1 (Continued)

Study	Year	LOE	Study design	Study groups	Clinical endpoints	Conclusion
Swain et al. ⁴⁸²	2021	4	Retrospective case series	ACC at a single institution (SNM $n = 13$)	5-year LPFS	LPFS 51%
Ting et al. ⁴⁸³	2021	4	Retrospective case series	SNM at a single institution ($n = 7$)	Ocular and periocular complications following EBRT	High-dose EBRT for inoperable maxillary sinus tumors can lead to a wide array of severe ocular/periocular complications
Zeng et al. ⁴⁸⁴	2021	4	Retrospective case series	ONB at a single institution ($n = 64$)	OS	Surgery combined with RT with or without chemotherapy resulted in significantly better OS (84.4 vs. 50.6%, 84.4 vs. 37.5%) compared to surgery alone and RT alone
Chen et al. ⁴⁸⁵	2021	4	Retrospective case series	SNM at a single institution ($n = 49$, helical tomotherapy)	1. 5-year PFS 2. 5-year OS	1. PFS 63% 2. OS 55%
Bao et al. ⁴⁸⁶	2020	4	Retrospective case series	ONB at a single institution ($n = 52$)	1. 3-year LPFS 2. 3-year OS	1. LPFS 90% 2. OS 90% 3. Severe late toxicities were infrequent (11.5%)
Ferella et al. ⁴⁸⁷	2020	4	Retrospective case series	SNM at a single institution ($n = 34$)	Tumor volume association with PFS and OS	Smaller disease burden showing improved oncologic control
Li et al. ¹⁶⁴	2020	4	Retrospective case series	SNM at a single institution ($n = 93$; IMRT $n = 38$, 3DCRT $n = 55$)	1. 5-year OS	1. OS 57% 2. 5-year PFS and OS were similar between RT \pm surgery
Liu et al. ⁴⁸⁸	2020	4	Retrospective case series	ONB at a single institution ($n = 37$) comparing CRT \pm surgery	1. 5-year OS 2. 5-year PFS 3. 5-year LRFS	In IMRT era, no differences in OS, PFS, or LFRS between CRT \pm surgery
Sharma et al. ⁴⁸⁹	2020	4	Retrospective case series	SNM across multi-institutional national database ($n = 184$)	Patterns of failure	76 (41%) of patients relapsed, and the majority were in the involved primary site (76%)
Sharma et al. ⁴⁹⁰	2020	4	Retrospective case series	SNM at two centers in Denmark ($n = 27$)	Cerebral toxicity	Clinically significant cognitive impairment was present in more than one third of the participants, and several dose-response associations were present
Sharma et al. ⁴⁹¹	2020	4	Retrospective case series	SNM at two centers in Denmark ($n = 27$)	Late toxicity	Late toxicity after RT was substantial in all examined organs, with dose-response associations between visual acuity impairment and the optic nerve

(Continues)

TABLE XIV.1 (Continued)

Study	Year	LOE	Study design	Study groups	Clinical endpoints	Conclusion
Sun et al. ³⁹⁶	2020	4	Retrospective case series	ONB at a single institution (IMRT <i>n</i> = 71, 60 conventional/3DCRT)	1. 5-year OS 2. 5-year LRRFS	1. OS 70% 2. LRRFS 78% 3. Orbital invasion, intracranial invasion, lymph node metastasis, and advanced Kadish disease at initial diagnosis were significantly associated with inferior prognosis
Wang et al. ⁴⁹²	2020	4	Retrospective case series	SNM at a single institution (<i>n</i> = 140; IMRT <i>n</i> = 84, 2D/3DCRT = 56)	1. 5-year LC 2. 5-year DFS 3. 5-year OS	1. LC 66% 2. DFS 58% 3. OS 62% 4. Orbital content retention rate in preoperative RT group was 85.7%, superior to 58.3% in postoperative RT group
Frederic-Moreau et al. ⁴⁹³	2019	4	Retrospective case series	SNM at a single institution (IMRT <i>n</i> = 34, 3DCRT = 24)	1. 3-year LC VMAT/3DCRT 2. 3-year OS MVAT/3DCRT	1. LC 85%/65% 2. 81%/63% 3. Reduction of acute and late ocular toxicity of grade ≥ 2 with VMAT
Guazzo et al. ⁴⁹⁴	2019	4	Retrospective case series	ACC at a single institution (SNM <i>n</i> = 17)	1. 5-year LRC 2. 5-year OS	1. LRC 88% 2. OS 92%
Li et al. ⁴⁹⁵	2019	4	Retrospective case series	ONB at a single institution (<i>n</i> = 88; IMRT <i>n</i> = 26, 3DCRT <i>n</i> = 34)	1. 5-year OS RT alone 2. 5-year OS postop RT	1. OS 64% 2. OS 71% 3. 5-year LRRFS survival was 100% in patients with ENI and 58% in patients without ENI
Fu et al. ³⁸⁰	2018	4	Retrospective case series	SNM at a single institution (<i>n</i> = 84)	Margin status neoadjuvant versus adjuvant RT	Neoadjuvant RT was associated with an 81% decreased odds of positive margins
Lee et al. ⁴⁹⁶	2018	4	Retrospective case series	SNM at a single institution (<i>n</i> = 40; IMRT <i>n</i> = 35, 3DCRT <i>n</i> = 5)	ENI impact on OS and PFS	There was no significant difference between the ENI (+) and ENI (−) groups regarding OS and PFS
de Bonnecaze et al. ⁴⁹⁷	2018	4	Retrospective case series	SNM at a single institution (<i>n</i> = 54)	1. 3-year RFS 2. 3-year OS	1. RFS 48% 2. OS 62%
Chopra et al. ⁴⁹⁸	2017	4	Retrospective case series	SNM at a single institution (<i>n</i> = 23)	1. 5-year PFS 2. 5-year OS	1. PFS 30% 2. OS 60%
Gamez et al. ⁴⁹⁹	2017	4	Retrospective case series	SNM at a single institution (IMRT = 24, 3DCRT = 12, other = 4)	1. 5-year LRC 2. 5-year OS	1. LRC 71% 2. OS 44% 3. Better outcomes were obtained with a trimodality approach and doses ≥ 60 Gy
Ahmad et al. ⁵⁰⁰	2016	4	Retrospective case series	SNM at a single institution (<i>n</i> = 26)	Intracranial radiation necrosis	Patients with STR and rapid onset of MRI changes in post-surveillance scans are more likely to have tumor recurrence versus radiation necrosis

(Continues)

TABLE XIV.1 (Continued)

Study	Year	LOE	Study design	Study groups	Clinical endpoints	Conclusion
Amsbaugh et al. ⁵⁰¹	2016	4	Retrospective case series	SNM at a single institution treated with orbital preservation ($n = 14$) versus exenteration ($n = 6$)	1. 2-year LRC 2. 2-year PFS 3. 2-year OS	At 2 years, there were no significant differences in LRC, PFS, or OS between those undergoing orbital preservation
Askoxylakis et al. ⁵⁰²	2016	4	Retrospective case series	SNM at a single institution ($n = 122$)	1. 5-year LC 2. 5-year PFS 3. 5-year OS	1. LC 51% 2. PFS 47% 3. OS 54%
Burt et al. ⁵⁰³	2016	4	Retrospective case series	SNM at a single institution ($n = 11$)	1. LC 2. G3 Tox	1. LC 73% 2. Tox 18%
Suh et al. ⁵⁰⁴	2016	4	Retrospective case series	SNM at a single institution ($n = 54$; IMRT $n = 19$, 3DCRT $n = 35$)	1. 3-year LRC IMRT 2. 3-year LRC 3DCRT	1. LRC IMRT 89% 2. LRC 3DCRT 60%
Yin et al. ⁵⁰⁵	2016	4	Retrospective case series	ONB at a single institution (IMRT $n = 44$, conventional $n = 63$)	1. 5-year LRC 2. 5-year OS	1. LRC 73% 2. OS 65%
Duru Birgi et al. ⁵⁰⁶	2015	4	Retrospective case series	SNM at a single institution ($n = 43$)	1. 2-year LC 2. 2-year PFS 3. 2-year OS	1. LC 81% 2. PFS 71% 3. OS 80%
Batth et al. ⁵⁰⁷	2013	4	Retrospective case series	SNM at a single institution ($n = 40$)	Toxicity	The incidence of acute and late grade 3+ toxicity was 23% and 19%, and volumes receiving ≥ 20 Gy was the most significant predictor of late toxicity
Fried et al. ⁵⁰⁸	2013	4	Retrospective case series	SNM at a single institution (IMRT $n = 41$, 3DCRT $n = 38$)	1. 3-year LC 2. 3-year OS	1. LC 64% 2. OS 68% 3. SNM failed marginally or out-of-field in 53% (8/15) of LR and 31% (8/26) of all local failures
Guan et al. ⁵⁰⁹	2013	4	Retrospective case series	SNM at a single institution (IMRT $n = 43$, 3DCRT $n = 16$)	1. 3-year LRC 2. 3-year OS	1. LRC 63% 2. OS 69% 3. Level Ib and level IIa were the most common sites of cervical nodal recurrence 4. None of the 11 patients who received ENI developed failure in the neck
Kaur et al. ⁵¹⁰	2013	4	Retrospective case series	ONB at a single institution (IMRT $n = 6$, EBRT $n = 5$)	1. 5-year PFS low/high grade 2. 5-year OS low/high grade	1. PFS 65%/49% 2. OS 86%/56% 3. Tumor histology appeared to be the best way of predicting the prognosis and selecting patients for adjuvant RT
Rajapurkar et al. ⁵¹¹	2013	4	Retrospective case series	SNM at a single institution (IMRT $n = 7$, 3DCRT $n = 7$)	1. LR 2. DFS	1. Eight local recurrences 2. 11 disease free at the end of follow-up

(Continues)

TABLE XIV.1 (Continued)

Study	Year	LOE	Study design	Study groups	Clinical endpoints	Conclusion
Buiret et al. ⁵¹²	2012	4	Retrospective case series	SN invasive papilloma at a single institution ($n = 11$; 3DCRT $n = 5$, IMRT $n = 6$)	1. LR	1. LR 45% 2. Degenerated IPs are thus aggressive diseases and must be treated similarly to primary SCC
Duprez et al. ⁴⁶⁴	2012	4	Retrospective case series	SNM at a single institution ($n = 130$)	1. 5-year LC 2. 5-year OS 3. G3 Ocular Tox	1. LC 59% 2. OS 52% 3. Worst grade of late ocular toxicity was Grade 3 ($n = 11$), Grade 2 ($n = 31$), Grade 1 ($n = 33$), and Grade 0 ($n = 11$)
Wiegner et al. ⁵¹³	2012	4	Retrospective case series	SNM at a single institution ($n = 52$)	1. 2-year LRC 2. 2-year OS	1. 2-year LRC 64% 2. 2-year OS 66% 3. Patients with SCC have worse LRC and OS 4. LRF is the predominant pattern of failure
Al-Mamgani et al. ⁴⁶²	2012	4	Retrospective case series	SNM at a single institution ($n = 82$, IMRT $n = 57$; 3DCRT $n = 25$)	1. 5-year LC 2. 5-year RC 3. 5-year OS 4. 5-year G2 Tox	1. LC 74% 2. RC 94% 3. OS 54% 4. G2 Tox 28% 5. Late toxicity was significantly lowered using IMRT, compared to 3DCRT (17% vs. 52%) 6. LC rate was also improved by IMRT (80% vs. 64%, respectively)
Dirix et al. ⁵¹⁴	2010	4	Retrospective case series	SNM at a single institution ($n = 40$)	1. 2-year LC 2. 2-year OS	1. LC 76% 2. OS 79%
Madani et al. ⁵¹⁵	2009	4	Retrospective case series	SNM at a single institution ($n = 84$)	1. 5-year LC 2. 5-year DFS 3. 5-year OS	1. LC 71% 2. DFS 59% 3. OS 59%
Hoppe et al. ⁵¹⁶	2008	4	Retrospective case series	SNM at a single institution (IMRT $n = 12$, conventional and three-dimensional $n = 27$)	1. 5-year LP 2. 5-year DFS 3. 5-year OS	1. LP 21% 2. DFS 51% 3. OS 15% 4. Severe late toxicities occurred in two patients 5. The only significant factor for disease control was a biologically equivalent dose of radiation ≥ 65 Gy
Hoppe et al. ⁴⁵⁹	2008	4	Retrospective case series	SNM at a single institution ($n = 37$)	1. 2-year LC 2. 2-year OS	1. LC 75% 2. OS 80%
Daly et al. ⁵¹⁷	2007	4	Retrospective case series	SNM at a single institution ($n = 36$)	1. 5-year LC 2. 5-year OS	1. LC 58% 2. OS 45%
Combs et al. ⁵¹⁸	2006	4	Retrospective case series	SNM at a single institution ($n = 46$)	1. 3-year LC 2. 3-year OS	1. LC 49% 2. OS 80%
Duthoy et al. ⁵¹⁹	2005	4	Retrospective case series	SNM at a single institution ($n = 39$)	1. 4-year LC 2. 4-year OS	1. LC 68% 2. OS 59%

Abbreviations: 3DCRT, three-dimensional conformal radiotherapy; DFS, disease-free survival; EBRT, external beam radiotherapy; ENI, elective nodal/neck irradiation; G2 Tox, grade 2 toxicity; G3 Ocular Tox, grade 3 ocular toxicity; IMRT, intensity modulated radiation therapy; LC, local control; LPPFS, local progression-free survival; LR, locoregional; LRC, local-regional control; LRF, locoregional failure; LRFPS, locoregional failure-free survival; LRPFS, locoregional progression-free survival; LRRFS, locoregional recurrence-free survival; OS, overall survival; PFS, progression-free survival; RC, regional control; SN, sinonasal; SNM, sinonasal malignancy; SNUC, sinonasal undifferentiated carcinoma.

Filtborg et al. reviewed a 331-patient nationwide clinical database (DAHANCA), showing that guideline compliance and a combined treatment approach reduced the incidence of LRF and thereby increased OS.⁴⁶⁵

In summary, retrospective cohort studies corroborate multiple single-institute studies demonstrating that IMRT allows for the maintenance of target coverage and avoidance of critical organs at risk (OARs) for SNM. The magnitude of locoregional control (LRC), DFS, and OS rate benefits depend on the extent of disease and pathology of the primary malignancy. IMRT is the standard therapy for photon radiation delivery for SNM at advanced cancer centers.

B | Proton beam therapy

PBT is the most widely available particle therapy for treating superficial and deep-seated tumors. Like IMRT, PBT allows for high-dose conformity, which is critical for the sensitive OARs adjacent to the skull base. In addition, PBT may also allow low- and moderate-dose reductions. Despite these benefits, the present treatment cost and geographic availability are limiting factors for PBT's widespread utilization. Favorably, a single cost-benefit analysis showed that PBT for SNM provided an extra 1.65 quality-adjusted life-year (QALY) at an additional cost of \$38,929 compared with IMRT, with an incremental cost-effectiveness ratio of \$23,611/QALY.⁴⁶⁶ This was secondary to improved DFS compared to IMRT, as demonstrated in a 2014 systematic review and meta-analysis. Patel et al. demonstrated that pooled OS and DFS rates were significantly higher at 5 years for PBT than for photon therapy (relative risk [RR] 1.51, 95% CI: 1.14–1.99; $p = 0.0038$ and RR 1.93, 95% CI: 1.36–2.75; $p = 0.0003$, respectively). Subgroup analysis specifically identified that PBT provided improved LRC (RR 1.26; $p = 0.011$) 5 years after treatment and DMFS rates (RR 1.44; $p = 0.045$) at the longest follow-up.⁴⁵⁸

In one of the largest published PBT series, Dagan et al. reviewed 143 patients at the University of Florida; the 5-year LRC rate was 78%, and the OS rate was 59%. Surgery improved LC rates, but only with GTR (5-year LC for GTR 87% vs. subtotal resection [STR] 62.9% vs. biopsy alone 55%; $p = 0.001$), and gross residual disease was the only significant prognostic factor for LRC rates on multivariate analysis. Late grade 3 toxicities were high at 22% (32 of 143), including central nervous system necrosis in 6% (9 of 143) and vision loss in 3.5% (five of 143).⁴⁶⁰

Fan et al. evaluated 86 prospective patients with PBT. The 2-year LC and OS rates for radiation-naïve patients were 83% and 81%, respectively. Nearly 25% experienced acute grade 3 toxicities, and 6% experienced late grade 3 toxicities, including osteoradionecrosis (ORN), vision

loss, and soft tissue necrosis/fibrosis.⁴⁴² While these studies reflect promising treatment outcomes related to PBT's physical dosimetry, further proton research focusing on technical improvements, including dynamic arc and biologic enhancement (e.g., RBE optimization, FLASH, proton boron capture therapy), may further impact the therapeutic ratio.⁴⁶⁷

In summary, retrospective cohort studies and a systematic review show that PBT allows for target coverage maintenance, high-dose RT conformity, and low- and moderate-dose radiation bath reductions (Table XIV.2). The magnitude of LRC, DFS, and OS rate benefits depends on the extent of disease and pathology of the primary malignancy. While IMRT is the standard therapy for SNM at most cancer centers, PT (particularly PBT) may provide further benefits in LRC and DFS rates and should be considered when available.

C | Fast neutron radiotherapy

While initial studies (particularly for head and neck and salivary gland malignancies) showed higher disease control rates compared to photon therapies, only a few centers worldwide have adopted and maintained the capacity to use NRT. While this initial promise in both retrospective and randomized trials showed improved LC rates, progress was stifled by concerns about higher toxicity rates. In addition, improvements in conventional photon conformity and the shielding requirements of neutrons (among others) lead to NRT's near abandonment. This is despite improvements in beam profile safety that may make neutron delivery more practical for treatment.^{468,469}

Douglas et al. studied 279 patients, of which 43 had SNM. The 6-year LRC and DSS rates were 59% and 67%, respectively, and grade 3 or higher complications were seen in 10% of patients. More recently, neutrons have been used in combination with PBT. In 2021, Aljabab et al. published a combined NRT-PBT cohort of 29 patients with unresectable skull base salivary gland tumors, including 12 SNM patients. LC, PFS, and OS rates were 90%, 79%, and 93%, respectively. Ten late grade 3 or 4 events were documented.⁴⁶³

In summary, retrospective cohort studies show that NRT can improve LRC, PFS, and OS rates in SNM, with the magnitude of the benefits dependent on the extent of disease and pathology of the primary malignancy (Table XIV.3). However, almost all data were collected on patients treated before 2000 without three-dimensional isodose dose distribution evaluation and plan review. Therefore, any comparison of NRT within the literature is not equivalent to modern outcomes with IMRT, PBT, or CIRT, as it was conducted without modern, surrounding medical

TABLE XIV.2 Evidence surrounding proton therapy in treatment of sinonasal tumors.

Study	Year	LOE	Study design	Study groups	Clinical endpoints	Conclusion
Zhang et al. ⁴⁷⁴	2020	2	Systematic review and meta-analysis	44 cohorts comparing 2282 patients treated with CIRT, PBT, or IMRT (PBT, <i>n</i> = 599)	1. 3-year LC 2. 3-year OS	1. LC 73% 2. OS 66% 3. LC and OS were significantly higher after CIRT than PBT or IMRT 4. No significant difference between PRT and IMRT for OS and LC was observed
Patel et al. ⁴⁵⁸	2014	2	Systematic review and meta-analysis	41 studies (43 cohorts) comparing SNM patients undergoing either particle or photon radiotherapy (<i>n</i> = 1472; IMRT therapy <i>n</i> = 36 for DFS and <i>n</i> = 147 for OS)	Endpoints: 1. Longest follow-up LRC 2. 5-year DFS 3. 5-year OS	1. LRC 0.81 (0.71–0.92) 2. DFS 0.72 (0.59–0.89) 3. OS 0.66 (0.52–0.85) 4. Subgroup analysis comparing PBT with IMRT, PBT showed significantly higher DFS at 5 years and LRC at longest follow-up
Fan et al. ⁴⁴²	2020	3	Retrospective cohort	SNM at single institution (<i>n</i> = 86); included 18, reirradiation pts	1. 2-year LC 2. 2-year DFS 3. 2-year OS	1. LC 82% 2. DFS 70% 3. OS 77% 4. Patients who received re-irradiation had higher complications compared to de novo
Dagan et al. ⁴⁶⁰	2021	4	Retrospective case series	SNM at single institution (<i>n</i> = 143)	1. 5-year PFS 2. 5-year CCS 3. 5-year OS	1. PFS 62% 2. CCS 59% 3. OS 64% 4. Patients who underwent GTR had an 87% LC rate
Nakajima et al. ⁵²⁰	2021	4	Retrospective case series	SNM at single institution (<i>n</i> = 62)	1. 2-year LC 2. 2-year PFS 3. 2-year OS	1. LC 92% 2. PFS 50% 3. OS 76% 4. 16 grade ≥3 late toxicities were observed in 12 patients (19%), including 11 events resulting in visual impairment
Hu et al. ⁵²¹	2020	4	Retrospective case series	ONB at single institution (<i>n</i> = 12)	1. 2-year PFS 2. 2-year OS	1. PFS 76% 2. OS 83%
Li et al. ⁴⁶⁶	2020	4	Cost effectiveness analysis	Analysis using a single SNM patient scenario	ICER	IMPT provided an extra 1.65 QALYs at an additional cost of \$38,928.7 compared with IMRT and had an ICER of \$23,611.2/QALY
Pasalic et al. ⁵²²	2020	4	Retrospective case series	SNM at single institution (<i>n</i> = 64)	1. 3-year LC 2. 3-year DFS 3. 3-year OS	1. LC 88% 2. DFS 76% 3. OS 82% 4. Low grade ≥3 toxicity, and PROs suggest significant changes in the acute–subacute period but no chronic sequelae
Lee et al. ⁵²³	2019	4	Retrospective database review (NCDB)	NCDB review of proton utilization for head and neck cancer (<i>n</i> = 220,491)	Proton utilization and determining factors	The most common primary site treated with proton therapy was the nasal cavity/nasopharynx (<i>n</i> = 151; 36.2%)

(Continues)

TABLE XIV.2 (Continued)

Study	Year	LOE	Study design	Study groups	Clinical endpoints	Conclusion
Yu et al. ⁵²⁴	2019	4	Retrospective case series	SNM multi-institutional of de novo (<i>n</i> = 42) or re-irradiation (<i>n</i> = 27)	1. 3-year FFLR (local-reg) 2. 3-year FFDP 3. 3-year OS	1. 93%/34% 2. 77%/32% 3. 100%/76% 4. re-RT was associated with inferior FFLR 5. Late toxicities occurred in 15% of patients, with no grade 3 or + toxicities 6. No patients developed vision loss or symptomatic brain necrosis
Dautruche et al. ⁵²⁵	2018	4	Retrospective case series	ACC at single institution (SNM <i>n</i> = 8)	1. 3-year LC 2. 3-year OS	1. LC 60% 2. OS 60%
Nakamura et al. ⁵²⁶	2017	4	Retrospective case series	ONB at single institution (<i>n</i> = 42)	1. 5-year PFS A/B/C 2. 5-year OS A/B/C Stratified by Kadish stage	1. PFS 80%/65%/39% 2. OS 100%/86%/76% 3. Late adverse events of grade 3–4 were seen in six patients (ipsilateral visual impairment, 3; bilateral visual impairment, 1; liquorrhea, 1; cataract, 1)
Dagan et al. ⁵²⁷	2016	4	Retrospective case series	SNM at single institution (<i>n</i> = 84)	1. 3-year PFS 2. 3-year CCS 3. 3-year OS	1. PFS 63% 2. CCS 70% 3. OS 68% 4. Patients who underwent GTR had a 90% LC rate
Russo et al. ⁵²⁸	2016	4	Retrospective case series	SNM at single institution (<i>n</i> = 44)	1. 5-year LC 2. 5-year OS 3. Toxicity	1. LC 80% 2. OS 47% 3. Nine grade 3 and 6 grade 4 toxicities, and no grade 5 toxicities
Lucas et al. ⁵²⁹	2015	4	Retrospective case series	Pediatric ONB at single institution (<i>n</i> = 8)	1. 4-year OS	1. OS 88% 2. Two cases of grade 2 retinopathy and one case of grade 3 optic neuropathy
Saito et al. ⁵³⁰	2015	4	Retrospective case series	SNM at single institution (<i>n</i> = 7)	LC	LC was achieved in 43% of patients
Zenda et al. ⁵³¹	2015	4	Retrospective case series	SNM at single institution primary (<i>n</i> = 90)	1. 5-year PFS 2. 5-year OS 3. 5-year toxicities	1. PFS 45% 2. OS 64% 3. Tox 19%
Herr et al. ⁵³²	2014	4	Retrospective case series	ONB at single institution (<i>n</i> = 22)	1. 5-year DFS 2. 5-year OS	1. LC 86% 2. OS 95% 3. High incidence of regional metastases warrants strong consideration for ENI
Fukumitsu et al. ⁵³³	2012	4	Retrospective case series	SNM at single institution (Unresectable <i>n</i> = 17)	1. 5-year LC 2. 5-year OS	1. LC 18% 2. OS 16%
Okano et al. ⁵³⁴	2012	4	Retrospective case series	SNM at single institution (<i>n</i> = 13)	1. 5-year PFS 2. 5-year OS	1. PFS 34% 2. OS 76%

(Continues)

TABLE XIV.2 (Continued)

Study	Year	LOE	Study design	Study groups	Clinical endpoints	Conclusion
Zenda et al. ⁵³⁵	2011	4	Retrospective case series	SNM at single institution primary (<i>n</i> = 39)	1. 3-year PFS 2. 3-year OS	1. PFS 49% 2. OS 59% 3. 13% experienced grade 3–5 toxicities
Truong et al. ⁵³⁶	2009	4	Retrospective case series	SNM at single institution (<i>n</i> = 20)	1. 2-year LC 2. 2-year DFS 3. 2-year OS	1. LC 86% 2. DFS 31% 3. OS 53% 4. Brain invasion was predictive for decreased OS rate
Nishimura et al. ⁵³⁷	2007	4	Retrospective case series	ONB at single institution (<i>n</i> = 14)	1. 5-year LPFS 2. 5-year RFS 3. 5-year OS	1. LPFS 84% 2. RFS 71% 3. OS 93%
Pommier et al. ⁵³⁸	2006	4	Retrospective case series	ACC at a single institute (SNM <i>n</i> = 17)	1. 5-year LC 2. 5-year DFS 3. 5-year OS	1. LC 93% 2. DFS 56% 3. OS 77%
Weber et al. ⁵³⁹	2006	4	Retrospective case series	SNM at single institution primary (<i>n</i> = 33) or recurrent (<i>n</i> = 3) to review 5-year visual LENT	1. LENT 2. 5-year DFS 3. 5-year OS	1. LENT 21% 2. DFS 81% 3. OS 90%
Fitzek et al. ⁵⁴⁰	2002	4	Retrospective case series	SNEC at single institution (<i>n</i> = 19)	1. 5-year LC 2. 5-year OS	1. LC 88% 2. OS 74%

Abbreviations: ACC, adenoid cystic carcinoma; CCS, cystic carcinoma survival; CIT, cancer immunotherapy; DFS, disease-free survival; FFDP, freedom from distant progression; FFLR, freedom from locoregional recurrence; ICER, incremental cost-effectiveness ratio; LC, local control; LENT, late effect normal tissue; ONB, olfactory neuroblastoma; OS, overall survival; PFS, progression-free survival; SN, sinonasal; SNM, sinonasal malignancy; QALY, quality-adjusted life year.

infrastructural developments. In addition, while less expensive than other forms of heavy particles, NRT is not widely available, and most of the published data were conducted with now outdated image guidance and treatment delivery systems.

D | Carbon ion radiotherapy

CIRT is a form of heavy ion particle therapy with limited availability. The construction and treatment cost is higher than even PBT, and most centers deliver treatment using fixed beamlines due to the gantry's size and weight.⁴⁷⁰ This can limit the treatment delivery angles critical for treating SNM's irregularly shaped geometries or regional lymphatics, and therefore many of the published series combine either IMRT or PBT as a component of therapy or use CIRT as a boost. Similar to NRT, the high RBE (estimated ranges from 2.5 to 5) of carbons may provide for biologic enhancement for unresectable, radioresistant tumors, and the beam penumbra is sharper than with protons. However, due to the high RBE throughout the beam path, there is little benefit to conventional fractionation, a treatment strategy used for sparing normal tissue com-

plications when tumors directly involve or abut sensitive neural tissues.⁴⁷¹

The largest multi-institutional cohort evaluating the outcomes for SNM is a 458 series from the Japan Carbon-Ion Radiation Oncology Study Group (J-CROS). In their 2018 retrospective review of 458 patients, 393 had de novo tumors and 65 were recurrent. The 2-year OS and LC rates were excellent at 80% and 84%, accordingly. Grade 3 and 4 late toxicities developed in nearly one fifth of patients, with visual injury being the most common.⁴⁷² Similar disease control rates were seen by Mizoe et al., who reported the experience of 116 SNM patients. The 5-year LC and OS rates were 68% and 47%, respectively. While toxicity was reportedly low, four cases of ipsilateral blindness were documented.⁴⁷³

With regard to outcomes as compared to other modalities, the locoregional recurrence and OS with CIRT are promising. In a systematic review and meta-analysis of 2282 patients with SNM, both LC and OS were significantly higher after CIRT than IMRT or PBT. While these results are encouraging, the authors note that prospective randomized evidence will likely be needed to better define the optimal treatment approach.⁴⁷⁴

TABLE XIV.3 Evidence surrounding neutron therapy in treatment of sinonasal tumors.

Study	Year	LOE	Study design	Study groups	Clinical endpoints	Conclusion
Aljabab et al. ⁴⁶¹	2021	4	Retrospective case series	Combined proton neutron for salivary tumors (SNM $n = 12$)	1. LC 2. PFS 3. OS	1. LC 90% 2. PFS 79% 3. OS 93% 4. Late grade 3/4 events included trismus ($n = 1$), hearing loss ($n = 2$), visual loss ($n = 6$), and bone necrosis ($n = 1$)
Novikov et al. ⁵⁴¹	2015	4	Retrospective case series	SNM at single institute treated with NRT (postop $n = 46$, gamma + NRT $n = 45$)	1. 5-year DFS 2. 5-year OS	1. DFS 68% 2. OS 62% 3. Complications of the treatment were registered in 39.4% of patients
Douglas et al. ⁴⁶³	2003	4	Retrospective case series	Salivary gland carcinoma at a single institute (SNM $n = 43$)	1. 6-year LRC 2. 6-year CCS 3. 6-year G3+ tox	1. LRC 59% 2. CCS 67% 3. G3 + tox 10%
Huber et al. ⁵⁴²	2001	4	Retrospective case series	ACC at a single institute (SNM $n = 12$ with NRT or mixed with photons)	1. 5-year LC neu- trons/mixed 2. Toxicity	1. 75/32 2. Severe late grade 3 and 4 toxicity tended to be more prevalent ($p > 0.1$) with neutrons (19%) than with mixed beam (10%) and photons (4%)
Douglas et al. ⁵⁴³	2000	4	Retrospective case series	ACC at a single institute (SNM $n = 32$)	1. 5-year LRC 2. 5-year CCS 3. 5-year OS	1. LRC 57% 2. CCS 77% 3. OS 72%
Douglas et al. ⁵⁴⁴	1996	4	Retrospective case series	ACC at a single institute (SNM $n = 27$)	1. 5-year LRC 2. 5-year CCS 3. 5-year OS	1. LRC 47% 2. CCS 64% 3. OS 59% 4. Patients without involvement of the cavernous sinus, base of skull, or nasopharynx (51 patients) had a 5-year actuarial LRC rate of 59%, whereas LRC was significantly lower (15%) for patients with tumors involving these sites
Buchholz et al. ⁵⁴⁵	1993	4	Retrospective case series	ACC at a single institute (SNM $n = 7$)	1. 5-year LRC 2. 5-year DFS 3. 5-year OS	1. LRC 63% 2. DFS 93% 3. OS 65%
Saroja et al. ⁵⁴⁶	1987	4	Retrospective case series	Salivary gland carcinoma at a single institute (SNM $n = 19$)	1. LC 2. Toxicity	1. LC 27% 2. 23% had major morbidity directed related to the total dose delivered
Errington ⁵⁴⁷	1986	4	Retrospective case series	SNM at single institute ($n = 43$)	1. 5-year LC 2. 5-year OS 3. 2-year Complication	1. LC 50% 2. OS 30% 3. Complication 30%

(Continues)

TABLE XIV.3 (Continued)

Study	Year	LOE	Study design	Study groups	Clinical endpoints	Conclusion
Vikram et al. ⁵⁴⁸	1984	4	Retrospective case series	ACC at a single institute (SNM $n = 19$)	1. Tumor regression/local control rate	<ol style="list-style-type: none"> 1. Irradiation is used for advanced, inoperable ACC; it offers useful palliation but is rarely, if ever, curative 2. Postoperative irradiation, on the other hand, might improve the local control rate and the survival in patients with operable ACC who are at high risk for relapse, but only if the field size and the dose are adequate

Abbreviations: ACC, adenoid cystic carcinoma; CCS, cystic carcinoma survival; DFS, disease-free survival; G3 + tox, grade 3 plus toxicity; LC, local control; LRC, local-regional control; NRT, fast neutron therapy; OS, overall survival; PFS, progression-free survival; SNM, sinonasal malignancy.

In summary, retrospective cohort studies show that CIRT can improve LRC, DFS, and OS rates in SNM, with the magnitude of the benefits dependent on the extent of disease and pathology of the primary malignancy (Table XIV.4). Its role as monotherapy or in combination with PBT or IMRT is currently being studied. The question of improved disease control compared to other radiation techniques for those with radioresistant pathologies such as ACC is currently being studied.

No randomized trials address the topic of advanced RT modalities for SNM, and only two multimodality systematic reviews are available, which are limited by significant heterogeneity and patient numbers. Despite these limitations, the evidence, predominantly from single-institution retrospective series, supports the use of IMRT and PT (specifically NRT, PBT, and CIRT) as the standard of care for RT modalities for primary or adjuvant therapy of SNM to improve LC, DFS, and OS rates. The presence and magnitude of the absolute benefit from primary or adjuvant radiotherapy are based on the extent of residual disease, pathology, and pathology-specific factors. The highest level of reported evidence shows PT (particularly PBT) improves LRC and DFS rates over IMRT. Preliminary cohorts using CIRT suggest a potential benefit beyond PBT, particularly with radioresistant pathology. While some series show concern for a higher side effect profile with NRT, there have been no modern experiences reported. There is limited evidence that compares acute and late toxicity profiles and events between treatment modalities, nor are there differences in oncologic outcomes among PT.

Radiation modalities for treatment of sinonasal malignancies

Aggregate grade of evidence	<p>IMRT: B (Level 2: three studies; Level 3: one study; Level 4: 50 studies)</p> <p>PBT: C (Level 2: two studies; Level 3: one study; Level 4: 23 studies); five level 4 CIRT series include single modality PBT patients</p> <p>NRT: C (Level 4: 10 studies)</p> <p>CIRT: C (Level 2: two studies; Level 3: two studies; Level 4: 23 studies)</p>
Benefit	IMRT provides LRC and benefits in PFS and OS rates as either primary or adjuvant therapy for SNM with absolute benefits dependent on patient- and pathology-specific factors.
Harm	RT morbidity is related to the extent and site of the tumor, including soft tissue, bone, vascular, and neural injury. Aside from IMRT, the other modalities may not be widely available, and patients may need to travel to specialized facilities for care.
Cost	Limited to two series. PBT provided extra QALY compared to IMRT and was cost-effective in patients ≤ 56 years old and CIRT increased costs compared to IMRT despite survival benefits.
Benefits-harm assessment	Preponderance of benefits over harms.

(Continued)

TABLE XIV. 4 Evidence surrounding carbon ion therapy in treatment of sinonasal tumors.

Study	Year	LOE	Study design	Study groups	Clinical endpoints	Conclusion
Zhang et al. ⁴⁷⁴	2020	2	Systematic review and meta-analysis	44 cohorts comparing 2282 patients treated with CIRT, PBT, or IMRT (IMRT, $n = 911$)	1. 3-year LC 2. 3-year OS	1. LC 80% 2. OS 75% 3. LC and OS were significantly higher after CIRT than PBT or IMRT 4. No significant difference between PRT and IMRT for OS and LC was observed
Patel et al. ⁴⁵⁸	2014	2	Systematic review and meta-analysis	SNM patients undergoing either particle or photon radiotherapy ($n = 1472$; CPT therapy $n = 58$ for DFS and $n = 146$ for OS)	Evidence: 1. Longest follow-up LRC 2. 5-year DFS 3. 5-year OS	1. LRC 0.76 (0.68–0.86) 2. DFS 0.80 (0.67–0.95) 3. OS 0.72 (0.58–0.90) 4. Subgroup analysis comparing CPT with photons, CPT showed significantly higher 5-year DFS, OS, and LRC at longest follow-up
Kubo et al. ⁵⁴⁹	2019	3	Prospective case series	SNM at single institution (SNM $n = 15$)	Incidences of Grade 1 and 2 nasolacrimal duct obstructions	1. G1 46% 2. G2 7%
Jensen et al. ⁵⁵⁰	2015	3	Prospective case series	Salivary gland tumors at single institution (SNM, $n = 18$, IMRT + CIRT)	1. 3-year LC 2. 3-year PFS 3. 3-year OS	1. LC 82% 2. PFS 58% 3. OS 78% 4. No significant difference could be shown regarding resection status
Musha et al. ⁵⁵¹	2022	4	Retrospective case series	SNM at single institution (SNM $n = 18$)	1. 5-year LC 2. 5-year PFS 3. 5-year OS 4. Toxicity	1. LC 75% 2. PFS 53% 3. OS 81% 4. Acute grade 3 radiation mucositis was seen in eight patients, and late grade 4 adverse events were observed, including two cases of visual loss and one case of brain necrosis
Bhattacharyya et al. ⁵⁵²	2020	4	Retrospective case series	SNM at single institution ($n = 50$; IMRT + CIRT)	Oronasal fistula	37 developed small localized fistula; however, none were of grade 3 severity
Hagiwara et al. ⁵⁵³	2020	4	Retrospective case series	SNM at single institution ($n = 22$)	1. 5-year LC 2. 5-year OS 3. Toxicity	1. 51% 2. 63% 3. Grade 4 visual impairment and grade 4 brain necrosis were seen in six and one patient, respectively
Hu et al. ⁵⁵⁴	2020	4	Retrospective case series	SNM at single institution (PBT $n = 4$, CIRT $n = 70$, CIRT + PBT $n = 37$)	1. 2-year LPFS 2. 2-year PFS 3. 2-year OS 4. Toxicity	1. LPFS 83% 2. PFS 66% 3. OS 82% 4. Late toxicity occurred in 22 (19.8%) patients, but only four (3.6%) patients experienced grades 3–4 late toxicity

(Continues)

TABLE XIV.4 (Continued)

Study	Year	LOE	Study design	Study groups	Clinical endpoints	Conclusion
Hu et al. ⁵⁵⁵	2020	4	Retrospective case series	ACC SNM at single institution (PBT <i>n</i> = 3, CIRT <i>n</i> = 17, CIRT + PBT <i>n</i> = 18)	1. 3-year LC 2. 3-year PFS 3. 3-year OS	1. LC 82% 2. PFS 70% 3. OS 77%
Akbaba et al. ⁵⁵⁶	2019	4	Retrospective case series	ACC SNM at single institution (<i>n</i> = 227, IMRT + CIRT)	1. 3-year LC RT 2. 3-year LC postop RT 3. Toxicity	1. LC 79% 2. LC 82% 3. Worse late toxicity observed for postoperative RT 17% versus 6% late grade 3 toxicity
Jensen and Debus ⁴⁷⁰	2019	4	Cost-effective analysis	ACC at a single institute (IMRT <i>n</i> = 37, IMRT + CIRT <i>n</i> = 58)	ICER	Experimental treatment increased overall costs by € 18,076 (€13,416–€22,922) at a mean survival benefit of 0.86 years. Despite improved local control, following costs were also increased in the experimental treatment ICER was estimated to be 26,863 €/LY
Koto et al. ⁴⁷²	2018	4	Retrospective case series	SNM across four carbon centers in Japan (<i>n</i> = 458)	1. 2-year LC 2. 2-year OS 3. Toxicity	1. LC 84% 2. OS 80% 3. 17% of patients developed grade 3 and 4 toxicities, of which visual impairment was the most common
Liermann et al. ⁵⁵⁷	2018	4	Retrospective case series	ONB at single institution (CIRT <i>n</i> = 4, +-photons <i>n</i> = 8)	1. 4-year PFS 2. 4-year OS	1. PFS 81% 2. OS 100%
Suefuji et al. ⁵⁵⁸	2018	4	Retrospective case series	ONB at single institution (<i>n</i> = 21)	1. 3-year LC 2. 3-year OS	1. LC 83% 2. OS 88% 3. Grade 4 late toxicity was observed in three patients, including ipsilateral optic nerve disorder (<i>n</i> = 2) and ipsilateral retinopathy (<i>n</i> = 1)
Sulaiman et al. ⁵⁶⁰	2018	4	Retrospective case series	ACC at four institutions (SNM <i>n</i> = 122)	1. 5-year LC 2. 5-year PFS 3. 5-year OS	1. LC 68% 2. PFS 44% 3. OS 74% 4. 43 patients (15%) experienced grade ≥ 3 late toxicity, of which osteonecrosis of the jaw bone was the most common 5. Two patients treated for nasopharyngeal ACC died from a bleeding ulcer at the tumor site (grade 5 toxicity)
Toyomasu et al. ⁵⁵⁹	2018	4	Retrospective case series	SNM at single institution (<i>n</i> = 59, PT <i>n</i> = 38, CIRT <i>n</i> = 21)	1. 5-year LC 2. 5-year PFS 3. 5-year OS	1. LC 50% 2. PFS 35% 3. OS 42% 4. Late toxicities of grade ≥ 3 occurred in 13 patients (22%)

(Continues)

TABLE XIV.4 (Continued)

Study	Year	LOE	Study design	Study groups	Clinical endpoints	Conclusion
Ikawa et al. ⁵⁶¹	2017	4	Retrospective case series	ACC SNM at single institution (<i>n</i> = 50)	1. 5-year LC 2. 5-year OS	1. LC 69% 2. OS 75%
Saitoh et al. ⁵⁶²	2017	4	Retrospective case series	SNM multicenter in Japan (<i>n</i> = 21)	1. 5-year LC 2. 5-year OS	1. LC 79% 2. OS 60%
Shirai et al. ⁵⁶³	2017	4	Retrospective case series	SNM at single institution (SNM <i>n</i> = 18)	1. 3-year LC 2. 3-year OS	1. LC 93% 2. OS 88%
Jensen et al. ⁵⁶⁴	2015	4	Retrospective case series	ACC SNM at single institution (SNM, <i>n</i> = 116, IMRT + CIRT)	1. 5-year LC 2. 5-year PFS 3. 5-year OS	1. LC 59% 2. PFS 56% 3. OS 75%
Koto et al. ⁵⁶⁵	2014	4	Retrospective case series	SNM at single institution (<i>n</i> = 22)	1. 3-year LC 2. 3-year OS 3. Toxicity	1. LC 77% 2. OS 59% 3. Late reactions included lateral visual loss (five patients), mucosal ulceration (one patient), and brain necrosis with clinical symptoms (one patient)
Morimoto et al. ⁵⁶⁶	2014	4	Retrospective case series	SNM at single institution (PBT <i>n</i> = 47, CIRT <i>n</i> = 10)	1. 3-year LPFS 2. 3-year OS	1. LPFS 56% 2. OS 61%
Sasahara et al. ⁵⁶⁷	2014	4	Retrospective case series	SNM at single institution (SNM <i>n</i> = 29)	Maxillary ORN	V50 and the presence of teeth within the planning target volume were independent risk factors for the development of ORN after C-ion RT using a 16-fraction protocol
Takagi et al. ⁵⁶⁸	2014	4	Retrospective case series	SNM at single institution (<i>n</i> = 80, PT <i>n</i> = 40, CIRT <i>n</i> = 40, SNM <i>n</i> = 41)	1. 5-year LC 2. 5-year PFS 3. 5-year OS	1. LC 75% 2. PFS 39% 3. OS 63% 4. Twenty-one patients (26%) experienced grade 3 or greater late toxicities, including three patients who developed grade 5 bleeding from nasopharyngeal ulcers
Mizoe et al. ⁴⁷³	2012	4	Retrospective case series	SNM at single institution (<i>n</i> = 116)	1. 5-year LC 2. 5-year OS	1. LC 68% 2. OS 47%
Jensen et al. ⁵⁶⁹	2011	4	Retrospective case series	SNM at single institution (CIRT <i>n</i> = 4, ±IMRT <i>n</i> = 29)	1. Radiographic response	1. RR 50%
Mizoe et al. ⁵⁷⁰	2004	4	Retrospective case series	SNM at single institution (<i>n</i> = 10)	1. 5-year LC 2. 5-year OS	1. LC 75% 2. OS 33%

Abbreviations: ACC, adenoid cystic carcinoma; CIRT, carbon ion radiotherapy; CPT, charged particle therapy; ICER, incremental cost-effectiveness ratio; IMRT, intensity modulated radiation therapy; LC, local control; OS, overall survival; PBT, proton beam therapy; PFS, progression-free survival; RR, radiographic response; SNM, sinonasal malignancy.

Value judgments	All modalities should be considered for improving LRC rates. The absolute benefit to LRC rates for SNM depends on patient- and pathology-specific factors and should be weighed against the risk of treatment toxicity. IMRT/CIRT should be considered for salivary glands or radioresistant histologies with gross residual disease at the time of treatment.
Policy level	Recommendation.
Intervention	IMRT should be considered for improving LRC, DFS, and OS rates when weighed for patient-specific and tumor features. Evidence suggests that PT, particularly PBT, could be considered when available.

SECTION II: BENIGN LESIONS AND NEOPLASMS

XV | BENIGN MASS-OCCUPYING LESIONS

A | Hamartomas

Hamartomas are benign malformations consisting of multiple tissue types. In the sinonasal cavity, hamartomas can be further classified into four histopathologic entities: respiratory epithelial adenomatoid hamartoma (REAH), chondro-osseous respiratory epithelial adenomatoid hamartoma (COREAH), nasal chondromesenchymal hamartoma (NCH), and seromucinous hamartoma.⁵⁷¹

1 | Respiratory epithelial adenomatoid hamartoma

REAH is the most common type of sinonasal hamartoma, with over 600 cases reported, and is characterized by excessive glandular proliferation lined by ciliated respiratory epithelium.⁵⁷² The precise etiology of REAH remains controversial, with some postulating that it arises as a nonneoplastic byproduct of sinonasal inflammation given its similar gross pathology and common association with nasal polyposis,⁵⁷³ while others consider it as a neoplasm given that the extent of allelic loss is unusually high for a nonneoplastic entity.⁵⁷⁴

REAH is most commonly seen in the third to ninth decade of life, with a reported preponderance in males.^{572,575–578} Similar to other sinonasal masses, patients with REAH can present with symptoms of nasal obstruction, nasal discharge, facial pressure, or olfactory impairment.⁵⁷⁸ REAH can present as an isolated

nasal lesion or with concurrent inflammatory nasal polyposis.^{573,575,577–579} In the most recent systematic review of 441 cases of REAH, 34.9% were isolated lesions and 50.1% occurred with nasal polyposis.⁵⁸⁰ One pathologic study investigated REAH in 150 patients undergoing surgery for nasal polyposis, and REAH was found in 35% of cases,⁵⁷⁵ suggesting that REAH is underdiagnosed clinically, on imaging studies, and on histopathology. The most common location of REAH is in the olfactory cleft, with the posterior septum as the second most common site.^{573,581–583} REAH in the olfactory cleft has been shown to be significantly associated with longstanding (>10 years) nasal polyposis and with comorbid asthma.⁵⁸⁴ Interestingly, REAH is found more frequently in cases of revision sinus surgery compared to primary cases.^{582,584}

Grossly, REAH typically appears as a polypoid mass, usually darker and more indurated than an inflammatory polyp.⁵⁷¹ Histologically, REAH classically demonstrates glandular proliferation and a thickened hyalinized basement membrane, often within a background of inflamed stroma.⁵⁸⁵ On IHC, the glandular component is positive for cytokeratins (including cytokeratin 7), and there is usually a retained basal cell layer with positivity for p63 and cytokeratin 34 β E12.⁵⁸⁵

On CT, REAH is associated with a characteristic unilateral or bilateral widening of the olfactory cleft in the coronal plane.^{573,577,586–589} The first report to describe this finding found that the mean olfactory cleft width was 12.1 mm in patient with REAH, compared to 5.4 mm in patients with nasal polyposis and 4.2 mm in patients without sinonasal pathology.⁵⁸⁹ Another comparative study found that a width of >10 mm was characteristic of REAH, with 88% sensitivity and 74% specificity.⁵⁸⁸ Typically there is no associated bone erosion on CT.⁵⁸⁶ On MRI, REAH is intermediate in signal intensity on T1- and T2-weighted sequences, often with a cerebriform contour and homogeneous postgadolinium enhancement.^{576,580,590}

Endoscopic surgical resection is the primary treatment modality for REAH, with excellent outcomes. In cases of isolated REAH, the extent of surgery reported ranges from simple excision to subperiosteal dissection and drilling of the bone.^{576,577,587,591} In cases of REAH with nasal polyposis, authors report performing standard endoscopic sinus surgery, including total ethmoidectomy.^{573,576,577,584,586,592–594} Evidence-based recommendations regarding extent of surgery for REAH cannot be made, given the limitation of existing evidence to case series. There are no studies assessing medical therapy for management of REAH. Of all reported surgical patients, the recurrence rate is 4.1% (15/363).⁵⁸⁰ The clinical characteristics and risk factors of these recurrences are not well characterized in the existing literature. Olfactory outcomes following surgery for REAH are reported

in three studies.^{587,592,593} Subjectively, 86%–91% patients experience improvement in olfaction postoperatively^{587,593} Using the Sniffin' Sticks test, 45% of patients with preoperative hyposmia had improved olfactory function.⁵⁹² In this study, poor olfactory outcomes were significantly associated with previous surgery and previous middle turbinate resection.

2 | Chondro-osseous respiratory epithelial adenomatoid hamartoma

COREAH is an exceedingly rare type of sinonasal hamartoma, with fewer than 20 cases reported to date in the most recent LR.⁵⁹⁵ COREAH has the same epithelial components as REAH, with the addition of mesenchymal elements including cartilaginous and/or osseous trabeculae. Nearly all reported cases have been located in the nasal cavity, with sites of origin including the lateral nasal wall, posterior septum, olfactory cleft, and middle turbinate. Cases have been reported from ages 3 to 83 years, without a clear sex predilection.⁵⁹⁵ In contrast to REAH, there are no cases of COREAH occurring with comorbid nasal polyposis.

On CT imaging, 58% lesions have intralesional bony density/calcification, and none show adjacent bone erosion. On MRI, COREAH appears as a heterogeneously T2-isointense/hyperintense expansile mass that may have cystic components.⁵⁹⁵ All reported cases have been treated with surgical excision, with one case reporting recurrence at 1 year.⁵⁹⁵

3 | Nasal chondromesenchymal hamartoma

NCH is very rare, with about 50 reported cases to date. While traditionally categorized as a sinonasal hamartoma, NCH is now understood to be a benign neoplasm with strong association with *DICER1* syndrome. NCH is predominantly found in children, with a median age of 9.6 years (range 1 day to 69 years) and about one third of reported cases found in patients younger than 1 year.⁵⁹⁶ NCH most commonly presents with nasal obstruction, which in the nasally dependent newborn can lead to stertor or respiratory distress. Other presenting features include eye abnormalities, facial swelling, headache, sinusitis, and epistaxis. Tumor locations have been most commonly reported in the ethmoid cavity (24%), followed by the orbit (19%), skull base/intracranial (20%), maxillary sinus (14%), and nasal cavity (8%).⁵⁹⁷

NCH has been associated with the *DICER1* familial tumor predisposition syndrome, characterized by germline pathogenic loss-of-function mutation in *DICER1*,

a gene that encodes for a multifunctional protein with RNA endonuclease activity implicated in microRNA production.⁵⁹⁷ Patients with *DICER1* syndrome have increased risk of multiple benign and malignant tumors in addition to NCH, including pleuropulmonary blastoma, ovarian sex cord-stromal tumors, thyroid hyperplasia and neoplasia, and pituitary blastoma, among others.⁵⁹⁸ A systematic review found that 38% of patients with NCH had at least one other *DICER1*-associated tumor.⁵⁹⁷ As such, a diagnosis of NCH should prompt consideration of *DICER1* genetic testing and comprehensive oncologic surveillance.

On histology, NCH demonstrates predominantly cartilaginous nodules, ranging in differentiation from immature chondromyxoid matrix to mature cartilage. An osseous component may also be present, ranging in differentiation from immature woven bone to mature ossicles.⁵⁷¹ Generally, no significant mitotic activity or necrosis is expected. Radiographically, NCH demonstrates areas of matrix calcification on CT; on MRI, the mass is generally T2 hyperintense secondary to high water content within the extracellular matrix of hyaline cartilage, while areas of mineralization appear lower in signal intensity.⁵⁹⁹

All reported cases of NCH underwent surgical resection, with the approach dependent on tumor location and size. Both endoscopic and open approaches have been employed in NCH. Among all reported cases, 24 patients have follow-up reported (mean 24 months). Of these cases, 45.8% reported persistent or recurrent disease, often requiring surgical re-resection.⁵⁹⁶ There is one reported case of malignant transformation at 3 months follow-up, in a 40-year-old female.⁶⁰⁰

B | Nasolabial cysts

Nasolabial cysts (NLCs) are benign, nonodontogenic cysts arising in the anterior maxillary region, often located submucosally in the anterior nasal floor. The etiology of NLCs is thought to be a result of a developmental error from the epithelial rests at the fusion of globular, lateral, nasal, and maxillary processes from embryonic remnants of the nasolacrimal duct.⁶⁰¹ NLCs are found across all ages (range 4 months to 78 years), with a roughly 3:1 female predilection in reported cases.⁶⁰² The most common presenting symptom is facial swelling in the nasolabial region (71%), followed by nasal obstruction (17%). Rarely, NLCs present as an acutely infected cyst (3%).⁶⁰² Examination can demonstrate a variably fluctuant or tender mobile cyst within the nasolabial area, and endoscopy can demonstrate submucosal fullness in the anterior nasal floor.⁶⁰³

CT of NLC demonstrates a well-defined, low-density cyst in the nasolabial region.^{601,602,604,605} Erosion or

remodeling of adjacent bone is seen in 38% of cases.⁶⁰² MRI findings include a wide variation in T1 and T2 signal depending on protein content.^{602,604} Ultrasound in five cases has reported well-defined cysts with anechoic to hypoechoic fluid.⁶⁰²

On histopathology, these cysts demonstrate a range of epithelial cell types, including columnar, cuboidal, and squamous epithelium, and roughly half of lesions demonstrate goblet cells and mucous glands.⁶⁰²

The two most common surgical treatments for NLCs are transoral sublabial excision and transnasal endoscopic marsupialization, and both approaches can be performed under local or general anesthesia.^{603,606–613} A 2016 systematic review of all reported cases found an overall recurrence rate of 2.2%, with 1.6% following transoral excision and 5.0% following endonasal marsupialization.⁶⁰² A prospective randomized study directly comparing these techniques in 20 patients found that, while there was no recurrence at 1 year in either treatment group, the endonasal marsupialization group had significantly shorter operative time (18.3 vs. 46.4 min, $p < 0.002$) and lower postoperative pain (3.5 vs. 6.1 as measured by visual analog score, $p < 0.01$).⁶¹⁴ A retrospective study of 30 patients found significantly lower operative time, blood loss, and hospitalization time for endonasal marsupialization compared to transoral excision, with no recurrences in either group.⁶⁰⁹ Furthermore, endonasal marsupialization imposes significantly less medical costs compared to sublabial excision.⁶⁰⁹ Recently, a series of 31 patients describe endonasal microwave ablation under local anesthesia, with minimal complications and no recurrences or oroantral fistula at 1 year.⁶¹⁵

C | Antrochoanal polyps

Antrochoanal polyps (ACP) are benign, typically unilateral lesions that arise from the maxillary sinus and extend through the nasal cavity to, and often through, the choana, representing 4%–10% of adult polyps and 35% of pediatric polyps.^{616–618} ACPs commonly present with unilateral nasal obstruction, rhinorrhea, and postnasal drainage; when larger, they can cause snoring, obstructive sleep apnea, dysphonia, and dysphagia.^{616–620}

While the exact etiology is unknown, inflammation is thought to play a key role in the pathogenesis of ACP. ACPs demonstrate type 1 inflammation (neutrophilic), with higher expression of IL-8, IFN- γ , and myeloperoxidase compared to eosinophilic and noneosinophilic nasal polyps⁶²¹ and higher levels of IL-6 and IL-10 compared to control tissue.⁶²² Any correlation between ACP and anatomic variations such as septal deviation, concha bul-

losa, or Haller cells has been studied with inconclusive results.^{623,624}

Diagnosis is made using nasal endoscopy and CT. Endoscopic exam typically reveals a smooth polypoid mass originating from the middle meatus and often filling the entire nasal cavity.⁶²⁵ CT demonstrates a homogenous, low-density soft tissue mass emanating from the maxillary sinus through a widened ostium or patent posterior fontanelle, and extending to the choana. Typically, no bony destruction is observed, though the posterior choana may be remodeled and widened if the polyp extends to the nasopharynx.⁶²⁵ While MRI is not necessary, it can help differentiate ACP from other unilateral sinonasal masses. ACPs are typically hypo- to isointense on T1-weighted and hyperintense on T2-weighted images, with peripheral enhancement postcontrast.^{626,627} On histopathology, ACPs generally demonstrate a sparsity of mucous glands and eosinophils as compared to sinonasal polyps, and may additionally show areas of infarction as well as stromal cells with cytologic atypia.⁶²⁸

ACPs are treated surgically, using standard endoscopic techniques, with consideration given to extended endoscopic and very rarely Caldwell-Luc approaches, depending on site of origin. Identification and removal of the site of origin are key to preventing recurrence.⁶²⁹ The majority of tumors originate from the posterior wall and are thus amenable to resection through a standard maxillary antrostomy.^{619,630–635} If the ACP exits an accessory ostium of the maxillary sinus, this opening should be brought into continuity with the natural ostium to avoid recirculation.^{636,637} In cases of anterior or inferior wall attachment or in cases of recurrence, an endoscopic medial maxillectomy or prelacrimal approach can achieve successful removal.⁶³⁷ A Caldwell-Luc approach in combination with an endonasal approach is also effective in removing anteriorly based or recurrent ACPs.^{629,638–642} A 2018 systematic review of 285 cases of ACP identified an overall 15% recurrence rate. In this study, the difference in recurrence rate between endoscopic only (17.7%) and combined endoscopic + Caldwell-Luc approach (0%) was statistically significant; however, this is before the prelacrimal approach became very widely used, as it is today. The Caldwell-Luc should be used judiciously, especially in children, given the risk of damaging dentition and developing maxillary bone.^{629,633}

XVI | SINONASAL PAPILOMAS

Sinonasal papilloma, although benign, represents a locally disruptive subtype of head and neck pathology arising from the Schneiderian mucosa, an ectoderm-derived respiratory mucosa.⁶⁴³ Variations in tumor morphology and

TABLE XVI.1 Summary table on different types of sinonasal papilloma.

	Rates of malignant transformation	Molecular mutations	Dysplasia predisposing to malignancy	Association with HPV
Inverted	5%–15%	<i>EGFR</i>	Association noted	Low-risk HPV may present in some patients and may play a role in tumor development, but not consistent in all patients
Exophytic	Rare	Unknown	Rarely seen	Strong association with low-risk HPV
Oncocytic	4%–17%	<i>KRAS</i>	Association noted	Weak to no association with HPV

clinical behavior patterns can make the diagnosis difficult at times (Table XVI.1). Furthermore, certain tumors possess the ability to progress to malignancy. Advances in immunohistologic and molecular analysis have generated much interest in the investigation of factors that drive tumor progression. Specific areas of concern include the role of HPV, both high-risk and low-risk strains, and somatic genomic mutations. In this section, we summarize the current literature pertaining to sinonasal papilloma subtypes (inverted, exophytic, and oncocytic), explore the association of HPV to these papillomas, and evaluate factors leading to malignant conversion.

A | Exophytic papilloma

Exophytic papillomas are the second most common sinonasal papilloma type, representing 10%–33% of all sinonasal papillomatous disease.^{643–645} These tend to occur in younger patients between the second and fifth decade of life and have a 2–3:1 predilection for male patients.^{645–648} The nasal septum appears to be the most common site of anatomic involvement.⁶⁴³ Although there is a propensity to recur, exophytic papilloma rarely undergo malignant transformation and have improved prognosis compared to other papilloma subtypes.^{644,649–653} Histologically, exophytic papilloma is distinct from IP due to its predominantly exophytic growth pattern, lack of transmigrating intraepithelial neutrophilic inflammation, and frequent presence of overlying keratosis.^{643,646} Low-risk HPV—in particular, types 6 and 11—has a strong association with this disease process, with many studies reporting over 70% positivity rate.^{95,643,646,654–657}

B | Oncocytic papilloma

Oncocytic sinonasal papilloma is the least common subtype of sinonasal papilloma (about 6%) with no apparent predilection for sex.^{643,645–647} Clinically, these tumors are similar to IP, based on anatomic location (i.e., fre-

quent involvement of the paranasal sinuses), overall prognosis, and risk of malignant transformation (approximately 4%–17%).^{645–647} Histologically, oncocytic papillomas are distinct from IPs due to their frequent combined endophytic and exophytic growth patterns, predominant cuboidal to columnar cell morphology with eosinophilic cytoplasm, and prominent intraepithelial neutrophilic microabscesses.^{36,643,646} Oncocytic papilloma is also different from IP due to the absence of somatic *EGFR* mutations and presence of highly prevalent somatic *KRAS* mutations.^{643,658} Additionally, there is infrequent association with HPV in oncocytic sinonasal papilloma. Regardless, the risk of malignant degeneration is similar to that of IP, warranting a similar treatment approach.

C | Inverted papilloma

IP is the most common sinonasal papilloma subtype, representing 62%–78% of cases and, as such, data for IP dominate the literature.^{645–647} Usually these tumors occur along the lateral nasal wall or arise from within the paranasal sinuses. Histologically, IP has a characteristic appearance: it is composed predominantly of immature squamous cells with a classic “ribbon-like” endophytic (inverted) growth pattern and pathognomonic transmigrating intraepithelial neutrophilic inflammation.^{643,646} Somatic mutations in the epidermal growth factor receptor (*EGFR*) gene are present in the majority of IP.^{658,659} Low-risk HPV (types 6 and 11) is common in IP and is presumed to play a role in tumorigenesis.^{658,659} Indeed, recent data indicate that these are mutually exclusive processes driving tumorigenesis, in that IP is either driven by low-risk HPV or somatic *EGFR* mutations.

D | Dysplasia and risk of malignant transformation

Malignant transformation of sinonasal papilloma is a major source of morbidity and mortality

TABLE XVI.2 Evidence surrounding sinonasal papilloma association with human papillomavirus (HPV) and malignant conversion.

Study	Year	LOE	Study design	Study groups	Clinical endpoints	Conclusion
Rha et al. ⁶⁵⁶	2022	2	Systematic review and meta-analysis	592 patients with sinonasal IP (14 studies)	HPV association with sinonasal IP recurrence	Higher rates of recurrence noted in HPV-associated sinonasal IP
McCormick et al. ⁷⁴⁴	2022	2	Systematic review and meta-analysis	17 studies including 551 patients with benign sinonasal IP and 56 patients with malignant sinonasal IP	Association between HPV infection and malignant sinonasal IP	<ol style="list-style-type: none"> 1. High-risk HPV subtypes associated with increased risk of malignant sinonasal IP 2. HPV-18 shows the greatest effect size
Stepp et al. ⁶⁶³	2021	2	Systematic review and meta-analysis	794 patients with IP (19 studies)	HPV in sinonasal IP and risk of malignant transformation to SCC	Significant association between HPV infection and malignant transformation of IP
Ding et al. ⁷⁴⁵	2021	2	Systematic review and meta-analysis	900 patients with sinonasal IP (26 studies)	HPV infection of sinonasal IP	HPV types 16, 11/16, 18, and 16/18 associated with an increased risk of malignant sinonasal IP
Re et al. ³⁶	2017	2	Systematic review	3177 patients with IP (29 studies)	Rates of malignant transformation	Overall rate of malignant transformation for Schneiderian papilloma 9%
Zhao et al. ⁷⁴⁶	2016	2	Systematic review and meta-analysis	32 studies including 972 patients with benign sinonasal IP and 152 patients with malignant sinonasal IP	HPV association with transformation of sinonasal IP	HPV-18 associated with the malignant transformation of sinonasal IP
Syrjänen and Syrjänen ⁹⁵	2013	2	Systematic review and meta-analysis	1956 patients with sinonasal papilloma (76 studies)	Role of HPV in development and progression of sinonasal papilloma	HPV infection varies with sinonasal papilloma histology, but no outcomes significant in formal meta-regression for this study
Viitasalo et al. ⁶⁵²	2023	3	Retrospective cohort	296 patients with sinonasal IP	<ol style="list-style-type: none"> 1. Malignant transformation rate of sinonasal IP 2. To determine factors that contribute to recurrence in patients treated for sinonasal IP 	<ol style="list-style-type: none"> 1. Two out of 296 patients with sinonasal IP underwent malignant transformation over 8 years 2. Attachment-oriented surgery reduces recurrence rates 3. Dysplasia associated with a higher recurrence rate

(Continues)

and results in poorer overall outcomes (Table XVI.2).^{36,643,646,647,649–651,653,660} Malignant transformation is rarely ever seen in exophytic papilloma but can occur 4%–17% and 5%–15% of the time for oncocytic and IP

subtypes, respectively.⁶⁴⁷ Dysplasia plays a preceding role in progression to malignancy in IP and oncocytic papilloma but is rarely seen in exophytic papilloma.^{36,643,646} Two major types of dysplasia include keratinizing and

TABLE XVI.2 (Continued)

Study	Year	LOE	Study design	Study groups	Clinical endpoints	Conclusion
Paehler Vor der Holte ⁷⁴⁷	2021	3	Retrospective cohort	101 patients with benign papilloma and six patients with carcinoma in situ and SCC related IP	<ol style="list-style-type: none"> 1. Role of HPV infection on recurrence of sinonasal papilloma 2. Role of HPV infection on malignant progression of sinonasal papilloma 	<ol style="list-style-type: none"> 1. Recurrent IPs were more often HPV+ than nonrecurrent IPs 2. Low-risk HPV infection increased the risk of tumor recurrences 3. IP and oncocyctic papilloma were more often high-risk HPV-associated than fungiform papilloma
Hongo et al. ⁶⁷²	2021	3	Retrospective cohort	146 patients with SNSCC (14 with sinonasal IP-related SCC)	Prognostic significance of HPV infection, EGFR mutations, and KRAS	<ol style="list-style-type: none"> 1. EGFR may play a role in the pathogenicity of sinonasal IP-related SCC 2. HPV-associated SNSCC patients have better prognoses than HPV-independent patients
Li et al. ⁷⁴⁸	2020	3	Retrospective cohort	21 patients with SCC associated with IP	<ol style="list-style-type: none"> 1. Rate of recurrence 2. 1-, 3-, and 5-year OS 3. 1-, 3-, and 5-year DSS 	<ol style="list-style-type: none"> 1. Nine out of 21 (42.9%) patients experienced local recurrence 2. T4 stage and invasive orbital cavity had a significant influence on recurrence 3. DSS is favorable in patients with SCC associated with IP
Frasson et al. ⁷⁴⁹	2020	3	Retrospective cohort	55 patients with sinonasal IP	HPV status in samples of IP	<ol style="list-style-type: none"> 1. HPV DNA was identified in 34 out of 55 (61.8%) patients with IP 2. High-risk genotypes (19/34, 55.9%) were more prevalent than low-risk genotypes (15/34, 44.1%)
Wang et al. ⁷⁵⁰	2020	3	Retrospective cohort	49 patients with sinonasal IP and 36 patients with sinonasal oncocyctic papilloma	<ol style="list-style-type: none"> 1. Role of HPV in sinonasal IP and sinonasal oncocyctic papilloma 2. Determine whether p16 can serve as a surrogate marker for HPV infection 	<ol style="list-style-type: none"> 1. HPV DNA was present in 6.1% (3/49) of patients with SN IP and 11.1% (4/36) of patients with oncocyctic papilloma 2. 22.4% (11/49) of sinonasal IP lesions and 27.8% (10/36) of sinonasal oncocyctic papilloma lesions were p16 positive

(Continues)

nonkeratinizing. Keratinizing dysplasia is morphologically similar to that seen in other head and neck squamous pathology—orthokeratosis, cytologic atypia, squamous dysmaturation, and increased intraepithelial disorganization as it progresses from low to high grade.^{36,93,645,646,660} Nonkeratinizing dysplasia is more histologically subtle and is recognized by loss of neutrophilic inflammation with associated increased mitotic activity.⁶⁴³ Recent

molecular profiling data indicate that *TP53* and/or *CDKN2A* alterations are central events in malignant progression of sinonasal papillomas.⁶⁶⁰ Although studies have posited a role for high-risk HPV subtypes—in particular, types 16 and 18—during malignant conversion of sinonasal papilloma, more recent meta-analytic data indicate that high-risk HPV is associated with de novo sinonasal SCC (i.e., not arising from IP).^{646,656,657,661–665} Importantly,

TABLE XVI.2 (Continued)

Study	Year	LOE	Study design	Study groups	Clinical endpoints	Conclusion
Pähler vor der Holte et al. ⁷³⁰	2020	3	Retrospective cohort	100 patients treated for sinonasal papilloma	<ol style="list-style-type: none"> 1. Identify and assess potential clinical and risk factors for development of sinonasal papilloma 2. Identify and assess potential clinical and biological risk factors for recurrence of sinonasal papilloma 	<ol style="list-style-type: none"> 1. Risk factors for recurrence of sinonasal papilloma include young at initial diagnosis and incomplete tumor resection 2. HPV infection may play a role in the development and/or progression of sinonasal papilloma
Mehrad et al. ⁶⁶⁶	2020	3	Retrospective cohort	44 patients with IP	<ol style="list-style-type: none"> 1. Rates of low-risk HPV, high-risk HPV, and p16 positivity 2. Relationship between EGFR mutations and HPV status 	<ol style="list-style-type: none"> 1. All samples negative for p16 and high-risk HPV 2. Low-risk HPV subtypes mutually exclusive with EGFR mutations 3. Low-risk HPV positivity and EGFR mutations may be alternate mechanisms of pathogenesis
Cabal et al. ⁶⁶⁹	2020	3	Retrospective cohort	55 patients with IP, 14 patients with SNSCC associated with IP, and 60 SNSCC not associated with IP	<ol style="list-style-type: none"> 1. Determine the presence of EGFR gene mutation and protein expression 2. Determine the presence of HPV infection 3. Determine the presence of KRAS mutation 	<ol style="list-style-type: none"> 1. Activation of EGFR through phosphorylation is important in the pathogenesis of this pathway 2. EGFR inhibitors are a potential treatment pathway for some SNSCC patients.
Elliot et al. ⁷⁵¹	2019	3	Retrospective cohort	98 patients diagnosed with IP	Determine the presence of stathmin, EGFR, and HPV	<ol style="list-style-type: none"> 1. Higher stathmin correlated with dysplasia and earlier recurrences 2. No association between EGFR and recurrence or dysplasia

(Continues)

recent evidence also suggests that low-risk HPV is an independent risk factor for malignant transformation of IP.^{659,666–668}

Differentiating de novo sinonasal SCC from malignant conversion of IP can present a diagnostic dilemma, as

there is increasing recognition of high-risk HPV as a primary etiologic factor for SNM, and high-risk HPV-associated sinonasal SCC may show morphologic overlap with IPs and associated sinonasal carcinomas.^{661,669–672} Indeed, similar to HPV-associated oropharyngeal SCC,

TABLE XVI.2 (Continued)

Study	Year	LOE	Study design	Study groups	Clinical endpoints	Conclusion
Sahnane et al. ⁶⁶	2019	3	Retrospective cohort	25 patients with sinonasal IP, five patients with oncocyctic sinonasal papilloma, and 35 patients with SCC	<ol style="list-style-type: none"> Determine the presence of HPV DNA Quantitative determination of LINE-1 methylation 	<ol style="list-style-type: none"> High-risk HPV present in 13% of sinonasal IP-associated SCC EGFR mutations in 72% of sinonasal IPs, 30% of sinonasal IP-associated SCCs, and 17% of SCCs not related to sinonasal IPs LINE-1 hypomethylation significantly increased from papilloma/early-stage SCC to advanced-stage SCC
Udager et al. ⁶⁶⁷	2018	3	Retrospective cohort	58 patients with sinonasal IP, 22 with sinonasal IP-associated SNSCC (13 patients have matched benign IP samples), and 14 patients with SNSCC without evidence of an IP	Identify a relationship between HPV infection and activating EGFR mutations	All patients with sinonasal IP and sinonasal IP-associated SNSCC demonstrated either an EGFR mutation or HPV infection
Rooper et al. ⁶⁶²	2017	3	Retrospective cohort	30 patients with benign IP, seven patients with IP with dysplasia, 16 IP with transformation, and seven nonkeratinizing SCCs that are not associated with IP	Directly visualize transcriptionally active high-risk HPV to assess its role in development and progression of sinonasal IPs	<ol style="list-style-type: none"> HPV was not detected in any sample of IP but was detected in two of seven (29%) of SCCs that were not associated with sinonasal IPs P16 correlated with high-risk HPV
Jalilvand et al. ⁷⁵²	2016	3	Retrospective cohort	Benign IP ($n = 37$) versus IP associated with SCC ($n = 3$)	Prevalence of HPV types in benign and malignant IP in an Iranian population	<ol style="list-style-type: none"> HPV was present in 18.9% of IP and 100% of IP associated with SNSCC In HPV+ IP cases, HPV6/11 was detected, as compared to HPV+ IP-associated SNSCC cases where HPV16/18 was detected
Scheel et al. ⁷⁵³	2015	3	Retrospective cohort	112 samples from 90 patients with IP	<ol style="list-style-type: none"> Determine the prevalence of HPV infection Conduct additional staining for p16, p53, EGFR, and cyclin D1 	<ol style="list-style-type: none"> Low-risk HPV subtypes may predispose progression of IP into malignancy Increase in EGFR expression associated with low-risk HPV-associated IP

(Continues)

there is a large subset of HPV-associated sinonasal SCC, which show high-risk HPV infection and diffuse p16 immunostaining.^{662,667} In addition, the recently described HPV-related multiphenotypic sinonasal carcinoma shows

a strong association with high-risk HPV (i.e., type 33). This, however, is morphologically distinct from the above due to characteristic myoepithelial differentiation and frequent cribriform growth pattern reminiscent to ACC.^{643,662,667}

TABLE XVI.2 (Continued)

Study	Year	LOE	Study design	Study groups	Clinical endpoints	Conclusion
Cheung et al. ⁶⁵⁵	2010	3	Retrospective cohort	56 patients with sinonasal IP, eight patients with sinonasal exophytic papilloma, and three patients with sinonasal oncocyctic papilloma	<ol style="list-style-type: none"> 1. Morphology of IP and expression of p53 and p16 2. Association between malignant transformation and HPV infection 	<ol style="list-style-type: none"> 1. Severe dysplasia and p53 strongly associated with malignant transformation 2. HPV positivity was strongly associated with exophytic papilloma and carcinomas 3. Evidence of p53 and dysplasia warrant aggressive surgical treatment and close follow-up
Buchwald et al. ⁶⁵⁴	2001	3	Retrospective cohort	IP associated with carcinoma ($n = 31$) versus exophytic papilloma associated with carcinoma ($n = 5$)	<ol style="list-style-type: none"> 1. Determine the presence of HPV DNA 2. Assess p53 overexpression 	Inverse relationship between HPV and p53 overexpression and association with sinonasal carcinomas
Brown et al. ⁶⁶⁰	2021	4	Case-control	Sinonasal papilloma associated sinonasal carcinomas including IP ($n = 24$) and oncocyctic ($n = 5$)	Characterize the molecular landscape of a large cohort of sinonasal papilloma associated sinonasal carcinomas	EGFR (21/29, 72.4%) or KRAS mutations (5/29, 17.2%) were present in most tumors
Nishikawa et al. ⁶⁶¹	2021	4	Case-control	85 patients with SNSCC	Prognosis of EGFR mutation and HPV status in SNSCC	<ol style="list-style-type: none"> 1. EGFR mutations detected in 24 out of 85 (28%) patients 2. HPV DNA was detected in seven out of 85 (8%) patients 3. Patients with EGFR mutated SNSCC had worse OS than those with EGFR wild type
Sbrana et al. ⁶⁴⁴	2021	4	Case-control	Sinonasal papilloma including IP ($n = 49$), exophytic papilloma ($n = 6$), and oncocyctic papilloma ($n = 6$)	<ol style="list-style-type: none"> 1. Rate of recurrence in patients with IP 2. Rate of malignant transformation in patients with an IP 	<ol style="list-style-type: none"> 1. Recurrence rates in IP 34.09% (15/44) with a mean time of recurrence of 24.6 months 2. Malignant transformation occurred in six out of 44 (13.64%) patients with IP
Beigh et al. ⁷⁵⁴	2018	4	Case-control	102 patients with nonneoplastic sinonasal lesions versus 94 patients with neoplastic sinonasal lesions	<ol style="list-style-type: none"> 1. Association between HPV and sinonasal papilloma 2. Association between HPV and sinonasal SCC 	Low-risk HPV-6 and HPV-11 were associated with sinonasal papilloma, and high-risk subtypes HPV-16 and HPV-18 were associated with SCC

(Continues)

TABLE XVI.2 (Continued)

Study	Year	LOE	Study design	Study groups	Clinical endpoints	Conclusion
Liu et al. ⁷⁵⁵	2017	4	Case-control	80 sinonasal IP tissue samples and 40 control tissue samples	<ol style="list-style-type: none"> 1. Rates of HPV infection in sinonasal IP as compared to control 2. Differences in phosphorylated Akt and phosphorylated S6 ribosomal protein staining 	<ol style="list-style-type: none"> 1. 47 out of 80 (58.8%) sinonasal IPs were HPV associated, most common HPV-11 (20/53, 37.7%) 2. Phosphorylated Akt and phosphorylated S6 ribosomal protein increased in HPV + sinonasal IP
Stasikowska-Kanicka et al. ⁷⁵⁶	2016	4	Case-control	41 patients with sinonasal IP, 33 patients with sinonasal SCC, and 22 control patients with normal mucosa	Expression of epithelial to mesenchymal transition (EMT) proteins including Slug, E-cadherin, and fibronectin	<ol style="list-style-type: none"> 1. The expression of Slug and fibronectin was significantly increased in the SNSCC group as compared to sinonasal IPs and to controls 2. Expression of E-cadherin was significantly lower in SNSCCs as compared to sinonasal IPs and to controls.
Udager et al. ⁶⁵⁸	2016	4	Case-control	111 sinonasal papilloma patients, 27 sinonasal papilloma-associated SNSCC, and 19 sinonasal SCC with no known IP association	Identify KRAS mutations present in different disease groups	<ol style="list-style-type: none"> 1. KRAS mutations were present in 51 out of 51 oncocytic sinonasal papilloma- and five out of five (100%) of oncocytic sinonasal papilloma-associated SNSCCs 2. KRAS mutations present in one out of 19 (5%) of SNSCCs with no known IP association
Lin et al. ⁷⁵⁷	2016	4	Case-control	28 patients with sinonasal IP versus 10 control patients	<ol style="list-style-type: none"> 1. Role of HPV infection in sinonasal IP 2. Role of stathmin in sinonasal IP 	<ol style="list-style-type: none"> 1. Recurrent cases and higher Krouse stage had increased rates of HPV infection 2. Stronger expression of stathmin, Kif2a, and cyclin D2 was seen in sinonasal IP, especially HPV+ cases
Udager et al. ⁶⁵⁹	2015	4	Case-control	Inverted sinonasal papilloma ($n = 50$), inverted sinonasal papilloma-associated SNSCC ($n = 22$), and other sinonasal squamous lesions ($n = 35$)	Identify EGFR mutations present in different disease groups	Activating EGFR mutations play an important role in the pathogenesis of sinonasal IP and sinonasal IP associated SNSCC

(Continues)

However, in diagnostically challenging cases, IP and associated sinonasal carcinoma can be differentiated from de novo sinonasal SCC by the presence of either low-risk HPV or somatic *EGFR* mutation.^{643,662,667}

An in-depth histopathologic understanding of sinonasal papillomas is crucial for diagnosis and clinical management of these tumors. Given recent advancements in our understanding of the molecular basis for IPs and

TABLE XVI.2 (Continued)

Study	Year	LOE	Study design	Study groups	Clinical endpoints	Conclusion
Yamashita et al. ⁷⁵⁸	2015	4	Case-control	Compared 17 patients with IP, five patients with both IP and SCC, and 16 patients with primary SNSCC to 32 patients with CRS	<ol style="list-style-type: none"> Determine the presence of HPV and viral loads of HPV DNA Determine the presence of retinoblastoma, p53, and p16(INK4a) gene products 	Viral loads were higher in the IP + SCC group and SCC group
Nudell et al. ⁶⁵³	2014	4	Case-control	20 cases of malignant transformation of sinonasal papilloma	Features associated with malignant transformation of sinonasal papilloma	<ol style="list-style-type: none"> IP is the most common type of Schneiderian papilloma to precede carcinoma Synchronous SCC is the most common carcinoma ex-Schneiderian papilloma
Lin et al. ⁷⁵⁹	2013	4	Case-control	162 specimens of IP with 22 also containing carcinoma	Characterize patterns of IP with and without carcinoma	<ol style="list-style-type: none"> Differences in staining were significant for p16 and p53 Lower expression of p16 was a marker of malignancy and positive staining of p53 correlated with the development of carcinoma in IP
Lee and Kim ⁷⁶⁰	2013	4	Case-control	21 patients with precancerous papilloma or malignant lesions versus 35 samples of benign tissue	Tissue expression of MMP-2, HPV-16, and HPV-18	High MMP-2 expression and HPV-16 or HPV-18 expressions may be associated with the process of malignant transformation of IP
Sham et al. ⁷⁶¹	2012	4	Case-control	Patients with IP, nasal polyps, and hypertrophied turbinates were tested for either HPV ($n = 73$, $n = 48$, and $n = 85$, respectively) or EBV, p21, and p53 ($n = 73$, $n = 30$, and $n = 32$, respectively)	Pathogenesis of sinonasal IP by looking at HPV, EBV, p21, and p53	<ol style="list-style-type: none"> HPV prevalence was overall low in this population of patients with IP, and EBV infection was not present in any patients with IP High levels of p21 and low levels of p53 indicate that the regulation pathway is not dependent on p53 expression
Hasegawa et al. ⁶⁷⁰	2012	4	Case-control	13 patients with IP, 11 patients with SCC of the maxillary sinus, and 39 patients with chronic inflammatory lesions	Role of HPV in sinonasal IP	IP and SCC have higher HPV+ rates and viral load compared to the inflammatory group

(Continues)

TABLE XVI.2 (Continued)

Study	Year	LOE	Study design	Study groups	Clinical endpoints	Conclusion
Jenko et al. ⁷⁶²	2011	4	Case-control	68 patients with sinonasal IP and five patients with sinonasal IP associated with SCC compared to 47 control patients	<ol style="list-style-type: none"> 1. Malignant alteration 2. Recurrence rate 	<ol style="list-style-type: none"> 1. HPV in sinonasal IP ± SCC higher than in the control group 2. HPV DNA was not a predictor of recurrence of IP and was not a significant risk factor for associated SCC
Kim et al. ⁷⁶³	2007	4	Case-control	57 sinonasal IP with histologic grades stage I to stage IV	<ol style="list-style-type: none"> 1. Prevalence of HPV subtypes in samples classified by histological grade 	<ol style="list-style-type: none"> 1. All HPV+ cases were early grade (grade I or II) IP lesions. 2. No higher grade (grades III or IV) lesions showed HPV DNA 3. Five out of seven HPV+ patients were high-risk subtypes and two were unspecified subtypes
Katori et al. ⁶⁵¹	2006	4	Case-control	29 patients with IP, 12 patients with invasive SNSCC, seven patients with exophytic papilloma, and 10 inferior turbinates (control)	Relationship between p21 and p53 expression, HPV infection, and malignant transformation	<ol style="list-style-type: none"> 1. Increase in staining of p21 and p53 was seen in IP with severe dysplasia, IP with carcinoma, and invasive SNSCC as compared to control mucosa. 2. In groups that were HPV+, a significant increase in dysplasia was seen
Hoffmann et al. ⁶⁷¹	2006	4	Case-control	86 patients with sinonasal IP (<i>n</i> = 26), SNSCC (<i>n</i> = 20), sinonasal polyps (<i>n</i> = 20), and control mucosa (<i>n</i> = 20)	Determine whether HPV DNA presence indicates a coincidental, persistent/latent, or specific infection	<ol style="list-style-type: none"> 1. HPV infection was not detected in specimens from clinically intact mucosa or nasal polyps 2. Three out of 26 IP were HPV associated (each double infected with HPV 6 and HPV 11) 3. Four out of 20 SNSCCs were HPV 16 positive
Katori et al. ⁶⁵⁰	2006	4	Case-control	36 patients with sinonasal papilloma, 12 patients with invasive SNSCC, and 10 control patients	Matrix metalloproteinase (MMP)-2 and MMP-9 expression	<ol style="list-style-type: none"> 1. Elevated MMP-2 and 9 may be associated with early events in IP carcinogenesis 2. HPV infection may contribute as an early event in this process
Katori et al. ⁶⁴⁹	2005	4	Case-control	32 patients with sinonasal papilloma, 12 patients with invasive SNSCC, and 10 patients with normal mucosa (control)	HPV status, EGFR expression, and ki-67	<ol style="list-style-type: none"> 1. Significant increase in EGFR and TGF-α expression in IP with severe dysplasia, IP with carcinoma, and invasive SCC as compared to IP with mild dysplasia and control nasal mucosa 2. As dysplasia increased in IP, the Ki-67 increased
Buchwald et al. ⁷⁶⁴	1995	4	Case-control	57 IP (five associated with carcinoma), 16 exophytic papilloma, and five oncocytic papilloma	Presence of HPV DNA	HPV DNA was present in 6% of the benign IP, 69% of the exophytic papilloma, and 40% of the IP that contained carcinoma.

Abbreviations: DSS, disease-specific survival; EGFR, epidermal growth factor receptor; KRAS, Kirsten rat sarcoma viral oncogene homolog; IP, inverted papilloma; OS, overall survival; SNSCC, sinonasal squamous cell carcinoma.

TABLE XVI.3 Evidence surrounding the role of orbital bony resection.

Study	Year	LOE	Study design	Study groups	Clinical endpoints	Conclusion
Wang et al. ⁶⁷⁸	2021	4	Retrospective case series	Patients with periocular IP resected via EEA (<i>n</i> = 22)	1. Recurrence 2. OS	IP invading the orbit required more aggressive treatment compared to those limited to the nasolacrimal system
Shin et al. ⁶⁸³	2015	4	Retrospective case series	Patients with tumors involving the orbit (<i>n</i> = 15; <i>n</i> = 1 with IP resected via EEA)	1. Recurrence 2. Orbital preservation	Endoscopic resection of orbital IP preserved the orbit without recurrence
Christianson et al. ³³⁶	2015	4	Retrospective case series	Patients with benign or malignant sinonasal tumors involving the orbit; (<i>n</i> = 41; <i>n</i> = 13 with IP resected via EEA)	1. Recurrence 2. Orbital preservation	Endoscopic resection of orbital IP provided low rates of recurrence (0/13, 0.0%) and high rates of orbital preservation (13/13, 100.0%)
Saldana et al. ⁶⁸¹	2013	4	Retrospective case series	Patients with IP invading the orbit and open resection (<i>n</i> = 6)	1. Recurrence 2. Orbital preservation	Open resection afforded orbital preservation (5/6, 83.3%) at low risk of recurrence (1/6, 16.7%)
Elnor et al. ⁶⁷⁹	1995	4	Retrospective case series	Patients with IP invading the orbit and open resection (<i>n</i> = 10)	1. Recurrence 2. Orbital preservation	An open surgical approach led to high rates of recurrence (8/10, 80.0%) and orbital exenteration (8/10, 80.0%)
Johnson et al. ⁶⁸⁰	1984	4	Retrospective case series	Patients with sinonasal tumors invading the orbit (<i>n</i> = 47; <i>n</i> = 4 with IP resected openly)	1. Recurrence	Open resection led to high recurrence rates (3/4, 75.0%)

Abbreviations: EEA, endoscopic endonasal approach; IP, inverted papilloma; OS, overall survival.

resection specimens confirming that bony resection is vital in addressing IP lesions.⁶⁸⁷ The areas of skull base attachment should be definitively managed (e.g., drilled, cauterized, or completely resected; can spare dura when there is no malignancy) to decrease the risk of recurrence. Mucosal stripping, however, is not adequate for complete removal (Table XVI.4).⁴¹⁰

Special consideration must be taken for frontal sinus lesions with skull base involvement. The Draf III or peri-orbital suspension techniques can be used to access the superior and lateral extents of the sinus.^{359,690} Combined open and endoscopic approaches, like the transpalpebral orbitofrontal craniotomy, may also be utilized if the tumor cannot be completely accessed endoscopically.^{691,692}

Role of orbital resection for inverted papilloma

Aggregate grade C (Level 4: six studies) of evidence

Benefit Lower recurrence rates with improved orbital preservation.

(Continued)

Harm	Small potential for orbital injury. Baseline risk of epistaxis and postoperative pain.
Cost	Associated costs with surgery.
Benefits-harm assessment	Preponderance of benefits over harms.
Value judgments	Determining involvement of orbit on preoperative imaging is helpful for preoperative planning and patient counseling. There are limited data to suggest that lamina resection may lead to orbital soft tissue seeding/recurrence.
Policy level	Recommendation.
Intervention	Perform resection or drilling of hyperostotic focus for orbital IP with lamina papyracea involvement.

Role of skull base resection for inverted papilloma

Aggregate grade C (Level 4: six studies) of evidence

Benefit Lower recurrence rates with reduced morbidity.

(Continued)

Harm	Small potential for intracranial and/or dural injury and CSF leak. Baseline risk of epistaxis and postoperative pain.
Cost	Associated costs with surgery.
Benefits-harm assessment	Preponderance of benefits over harms.
Value judgments	Determining involvement of skull base on preoperative imaging is helpful for preoperative planning and patient counseling, especially if at risk for CSF leak. There are limited data comparing judicious cautery (e.g., bipolar) versus direct resection of the skull base. Furthermore, there are limited data to suggest that skull base resection may lead to intracranial seeding/recurrence.
Policy level	Recommendation.
Intervention	Perform endoscopic and/or open resection of skull base IP with bony resection, drilling, or cauterization of mucosal rests to adequately address pedicle.

F | Role of radiation or medical therapy

The primary treatment for IP is surgical, yet there remains a role for radiation and/or medical therapy in limited circumstances. RT for IP fell from favor due to anaplastic transformation following irradiation of the tumors.⁶⁹³⁻⁶⁹⁶ More recent literature has dispelled this concern as no such relationship could be confirmed in the majority of IP-associated squamous cell carcinoma (IP-SCC) cases.⁶⁹⁷⁻⁶⁹⁹ To date, there is no consensus as to indications for RT in the treatment of IP, yet associated carcinoma, multiple recurrent disease, and impossibility of resection are widely accepted. While there are limited data, the published studies report superior rates of LRC and OS when RT is used as adjuvant therapy for IP-SCC lesions.^{409,675,700} Prior published data suggest consideration of moderate RT (≤ 60 Gy) in patients following GTR or STR can help prevent recurrence, while higher doses (70 Gy) should be used in those unable to undergo resection (Table XVI.5).⁶⁷⁵

Medical management of IP is a diverse topic, and observational published studies implicate several methods that could be effective but have yet to be established in larger studies. Most forms of medical therapy are experimental in nature. In one study, topical 5-fluorouracil applied to the wound bed following excision yielded a statistically significant reduction in recurrence rate, although there is some concern for confounding due to patient selection.⁷⁰¹ In another study, Anlotinib, a tyrosine kinase inhibitor, showed some efficacy for IP lesions with malignant foci.⁷⁰² Other studies have suggested use of COX2 inhibitors, HPV vaccines, and other experimental agents

to reduce recurrence rate of IP, yet each of these are observational reports not supported by sufficient data to make generalizable claims.^{703,704} Some cases report use of neoadjuvant chemotherapy for unresectable disease, which can facilitate resection if there is good response to treatment.⁷⁰⁵ Overall, medical management strategies cannot be supported by substantive evidence at this time to provide recommendations.

Role of radiation therapy for inverted papilloma

Aggregate grade C (Level 4: four studies) of evidence	
Benefit	Potential for improved disease control in patients in whom surgery has failed or is not possible.
Harm	Nearly all patients experience minor (mucositis, conjunctivitis, xerostomia, epiphora, anorexia) adverse effects from toxicity, some with major (CNS, radionecrosis, visual changes, etc.) effects that can be life threatening.
Cost	Procedural costs, as well as radiation-associated morbidity.
Benefits-harm assessment	Balance of benefits and harms.
Value judgments	Role of RT is well established but limited to specific circumstances in management of IP.
Policy level	Option.
Intervention	Consider RT for patients who meet limited indications or special conditions such as unresectable disease, poor surgical candidates, multiply recurrent lesions, or IP associated with malignancy.

G | Treatment of site of attachment

IPs usually grow in an exophytic, noninvasive way and, as a result, their site of attachment requires resection, or management, along with the lesion.⁷⁰⁶ CT and MRI can be used as adjuncts for preoperative identification of attachment site. CT has the lowest sensitivity ($\sim 50\%$) but high specificity (PPV as high as 100%) for identification of attachment site when hyperostosis is present.⁷⁰⁶⁻⁷¹⁴ These studies also report that MRI is superior for detecting site of attachment (sensitivity $\sim 80\%$) when able to detect the classic columnar and cerebriform patterns typical of IP (Table XVI.6).^{707,710}

If the pedicle is identified preoperatively or intraoperatively, there is clear consensus among the literature that resection of the attachment site is paramount for effective clearance of IP.^{137,305} Incomplete removal is thought to be the primary reason for postoperative recur-

TABLE XVI. 4 Evidence surrounding the role of skull base bony resection.

Study	Year	LOE	Study design	Study groups	Clinical endpoints	Conclusion
Tilak et al. ³⁵⁹	2021	4	Retrospective case series	Patients undergoing periorbital suspension during EEA ($n = 29$; $n = 11$ with IP)	1. Recurrence 2. Complications	Periorbital suspension provided excellent endoscopic access for curative resection with low recurrence (0/11, 0.0%) and complications (0/11, 0.0%)
Pietrobon et al. ⁶⁹²	2019	4	Retrospective case series	Patients undergoing EEA or combined EEA and open approaches for IP involving the frontal sinus ($n = 47$)	1. Recurrence 2. Complications	Management of IP involving the frontal sinus should tailor surgical technique to its site of attachment and extension and the anatomical conformation of each frontal sinus in order to achieve low recurrence (2/47, 4.3%) and complications (1/47, 2.1%)
Albathi et al. ⁶⁹¹	2018	4	Retrospective case series	Patients with IP involving the lateral frontal sinus undergoing EEA and Draf IIB or Draf III sinusotomy ($n = 4$)	1. Recurrence 2. Complications	Aggressive endoscopic resection of skull base IP was effective at producing durable cure rates (0/4, 0.0% recurrence) with acceptable complication rates (1/4, 25.0%)
Grayson et al. ⁶⁷³	2016	4	Retrospective case series	Patients with skull base IP resected via EEA ($n = 49$)	1. Recurrence 2. Complications	Aggressive endoscopic resection of skull base IP was effective at producing durable cure rates (0/49, 0.0% recurrence) with acceptable complication rates (5/49, 10.2%)
Gras-Cabrerizo et al. ⁶⁸⁹	2013	4	Retrospective case series	Patients with varying skull base lesions resected via EEA ($n = 72$; $n = 5$ with IP)	Recurrence	Aggressive endoscopic resection of skull base IP was effective at producing durable cure rates (0/5, 0.0% recurrence)
Endo et al. ⁶⁸⁸	2008	4	Retrospective case series	Patients with sinonasal IP resected via EEA and/or open approaches ($n = 24$; $n = 15$ with bony resection)	Recurrence	Bony resection reduced recurrence rates when skull base involvement was suspected (2/15, 13.3% vs. 7/17, 41.2%)

Abbreviations: EEA, endoscopic endonasal approach; IP, inverted papilloma.

rence, and the leading causes of incomplete removal are improper approaches and mismanagement of the attachment site.^{715–718} Debulking of tumor to attachment site, resection of diseased and partially healthy mucosa underlying attachment site, cauterizing the bone and mucosa underlying the attachment site, and/or drilling/resecting the bone underlying the attachment site is a generalized approach commonly employed for IP resection. In one systematic review, there does not appear to be significant advantage of tumor recurrence rates with any specific approach but rather the surgeon can use discretion when employing one or more of these techniques.¹³⁸

When IP lesion attachment sites are in problematic areas such as the sphenoid sinus, anterior wall of the maxillary sinus, frontal sinus, or hidden behind large bulky disease, the literature base is clear that surgeons must prioritize access to the pedicle and may need to utilize extended endoscopic surgical approaches such as Draf III, bilateral sphenoidotomy with or without a sphenoid drill-out, transseptal access with crossing multiple incisions (TACMI), prelacrimal approaches, modified endoscopic medial maxillectomy, or Denker's approaches.^{303,706,719–725} Multifocal attachment of IP was more commonly seen in recurrent lesions and conferred a 3.5-fold increased risk of recurrence when present.⁷²⁶ Some studies reported

TABLE XVI.5 Evidence surrounding the role of radiation therapy in management of IP.

Study	Year	LOE	Study design	Study groups	Clinical endpoints	Conclusion
Rutenberg et al. ⁷⁰⁰	2013	4	Retrospective case series	Patients with advanced or recurrent IP or cylindrical cell papilloma treated with adjuvant, definitive, or neoadjuvant RT ($n = 13$)	1. Recurrence 2. Complications	RT should be considered in patients with unresectable disease, multiply recurrent lesions, or papillomas associated with malignancy, given low risk (1/13, 7.6%) of severe complication
Strojan et al. ⁶⁷⁵	2013	4	Case report	Patient with IP undergoing adjuvant RT ($n = 1$)	Recurrence	RT was safe and effective following STR
Gomez et al. ⁶⁹⁸	2000	4	Retrospective case series	Patients with advanced and/or recurrent IP or cylindrical cell papilloma with or without SCC, treated with adjuvant, definitive, or neoadjuvant RT ($n = 8$)	1. Recurrence 2. Complications	RT may be considered albeit with high rates of recurrence in IP only (1/1, 100.0% RT only; 2/4, 50.0% surgery with adjuvant RT) and IP with SCC patients (1/1, 100.0% neoadjuvant RT with surgery; 2/2, 100.0% surgery with adjuvant RT)
Hug et al. ⁶⁹⁷	1993	4	Retrospective case series	Patients with locally advanced IP with or without SCC, treated with adjuvant or definitive RT ($n = 25$)	1. Recurrence 2. Complications	RT effectively controlled locally advanced IP (4/25, 16.0% recurrence) but also led to a high rate of severe adverse events related to treatment (6/25, 24.0%)
Guedea et al. ⁷⁶⁵	1991	4	Retrospective case series	Patients with advanced IP or cylindrical cell papillomas treated with definitive or neoadjuvant or adjuvant RT ($n = 7$)	1. Recurrence 2. Complications	Although surgery is generally the primary treatment for IP, radiation may be considered for patients with advanced, incompletely resected, or unresectable lesions with low risk for recurrence (1/7, 14.2%) or severe complication (0/7, 0.0%)

Abbreviations: IP, inverted papilloma; RT, radiation therapy; SCC, squamous cell carcinoma.

that large IP lesions often originated from a narrow pedicle or unifocal attachments. However, multifocal and large diameter attachments can occur in primary lesions (Table XVI.7).⁷⁰⁷

Imaging of the site of attachment in inverted papilloma

Aggregate grade of evidence	C (Level 3: two studies; Level 4: five studies)
Benefit	Imaging is useful for accurate identification of IP pedicle for preoperative planning.

(Continued)

Harm	Mild radiation associated with CT imaging as well as contrast burden for CT and MRI images.
Cost	Associated costs with imaging studies.
Benefits-harm assessment	Preponderance of benefits over harms.
Value judgments	Determining site of attachment is imperative for effective surgery and to reduce local recurrence.
Policy level	Recommendation.
Intervention	Utilize preoperative CT (as evidenced by osteitis) with or without MRI for accurate identification of IP attachment site, which can also be used to guide surgical approach.

TABLE XVI. 6 Evidence surrounding the use of imaging to predict pedicle location.

Study	Year	LOE	Study design	Study groups	Clinical endpoints	Conclusion
Lee et al. ⁶⁸⁴	2021	3	Retrospective cohort	Patients with IP who underwent CT preoperatively for surgical planning (<i>n</i> = 86)	1. Identification of pedicle 2. Sensitivity 3. Specificity	CT is useful preoperative tool to identify site of origin and had high specificity (92.0%) but low sensitivity (59.5%) for skull base involvement
Al Badaai et al. ⁷⁶⁶	2011	3	Retrospective cohort	Patients with IP or cylindrical papilloma who underwent preoperative CT for localization of site of origin by a head and neck radiologist (<i>n</i> = 34)	1. Identification of pedicle 2. Sensitivity 3. Specificity	Osteitic changes are common and nonspecific Sensitivity 74%, specificity 0%, predictive value for localization was 41%
Fang et al. ⁷⁰⁹	2016	4	Retrospective case series	Patients with IP who underwent preoperative MRI and CT for localization of site of origin (<i>n</i> = 143)	1. Identification of pedicle 2. Sensitivity 3. Specificity	CT combined with MRI provides increased sensitivity (94.6%) and specificity (92.3%) for preoperatively localization of origin site for sinonasal IP
Bhalla and Wright ⁷⁰⁸	2009	4	Retrospective case series	Patients who underwent CT for preoperative prediction of site of attachment of IP lesion (<i>n</i> = 24)	1. Identification of pedicle 2. PPV	Computed tomography imaging has a high PPV (95%) when determining most likely site of attachment for IP
Lee et al. ⁷¹¹	2007	4	Retrospective case series	Patients with hyperostotic foci on preoperative imaging (CT) for surgical planning for IP (<i>n</i> = 48)	Identification of pedicle	CT imaging revealing hyperostosis in the setting of IP was predictive of site of attachment in 49 out of 55 cases (89.1%)
Yousuf and Wright ⁷¹⁴	2007	4	Retrospective case series	Patients with preoperative CT imaging of IP (<i>n</i> = 28)	Identification of pedicle	CT imaging revealing hyperostosis in the setting of IP was predictive of the site of attachment in 22 out of 25 cases (88.0%)
Maroldi et al. ⁷¹³	2004	4	Retrospective case series	Patients with sinonasal tumors and preoperative imaging (MRI) (<i>n</i> = 46; <i>n</i> = 23 with primary or recurrent IP)	1. Identification of IP 2. PPV	A columnar pattern was a reliable MRI indicator of IP histology (PPV = 95.8%) and can be used to differentiate from malignant lesions

Abbreviations: CT, computed tomography; IP, inverted papilloma; MRI, magnetic resonance imaging; PPV, positive predictive value.

TABLE XVI.7 Evidence surrounding the role of treatment of attachment site.

Study	Year	LOE	Study design	Study groups	Clinical endpoints	Conclusion
Spinos et al. ⁷⁰⁶	2021	4	Retrospective case series	Patients undergoing EEA for IP with intracranial or intraorbital involvement (<i>n</i> = 18)	1. Recurrence 2. Complications	Endoscopic endonasal approach to IP with prioritization of pedicle-oriented resection induces durable cure for IP (2/18, 11.1% recurrence), even when multiply recurrent, with low risk for complication (0/18, 0.0%)
Wang et al. ⁷⁰⁷	2020	4	Retrospective case series	Patients undergoing EEA for IP involving the frontal sinus/recess (<i>n</i> = 13)	1. Recurrence 2. Complications	Endoscopic resection of IP with prioritization of pedicle-oriented resection induces durable cure for IP (0/13, 0.0% recurrence), even when involving the frontal sinus, with low risk for complication (0/13, 0.0%)
Ferrari et al. ⁷¹⁰	2020	4	Retrospective case series	Patients undergoing EEA for IP (<i>n</i> = 210)	1. Recurrence 2. Complications	Insertion-driven resection of IP is adequate for IPs limited to NOE and frontal sinus, whereas centripetal resection should be considered for maxillary IPs
Wu et al. ³⁰⁵	2018	4	Retrospective case series	Patients undergoing EEA for maxillary sinus IP (<i>n</i> = 28)	1. Recurrence 2. Complications	IPs originating from maxillary sinus frequently had multifocal attachments but this did not impact recurrence when pedicle-oriented resection conducted
Dean et al. ³⁰³	2015	4	Retrospective case series	Patients undergoing endoscopic modified medial maxillectomy for IP located on the anterolateral maxillary wall (<i>n</i> = 35)	1. Recurrence 2. Complications	Visualization of pedicle in anatomically difficult areas, such as the anterior or anterolateral maxillary sinus is possible without an open approach
Suh et al. ⁷²⁰	2015	4	Retrospective case series	Patients undergoing open, transnasal, or combined approaches with or without adjuvant RT for IP (<i>n</i> = 57)	Recurrence: seven out of 48 (14.6%) Complications: NA OS	1. IP was associated with a 26.8% (18/67 procedures) rate of recurrence 2. Risk factors for recurrence included attachment sites over the optic nerve and carotid artery or evidence of dysplasia or CIS
Pagella et al. ¹³⁷	2014	4	Retrospective case series	Patients undergoing either global ESS (sinus demucosalization with bony drilling) or POES for IP (<i>n</i> = 73)	1. Recurrence 2. Complications	1. Data confirm efficacy of endonasal endoscopic treatment of IP (0/37, 0.0% recurrence) 2. POES offers an equally effective oncologic outcome (1/36, 0.0%) with fewer complications (0/36, 0.0% vs. 6/37, 16.2%, <i>p</i> < 0.05)

Abbreviations: EEA, endoscopic endonasal approach; ESS, endoscopic sinus surgery; IP, inverted papilloma; POES, pedicle-oriented endoscopic surgery; RT, radiation therapy.

Treatment of the site of attachment in inverted papilloma

Aggregate grade of evidence	C (Level 4: seven studies)
Benefit	Lower recurrence rates with reduced morbidity.
Harm	Baseline risk of epistaxis and postoperative pain.
Cost	Associated costs with surgery.
Benefits-harm assessment	Preponderance of benefits over harms.
Value judgments	The surgeon must attempt to identify the attachment site in order to properly resect this region to minimize risk of recurrence.
Policy level	Recommendation.
Intervention	Perform pedicle-oriented resection via any surgical approach in order to definitively address primary site and reduce recurrence risk. Definitive treatment may entail cauterization or drilling of the pedicle following mucosal resection.

H | Recurrence and surveillance

Predilection for recurrence is one of the most significant clinical features of IP, with published recurrence rates as high as 78%.^{410,644,727} As such, there are several published reports who aim to define the most important risk factors that portend recurrence. One multivariate retrospective analysis indicates the presence of moderate to severe dysplasia, Dragonetti-Minni classification, anatomic location of lesion, and history of prior sinonasal surgery as the key factors associated with recurrence.⁷²⁸ Other notable studies identified detection of HPV,⁶⁷ young age at initial diagnosis,⁶⁸ smoking history,^{64,66,69} multiple IP attachment sites,^{54,63} Krouse stage T3 or T4,⁷⁰ and postoperative elevation of serum SCC antigen levels⁷¹ as risk factors for recurrence.^{138,644,726,728-733}

Endoscopic resection of IP, as compared with traditional open techniques, afforded obvious reduction in morbidity of resection, yet endoscopic techniques were only widely accepted once recurrence rates were at least as good as open approaches.^{409,734-736} One of the largest meta-analyses of outcomes of IP resection by surgical approach documented recurrence rates of 12.8%, 16.58%, and 12.60% for endoscopic, open, and combined surgical approaches, respectively (Table XVI.8).^{737,738}

The majority of recurrent IP lesions arise within the first year following resection and often occur in the same anatomic location as the primary lesion; however, 20% of recurrences will occur after 5 years postoperatively.⁷³⁹ Given this potential for late recurrence and potential metachronous malignant transformation, IP follow-up

duration and modalities should include routine endoscopic evaluation or MRI in lesions not easily seen endoscopically for a minimum of 5 years postoperatively, followed by recommended lifetime follow-up.^{736,740}

Postoperative follow-up appears to primarily consist of clinical history, endoscopy, and interval CT/MRI scans. Some recurrences are subclinical in up to 70% of cases, so radiographic follow-up is imperative in those lesions that cannot be adequately evaluated endoscopically.⁷⁰¹ One study elucidating the role of radiographic follow-up for IP determined that MRI visualized recurrent lesions and permitted precise evaluation of extension where CT remained equivocal in 40% of recurrent lesions.⁷⁴¹ There are also published small case series indicating a possible role for ¹⁸FDG-PET/CT whereby patients who had suspected recurrences had avid lesions on PET and those without recurrence did not, yet the use of nuclear medicine surveillance is not established for IP (Table XVI.9).^{742,743}

Recurrence risk and surveillance in inverted papilloma

Aggregate grade of evidence	Recurrence: B (Level 2: three studies, Level 3: two study, Level 4: 14 studies) Surveillance: C (Level 4: six studies)
Benefit	Prognosis for recurrence can be determined by identification of risk factors (multifocal attachment, prior surgery, high-risk HPV, STR such as disease overlying carotid, etc.). Prolonged surveillance allows for prompt identification of IP recurrence.
Harm	Potential for under- or oversurveillance and early discharge from surveillance that would preclude detection of later recurrences.
Cost	Clinical charges associated with assessment of risk factors including clinic visits for history and physical, imaging, endoscopy, and operative cost for intra/postoperative risk factor assessment.
Benefits-harm assessment	Preponderance of benefits over harms.
Value judgments	Risk factors for recurrence are wide ranging and need to be assessed on a patient-specific basis. Determining presence of recurrence as soon as evident will allow for more timely intervention of a less extensive tumor and potential mitigation of malignant transformation risk. Though endoscopy may be utilized for most surveillance visits, imaging may be considered for specific cases (e.g., maxillary sinus following prelacrima approach, lateral frontal sinus).

(Continued)

TABLE XVI.8 Evidence surrounding recurrence of IP.

Study	Year	LOE	Study design	Study groups	Clinical endpoints	Conclusion
Trent et al. ¹³⁸	2022	2	Systematic review	Patients with IP treated via endoscopic, open, and combined resection approaches across 14 studies ($n = 585$)	Recurrence	<ol style="list-style-type: none"> 1. No single resection technique predicted a propensity for recurrence, but varied on location of pedicle 2. Pedicle in sphenoid sinus with highest recurrence rate (10.4% vs. 5.8% overall) 3. Intraoperative frozen section significantly reduced rates of recurrence (3.4% vs. 7.3%, $p = 0.045$)
Peng and Har-El ⁷³⁷	2019	2	Systematic review and meta-analysis	Patients who underwent endoscopic, open, or combined endoscopic and open approaches for resection of IP across 96 studies ($n = 4134$)	Recurrence	Large body of data indicating endoscopic resection has improved ability to prevent recurrence following resection of IP relative to open approaches (RR = 0.66, $p = 0.014$ after adjusting for publication bias)
Lisan et al. ⁷³²	2017	2	Systematic review and meta-analysis	Patients across 13 studies undergoing resection of IP via any approach ($n = 1787$)	Recurrence	<ol style="list-style-type: none"> 1. IP lesions classified as stage T3 according to the Krouse classification system presented a higher likelihood of recurrence compared to Krouse stage 2 (OR = 1.51, $p = 0.01$) 2. No significant difference in recurrence between T1 versus T2 or T3 versus T4 IP
Pähler Vor der Holte et al. ⁷³⁰	2020	3	Retrospective cohort	Patients with sinonasal papillomas resected via endoscopic or combined open/endoscopic approaches ($n = 101$; $n = 91$ with IP)	Recurrence	Factors associated with increased risk for recurrence included young age at initial diagnosis, epithelial dysplasia, and incomplete resection
Van Zijl et al. ⁷³³	2017	3	Retrospective cohort	Patients with IP and available preoperative, postoperative, and follow-up serum squamous cell carcinoma antigen values ($n = 130$)	Recurrence	Postoperative SCC antigen is strongly positively associated with risk of recurrence (AUC: 80.9%)
Kim et al. ⁷³⁴	2022	4	Retrospective case series	Patients undergoing maxillary IP resection via endoscopic resection with or without Caldwell Luc, canine fossa trephination, or expanded endoscopic approaches ($n = 155$)	Recurrence	Patients with disease originating from maxillary sinus showed significantly more durable cure rates with expanded endoscopic approaches (medial maxillectomy, prelacrima approach, etc.) (0.0% [0/28] vs. 10.0% [7/70], $p = 0.024$)

(Continues)

TABLE XVI.8 (Continued)

Study	Year	LOE	Study design	Study groups	Clinical endpoints	Conclusion
Viitasalo et al. ⁷²⁹	2021	4	Retrospective case series	Patients with IP treated endoscopically either with or without attachment-oriented resection ($n = 90$)	Recurrence	Risk of IP recurrence was highly associated with HPV positivity in >1 resection specimen versus 0 (72.2% [13/18] vs. 34.7% [25/72], $p = 0.004$) and surgical approach without attachment-oriented resection versus with (78.6% [22/28] vs. 25.8% [16/62], $p < 0.001$)
Minni et al. ⁷²⁸	2021	4	Retrospective case series	Patients with IP resected via endoscopic or combined open and endoscopic approaches ($n = 130$)	Recurrence	Recurrence of sinonasal IP is significantly increased based upon site of origin (anterior maxillary wall 7/12 [58.3%] and frontal sinus attachment [3/12, 25.0%] [$p = 0.045$]), increasing Dragonetti–Minni Stage ($p = 0.045$), and presence of dysplasia (HR = 2.4, $p = 0.038$)
Tong et al. ⁷²⁶	2019	4	Retrospective case series	Patients with IP resected via EEA ($n = 210$)	Recurrence	Primary resection (12.4% vs. 22.3%, $p > 0.05$) and single-focus attachment of IP (6.1% vs. 12.5%, $p = 0.002$) are associated with lower recurrence at 3-year follow-up
Miglani et al. ⁴⁰⁹	2018	4	Retrospective case series	Patients with IP who underwent EEA until clear margins on intraoperative frozen histopathology ($n = 22$)	Recurrence	Clearance of margins on frozen sections may lead to lower rates of IP recurrence (0.0%, 0/22)
Bugter et al. ⁷³⁸	2017	4	Retrospective case series	Patients with IP resected via endoscopic, open, or combined approaches ($n = 247$)	1. Recurrence 2. Time to recurrence	1. Given prolonged mean time to recurrence (20.5 months), long-term follow-up may be required 2. EEA approaches have comparable, if not improved, recurrence rates over open or combined approaches (16/79 [21.7%] vs. 54/154 [35.1%] [$p = 0.017$] vs. 4/14 [28.6%], respectively)
Roh et al. ⁷¹⁷	2016	4	Retrospective case series	Patients with IP undergoing EEA resection with or without Caldwell-Luc approach ($n = 54$)	Recurrence	Smoking was associated with recurrence of IP (42.9% [3/7] vs. 8.5% [4/47], $p = 0.039$), whereas HPV positivity versus negativity (0.0% [0/8] vs. 15.2% [7/46], $p = 0.580$) was not found to be a risk factor

(Continues)

TABLE XVI.8 (Continued)

Study	Year	LOE	Study design	Study groups	Clinical endpoints	Conclusion
Healy et al. ⁴¹⁰	2016	4	Retrospective case series	Patients undergoing EEA for IP or oncocytic papilloma (<i>n</i> = 127)	1. Recurrence 2. Time to recurrence	Drilling, cauterizing, or completely excising the bone underlying the tumor base during endoscopic resection reduced the recurrence rate of inverted and oncocytic papilloma when compared to mucosal stripping alone (4.9% [3/61] vs. 4.7% [1/21] vs. 0.0% [0/22] vs. 52.2% [12/23], <i>p</i> = 0.001)
Ungari et al. ⁷³⁵	2015	4	Retrospective case series	Patients with IP undergoing resection via open, endoscopic, or combined approaches (<i>n</i> = 35)	Recurrence	Radical removal with emphasis on bony resection may be key to prevent recurrence of IP
Moon et al. ⁷³¹	2010	4	Retrospective case series	Patients who underwent resection via endoscopic, open, or combined approaches for IP (<i>n</i> = 132)	Recurrence	Smoking (28.2% [11/39] vs. 10.8% [10/93], <i>p</i> = 0.012) and tumor with extranasal/sinus extension (OR = 15.2, <i>p</i> = 0.049) appear to be associated with increased rates of IP recurrence after surgical resection
Diaz-Molina et al. ⁷³⁶	2009	4	Retrospective case series	Patients undergoing endoscopic, open, or combined resection for IP (<i>n</i> = 61)	1. Recurrence 2. Time to recurrence	1. The endoscopic approach achieved low recurrence rates compared to open approaches (14.3% [6/42] vs. 66.7% [6/9]) 2. Close long-term follow-up is warranted for early detection and to allow for surgical salvage (mean time to recurrence 41 months)
Woodworth et al. ⁷²¹	2007	4	Retrospective case series	Patients undergoing endoscopic or endoscopic-assisted open resection for IP (<i>n</i> = 114)	1. Recurrence 2. Time to recurrence	Recurrences occurred an average of 23 months after surgery, emphasizing need for long-term endoscopic follow-up to detect recurrence (15% [17/114])
Peng and Har-El ⁷²⁷	2006	4	Retrospective case series	Patients with IP resected via midfacial degloving and medial maxillectomy (<i>n</i> = 98)	Recurrence	Midface degloving can result in excellent access for resection with durable cure rates (2.1% [2/98] recurrence) without scar of lateral rhinotomy incision
Kraft et al. ⁷¹⁸	2001	4	Retrospective case series	Patients with sinonasal papillomas (<i>n</i> = 43; <i>n</i> = 34 with IP)	Recurrence	Suggested role for HPV in the pathogenesis of sinonasal papilloma but no correlation seen between HPV and rates of recurrence or malignancy

Abbreviations: AUC, area under the curve; EEA, endoscopic endonasal approach; IP, inverted papilloma; SCC, squamous cell carcinoma.

TABLE XVI.9 Evidence surrounding surveillance of IP.

Study	Year	LOE	Study design	Study groups	Clinical endpoints	Conclusion
Sbrana et al. ⁶⁴⁴	2021	4	Retrospective case series	Patients diagnosed with sinonasal papilloma undergoing ESS with or without open approach ($n = 69$; $n = 49$ with IP)	1. Recurrence 2. Time to recurrence 3. Malignant transformation	Recurrences (34.09% [15/44]) were observed up to 10 years postoperatively (mean 24.6 months), indicating need for prolonged follow-up
Binz et al. ⁷³⁹	2021	4	Retrospective case series	Patients diagnosed with primary IP undergoing EEA resection ($n = 102$)	Recurrence	Long-term follow-up is important due to documented cases of recurrences more than 5 years following index surgery (20.0% [2/10] of recurrences)
Allegra et al. ⁷⁴³	2010	4	Retrospective case series	Patients with concern for primary or recurrent IP undergoing preoperative ¹⁸ F-DG-PET/CT imaging ($n = 12$)	Recurrence	¹⁸ F-DG uptake on PET/CT imaging may represent a helpful adjunctive tool to determine presence of recurrent IP for patients in whom recurrence is suspected
Diaz Molina et al. ⁷³⁶	2009	4	Retrospective case series	Patients undergoing endoscopic, open, or combined resection for IP ($n = 61$)	1. Recurrence 2. Time to recurrence	Close, long-term follow-up is necessary for early detection of recurrence (mean time to recurrence of 41 months) and successful surgical salvage
Woodworth et al. ⁷²¹	2007	4	Retrospective case series	Patients undergoing endoscopic or endoscopic-assisted open resection for IP ($n = 114$)	1. Recurrence 2. Time to recurrence	Long-term endoscopic follow-up for surveillance of recurrence following IP resection is imperative (mean time to recurrence of 23 months)
Petit et al. ⁷⁴¹	2000	4	Retrospective case series	Patients diagnosed with recurrent IP ($n = 10$)	1. Recurrence 2. Time to recurrence	MRI may represent the most effective imaging modality for IP recurrence detection (mean time to recurrence 43 months) relative to CT and endoscopic exams and should be considered for surveillance, particularly when the area cannot be adequately assessed with endoscopy

Abbreviations: CT, computed tomography; EEA, endoscopic endonasal approach; ESS, endoscopic sinus surgery; FDG, fluorodeoxyglucose F 18 (¹⁸F-FDG); IP, inverted papilloma; MRI, magnetic resonance imaging; PET, positron emission tomography.

Policy level	Recommendation.
Intervention	Recommend identification of evidence-based risk factors that will increase risk of recurrence for IP and prolonged follow-up for surveillance of IP patients due to propensity for delayed recurrence. Close clinical follow-up for all patients due to risk for recurrence even after 5 years.

XVII | BENIGN VASCULAR NEOPLASMS AND LESIONS

A | Juvenile nasopharyngeal angiofibroma

JNA is a benign but locally destructive, highly vascular lesion that typically affects adolescent males.⁷⁶⁷ JNA accounts for approximately 0.5% of head and neck tumors with an incidence of about 1 in 150,000.^{6,768} The most

common presenting symptoms are nasal obstruction (76%–100%) and recurrent epistaxis (45%–77%).^{767,769}

Etiology is controversial—some evidence suggests that they are the result of a nonresorbed remnant of the first branchial arch, while other evidence suggests that angiofibromas develop in a specific hormonal and genetic milieu.^{770–772} Clinically, they originate from the posterior nasal cavity, near the basisphenoid and the superior margin of the sphenopalatine foramen. Patterns of extension are determined by the surrounding foramina: medially into the nasal cavity, nasopharynx, and paranasal sinuses through the sphenopalatine foramen; superior into the orbit via the infraorbital fissure; inferiorly into the greater palatine foramen; and laterally into the infratemporal fossa via the pterygomaxillary fissure. Extension to the skull base and intracranially can be seen in up to 26% of cases.⁷⁷³

Workup typically includes imaging with CT, MRI, and angiography. Recent advances in CT have allowed for dynamic flow imaging, termed four-dimensional CT. Early studies have demonstrated similar performance and less radiation exposure when compared to gold standard digital subtraction angiography, but additional work is required to define its role in the management of patients with JNA.⁷⁷⁴ Biopsy is not routinely performed, especially in the outpatient setting, given the possibility of massive hemorrhage unless radiographic features are atypical and there is concern for malignancy.

Histologically, the tumors demonstrate a dense stromal component with a large population of fibroblasts as well as vessels of varying caliber. Immunohistochemical stains will demonstrate β -catenin, androgen receptor, estrogen receptor B, and prostate-specific antigen expression. Genomic analysis has demonstrated fourfold upregulation in vascular endothelial growth factor (VEGF) signaling.⁷⁷⁵ High c-Kit expression has been associated with rapid tumor growth and recurrence, while high VEGF signaling has been associated with skull base involvement and hemorrhage.⁷⁷⁶

This current section represents an update on the prior evidenced-based review with recommendations published in ICSB 2019 (section V.A) and focuses on studies published from 2018 to 2022.^{5,777} For specific outcomes that were not addressed in the ICSB, a complete systematic review and subsequent evidenced-based review with recommendations were performed.⁷⁷⁸

1 | Open versus endoscopic approaches

JNA is most commonly managed surgically. Historically, open craniofacial approaches were employed; however, EEA has been successfully employed in recent years for management. Current EBRs support the utility and

outcomes of EEA in addition to preoperative embolization as the preferred method of tumor resection.^{5,777} A more recent meta-analysis of nine studies including 362 patients demonstrated superiority of the endoscopic and/or combined approaches when compared to purely open approaches with respect to recurrence, irrespective of tumor stage: 2% versus 17% for low-stage tumors, and 26% versus 32% for high-stage tumors.³⁵¹ This single meta-analysis represents the strongest LOE at present comparing endoscopic and open techniques in the management of JNA and has increased the aggregate LOE from the ICSB.^{5,777} Long-term institutional studies that transitioned initially from open approaches to endoscopic or combined approaches also lend evidence to support the superiority of EEA for management of JNA. Szyfter et al. report a series of 71 patients over 20 years (37 patients with open-only approaches and 34 with endoscopic or combined approaches). They report less blood loss, lower rates of recurrence, and fewer side effects of open approaches (scarring, cranial neuropathies) when employing the endoscopic approach.⁷⁷⁹ Similarly, Cohen-Cohen et al. report a 22-patient cohort compared to an internal 65-patient historical cohort and found increasing utilization of EEA in recent cases with preservation of tumor control and equivalent recurrence rates.⁷⁸⁰

Stapleton et al. performed a cost analysis of 55 pediatric patients who underwent EEA for skull base lesions; in this cohort, there were six patients with JNA. They found that, on average, surgery accrued \$59,915 in-hospital costs with a mean LOS of 3.3 days. JNA was associated with the greatest hospital costs of the pathologies studied. While there was no direct comparison to tumors managed with open craniofacial approaches, the LOS for the endoscopic management of JNA determined in this series was lower than data published for open approaches; thus, the authors conclude that endoscopic management of JNA was a cost-effective approach in the pediatric population (Table XVII.A.1).⁷⁸¹

Open versus endoscopic approaches for JNA

Aggregate grade of evidence	B (Level 2: one study; Level 4: seven studies)
Benefit	Endoscopic approaches demonstrate comparable and possibly reduced tumor recurrence rates along with lower patient morbidity and intraoperative bleeding.
Harm	Endoscopic approach is associated with low complication rates and morbidity.
Cost	Endoscopic management is associated with favorable costs when compared to costs from open surgery.

(Continued)

TABLE XVII. A. 1 Evidence surrounding open versus endoscopic surgery for JNA.

Study	Year	LOE	Study design	Study groups	Clinical endpoints	Conclusion
Reyes et al. ³⁵¹	2019	2	Meta-analysis	Nine studies of patients with JNA treated with open versus endoscopic surgical approach (<i>n</i> = 362)	Recurrence rates	<ol style="list-style-type: none"> 1. Endoscopic approach had significantly lower rates of recurrence than open approach for all tumor stages 2. Advanced tumors had significantly higher recurrence rates than low-stage tumors
Cohen-Cohen et al. ⁷⁸⁰	2021	4	Case-control	Patients who underwent surgical resection of JNA from 2005 to 2019 compared to 65 historical cases (<i>n</i> = 22)	<ol style="list-style-type: none"> 1. Surgical approach 2. GTR 3. Intraoperative blood loss 4. Recurrence 	<ol style="list-style-type: none"> 1. 82% of cases were managed endoscopically in the modern cohort versus 8% in historical cohort 2. Significantly less blood loss in endoscopic cohort 9% recurrence rate versus 24% recurrence rate comparing endoscopic to historical open cohort
Schofield et al. ⁸¹²	2021	4	Retrospective case series	Patient series who underwent midfacial degloving for resection of JNA (<i>n</i> = 21)	<ol style="list-style-type: none"> 1. Blood loss 2. Operative time 3. Complications 4. Residual and recurrent disease 	<ol style="list-style-type: none"> 1. Midfacial degloving is a good approach for tumors that involve the infratemporal fossa and orbit 2. Median 600 mL blood loss, median 105 min operative time, two episodes of epistaxis, three patients with residual disease, one patient with recurrent disease
Szyfter et al. ⁷⁷⁹	2021	4	Retrospective case series	Patients who underwent either open or endoscopic resection of JNA (<i>n</i> = 71)	<ol style="list-style-type: none"> 1. GTR 2. Rates of residual or recurrent tumor 3. Blood loss 	<ol style="list-style-type: none"> 1. 72% of patients had GTR 2. 28% had residual or recurrent tumor that required reoperation 3. Low-stage tumors had 100–400 mL blood loss; advanced tumors had 500–2500 mL blood loss
Sousa et al. ⁷⁶⁹	2019	4	Retrospective case series	Patients with JNA treated with open surgical approaches (<i>n</i> = 27)	<ol style="list-style-type: none"> 1. Intraoperative blood loss 2. GTR 3. Recurrence 	<ol style="list-style-type: none"> 1. 1500 mL mean blood loss 2. 66.7% cases of GTR 3. Nine patients with recurrence or residual tumor
Epprecht et al. ⁸¹³	2018	4	Retrospective case series	Patients with JNA: four treated with open approach versus nine treated endoscopically (<i>n</i> = 13)	<ol style="list-style-type: none"> 1. Postoperative complications 2. Disease persistence 3. Size of persistent disease 	<ol style="list-style-type: none"> 1. Open approach had significantly higher postoperative complications 2. No significant difference in rate or size of persistent disease between open and endoscopic groups
Rupa et al. ⁸¹⁴	2018	4	Retrospective case series	Patients with advanced (Radkowski IIIa or IIIb) JNA (<i>n</i> = 45)	<ol style="list-style-type: none"> 1. Surgical approach (open vs. endoscopic) 2. Disease recurrence 	<ol style="list-style-type: none"> 1. 42% underwent open resection of extracranial tumor versus 58% with endoscopic 2. 72% had no evidence of recurrence/residual, management of recurrence included observation, radiation, and excision in symptomatic patients

(Continues)

TABLE XVII.A.1 (Continued)

Study	Year	LOE	Study design	Study groups	Clinical endpoints	Conclusion
Stapleton et al. ⁷⁸¹	2015	4	Retrospective case series	Cost analysis of patients who underwent endoscopic resection of JNA (<i>n</i> = 6)	1. Length of stay 2. Hospital cost	JNA was associated with \$59,915 in-hospital cost; average LOS was 3.3 days postoperatively

Abbreviations: GTR, gross total resection; JNA, nasopharyngeal angiofibroma (formerly juvenile nasopharyngeal angiofibroma).

Benefits-harm assessment	Preponderance of benefits over harms.
Value judgments	Endoscopic intervention requires familiarity with endoscopic surgery and endoscopic equipment including tools for hemostasis.
Policy level	Recommendation.
Intervention	In experienced institutions, endoscopic and combined approaches are the preferred surgical approaches for management of JNA.

2 | Staging systems

Numerous systems have been used to stage JNA, including Sessions et al. in 1981, Fisch et al. in 1983, Chandler et al. in 1984, Bremer et al. in 1986, Antonelli et al. in 1987, Andrews et al. in 1989, Radkowski et al. in 1996, Onerci et al. in 2006, and Snyderman et al. in 2010 (Table XVII.A.2).⁷⁸²⁻⁷⁹⁰ The University of Pittsburgh Medical Center (UPMC) staging system proposed by Snyderman et al. in 2010 incorporated residual vascularity from the ICA after embolization and was found to have better ability to predict blood loss, need for multiple operations, and tumor recurrence.⁷⁷³ In 2019, Abdelwahab proposed a staging system that incorporated the following factors: nose/nasopharynx, sinus, fossae, cranium, orbit, and residual ICA vascularity (NSF-COR).⁷⁷³ The goal of the system was to create a method for mapping anatomic involvement, allowing for site- and stage-specific recommendation of endoscopic approaches, and incorporating residual ICA vascularity. NSF-COR was applied to a cohort of 54 patients and on analysis correlated significantly with the UPMC system for prognostic ability. Moreover, the COR component of the staging system correlated significantly with blood loss and recurrence. Study details for the UPMC staging system and NSF-COR system are presented in Table XVII.A.3.

Staging systems in JNA

Aggregate grade of evidence	C (Level 4: two studies)
Benefit	Use of staging system that incorporates residual vascularity may better predict intraoperative bleeding and tumor recurrence.
Harm	Numerous staging systems may provide overlapping information and inconsistent correlation of stage with outcomes or biological behavior.
Cost	No specific studies dedicated to assessing cost related to staging systems.
Benefits-harm assessment	Preponderance of benefits over harms.
Value judgments	Staging systems should help prognosticate pathology as well as facilitate communication about specific pathology by providing a common language between providers managing the disease process.
Policy level	Recommendation.
Intervention	The use of a staging system that incorporates residual vascularity has better predictive and prognostic impact than systems that exclusively grade anatomic involvement.

3 | Patterns of recurrence and natural history

The definition of recurrent, residual, and persistent disease varies across the JNA literature. Some authors define residual disease as radiographic evidence of disease within 6 months of surgery and recurrent disease as new radiographic evidence of disease more than 6 months after surgery.³⁵¹ Others contend that there is no true de novo recurrent disease in JNA and that "recurrence" is the interval growth of unintentional residual disease (i.e., tumor left behind after surgery).⁷⁹¹ Moreover, many surgeons will intentionally leave disease intraoperatively to

TABLE XVII. A. 2 Overview of staging systems.

Source	Stage I	Stage II	Stage III	Stage IV	Stage V
Snyderman/UPMC 2010 ⁷⁹⁰	Nasal cavity, medial PPF	≥1 sinus, lateral PPF; no residual vascularity	Skull base erosion, orbit, ITF; no residual vascularity	Skull base erosion, orbit, ITF; residual vascularity	Intracranial extension, residual vascularity; M, medial extension; L, lateral extension
Onerci 2006 ⁷⁸⁹	Nose, NP, ethmoid and sphenoid sinuses or minimal extension into PMF	Maxillary sinus, full occupation of PMF, extension to anterior cranial fossa, limited extension into ITF	Deep extension into cancellous bone at pterygoid base or body and GW sphenoid, significant lateral extension into ITF or pterygoid plates, orbit, cavernous sinus obliteration	Intracranial extension between pituitary gland and ICA, tumor localization lateral to ICA, middle fossa extension, and extensive intracranial extension	
Radkowski 1996 ⁷⁸⁸	IA: limited to nose or NP IB: as in stage Ia with extension into one sinus	II: minimal extension into medial PMF IIb: full occupation of PMF, displacing posterior wall of maxilla forward, orbit erosion IIc: ITF, cheek, posterior to pterygoid plates	IIIa: minimal intracranial extension IIIb: extensive intracranial extension ± cavernous sinus		
Andrews 1989 ⁷⁸⁷	Limited to NP; minimal bone destruction or limited to SPF	Invading PPF or maxillary, ethmoid or sphenoid sinus with bone destruction	Invading ITF or orbit: IIIa: no intracranial IIIb: extradural, parasellar	Intracranial, intradural: IVa: with IVb: without cavernous sinus, pituitary or optic chiasm infiltration	
Antonelli 1987 ⁷⁸⁶	Limited to NP or nasal fossa	Extending into sphenoid sinus or PMF	Extension to ≥1 of: maxillary sinus, ethmoid, orbit, ITF, cheek, and palate	Intracranial extension	

(Continues)

TABLE XVII.A.2 (Continued)

Source	Stage I	Stage II	Stage III	Stage IV	Stage V
Bremer 1986 ⁷⁸⁵	Ia: limited to posterior nares or NP Ib: extension to ≥ 1 sinus	Ia: minimal lateral extension through the sphenopalatine foramen in medial PPF Ib: full occupation of PPF displacing posterior wall of antrum forward, superior extension eroding orbital bone Ic: extension through PMF into cheek and ITF.	III: intracranial extension		
Chandler 1984 ⁷⁸⁴	Limited to NP	Extension into nasal cavity or sphenoid sinus	Tumor into antrum, ethmoid sinus, PMF, ITF, orbit \pm cheek	Intracranial extension	
Fisch 1983 ⁷⁸³	Limited to NP and nasal cavity without bone destruction	Invading the PMF and ≥ 1 sinus with bone destruction	Invading ITF, orbit, parasellar region remaining lateral to the cavernous sinus	Massive invasion of the cavernous sinus, the optic chiasmatal region, or pituitary fossa	
Sessions 1981 ⁷⁸²	Stage Ia: limited to nose and NP Stage Ib: extension into ≥ 1 sinus	Ia: minimal extension into PMF Ib: full occupation of PMF \pm orbit erosion Iic: ITF \pm cheek extension	Intracranial extension		

Abbreviations: GW, greater wing; NP, nasopharynx; PMF, pterygomaxillary fissure; SPF, sphenopalatine foramen; UPMC, University of Pittsburgh Medical Center.

TABLE XVII.A.3 Evidence surrounding staging systems of JNA.

Study	Year	LOE	Study design	Study groups	Clinical endpoints	Conclusion
Abdelwahab et al. ⁷⁷³	2019	4	Retrospective cohort	Patients with JNA treated with endoscopic surgery; validation of a new staging system incorporating nose/nasopharynx, sinus, fossae, cranium, orbit, and residual ICA vascularity (NSF-COR) (<i>n</i> = 54)	1. Blood transfusion volume 2. Recurrence 3. Resectability	NSF-COR staging system correlated with need for blood transfusion, recurrence rates, and resectability; correlated significantly with other staging systems
Snyderman et al. ⁷⁹⁰	2010	4	Retrospective case series	Patients undergoing endoscopic resection of JNA; all patients had ECA embolization preoperatively (<i>n</i> = 35)	1. Presence of ICA residual vascularity 2. Intraoperative blood loss	Residual vascularity correlated significantly with blood loss and residual/recurrent tumor

Abbreviations: ECA, external carotid artery; JNA, nasopharyngeal angiofibroma (formerly juvenile nasopharyngeal angiofibroma); ICA, internal carotid artery.

mitigate the risk to key neurovascular structures, creating the possibility of intentional residual disease.

GTR of JNA, regardless of approach or stage, has been reported to range from 72% to 100%.^{779,780} Studies have demonstrated that a considerable proportion of patients who have residual disease identified on follow-up imaging demonstrate stable disease or even disease regression on serial imaging, ranging from 67% to 83%.⁷⁹² When disease progression is identified on serial imaging, these studies demonstrated a growth rate ranging from 2.2 to 9.2 mm/year.^{791,793} In a study by Rowan et al., all patients with residual disease had a UPMC Staging Score of V_L (advanced disease with residual ICA contribution postembolization and lateral extension), and the most common site of residual disease was the infratemporal fossa.⁷⁹³

In a series of 131 patients, Liu et al. reported that following endoscopic or combined resection, the pterygoid process (76%), pterygopalatine foramen (71%), and pterygoid canal (83.3%) were the most common sites involved by recurrent tumor.⁷⁹⁴ Reyes et al. performed a meta-analysis of nine studies and 362 patients and found an overall recurrence rate of 24.5% with a mean duration of follow-up of 49.4 months.³⁵¹ In patients without intracranial spread, endoscopic approach to removal had statistically significantly lower rates of recurrence than patients who had surgery via an open approach.³⁵¹ Low-stage disease had significantly lower recurrence rates than patients with advanced disease (Radkowski Ia–Iib 18% vs. Radkowski IIc–IIIb 42%).³⁵¹ Pamuk et al. found a 20.8% rate of recur-

rence in a 48-patient cohort and a significant difference in recurrence rate between patients younger than 14 (34.7%) and patients older than 14 (8%) over a mean duration of follow-up of 23.3 months (range 6–120 months).⁷⁶⁸

Surgical approach, patient age, extent of tumor, management of the pterygoid canal, and residual vascularity can help guide surgeons in predicting risk of residual tumor and location of recurrent/persistent disease following surgery for JNA (Table XVII.A.4).

Aggregate grade of evidence: C (Level 2: 1 study; Level 4: six studies)

4 | Trigeminal function

Trigeminal dysfunction can be seen preoperatively (due to tumor involvement of CN V₂ or V₃ frequently manifested as reduced sensation) or postoperatively as a result of iatrogenic injury or sacrifice of the nerves during the approach or tumor resection. Previous work has demonstrated a 2% (12/699) rate of postoperative trigeminal dysfunction, most commonly involving the infraorbital nerve, in patients who underwent endoscopic resection of early-stage JNA.^{5,777} Sacrifice of the descending palatine nerve is rarely documented. This rate was concluded to be favorable when compared to open, craniofacial approaches, though no direct comparison of postoperative trigeminal dysfunction or cranial neuropathies has been performed.

TABLE XVII.A.4 Evidence surrounding patterns of recurrence of JNA.

Study	Year	LOE	Study design	Study groups	Clinical endpoints	Conclusion
Reyes et al. ³⁵¹	2019	2	Meta-analysis	Nine studies of patients with JNA treated with open versus endoscopic surgical approach (<i>n</i> = 362)	Recurrence rates	<ol style="list-style-type: none"> Endoscopic approach had significantly lower rates of recurrence than open approach for all tumor stages Advanced tumors had significantly higher recurrence rates than low-stage tumors
Szyfter et al. ⁷⁷⁹	2020	4	Retrospective case series	Patients who underwent either open or endoscopic resection of JNA (<i>n</i> = 71)	<ol style="list-style-type: none"> GTR Rates of residual or recurrent tumor Blood loss 	<ol style="list-style-type: none"> 72% of patients had GTR 28% had residual or recurrent tumor that required reoperation Low-stage tumors had 100–400 mL blood loss; advanced tumors had 500–2500 mL
Cohen-Cohen et al. ⁷⁸⁰	2020	4	Case-control	Patients who underwent surgical resection of JNA from 2005 to 2019 compared to 65 historical cases (<i>n</i> = 22)	<ol style="list-style-type: none"> Surgical approach GTR Intraoperative blood loss Recurrence 	<ol style="list-style-type: none"> 82% of cases were managed endoscopically in the modern cohort versus 8% in historical cohort Significantly less blood loss in modern cohort 9% recurrence rate versus 24% recurrence rate comparing modern to historical cohort
Schreiber et al. ⁷⁹¹	2018	4	Retrospective case series	Patients with JNA including six cases of patients with postsurgical persistent JNA (<i>n</i> = 74)	Natural history of persistent JNA	Three cases regressed, two cases stayed stable, one case increased at 2.2 mm/year
Liu et al. ⁷⁹⁴	2018	4	Retrospective case series	Patients with JNA treated with endoscopic resection (<i>n</i> = 131)	<ol style="list-style-type: none"> Presence of residual disease Location of residual disease 	<ol style="list-style-type: none"> 16.8% of patients had residual disease on follow-up imaging Most common sites of disease were pterygoid canal, base of pterygoid, and pterygopalatine foramen
Pamuk et al. ⁷⁶⁸	2018	4	Retrospective case series	Patients with JNA underwent endoscopic resection (<i>n</i> = 48)	<ol style="list-style-type: none"> Disease recurrence Intraoperative blood loss LOS 	<ol style="list-style-type: none"> Age <14 years at diagnosis had significantly higher recurrence rate than age >14 years (34.7% vs. 8%) Preoperative embolization did not significantly decrease intraoperative blood loss but did increase LOS
Rowan et al. ⁷⁹³	2018	4	Retrospective case series	Patients who underwent endoscopic or combined resection of JNA (<i>n</i> = 38)	<ol style="list-style-type: none"> Proportion of patients with residual disease Natural history of and management of residual disease 	12 of 38 patients had postoperative residual disease; eight demonstrate stable disease, four demonstrated progression ranging from 4.1 to 9.2 mm/year patients with residual disease had significantly higher UPMC Staging System scores than patients with GTR and no residual disease on interval imaging

Abbreviations: GTR, gross total resection; JNA, nasopharyngeal angiofibroma (formerly juvenile nasopharyngeal angiofibroma); LOS, length of stay; UPMC, University of Pittsburgh Medical Center.

5 | Techniques for hemostasis

Achieving hemostasis is a critical goal in the perioperative management of JNA. In the preoperative setting, embolization of external carotid artery branches has become a mainstay in the multimodal management of JNA.^{5,777} While branches of the ICA may be embolized, the risk of stroke and retinal artery embolization with subsequent blindness precludes safe ICA embolization.

Typically, angiography with embolization is performed 24–72 h prior to surgery. A variety of embolic agents are employed, frequently including polyvinyl alcohol, gelatin sponge, microcoils, and radiopaque liquid embolic agents (e.g., Onyx, ethylene vinyl alcohol copolymer).^{5,777,795–799} Numerous studies have shown that preoperative embolization is associated with reduction in intraoperative blood loss, though some studies suggest this benefit is limited to the advanced-stage cases.^{5,777,796,797,800} Choi et al. queried the Kids' Inpatient Database and reviewed 473 cases of patients with JNA. They found that preoperative embolization was associated with an additional cost of \$36,500 to patients; however, this additional cost trended down when examined over time.⁸⁰¹ While embolization is typically performed in a trans-arterial fashion, experience is emerging with embolization with direct tumoral puncture.⁸⁰²

Intraoperatively, many techniques and devices have been tested to assist with hemostasis including traditional electrocautery, lasers, and radiofrequency plasma ablation.^{5,777,803} However, there are no RCTs that directly compare methods for intraoperative hemostasis, and techniques are likely best chosen by the surgeon based on comfort, availability of resources, and specific clinical scenarios (Table XVII.A.5).

Techniques for hemostasis in JNA

Aggregate grade of evidence	C (Level 4: eight studies)
Benefit	Preoperative embolization reduces intraoperative bleeding and may reduce LOS, surgical duration, and need for perioperative blood transfusion.
Harm	Risk of inadvertent embolization of ICA-supplied structures via internal–external anastomosis, puncture site hematoma, and contrast exposure.
Cost	Possible additional cost of ~\$36,500 and need for prehospitalization for procedural planning.

(Continued)

Benefit–harm assessment	The procedural risks of embolization are significantly less than the perioperative benefit of reduced bleeding and improved visualization; the procedural cost may be offset by reduced LOS and need for blood products.
Value judgments	Choices for or against specific embolic agents or instruments for intraoperative hemostasis should be guided by surgeon/interventionalist experience and preference.
Policy level	Recommendation.
Intervention	For advanced tumors, and possibly for locally limited tumors, preoperative embolization of ECA feeder vessels reduces perioperative bleeding, may reduce LOS and need for transfusion, and should be considered.

6 | Role of nonsurgical therapy

RT has been used in the management of JNA, but its use is, in general, controversial given the benign nature of the disease and the young population affected by JNA. Early work investigated the use of RT as definitive treatment with local control rates ranging from 80% to 92%.^{804,805} More commonly, RT is used in the adjuvant setting to treat residual/persistent tumor in proximity to critical structures not amenable to surgical resection (e.g., cavernous sinus, ICA, orbital apex) or for management of large-volume intracranial disease.⁸⁰⁶

A variety of chemotherapeutics have been employed to try and treat JNA, including classic, cytotoxic agents (doxorubicin, Adriamycin, vincristine), hormonal agents (flutamide, given that JNA cells are prostate-specific antigen receptor positive), and immunomodulating therapies (e.g., anti-VEGF, steroids).^{807–811} There have been no significant advances since the last ICSB document.

B | Vascular malformations, hemangiomas, and paragangliomas

1 | Hemangioma

Hemangiomas are the most common vascular lesion of the head and neck; however, sinonasal hemangiomas are rare.⁸¹⁵ Hemangiomas are categorized into capillary and cavernous types, depending on the size of the involved vessels.⁸¹⁶ Historically, capillary hemangiomas were termed pyogenic granuloma, but it was recognized that this was a misnomer and lobular capillary hemangioma became the preferred descriptor as it most accurately describes the histopathologic characteristics of this

TABLE XVII.A.5 Evidence surrounding techniques for hemostasis in JNA, including embolization.

Study	Year	LOE	Study design	Study groups	Clinical endpoints	Conclusion
Giorgianni et al. ⁷⁹⁵	2021	4	Retrospective case series	Patients undergoing preoperative ECA superselective arterial embolization (<i>n</i> = 79)	1. Operative time 2. Blood loss 3. Complications	1. 217 min mean operative time, 784 mL mean blood loss, no complications 2. Preoperative arterial embolization is a safe procedure in the management of JNA
Abouzeid et al. ⁸⁰⁰	2021	4	Retrospective case series	Patients undergoing preoperative embolization prior to surgical resection of JNA (<i>n</i> = 20)	1. Operative time 2. Blood loss 3. Complications	Mean operative time 2.5 h, mean 225 mL blood loss, and no complications
Vakharia et al. ⁷⁹⁹	2021	4	Retrospective case series	Patients embolized with Onyx (<i>n</i> = 5)	1. Degree of devascularization 2. Complications	There was an average of 86% devascularization postembolization; no complications
Choi et al. ⁸⁰¹	2020	4	Retrospective cohort	Patients—comparison of patients who underwent preoperative embolization to patients who did not (<i>n</i> = 473)	1. LOS 2. Perioperative blood transfusion 3. Cost	Preoperative embolization reduced LOS (decrease by 1 day), decreased odds of requiring perioperative transfusion, increased cost of \$36,500
Jaiswal et al. ⁸⁰³	2020	4	Case-control	Prospectively recruited patients underwent endoscopic resection assisted by plasma ablation compared to 18 historical controls (<i>n</i> = 18)	1. Intraoperative blood loss 2. Duration of surgery	Significantly lower intraoperative blood loss (648 mL) and duration of surgery (84 min) in patients with plasma-assisted surgery after embolization and with low-stage tumors
Pei et al. ⁷⁹⁶	2018	4	Case-control	Patients with JNA—10 with no preoperative embolization; 17 with preoperative gelatin sponge embolization (<i>n</i> = 27)	1. Intraoperative blood loss 2. surgical time	Patients with preoperative embolization had significantly less bleeding (385 vs. 1215 mL) and shorter surgical time (205 vs. 264 min) than patients without preoperative embolization
Tan et al. ⁷⁹⁷	2017	4	Retrospective case series	Patients with JNA; 32 with surgery + preoperative embolization versus 42 with surgery alone (<i>n</i> = 74)	1. Intraoperative bleeding 2. surgery time 3. hospital stay duration	Preoperative embolization significantly decreased bleeding in Radkowski Stage II and III tumors with no difference in surgical time or duration of stay
Gao et al. ⁷⁹⁸	2013	4	Retrospective case series	Patients embolized with particulate agents; 11 patients with liquid agent (Onyx) (<i>n</i> = 39)	1. Intraoperative blood loss 2. Perioperative transfusion	Patients embolized with Onyx had significantly lower intraoperative blood loss (569 vs. 1348 mL) and required significantly lower number of transfusions (0.45 vs. 1.56 U PRBCs)

Abbreviations: JNA, nasopharyngeal angiofibroma (formerly juvenile nasopharyngeal angiofibroma); LOS, length of stay; PRBC, packed red blood cells.

lesion. Local trauma and hormonal influences have been proposed as possible etiologies.^{817–819} Most commonly occurring around the fifth decade of life, about 80% arise from the anterior nasal septum (Little's area), 15% from the lateral nasal wall, and 5% from elsewhere within the sinonasal cavity.^{817–820}

The most common presentation is epistaxis; however, the patient may also experience nasal obstruction, facial pain and/or pressure, and rhinorrhea as the lesion grows.^{815,817–819,821} As exam findings may be difficult to discern from other lesions, frozen section at the time of planned resection is commonly recommended in lieu of in-office biopsy. Imaging can help determine the size of the lesion as well as possible involvement of adjacent structures.⁸²¹ CT may also delineate any bone destruction and show evidence of calcified thrombus (phleboliths). On MRI, hemangiomas tend to vividly enhance with gadolinium on T1-weighted images and demonstrate flow-voids on T2-weighted images, suggesting vascularity.⁸²¹

The treatment for sinonasal hemangiomas is complete surgical excision. Recent technological advances in endoscopic endonasal treatment have demonstrated favorable outcomes and less morbidity with this approach, as compared to open techniques.^{815,816,819,822,823} To facilitate resection, some surgeons advocate for preoperative embolization for larger tumors, but this is not always necessary.^{818,819}

Other interventions, including laser and medical treatment including bevacizumab and intralesional steroids, have been reported with success.^{817,824,825} Overall, these treatments are considered nonstandard, and studies are limited to case reports and small series.

The current evidence indicates that surgical excision is safe and effective, with low recurrence rates. A study of 37 patients showed no major complications, but two patients had recurrence at 4 and 60 months.⁸¹⁵ In a similar study of 14 patients, there were no major complications or recurrence at 59.9 ± 44.7 months.⁸¹⁶ Lastly, Smith et al. reported a series of 34 patients with a mean follow-up time of 58.6 months and found 13 patients recurred, the majority of which (7/13) underwent incisional biopsy only.⁸²⁰ Collectively, these data indicate seemingly low recurrence rates, though complete extirpation may increase the likelihood of long-term control. Additional study is needed to better understand the risks of recurrence and the associated factors. Table XVII.B.1 summarizes evidence surrounding hemangioma.

2 | Arteriovenous malformations

Arteriovenous malformations (AVMs) are vascular malformations that can occur in the head and neck region.

Most of these lesions involve the skin and are in the mid-face region with infrequent involvement of the nasal cavity or sinuses.^{826–828} These lesions do not typically involute and approximately 35% will involve bone.⁸²⁹ These lesions can result in massive bleeding after what would otherwise be minor or innocuous trauma (e.g., tooth extraction).⁸³⁰ AVMs can be congenital or acquired, and when acquired they can be associated with surgery or blunt trauma. Several molecular pathways have been associated with AVMs and include alterations within *PIK3CA* and *RAS* signaling pathways, as well as mutations in the *MAP2KI* gene.⁸³¹ Ultimately, these alterations result in changes within vascular growth factor-directed angiogenesis causing aberrant arteriovenous channels that communicate with each other.

The presentation of AVMs can vary based on the anatomic site, size, and propensity for trauma or manipulation to the area. The lesions are typically slow growing and can be associated with spontaneous bleeding (e.g., epistaxis). Patients may report nasal obstruction, pulsating sensations, and pain. Smaller lesions located within a paranasal sinus could be asymptomatic and incidentally identified on radiographic imaging for other purposes.

Diagnosing AVMs includes a comprehensive history and physical examination. On examination, a raised, red, and often-pulsating lesion can be identified on anterior rhinoscopy or nasal endoscopy. Evidence of current or recent bleeding may be noted, and some authors have advocated consideration of needle aspiration to differentiate vascular lesions from those that are inflammatory in nature.⁸³² However, most authors report utilization of radiographic imaging including CT and MR as the initial complementary imaging modalities of choice.⁸³³ Common findings on CT include a multilobulated lesion with bone changes, and subsequent contrasted imaging on MRI reveals avid enhancement and a heterogenous-appearing soft tissue mass. Subsequent magnetic resonance angiography (MRA) or computed tomographic angiography (CTA) is then indicated, with MRA considered the most informative.

Published data regarding optimal treatment strategies for AVMs are limited to retrospective case reports only, and therefore clinical decisions are mostly informed by experience with other vascular anomalies.^{826–834} A combination of intra-arterial angiography with embolization followed by complete surgical excision is the strategy most commonly reported. Embolization alone and embolization followed by curettage have been associated with higher risks of recurrence in several case reports, and most argue for embolization and complete surgical resection when feasible. Published reports describe a variety of surgical approaches including craniofacial, transfacial, transcranial, and endoscopic endonasal depending on disease extent and location. Most recent reports advocate

TABLE XVII. B. 1 Evidence surrounding sinonasal hemangioma.

Study	Year	LOE	Study design	Study groups	Clinical endpoint	Conclusions
Lim et al. ⁸¹⁶	2021	4	Retrospective case series	Patients with sinonasal hemangiomas (eight LCH and six CH) who underwent endoscopic resection (<i>n</i> = 14)	1. Safety of transnasal endoscopic resection 2. Recurrence	1. No difference in clinical features between LCH and CH 2. Endoscopic resection of sinonasal hemangioma is safe and effective 3. One CH patient recurred
Kim and Kwon ⁸¹⁵	2017	4	Retrospective case series	Patients with sinonasal hemangiomas (24 LCH and 13 CH) who underwent endoscopic resection (<i>n</i> = 37)	1. Safety of transnasal endoscopic resection 2. Recurrence	1. LCHs tended to present at IT and septum compared to CHs 2. Endoscopic resection of sinonasal hemangioma is safe and effective 3. Two patients recurred, one at 4 months and other at 60 months
Takaishi et al. ⁸¹⁹	2017	4	Retrospective case series	Patients with sinonasal hemangiomas (22 LCH, nine CH) who underwent endoscopic resection (<i>n</i> = 31)	1. Safety of transnasal endoscopic resection 2. Recurrence	1. Lesions tended to occur at IT and septum 2. Endoscopic resection of sinonasal hemangioma is safe and effective 3. One CH patient recurred.
Smith et al. ⁸²⁰	2012	4	Retrospective case series	Patients with sinonasal hemangiomas (all LCHs) who underwent biopsy or resection (unknown approach) (<i>n</i> = 34)	1. Histologic characterization of LCH 2. Recurrence	1. Wide range of histologic morphology observed 2. 13 patients (42.0%) recurred Mean time to recurrence 5.7 months
Song et al. ⁸²³	2009	4	Retrospective case series	Patients with sinonasal hemangiomas (12 LCH, nine CH, one mixed) who underwent endoscopic resection (<i>n</i> = 22)	1. Safety of transnasal endoscopic resection 2. Recurrence	1. Endoscopic resection of sinonasal hemangioma is safe and effective 2. No patients recurred
Puxeddu et al. ⁸¹⁸	2006	4	Retrospective case series	Patients with sinonasal hemangiomas (all LCHs) who underwent endoscopic resection (local or general) (<i>n</i> = 40)	1. Location of lesions 2. Safety of transnasal endoscopic resection 3. Recurrence	1. Lesions tended to occur at vestibule and septum 2. Large lesions had a predilection for the LNW and the IT 3. Endoscopic resection of sinonasal hemangioma is safe and effective 4. No patients recurred
Iwata et al. ⁸¹⁷	2002	4	Retrospective case series	Patients with sinonasal hemangiomas (five LCH, three CH) who underwent endoscopic resection (<i>n</i> = 8)	1. Diagnostic utility of CT/MR imaging for hemangiomas 2. Safety of transnasal endoscopic resection	1. CT and MR imaging were useful in identifying the extension of the tumor and for surgical planning 2. Endoscopic resection of sinonasal hemangioma is safe and effective

(Continues)

TABLE XVII.B.1 (Continued)

Study	Year	LOE	Study design	Study groups	Clinical endpoint	Conclusions
Denk et al. ⁸⁷⁶	2002	4	Retrospective case series	Patients with nasal hemangiomas who underwent open surgical resection (<i>n</i> = 11)	1. Efficacy of midline open surgical approach 2. Age of hemangioma and feasibility of surgery	1. The midline approach provides excellent visualization and an aesthetically acceptable scar 2. Early surgical intervention (usually between 2 and 2.5 years of age) is reasonable
Dillon et al. ⁸²¹	1991	4	Retrospective case series	Patients with sinonasal hemangiomas (all LCHs) who underwent diagnostic imaging and resection (unknown type) (<i>n</i> = 8)	Diagnostic utility of CT/MR imaging for hemangiomas	1. Imaging demonstrates well-circumscribed and intensively enhancing lesions 2. CT showed bony remodeling MR was helpful to distinguish lesions from surrounding mucus secretions

Abbreviations: CH, cavernous hemangioma; CT, computed tomography; LCH, lobular capillary hemangioma; IT, inferior turbinate; LNW, lateral nasal wall.

for consideration of EEAs, but at present individualized care with consideration of the patient, disease, as well as the surgeon's experience and familiarity with endoscopic and endovascular procedures needs to be considered. Although well described for intracranial AVM, Gamma Knife radiosurgery has not been reported for those within the sinuses and extracranial skull base. Risk of recurrence for sinonasal AVM is not known, but data from soft tissue AVM within the head and neck regions suggest recurrence rates could be as high as 80%.⁸²⁶

3 | Venous malformations

Venous malformations (VMs) are developmental errors in venous morphogenesis that arise in utero, but may not become clinically evident until later in life.⁸³⁵ They result from somatic mutations in *PIK3CA* or *TEK/TIE2*.^{836–838} The incidence is estimated to be 1:10,000.⁸³⁹ VMs are slow-flow malformations that tend to grow with the patient and may expand abruptly with trauma or hormonal changes.⁸³⁵ Clinically these manifest with blue skin discoloration or as a soft subcutaneous mass that is compressible and enlarges with increased venous pressure.⁸⁴⁰ The slow flow within the malformation can result in thrombosis, phleboliths, and sometimes localized intravascular coagulopathy (LIC), which can decompensate into disseminated intravascular coagulopathy (DIC).⁸⁴¹ Depending on their extent, these can be focal, multifocal, or diffuse.⁸⁴² Approximately 40% of VMs occur in the head and neck and are commonly associated with muscles or involve the mucosal lining.⁸⁴³ Histologically, they are composed of aberrant thin-walled veins that exhibit progressive ectasia over

time.⁸⁴⁴ The endothelial cells are flattened and mitotically quiescent, surrounded by scant and often disorganized smooth muscle cells.⁸⁴⁵

VMs of the nasal cavity are very rare. Interpretation of the literature is additionally challenging due to longstanding confusion around the proper nomenclature of vascular anomalies. The International Society for the Study of Vascular Malformations classification system has become the standard in the field but is not universally used.⁸⁴⁰ Published literature on nasal VM is restricted to case reports. Only three cases of VM involving the sinuses or nasopharynx have been reported.^{843,846,847} Diagnostic imaging can include contrast-enhanced CT and MRI, as well as consideration of angiography. Reported treatments include medical therapies (targeted therapies and/or anticoagulation), laser, sclerotherapy, surgery, or a combination of these modalities.^{845,848} In one case, hormonal therapy (progesterone) was felt to be contributing to VM development and was therefore discontinued.⁸⁴⁶

4 | Paragangliomas

Paragangliomas of the sinonasal cavity occur at an incidence of 1 in 100,000, representing only 0.6% of all tumors within the head and neck.⁸⁴⁹ It is classified as a neuroendocrine tumor, though it is included in this section given its well-described vascularity and strategies needed for mitigating blood loss during resection. The average age of presentation is 45 years with most lesions occurring in women, typically in the fifth to seventh decades.^{849–851} In a systematic review by Nguyen et al. of 45 studies incorporating 54 patients with sinonasal paraganglioma and a

mean follow-up time of 28 months, the nasal cavity was the primary tumor location in 66.7% of cases, with two thirds arising from the middle turbinate.⁸⁵² Other sites of nasal origin include the superior and inferior turbinates, the lateral nasal wall, and the nasal septum.^{853–855} Tumors arising from the paranasal sinuses were most commonly situated in the ethmoid cavity. The most common presenting symptoms included recurrent epistaxis (68.5%), nasal obstruction (53.7%), and headache (13.0%).

Macroscopically, tumors are often firm and encapsulated. Histologically, paragangliomas need to be differentiated from other neuroendocrine neoplasms. Paragangliomas are positive for chromogranin, synaptophysin, and neuron-specific enolase, but negative for cytokeratin. The associated sustentacular cells will stain for S100. Tumors classically consist of individual tumor cells with round nuclei (chief cells) arranged in nests—the characteristic “zellballen” architecture—surrounded by sustentacular cells and divided by vascular stroma.^{856–859} Up to 50% of head and neck paragangliomas are associated with a genetic syndrome, most commonly mutations in the genes for succinate dehydrogenase subunits. In particular, *SDHB* mutations are associated with extra-adrenal tumors and have an increased risk of malignant and recurrent lesions.^{851,856}

In one systematic review, of the studies reporting tumor pathology, 71.4% were designated as benign lesions and 28.6% diagnosed as malignant paraganglioma.⁸⁵² The distinction between benign and malignant entities is controversial. Consequently, diagnosis of malignant paraganglioma is often made on clinical evidence of aggressive behavior including regional spread to lymph nodes or distant metastasis to nonneuroendocrine tissue.^{852,860–865}

Functional paragangliomas have been estimated to represent 1%–3% of all cases in the head and neck, though a recent systematic review of sinonasal lesions noted an incidence of 7.4% with tumors secreting adrenocorticotrophic hormone (ACTH) or catecholamines.^{849,851,852,866–869} Evaluation for biochemical abnormalities is indicated in paragangliomas, particularly in symptomatic patients, and is critically important in cases of catecholamine-secreting tumors where surgical intervention without appropriate adrenergic blockade may be catastrophic.^{851,866}

CT imaging, though less specific than MRI, is useful for surgical planning and for evaluating bone involvement.⁸⁵² On MRI, paragangliomas demonstrate high signal on T2 sequences and low signal on T1-weighted imaging, with the classic “salt and pepper” appearance resulting from hyperintense foci interspersed with areas of signal void related to high-flow vascular channels.⁸⁶⁹ Tumors enhance with contrast on both CT and MRI. Nuclear imaging such as metaiodobenzylguanidine (¹²³I]MIBG) or indium [¹¹¹In]DTPA-octreotide SPECT scintigraphy—

particularly in cases with a genetic predisposition—can help determine the extent of the tumor and detect synchronous lesions.^{870,871} PET/CT imaging is a more efficient and sensitive means of imaging paragangliomas compared to scintigraphy.⁸⁶⁹ In particular, ¹⁸F-FDG or [68Ga-DOTA]-TATE PET imaging is used to assess locoregional extension, multifocality, and metastases, while the latter is particularly useful in detecting functional tumors producing ACTH.^{849,851,867,871,872}

Surgery is the first-line treatment for sinonasal paragangliomas. The optimal approach—open, endoscopic, or combined—should be made with the goal of achieving complete resection through optimal exposure while limiting morbidity. More recent case reports have demonstrated a trend toward endoscopic approaches for resection of these lesions, though open approaches are also effective. Indeed, in a systematic review of published cases, an open approach was employed in 63% of cases, an endoscopic approach in 33.3%, and a combined approach in 3.7%.⁸⁵² Preoperative angiography and embolization should be strongly considered given the rich vascularity of paragangliomas.^{851,873} The use of advanced technology, such as radiofrequency coblation, can facilitate hemostasis during dissection.⁸⁷⁴ While chemotherapy is largely ineffective, RT has been used to successfully halt the growth of disease, particularly in patients with unresectable disease or who cannot tolerate surgery.^{851,872,875} Estimation of long-term prognosis is dependent on systematic reviews incorporating case series indicating that most (63%) of patients were disease free at a mean follow-up of 24.6 months. Recurrence rate was 21.7% between 12 and 156 months after initial resection. Metastasis was reported in 8.7% of cases.⁸⁵² Table XVII.B.2 summarizes evidence surrounding paraganglioma.

Aggregate grade of evidence: C (Level 2: one study; Level 3: 10 studies)

XVIII | CONGENITAL MIDLINE NASAL MASSES

A | Introduction

CMNMs are relatively rare midline nasal lesions, and are estimated to occur in about 1:20,000–1:40,000 births.⁸⁷⁷ They arise from failure of embryological separation of neuroectodermal and ectodermal tissue, which can lead to intranasal and extranasal masses.^{878–880} Even though most are diagnosed at birth or childhood, rarely they may not be recognized until adulthood and require a high level of suspicion.⁸⁸¹ The most common CMNMs are nasal dermoid cysts, nasal gliomas, and meningoceles/encephaloceles.⁸⁸² These lesions may

TABLE XVII. B. 2 Evidence surrounding sinonasal paraganglioma.

Study	Year	LOE	Study design	Study groups	Clinical endpoint	Conclusion
Nguyen et al. ⁸⁵²	2019	2	Systematic review	45 studies including patients with sinonasal paraganglioma (<i>n</i> = 54)	<ol style="list-style-type: none"> 1. Recurrence 2. Metastasis 3. OS 	Optimal management includes total resection with clear margins and long-term follow-up
Papaspyrou et al. ⁸⁶²	2013	4	Retrospective case series	Patients with benign or malignant sinonasal paraganglioma (<i>n</i> = 6)	<ol style="list-style-type: none"> 1. Locoregional spread 2. Metastasis 	<ol style="list-style-type: none"> 1. Lesions can be malignant with rapid local and distant spread despite resection 2. Malignancy diagnosed on clinical behavior

Abbreviation: OS, overall survival.

involve the nasal dorsum, have a fistulous tract, or extend into the intracranial space. Therefore, prompt diagnosis and appropriate workup of CMNMs are critical to ensure complete resection and to avoid intracranial complications.⁸⁷⁷

B | Dermoid and epidermoid cysts

Nasal dermoid and epidermoid cysts are the most common congenital midline nasal masses and account for up to 61% of all CMNM cases.⁴⁰ Embryologically, they arise from a retained connection between the dural diverticulum and ectodermal tissue.⁸⁷⁹ Clinically, patients may present with a cyst, sinus, fistula, or a firm, nonpulsatile mass located between the columella and glabella.⁸⁸³ These lesions do not transilluminate and are negative for the Furstenberg test (pressure on the ipsilateral jugular vein to elicit swelling or pulsation of the lesion). Compared to epidermoids, which consist of ectoderm/skin elements only, nasal dermoids are composed of ectodermal and mesodermal tissue and may contain hair follicles and sweat glands. Most are detected early in life, with a mean age at the time of diagnosis of 2–3 years, but a number of cases in young adults have been reported in the literature.⁸⁸¹ There appears to be a male predominance across the literature and a likely familial inheritance in some cases.^{883,884} Most recent large retrospective studies show that approximately 25%–35% of patients demonstrate evidence of intracranial extension.^{883,885} Therefore, both MRI and CT imaging are usually obtained as part of the workup, although some authors favor the use of MRI as sole and primary imaging tool.⁸⁷⁷ Given the potential of intracranial extension and delayed diagnosis due to subtle physical exam findings, up to 36% of patients may present with significant complications (meningitis, osteomyelitis, cellulitis/abscess), highlighting the need for timely surgical excision.⁸⁸⁵

C | Nasal glial heterotopia

Nasal glial heterotopias, formerly termed gliomas, are the least common CMNMs, with only a few hundred cumulative cases reported in the literature.^{879,886–888} Development of these lesions is similar to that of nasal dermoids.⁸⁸⁰ They arise from ectopic rests of neural glial tissue sequestered in the nasal soft tissue following obliteration of their embryologic connection to the subarachnoid space.⁸⁸⁸ Nasal gliomas may present as noncompressible masses that may appear red or with a bluish hue. Nearly 10%–30% of these lesions may have a persistent dural connection traversing the foramen cecum.⁸⁸⁸ However, unlike meningoencephaloceles, they do not have subarachnoid communications and are not filled with CSF. On CT imaging, gliomas appear isodense to brain parenchyma. However, MRI is the preferred modality of evaluation, and these lesions are typically T1 hypointense and nonenhancing.⁸⁷⁹

D | Meningoencephaloceles

Nasal midline congenital meningoencephaloceles are extensions of the brain parenchyma (encephaloceles) or meninges (meningoceles) through a skull base defect caused by abnormal persistent patency of fonticulus frontalis and foramen cecum.⁸⁷⁹ This allows for communication with the subarachnoid space; therefore, meningoencephaloceles may be filled with CSF and present with CSF rhinorrhea. Their incidence is estimated to be around 1 in 35,000 births.^{889,890} They typically present at birth as bluish, compressible masses along the nasal dorsum/glabella, which may also enlarge with Valsalva or crying (positive Furstenberg's sign).⁸⁸⁰ Appropriate workup, including MRI, is very important in assessing the degree of intracranial involvement and other associated intracranial pathologies, most commonly hydrocephalus

TABLE XVIII.1 Evidence surrounding imaging workup of congenital midline nasal masses (CMNMs).

Study	Year	LOE	Study design	Study groups	Clinical endpoints	Conclusions
Vaghela and Bradley ⁸⁸¹	2004	2	Systematic review	Adults (>16 years of age) presenting with nasal dermoids across 30 studies (<i>n</i> = 44)	Rate of intracranial extension of CMNMs presenting in adulthood	<ol style="list-style-type: none"> 1. Similar presentation in adults 2. Rate of intracranial extension of 27.5% in adult cases
Winterton et al. ⁸⁹⁶	2010	4	Retrospective case series	Patients with nasal dermoid sinus cysts with 4-year follow-up (<i>n</i> = 19)	<ol style="list-style-type: none"> 1. Utility of imaging at predicting intracranial extension 2. Deep and superficial recurrence rates at 4 years 	<ol style="list-style-type: none"> 1. Positive and negative predictive values for intracranial extension were 85.7% and 50% for CT and 100% and 50% for MRI, respectively 2. No deep recurrences and 26% superficial nasal recurrence rate at 4 years
Huisman et al. ⁸⁷⁷	2004	4	Retrospective case series	Children with CMNMs (nine dermoids, one meningocele, one glioma) (<i>n</i> = 11)	<ol style="list-style-type: none"> 1. Imaging characteristics 2. Sensitivity and CT and MRI modalities 	<ol style="list-style-type: none"> 1. MRI did not show any false-negative results, favoring the use of MRI as primary imaging tool 2. Intracranial extension is equally well detected by CT and MRI using indirect imaging signs
Barkovich et al. ⁸⁹³	1991	4	Case-control	Children with CMNMs (eight encephaloceles, seven dermoids, one glioma) and 45 matched normal patients as controls (<i>n</i> = 61)	<ol style="list-style-type: none"> 1. Imaging characteristics 2. Sensitivity and CT and MRI modalities 	<ol style="list-style-type: none"> 1. CT and MRI appear to be equally sensitive and excellent at detection of CMNMs 2. MRI appears superior in delineating extent and intracranial involvement identifying other concomitant anomalies, especially for encephaloceles

Abbreviations: CMNMs, congenital midline nasal masses; CT, computed tomography; MRI, magnetic resonance imaging.

(20%).⁸⁹¹ MRI reveals a soft tissue mass, usually isointense to brain and with contiguous connection with the subarachnoid space.⁸⁹² CT may also help in identifying the osseous defects associated with encephaloceles and surgical planning.⁸⁹³ Early surgical intervention appears to be associated with improved prognosis.⁸⁹¹

E | Role of imaging

Imaging is essential in the workup of congenital midline nasal masses to both accurately diagnose the lesion and identify potential intracranial involvement, which may occur in up to 30%–40% of cases (Table XVIII.1).^{894,895} Both MRI and CT imaging are usually obtained, and both modalities appear to be equally sensitive and excellent at

detection of CMNMs.⁸⁹³ Findings suggestive of intracranial extension on CT may include a widened/bifid nasal septum or crista galli, as well as bony defects in the cribriform or ethmoid skull base. However, MRI appears to be superior in delineating soft tissue extent and intracranial involvement, as well as other concomitant anomalies.⁸⁹³ In addition, due to its multiplanar capabilities, different image sequences, and lack of radiation exposure, many authors favor using MRI as primary imaging modality in children.^{877,880,891–893} Of note, neither technique is able to completely visualize the sinus tract itself, which can be seen in dermoids and gliomas, especially if they are small. For nasal dermoids, the PPV and NPV for intracranial extension appear to be 86% and 50% for CT and were 100% and 50% for MRI, requiring a high index of intraoperative suspicion to ensure complete excision of the tract.⁸⁹⁶

F | Management

Treatment of CMNMs involves complete surgical excision, which allows for formal histologic diagnosis and prevents future complications and recurrence. Early surgical excision is important to prevent potential complications such as local infection, craniofacial deformity, and intracranial complications and has also been associated with improved patient outcomes (Table XVIII.2).^{883,891} Complete removal is imperative—incision and drainage, aspiration, or STR without complete removal results in historical recurrence rates ranging from 50% to 100%.^{881,897}

Multiple surgical approaches have been developed for extirpation of these lesions, including local excision, rhinoplasty techniques, endoscopic endonasal, open craniofacial, and combined approaches. Ultimately, excision must be tailored to a patient's unique combination of pathology, location and size of the lesion, and individual patient characteristics.⁸⁹⁸ In cases where there is concern for intracranial extension, a combined approach with neurosurgery is frequently necessary. For nasal dermoids, combined intracranial–extracranial excision is utilized in approximately 20% of cases.⁸⁸³ Similarly, when there is extension of the sinus tract deep to the nasal bones, nasal bone osteotomies may be required to obtain appropriate access. The use of frozen pathology to rule out intracranial extension in dermoids has not been well studied, but some authors have reported success in using frozen sections of the superior margin of the specimen to ensure that there is no intracranial extension.^{878,883,898,899} If complete resection is able to be achieved, the overall 7-year recurrence rates appear to be very low (12%).⁸⁸³

Anterior skull base encephaloceles in children have been historically repaired through open approaches due to narrow anatomy that may prevent endoscopic repair in very young children and concern for STR.⁸⁹¹ Continued advances in endoscopic techniques have made minimally invasive extracranial approaches possible and are known to be associated with decreased patient morbidity.⁹⁰⁰ Endoscopic techniques have already essentially become the standard of care for repair of encephaloceles in adults, with reported 90% successful closure rate.^{901,902} Endoscopic approaches appear to be associated with decreased mortality, LOS, and duration of follow-up compared to open approaches.⁹⁰³ A number of studies in the pediatric population suggest that endoscopic resection and repair are feasible for some masses and appear to have a more favorable complication profile than open approaches, even in children as young as 8 months old.^{904–906} Multiple endonasal endoscopic approaches have been described, all tailored to the pathology, location, and size of the lesion, but in general, a technique that grants adequate exposure of the skull base and minimizes trauma to surrounding

tissues is favored.⁹⁰⁰ The entire defect must be circumferentially identified and accessible for instrumentation and ablation, which for midline congenital nasal masses often includes exposure of the anterior ethmoid skull base and the cribriform adjacent to the foramen cecum.⁹⁰⁷ Skull base repair for endonasal approaches is often done concurrently to diminish the risk of intracranial complications and postoperative CSF leaks and usually necessitates a multilayered closure.^{900,908} Details of repair are surgeon specific, but may involve a combination of inlay (intracranial, extradural) or onlay (extracranial) grafts that can be made from autologous or synthetic materials.⁹⁰⁷ Larger defects, especially with an intraoperative CSF leak, are usually managed with a combination of “gasket-seal” repair to achieve watertight closure of the anterior cranial base and vascular pedicle flaps, such as the nasoseptal mucosal flap.^{244,908}

In conclusion, congenital midline nasal masses arise from embryologic errors of development of the nasofrontal region and require a thorough, prompt workup and a high index of suspicion. Neuroimaging is essential in the evaluation to characterize the lesion and identify the presence and extent of intracranial involvement and should include a CT and an MRI. Timely and complete surgical resection with approaches tailored to the patient and tumor characteristics is recommended to prevent postoperative complications and recurrence. Resection should be done through an endonasal endoscopic approach whenever possible and appropriate.

Aggregate grade of evidence: C (Level 2: two studies; Level 4: nine studies)

XIX | BENIGN ORBITAL TUMORS AND LESIONS

A | Benign orbital lesions—intraconal

Traditionally, orbital lesions have been surgically addressed by ophthalmologists and neurosurgeons via open approaches such as frontotemporal craniotomies with orbitozygomatic osteotomy, transcutaneous or transconjunctival orbitotomy, and lateral orbitotomy.⁹⁰⁹ Seeking to improve tumor resection efficacy and reduce morbidity, endoscopic approaches for orbital lesions evolved during the last decade as a natural evolution of endoscopic sinonasal and skull base surgery.⁹¹⁰

Since the ICSB 2019 document (Section VI.B), several studies have been published describing surgical techniques, reporting outcomes, and adding to the nascent field of endoscopic resection of benign orbital tumors.⁵ Two new classification systems were developed to improve

TABLE XVIII.2 Evidence surrounding surgical management of congenital midline nasal masses (CMNMs).

Study	Year	LOE	Study design	Study groups	Clinical endpoints	Conclusions
Thompson et al. ⁹⁰³	2020	2	Systematic review	Patients with anterior encephaloceles (222 and 127 patients undergoing open and endoscopic resection, respectively) over last 50 years across 153 studies (<i>n</i> = 349)	Outcomes of open versus endoscopic repair of congenital anterior encephaloceles	<ol style="list-style-type: none"> 1. Endoscopic procedures had a lower number of complications per operation compared with open procedures 2. Decreased mortality, length of stay, and duration of follow-up with endoscopic resection compared to open approaches
Thompson et al. ⁹⁰⁴	2020	4	Retrospective case series	Children with congenital encephaloceles treated using endoscopic techniques (<i>n</i> = 15)	Feasibility of endoscopic repair of congenital encephaloceles out outcomes	Successful and safe repair of encephaloceles in children using endoscopic techniques
Keshri et al. ⁹⁰⁷	2016	4	Retrospective case series	Consecutive patients below 12 years of age with intranasal meningoencephalocele treated by endonasal endoscopic approach between 2013 and 2014 (<i>n</i> = 6)	Feasibility of endoscopic repair in pediatric patients, length of hospital stays, and cost	<ol style="list-style-type: none"> 1. Endoscopic repair in pediatric patients decreases hospital stay and cost of treatment 2. Successful use of gasket-seal technique in skull base repair for CMNM postresection defects
Woodworth et al. ⁹⁰⁰	2004	4	Retrospective case series	Children (mean age 6 years old) with encephaloceles and CSF leaks between 1992 and 2003 (<i>n</i> = 8)	Feasibility and outcomes of endoscopic encephalocele repair compared to traditional craniotomy approaches	Endoscopic repair is a successful alternative to traditional craniotomy approaches, with less morbidity
Rahbar et al. ⁸⁸³	2003	4	Retrospective case series	Children with nasal dermoids, single institution, 30-year cohort (<i>n</i> = 42)	<ol style="list-style-type: none"> 1. Presentation of nasal dermoids 2. Surgical management 3. 7-year recurrence rate 	<ol style="list-style-type: none"> 1. Majority (81%) underwent extracranial resection, 19% underwent combined intracranial–extracranial excision 2. Overall, 7-year recurrence rate was low (12%)
Turgut et al. ⁸⁹¹	1995	4	Retrospective case series	Patients with congenital nasal encephaloceles repaired with frontal craniotomy approach, 20-year cohort at a single institution (<i>n</i> = 35)	Assess frequently of other intracranial anomalies and timing of surgical intervention	<ol style="list-style-type: none"> 1. Early surgical intervention associated with improved prognosis 2. High rate of other intracranial pathologies, most common being hydrocephalus (20%)

(Continues)

TABLE XVIII.2 (Continued)

Study	Year	LOE	Study design	Study groups	Clinical endpoints	Conclusions
Wardinsky et al. ⁸⁸⁵	1991	4	Retrospective case series	Patients with nasal dermoids, 10-year cohort at a single institution (<i>n</i> = 22)	Assess frequently of intracranial extension and preoperative complications	1. 45% with intracranial extension 2. 36% of patients with preoperative complications (two with meningitis, two osteomyelitis, seven cellulitis/abscess)

Abbreviation: CMNMs, congenital midline nasal masses.

TABLE XIX.A.1 Overview of CHEER staging and ORBIT classification systems.

Stage/Class	CHEER Anatomic Description	ORBIT Anatomic Description
I	Extraconal OCH	Extraconal
II	Intraconal OCH anterior to the inferomedial muscular trunk of the ophthalmic artery and inferior to the horizontal axis of the medial rectus	Intraconal and anterior to the intersection of the ophthalmic artery and optic nerve
III	Intraconal OCH anterior to the inferomedial muscular trunk of the ophthalmic artery and superior to the horizontal axis of the medial rectus	Intraconal and posterior to the intersection of the ophthalmic artery and optic nerve
IV	IVA: Intraconal OCH posterior to the inferomedial muscular trunk of the ophthalmic artery without extension into the optic canal IVB: Intraconal OCH posterior to the inferomedial muscular trunk of the ophthalmic artery with extension into the optic canal or an isolated OCH within the optic canal	Extraconal or intraconal with extension into the pterygopalatine and/or infratemporal fossae through the inferior orbital fissure
V	VA: Extraconal or intraconal OCH with pterygopalatine and/or infratemporal fossa extension through the inferior orbital fissure VB: Extraconal or intraconal OCH with intracranial extension through the superior orbital fissure	Extraconal or intraconal with intracranial extension through the superior orbital fissure

Abbreviations: CHEER, Cavernous Hemangioma Exclusively Endonasal Resection; OCH, orbital cavernous hemangioma; ORBIT, Orbital Resection By Intranasal Technique.

communication between multidisciplinary teams and standardize surgical candidacy, tumor extent, and outcomes reporting. The Cavernous Hemangioma Exclusively Endonasal Resection (CHEER) staging system for OCHs was developed in 2019 by an international multidisciplinary panel, based on tumor location relative to critical intraconal structures. Selected tumors located medial to the optic nerve and/or inferior to the plane of resectability (intraconal orbital surgery) were defined as candidates for endoscopic resection.⁹¹¹ In an attempt to extend the accumulated knowledge obtained from endoscopic orbital cavernous hemangioma (OCH) resection to include all benign tumors, the ORBIT classification system was then introduced to define the surgical complexity of both endoscopic resection and combined open and endoscopic resection for any benign primary orbital lesion (Table XIX.A.1).⁹¹²

1 | Efficacy of tumor resection

Tailoring the appropriate approach based on tumor location and characteristics is the key to safe and efficacious treatment (Table XIX.A.2). Continued development and refinement of surgical techniques enable the use of 360° approaches based on the endoscopic endonasal corridor. Thus, coupling transnasal endoscopic orbit surgery with transconjunctival, transorbital/transcaruncular, lateral orbitotomy, or craniotomy approaches can extend the boundaries of reach to various ORBIT classes with decreased morbidity. A transcaruncular approach can supplement EEA to gain additional access to the medial orbit and for fat retraction and lateral tumor surface dissection. For intraorbital neoplasms located lateral to the optic nerve, the transorbital endoscopic approach represents the less invasive route to perform biopsies, debulking, or complete removal of lesions.^{910,913,914}

TABLE XIX.A.2 Evidence surrounding tumor resection for benign orbital lesion and associated complications.

Study	Year	LOE	Study design	Study group	Study endpoints	Conclusion
Lehmann et al. ⁹⁴⁰	2022	2	Systematic review and meta-analysis	Patients with benign orbital tumors resected via EEA across 24 studies (<i>n</i> = 60)	<ol style="list-style-type: none"> 1. Extent of resection 2. Postoperative complications 3. Postoperative clinical outcomes 4. Recurrence 	Most outcomes assessed did not appear affected by orbital reconstruction status
Jafari et al. ⁹¹⁵	2021	2	Systematic review and meta-analysis	Patients with benign orbital tumors resected via EEA across 36 studies and retroactively staged via the CHEER system (<i>n</i> = 105)	<ol style="list-style-type: none"> 1. Extent of resection 2. Postoperative clinical outcomes 3. Recurrence 	<ol style="list-style-type: none"> 1. Improved outcomes and safety of benign orbital tumor treatment were observed with endoscopic resection relative to external approaches 2. The CHEER anatomic-based framework can potentially be broadened beyond OCHs to all benign orbital tumors
Jafari et al. ⁹¹²	2022	4	Retrospective case series	Patients who underwent EEA for resection of primary orbital tumors and were retroactively classified via the ORBIT system (<i>n</i> = 110)	<ol style="list-style-type: none"> 1. Extent of resection 2. Postoperative clinical outcomes 3. Recurrence 	<ol style="list-style-type: none"> 1. Endoscopic treatment of primary orbital tumors is a safe and effective approach, with favorable short- and long-term postoperative outcomes 2. The ORBIT classification system is a simplified anatomic-based framework that may effectively facilitate high-quality outcomes reporting for all primary orbital tumors
Pennington et al. ⁹¹⁶	2021	4	Retrospective case series	Patients with symptomatic orbital schwannoma resected via endoscopic transorbital-assisted approach (<i>n</i> = 3)	<ol style="list-style-type: none"> 1. Extent of resection 2. Postoperative visual outcomes 	Resection of orbital schwannomas using an endoscopic endonasal approach with small incision medial transorbital assistance is a safe and effective option for a multidisciplinary surgical team
Caballero-Garcia et al. ⁹²¹	2021	4	Retrospective case series	Patients with orbital intraconal tumors treated via EEA or anterior endoscopic orbitotomy (<i>n</i> = 22)	<ol style="list-style-type: none"> 1. Postoperative complications 2. Postoperative visual outcomes 	The minimally invasive 360° surgical approach with full endoscopic visualization can be safe and efficient in patients with select orbital intraconal tumors
Jeon et al. ³⁵⁶	2021	4	Retrospective case series	Patients with intra- and extraconal orbital tumors treated via transorbital superior eyelid approach or EEA (<i>n</i> = 16)	<ol style="list-style-type: none"> 1. Postoperative visual outcomes 2. Postoperative complications 3. Need for adjuvant therapy 	Selection of the approach based on a concept of a four-zone model with its epicenter around the optic nerve successfully provides a minimally invasive 360° circumferential access to the entire orbit

(Continues)

TABLE XIX.A.2 (Continued)

Study	Year	LOE	Study design	Study group	Study endpoints	Conclusion
Maza et al. ⁹²²	2019	4	Retrospective case series	Patients with optic nerve sheath meningiomas undergoing transnasal endoscopic optic nerve decompression ($n = 4$)	Postoperative visual outcomes	Transnasal endoscopic optic nerve decompression could be a viable initial treatment modality of select primary optic nerve sheath meningiomas
Castelnuovo et al. ⁹³⁵	2019	4	Case report	Patients with intraconal cavernous hemangioma treated via cryoprobe-assisted transnasal endoscopic resection ($n = 2$)	Postoperative visual outcomes	<ol style="list-style-type: none"> 1. Cryoprobes represent an adjunctive tool in the orbital surgeon's armamentarium useful in extracting fluid-filled intraorbital lesions 2. Their use may ease the removal of intraconal hemangiomas with an exclusively transnasal approach
McCormick et al. ⁹³⁸	2019	4	Retrospective case series	Patients with simultaneous skull base and medial orbital wall defects undergoing modified nasoseptal flap reconstruction ($n = 3$)	<ol style="list-style-type: none"> 1. Postoperative CSF leak 2. Orbital edema 3. Postoperative cosmesis 	The described nasoseptal flap modification provides excellent coverage for reconstructing large anterior skull base defects and simultaneous medial orbital wall defects
Montano et al. ⁹¹⁹	2018	4	Retrospective case series	Patients with orbital tumors treated via fronto-orbital craniotomy, frontal approach, fronto-orbit-zygomatic approach, and EEA ($n = 70$)	<ol style="list-style-type: none"> 1. Extent of resection 2. Postoperative clinical outcomes 3. Postoperative complications 	<ol style="list-style-type: none"> 1. EEA should be used for primary orbital tumors located in the medial or inferior orbital walls without extra-orbital extension 2. The trans-eyelid approach should be used for extraconal tumors located in the upper and upper-lateral quadrants 3. The fronto-orbital approach should be used for intraconal-located tumors involving more than one quadrant
Peron et al. ⁹²⁴	2017	4	Retrospective case series	Patients with sphenoidal meningiomas treated via open, endoscopic, or combined open/endoscopic approach ($n = 30$)	<ol style="list-style-type: none"> 1. Extent of resection 2. Postoperative complications 	In selected cases, the endoscopic approach allows complete removal of sphenoidal meningiomas with a low rate of complications

Abbreviation: EEA, endoscopic endonasal approach.

A comprehensive meta-analysis that included 105 primary benign orbital lesions resected exclusively by endoscopic approach found that 61.9% of tumors were intraconal. The leading presenting symptoms were decreased visual acuity, visual field defect, proptosis, diplopia, color

vision deficit, and pain. GTR was achieved in 76.2% of cases, and only 2.9% of cases had tumor recurrence. After 24 months of follow-up, 95.5%, 98.3%, and 100% of the patients had improved/stable visual symptoms, resolved diplopia, and no pain symptoms, respectively.

There were no differences in surgical outcomes when comparing OCH and other benign orbital tumors by individual CHEER stages.⁹¹⁵ With increased CHEER stage, preferences toward a binarial approach and using a two-surgeon (three- or four-hand) dissection technique as well as increased likelihood of intraoperative reconstruction was reported.⁹¹¹

Endoscopic resection of selected intraconal and medial orbital schwannomas of symptomatic patients can be achieved via purely EEA or assisted by small-incision medial orbitotomy, particularly when the tumor extends anterior to the meridian of the globe. Several studies reported that tumors ranging from 1.6 to 5.9 cm³ were resected with no complications and with improved postoperative visual symptoms.^{356,916–920} On the other hand, optic nerve sheath meningiomas are complex to manage, and iatrogenic blindness is not rare. Several cases of endoscopic endonasal optic canal decompression and GTR were recently published with encouraging outcomes. However, the value of endoscopic surgery for these lesions remains unclear.^{921–924}

A multicenter international retrospective analysis of 110 consecutive tumors found that ORBIT class III tumors represented approximately half (45.9%) and class II tumors represented 18.4% of all tumors, followed by classes I, IV, and V tumors, which constituted 16.5%, 13.8%, and 5.5%, respectively. When comparing benign orbital tumors that were resected exclusively endoscopically (76.4%) to those that were addressed in a combined fashion (23.6%), the former tended to be OCHs and were smaller in size. The presentation included visual field deficits and decreased visual acuity in over half of all patients at presentation (58.2% and 57.3%, respectively). Proptosis was seen in 37.3% patients, and approximately a fifth of patients presented with diplopia (21.8%) or pain/headache (20.9%). A combined approach was more commonly used when the patient presented with diplopia (46.2%, $p = 0.001$) but tended to be less commonly used in cases of visual field deficit (42.3%, $p = 0.06$) on presentation. Medial rectus muscle retraction was more commonly performed for tumors that were addressed via a combined approach, and two or more surgeons were more likely to be involved in those cases. Tumors that were exclusively endoscopically approached tended to achieve GTR, although this may be confounded by smaller tumor size. Overall, GTR was achieved in 80.2% of tumors. When considering long-term surgical outcomes using the ORBIT classification system, as with CHEER, there was also a significant trend away from GTR within an increasing class. Overall, the long-term outcomes were favorable compared to patients' baseline presentation, with 99% of patients who had visual deficits at baseline (i.e., visual field deficits, decreased visual acuity, and/or impaired color vision) experienc-

ing an improvement in their preoperative visual deficits, and 79.7% patients showing improvement or no change in diplopia, 92.3% in eye position, and 96.7% in reported pain/headache.⁹¹²

A cadaveric study investigated the prelacrimal corridor to orbital floor lesions located inferolateral to the optic nerve and found improved visualization and preservation of neurovascular structures by entry laterally to the inferior rectus muscle after mobilization of the infraorbital nerve and drilling of the orbital floor.⁹²⁵ This approach provided good access to the space between the orbital floor and the optic nerve. The prelacrimal approach may also facilitate access to select ORBIT III lesions and preclude the need for septectomy or a transeptal approach, while ORBIT II lesions may be approached via a transtmoid approach, through the corridor between the medial rectus and superior oblique muscles after retraction of the medial rectus muscle.^{925–928} Described methods for medial rectus muscle retraction include the placement of vessel loops around the medial rectus muscle insertion point at the globe, pulled through a transeptal corridor or transchoanal static retraction. Dynamic retraction options using various instruments have been associated with the greatest intraconal exposure and reduce the risk of oculomotor neuropraxia resulting from tonic retraction.^{929–931} Injection of indocyanine green with the enhancement of vascular lesions 1–30 min after injection and use of suitable endoscope filters may facilitate differentiation of the vascular lesion from the muscular and surrounding soft structures and allow refined dissection.⁹³² Methods of direct tumor retraction may also include the placement of traction suture through the OCH capsule and use of a cryoprobe.^{933–935}

The benefit of medial orbital wall reconstruction is an area of active investigation, and while data are being accrued, the current literature remains scant, with variable risk of postoperative enophthalmos and diplopia based on tumor size, location, and degree of intraconal dissection. Some surgeons advocate using soft materials such as free mucosal grafts, pedicled flaps, or self-dissolving materials, while others have used rigid materials such as bone, titanium mesh, or porous polyethylene implants. The associated risk of orbital compartment syndrome due to postoperative edema, oozing, and fluid transudation in the setting of immediate rigid reconstruction is an area of continued investigation.^{910,936–939}

A meta-analysis of 60 patients from 24 studies reported that 56.7% of patients underwent orbital reconstruction following resection by pedicled flaps (44.1%), free mucosal grafts (32.4%), and rigid reconstruction (8.8%). The decision to perform reconstruction was linked with preoperative vision compromise—visual field defect (61.8% vs. 7.7%; $p < 0.001$), decreased visual acuity (73.5% vs.

34.6%; $p = 0.003$), and color vision deficits (41.2% vs. 0%; $p < 0.001$)—and a trend toward intraconal location, whereas the patients for whom reconstruction was foregone were presented with preoperative proptosis (69.2% vs. 17.6%; $p < 0.001$), larger tumor size ($p < 0.001$), a uninarial approach ($p = 0.01$), and operative exposure of orbital fat ($p < 0.001$) and extraocular muscles ($p = 0.035$). In patients with intraconal tumors, there was a lower rate of short-term postoperative diplopia when reconstruction was performed (7.4% vs. 31.3%; $p = 0.041$). Nevertheless, at an average of 2 years postoperatively, this potential benefit of reconstruction did not persist, and the diplopia either improved or remained unchanged for all patients for whom reconstruction was foregone.⁹⁴⁰ A trend toward reconstruction for higher CHEER stages was reported in numerous studies.^{911,915,940}

Endoscopic resection of intraconal orbital lesions

Aggregate grade of evidence	C (Level 2: two studies; Level 4: nine studies)
Benefit	Higher rates of GTR with reduced local morbidity relative to open approaches among patients with lesions medial to optic nerve and/or inferior to POR.
Harm	Risk of diplopia related to necessity for translamellar approach.
Cost	Associated costs with surgery and preoperative evaluations.
Benefits-harm assessment	Balance of benefits and harms.
Value judgments	No study to date has compared endoscopic and open approaches directly. However, in appropriately selected patients (e.g., tumor medial to the optic nerve and/or inferior to POR), endoscopic orbital surgery was preferred to traditional open approaches with reduced external morbidity. Not all patients are candidates for an endoscopic orbital approach, with tumors lateral and superior to POR and/or concern for invasion of local structures.
Policy level	Option.
Intervention	Endoscopic orbital surgery approach may be offered in lieu of open surgery by trained multidisciplinary orbital teams following appropriate workup and candidacy determination.

2 | Complications

Increased risk of complications was associated with higher tumor stage.⁹¹¹ The meta-analyses revealed a short-term

(<14 days) overall postoperative complication rate of 30%, including diplopia (15.2%), cranial nerve palsy (II, III, V₁, VI) (8.6%), and visual acuity and field defects (<4%). This complication rate was substantially lower than the previously reported 50% complication rate reported with external approaches.^{915,941}

Among the 110 patients who were operated by endoscopic or combined approaches, the 26 patients who underwent a combined approach were more likely to experience an immediate cranial nerve palsy after surgery (11.5% vs. 1.2%, $p = 0.04$) and had a trend toward increased periorbital ecchymosis ($p = 0.09$). However, this difference did not sustain in the long term (>14 days). The remainder of immediate complications (visual field defect, visual acuity defect, diplopia, epistaxis, infection, new enophthalmos, severe edema, uncontrolled pain, and others) were similar between both groups.⁹¹²

B | Other benign orbital lesions

1 | IgG4-related ophthalmic disease

IgG4-related ophthalmic disease (IgG4-ROD) was first suspected as a cause of autoimmune pancreatitis in 2001 and, in 2012, IgG4-related disease was formally defined as a multisystem immune-mediated inflammatory condition characterized by the abnormal infiltration of IgG4-positive plasma cells leading to pathologic formation of tumefactive masses and hypertrophic lesions (Table XIX.B.1).⁹⁴² Though largely associated with pancreatic lesions, the orbit was in fact the first reported extra-pancreatic site.⁹⁴³ Therefore, IgG4-ROD is considered to be a subset of IgG4-related disease and was traditionally known as orbital pseudotumor (OP), also known as idiopathic orbital inflammation (IOI).

Unlike many autoimmune disorders, IgG4-ROD has a near-equal distribution between males and females.⁹⁴⁴ The presentation of IgG4-ROD is classically insidious, is often bilateral, and is associated with painless eyelid swelling and proptosis. Symptoms vary depending on the involved periorbital tissues and include epiphora, erythema, and visual deficits. Pain is uncommon. The most commonly affected periorbital site is the lacrimal gland, although involvement of periocular nerves (including the optic and trigeminal nerves), adnexa, and soft tissue has been reported.⁹⁴⁵ Salivary gland involvement is common.^{945,946} Absence of pain, bilateral involvement, a prolonged waxing and waning history, and concomitant salivary gland involvement may help to clinically distinguish IgG4-ROD from other causes of orbital inflammation.^{947,948} Though not pathognomonic, radiographic lacrimal gland involvement in IgG4-ROD

TABLE XIX.B.1 Evidence surrounding IgG4-related ophthalmic disease (formerly idiopathic orbital inflammation/orbital pseudotumor).

Study	Year	LOE	Study design	Study groups	Clinical endpoints	Conclusions
Wu et al. ⁹⁴⁷	2015	2	Systematic review	Biopsy-confirmed cases of IgG4-ROD with available histopathologic features (<i>n</i> = 172)	1. Clinical features 2. Histopathologic features	No gender predilection, bilateral in >50% of cases, steroid-responsive but recurrent
Suhr et al. ⁹⁶⁷	2014	2	Double-blinded RCT	Orbital inflammation patients refractory to systemic corticosteroids and at least one other immunosuppressant (<i>n</i> = 10)	1. Validated orbital disease grading scale 2. Corticosteroid dose reduction	1. Rituximab was safe and effective in seven out of 10 refractory OP patients, without toxicity 2. Rituximab should be considered in steroid-refractory orbital inflammation
Andrew et al. ⁹⁴³	2013	2	Systematic review and meta-analysis	Cases of “definite” or “probable” IgG4-ROD identified in the literature (<i>n</i> = 88)	Clinical features	Compared to pancreatic IgG4-RD, IgG4-ROD affects younger patients and is associated with salivary gland lesions
Goto et al. ⁹⁴⁶	2021	3	Retrospective cohort	Patients diagnosed with IgG4-ROD (<i>n</i> = 378)	Clinical features	Periocular tissue other than the lacrimal gland may be affected in IgG4-ROD
Chen et al. ⁹⁴⁸	2021	3	Retrospective cohort	Idiopathic orbital inflammatory disease patients with and without IgG4-positive histopathology (<i>n</i> = 165)	1. Clinical features 2. Recurrence	1. IgG4-ROD had fewer symptoms and longer duration at presentation than IgG4-negative orbital inflammatory pseudotumor 2. IgG4 positivity portended a greater rate of recurrence in the subgroup of patients treated with surgery plus oral glucocorticoids
Abad et al. ⁹⁵¹	2019	3	Prospective cohort	Patients with orbital tumors and histologically documented (<i>n</i> = 35)	1. IgG4 positivity on biopsy 2. Other histopathologic features	IgG4-ROD more likely to have storiform fibrosis, plasmacytic infiltrate, and periphlebitis
Min et al. ⁹⁵⁶	2019	3	Retrospective cohort	Orbital inflammatory pseudotumor patients diagnosed via surgical pathology (<i>n</i> = 16)	Histopathologic features	Histopathologic findings of collagenous fibrosis, count and ratio of IgG4-positive plasma cells, and anatomic location of lesion (lacrimal gland) all point to IgG4-ROD; in their absence, OP is likely
Aryasit et al. ⁹⁵⁷	2021	4	Retrospective case series	Patients with a histopathologic diagnosis of idiopathic orbital inflammation (<i>n</i> = 45)	1. Clinical features 2. Histopathologic features	IgG4-ROD more frequent in patients with infraorbital nerve involvement and bilateral disease

(Continues)

TABLE XIX.B.1 (Continued)

Study	Year	LOE	Study design	Study groups	Clinical endpoints	Conclusions
Derakhshandeh et al. ⁹⁵²	2021	4	Retrospective case series	Cases of inflammatory pseudotumor ($n = 13$)	Histopathologic features	OP may demonstrate on pathology B-cell clonality without meeting pathologic or clinical criteria for IgG4-ROD
Eissa et al. ⁹⁵⁴	2021	4	Retrospective cohort	OP ($n = 21$) and orbital lymphoma patients ($n = 16$) with MRI-specific findings of tumor blood flow, arterial-spin labeling, apparent diffusion coefficient, and diffusion-weighted imaging	1. AUC 2. Sensitivity 3. Specificity 4. PPV 5. NPV	On MRI, tumor blood flow and apparent diffusion-coefficient alone and in combination may differentiate OP from orbital lymphoma
Hou et al. ⁹⁵³	2021	4	Retrospective cohort	Pathology-confirmed OP ($n = 28$) and ocular adnexal lymphoma patients ($n = 28$) retrospectively divided into training ($n = 42$) and testing groups ($n = 14$)	1. AUC 2. Sensitivity 3. Specificity 4. PPV 5. NPV	OP and ocular adnexal lymphoma may be differentiated on MRI using machine-learning enhanced algorithms
Kubota et al. ⁹⁶¹	2020	4	Retrospective case series	IgG4-ROD patients with ocular adnexal lesions ($n = 82$)	Long-term recurrence	CN V and/or extraocular muscle involvement may confer long-term disease refractoriness to systemic corticosteroid treatment
Lee et al. ⁹⁵⁵	2016	4	Retrospective case series	Patients clinically diagnosed with OP with presenting radiology and 12-month clinical follow-up ($n = 89$)	1. Clinical features 2. Radiographic findings	Patients diagnosed with OP that have infra-orbital nerve enlargement have higher recurrence following corticosteroid treatment
Wu et al. ⁹⁵⁹	2015	4	Retrospective case series	Biopsy-confirmed cases of steroid-dependent or resistant IgG4-ROD treated with rituximab ($n = 5$)	1. Adverse events 2. Treatment outcomes	Rituximab resulted in clinical and radiologic improvement with relatively benign side effect profile in patients with IgG4-ROD that is steroid dependent or steroid-resistant
Sogabe et al. ⁹⁴⁹	2014	4	Retrospective case series	Histopathologically confirmed cases of IgG4-ROD ($n = 65$)	1. Clinical features 2. Lesion frequency 3. Lesion location	1. Lacrimal gland enlargement was the most frequently observed lesion (87.7%) 2. 31 patients (47.7%) had lacrimal gland involvement alone

(Continues)

TABLE XIX.B.1 (Continued)

Study	Year	LOE	Study design	Study groups	Clinical endpoints	Conclusions
Kubota et al. ⁹⁶⁰	2013	4	Retrospective cohort	IgG4-ROD patients with ($n = 24$) or without ($n = 6$) corticosteroid treatment	<ol style="list-style-type: none"> 1. Serum rheumatoid factor 2. Recurrence 	<ol style="list-style-type: none"> 1. Eight (33%) of the steroid-treated patients showed relapse 2. Serum rheumatoid factor was elevated in steroid-treated patients who relapsed at 6 months after discontinuation of treatment
Bijlsma et al. ⁹⁶⁴	2011	4	Retrospective cohort	Patients with inflammatory pseudotumor treated with intravenous corticosteroids plus oral steroids ($n = 12$) and oral steroids only ($n = 15$)	<ol style="list-style-type: none"> 1. Duration of oral prednisone 2. Symptom-free outcome 3. Complication 	Intravenous corticosteroids are most advantageous for short-term symptomatic control and optic nerve dysfunction recovery
Chirapapaisan et al. ⁹⁷⁵	2007	4	Retrospective case series	OP patients ($n = 49$)	<ol style="list-style-type: none"> 1. Demographic and clinical characteristics 2. Treatment outcomes 	Three quarters of patients had unilateral disease; proptosis was most common presenting symptom
Leibovitch et al. ⁹⁶⁵	2007	4	Retrospective case series	Patients with clinical, radiologic, pathologic confirmation of OP treated with intra-orbital triamcinolone, repeated at 4 weeks if incomplete resolution ($n = 10$)	Local and systemic complications	Intraorbital corticosteroid should be considered an effective treatment for OP
Yuen and Rubin ⁹⁶²	2003	4	Retrospective case series	Patients with idiopathic orbital inflammation ($n = 65$)	Clinical and treatment outcomes	Systemic steroid with slow taper should be considered first-line therapy for OP
Derzko-Dzulynsky ⁹⁴⁵	2017	5	Expert opinion	N/A	<ol style="list-style-type: none"> 1. Clinical features 2. Treatment outcomes 	<ol style="list-style-type: none"> 1. Systemic involvement common when IgG4 ROD is bilateral or involving the lacrimal gland 2. Rituximab is a targeted therapy that may improve outcomes
Mombaerts et al. ⁹⁷⁶	2016	5	Expert opinion	N/A	Expert opinion on utility of biopsy over corticosteroid in suspected OP	Histopathology is advocated as efficient manner of making diagnosis in orbital inflammatory disorders
Dagi Glass and Freitag ⁹⁶³	2016	5	Expert opinion	N/A	Expert opinion on utility of empiric corticosteroid in suspected orbital inflammation	Empiric corticosteroid treatment and attention to responsiveness may obviate histopathologic diagnosis in orbital inflammatory disease

(Continues)

TABLE XIX.B.1 (Continued)

Study	Year	LOE	Study design	Study groups	Clinical endpoints	Conclusions
Goto et al. ⁹⁵⁰	2015	5	Expert opinion	N/A	<ol style="list-style-type: none"> 1. Disease characteristics 2. Diagnostic criteria 	<ol style="list-style-type: none"> 1. IgG4-ROD is characterized by multispatial and multitemporal lesion onset, relative responsiveness to steroid treatment, and recurrence following treatment tapering 2. Further studies to develop a classification system of severity specifically for ophthalmic lesions are warranted
McNab and McKelvie ⁹⁴⁴	2015	5	Expert opinion	N/A	Description of presentation and co-morbid disease	Common patterns include enlargement of V2 (most often infraorbital) with eosinophilia and multiorgan disease
McNab and McKelvie ⁹⁴²	2015	5	Expert opinion	N/A	Description of presentation and co-morbid disease	Common patterns include enlargement of V2 (most often infraorbital) with eosinophilia and multiorgan disease
Mendenhall and Lessner ⁹⁷⁷	2010	5	Expert opinion	N/A	Expert opinion on clinical progression of OP and radiotherapy	Oral steroids are first-line therapy and for those who do not respond or relapse, radiotherapy or other cytotoxic therapies may be considered
Jacobs and Galetta ⁹⁷⁸	2002	5	Expert opinion	N/A	Expert opinion on OP evaluation, treatment, and outcomes	<ol style="list-style-type: none"> 1. Recurrent or steroid-resistant case of presumed OP warrant biopsy 2. Consider radiotherapy if multiply recurrent or refractory

Abbreviations: AUC, area under the curve; IgG4-ROD, IgG4-related ophthalmologic disease; NPV, negative predictive value; OP, orbital pseudotumor; PPV, positive predictive value.

has been demonstrated in up to 88% of patients in one radiographic review of 65 histologically confirmed cases.⁹⁴⁹

Histopathologic examination of affected tissue is necessary to establish the diagnosis, and cellular makeup reveals marked lymphocytic and plasmacytic infiltration, fibrosis (often “storiform”), a ratio of IgG4+ plasmacytes to IgG+ plasmacytes of more than 40%, and more than 400 IgG4+ cells per mm². “Definitive” IgG4-ROD is defined as (A) enlargement of periorbital tissue including the trigeminal nerve on imaging, (B) the previously mentioned histopathologic findings, and (C) a serum IgG4 \geq 135 mg/dL. “Probable” disease is defined as a combination of points A and B, while “possible” disease is defined as having met points A and C.^{950,951}

Many radiographic studies have focused on OP as an entity prior to recent pathologic classification as IgG4-ROD. Contrast-enhanced MRI with fat suppression is acknowledged to be superior to CT in the initial evaluation. Neither modality has findings specific for IgG4-ROD; however, an enhancing focal or infiltrating orbital mass

is typically more thoroughly defined on MRI.⁹⁵² Unfortunately, the nonspecific nature of these imaging findings makes it difficult to distinguish IgG4-ROD from other more common orbital adnexal lymphoproliferative (OAL) disorders or in rare cases, fungal disease or vasculitis. Machine learning techniques, however, have been recently evaluated as a method to improve diagnostic accuracy. In a retrospective study of 28 OP and 28 OAL patients, Hou et al. found that machine learning reliably distinguished the two entities with a sensitivity, specificity, PPV, and NPV of 71%, 91%, 89%, and 76%, respectively. In the same study, expert radiologists reliably distinguished the two disease entities with 75%, 68%, 70%, and 73% sensitivity, specificity, PPV, and NPV, respectively.⁹⁵³ Another retrospective study of 21 OP and 16 OAL patients utilized a combination of tumor blood flow and apparent diffusion coefficient (ADC) on MRI to differentiate OP from OAL with 90% sensitivity, 93% specificity, 95% PPV, 88% NPV, and 91% accuracy.⁹⁵⁴ Radiologic findings may have some prognostic significance in OP. A relatively large study evaluating 89 patients with OP demonstrated that the 12 patients with infraorbital nerve

enlargement had more severe symptomology and higher propensity for recurrence.⁹⁵⁵

As recognition of IgG4-ROD as a distinct disease entity has become more widespread, a large body of literature has focused on re-examining previously diagnosed cases of OP. Recently, Min et al. reviewed 16 cases previously diagnosed as OP, and after staining for IgG4+ plasma cells and identifying storiform fibrosis, a diagnosis of IgG4-related disease was made.⁹⁵⁶ A review of 55 previously diagnosed cases of OP demonstrated that over 40% were histologically re-classified as IgG4-ROD. In another study, which evaluated cases of previously diagnosed OP, the radiologic findings of bilateral orbital involvement and infraorbital nerve involvement are associated with IgG4-ROD when tissue samples are assessed by IgG4-ROD criteria.^{957,958}

Corticosteroids are the first-line treatment of IgG4-ROD.⁹⁵⁹ Data suggest that involvement of the trigeminal nerve and elevation of serum rheumatoid factor correlate with corticosteroid treatment failure, however.^{960,961} In some cases, successful treatment with corticosteroids may obviate the need to obtain histopathology.^{962,963} Intravenous corticosteroids have been shown to improve short-term disease, particularly when the optic nerve is involved.⁹⁶⁴ Intraorbital corticosteroid injection alone may be safe and efficacious for anterior chamber involvement.⁹⁶⁵ A current randomized trial comparing oral corticosteroid alone versus intraorbital steroid injection alone is ongoing.⁹⁶⁶ Finally, a small body of evidence reveals that rituximab may lead to clinical and radiologic improvement in steroid-responsive and steroid-resistant IgG4-ROD.^{959,967} Nevertheless, biopsy is recommended in cases that display signs of malignancy or when patients fail to respond to empiric corticosteroid therapy.

Aggregate grade of evidence: C (Level 2: three studies; Level 3: four studies; Level 4: 13 studies; Level 5: eight studies)

2 | Tolosa–Hunt syndrome

THS, which was first described in 1954 Tolosa and then further characterized in 1961 by Hunt, was classified in 1988 by the International Headache Society in the First International Classification of Headache Disorders (ICHD-I) (Table XIX.B.2).⁹⁶⁸ The initial criteria revolved around painful unilateral orbital pain associated with paresis of cranial nerves III, IV, or VI (inclusive of pain preceding paresis by up to 2 weeks), resolution of pain within 72 h of corticosteroid treatment, and exclusion of other causes by neuroimaging.⁹⁶⁸ These criteria were further refined such that by the third rendition (2018) of the ICHD, granulomatous inflammation in the cavernous sinus, superior orbital fissure, or orbit demonstrated by MRI or biopsy

was included.^{969,970} Though not strictly part of the diagnostic criteria, optic nerve and/or CN V involvement is commonly associated with THS, and the involvement of CN V and the optic nerve together has been associated in a retrospective case series with longer disease duration.⁹⁷¹ Given the rarity of THS, the demographic distribution of THS is uncertain; however, data suggest that it may be equally distributed between males and females.⁹⁷²

In THS, symptoms may improve spontaneously; however, they tend to remit and recur without adequate treatment. High-dose corticosteroids are the mainstay of treatment.⁹⁷³ If symptoms persist despite >72 h of high-dose systemic corticosteroids, surgical exploration of the affected tissue for sampling or consideration for alternative diagnoses are warranted.⁹⁷⁴

Aggregate grade of evidence: C (Level 2: one study; Level 4: two studies; Level 5: one study)

XX | OTHER RARE BENIGN NEOPLASMS AND LESIONS

A | Rosai–Dorfman disease

Rosai–Dorfman disease (RDD), or sinus histiocytosis with massive lymphadenopathy, classically presents with neck lymphadenopathy, fever, and weight loss.⁹⁷⁹ This rare condition, linked to gene mutations in *NRAS*, *KRAS*, *MAP2K1*, and *ARAF*, is more common in men and African Americans.⁹⁸⁰ Usually diagnosed by the second decade, RDD can occur in isolation or with autoimmune or malignant diseases. Isolated extranodal involvement arises in 43% of patients, with the head and neck region most affected, predominantly in the nasal cavity and paranasal sinuses (11%).^{980–982} Sinonasal disease presents as polyps, obstruction, rhinorrhea, facial asymmetry, headache, epistaxis, hyposmia, and proptosis.^{982,983} Imaging includes contrasted CT of the paranasal sinuses, MRI of the orbit/brain, or FDG-PET/CT. RDD lesions enhance on T1-weighted MRI and are FDG avid.⁹⁸⁰

On IHC, RDD histocytes are S100 and OCT2 positive with variable CD14, CD68, and CD163 positivity.⁹⁸⁰ Due to the self-limiting nature of the disease and the fact that spontaneous remission occurs in 50% of patients, management is reserved for symptomatic patients.⁹⁸⁴ Endoscopic resection of sinonasal disease can resolve symptoms.⁹⁸⁵ For unresectable, recurrent, or multifocal disease, corticosteroids, chemotherapy, and immunomodulators are options; however, results are mixed.⁹⁸² RT has been successful but is generally reserved for disease involving vital organs, such as the central nervous system, eyes, heart, and liver, where the risks of surgery outweigh its benefits.⁹⁸¹

TABLE XIX.B.2 Evidence surrounding Tolosa–Hunt syndrome.

Study	Year	LOE	Study design	Study groups	Clinical endpoints	Conclusions
Colnaghi et al. ⁹⁷³	2008	2	Systematic review	Patients with THS or orbital myositis across 48 studies (<i>n</i> = 62)	<ol style="list-style-type: none"> 1. Lesion location 2. Duration of symptoms and signs 	Diagnosis of THS cannot rely only on MRI findings, which should be considered in conjunction with clinical findings; in some cases, a biopsy will still be necessary
Zhang et al. ⁹⁷²	2014	4	Retrospective case series	Patients with nontraumatic painful ophthalmoplegia (<i>n</i> = 77)	<ol style="list-style-type: none"> 1. Clinical features 2. Radiographic findings 	<ol style="list-style-type: none"> 1. THS was the most frequently diagnosed type of painful ophthalmoplegia (46/77, 59.7%); however, it is essential to rule out all other causes of painful ophthalmoplegia to confirm the diagnosis of THS 2. CN III was the most commonly affected CN in THS
Türkoglu et al. ⁹⁷⁴	2008	4	Retrospective case series	Patients with THS causing cavernous sinus syndrome (<i>n</i> = 10)	<ol style="list-style-type: none"> 1. Clinical features 2. Radiographic findings 	Knowledge of the clinical presentation of THS is helpful in clinical decision-making for patients with cavernous sinus syndrome
Dutta and Anand ⁹⁶⁸	2021	5	Scoping-type review	Cases diagnosed and managed as THS across 153 studies	<ol style="list-style-type: none"> 1. Clinical features 2. Radiographic findings 3. False-positive THS diagnoses 	<ol style="list-style-type: none"> 1. THS is an agglomeration of symptoms rather than a diagnosis and may be associated with intra- and extracavernous vascular abnormalities 2. When histopathological diagnosis is unavailable, steroid-induced resolution of symptoms should be confirmed radiologically and followed up

Abbreviations: MRI, magnetic resonance imaging; THS, Tolosa–Hunt syndrome.

B | Lipomas

Lipomas are benign tumors composed of mature fat cells.^{986,987} Peak incidence is between 40 and 50 years of age with a slight male predominance.⁹⁸⁸ Thirteen percent of lipomas occur in the head and neck and become symptomatic due to mass effect.^{989–991} Sinonasal lipomas may present with unilateral nasal obstruction, facial swelling, pain, epistaxis, and nasal discharge. Imaging shows a low-density mass on CT and high-signal intensity on T1 MRI and low to iso-intense signal on T2.⁹⁸⁷ Histologically, lipomas resemble normal adipose tissue with a proliferation of mature fat cells; however, most of these tumors have chromosomal aberrations, including translocations (12q13-15), deletions (13q), and re-arrangements (8q11-13.4).⁹⁸⁹ Due to compromised blood supply or traumatic injury, lipomas may undergo changes such as infarction, hemorrhage, cystic degeneration, and calcifications.^{989,991} Curative treatment for symptomatic lesions is complete surgical excision.⁹⁸⁷

C | Pleomorphic adenoma

Pleomorphic adenomas are benign mixed tumors that arise from salivary gland ductal myoepithelial and epithelial cells. They rarely occur in the sinonasal cavity.^{992,993} They present in the third to sixth decade with unilateral nasal obstruction and/or epistaxis and have a slight female predominance.^{992–994} The nasal septum, lateral nasal wall, and nasopharynx are the most common primary sites; the maxillary sinus is the most commonly involved paranasal sinus.^{992,994,995}

CT may show an enhancing expansile lesion, and MRI typically demonstrates a well-defined lesion with low signal intensity on T1 MRI and variable signal intensity on T2 with heterogeneous contrast enhancement.^{994,996} Pre-operative tissue sampling is critical for treatment planning, particularly in tumors with aggressive behavior (skull base extension, bony invasion, PNI) or high-risk imaging features (large size, poorly defined margins, T2 hypointensity) that suggest malignant potential.⁹⁹² Sinonasal pleomor-

phic adenoma has a predominant epithelial component, little stroma, and no capsule compared to major salivary gland counterparts.⁹⁹⁴ On IHC, they can stain positive for cytokeratin, vimentin, S100 protein, smooth muscle actin, and glial fibrillary acidic protein.⁹⁹⁴

En bloc resection is recommended. EEA or endoscopic-assisted approach provides superior visualization with low recurrence rate.^{994,995} Piecemeal resection and paranasal sinus site of origin may result in higher rate of recurrence.⁹⁹⁵ Lifelong surveillance is recommended due to potential for recurrence and malignant transformation.⁹⁹²

D | Phosphaturic mesenchymal tumors

Phosphaturic mesenchymal tumors (PMTs) are rare low-grade polymorphous tumors that generally affect adults over the fourth decade with no gender predominance.⁹⁹⁷ A total of 5%–32% of PMTs arise in the head and neck, and up to 50% occur in the sinonasal tract.⁹⁹⁸ The ethmoid sinus is most commonly involved.⁹⁹⁸

PMTs commonly cause tumor-induced osteomalacia (TIO), a fibroblast growth factor-23 (FGF-23)-mediated paraneoplastic syndrome that results in bone demineralization, hyperphosphaturia, and hypophosphatemia.^{997,998} Patients are asymptomatic or may present with osteoporosis, pathologic fractures, muscle weakness, or nasal obstruction secondary to mass effect.^{997,999} Diagnosis is often delayed due to insidious, nonspecific symptoms and challenges in localizing the lesion. Laboratory evaluation may show (1) elevated FGF-23, parathyroid hormone, and alkaline phosphatase; (2) normal calcium and vitamin D; and (3) low phosphate.^{997,998} Rarely, tumors are biochemically inactive.⁹⁹⁹

CT may show an enhancing soft tissue lesion with bone erosion; MRI will show diffuse enhancement on T1. PMTs are FDG avid on PET.⁹⁹⁷ Technetium-99m-octreotide scan may help with localization of TIO-associated tumors.⁹⁹⁸

PMTs display hemangiopericytoma (HPC)-like vasculature and adipose tissue.^{997,1000,1001} IHC helps differentiate from other lesions; PMTs are usually positive for CD56, ERG, and SATB2.^{1000,1001}

Surgical resection with wide margins can normalize laboratory values within 1–7 days and resolve TIO symptoms within months.^{997,998} Endoscopic resection has comparable results to open surgery.⁹⁹⁸ Postoperative RT can be used for the rare malignant lesion or for locally invasive disease in vital structures.^{999,1002} Laboratory values should be monitored due to recurrence risk. For inoperable tumors, phosphorus supplementation can control symptoms.⁹⁹⁸

Monoclonal antibody treatment (burosumab) has been reported, but requires further study.^{998,1003}

E | Solitary fibrous tumor

HPC is a vascular neoplasm, now classified as a solitary fibrous tumor (SFT), originating from mesenchymal cells with pericyte differentiation.¹⁷ For the purposes of this section, the term HPC will be used in place of SFT. A total of 15%–25% occur in the head and neck, comprising 1% of all vascular tumors and 2.5% of all vascular sinonasal tumors.^{1004–1006} Sinonasal HPC occurs equally in females and males and typically present in the third to fifth decade of life with no identified risk factors. Grossly, HPC is a vascular, firm, circumscribed mass with variable color.¹⁰⁰⁴ Two systematic reviews reported epistaxis and nasal obstruction as the most common presenting symptoms.^{1007,1008} Bone pain and myopathy from associated hypophosphatemic osteomalacia have been described, with one study noting these symptoms in 4.6% of patients.¹⁰⁰⁸

HPCs often originate from the ethmoid sinus, nasal septum, and inferior and middle turbinates.¹⁰⁰⁸ On contrast-enhanced imaging, they enhance strongly. A characteristic “soap bubble” or “honeycomb” appearance may be present on CT, while typical MRI characteristics are hypointense T1 signal, hyperintense T2 signal, and avid enhancement with intratumoral flow voids.^{19,1009} HPC stains intensely positive for vimentin and focally positive for CD34. While most HPCs are benign, malignancy can occur. Necrosis, cellular pleomorphism, moderate/high cellularity, and mitotic rate of >4 mitoses/2 mm² are features associated with malignant conversion.^{1010–1012}

Surgical resection is the primary treatment modality for HPC, and complete resection is the most important prognostic factor. Systematic reviews by Dahodwala et al. ($n = 104$) and Duval et al. ($n = 190$) found that 98% of patients underwent surgical resection, while <2% underwent RT.^{1007,1008} Half of the patients underwent open surgical approaches (most commonly rhinotomy) ($n = 100$), but 97% of cases have been performed endoscopically since 2003 ($n = 82$).¹⁰⁰⁷ Factors such as involvement of the anterior/inferolateral maxillary, anterior frontal sinus, or extrasinus extension limited a purely endoscopic approach.¹⁰¹³ There was no significant difference between open versus endoscopic approach with respect to recurrence rates or time to recurrence, but there was a trend toward better outcomes with the endoscopic approach. Preoperative embolization was reported in 8.6% of cases and assisted in optimizing the environment for an endoscopic approach ($n = 10$).¹⁰⁰⁷

The addition of RT for incomplete resection was associated with decreased recurrence rate and trended toward an increased time to recurrence; however, in patients receiving RT following complete surgical resection, there was no improvement in recurrence rate compared to those with complete surgical resection alone.¹⁰⁰⁸ Analysis of the SEER database showed that surgery plus chemotherapy improved survival to a greater extent than chemotherapy alone, although the outcomes of surgery alone were more favorable.¹⁰¹⁴ Skull base origin conferred worse prognosis as compared to sinonasal primary site.¹⁰¹⁵ Multiple different chemotherapeutic agents have been used with overall poor response rates, regardless of whether they were first-, second-, or third-line treatments.^{1016,1017} The only two surviving cases in a series of 21 locally advanced and unresectable HPCs had undergone neoadjuvant chemotherapy.¹⁰¹⁶ Alternative agents that inhibit VEGF or tyrosine kinase have shown more favorable responses or partial responses ($n = 14$).^{1018–1020}

Reported recurrence rate of sinonasal HPC is 20.3%–29.9% with an average mean follow-up of 47 months.^{1007,1008} Incomplete resection led to recurrence or tumor-related death in 71% (15/21) undergoing an endoscopic approach and 100% (3/3) undergoing an open approach.¹⁰⁰⁸ The rate of metastasis has been reported at 1.9%, with no increased risk from high-grade or large tumors.¹⁰⁰⁸ The majority of recurrences happen within 5 years, though late recurrence up to 210 months has been described and thus long-term follow-up is indicated.¹⁰⁰⁷

F | Glomangiopericytoma

Glomangiopericytoma (GPC), also known as sinonasal-type HPC, is a rare mesenchymal neoplasm with low malignant potential. Symptoms are typically nonspecific, with epistaxis being the most common, followed by nasal obstruction and headache.¹⁰²¹ GPC has a slight female predominance, an average age of presentation of 58 years (ranging from 3 months to 87 years), and an average duration of symptoms prior to presentation of 19 months.^{1022,1023} Similar to HPC, GPC may present with associated osteomalacia.¹⁰²² Although there are no clear risk factors, increased vascularity from trauma, pregnancy, hypertension, or use of corticosteroids has been associated with GPC.¹⁰²⁴

GPC is in part characterized by *CTNNB1* mutations and positive immunohistochemical staining for nuclear β -catenin.¹⁰²⁵ Lasota et al. demonstrated that oncogenic *CTNNB1* mutations activate β -catenin signaling and upregulate *Wnt*-signaling and cyclin D1 expression, which dysregulate the cell cycle leading to neoplastic transformation.¹⁰²⁶ This pathway is thought to play a cen-

tral role in the pathogenesis of GPC. GPCs are typically well-defined round or lobulated soft-tissue masses, often with erosive bone remodeling commonly located in the ethmoid or sphenoid sinuses.^{1027,1028} MRI characteristics may include avid enhancement, moderate to high T2 signal intensity with signal voids, and rapid wash-in and wash-out on dynamic contrast-enhanced MRI and high ADC values indicating low malignant potential.¹⁰²⁷ T2 signal voids indicate high vascularity, and embolization may be considered prior to resection.^{1029,1030}

The term GPC was first used to describe a tumor that exhibits both the branching vessels of HPCs and rounded cells with pale or basophilic cytoplasm of glomus tumors.¹⁰³¹ It is a submucosal tumor with pericytic myoid differentiation. Macroscopically, it is beefy, red, soft, and hemorrhagic.¹⁰³² Microscopically, GPC is a nonencapsulated tumor with spindle shaped cells in a storiform pattern, branching vessels in a staghorn configuration and perivascular hyalinization.^{1023,1024,1032} Immunohistochemical staining is commonly positive for smooth muscle actin, vimentin, and nuclear β -catenin while lacking expression of CD34, AE1/AE3, Bcl-2, CD99, CD117, Factor VIIIIR Ag, S100, and the NAB2-STAT6 fusion complex seen in SFT.

Surgical resection is the primary treatment for GPC.^{1024,1028,1033} In one systematic review, clean surgical margins resulted in 100% 5-year survival with no evidence of recurrence or metastasis (10/10).¹⁰²² For large and highly vascularized tumors, preoperative embolization has been shown to decrease tumor size, resection area, and intraoperative bleeding, increasing the likelihood of total resection. RT and chemotherapy alone have a high rate of recurrence and insufficient data exist to support adjuvant RT, particularly in cases of complete resection.^{1029,1034} The use of RT and chemotherapy was shown in one study to be significantly correlated to recurrence/metastasis ($p = 0.03$).¹⁰²² This association could be because RT and/or chemotherapy was used in cases of larger and more extensive tumors or ones not amenable to complete resection, but this was not discussed in detail. Other studies have shown that in the rare case of unresectable or metastatic disease, RT and chemotherapy can be useful as adjuvant or palliative treatment.^{1028,1031}

Overall prognosis is favorable with a 5-year survival rate of 88% and a recurrence rate of 17%, which change based on complete versus partial resection.^{1021,1023} Recurrence has been described to occur up to 12 years later, but most recur within 5 years.¹⁰³⁵ Recurrence is associated with incomplete resection, bony invasion, bilateral involvement, adjuvant chemo/RT, severe nuclear pleomorphism, tumor >5 cm, and high mitotic rate.^{1022,1023} One systematic review found that actin immunonegativity and CD34 immunopositivity correlated with poor prognosis in patients with GPC.¹⁰²² Metastasis is rare and typically pre-

ceded by multiple recurrences, and long-term surveillance with nasal endoscopy and imaging is recommended.

G | Eosinophilic angiocentric fibrosis

Eosinophilic angiocentric fibrosis (EAF) is a rare indolent fibroinflammatory lesion that typically involves the sinonasal tract, upper airway, and occasionally the orbit. The etiology of EAF is unknown, although it has been associated with allergies, atopy, chronic rhinosinusitis (CRS), prior trauma, and history of nasal surgery.¹⁰³⁶ Presenting symptoms are nonspecific and related to the anatomic location of the lesion, with the septum being the most common site. Nasal obstruction is found in over 75% of cases, with other presenting symptoms including nasal swelling/deformity, epistaxis, epiphora, pain, rhinorrhea, and headache.¹⁰³⁷ EAF was originally described as a mucosal form of granuloma faciale (GF), and while they have since been described as separate diseases, about 25% of patients with EAF have concurrent GF.¹⁰³⁸ There is no sex predilection, and average age of diagnosis is 48 years.¹⁰³⁹ Patients report symptoms for an average of 3 years prior to diagnosis.¹⁰³⁶ There are fewer than 70 cases of EAF described in the literature, so much remains unknown.

EAF lesions possess several characteristics of IgG4-related disorders (IgG4RD), including tumefactive lesions, elevated IgG4 plasma cells, and an increased IgG4:IgG ratio.¹⁰⁴⁰ Oligoclonal expansion of T cells plays a role in IgG4RD pro-fibrosis and has also been observed in EAF.¹⁰⁴¹ Eosinophils are not as common in IgG4RD and are more commonly seen in immune hypersensitivity production of inflammatory mediators and downstream fibroblast stimulation.¹⁰⁴² However, the association with IgG4 is not absolute, with many cases not meeting the traditional IgG4RD criteria, although some speculate that this is because IgG4 dissipates in more progressed or chronic disease.¹⁰³⁶

CT and MRI characteristics in EAF are nonspecific. EAF may appear as a well-circumscribed submucosal thickening of the septum or lateral walls or sinus opacification.¹⁰³⁸ Noncontrast CT typically shows a homogenous isodensity with rare to no calcifications and includes bone thinning, remodeling, or sclerosis in about 25% of patients.^{1037,1043} EAF is often misdiagnosed as inflammation or malignancy on PET because of the hypermetabolic FDG avidity.¹⁰⁴¹ For MRI, T1 images are isointense with moderate contrast enhancement, while T2 images are hypointense, attributed to later stage fibrosis.¹⁰⁴³

EAF lesions grossly appear as a fleshy, tan to pink submucosal mass.¹⁰⁴² Roberts and McCann initially described the histology and staging criteria for early and late

disease.¹⁰⁴⁴ Early disease tends to be a perivascular inflammatory lesion containing eosinophils, plasma cells, and lymphocytes. Foci of fibrosis develop as the lesion matures until there is dense fibrous thickening with perivascular “onion skin” fibrosis and decreased inflammatory cells in the late stage, although eosinophils remain prominent.^{1038,1042,1045} Concentric fibrosis is seen in all cases and is more intense in longstanding disease.¹⁰⁴⁶ There is no true granulomatous reaction, cytologic atypia, necrosis, or mitotic activity observed.¹⁰⁴² IgG4 assessment is also important for further characterization of the lesion and can impact management.

The treatment approach for EAF may involve surgery, medical therapy, or both. A systematic review reported 90% of patients received complete or partial surgical resection and one third received additional medical treatment with corticosteroids or immunosuppressants.¹⁰³⁶ Because of the rarity of the disease, testing and comparing treatments have been limited. The only treatment approach that has resulted in resolution of disease is total resection. The endoscopic surgical approach is the only variable that has correlated with likelihood of total resection.¹⁰³⁶ There is no clear benefit of adjuvant medical therapy along with complete resection in preventing recurrence.^{1036,1037} In all cases treated with partial resection with or without medical management or medical management alone, patients had persistent disease that needed closer monitoring for progression.¹⁰³⁶

There have been small case reports and case series on alternative treatments, including rituximab that is known to produce a good response in IgG4RD and showed reduction in tumor size of 50% with symptom resolution in a case of EAF that had recurred multiple times and failed multiple debulking procedures and steroid therapy.¹⁰⁴¹ Additionally, a recent case study showed benefit with methotrexate in EAF of the lip and palate in a single case.¹⁰⁴⁷ So while resolution of disease has only been seen with complete resection, alternative therapies may have a role when total resection is not possible or when there have been multiple recurrences. Multiple resections may be required as complete excision can be difficult as demonstrated by high recurrence rates of up to 70% following total resection.^{1037,1038} Recurrence generally occurs in the original anatomic location; however, there have been no statistically significant risk factors found to predict recurrence.¹⁰³⁷ All EAF cases to date have been nonfatal with no reports of malignant progression. Long-term follow-up is necessary due to the slow progression and high recurrence rate.¹⁰³⁹

Other benign sinonasal lesions that have been previously covered in ICSB include fibroosseous lesions (Section V.B), cholesterol granuloma (Section V.C), and schwannomas (Section V.D).⁵

SECTION III: MALIGNANT NEOPLASMS

XXI | SINONASAL SQUAMOUS CELL CARCINOMA

A | De novo sinonasal squamous cell carcinoma

1 | Background and epidemiology

Malignancies of the nasal cavity and paranasal sinuses are rare, representing only 3%–5% of cancers originating within the head and neck.¹⁰⁴⁸ In a review of 13,295 patients with SNM from the National Cancer Institute's SEER database between 1973 and 2011, Dutta et al. report the overall incidence of sinonasal cancer to be 0.83 cases per 100,000 patients.²⁹ Of all SNM, sinonasal squamous cell carcinoma (SNSCC) is the most common histologic subtype across all subsites of the sinonasal tract, representing an estimated 41.9%–51.6% of all sinonasal cancers.^{29,30,1048} This section serves as a standalone assessment of the current evidence for SNSCC and also as an update to the ICSB 2019 section on this topic (Section VIII.B).

In a SEER database analysis of 4994 patients with SNSCC between 1973 and 2009, Sanghavi et al. report the overall average incidence of SNSCC to be 0.36 cases per 100,000 patients.¹⁰⁴⁹ Importantly, however, trend analysis over the last 30 years demonstrates a statistically significant decline in the SNSCC incidence rate over that same time period. In 1973, the overall incidence rate of SNSCC was 0.41 cases per 100,000. While this incidence rate peaked in 1986, with an average incidence of 0.50 cases per 100,000, by 2009 that incidence rate fell to just 0.32 cases per 100,000. This translates to an annual percentage change between 1973 and 2009 of –2.21%, a trend that was reflected in both male and female populations independently (–2.63% and –1.69%, respectively).¹⁰⁴⁹

The rate and incidence of SNSCC vary greatly by patient demographic factors. This is an important consideration, given oncologic outcome disparities between patients of various socioeconomic backgrounds. In an NCDB review of 6155 patients with SNSCC, Black, Asian, and Pacific Islanders and those with Medicaid or uninsured were found more likely to present with advanced-stage disease. Of these, Black patients had the lowest OS rates (31.9% at 5 years). Additionally, older age was independently associated with worse OS when presenting with an advanced stage.¹⁰⁵⁰

The average age of diagnosis for SNSCC is estimated to be 62.3 years, with approximately 80% of patients diagnosed over the age of 55 and only 4.3% of patients diagnosed under the age of 40.^{29,32,1049} Further 64.44% of SNSCC presents in males.¹⁰⁴⁹ This translates to an estimated male

incidence of SNSCC of 0.52 cases per 100,000 patients, a female incidence of just 0.23 cases per 100,000 patients, and a male-to-female incidence ratio of 1.82–2.26:1.^{1048,1049} These data are corroborated by Ansa et al., who identify 63.6% of patients with SNSCC as male and 75% as White.³² Lastly, SNSCC presents much more commonly in Caucasians than in other races. An estimated three quarters of SNSCC presents in Caucasian patients, while only 12.9% present in African American patients.¹⁰⁴⁸

Interestingly, the incidence of SNSCC arising as a second primary in head and neck cancer patients is very low (estimated to be approximately 0.2%).¹⁰⁵¹ This is likely attributable to the fact that the common etiologies of SCC arising at other subsites of the head and neck are not strong causative risk factors for SNSCC.

a | Etiologies and risk factors

A number of etiologies have been proposed, including environmental and occupational exposures. While alcohol consumption and smoking are primary etiologies recognized in the development of SCC at other subsites of the aerodigestive tract, the causal relationship is not as clear for SNSCC. Alcohol consumption has never been implicated as a risk factor toward the development of SNSCC, and, although many historic case–control studies support smoking (and secondhand smoke exposure) as a risk factor for the development of SNSCC based on dose–response relationships and a decrease in risk associated with time since quitting, the evidence is dated and may be confounded by the inclusion of nasal vestibular SCC in those historic studies.^{58,92,231,1052–1055} Even by the most liberal estimates, smoking only increases the risk of SNSCC development by two to three times, far less than that at other subsites of the aerodigestive tract.⁹⁸

The most oft-cited occupational exposure is softwood dust, which is purported to confer a 20 times increase in risk of developing SNSCC compared with the general population and other sinonasal tumors. Additional occupational exposures that have been identified as etiologic risk factors in the development of SNSCC include leather dust, glues, formaldehyde, chrome, nickel, arsenic, and welding fumes.^{55,101,1056–1059} These chemical substances and industrial compounds are attributed in up to 30% of SNSCC.^{88,1049,1058,1059} There are additional reports of SNSCC in hairdressers and rubber workers, although these reports are limited.¹⁰⁶⁰

Another proposed etiology is viral oncogenesis. While the causative role of HPV on tumorigenesis is well established, its role in the tumorigenesis of SNSCC is not as well defined as at other subsites of the head and neck. Lawson et al. found HPV DNA by polymerase chain reaction (PCR) in 20% (46/230 cases) of SNSCC.⁶⁵⁷ However, this study did not distinguish between transcriptionally

active and transcriptionally inactive HPV infections. As such, Svajdler et al. performed a meta-analysis specifically assessing the presence of transcriptionally active HPV within SNSCC.¹⁰⁶¹ They identified transcriptionally active HPV in 23.5% of SNSCC cases (95% CI: 10.7%–41.2%) and transcriptionally active high-risk HPV in 32% of patients specifically with keratinizing SNSCC.¹⁰⁶¹ Lewis et al. reported rates of transcriptionally active high-risk HPV based on histologic subtype of SNSCC and identified HPV positivity in 75% of papillary SCC, 41.7% of basaloid SCC, 39.7% of nonkeratinizing SCC, and only 3.4% of keratinizing SCC.⁶⁶⁴ The significance of the discrepancy between rates of HPV within keratinizing SNSCC between these two studies is not well understood. Nonetheless, HPV infection appears to play an etiologic role in approximately 25% of SNSCC. It is proposed that HPV-associated SNSCC confers an improved prognosis.^{1062,1063} Similarly, EBV has been detected in SNSCC. However, EBV has also been reported in a similar proportion of nasal polyps, and thus the role of EBV in SNSCC tumorigenesis is unclear.^{1064,1065}

Finally, CRS, allergic rhinitis, and nasal polyposis have been suggested as possible risk factors in the development of SNSCC.^{1052,1066} Chronic inflammatory states have been implicated as risk factors for tumorigenesis elsewhere in the body. However, the data for SNSCC are more limited, and a direct causative link between nonirritant chronic sinonasal inflammation and the development of SNSCC has not been established.¹⁰⁶⁷

2 | Pathologic features

Patients with SNSCC most often present with typical, albeit nonspecific, features. These include nasal obstruction, rhinorrhea, epistaxis, and facial pain.¹⁰⁶⁷ These symptoms are often, but not always, unilateral. The symptoms can be misinterpreted as more common benign processes, which may delay time from initial presentation to diagnosis.

In the head and neck, SCC generally arises from precursor squamous intraepithelial neoplasia. However, in the respiratory mucosa-lined sinonasal tract, squamous metaplasia must develop prior to neoplasia. Interestingly, in de novo SNSCC, dysplastic squamous epithelium/carcinoma in situ is uncommonly found in neighboring mucosa.¹⁰⁶⁸

a | Histology

Like at other anatomic subsites of the head and neck, the WHO classification designates a number of specific histologic subtypes of SNSCC. Most are either classified as keratinizing (conventional) or nonkeratinizing. It is estimated that 49.5% of SNSCC is keratinizing, 33.3% is nonkeratinizing, and the remaining 17% represent other subtypes.¹⁰⁶⁷ This is a distinction of potential clinical rele-

vance due to a potential discrepancy of prognosis between varying subtypes.

Keratinizing SCC is characterized by stellate, irregular nests of tumor cells in a desmoplastic stroma. These tumor cells have abundant eosinophilic cytoplasm filled with keratin filaments, prominent intercellular bridges, and keratin production. For keratinizing SNSCC, the histologic features are very characteristic and there is no significant differential diagnosis. Keratinizing SNSCC is further classified by grade (well, moderate, or poorly differentiated). Nonkeratinizing SCC was historically referred to as Schneiderian carcinoma, transitional cell carcinoma, or cylindrical cell carcinoma. Today, these terms are considered obsolete. The preferred terminology is nonkeratinizing SCC. Nonkeratinizing SNSCC is characterized by a ‘blue cell tumor appearance’ with high nuclear to cytoplasmic ratios arranged in large, rounded nests or ribbons with little desmoplastic stroma. The nests are typically well demarcated with smooth borders and commonly have central necrosis. Interestingly, these tumors often have a noninvasive appearance and can actually consist of completely exophytic projections. However, in the case of nonkeratinizing SNSCC, there are no clear data to suggest these tumors are clinically or prognostically different from more obviously invasive tumors. There is no role for tumor grading classification for nonkeratinizing SCC.

Importantly, other major SCC subtypes have been described in the sinonasal tract. The diagnosis of these subtypes is based on histopathologic appearance and features. These include papillary SCC, verrucous SCC, basaloid SCC, spindle cell carcinoma (sarcomatoid), and adenosquamous carcinoma. It is suggested that, like at other subsites of the aerodigestive tract, these subtypes may confer differing prognoses.^{65,1069} The 5-year DSS for each of the aforementioned subtypes is 62%, 70%, 56%, 32%, and 15%, respectively. The estimated 5-year DSS for patients with keratinizing and nonkeratinizing SNSCC is 45%.^{1069,1070}

b | Emerging subtypes

Beyond these traditional pathologies, newly characterized pathologies have been described. These include HPV-related multiphenotypic sinonasal carcinoma, sinonasal renal cell-like adenocarcinoma, NUT carcinoma, SCC associated with IP, SNUC, and SWI/SNF complex-deficient carcinoma. HPV-related multiphenotypic sinonasal carcinoma was described first in 2013 and is now included in the new WHO classification.¹⁷ There is a slight preponderance seen in female patients. It is characterized by cellular proliferation of basaloid cells, a solid growth pattern separated by thin fibrous bands. Additionally, there is usually surface dysplasia (carcinoma in situ), while a population of subtle eosinophilic ducts

may be identified. While this appears similar to ACC, PNI is uncommon. While these tumors stain p16 positive, the staining pattern is different from that of oropharyngeal HPV-associated tumors. This tumor tends to demonstrate an indolent course compared to aggressive sinonasal carcinomas, such as SCC. The largest study to date includes 49 patients and demonstrates a failure rate of 36%, primarily recurring locally. Only rare cases cause distant disease. Primary treatment is surgical resection, with the possibility of adjuvant radiation if there is concern regarding the adequacy of the surgical margins or in the setting of recurrence.¹⁰⁷¹

c | Primary site

SNSCC does not affect all subsites within the sinonasal tract equally. In a review of 5567 SNSCC patients from the SEER database between 1973 and 2011, Dutta et al. noted SNSCC to most commonly originate from the nasal cavity (46.5%), followed by the maxillary sinus (40.2%), ethmoid sinus (5.6%), sphenoid sinus (2.3%), and then the frontal sinus (1.1%). In this review, it was noted that 4.1% of SNSCC originated in an accessory sinus or from overlapping subsites.²⁹ However, other reports suggest that the maxillary sinus is in fact the most common site affected by SNSCC (60%), followed by the nasal cavity (25%) and the ethmoidal complex (15%).¹⁰⁷⁰ The reason for this disagreement is unclear.

Nonetheless, the site of origin is an important distinction, as the clinical behavior and prognosis of SNSCC arising from the maxillary sinus are different from those arising from the nasoethmoidal complex. Dutta et al. report a 52.3% 5-year DFS for SNSCC. However, this ranges from 30.5% when the site of origin is the frontal sinus to 34.1% when the site of origin is the maxillary sinus, and up to 76.0% when the site of origin is the nasal cavity.²⁹ Because of this, as is described below, the “T” definitions within the TNM staging system vary by tumor subsite. Additionally, though cervical lymph node metastasis is uncommon overall for SNSCC, a maxillary site of origin is much more likely to present with nodal metastasis than nasoethmoidal SNSCC. Cervical metastases, when present, confer worse prognosis.^{231,1063}

d | Biomarkers

While the diagnosis of these subtypes often relies on histologic features, there has been recent interest in novel biomarkers as a means of diagnostic, prognostic, and therapeutic intervention. The diagnosis of poorly differentiated SNSCC is challenging, as the differential is broad, including SNUC, SNEC, and subtypes of SNUC. The use of IHC and genomic analysis may help aid tumor characterization (i.e., *SMARCA4*, *SMARCB1*, *IDH2*, *NUTM1* pathogenic variants). Additionally, the use of biomarkers in defining

tumor cell lines has demonstrated that de novo SNSCC and IP-associated SNSCC are biologically distinct entities. Further, EGFR, p53, TrkB, and programmed death-ligand 1 (PD-L1) have been identified in SNSCC, offering possible targets for therapeutic intervention.¹¹¹

3 | Staging and imaging

Appropriate pretreatment staging of SNSCC is critical. Staging of SNSCC follows the same staging system as all other primary epithelial sinonasal tumors as defined by the AJCC 8th edition.¹⁵⁸ Unlike SCC of other sites in the head and neck, in which TNM stage is often defined by size, “T” stage of SNSCC is defined by location of origin and extent of involvement and invasion of local structures. To that end, high-quality cross-sectional imaging is critical to properly assess the degree of local extension with attention to the skull base, orbit, PPF, ITF, and parapharyngeal space. The gold standard imaging modalities include both CT and MRI. SNSCC can extend to adjacent structures via transgressing bony barriers of the nasal cavity, paranasal sinuses, orbit, and skull base. Erosion or reabsorption of these bony structures is best demonstrated on CT. Gadolinium-enhanced MRI offers great soft tissue resolution and provides better structural imaging than CT. MRI is useful for detecting invasion of nearby soft tissues including periosteum/periorbita, orbit, dura, brain, and cavernous sinus. Finally, like for SCC at other sites of the head and neck, PET/CT can offer essential staging information for advanced SNSCC. PET/CT can provide simultaneous anatomical and metabolic data of the primary tumor, while identifying both regional and distant metastasis.

4 | Treatment and outcomes

a | Role of induction/neoadjuvant chemotherapy

There is currently no consensus on the role of neoadjuvant chemotherapy for SNSCC. Data for outcomes of neoadjuvant chemotherapy are limited due to the rarity of the disease and because most phase III head and neck SCC studies excluded patients with sinonasal cancer. Current treatment regimens are largely extrapolated from more common tumors in other subsites of the head and neck.¹⁰⁷² A recent Triological Society Best Practices article reviewed this topic and identified several studies supporting treatment of locally advanced SNSCC with potential for organ preservation, suggesting its utility in the management algorithm.¹⁰⁷³

One of the earliest studies evaluating the role of neoadjuvant chemotherapy in the treatment of SNSCC was

published in 2000 by Kim et al. In this matched-control study 34 patients with unresectable SCC of the maxillary sinus were treated with neoadjuvant chemotherapy and RT and compared to 34 patients treated with RT alone. Despite a higher response rate to neoadjuvant chemotherapy, there was no OS or DFS benefit at 5 years posttreatment.¹⁰⁷⁴ However, since that time the application and treatment strategies have changed.

Much of the more recent data regarding neoadjuvant systemic therapy in the treatment of SNSCC are from retrospective reviews from major cancer centers. In a 2014 review of 41 patients with unresectable maxillary SCC treated between 2008 and 2011 with neoadjuvant chemotherapy followed by either surgery (29.3%), definitive CRT (58.5%), definitive RT (2.4%), or palliative RT (2.4%), the OS at 2 and 3 years was 41% and 35%, respectively. Ultimately, the conclusion of this retrospective review was that IC has clinically significant benefit with acceptable toxicity.¹⁰⁷⁵

Hanna et al. performed a single-institution retrospective review of 46 patients with advanced-stage (T3–4) SNSCC published in 2011. They found that 67% of this cohort demonstrated at least a partial response to neoadjuvant chemotherapy and an additional 9% demonstrated stable disease; 24% of patients had progressive disease during IC. The patients who had stable disease or a partial response to neoadjuvant chemotherapy demonstrated an improved rate of 2-year OS compared to patients with progressive disease (77% vs. 36%, respectively).¹⁰⁷⁶ In an updated retrospective review of 127 patients with previously untreated, locoregionally advanced SNSCC treated with neoadjuvant chemotherapy between 1988 and 2017 from the same group, Abdelmeguid et al. report similar findings. Most patients had at least partial response (52%), with complete response in 5% and progression of disease in 17%. Recurrence occurred in 26.8% of patients at a median time of 8.3 months. Most recurrences were local (63.6%). The study showed better 2-year OS and DFS in patients who had at least partial response or stable disease compared to patients who had progression of disease after neoadjuvant chemotherapy ($p = 0.028$ and $p = 0.021$, respectively). The 2-year OS and DFS rates for the whole cohort were 61.4% and 67.9%, respectively. There was no statistically significant difference between survival outcomes between the locoregional treatment modalities.¹⁰⁷⁷ In all, a systematic review assessing the role of IC in advanced SNM by Khoury et al. from 2019 concludes that, while IC has similar OS outcomes, it can be offered as an option to patients as part of multimodality therapy.¹⁰⁷⁸

This is particularly true in cases that would require deforming resections. While the goals of neoadjuvant systemic therapy for advanced-stage SNSCC are many—including decreasing the incidence of local recurrence

and distant metastasis in hopes of improving overall and disease-free survival—one major role of neoadjuvant systemic therapy that has been advocated for is to improve tumor control, downstage the primary “T” stage, and offer orbital preservation. In a retrospective review of 21 patients, Ock et al. showed a 61.9% partial response to IC in their patient cohort. Their most common regimen was docetaxel, fluorouracil, and cisplatin. They concluded that patients with a partial response and a downgrade in “T” stage led to increased incidences of orbit preservation and improved OS.¹⁰⁷⁹ In a similar effort to preserve the orbit, some advocate for neoadjuvant CRT. In a study by Amsbaugh et al., 20 patients with SNM involving the orbit requiring orbital exenteration (eight of which were SNSCC) were studied. Fourteen patients underwent neoadjuvant CRT and orbit preserving surgery, while six patients received an exenteration with adjuvant CRT. They found that exenteration-free survival was 62% at 2 years after treatment for patients undergoing initial orbit preservation treatment. Further, at 2 years posttreatment, there were no significant differences of PFS or OS. This is suggestive that in select cases, neoadjuvant CRT may offer a lasting means of orbit preservation.⁵⁰¹

The role of neoadjuvant CRT is further supported by a large NCDB review by Robin et al. of 11,160 patients with sinonasal cancer, 3331 of whom had SNSCC. In a subset analysis of just SNSCC, compared to surgery alone, neoadjuvant chemotherapy followed by surgery, and neoadjuvant RT followed by surgery, only neoadjuvant CRT was found to increase the rate of negative margins.¹⁵⁹ However, in another NCDB study of 3835 patients primarily designed to assess outcomes of SNSCC based on the volume of the treatment center, Teitelbaum et al. performed a multivariate regression analysis of different treatment regimens and found no statistically significant difference in outcomes for patients treated with surgery and neoadjuvant or adjuvant chemotherapy ($n = 34$) and surgery with neoadjuvant chemotherapy and adjuvant RT ($n = 47$).¹⁰⁸⁰

In an effort to increase cytotoxicity to tumor cells while decreasing systemic toxicity of chemotherapeutic agents, intra-arterial neoadjuvant chemotherapy has been described. Theoretically, this allows for a more direct delivery of high-dose cytotoxic agents to the tumor with potential to minimize side effects. However, because of small sample sizes and uncertainty about selection criteria, as well as conflicting toxicity reports, generalizations regarding this approach are limited.^{1081–1083}

Neoadjuvant chemotherapy seems to have a role in treatment of locally advanced SNSCC. Response rates are variable, and responders seem to demonstrate an improved OS. Additionally, patients with locally advanced tumors treated with neoadjuvant chemotherapy seem to

reflect improved OS compared to patients with similarly staged disease not treated with neoadjuvant therapy. The prospective clinical trials will be informative of its role and outcomes. Intra-arterial neoadjuvant chemotherapy may be useful for treatment of advanced maxillary sinus carcinomas as it demonstrates the ability to minimize toxicity from chemotherapeutic drugs. However, it is unclear which patients would benefit most from this therapy. Further studies are required to fully understand its indications and applications. Review of articles regarding IC is found in Table XXI.A.1.

Role of induction/neoadjuvant chemotherapy in sinonasal SCC

Aggregate grade of evidence	C (Level 3: one study; Level 4: four studies)
Benefit	Patients who respond to induction chemotherapy demonstrate improved OS and DFS.
Harm	There are systemic toxicities related to neoadjuvant therapy. Selective intraarterial neoadjuvant chemotherapy seems to reduce the rate and severity of toxicity. Additionally, inappropriate patient selection may lead to less favorable outcomes. Progression of disease during the neoadjuvant treatment period may lead to less favorable outcomes.
Cost	Insufficient data to make recommendation regarding long-term costs of neoadjuvant therapy.
Benefits-harm assessment	Balance of benefits and harms.
Value judgments	The stage of tumor at presentation and the goals of the patient with respect to orbit preservation should be carefully considered. It is important to consider that negative margin resection remains the primary goal with most cases of SNSCC.
Policy level	Option.
Intervention	Patients with locally advanced disease (i.e., orbit or intracranial invasion) may have benefit from neoadjuvant chemotherapy. Response to neoadjuvant chemotherapy offers prognostic information.

b | Role of surgery

While there is emerging evidence for nonsurgical treatment protocols, surgical resection of SNSCC remains the mainstay of treatment. Traditionally, SNM, including SNSCC, amenable to surgical resection necessitated an open approach. However, with the advancement of endonasal techniques over the past three decades, treat-

ment of diverse sinonasal pathologies, including aggressive malignancies such as SNSCC, via an endoscopic approach has become more widely accepted. Regardless of surgical approach, the literature is uniformly in agreement regarding the importance of negative surgical margins. Unlike SCC at other subsites within the head and neck, however, there are no clear recommendations regarding margin size for SNSCC. This is due to both lack of data and the impracticality of achieving wide margins (i.e., 1 cm) for the vast majority of SNSCC tumors. In an NCDB review of 7808 patients with SNSCC, when compared to patients with SNSCC treated nonsurgically, propensity score-matched results demonstrated improved OS in surgical patients with negative surgical margins and micro-positive surgical margins ($p < 0.001$), but patients with macro-positive surgical margins did not demonstrate improvement ($p = 0.20$).¹⁶¹

In a 2018 NCDB review of 1483 patients with SNSCC without regional or distant metastasis treated between 2010 and 2014, Kilic et al. compared outcomes of the endoscopic approach to outcomes of the open approach. Of the 1483 patients identified, 353 (25.8%) were treated with an endoscopic approach and 1130 (76.2%) were treated with an open approach. Propensity score matching was utilized, and there was no significant difference in 5-year OS between the two groups.¹³⁵

This is further corroborated by several retrospective case series, which have reported comparable long-term outcomes and survival rates between endoscopic and open approaches for both SNM in general and specifically for SNSCC.^{316,1084-1086} In a retrospective review of 43 patients with SNSCC, Nicolai et al. report an overall recurrence rate of 16.2% (7/43), with a 12% (3/25) recurrence rate reported in patients treated via endoscopic approach and a 22.2% (4/18) recurrence rate reported in patients treated via an open approach.³¹⁶ Similarly, in a retrospective review of 21 patients with SNSCC who underwent endoscopic resection, Luong et al. report an overall recurrence rate of 24% (5/21). However, 57% (12/21) of this patient cohort had T4 disease.¹⁰⁸⁶ More recently, a retrospective review of 15 patients with SNSCC who underwent endoscopic resection, none of whom had T4 disease, identified a 5-year OS of 72.4%, DSS of 79.6%, and LRC rate of 92.9%.¹⁴⁰

These results are supported by two large position papers—the EPOS on Endoscopic Management of Tumours of the Nose, Paranasal Sinuses, and Skull Base from 2010⁶ and the more recently published ICSB 2019.⁵ Within the EPOS, a systematic review concluded that the DFS between patients treated via either endoscopic or open approach was comparable but depended on the completeness of resection.⁶ Similarly, the ICSB concluded that endoscopic and open resection of SNSCC had similar

TABLE XXI.A.1 Evidence for induction chemotherapy in the treatment of SNSCC.

Study	Year	LOE	Study design	Study groups	Clinical endpoints	Conclusion
Abdelmeguid et al. ¹⁰⁷⁷	2021	3	Retrospective cohort	123 patients with previously untreated, locoregionally advanced SNSCC	1. Response 2. Recurrence 3. Organ preservation 4. Survival	1. High percentage of patients had favorable response to induction chemotherapy 2. Response to induction chemotherapy is associated with an improved outcome and good chance of organ preservation
Ock et al. ¹⁰⁷⁹	2016	4	Retrospective case series	21 patients with SNSCC	1. Response rate 2. Orbit preservation rate 3. OS	Induction chemotherapy should be considered for orbit preservation and for downstaging T stage
Noronha et al. ¹⁰⁷⁵	2014	4	Retrospective case series	41 patients with unresectable SCC of the maxillary sinus treated between 2008 and 2011	1. Response and toxicity to chemotherapy 2. Definitive treatment received 3. PFS 4. OS	In unresectable SCC of the maxillary sinus, induction chemotherapy has minimal toxicity and clinical benefits
Hanna et al. ¹⁰⁷⁶	2011	4	Retrospective case series	46 patients with unresectable SNSCC	Oncologic outcomes	Better patient survival and possible organ preservation may occur when there is favorable response to induction chemotherapy
Kim et al. ¹⁰⁷⁴	2000	4	Matched-control study	34 patients with unresectable SCC of the maxillary sinus	1. Response rate 2. Patterns of failure 3. Toxicity 4. Survival	Combined therapies (neoadjuvant chemotherapy + RT) did not demonstrate advantage over RT alone

Abbreviations: OS, overall survival; PFS, progression-free survival; RT, radiation therapy; SCC, squamous cell carcinoma; SNSCC, sinonasal squamous cell carcinoma.

oncologic outcomes, with an aggregate grade of evidence of C.⁵

In conclusion, endoscopic resection of SNSCC seems to have comparable oncologic outcomes to open resection. However, a critical factor affecting survival regardless of surgical approach is margin status. The surgical approach that confers the greatest degree of tumor resection and allows the best opportunity for negative margins should be selected on a case-by-case basis, and if negative margins are unachievable, nonsurgical treatment should be considered.

c | Role of adjuvant therapy

The most common treatment regimen for SNSCC, particularly for advanced-stage tumors (pT3-T4, and most pT2), remains surgery followed by adjuvant RT.³⁰ There is little evidence to support single-modality or dual-modality treatment for T1 SNSCC tumors, as the data are limited. There is some evidence that some histologic subtypes, such as nonkeratinizing SNSCC, may be particularly radiosens-

sitive, further supporting the role of adjuvant therapy in these cases.²³¹

Traditionally, IMRT using photons has been the preferred modality. The contralateral nodal basin is considered in tumors with midline and bilateral involvements and considered on a case-by-case basis.²³¹ More recently, intensity modulated particle therapy (IMPT) has been used in an adjuvant setting in the treatment of SNSCC. IMPT offers several theoretical advantages over photon therapy including a sharp dose gradient, high linear energy transfer, and relative independence of tissue oxygenation. These advantages are theoretically beneficial in areas adjacent to radiosensitive structures such as the skull base. In a series of 54 patients with SNSCC, 37 of which underwent postsurgical IMPT and 24 of which underwent IMPT in combination with induction, concurrent, or adjuvant chemotherapy, there were 10 cases of local recurrence, seven cases of regional recurrence, and 11 cases of distant failure. The overall 2-year survival was 67%, while the overall 5-year survival was 47%. Toxicities were considered

acceptable by the authors, with nine grade 3 and six grade 4 toxicities reported.⁵²⁸ The time to initiation of postoperative RT is critical. In an NCDB review of SNSCC patients, a shorter postoperative time to radiotherapy was associated with increased OS. This is estimated to be at approximately 61 days.¹⁰⁸⁷

Evidence for postoperative CRT is extrapolated from the head and neck SCC literature. Positive resection margins or extra-nodal extension are considered indications for platinum-based concurrent chemotherapy. Additionally, in the presence of high-risk features such as high-grade tumors, close resection margins, and nodal metastasis, concurrent chemotherapy may be considered.^{1088,1089} Review of articles regarding the role of adjuvant therapy can be found in Table XXI.A.2.

Role of adjuvant therapy in sinonasal SCC

Aggregate grade of evidence	C (Level 4: four studies)
Benefit	Surgery followed by postoperative RT demonstrates improved LRC and OS compared to patients treated with definitive RT/CRT or surgery alone.
Harm	Associated with treatment-specific toxicities.
Cost	Insufficient data to make recommendation regarding long-term costs of adjuvant therapy.
Benefits-harm assessment	Preponderance of benefits over harms.
Value judgments	The stage of tumor at presentation, the specific histologic subtype, and the goals of the patient should be carefully considered.
Policy level	Recommendation.
Intervention	Patients with locally advanced disease or poorly differentiated histologies would benefit from postoperative RT. The role of CRT is not clearly defined specifically for SNSCC but should be considered when positive margins or extranodal extension is present.

d | Role of definitive chemoradiotherapy

Although upfront surgery followed by adjuvant RT has been associated with improved survival outcomes in the treatment of SNSCC, definitive CRT/RT can be considered for patients who have unresectable tumors, are not candidates for surgery or chemotherapy, or have early-stage tumors. Chemotherapy is generally platinum based, and IMRT and IMPT are the two most common radiotherapy options. Definitive CRT has been shown to have similar OS compared to single-modality therapy with surgery, but

worse outcomes compared to triple-modality therapies and treatment protocols with neoadjuvant therapy.¹⁵⁹

Homma et al. are currently conducting a prospective trial investigating the use of intra-arterial high-dose cisplatin with concomitant RT for advanced maxillary sinus cancers (T4a/bN0M0). They published the outcomes of 18 patients for their dose-finding phase in 2018 and reported that seven cycles of intra-arterial high dose cisplatin were clinically safe and their recommended cycle number. Further data are expected as they complete their studies.¹⁰⁹⁰

There may be a role for immunotherapy/targeted therapy in definitive RT. Qiu et al. showed that definitive RT in combination with immunotherapy/targeted therapy (cetuximab) demonstrated improved OS, objective response, and PFS compared to RT alone.¹⁰⁹¹

In 2018, Toyomasu et al. published a series describing the use of IMPT monotherapy in 59 cases of SNSCC. This represents the largest series to date. The majority of their patient cohort (70%) were classified to have T4 disease. They report comparable outcomes with other treatment modalities. Their reported 5-year OS, PFS, and LRC rates are 41.6%, 34.7%, and 50.4%, respectively. They report a grade 3 or 4 toxicity rate in 22% of patients.⁵⁵⁹ Mimica et al. report IMPT as an option for organ preservation for patients with nasal cavity/septum SCC that declined rhinectomy. Seven of the 11-patient cohort was treated with primary IMPT with concurrent chemotherapy, the rest were treated with IMRT ± chemotherapy. They report a 2-year survival rate of 100% and only one out of seven (14%) patients who underwent IMPT had local recurrence.¹⁰⁹²

In particular, the role of definitive CRT/RT in the treatment of early-stage SNSCC is not clearly defined. NCCN guidelines support definitive CRT/RT for T1 and T2 ethmoid and nasal cavity SCC; however, there are no trials evaluating this recommendation.

Role of definitive chemoradiotherapy in sinonasal SCC

Aggregate grade of evidence	C (level 4: four studies)
Benefit	In cases of unresectable tumors, nonsurgical therapies offer an alternative to palliative treatments. Additionally, in early-stage cancers, nonsurgical therapy may confer equivalent outcomes as compared to surgery ± adjuvant therapy.
Harm	There are systemic and local toxicities related to nonsurgical therapies.

(Continued)

TABLE XXI.A.2 Evidence for the role of (chemo)radiotherapy in the treatment of SNSCC.

Study	Year	LOE	Study design	Study groups	Clinical endpoints	Conclusion
Ackall et al. ⁴¹⁴	2021	4	Retrospective database review (NCDB)	1074 patients with SNSCC; 15.5% surgery alone, 25.2% RT alone, 16.5% definitive CRT, 13.9% surgery + adjuvant CRT, 24.4% surgery + adjuvant RT	OS	1. Surgery followed by adjuvant RT had improved OS compared to surgery alone
Toyomasu et al. ⁵⁵⁹	2017	4	Retrospective case series	59 patients with SNSCC treated with IMPT; 70% with T4 disease	1. PFS 2. OS	5-year PFS 34.7% and OS 41.6%
Robin et al. ¹⁵⁹	2017	4	Retrospective database review (NCDB)	6039 patients with SNSCC; RT alone versus chemotherapy alone, surgery + adjuvant RT, surgery alone	1. OS	1. RT and chemotherapy alone had worse OS than surgery + RT 2. OS did not differ between definitive CRT and surgery alone 3. Neoadjuvant RT was associated with improved OS
Kim et al. ¹¹⁰⁵	2015	4	Retrospective case series	30 patients with SNSCC; 50% surgery + adjuvant therapy (adjuvant cohort), 50% primary CRT (definitive cohort)	1. LRC 2. OS	1. Adjuvant cohort: 5-year 58% LRC rate and 55% OS 2. Definitive cohort: 5-year 55% LRC rate and 53% OS

Abbreviations: LRC, local–regional control; OS, overall survival; PFS, progression-free survival; RT, radiation therapy; SNSCC, sinonasal squamous cell carcinoma.

Cost	Insufficient data to make recommendation regarding long-term costs of adjuvant therapy.
Benefits–harm assessment	Balance of benefits and harms.
Value judgments	Definitive CRT/RT could be considered in the setting of unresectable tumors, for patients who are poor surgical and chemotherapy candidates, and in patients who decline surgery. Additionally, for early-stage tumors, definitive CRT/RT can be considered, although there are limited studies evaluating this.
Policy level	Option.
Intervention	Patients with unresectable or early-stage disease, patients who are poor surgical candidates, and patients who do not desire surgery may be considered for definitive CRT/RT.

e | Management of the neck

Nodal involvement of SNSCC at the time of presentation is rare. This is thought to be due to a paucity of lymphatic drainage pathways. One drainage pathway runs from the

maxillary gingiva to the submandibular nodes through the buccal nodes, while another drainage pathway runs from the nasal floor to the upper jugular nodes through the retropharyngeal and parapharyngeal nodes.¹⁰⁹³ In a review of 6448 cases of SNSCC from the NCDB, nodal metastasis was seen in 13.2% of patients at the time of presentation.⁴² However, subsite of tumor origin is critical—as initial nodal involvement rate for nasal cavity SCC was only 9.3%, while maxillary sinus SCC was 20.7% in a large meta-analysis of 1283 patients with SNSCC.¹⁰⁹⁴ Ultimately, it is estimated that up to one third of patients may develop nodal disease during the course of follow-up, which confers worse prognosis.¹⁰⁹⁵

While the recommended management of a clinically positive neck is surgery if the initial management of the primary tumor is also surgery, the management of the cN0 neck is not clearly defined. The decision to adopt watchful waiting of the neck or to perform elective treatment—whether it be in the form of neck dissection or neck radiation—has been understudied. In a systematic review of 26 articles encompassing 1320 patients with sinonasal carcinoma, Galloni et al. identified 1178 cases of cN0 patients. Of these, 407 patients underwent elective neck

treatment, while 771 patients were observed. Of the 771 patients observed, there was a 34.6% rate of regional recurrence (140/771), while of the patients who underwent elective neck treatment at the time of initial therapy, there was only a 5.9% rate of regional recurrence (24/407). The ORs for regional recurrences after elective neck treatment ranged from 0.03 to 1.39. The cumulative OR was 0.38, indicating a 62% lower risk of regional recurrence in patients undergoing elective neck treatment compared to patients who were observed in follow-up. However, relevant limitations of this study include broad histologies included and no interpretation of impact on outcomes.¹⁰⁹⁵

In a population-based, concurrent retrospective SEER database analysis of 927 patients with N0M0 SNSCC of the maxillary sinus between 2004 and 2013, Sangal et al. conclude that elective neck dissection (END) significantly and independently reduces the 5-year hazard of death (HR 0.646, $p = 0.047$). They found that for T1, T2, and T4 tumors, END did not independently improve 5-year survival, but for T3 maxillary sinus SNSCC, END did significantly reduce the 5-year hazard of death (HR 0.471, $p = 0.001$).¹⁰⁹⁶ Likewise, in a 2014 meta-analysis of N0M0 maxillary sinus SCC, Abu-Ghanem et al. show that ENI significantly reduces the risk of regional recurrence compared to observation (OR 0.16, $p = 0.01$).¹⁰⁹⁷ This was similarly concluded by Le et al. in a review of 97 patients with maxillary sinus malignancy, of which 58 were SCCs. They found a statistically significant difference with respect to nodal recurrence between the 36 patients who received RT (25 cN0) and those who did not receive neck radiation (0% and 20%, respectively).¹⁰⁹⁸

Dooley and Shah reviewed the role of elective neck treatment for N0M0 patients with maxillary sinus SCC and found the rate of isolated neck failure to be between 4% and 17%. More commonly, recurrence in the neck was accompanied by local recurrence or distant metastatic spread, both of which are unlikely amenable to salvage therapy. They did find that T3 and T4 primary tumors were more likely to involve the neck, and therefore argue that, while elective neck treatment is not justified for T1 and T2 SCC of the maxillary sinus, it may be considered for T3 and T4 disease.¹⁰⁹³ Contrarily, Cantu et al. report the rate of neck metastasis to be higher for T2 tumors than for high “T” stage tumors, and therefore elective neck treatment should be considered for T2N0 SNSCC but is not indicated in T3 and T4N0 patients.¹⁰⁹⁹

There is also evidence that elective neck treatment may not improve oncological outcomes. Crawford et al. in a retrospective study of 1220 patients from the NCDB with T3/4 cN0 SNSCC reported no statistically significant difference in OS with END. A total of 19.6% of their patient cohort underwent END, and there was an occult metastases rate

of 12.7%.¹¹⁰⁰ However, DFS and recurrence data were not reported.

In a Triological Society Best Practice summary from 2019 specifically for maxillary sinus SCC, Berger et al. draws attention to heterogenous evidence and conclusions with a lack of prospective trials. Despite this, existing database and retrospective evidence suggest that elective neck treatment may be appropriate for higher T stage SCC, and if the neck is to be entered for resection or reconstruction purposes, END should be strongly considered for T3 and T4 tumors.¹¹⁰¹

It is additionally important to consider the extent of elective neck treatment. In a review of 128 patients with T4 SCC of the maxillary sinus, of those with regional metastasis at the time of diagnosis, 96% had ipsilateral upper jugulodigastric and submental disease. However, lower jugular chain, contralateral node, and retropharyngeal node involvement is also reported.¹¹⁰² The latter is not easily accessible by surgery and consideration should be given to extending radiotherapy coverage of the primary tumor to include the retropharyngeal node, regardless of if or how the lateral neck is treated. Review of articles regarding elective neck treatment can be found in Table XXI.A.3.

Elective management of the N0 neck in sinonasal SCC

Aggregate grade of evidence	C (Level 2: two studies, Level 3: two studies; Level 4: two studies)
Benefit	Elective neck treatment may decrease the rate of regional recurrence.
Harm	There are morbidities associated with elective neck treatment, both for surgical treatment and elective irradiation.
Cost	Insufficient data to make recommendations regarding long-term costs of elective neck treatment.
Benefits-harm assessment	Balance of benefits and harms.
Value judgments	Patient with advanced T stage tumors may benefit from elective neck treatment. Maxillary sinus SCC has a higher risk of neck metastasis than nasal cavity SCC.
Policy level	Option.
Intervention	Strong consideration should be given to elective neck treatment in cases of advanced T-stage tumors, especially if it is a maxillary sinus primary and if primary surgery is undertaken. Elective treatment may be in the form of elective irradiation or END.

TABLE XXI.A.3 Evidence for elective neck treatment in the management of SNSCC.

Study	Year	LOE	Study design	Study groups	Clinical endpoints	Conclusion
Galloni et al. ¹⁰⁹⁵	2021	2	Systematic review and meta-analysis	1178 cN0 sinonasal carcinoma; 407 elective neck treatment, 771 observed (encompassing 26 studies)	Regional recurrence	34.6% regional recurrence in observation group versus 5.9% regional recurrence in elective neck treatment group
Abu-Ghanem et al. ¹⁰⁹⁷	2014	2	Systematic review and meta-analysis	129 total patients with N0M0 SNSCC maxillary sinus (encompassing four studies)	Regional recurrence	Elective neck irradiation significantly reduces risk of regional recurrence compared to observation (OR 0.16, $p = 0.01$)
Crawford et al. ¹¹⁰⁰	2020	3	Retrospective cohort	1220 patients with T3/T4 cN0 SNSCC; 19.6% underwent END	OS	No OS benefit with END in T3/T4 cN0 SNSCC
Sangal et al. ¹⁰⁹⁶	2018	3	Retrospective cohort	927 N0M0 SNSCC maxillary sinus; 146 with ENDS	OS	T3 tumors and >4 cm require END
Cantu et al. ¹⁰⁹⁹	2008	4	Retrospective case series	156 patients with SNSCC	Regional recurrence	Consider neck dissection in maxillary sinus T2
Le et al. ¹⁰⁹⁸	2000	4	Retrospective case series	58 patients with SNSCC of maxillary sinus, 25 cN0	Regional recurrence	Those that did not receive neck radiation were more likely to recur (0% vs. 20%)

Abbreviations: OS, overall survival; SNSCC, sinonasal squamous cell carcinoma.

f | Role of immunotherapy

In SNSCC, local recurrence is the main mode of treatment failure.⁴¹⁸ Due to the rarity of SNSCC, and even greater rarity of recurrences, optimal management of locally recurrent SNSCC is not well studied. Locoregional recurrence and distant metastasis may be treated with systemic therapy. There is emerging evidence that systemic immunotherapy (with nivolumab or pembrolizumab) may have an important role as treatment alternatives in the setting of unresectable recurrent or metastatic SNSCC.²³¹ While there are little data currently available, Riobello et al. demonstrate that 45% of immune infiltrating SNSCC cells express PD-L1, indicating a potential benefit of immunotherapy.¹¹⁰³ Additionally, in an analysis of tumor-infiltrating lymphocytes (TILs) on 57 samples of SNSCC, Garcia-Marin et al. found that a high level of intratumor CD8 TILs correlated with worse survival. Again, this result suggests SNSCCs are immunogenic tumors, and these patients may benefit from immune checkpoint inhibitor immunotherapies.¹¹⁰⁴

Despite advances in multimodality therapy and evidence for survival benefit with treatment at high volume centers, the overall prognosis is still poor.¹⁰⁸⁰ In a recent meta-analysis of 41 studies reporting on outcomes of SNSCC, the aggregate 5-year OS was 54.5% with a recur-

rence rate of 42.7% and an aggregative 5-year LRC rate of 42.7%.¹⁰⁶³ Despite this, emerging therapies and better understanding of tumor biology may shift treatment paradigms and improve long-term oncologic outcomes.

B | Inverted papilloma-transformed squamous cell carcinoma

1 | Survival outcomes of IP-SCC versus DN-SCC

Sinonasal IP most commonly affects the maxillary sinus, lateral nasal wall, sphenoid, ethmoid, and frontal sinuses, while uncommonly affecting the nasopharynx, Eustachian tube and middle ear, and lacrimal sac.^{130,247,1106–1117} It is not uncommon to have more than one contiguous site involved, representing multifocal and/or bilateral disease. Tumors tend to grow to large sizes (average 4 cm), described as papillary, polypoid, and sessile in appearance.^{130,1112,1117–1120} Due to large size and extension, tumors often present with a high pathologic or clinical T stage. Accordingly, the symptoms associated with a large space-occupying mass mimic other benign processes, such as nasal polyps, which may delay proper diagnosis and

treatment. The unique characteristics of IP are discussed previously in this consensus statement, and the focus of this section is on malignant transformation of IP. The overall incidence of identifying IP-transformed SCC (IP-SCC) accounts for 2%–10% of all IP cases, with synchronous lesions much more likely to develop than metachronous ones.^{247,653,1107–1109}

There is evidence to suggest that IP-SCC carries a more favorable prognosis compared to de novo SCC (DN-SCC, or primary sinonasal SCC not arising from pre-existing IP).^{1110–1112,1121} A recent meta-analysis has found that patients with DN-SCC carry a 1.87-fold increased risk of mortality with 5-year OS of 56%, compared to 65% for patients with IP-SCC.¹¹¹³ Despite the improved reported survival, IP-SCC patients often present with locally advanced tumors (74% with T3/T4 stage disease), and 23.8% cases experienced a recurrence despite similar treatment to DN-SCC.¹¹¹⁴ It should be noted that most studies are limited by sample size, heterogeneity in tumor origin, clinical stage, and treatment modalities. Furthermore, the significance of the findings is most vulnerable to the studies' respective methodology in classifying the subjects into their respective cohorts. IP, and by extension, IP-SCC, is defined histologically. To date, there is no defined set of molecular markers to distinguish IP-SCC from DN-SCC. Accurate classification of IP-SCC requires presence of benign IP in cases with carcinoma (synchronous lesions) or history of IP by report (metachronous lesions). Efforts to further characterize these tumors by molecular pathways should take precedence, with large multicenter studies required to validate historic findings (Table XXI.B.1).

Aggregate grade of evidence: C (Level 4: eight studies)

2 | Imaging to predict malignant transformation

Recently, noninvasive techniques, such as preoperative radiographic imaging, have been studied that better predict the presence of IP-SCC. Focal hyperostosis on CT scans has been correlated with tumor origin and site of attachment, and bony erosion is indicative of aggressive tumor.^{711,1120} In addition, unique characteristics identified in MRI have been used to better differentiate IP from IP-SCC. Benign IPs demonstrate a distinct morphologic pattern on MRI known as convoluted cerebriform pattern (CCP), which is appreciated as alternating hypo- and hyperintense bands on T2-weighted and contrast-enhanced T1-weighted imaging.^{709,1122} Currently, a few studies suggest that CCP may be beneficial in distinguishing IP from IP-SCC.^{1123–1126} Specifically, there appears to be an overall loss of CCP among IP-SCC, with most tumors

demonstrating either partial or near-complete absence (Table XXI.B.2). The obvious limitation in making diagnoses based on CCP is that it is subject to interpretation error. A more objective analysis utilizes ADC value, and it has been found that malignant sinonasal neoplasms have lower mean ADC values.^{1127,1128} ADC map generation from diffusion-weighted MRI (DW-MRI) images requires additional image analysis software, but current evidence supports its potential role in developing a predictive model for IP-SCC.

Aggregate grade of evidence: C (Level 4: six studies)

3 | Histopathology and molecular and genetic studies

IP shows an inverted (endophytic), nondestructive growth into the underlying stroma, enclosed by an intact basement membrane. Benign areas may be concurrently present with zones of malignant tumor, showing considerable volume variation between cases. IP is cytologically bland, shows normal maturation and polarization, may have koilocytic atypia, and contains intraepithelial mucous cysts filled with mucin and cellular debris, with prominent transmigrating intraepithelial neutrophils. Areas of dysplasia may develop as a precursor to malignant transformation.^{653,1129} Hyperkeratosis, increased basaloid morphology, conspicuous pleomorphism, and increased mitoses, including atypical forms, with loss of transepithelial neutrophils signal malignant transformation. Carcinomas include nonkeratinizing, keratinizing, and low-grade papillary subtypes, and even SNUCs.^{653,664,666,1130–1134} Keratinizing carcinoma may appear as verrucous carcinoma, although most keratinizing carcinoma are represented as well, moderately, or poorly differentiated. Recognized as a gradient without any absolute morphologic cutoffs, it is important to stress the volume of the neoplastic tissue (i.e., significantly more epithelium than stroma) and the pleomorphism, destructive growth, and atypical mitoses that define carcinoma, without any one feature alone being sufficient. Other malignant features include destructive bone invasion, paradoxical basal maturation, and true tumor comedonecrosis.^{648,653,666,667,1135} True invasion is seldom identified, but when there is a desmoplastic reaction, loss of basement membrane, single cell infiltration, irregular, stellate islands of neoplastic cells, and destructive bone/cartilage invasion, definitive traditional invasion can be confirmed. p53 may be abnormally overexpressed, but a completely negative reaction can also be seen.^{655,1136} There is no Ki-67 proliferation index cutoff for diagnosing carcinoma.⁶⁵³ p16 may be positive, but few cases show transcriptionally active high-risk HPV by in situ RNA hybridization.^{653,655,657,666,667,1137}

TABLE XXI.B.1 Evidence for outcomes for IP-SCC versus DN-SCC.

Study	Year	LOE	Study design	Study groups	Clinical endpoints	Conclusion
Li et al. ¹¹¹⁹	2021	4	Retrospective case series	DN-SCC (<i>n</i> = 84), IP-SCC (<i>n</i> = 89)	1. OS 2. DFS 3. Distant metastasis	1. DN-SCC 5-year OS 55.4%, DFS 50.1%; IP-SCC 5-year OS 63.3%, DFS 45.4% 2. Metachronous tumors had better prognosis than synchronous tumor and DN-SCC 3. DN-SCC demonstrated increased incidence of distant metastasis
Yasumatsu et al. ¹¹¹⁷	2020	4	Retrospective case series	DN-SCC (<i>n</i> = 94), IP-SCC (<i>n</i> = 23)	1. DSS 2. Recurrence rates	1. No significant difference in DSS in T1, T2, and T3 tumors 2. T4 DN-SCC had better DSS than those with IP-SCC
Quan et al. ¹¹¹⁸	2020	4	Retrospective case series	DN-SCC (<i>n</i> = 123), IP-SCC (<i>n</i> = 39)	1. OS 2. DFS 3. Local failure rate 4. Nodal failure rate 5. Distant metastasis	1. No significant difference in OS or DFS 2. Similar survival outcomes; IP-SCC had a higher local failure rate
Yu et al. ¹¹¹⁵	2017	4	Retrospective case series	DN-SCC (<i>n</i> = 65), IP-SCC (<i>n</i> = 21)	1. OS 2. DSS	1. DN-SCC 5-year OS 39.5%, DSS 52.8% 2. IP-SCC 5-year OS 58.3%, DSS 61.5%
Yan et al. ¹¹¹⁰	2017	4	Retrospective case series	DN-SCC (<i>n</i> = 28), IP-SCC (<i>n</i> = 38)	1. OS 2. DSS	1. DN-SCC 5-year OS 69%, DSS 72.9%; IP-SCC 5-year OS 84.6%, DSS 89.6% 2. Early-stage IP-SCC had better DSS than DN-SCC
Lobo et al. ¹¹¹⁶	2017	4	Retrospective case series	DN-SCC (<i>n</i> = 88), IP-SCC (<i>n</i> = 29)	1. OS 2. DFS	1. DN-SCC 5-year OS 65.8%, DFS 60.3% 2. IP-SCC 5-year OS 77%, DFS 62.6%
de Almeida et al. ¹³⁰	2015	4	Retrospective case series	DN-SCC (<i>n</i> = 21), IP-SCC (<i>n</i> = 13)	1. OS 2. DFS	1. DN-SCC 5-year OS 75.1%, DFS 62%; IP-SCC 5-year OS 86%, DFS 62% 2. IP-SCC has no prognostic significance
Lavertu et al. ¹¹¹¹	1989	4	Retrospective case series	DN-SCC (<i>n</i> = 43), IP-SCC (<i>n</i> = 11)	OS	1. DN-SCC 5-year OS 29.8% 2. IP-SCC 5-year OS 70%

Abbreviations: DFS, disease-free survival; DN-SCC, de novo squamous cell carcinoma; IP-SCC, inverted papilloma associated squamous cell carcinoma; OS, overall survival.

The majority of IP-SCCs harbor *EGFR* mutations; these activating mutations are typically frame-preserving exon 20 indels, but exon 6 and exon 19 mutations have also been reported.^{659,660,672,1131,1138} *EGFR* exon 20 mutations have described in minor subsets of lung adenocarcinoma, glioma, and urothelial carcinoma but are otherwise rare in human malignancies.⁶⁵³ As such, the presence of an *EGFR* exon 20 mutation in a sinonasal carcinoma is essentially diagnostic of IP-SCC, even without clin-

ical or pathologic evidence of IP, and molecular-based estimates suggest that IP-SCC represent 15%–30% of all sinonasal SCC.^{672,1138,1139} Tumors without *EGFR* mutations usually demonstrate low-risk HPV infection, and high-risk HPV infection is uncommon (or not observed) in contemporary IP-SCC cohorts with expert pathology review.^{660,662,666,667,672,1138} Shared *EGFR* mutations or low-risk HPV genotypes are present in the associated metachronous or synchronous IP, indicating that IPs are

TABLE XXI. B. 2 Evidence for preoperative imaging in distinguishing IP-SCC from IP.

Study	Year	LOE	Study design	Study groups	Clinical endpoints	Conclusion
Suh et al. ¹¹²⁶	2021	4	Retrospective case series	Biopsy-proven IP (<i>n</i> = 41), IP-SCC (<i>n</i> = 21)	1. Loss of CCP 2. Bone Erosion 3. ADC	IP: 1. 85% demonstrated CCP, 10% with partial loss, 5% with complete loss. 2. 34% demonstrated bone erosion on CT. IPSCC 1. 5% demonstrated CCP, 48% with partial loss, 48% with complete loss. 2. 91% demonstrated bone erosion on CT. 3. Mean ADC is lower in IP-SCC (1.20 vs. 1.51, <i>p</i> < 0.001) 4. Conventional imaging features (CT, MRI) with ADC values can predict IP-SCC
Yan et al. ¹¹²⁴	2019	4	Retrospective case series	Biopsy-proven IP (<i>n</i> = 30), IP-SCC (<i>n</i> = 35)	1. Loss of CCP 2. Bone Erosion 3. ADC	IP: 1. 60% demonstrated CCP, 26.7% with partial loss, 13.3% with complete loss. 2. 28.2% demonstrated bone erosion on CT. IP-SCC: 1. 17.1% demonstrated CCP, 22.9% with partial loss, 60% with complete loss. 2. 74.2% demonstrated bone erosion on CT. 3. Mean ADC is lower in IP-SCC (1.12 vs. 1.49, <i>p</i> = 0.002)
Miyazaki et al. ¹¹²⁰	2018	4	Retrospective case series	Biopsy-proven IP (<i>n</i> = 64), IP-SCC (<i>n</i> = 6)	Bone destruction on CT	IP-SCC is associated with bone destruction on CT (<i>p</i> < 0.001)
Fujima et al. ¹¹²⁵	2015	4	Retrospective case series	Biopsy-proven IP (<i>n</i> = 5), IP-SCC (<i>n</i> = 3), DN-SCC (<i>n</i> = 33)	Loss of CCP	1. CCP is detected at a high rate in IPs 2. All IPs and IP-SCCs demonstrated CCP 3. Only five DN-SCCs (15.2%) demonstrated CCP Note: study did not subcategorize partial or complete loss of CCP
Jeon et al. ¹¹²³	2008	4	Retrospective case series	Biopsy-proven IP (<i>n</i> = 22), IP-SCC (<i>n</i> = 8)	Loss of CPP	1. All IPs demonstrated diffuse CCP 2. Half (50%) of IP-SCCs demonstrated diffuse CCP, with the other half with partial or focal loss of CCP 3. Partial CCP can be indicative of IP-SCC

(Continues)

TABLE XXI.B.2 (Continued)

Study	Year	LOE	Study design	Study groups	Clinical endpoints	Conclusion
Ojiri et al. ¹¹²²	2000	4	Retrospective case series	Biopsy-proven IP, previously untreated (<i>n</i> = 10)	Loss of CPP	<ol style="list-style-type: none"> 1. Co-existing SCCs demonstrate distinctive imaging finding (partial or absent CCP) 2. CCP present in eight tumors (80%) 3. One tumor contained microscopic IP-SCC 4. Partial CCP detected in two tumors that contained IP-SCC

Abbreviations: ADC, apparent diffusion coefficient; CCP, convoluted cerebriform pattern; DN-SCC, de novo squamous cell carcinoma; IP-SCC, inverted papilloma associated squamous cell carcinoma; OS, overall survival.

clonal precursor lesions to IP-SCC.^{659,667} In contrast to IP, *TP53* and/or *CDKN2A* mutations/deletions are present in the majority of IP-SCC, while *NFE2L2* and *PIK3CA* mutations and *EGFR*, *TERT*, *SOX2*, *CCND1*, *MYC*, and *FGFR1* amplifications have been reported in subsets of cases.^{660,1138} IP-SCC shows high expression of genes associated with epithelial–mesenchymal transition and extracellular matrix remodeling.¹¹⁴⁰ Preclinical models of IP-SCC with *EGFR* exon 20 mutations demonstrate endogenous *EGFR*, *MAPK*, and *PI3K/AKT* pathway activity and responsiveness to irreversible *EGFR* inhibitors (e.g., neratinib, afatinib, dacomitinib) in vitro.⁶⁵⁹ Table XXI.B.3 summarizes evidence surrounding histopathologic studies and molecular pathogenesis of IP-SCC.

Aggregate grade of evidence: C (Level 2: one study; Level 3: five studies; Level 4: six studies)

XXII | MINOR SALIVARY GLAND TUMORS OF THE SINONASAL TRACT

A | Intestinal-type adenocarcinoma

The 5th edition of the WHO Classification of Head and Neck Tumors classifies sinonasal adenocarcinomas of surface epithelial origin (nonsalivary-type adenocarcinomas) in intestinal and nonintestinal types.¹⁷ ITAC is one of the most common sinonasal cancers, especially in European countries.¹¹⁴¹ The typical site of origin is the ethmoid, often arising from the olfactory cleft.¹¹⁴² The correlation between sinonasal ITAC and occupational exposure is well known.¹¹⁴³ The most important risk factor is exposure to hardwood dusts, such as beech or oak, followed by products from the textile industry and leather dusts.^{39,1144} The current staging system for sinonasal ITAC follows the AJCC TNM classification of nasal cavity and paranasal sinuses cancers (8th edition), which has been demonstrated to stratify patients according to prognosis.^{16,158,1144}

However, the propensity of ITAC to present at a locally advanced stage supports the need for a more personalized approach to cancer staging, since different prognostic patterns are recognizable even within the pT4a (anterior wall of the sphenoid involvement vs. lateral or posterior sphenoid walls invasion) and the pT4b groups (focal dural invasion vs. massive dura and cerebral extension or leptomeningeal spread).^{1145,1146}

1 | Tumor subtypes and grade

From a histological perspective, ITAC resembles primary adenocarcinoma arising from the intestinal mucosa and consists of proliferation of dysplastic columnar cells with interspersed goblet cells forming papillae and glands. In an attempt to stratify patients according to prognosis, several histologic features have been considered over the years. Historically, Barnes classified ITACs into five subtypes: papillary (18%), colonic (40%), solid (20%), mucinous (14%), and mixed (8%).¹¹⁴⁷ A few years later, Kleinsasser and Schroeder divided ITACs into four subtypes: papillary-tubular cylinder cell, which was further graded from I to III; alveolar goblet; signet-ring cell; and transitional.^{1148,1149} The signet-ring cell subtype represents the ITAC subtype associated with the worst prognosis.¹⁷ In addition to morphologic subtypes, the histological grade of differentiation (well, moderately, and poorly differentiated) can be associated with prognosis, with poorly differentiated ITAC being the most aggressive subtype and more prone to local and distant relapse.^{362,1150} Recent evidence also suggests that *P53* could play a role in disease behavior and response to treatment, with *P53* status on pretreatment biopsy used to determine treatment strategy.²⁹³ In ITACs with functional *P53* (58% of cases), including both the wild-type and the mutated protein with function preservation or gain, neoadjuvant chemotherapy with cisplatin, 5-fluorouracil, and leucovorin (PFL) resulted in complete response in

TABLE XXI. B. 3 Evidence for HPV, molecular markers, and genetic studies in IP, IP-SCC, and DN-SCC.

Study	Year	LOE	Study design	Study groups	Clinical endpoints	Conclusion
Lawson et al. ⁶⁵⁷	2008	2	Systematic review	887 cases	HPV detection rates	<ol style="list-style-type: none"> 1. HPV detection varies widely 2. Similar detection rates across methods (26.8%, 25.2%, 23.6%) 3. HPV more often detected in malignant (55.1%) and recurrent tumors (57.9%)
Hongo et al. ⁶⁷²	2021	3	Retrospective cohort	14 IP-SCCs, 132 DN-SCCs	<ol style="list-style-type: none"> 1. Mutational status (<i>EGFR</i>, <i>KRAS</i>) 2. HPV status 	<ol style="list-style-type: none"> 1. High-risk HPV in 11 out of 146 (7.5%) 2. <i>EGFR</i> mutation in 13 out of 14 IP-SCCs 3. <i>EGFR</i> mutation in eight out of 132 DN-SCCs 4. No <i>KRAS</i> mutation detected 5. <i>EGFR</i> copy number gain in 41 out of 146 6. <i>EGFR</i>, <i>EGFR</i> copy number gain, and high-risk HPV are mutually exclusive
Mehrad et al. ⁶⁶⁶	2020	3	Retrospective cohort	39 IPs, five IP-SCCs, seven DN-SCCs	<ol style="list-style-type: none"> 1. Mutational status (<i>EGFR</i>, p16) 2. HPV status 	<ol style="list-style-type: none"> 1. Subset of IPs had low-risk HPV 2. Low-risk HPV is mutually exclusive with <i>EGFR</i> mutations 3. All IPs and IP-SCCs negative for p16 and high-risk HPV 4. Three out of five (60%) IP-SCCs with low-risk HPV 5. Five of seven (71.4%) DN-SCCs with p16 and high-risk HPV 6. 11 out of 15 (73.3%) IPs with negative HPV had <i>EGFR</i> exon 19 or 20 mutation
Rooper et al. ⁶⁶²	2017	3	Retrospective cohort	30 IPs without dysplasia, six IPs with dysplasia, 14 IP-SCCs (synchronous), two IP-SCCs (metachronous), seven DN-SCCs	Role of HPV in IP and IP-SCC	<ol style="list-style-type: none"> 1. HPV in 0 out of 52 IPs or IP-SCCs 2. HPV in two of seven DN-SCCs 3. Transcriptionally active high-risk HPV does not play a role in IP or malignant transformation
Udager et al. ⁶⁶⁷	2018	3	Retrospective cohort	58 IPs, 22 IP-SCCs with 13 matched with IPs, 14 DN-SCCs	<ol style="list-style-type: none"> 1. Mutational status (<i>EGFR</i>, <i>KRAS</i>) 2. HPV status 	<ol style="list-style-type: none"> 1. All IPs and IP-SCCs demonstrated <i>EGFR</i> mutation or HPV HPV and <i>EGFR</i> are mutually exclusive except one case <ol style="list-style-type: none"> 1. High-risk HPV more often found in DN-SCC (28.6% vs. 4.5%) 2. Low-risk HPV found in IP-SCC (18.2% vs. 0%) 3. IP progression to IP-SCC associated with HPV and absence of <i>EGFR</i> 4. <i>EGFR</i> mutation and HPV infection may represent alternative oncogenic mechanism in IP-SCC

(Continues)

TABLE XXI.B.3 (Continued)

Study	Year	LOE	Study design	Study groups	Clinical endpoints	Conclusion
Cheung et al. ⁶⁵⁵	2010	3	Retrospective cohort	Five IP-SCCs, one IP with CIS, one SCC with exophytic papilloma	<ol style="list-style-type: none"> 1. <i>p53</i> mutational status 2. HPV status 3. Prognosis 	<ol style="list-style-type: none"> 1. Five of seven were <i>p53</i> positive, the other two of seven were <i>p16</i> positive 2. Four of seven were positive for HPV on PCR 3. Severe dysplasia and <i>p53</i> associated with malignant progression
Tong et al. ¹¹⁴⁰	2022	4	Retrospective case series	Six IPs, five IPs with CIS, 13 IP-SCCs	Upregulation of genes in IP with CIS and IP-SCC	<ol style="list-style-type: none"> 1. Progressive upregulation of 11 genes (<i>CALD1</i>, <i>COL1A1</i>, <i>COL3A1</i>, <i>COL4A2</i>, <i>COL5A2</i>, <i>FNI</i>, <i>ITGA5</i>, <i>LGALS1</i>, <i>MMP11</i>, <i>SERPINH1</i>, <i>SPARC</i>) that correlated with severity of disease 2. Gene set enrichment analysis identified epithelial mesenchymal transition, extracellular matrix organization, and coagulation to be significant 3. Progressive upregulated genes can improve concordance of histologic classification of IP, which may impact prognostication and treatment strategies
Brown et al. ⁶⁶⁰	2021	4	Retrospective case series	29 SCCs (IP-SCC or ex-oncocyctic papilloma)	<ol style="list-style-type: none"> 1. Presence of mutations (<i>EGFR</i>, <i>KRAS</i>, <i>TP53</i>, <i>CKN2A</i>, <i>TERT</i>) 2. Copy number gains of mutations 	<ol style="list-style-type: none"> 1. <i>EGFR</i> mutation in 21 out of 29 and <i>KRAS</i> in five out of 29 2. Mutually exclusive <i>TP53</i> or <i>CDKN2A</i> mutation in 28 out of 29 but no <i>TERT</i> promoter mutation 3. <i>TERT</i> copy number gains in eight of 29 but no <i>TERT</i> promoter mutation <ol style="list-style-type: none"> 1. IP-SCC and SCC ex-oncocyctic papillomas have a distinct molecular phenotype compared to other aerodigestive tract SCC
Hieggelke et al. ¹¹³⁸	2021	4	Retrospective case series	28 IPs, 10 IP-SCCs, 43 SNSCCs (keratinizing), six SNUCs, seven ITACs, 11 ACCs, two SNECs, six exophytic papillomas, one oncocyctic papilloma, 10 SNSCC cell lines	Molecular classification of IP and IP-SCC	<ol style="list-style-type: none"> 1. <i>EGFR</i> mutation in 25 out of 28 IPs, six out of 10 IP-SCCs 2. Deficiency in mismatch repair protein (dMMR)/microsatellite instability (MSI-H) in four out of 125 SNSCCs 3. IP displayed intact MMR phenotype 4. Molecular classification of sinonasal tumors can provide useful information for individualized therapeutic strategy

(Continues)

TABLE XXI.B.3 (Continued)

Study	Year	LOE	Study design	Study groups	Clinical endpoints	Conclusion
Stoddard et al. ¹¹³⁷	2015	4	Retrospective case series	16 IPs, 3 IP-SCCs	Presence of HPV DNA and mRNA	<ol style="list-style-type: none"> HPV mRNA present in all specimens but found in <1% of cells in 58% of them Two of 19 had HPV DNA Transcription of HPV may play a role in the pathogenesis of IP
Udager et al. ⁶⁵⁹	2015	4	Retrospective case series	50 IPs with 12 matched IP-SCCs, 10 IP-SCCs, 20 DN-SCCs	<i>EGFR</i> mutational status	<ol style="list-style-type: none"> Activating <i>EGFR</i> mutations in 88% of IPs and 77% of IP-SCCs <i>EGFR</i> mutation not found in DN-SCC Important role of <i>EGFR</i> mutations in IP and IP-SCC
Nudell et al. ⁶⁵³	2014	4	Retrospective case series	17 cases of malignant transformation from IP and exophytic papilloma (<i>n</i> = 3)	<ol style="list-style-type: none"> Ki-67 status <i>p53</i> expression HPV status 	<ol style="list-style-type: none"> Carcinoma ex-IP or ex-EP exhibits increased Ki-67; >50% is more likely associated with severe dysplasia or carcinoma <i>p53</i> overexpression is correlated with Ki-67 HPV is uncommon Large series needed to validate findings

Abbreviations: DN-SCC, de novo squamous cell carcinoma; HPV, human papillomavirus; IP, inverted papilloma; IP-SCC, inverted papilloma associated squamous cell carcinoma; SNSCC, sinonasal squamous cell carcinoma.

up to 40% of cases and partial response in the remaining cases.¹¹⁵¹ Therefore, *P53* functionality analysis may be used to identify the subgroup of chemoresponsive tumors that should be selected for IC and by the same mechanism predict outcomes, since patients with good response to IC are generally those with the best prognosis.¹⁷

B | Role of surgery

There is general agreement in the literature that surgery still plays a significant role in the treatment for sinonasal ITAC, and it should be performed according to the oncological principle of complete excision with negative margins. In the last 25 years, surgical treatment has evolved considerably due to impressive advances in technologies and instruments, together with refinements in radiological diagnosis. Indications for minimally invasive endoscopic-assisted approaches have expanded over time, making it now possible to obtain negative margins for resection of selected cases of pT4b sinonasal ITAC.^{293,1151} Current available data suggest that EEA, with or without expanded resection of the ethmoidal roof and dura of the ASB (endoscopic resection with transnasal craniectomy, ERTC), represents the surgical technique most used for excision of sinonasal ITAC. Several reports have demonstrated that this approach is oncologically safe, effective, and associ-

ated with limited complications, while reducing impact on QOL.^{16,293,1146} In selected cases with dural extension over the orbital roof or significant intracranial extension, EEA can be combined with an external transcranial approach (cranioendoscopic resection).²⁹³

The extent of surgical resection as compared to the local extent of the tumor still remains a matter of debate. Historically, the multifocal pathogenesis of ITAC prompted surgeons to perform a bilateral ethmoid resection in all cases, regardless of the extent of the tumor, with the aim of removing any microscopic areas of ITAC or synchronous precancerous lesions that might potentially have resulted from occupational exposure to carcinogenic agents in both ethmoids.¹¹⁵² However, bilateral ethmoid resection inevitably leads to significant olfactory dysfunction and increased morbidity. Recently, some authors have reported adequate oncological outcomes even with unilateral endoscopic resection in selected cases.^{374,1153} According to preliminary experiences, ITACs with unilateral extension and without invasion to the contralateral nasal fossa, if ruled out by preoperative imaging and intraoperative assessment with frozen sections, can be safely managed with unilateral ERTC, which provides shorter hospitalization, preservation of some olfactory functions, and, most importantly, oncological outcomes comparable to bilateral ERTC.^{16,374,1153} Therefore, current evidence does not support the routine use of bilateral ethmoid resection in

sinonasal ITAC, even in case of proven occupational exposure, but suggests to tailor the extent of surgery based on the local extension of the tumor.^{16,1152}

Role of surgery in ITAC

Aggregate grade of evidence	B (Level 2: two studies; Level 3: one study; Level 4: seven studies)
Benefit	Oncologic resection is possible with endoscopic approaches in many cases. Reduced complication rate, improved QOL, and better survival outcomes have been described as direct benefit of a multimodal treatment strategy including surgery.
Harm	Insufficient tumor excision with positive surgical margins, leading to increased risk of local or distant recurrences, and morbidity and complication risks related to surgery.
Cost	Although no studies have examined the issue of costs in sinonasal ITAC treatment, short hospitalization period and fast patient recovery associated with minimally invasive surgery could translate to lower costs.
Benefits-harm assessment	Preponderance of benefits over harms.
Value judgments	All studies to date have suggested equivalent or better outcomes of endoscopic surgery as compared to traditional craniofacial surgery. There is no significant argument for or against bilateral ethmoid resection as routine procedure for patients with occupational exposure.
Policy level	Recommendation.
Intervention	Multidisciplinary management of sinonasal ITAC with primary surgery and achieving negative margins currently represents the standard of care.

1 | Role of adjuvant therapy

To date, given the rarity of the disease, no RCTs have been possible to define indications for adjuvant treatments in sinonasal ITAC. Current evidence supports the use of adjuvant RT (conformal three-dimensional RT [3DRT] or IMRT) in case of positive surgical margins, advanced-stage tumors (pT3–4), as well as poorly differentiated ITAC regardless of the stage of the disease at presentation.^{374,1151,1153} While there is limited evidence to support the use of concurrent chemotherapy with RT, adjuvant cisplatin-based chemotherapy should be considered with adjuvant radiation in cases of positive surgical mar-

gins and for persistent disease in unresectable sites.^{293,1144} Table XXII.A.1 summarizes evidence surrounding the management of sinonasal ITAC.

Role of adjuvant therapy in ITAC

Aggregate grade of evidence	C (Level 2: one study; Level 3: one study; Level 4: four studies)
Benefit	Additional oncologic control in cases of positive margins or locally advanced/metastatic tumors.
Harm	The risk of ORN, mucositis, and other RT- and chemotherapy-induced complications should be discussed with the patient when adjuvant treatments are planned.
Cost	No dedicated studies on cost. Multidisciplinary management with multiple healthcare workers involved in the treatment may increase the economic burden.
Benefits-harm assessment	Balance of benefits and harms.
Value judgments	For patients with functional <i>P53</i> , neoadjuvant chemotherapy may improve survival rates. Adjuvant RT should be administered in advanced-stage and/or poorly differentiated tumors, though there are no dedicated studies on this. Biological studies to better understand the genetic and molecular profile of such rare cancers will be crucial to better stratify patients according to prognosis and discover potential new drug targets for precision medicine.
Policy level	Option.
Intervention	Adjuvant RT should be considered for ITAC treatment following surgery if pathology demonstrates positive surgical margins, for advanced-stage tumors (pT3–4), and/or for poorly differentiated grade. The role of chemotherapy and timing of administration is less clear.

2 | Surveillance, recurrence, and outcomes

Cohort studies of sinonasal cancers, including also ITAC, have demonstrated the efficacy of a strict follow-up protocol that includes nasal endoscopy and contrast-enhanced MRI every 3–4 months for the first year, every 4–6 months from the second to the fifth year, and after, once a year from the sixth to the 10th year.^{293,1144} Systemic staging (e.g., total body CT, PET/CT) should be conducted once per year for the duration of the follow-up as ITAC patients may develop

TABLE XXII.A.1 Evidence surrounding the management of sinonasal ITAC.

Study	Year	LOE	Study design	Study groups	Clinical endpoints	Conclusion
Huang et al. ¹¹⁵⁴	2021	2	Systematic review and meta-analysis	1126 cases of sinonasal ITAC, surgically treated with open, EEA, or combined approach	<ol style="list-style-type: none"> OS Local, regional, and distant recurrence Stratification of patients according to the enrollment year 	Patients treated more recently presented with older mean age have lower local recurrence rate, improved 5-year OS, and are most frequently treated via EEA
Meccariello et al. ²⁵⁹	2016	2	Systematic review	947 cases of sinonasal ITAC, surgically treated with EEA, external or combined approach	<ol style="list-style-type: none"> OS DFS LRFS To analyze morbidity rates, major and minor complications in EEA, open, and combined approaches 	Endoscopic management of sinonasal ITAC is safe and effective, with reduced morbidity and lower complication rates compared to open and combined approaches
Licitra et al. ¹¹⁵¹	2004	2	Clinical trial	30 cases of sinonasal ITAC treated with primary chemotherapy followed by CFR and postoperative RT when necessary	Status of <i>P53</i> as a therapeutic guide for the use of chemotherapy drugs	<ol style="list-style-type: none"> <i>P53</i> status represents a biomarker to predict response to chemotherapy in ITAC Induction chemotherapy (PFL) should be used for patients with <i>P53</i> functionality
Ferrari et al. ¹⁶	2022	3	Prospective multicenter case-control study	389 cases of sinonasal ITAC surgically treated with EEA with or without transnasal craniectomy or a combined CFR	<ol style="list-style-type: none"> OS RFS (LRFS, RRFS, DRFS) Multivariable analysis To create nomograms based on multivariable models 	Factors associated with poor prognosis were age at presentation >54 years old, histology subtype (mucinous signet-ring vs. solid or mucinous alveolar goblet vs. papillary, colonic, mixed), cranial resection, positive margins, and advanced pT stage
Fiaux-Camous et al. ¹¹⁴⁵	2017	3	Multicenter prospective cohort with systematic review	223 cases of sinonasal ITAC not previously treated, without evidence of positive neck nodes, who were treated with EEA	<ol style="list-style-type: none"> To evaluate whether the patients' stratification according to the local extension of tumor in the 7th edition of the AJCC/UICC TNM classification is associated with prognosis for ethmoidal ITAC To develop a prognostic risk prediction model for OS among patients undergoing endoscopy surgery for ethmoid ITAC 	<ol style="list-style-type: none"> Sphenoid lateral or posterior walls invasion can be considered as poor prognostic factors, with survival rates much more comparable to dura and/or cerebral extension rather than other sphenoidal subsites Two subsites might be classified as pT4b

(Continues)

TABLE XXII.A.1 (Continued)

Study	Year	LOE	Study design	Study groups	Clinical endpoints	Conclusion
Garcia-Marin et al. ¹¹⁶³	2020	4	Retrospective case series	133 cases of sinonasal ITAC treated with primary surgery followed by adjuvant RT (in selected cases)	To evaluate CD8+ TILs and TMIT (combining CD8+ TILs and PD-L1) as predictive biomarkers for immunotherapy	<ol style="list-style-type: none"> 1. CD8+ TILs and TMIT were correlated with the histological subtype of ITAC and with improved OS 2. The modest percentage of CD8 high/PD-L1-positive cases indicates that ITAC is a lowly immunogenic tumor type 3. Sinonasal ITACs, especially the papillary and colonic subtypes, may benefit from therapy with immune checkpoint inhibitors
Patel et al. ¹¹⁶⁴	2020	4	Retrospective database study (NCDB)	553 cases of adenocarcinoma No distinction between ITAC and non-ITAC	OS	<ol style="list-style-type: none"> 1. Surgery and RT associated with improved OS 2. Advanced age, comorbidities, advanced tumor grade, and stage associated with worse OS 3. Chemotherapy not associated with OS
Schreiber et al. ³⁷⁴	2018	4	Retrospective case-control study	54 cases of sinonasal ITAC divided into two groups: patients treated with unilateral ERTC (<i>n</i> = 27) versus patients treated with bilateral ERTC (<i>n</i> = 27)	<ol style="list-style-type: none"> 1. OS 2. DSS 3. RFS 4. LRFS 5. Morbidity and functional outcomes between the two groups 	<ol style="list-style-type: none"> 1. ITAC confined to one ethmoid without any extension to the contralateral nasal fossa at preoperative imaging and intraoperative assessment can be safely managed with unilateral resection 2. Unilateral resection provides shorter hospitalization, preservation of some olfactory function, and oncological outcomes comparable to bilateral resection 3. Occupational exposure to wood dusts or other inhalants is not per se an indication for bilateral resection
Camp et al. ¹¹⁶¹	2016	4	Retrospective case-control study	123 cases of sinonasal ITAC surgically treated with EEA	<ol style="list-style-type: none"> 1. OS 2. DSS 3. RFS 	Factors influencing survival rates are local recurrence, development of distant metastases, tumor stage (pT classification), and infiltrated surgical margins
Nicolai et al. ¹¹⁴⁶	2016	4	Retrospective case-control study	169 cases of sinonasal ITAC surgically treated with EEA with or without transnasal craniectomy or combined CFR followed by postoperative RT (in selected cases)	<ol style="list-style-type: none"> 1. OS 2. DFS 	Prognostic factors for both OS and DFS included pT stage, margin status, and tumor grade

(Continues)

TABLE XXII.A.1 (Continued)

Study	Year	LOE	Study design	Study groups	Clinical endpoints	Conclusion
Progetti et al. ¹¹⁶⁵	2015	4	Retrospective case series study	72 cases of sinonasal ITAC treated with surgery ($n = 5$); surgery followed by adjuvant RT ($n = 65$); exclusive RT ($n = 1$); primary CRT ($n = 1$).	<ol style="list-style-type: none"> To evaluate MET protein levels by IHC To evaluate MET amplification and/or chromosome 7 polysomy by DISH PFS OS 	<ol style="list-style-type: none"> MET protein was overproduced in about two thirds of ITACs, suggesting a possible role for this tyrosine kinase receptor in ITAC oncogenesis. Protein overproduction was not due to gene amplification, and the underlying mechanism remains to be determined Anti-MET treatments would be of interest in ITACs
Turri-Zanoni et al. ¹¹⁵⁰	2015	4	Retrospective case-control study	57 cases of sinonasal ITAC, early staged (T1-T2), surgically treated with EEA, with at least 24 months of follow-up	<ol style="list-style-type: none"> OS DFS Stratification of patients according to adjuvant RT 	Adjuvant IMRT is recommended in advanced-stage ITAC (pT3-pT4) and high-grade (G2-G3) early-stage (pT1-pT2) cases
Vergez et al. ¹¹⁶⁶	2014	4	Retrospective multicenter case-control study	136 cases of sinonasal ITAC surgically treated with EEA	<ol style="list-style-type: none"> Hospitalization time Complication rate Margin status Recurrence rate and RFS Mortality 	Mortality and systemic complications seem to be reduced with EEA, even when skull base removal is performed, in comparison with open CFR
Bossi et al. ¹⁰²	2013	4	Retrospective case series	74 cases of sinonasal ITAC, divided into two groups: A ($n = 30$): patients treated with CFR followed by postoperative RT B ($n = 44$): patients treated with primary chemotherapy followed by CFR and RT (selected cases).	<ol style="list-style-type: none"> OS DFS Stratification of patients according to <i>P53</i> functional status 	<ol style="list-style-type: none"> The functional status of <i>P53</i> can be helpful to identify the subgroup of chemoresponsive tumors The response to induction chemotherapy represents a positive prognostic factor
Cantu et al. ¹¹⁵²	2010	4	Retrospective case-control study	153 cases of sinonasal ITAC, surgically treated with CFR (96.7%) or with transfacial ethmoidectomy (3.3%)	<ol style="list-style-type: none"> To explore the relationship between ITAC and organic dusts OS DFS Incidence of the polymorphisms of the enzymes <i>CYP1A1</i> and <i>GSTM1</i> 	<ol style="list-style-type: none"> ITAC has an indisputable relationship with exposure to organic dusts, mainly wood and leather The <i>CYP1A1</i> codon 461 polymorphism is overrepresented in ITAC and is often associated with the <i>GSTM1</i> null genotype

Abbreviations: CFR, craniofacial resection; CSF, cerebrospinal fluid; CSS, cancer-specific survival; DFS, disease-free survival; DISH, dual color silver-enhanced in situ hybridization; DRFS, distant recurrence-free survival; EEA, endoscopic endonasal approach; ERTC, endoscopic resection with transnasal craniectomy; IHC, immunohistochemistry; IMRT, intensity-modulated radiotherapy; ITAC, intestinal-type adenocarcinoma; LOE, level of evidence based on the Oxford Centre for Evidence-Based Medicine Working Group; LRFS, local recurrence-free survival; OS, overall survival; pCR, pathologic complete response; PFL, cisplatin, fluorouracil, and leucovorin; PFS, progression-free survival; RFS, recurrence-free survival; RRFS, regional recurrence-free survival; RT, radiation therapy; TILs, tumor-infiltrating lymphocytes, TMIT, tumor microenvironment immune type.

distant metastatic disease.¹¹⁴⁶ With such a surveillance protocol, earlier detection of recurrences increases the possibility to cure patients who experience relapses.^{1144,1154} Globally, the recurrence rate after definitive treatment ranges from 17.6% to 49.6%.¹¹⁵⁵ The largest cohort studies on sinonasal ITAC have found that this cancer tends to recur mainly at the primary site (12%–16%), which is generally treatable by means of revision surgery and/or stereotactic radiosurgery. Regional recurrences to neck nodes are rare (1%), while distant metastases can occur in a nonnegligible proportion of cases (6%–10%) with limited possibility to cure patients despite using different protocols of chemotherapy and/or immunotherapy.¹¹⁴⁶

Oncologic outcomes are impacted by several factors, including patient characteristics, stage at presentation, and biological features of the tumor. Age >54 years; certain histology subtypes (mucinous signet-ring vs. solid or mucinous alveolar goblet vs. papillary, colonic, or mixed); positive surgical margins; and advanced pT classification at presentation with invasion of the lateral or posterior wall of the sphenoid sinus, orbit, dura, and brain have been identified as negative prognostic factors.^{104,293,1155,1156} High proliferation index and poor grade of differentiation are significantly associated with worse prognosis.^{104,293,1144,1151,1155,1156} In the largest European published series, 5-year OS, DSS, and DFS are 72.7% (67.3%–78.5%), 80.0% (75.1%–85.2%), and 73.2% (68.1%–78.6%), respectively.^{293,1155,1157}

Further improvements in survival rates might be obtained only by deciphering the genetic profile and the molecular landscape of such a rare cancer, in order to better stratify patients according to prognosis and discover potential new drug targets for precision medicine.^{1158,1159} Data available to date show that there is a low incidence of *EGFR*, *K-RAS*, and *BRAF* mutations and a high rate of increase in the number of *EGFR* copies. This genetic fingerprint seems to support the potential for anti-*EGFR* drugs.^{1145,1154} Current evidence for use of anti-*EGFR* drugs is limited, but several clinical trials are ongoing for patients with metastatic disease.^{1157,1160} Similarly, the high *MET* mutation rate (64%) suggests a possible role for the *MET* signaling pathway in the oncogenesis of ITAC and supports the possible use of *MET* inhibitors as an alternative option.¹¹⁶¹ Moreover, ITACs with *HRAS* mutation have a worse prognosis and might benefit from administration of inhibitors of the *MAPK/ERK* pathway, possibly in combination with cyclin-dependent kinase-4/6 inhibitors.¹¹⁶² Limited evidence based on in vitro studies is currently available in this regard and further studies will be needed to explore the real benefit of these drugs in the clinical setting.

C | Nonintestinal-type adenocarcinoma

Non-ITACs are nonsalivary adenocarcinomas of the sinonasal area. The WHO has defined non-ITAC as an adenocarcinoma that arises in the sinonasal tract and does not show features of salivary gland neoplasia and does not have an intestinal phenotype—essentially a diagnosis of exclusion.^{17,1167} Nonintestinal-type ITACs are further classified into low-grade and high-grade non-ITACs. Low-grade non-ITACs must be classified separately from other nonsalivary adenocarcinomas because of their favorable prognosis. Low-grade non-ITAC was described more than 30 years ago, and in the literature several synonyms have been used such as terminal tubulus adenocarcinoma, sinonasal tract seromucous adenocarcinoma, and sinonasal tubulopapillary low-grade adenocarcinoma.^{1168–1170} Rare cases may histologically resemble metastatic renal carcinoma and these cases are designated as sinonasal renal cell-like adenocarcinoma (RCLAD).¹¹⁷¹ As a matter of fact, under the umbrella of non-ITAC several different histotypes are included. Some reports also make the association between low-grade non-ITAC and REAH leading to controversy in the dividing line between reactive glandular lesions and adenocarcinomas.¹¹⁷² In one study, 33% of low-grade tubular sinonasal adenocarcinomas were found in association with REAHs.¹¹⁷³ Similarly, high-grade non-ITAC probably does not represent a single distinct entity but is rather a collection of several different adenocarcinoma types.¹¹⁷¹

1 | Clinical presentation, epidemiology, risk factors

In low-grade non-ITAC, males and females are equally affected.¹¹⁷⁴ The average age at diagnosis is 48 years but with a wide range from childhood until elderly.^{1172,1175} Patients with high-grade adenocarcinoma are more likely to be older and male than those with low-grade tumors.^{1176,1177} Low-grade non-ITACs have a predilection for the nasal cavity (38.2%), but also occur in the maxillary (30.5%) and ethmoid sinuses (18.9%).^{1172,1178} In high-grade non-ITAC, approximately one third involve the nasal cavity only and often these tumors present at advanced stages, so it is not possible to identify a clear site of origin.¹¹⁷⁵ In contrast to ITAC, there are no established risk factors for the development of low-grade and high-grade non-ITAC.¹¹⁷² Only rarely have high-grade non-ITACs been associated with high-risk HPV.¹¹⁷⁹

2 | Histopathology

Non-ITAC morphologically displays neither features of intestinal-type nor salivary-type adenocarcinoma. The histogenesis and the origin of low-grade non-ITAC are still debated. Two sites of origin of non-ITAC are proposed: the surface epithelium or the submucosal glands.^{1176,1180,1181} Low-grade non-ITACs exhibit typically an exophytic or papillary growth and have tubulo-glandular, papillary, and microcystic patterns. Most of the low-grade non-ITACs are considerably less pleomorphic than ITACs. The glands are closely packed with minimal stroma and no basal layer. They are composed of cuboidal to columnar cells with only focal mild atypia. PNI and necrosis are typically not present.^{1171,1172} This is in contrast to high-grade non-ITACs that are histologically very heterogeneous on both the architectural and cytological levels. Common features of high-grade non-ITAC are cellular pleomorphism, brisk mitotic activity, necrosis, and infiltrating growth.¹¹⁷¹ These features are currently the most distinguishing characteristics between high-grade and low-grade non-ITAC. However, it must be emphasized that definitive criteria are lacking.^{1156,1182} Indeed, low-grade and high-grade are diagnosed according to mitoses, necrosis, and cell pleomorphism, but no clear definitions are given in the literature.

3 | IHC and molecular profiling

Low-grade non-ITACs have a high expression of CK7, exhibit a focal expression of S100, DOG1, and SOX10, and can be positive for MUC1, MUC4, and MUC5ac.^{1180,1183–1186} SOX-10 and DOG-1 immunoreactivity have been noted in a subset, suggesting seromucinous differentiation.¹¹⁸⁰ Typically there is no expression of CK20, CDX2, MUC2, and MUC6.¹¹⁸⁷ Due to the lack of basal cells in low-grade non-ITAC, there is an absence of p63 or 34BE12 staining.¹¹⁷² Diffuse expression of CK7 is seen in 43% of high-grade non-ITACs.¹¹⁷⁵ Rare cases express seromucinous markers (SOX-10, DOG1).¹¹⁸⁰ p16 positivity has been described in the few cases associated with high-risk HPV.¹¹⁷⁵ The absence of SATB2 in non-ITAC is able to differentiate ITAC from non-ITAC with a high specificity.¹¹⁸¹ A second molecular marker differentiating non-ITAC from ITAC is OTX type 1 gene where OTX1 mRNA was identified only in non-ITAC.^{1188,1189} At the time of writing, no significant data regarding molecular profiling have been published

on high-grade non-ITAC. Table XXII.B.1 summarizes the above studies and findings.

4 | Renal cell-like adenocarcinoma

RCLADs are rare, low-grade, malignant tumors, histologically composed by glandular and follicular areas in various proportion. These tumors present a female-to-male ratio of 2:1, with a wide range of age of presentation. Most tumors arise in the nasal cavity and symptoms are usually nonspecific (e.g., epistaxis, nasal obstruction).¹¹⁹⁰ From a histological standpoint, neoplastic cells are uniform, cuboidal to polyhedral, with abundant clear to eosinophilic cytoplasm.¹¹⁹¹ Mitoses are rare, while necrosis and PNI are absent. There is a strong positivity for CK7, EMA, SOX10, and S100. There is absent CAIX and PAX8 immunoreactivity. Seromucinous gland markers (SOX10 and S100) are present, and these features are shared with most cases of low-grade non-ITAC, thus justifying the inclusion of this tumor in the non-ITAC group. Typically, on MRI, these tumors enhance avidly, like renal cell carcinoma.¹¹⁹² Definitive diagnosis always requires the exclusion of a renal clear cell carcinoma, clinically and/or radiologically.

5 | Role of surgery

No standardized treatment or well-established guidelines concerning sinonasal non-ITAC are available throughout the literature. Endoscopic transnasal resection, especially when negative postoperative margins can be achieved, remains the treatment of choice. When it follows an optimal preoperative imaging protocol and is carried out by an experienced surgical team, it can significantly reduce length of hospitalization.²⁶¹ Treatment modalities including surgery have been associated with higher survival rates, whether followed by adjuvant RT or not.⁵³

Open and endoscopic approaches should not be considered as divergent, since regardless of the approach, negative resection margins are their common goal. Extrapolated data from studies that do not discriminate between ITAC and non-ITAC patients suggest that there is no statistically significant difference between endoscopic and open surgical approaches in OS.¹¹⁵⁸ CFR is indicated when endoscopic transnasal resection cannot provide adequate access to the tumor circumference; however, it may be associated with increased morbidity.¹⁷⁴

TABLE XXII.B.1 Evidence surrounding relevant immunohistochemistry markers for non-ITAC.

Study	Year	LOE	Study design	Study groups	Biomarkers	Conclusion
Yue et al. ¹¹⁷⁴	2021	4	Retrospective case series	17 non-ITACs	CK7, CDX2, P63, calponin, S100, SOX10	CK7+, CDX2-, P63-, calponin-, S100 focal expression, SOX10+
Baneckova et al. ¹¹⁸⁴	2020	4	Retrospective case series	Nine low-grade non-ITACs	CK7, MUC4, SOX10, MUC1, S100, MUC5ac, SATB2, CK20, CDX2, MUC2, MUC6, p63	Low-grade non-ITAC are (1) CK7, MUC4, SOX10, MUC1, S100, MUC5ac, and SATB2 positive; (2) CK20, CDX2, MUC2, and MUC6 p63 all negative
Taverna et al. ¹¹⁸⁶	2019	4	Retrospective case series	51 ITACs: four non-ITACs, and 11 salivary gland-type carcinomas	MUC 1, 2, 4, 5AC, 6	MUC1 more expressed ITACs than non-ITACs MUC2 only in ITACs. MUC4 and MUC5AC were similarly expressed
Pirrone et al. ¹¹⁸⁹	2017	4	Retrospective case series	Five non-ITACs	OTX1, OTX2	OTX1 only in non-ITAC
Purgina et al. ¹¹⁸⁰	2014	4	Retrospective case series	23 non-ITACs, 17 ITACs, and five SSHs	CK20, CDX2, CK7, S100, DOG1, SOX10	Negative CK20 and CDX2, and positive for CK7, but SSH and some non-ITAC have focal, S100, DOG1, and SOX10
Tilson et al. ¹¹⁸⁷	2013	4	Retrospective case series	Six non-ITACs	CDX-2, CK20	CDX-2 and CK20 negative in non-ITAC
Jo et al. ¹¹⁷³	2009	4	Retrospective case series	29 low-grade non ITACs	CK7, CK20, S100, MUC2, CDX2	CK7+, CK20-, MUC2-, CDX2-
Resto et al. ¹¹⁸⁵	2006	4	Retrospective case series	Four cases of non-ITACs	CK7, CK20, Muc2, MUC5	ITAC: CK7+, CK20+, MUC2+ phenotype non-ITAC: CK7+, CK20-, MUC2- phenotype
Franchi et al. et al. ¹¹⁵⁶	2014	4	Retrospective case series	Four cases of tubulopapillary low-grade non-ITACs	CDX2, CK7, CK20	CDX2-, CK7+, CK20-
Choi ¹¹⁸³	2003	4	Retrospective case series	Five cases of non-ITACs	CK7, CK20, CK14, CK19, AE 1-3, CAM5.2	Non-ITAC tumors exclusively CK7+
Skalova et al. ¹¹⁸¹	2018	4	Retrospective case series	Six low-grade tubulopapillary ACs	CK14, CK19, CEA, S100, CD10, GFAP, p63, CD57, HER2/neu oncoprotein, GFAP, alfa SMA AE1-3, CAM5.2	CK14 and CK19 restricted expression, AE1-3, CAM5.2 strong expression, S100 positive

Abbreviation: ITAC, intestinal-type adenocarcinoma.

Role of surgery in non-ITAC

Aggregate grade of evidence	C (Level 2: one study; Level 3: two studies; Level 4: four studies)
Benefit	Surgical resection, either endoscopic or open approach, with negative margins may be associated with improved OS and DSS.
Harm	Procedural related, depending on the approach.
Cost	Cost comparison analyses have not been undertaken.
Benefits-harm assessment	Preponderance of benefits over harms.
Value judgments	Surgical resection with negative margins is beneficial to improve OS and DSS.
Policy level	Recommendation.
Intervention	Endoscopic transnasal resection with goal of negative margins is the primary treatment of choice for non-ITAC. Due to increased morbidity, open (craniofacial) resection should be considered when negative postoperative margins cannot be achieved otherwise.

6 | Role of chemoradiation therapy

Some studies suggest that postoperative RT should be considered regardless of tumor grade or stage.¹¹⁹³ Other authors emphasize the effectiveness of surgery alone for T1-T2/G1 tumors.^{1150,1194} Adjuvant RT is usually reserved for high-grade and/or advanced-stage tumors, since adjuvant RT is associated with more favorable prognosis in such tumors.¹¹⁷⁸ However, larger studies designed to evaluate the role of RT are required. There are no data on the use of neoadjuvant RT in the treatment of sinonasal non-ITAC.

The role of chemotherapy in treatment of non-ITAC is mainly in the palliative setting.¹¹⁹⁵ IC with a regimen of cisplatin, fluorouracil, and leucovorin has shown good results in advanced tumors, where a functional p53 protein is present; unfortunately, this is not the case for most (85%) non-ITAC patients.^{101,1195} Data on topical application of chemotherapeutic agents have existed since 1970, but not specifically for non-ITAC groups. There are no data on the use of immunotherapy or hormonal therapy in the management of non-ITAC. Table XXII.B.2 contains data on the management of non-ITACs.

Role of adjuvant therapy in non-ITAC

Aggregate grade of evidence	C for both RT and chemotherapy <ul style="list-style-type: none"> • Level 3: two studies (RT) • Level 3: two studies (chemotherapy)
-----------------------------	---

(Continued)

Benefit	There is some evidence that adjuvant RT improves DSS of non-ITAC patients, especially for high-grade tumors. No strong data on chemotherapy outside the palliative setting are available, except in the presence of functional p53 protein.
Harm	Possible side effects of RT include mucositis, nasal discharge, ORN/osteomyelitis, and hyposmia.
Cost	Cost comparison analyses have not been undertaken.
Benefits-harm assessment	Preponderance of benefits over harms (RT). No strong evidence (chemotherapy).
Value judgments	Adjuvant RT should be considered to improve DSS of non-ITAC patients. The role of chemotherapy is not established in the management of non-ITAC patients except in presence of functional p53 protein and as part of topical treatment.
Policy level	Recommendation for adjuvant RT. Option for adjuvant chemotherapy.
Intervention	Adjuvant RT should be considered for all patients with high-grade and/or advanced-stage non-ITAC. Concerning low-grade tumors, the potential benefit should be weighed against the side effects. The role of chemotherapy is established in cases of a functional p53 protein or for palliative therapy.

7 | Recurrence and survival

Adenocarcinomas, even low-grade, have shown a tendency to recur. However, the pleiomorphism of morphologic patterns of such lesions does not allow for safe conclusions or solid qualitative analyses.¹¹⁷³ Lesions without salivary gland features have not been shown to metastasize.¹¹⁷³ As with most sinonasal malignant tumors, high grade, advanced stage, and positive surgical margins seem to be independent negative prognostic factors.³⁶³

Very little survival data coming from small series or short-term follow-up are available. Five-year OS of non-ITAC groups of patients varies from 58% to 95.2%.^{363,1159} Chen et al. determined a 5-year DSS rate of 71.2% for non-ITAC patients, which is not statistically significantly different from ITAC patients, something that has been supported by other authors as well.^{1178,1196} On the contrary, Meccariello et al. associated non-ITAC histology with a less favorable prognosis.²⁵⁹ However, this is probably the result of different case mix of high- and low-grade tumors within the non-ITAC groups. Concerning tumor grade, prognosis of high-grade non-ITAC is poor.¹¹⁷⁷ Sphenoid sinus invasion has also been shown to reduce survival,

TABLE XXII.B.2 Evidence on treatment modalities for non-ITAC.

Study	Year	LOE	Study design	Study groups	Clinical endpoints	Conclusions
Surgery						
Meccariello et al. ²⁵⁹	2015	2	Systematic review and meta-analysis	1826 patients encompassing 39 articles; 1005 with histology information 865 ITAC (140 non-ITACs)	Evaluation of safety and effectiveness of endoscopic management of sinonasal adenocarcinomas	ER is a safe and effective treatment modality for adenocarcinomas
Vergez et al. ²⁶¹	2012	3	Retrospective cohort	48 patients with adenocarcinomas, 24 underwent CFR and 24 underwent ER	1. LRC 2. OS 3. Disease-free rates	Reduced duration of hospitalization for ER group, oncological outcomes, and early morbidity comparable between two groups
Ganly et al. ¹⁷⁴	2005	3	Retrospective cohort	334 patients, 107 with adenocarcinoma	1. Postoperative mortality 2. Postoperative complications 3. DSS 4. OS 5. RFS	Overall mortality of 4.5% and complication rate of 33% for CFR
Kiliç et al. ⁵³	2018	4	Retrospective database review (SEER)	746 patients, 464 of whom with non-ITAC between 1973 and 2013	DSS	1. Highest DSS was in surgery-only patients 2. Treatment modalities that included surgery had higher survival rates than those that did not
Turri-Zanoni et al. ¹¹⁵⁰	2015	4	Retrospective case-control study	61 adenocarcinoma T1–2 patients, 57 ITAC—four non-ITAC, 33 surgery alone—28 surgery + RT	1. OS 2. RFS	ER could be used as a single treatment modality for primary early-stage low-grade sinonasal adenocarcinoma
Bhayani et al. ¹¹⁵⁸	2014	4	Retrospective case series	66 patients, 31 of whom had non-ITAC	OS	ER not associated with adverse outcomes
Nicolai et al. ¹¹⁹⁴	2007	4	Retrospective case series	12 patients with adenocarcinoma underwent ER	1. DSS 2. DFS	ER for T1–2 lesions offers an alternative to external procedures
Radiotherapy						
Chen et al. ¹¹⁷⁸	2015	3	Retrospective cohort	325 patients, 300 of whom had non-ITAC	DSS	Compared with RT alone, surgery and surgery with adjuvant RT were associated with improved DSS
Bogaerts et al. ¹¹⁹³	2008	3	Retrospective cohort	44 patients with adenocarcinoma treated with surgery + RT	1. OS 2. DSS 3. Local control rate	ER followed by RT gives comparable oncological results to those of standard external approaches

(Continues)

TABLE XXII.B.2 (Continued)

Study	Year	LOE	Study design	Study groups	Clinical endpoints	Conclusions
Chemotherapy						
Choussy et al. ¹¹⁹⁶	2008	3	Multicenter retrospective cohort	418 patients with ethmoid adenocarcinoma, divided into two groups: ITAC and poorly differentiated carcinoma ($n = 248$) versus well-differentiated carcinoma ($n = 107$). 215 recurrences. 66 received chemo as part of the treatment for first recurrence	Determination of risk factors and evaluation of treatment	Chemotherapy considered in advance cases
Knekt et al. ¹²⁸	2001	3	Prospective cohort	62 adenocarcinoma patients (eight excluded) treated with surgery—no distinction between ITAC/non-ITAC	1. DFS 2. Local relapse-free survival 3. Distant relapse-free survival	Surgical debulking plus repeated topical fluorouracil therapy, preferable over CFR for adenocarcinomas

Abbreviations: CFR, craniofacial resection; DFS, disease-free survival; DSS, disease-specific survival; EEA, endoscopic endonasal approach; ITAC, intestinal-type adenocarcinoma; LRFS, locoregional failure/recurrence-free survival; OS, overall survival; RFS, recurrence-free survival.

although not specifically for the non-ITAC subtype.¹¹⁵⁸ Kiliç et al. reported that tumors originating at the nasal cavity had the greatest DSS.⁵³ These findings are summarized in Table XXII.B.3.

Aggregate grade of evidence: C (Level 2: one study; Level 3: six studies; Level 4: five studies)

D | Adenoid cystic carcinoma

Sinonasal ACC is a salivary gland tumor that originates from the nasal cavity and paranasal sinuses. It comprises 10%–25% of all cases of ACC of the head and neck.¹¹⁹⁸ The most common site of origin is the maxillary sinus, followed by the nasal cavity, which together contribute to more than 60% of sinonasal ACC cases.^{75,77,79,376,1198} Most patients (50%–80%) present with advanced-stage disease (T3–4) at the time of diagnosis, with high rates of PNI, bone invasion, and ASB involvement.^{75,77,376,398,1198,1199} Surgical resection is considered the main treatment, as patients undergoing surgery have better survival. This is commonly followed by RT.^{79,376} For unresectable cases, RT combined with or without chemotherapy is usually recommended.⁷⁹ The 5-year OS is reported to range between 56% and 78%.^{75,79,398,1200} However, sinonasal ACC is associated with high rates of local recurrence (up to 60%) and distant metastasis, even

compared to other malignant tumors of the paranasal sinuses.^{77,79,398,1201–1203} Hence, obtaining local control is a major concern when planning the treatment goal for patients with sinonasal ACC.

Due to the rarity of ACC, there are no clear guidelines available for management of these patients, especially in the sinonasal area. This section aims to review the evidence regarding the importance of total gross resection, achieving negative surgical margins, and the role of adjuvant radiotherapy in disease control. It also serves as an update to ICSB 2019 (Section VIII.D).^{5,777}

1 | Role and extent of surgery

It is widely accepted that surgical resection of sinonasal ACC significantly improves survival compared to RT or chemotherapy.^{79,376,1200,1203} However, the extent of the resection and importance of achieving clear margins is poorly defined. Given the adjacent vital structures, the extent of surgery is particularly important. A meta-analysis with 99 patients with sinonasal ACC in 2013 revealed that invasion to adjacent structures including the orbit, dura, cavernous sinus, brain, muscles, or skin is common (81% of patients) and must be considered in surgical planning.⁷⁵ Sinonasal ACCs typically present as advanced-

TABLE XXII.B.3 Evidence on survival in non-ITAC patients.

Study	Year	LOE	Study design	Study groups	Clinical endpoint	Conclusion
Meccariello et al. ²⁵⁹	2015	2	Systematic review and meta-analysis	1826 patients; 1005 with histology information 865 ITAC (140 non-ITAC)	Evaluation of safety and effectiveness of endoscopic management of sinonasal adenocarcinomas	Non-ITAC histology associated with less favorable prognosis
König et al. ¹¹⁹⁷	2019	3	Population-based consecutive prospective cohort	20 patients with AC, seven of whom with non-ITAC (four low-grade, three high-grade), follow-up 100%, median follow-up time 89 months for entire cohort	Evaluation of outcomes for patients with AC	2-year cumulative survival 100%, 5-year 83%, and 10-year 83% for non-ITAC group
Chen et al. ¹¹⁷⁸	2015	3	Retrospective cohort	325 patients, 300 of whom had non-ITAC	DSS	<ol style="list-style-type: none"> 5-year DSS rate of 71.2% for non-ITAC patients No significant difference in terms of survival between ITAC and non-ITAC subtypes Surgery alone or adjuvant RT, associated with more favorable prognosis
Choussy et al. ¹¹⁹⁶	2008	3	Multicenter retrospective cohort	418 patients with ethmoid adenocarcinoma, divided into two groups: ITAC and poorly differentiated carcinoma ($n = 248$) versus well-differentiated carcinoma ($n = 107$)	Determination of risk factors and evaluation of treatment	No significant difference in terms of survival between low- and high-grade tumors
Yue et al. ¹¹⁷⁴	2021	4	Retrospective case series	Study group: 17 patients with low-grade non-ITAC Control group: 10 patients with CRS involving the turbinates	Clinicopathological and immunohistochemical features of the tumors	14 out of 17 patients had no recurrence for a median of 60 months after diagnosis
Bignami et al. ³⁶³	2018	4	Retrospective case series	22 patients with non-ITAC	Outcomes and prognostic factors of sinonasal nonsalivary non-ITAC	<ol style="list-style-type: none"> Non-ITAC 5-year OS of $95.2\% \pm 4.7\%$ High grade, high pT4 stage, and positive surgical margins are independent negative prognostic factors
Kiliç et al. ⁵³	2018	4	Retrospective database review (SEER)	746 patients, 464 of whom with non-ITAC between 1973 and 2013	DSS	<ol style="list-style-type: none"> 5-year DSS 63.7%, 10-year DSS 57.9%, and 20-year DSS 48.3% for non-ITAC combined group Improved survival for ITAC compared to adenocarcinoma not otherwise specified, specifically

(Continues)

TABLE XXII.B.3 (Continued)

Study	Year	LOE	Study design	Study groups	Clinical endpoint	Conclusion
Bhayani et al. ¹¹⁵⁸	2014	4	Retrospective case series	66 patients, 31 of whom had non-ITAC	Outcomes of endoscopic resection	5-year OS of 65.9% for non-ITAC patients
Huber et al. ²⁶³	2011	4	Retrospective case series	20 patients with AC, five of whom had non-ITAC	1. RFS 2. DSS	Three patients died of disease (two high-grade, one low-grade), two patients alive without disease
Jo et al. ¹¹⁷³	2009	4	Retrospective case series	29 cases of low-grade non-ITAC	Association of low-grade tubular sinonasal adenocarcinomas with respiratory epithelial adenomatoid hamartomas	16 patients with follow-up information (median 16 months), none with recurrent disease
Orvidas et al. ¹¹⁵⁹	2005	4	Retrospective case series	24 patients, 14 of whom had non-ITAC	Histologic characteristics and outcomes	1. 5-year OS of 58% 2. Patients with high-grade tumors 5.4 times more likely to die than patients with low-grade tumors
Neto et al. ¹¹⁶⁹	2003	4	Retrospective case series	12 patients with seromucous adenocarcinomas	Clinical findings/pathologic features/histologic differential diagnosis	11 patients alive with no evidence of disease 36–108 months after diagnosis, one dead of other reasons

Abbreviations: DFS, disease-free survival; DSS, disease-specific survival; ITAC, intestinal-type adenocarcinoma; OS, overall survival; RFS, recurrence-free survival; RT, radiation therapy.

stage tumors in the majority of cases and, regardless of surgical technique, the rate of microscopic or gross positive margins is very high. In older studies, the surgical strategy for sinonasal ACC was an open approach with aggressive resection using wide margins to obtain total resection of the tumor. RT as the sole treatment was usually reserved for unresectable tumors.^{377,1198,1203,1204} In a series of 35 patients by Rhee et al., surgical treatment was directed by subsite in the paranasal sinuses and included medial maxillectomy, subtotal maxillectomy, CFR for skull base involvement, or orbital exenteration for periorbital involvement.¹¹⁹⁸ Nasopharynx tumors were considered surgically unresectable. The reported 5-year OS and DFS were 86% and 51%, respectively, with 30% local recurrence rate and 25% distant metastasis rate. Time to local recurrence was 51 ± 64 months after treatment, and time to distant metastasis was 37 ± 33 months.¹¹⁹⁸ Pitman et al. reported on a series of 35 patients treated with open CFR and adjuvant RT for treatment of sinonasal ACC.¹²⁰⁴ They performed GTR, except for where tumor abutted major neurovascular structures. In these cases, they tolerated positive margins. Overall, 46% had microscopic positive margins. With a 71% overall recurrence and 36% local

recurrence, analysis failed to reveal PNI, margin status, or tumor grade as predictors of survival despite an aggressive treatment strategy. Only 25% of recurrences survived longer than 24 months with salvage treatment. Given the high recurrence rate despite relatively high local control rate (65%), they considered treatment of sinonasal ACC palliative and recommended avoiding major morbidity during treatment.

While complete surgical resection with negative margins is often not feasible due to advanced disease at presentation and anatomic restrictions, other reports suggest a significant effect of achieving negative margins on the survival of patients. An analysis of 51 patients prospectively followed with ACC of the skull base revealed a significant role of achieving negative margins at the first surgical intervention.¹²⁰⁵ Even with piecemeal resection, there was an OS advantage of 20.1 ± 3.3 years compared with resections that left residual disease, even if microscopic (10.3 ± 1.6 years, $p = 0.035$). Notably, microscopic negative margins demonstrated a survival advantage compared to any positive margins. The surgical strategy included open or endoscopic approaches (in more recent cases) with the aim of achieving total resection without causing major

morbidity (described as carotid injury, need for bypass, stroke, fistula, and malocclusions). In a subset analysis of sinonasal primaries within international ACC consortium data ($n = 242$ patients), 5-year OS for patients with negative, close, and positive margins was 74%, 72%, and 41%, respectively, and 5-year DSS rates were 77%, 75%, and 40%, respectively, again emphasizing the impact on survival when able to achieve negative margins.¹²⁰⁶ In the international consortium study, adjuvant RT was administered to 57% of patients with negative margins and 68% and 78% with close or positive margins, which could obscure the impact of positive margins. Surgical debulking, which is typically discouraged in the head and neck, should also be considered in advanced cases of sinonasal ACC where the tumor involves critical organs (such as skull base, nerves, and orbit), and maximal removal of the tumor should be attempted. The literature does not have significant data on debulking, but delivery of RT to smaller field maybe a worthy goal and should be discussed as part of a multidisciplinary team.

EEA has become a preferred surgical approach for many cases, with the less aggressive resection aiming to preserve function and critical anatomy.^{106,494,1199,1205} EEA may be associated with shorter hospital stay and reduced complications.^{494,1199} In a retrospective study by Volpi et al. of 34 patients with sinonasal ACC, all underwent endoscopic resection with intent to cure and to achieve GTR.¹⁰⁶ Due to ASB involvement, five of these patients had extended endoscopic resection with a transnasal craniotomy. In these patients, the resection of the ASB included the ethmoidal roof and overlying dura from the posterior wall of the frontal sinus to the planum sphenoidale, and between the medial orbital walls. The defects were reconstructed with a multilayer technique, using autologous materials (fascia lata or iliotibial tract). Two out of the 34 patients underwent endoscopic nasopharyngectomy as well due to nasopharyngeal infiltration. All of the procedures achieved intraoperative clear surgical margins unless there was involvement of vital structures preventing further resection (i.e., vidian nerve at skull base and maxillary nerve at foramen rotundum). Eventually, all patients had GTR, but seven had positive surgical margins on histological examination. The 5- and 10-year OS were 86.5% and 66.8%, respectively. Positive histological margins were shown to correlate with worse survival outcome ($p = 0.014$) in this cohort even with GTR.¹⁰⁶ In a different cohort of 30 patients with sinonasal ACC undergoing EEA with preservation of key structures (orbital contents, optic nerves, carotid arteries, motor CNs) performed with removal of PPF contents (vidian, descending palatine, and infraorbital nerves) if involved, the majority (86.6%) of the cases were T4 disease and only 44.8% were described as “traditionally resectable.”¹¹⁹⁹ The endonasal

approach was supplemented with Caldwell-Luc approach in three patients or a Denker maxillectomy in two. With this organ preservation approach, negative margins and complete resection were achieved in only two patients. Nineteen patients (63.6%) had GTR with positive margins, while the remaining nine had STR with gross positive margins. No major complications were observed. All patients were recommended to receive adjuvant RT but two did not complete and four had missing data. While the mean follow-up time was only 3.97 years, this is one of the largest cohorts describing the outcomes of sinonasal ACC patients treated with an endoscopic approach. The OS rates at 5 and 10 years were 62.6% and 54.8%, and DFS rates at 5 and 10 years were 58.4% and 12.6%. Local and distant recurrence rates at 10 years were 36.8% and 69.5%, respectively. Margin status was not a factor in survival, but low-grade tumors did have longer survival.

Cohort studies of sinonasal ACC patients suggest that the site of origin is a significant factor affecting prognosis.^{75,77,79} A multicenter analysis of 99 patients revealed that in tumors originating from the nasal cavity or maxillary sinus, 5-year DSS was 83% and 64%, respectively, compared to 25% in patients with tumors originating from the sphenoid and ethmoid sinuses.⁷⁵ In another study of 105 sinonasal ACC patients, the nasal cavity and sphenoid subsites were associated with best and worst survival outcomes, respectively.⁷⁹ An NCDB review of 793 sinonasal ACC patients showed that tumors originating from the frontal sinus held worse prognosis in a multivariate analysis.³⁷⁶ Other factors limiting the ability to achieve negative margins are advanced tumor stage at presentation in more than 50% of the patients and the high prevalence of PNI.^{75,376,398,1198,1199} PNI is identified in most studies, but reporting varies in the literature. Volpi et al. identified PNI in 11% of cases, whereas Guazzo et al. found large nerve invasion in 62% and microinvasion in 97% of cases; Kashiwazaki et al. found PNI in 93%.^{494,106,1199} Mays et al. found 60% large nerve invasion and stated they do not record small nerve invasion because the finding was considered ubiquitous.³⁹⁸ The presence of nerve invasion and skip lesions also calls into question whether negative margins are truly ever obtained. These factors reflect the complexity in achieving negative surgical margins and great variability reported, with histological negative margins being achieved in only 6%–70% of cases.^{106,1199,1205} The lowest rate of positive margins was reported with endoscopic surgical series that also had a majority of lower stage tumors with 60% from T1–3 disease, and only 30% of patients had PNI.¹⁰⁶ Survival appears improved if gross negative, microscopic positive, or microscopic negative margins can be attained. In the largest single-institutional series of 160 patients with sinonasal ACC, surgical margins did not demonstrate a survival difference, but this was considered

to be due to the use of RT for advanced tumors and positive margins.³⁹⁸ Thus, while negative margins are ideal, close or microscopic margins with restraint around critical structures appear to provide similar outcomes in the setting of postoperative RT. Accordingly, ICSB 2019 reported an aggregate grade of evidence of C for primary surgery with consideration of adjuvant RT on a case-by-case basis.⁵

Role and extent of surgery in sinonasal ACC

Aggregate grade of evidence	C (Level 2: one study; Level 3: two studies; Level 4: 10 studies)
Benefit	Surgical resection is superior to any other modality in terms of local control and long-term survival.
Harm	Damage to vital structures or important organs (eye, carotid artery, brain, oral cavity), postoperative complications, and CN deficits.
Cost	No studies directly assessed cost. However, improved local control implies decreased future cost in terms of hospitalization, imaging, systemic therapy, and so forth.
Benefits-harm assessment	Preponderance of benefits over harms.
Value judgments	Endoscopic resection is associated with lower complication rates and improved QOL over the long term in select cases and is comparable to open approaches in terms of survival outcomes. Achieving negative margins will improve local control as well as improve OS. There is a high distant recurrence rate and risk of skip lesions in PNI. Given the high overall local control rate, a strategy of GTR and postoperative RT while preserving function provides QOL without reduction of survival.
Policy level	Recommendation.
Intervention	Surgical resection should be attempted as the first line of treatment when feasible, with the goal to achieve GTR (with negative surgical margins whenever possible) while preserving vital structures.

2 | Role of radiation therapy

While there are no RCTs on this topic, postoperative adjuvant RT is advocated as the standard of care, with emphasis on those with positive margins (microscopic or macroscopic) or advanced disease that infiltrates into adjacent structures.^{73,79,1198,1205,1207,1208} In patients with ACC of the head and neck overall, it has been observed that improved local control can be achieved with increased RT dose regardless of margin status, and the subsequent recom-

mendation is for a dose of at least 60 Gy to the tumor bed.^{1206,1208–1210}

Two retrospective cohorts from the same institution reviewed the cases of 105 patients with sinonasal ACC in 2007, and later on 160 patients in 2018, characterizing prognostic factors and treatment approach.^{79,398} Overall, surgical resection followed by adjuvant treatment offered the best OS in patients compared to RT or surgery alone. Surgical patients had improved OS and DFS when compared with those treated nonsurgically. The surgical approach varied among open (including radical resection and orbital exenteration in 7.6% of the patients), endoscopic, or combined. Large nerve PNI (40%–65% of the cases) was associated with higher recurrence rates and decreased OS.^{79,398} The extent of resection (STR or GTR with microscopic positive or negative margins) did not have any effect on OS or DFS, which might be in part due to the addition of adjuvant RT. RT was given as IMRT or proton therapy. RT doses were 66–70 Gy alone or with concurrent cisplatin chemotherapy for gross residual disease, 66 Gy for GTR with positive margins, and 60 Gy for negative margins.³⁹⁸

In several cohorts where adjuvant RT was recommended only for advanced-stage disease or positive margins, but not for early disease or negative margins, a clear trend toward better survival rates and better local control existed in the groups that received RT.^{79,106,1198,1211} Moreover, a multicenter study of 32 patients with advanced ACC with skull base involvement treated with surgical resection and adjuvant RT (17 originating from the paranasal sinuses) revealed a high 10-year LRC rate of 88.2% despite an 81.3% rate of positive surgical margins.⁴⁹⁴ In this study, the adjuvant RT doses were based on surgical margin status. Patients with negative margins received 54–56 Gy in 27–30 fractions, while those with positive margins were prescribed 63–66 Gy in 30–33 fractions. RT to critical organs such as brainstem, optic chiasm, and optic nerve was limited to 54 Gy and spinal cord to 45 Gy.⁴⁹⁴ Delivery techniques included three-dimensional conformal RT until 2008, and IMRT or volumetric modulated arc therapy after 2008. Complications following adjuvant RT included wound breakdown, ORN, and fistula.^{79,494}

One of the challenging aspects in radiation planning of the skull base is the risk to adjacent critical structures, which limits the dose of conventional photon radiation to the tumor region.^{538,1212,1213} Protons are charged particles with biological effectiveness like conventional photon radiation. Due to the Bragg peak, proton beam RT (PBRT) and carbon ion RT (CIRT) can provide a more precise dose distribution. This could potentially lead to improved local control and decreased acute and late toxic effects.¹²¹⁴ Compared with photon-based IMRT, this feature of PBRT improves the therapeutic ratio by introducing a sharp dose

gradient between the tumor volume and adjacent critical OARs.⁵⁵⁵ Particle beam RT results in a very encouraging local control rate in patients with ACC of the skull base. The first report of treatment with high-dose PBRT in ACC patients with skull base extension revealed 5-year local control rate of 93% and 5-year OS and DFS 77% and 56%, respectively.⁵³⁸ In a more recent retrospective analysis of intensity-modulated PBRT, CIRT, or combination therapy in 38 patients with sinonasal ACC, of which 94% had locally advanced disease (T3–4), the 3-year local control rate was 90% and 3-year OS and PFS were 96% and 80.6%, respectively.⁵⁵⁵ Reported treatment toxicities include optic neuropathy, neurological effects, and xerostomia.^{538,555}

To conclude, postoperative radiation may be delivered using conventional photon RT (e.g., IMRT) or PBRT. CIRT has shown promising rates of local control as adjuvant treatment and also for inoperable cases.⁵⁶⁸ In most cases, ACC is radiosensitive but not generally radiocurable disease, making RT an ineffective singular treatment modality.^{548,1215}

Role of adjuvant radiation therapy in sinonasal ACC

Aggregate grade of evidence	C (Level 2: one study; Level 3: two studies; Level 4: 10 studies)
Benefit	Postoperative RT improves local control rates and survival outcomes.
Harm	Acute and late toxicities.
Cost	No studies directly assessed cost. However, improved local control implies decreased future cost in terms of hospitalization, imaging, systemic therapy, and so forth.
Benefits-harm assessment	Preponderance of benefits over harms.
Value judgments	In patients with adverse features and positive surgical margins, adjuvant RT effect on local control is crucial. While RT as the primary treatment was not extensively studied and was usually reserved for unresectable cases, adjuvant RT shows clear survival benefit and a better local control trend in all patients, especially with positive surgical margins.
Policy level	Recommendation.
Intervention	Adjuvant postoperative RT should be recommended in all cases, with special importance in cases of advanced-stage disease, positive margins, and PNI.

3 | Role of chemotherapy

The role of chemotherapy in the treatment of sinonasal ACC is not well studied, with paucity of cases treated with chemotherapy. Most commonly, chemotherapy is

reserved for palliation in cases of unresectable tumors or metastatic disease; chemotherapeutic agents such as cisplatin, adriamycin, 5-fluorouracil, doxorubicin, and carboplatin have been proposed mostly for palliation when tumor resection is difficult or when faced with rapidly progressing tumor.^{73,79,377,408,1198} There are no dedicated prospective studies on chemotherapy for sinonasal ACC. Table XXII.C.1 summarizes evidence for treatment in sinonasal ACC.

E | Other salivary gland malignancies

1 | Mucoepidermoid carcinoma

Sinonasal mucoepidermoid carcinoma (MEC) is rare, comprising approximately 1.5% of all SNMs.¹²¹⁶ Patients with sinonasal MEC are mostly middle-aged and White.^{411,1217,1218} There is no clear gender predilection.⁴¹¹ Patients usually present with a nasal mass or symptoms of nasal obstruction. A large proportion of cases originate in the maxillary sinus (45.6%–52.6%) or nasal cavity (31.6%–41.0%), which is thought to reflect the proportion of seromucinous glands present in these areas.^{411,1217,1218} Many patients present with advanced-stage disease (Stage 3 or 4) (44.8%–54.5%).^{411,1217}

Surgical resection is the primary treatment of sinonasal MEC and has been shown to be a significant predictor of survival.⁴¹¹ In the included studies, 57%–100% of cases underwent surgical resection.^{411,1217–1219} Although achieving negative margins is associated with improved 5-year OS and median OS when compared to cases of positive margins, this was not a statistically significant finding in a retrospective review of 239 cases in the NCDB.⁴¹¹ A significant proportion of patients required preoperative or postoperative RT (10.5%–61.0%).^{411,1217–1219} In cases of surgical resection with negative margins, the addition of postoperative RT has been shown to be associated with improved survival.⁴¹¹ This association is not present, however, in cases of positive surgical margins. Chemotherapy is less utilized in the treatment of sinonasal MEC (0%–16.3%).^{411,1217–1219} In two small case series, the rate of recurrence was found to range from 28.6% to 31.6%.^{1218,1219}

Larger retrospective reviews have found the 5-year OS of patients with sinonasal MEC to range from 57.0% to 64.1%.^{411,1217} Several patient and tumor characteristics have been identified to influence survival. A review of the NCDB found that insurance status (specifically Medicaid), advanced T stage, and advanced nodal disease were associated with worse OS.¹²¹⁷ Other factors shown to be associated with worse OS include patient residence in an urban or rural area, primary tumor in the sphenoid sinus, high-grade tumors, and age >70 years.⁴¹¹ In a small case

TABLE XXII.C.1 Evidence for extent of surgery and adjuvant therapy in sinonasal ACC.

Study	Year	LOE	Study design	Study groups	Clinical endpoints	Conclusion
Husain et al. ⁷³	2013	2	Systematic review and meta-analysis	Compiled data of sinonasal ACC patients treated with different therapeutic combinations (<i>n</i> = 88 encompassing 55 studies)	OS	Surgery followed by adjuvant RT was correlated with the highest survival outcomes
Amit et al. ⁷⁵	2013	3	Systematic review and meta-analysis of retrospective case series	Sinonasal ACC patients treated with surgical resection with or without adjuvant treatment (<i>n</i> = 520)	1. OS 2. DFS	Negative surgical margins and tumor origin from nasal cavity or maxillary sinus are correlated with improved survival
Lupinetti et al. ⁷⁹	2007	3	Retrospective cohort	Sinonasal ACC patients treated with primary surgical excision or RT/CRT (<i>n</i> = 105)	1. OS 2. DSS 3. Local control	1. Surgery with postoperative RT provides the best OS and DSS compared with other treatment modalities 2. Primary treatment with surgery as opposed to RT or chemotherapy significantly improved survival
Kashiwazaki et al. ¹¹⁹⁹	2020	4	Retrospective case series	Endoscopic surgical resection with adjuvant RT for patients with sinonasal ACC (<i>n</i> = 30)	1. OS 2. DFS	Organ-preserving EEA with adjuvant RT for sinonasal ACC patients with low-grade tumors has similar OS outcome as open approach with more aggressive resection
Guazzo et al. ⁴⁹⁴	2019	4	Retrospective multicenter review	Patients with sinonasal ACC treated surgically with endoscopic, open, or combined approach followed by adjuvant RT (<i>n</i> = 32)	1. OS 2. RFS	1. Surgical resection when feasible is the treatment of choice even without achieving clear margins 2. Adjuvant therapy improves survival and local control
Volpi et al. ¹⁰⁶	2019	4	Retrospective case series	Endoscopic surgical resection with or without adjuvant RT for patients with sinonasal ACC (<i>n</i> = 34)	1. OS 2. DSS 3. RFS	1. Endoscopic approach when feasible has comparable outcomes to open approach 2. Negative surgical margins and adjuvant RT are associated with improved survival rates
Trope et al. ³⁷⁶	2019	4	Retrospective, NCDB database study	Patients with sinonasal ACC treated with either surgery, RT, or chemotherapy (<i>n</i> = 793)	OS	1. Surgery was the only predictor for improved OS 2. Frontal sinus primary site, positive margins, poorly differentiated or undifferentiated tumor grade, and advanced tumor stage were associated with worse OS

(Continues)

TABLE XXII.C.1 (Continued)

Study	Year	LOE	Study design	Study groups	Clinical endpoints	Conclusion
Unsal et al. ¹²⁰⁰	2017	4	Retrospective, population-based cohort study	Patients with sinonasal ACC treated with either surgery, RT, or surgery and adjuvant RT (<i>n</i> = 694)	DSS	Surgical resection associated with improved DSS.
Michel et al. ⁴⁰⁸	2013	4	Retrospective case series	Sinonasal ACC patients treated with surgical resection and adjuvant RT or combination of RT and chemotherapy (<i>n</i> = 25)	OS	Treatment with surgery and adjuvant RT is associated with improved 5-year survival compared to patients treated by exclusive RT or concomitant CRT
Rhee et al. ¹¹⁹⁸	2006	4	Retrospective case series	Sinonasal ACC patients treated with surgical resection or RT/CRT (<i>n</i> = 35)	1. OS 2. Local control	1. Adjuvant RT decreases local recurrence rates 2. Significant predictors for worse survival were T stage and distant metastasis
Wiseman et al. ³⁷⁷	2002	4	Retrospective case series	Sinonasal ACC patients treated with surgical resection or RT/CRT (<i>n</i> = 35)	1. OS 2. DFS	Negative surgical margins improve local control rates
Naficy et al. ¹²⁰³	1999	4	Retrospective case control	Surgical resection with adjuvant RT versus RT alone as treatment for patients with sinonasal ACC (<i>n</i> = 17)	OS	Surgery with adjuvant therapy group had better survival outcome than RT only, though this was not significant
Pitman et al. ¹²⁰⁴	1999	4	Retrospective case series	Sinonasal ACC patients treated with surgery with adjuvant RT (<i>n</i> = 35)	DFS	Local recurrence after surgery is associated with poor prognosis

Abbreviations: ACC, adenoid cystic carcinoma; CRT, chemoradiation therapy; DFS, disease-free survival; DSS, disease-specific survival; OS, overall survival; RT, radiation therapy.

series of 19 patients, several factors were identified to be associated with poorer DSS including high mitotic count, recurrent disease, high tumor grade, and higher tumor stage.¹²¹⁸ Modality of treatment and treatment sequence were not shown to significantly impact survival.¹²¹⁷

2 | Acinic cell carcinoma

Acinic cell carcinoma (AciCC) is also a rare, epithelial salivary gland-based malignancy with documented primary involvement in the paranasal sinuses and nasal cavity. In 2014, Biron et al. published the largest study to date of sinonasal AciCC by utilizing the SEER database analyzing demographic, tumor characteristic, and survival data from 18 patients from 1973 to 2009.¹²²⁰ At the time of that

publication, there had been only 19 prior cases of sinonasal AciCC reported in the English language literature in the form of primarily case reports. The mean age of diagnosis was 56.2 years, and most patients were White (77.8%). There was no sex predilection, although 61% of patients were female when looking at the previous case reports. All tumors from the Biron et al. study were classified as either T1 or T2 stage, with no cases with nodal or distant metastases. All tumors were histologically noted to be low grade. The most common subsite identified was the nasal cavity (50%), followed by the ethmoid sinus (22.2%), accessory sinus not otherwise specified (16.6%), maxillary sinus (5.6%), and overlapping lesions of the ethmoid and maxillary sinus (5.6%).

Surgical intervention was the primary offered treatment in 81.3% of cases with 18.7% also undergoing adjuvant RT.

TABLE XXII.D.1 Evidence for management of sinonasal mucoepidermoid and acinic cell carcinoma.

Study	Year	LOE	Study design	Study groups	Clinical endpoints	Conclusion
Auger et al. ⁴¹¹	2020	4	Retrospective database analysis (NCDB)	Cases of sinonasal MEC (<i>n</i> = 239)	OS	<ol style="list-style-type: none"> Achieving negative surgical margins is associated with improved OS, although this is not statistically significant In this group, adjuvant RT is associated with improved survival
Triantafyllou et al. ¹²¹⁷	2019	4	Retrospective database analysis (NCDB)	Cases of sinonasal MEC (<i>n</i> = 164)	OS	<ol style="list-style-type: none"> Insurance status, advanced T stage, and nodal stage were associated with worse OS Treatment modality and sequence were not associated with survival
Biron et al. ¹²²⁰	2014	4	Retrospective case-control analysis of the SEER database	Matched cohorts of cases of parotid gland AciCC and sinonasal AciCC (<i>n</i> = 18)	5- and 10-year: 1. OS 2. DSS	DSS of sinonasal AciCC did not significantly differ from parotid AciCC.
Wolfish et al. ¹²¹⁸	2011	4	Retrospective case series	Cases of sinonasal MEC (<i>n</i> = 19)	DSS	Large tumor size, high mitotic count, mixed anatomic site, high tumor grade, and higher stage are associated with worse DSS
da Cruz Perez et al. ¹²¹⁹	2006	4	Retrospective case series	Comparison of cases of maxillary sinus MEC (<i>n</i> = 7) and ACC (<i>n</i> = 18)	DSS	Patients with MEC had improved OS compared to those with ACC
Bhattacharyya ¹²¹⁶	2003	4	Retrospective case-control analysis of the SEER database	Comparison of cases of maxillary sinus non-SCC versus SCC (<i>n</i> = 188)	OS	<ol style="list-style-type: none"> Cases of non-SCC carcinoma had worse OS MEC cases had median OS of 53 months

Abbreviations: ACC, adenoid cystic carcinoma; AciCC, acinic cell carcinoma; DSS, disease-specific survival; MEC, mucoepidermoid carcinoma; NCDB, National Cancer DataBase; OS, overall survival.

The 5- and 10-year OS was noted to 82.1% and 52.3% and the DSS was 100% and 88.9%, respectively. Biron et al. also performed a grouped analysis of the previously documented cases in the literature and found an estimated 10-year RFS of 92.9%. Table XXII.D.1 summarizes evidence for management of sinonasal MEC and AciCC.

XXIII | SINONASAL SARCOMA

A | Rhabdomyosarcoma

Rhabdomyosarcoma (RMS) is overall a rare primary tumor. It is more common in the pediatric population, representing 7% of childhood cancers, and it is the most common extracranial soft tissue tumor of children.¹²²¹ In contrast, RMS represents 1% of adult malignancies. Nine-

teen percent of these occur in the head and neck, compared to 40% of pediatric RMS.¹²²² Different subtypes of RMS have been recognized, with new subtypes added over time. In the 5th edition of the WHO classification of soft tissue tumors there are four recognized subtypes: embryonal, alveolar, sclerosing/spindle cell, and pleomorphic.¹⁷ Sclerosing RMS is exceedingly rare, and pleomorphic RMS is generally treated like a non-RMS soft tissue sarcoma. Further subtypes have been described based on specific gene fusions.¹²²³ The embryonal subtype is the most common subtype. It usually occurs in children under 5 years old, although it can arise in adults as well. Botryoid RMS is considered a morphological subtype of this subtype, which presents as a polyp and has a better prognosis. Alveolar is the most undifferentiated subtype and is more aggressive than other subtypes. It is most common in adolescents and young adults.¹²²³

1 | Classification and staging

RMS utilizes unique staging systems that are distinct from those used for other soft tissue sarcomas. The most commonly used are the Intergroup Rhabdomyosarcoma Study Group (IRSG) systems, which utilize clinicopathologic stages to categorize patients into prognostic groups.^{1224,1225}

For head and neck RMS, consideration is also given to the specific location of the primary tumor. This is divided into parameningeal (PM), non-parameningeal (non-PM), and orbital. PM head and neck sites include the nasal cavity and paranasal sinuses, as well as the nasopharynx, parapharyngeal space, ITF, PPF, middle ear, and mastoid cavity. Recent studies have suggested that not all subsites within PM RMS carry similar prognosis and have suggested subdividing favorable and unfavorable PM sites. Unfavorable PM sites include the paranasal sinuses, ITF, and PPF. The nasal cavity and non-PM head and neck and orbital RMS, on the other hand, are generally associated with more favorable prognosis.

The IRSG defined four clinical risk groups based on extent of disease and resection in the Intergroup Rhabdomyosarcoma Study-I (IRS-I) clinical trial^{1226,1227}:

- Clinical Group 1: localized disease without regional metastases that is completely excised (R0 resection);
- Clinical Group 2: grossly resected tumor with microscopic residual disease (R1 resection) and/or presence of pathologically positive regional lymph node disease that is completely resected;
- Clinical Group 3: incompletely resected tumor (R2 resection) or biopsy with gross residual disease;
- Clinical Group 4: distant metastases.

IRSG has also proposed a pretreatment staging system based on primary tumor site, tumor size, regional lymph node status, and metastatic disease.¹²²⁸ In this staging system, sinonasal RMS without distant metastases would fall into stage 2 or 3 as it is an unfavorable site. Clinical trials of RMS have utilized combinations of IRSG clinical risk group, IRSG stage, TNM stage, and size to separate tumors into specific treatment arms.

2 | Role of surgery in pediatric rhabdomyosarcoma

While there are several clinical trials in RMS, none have examined the role of surgery as randomization typically starts after initial surgery or biopsy, and current evidence is based on retrospective studies (Table XXIII.A.1). These studies did not show a survival benefit with surgery. Interpretation of this is limited as both studies did not have clear selection criteria for surgery and were retrospective. In the

study by Siddiqui et al., the timing of surgery (i.e., primary vs. salvage) was not available in the database review, further limiting interpretation.¹²²⁹

Some groups have advocated for primary surgery for resectable tumors that would result in minimal functional or cosmetic deficits and against initial aggressive surgical management.^{1224,1230} Siddiqui et al. noted a survival difference according to IRSG group: 85.7%, 80%, 40%, and 24.4% for groups 1–4, respectively ($p = 0.047$).¹²²⁹ These data demonstrate that there is generally favorable OS with select tumors resected with clear margins (i.e., IRSG group 1), though this was not found to be an independent prognosticator on multivariate analysis. Furthermore, there are likely few patients who present with surgically resectable tumors; in the Siddiqui et al. study, which utilizes the NCDB database, there were only 13 total IRSG group 1 or 2 patients out of 157 patients total.¹²²⁹ Clinical trials have similarly shown that a majority of sinonasal RMS tumors are IRSG group 3.^{1225,1226,1231} It is also worth noting that many of the surgical advances that have allowed for minimally invasive endoscopic approaches may not be possible in young children due to anatomic limitations.

Role of surgery in pediatric rhabdomyosarcoma

Aggregate grade of evidence	C (Level 4: three studies)
Benefit	Possibility of additional survival benefit with upfront or salvage surgery.
Harm	Risk of surgical complications including anesthetic risks, blood loss, infection, CSF leak, and orbital injury. Potential for significant morbidity and disfigurement for locally advanced tumors.
Cost	Additional cost of surgery and perioperative care.
Benefits-harm assessment	Balance of benefits and harms.
Value judgments	Minimally invasive endoscopic approaches are limited by pediatric sinonasal anatomy. Studies do not differentiate between upfront and salvage surgery.
Policy level	Option.
Intervention	There is limited evidence to support routine upfront surgical intervention. May consider in salvage setting.

3 | Role of radiation therapy in pediatric rhabdomyosarcoma

In clinical trials of pediatric RMS, the majority of parameningeal tumors have been treated with RT in combination with chemotherapy. The timing, dose, and frac-

TABLE XXIII. A.1 Evidence surrounding role of surgery in pediatric rhabdomyosarcoma.

Study	Year	LOE	Study design	Study groups	Clinical endpoints	Conclusion
Kana et al. ¹²³⁸	2022	4	Retrospective case series	Five of 12 pediatric RMS patients underwent primary surgery	1. OS 2. Margin status	Four had R0 resection, one underwent debulking Two had positive margins
Siddiqui et al. ¹²²⁹	2019	4	Retrospective database study (NCDB)	CRT ($n = 83$) versus CRT + surgery ($n = 48$)	OS	1. No OS difference between those receiving surgery and those who did not 2. Timing of surgery not specified
Fyrmpas et al. ¹²³⁰	2009	4	Retrospective case series	CRT ($n = 6$) versus CRT + primary surgery ($n = 8$)	OS	Patients with sinonasal RMS who underwent surgery had higher OS, but this was not statistically significant

Abbreviations: CRT, chemoradiation therapy; OS, overall survival; RMS, rhabdomyosarcoma.

tionation of RT have differed according to study group protocol. RT was given to all patients with the exception of certain patients in MMT-84 and MMT-89 trials who were very young, had a low risk of meningeal involvement, or had a complete response after chemotherapy. In a systematic review of these trials, there was significant survival difference between those who received RT and those who did not.¹²²⁵ Additionally, the IRS-IV trial randomized IRSG group 3 parameningeal RMS (PM-RMS) to conventional and hyperfractionated regimens. There was no significant survival difference between the two arms.¹²²⁶

A single study examined whole-brain irradiation, which was used according to high-risk PM-RMS features. In the IRS trials, there was a gradual move away from whole-brain irradiation. In the early trial period of IRS-II, patients with cranial nerve palsy, skull base erosion, or intracranial extension received whole-brain and spine RT. In late IRS-II and IRS-III trials, whole-spine RT was omitted. Also, in IRS-III, IRSG groups 1 and 2 had whole-brain RT omitted, unless there was intracranial extension. In IRS-IV, whole-brain RT was omitted for all. Raney et al. demonstrated no survival benefit with the addition of whole-brain RT for cranial nerve palsies, skull base erosion, or intracranial extension (Table XXIII.A.2).¹²²⁴

Role of radiation therapy in pediatric rhabdomyosarcoma

Aggregate grade of evidence	B (Level 2: one study, Level 3: three studies)
Benefit	Improved survival with use of RT in primary treatment modality.

(Continued)

Harm	Acute and long-term radiation complications. Risk of secondary malignancy for pediatric patients.
Cost	Additional cost of RT.
Benefits-harm assessment	Preponderance of benefits over harms.
Value judgments	Vast majority of sinonasal RMS are higher risk (IRSG 2 or 3) and unlikely to have complete tumor clearance with surgery alone. Failure to show survival benefit with use of whole-brain radiation despite hypothetical benefit of reducing local recurrence.
Policy level	Recommendation.
Intervention	Primary RT, with or without chemotherapy, for pediatric sinonasal RMS is first-line therapy. Whole-brain radiation for high-risk PM-RMS is not recommended.

4 | Role of chemotherapy in pediatric rhabdomyosarcoma

The body of evidence for treatment of pediatric RMS has come from large clinical trial groups: initially IRSG, later Children's Oncology Group (COG, North America), Cooperative Weichteilsarkom Studiengruppe (CWS, Europe), and International Society of Pediatric Oncology Malignant Mesenchymal Tumors group (MMT, Europe). These trials have often used different risk-stratified chemotherapy protocols according to recurrence risk, and RMS tumors with similar risk were grouped together into a stage. Staging has differed between trial groups and has changed over time within the same trial group. Most often, sinonasal RMS has been grouped with other PM-RMS or with RMS from other body sites with a similar histology and IRS group.

TABLE XXIII. A. 2 Evidence surrounding role of radiation therapy in pediatric rhabdomyosarcoma.

Study	Year	LOE	Study design	Study groups	Clinical endpoints	Conclusions
Merks et al. ¹²²⁵	2014	2	Systematic review and meta-analysis	10 studies, RT (<i>n</i> = 1004) versus no RT (<i>n</i> = 89)	OS	1. 5-year OS 71.4% versus 49.6% (<i>p</i> < 0.0001) 2. RT as part of initial treatment is beneficial for PM-RMS
Raney et al. ¹²²⁴	2002	3	Prospective cohort	Risk-stratified protocol, all received local RT Whole-brain RT variably administered for high-risk meningeal involvement (<i>n</i> = 526)	OS	1. 5-year OS 73% for patients receiving RT 2. 5-year EFS 67%
Raney et al. ¹²²⁸	2002	3	Prospective cohort	Whole-brain RT versus no whole-brain RT in PM-RMS with high-risk meningeal involvement (<i>n</i> = 360)	OS	No additional benefit to whole-brain RT for localized PM-RMS with CNP, SBE, or ICE
Crist et al. ¹²²⁸	2001	3	Prospective cohort	Conventional RT (<i>n</i> = 251) versus hyperfractionated RT (<i>n</i> = 239)	OS	No difference between conventional and hyperfractionated RT for IRSG group 3 RMS

Abbreviations: CNP, cranial nerve palsy; EFS, event-free survival; ICE, intracranial extension; OS, overall survival; RMS, rhabdomyosarcoma; RT, radiation therapy; SBE, skull base erosion.

Of note, while these are pediatric studies, some trials have included young adults in their treatment with an age cutoff of 21.

Table XXIII.A.3 outlines the trials and their most relevant findings. Within a single trial, patients may be treated with the same chemotherapy protocol (i.e., prospective cohort) or randomized to different chemotherapy protocols (i.e., RCT). Results specific to tumor site are presented when available, and comparisons are summarized below:

- VAC versus intensified protocols: two RCTs compared VAC to intensified chemotherapy protocols that included doxorubicin.^{1227,1232} These groups included a majority of PM-RMS and showed no survival benefit to additional chemotherapy. One RCT compared VAC to VAC/VTC for intermediate-risk PM-RMS with no difference in survival.¹²³³
- VAI/VAIA versus CEVAIE: one RCT compared VAI to an intensified six-drug chemotherapy protocol without difference in survival.¹²³⁴ In another RCT, VAIA was compared to CEVAIE.¹²³¹ For PM-RMS tumors, there was a significant difference in EFS (combined outcome including recurrence, progression, or death). There was no difference in OS, and within the entire cohort that

included other sites, there was no significant difference in EFS and OS.

- VAC versus VAI: one RCT compared VAC to VAI to a third chemotherapy protocol.¹²²⁶ There was no significant difference in survival between the three regimens.
- Intrathecal chemotherapy: one study reviewed effects of increased doses of intrathecal chemotherapy for high-risk PM-RMS. Intrathecal chemotherapy consisted of methotrexate, hydrocortisone, and cytarabine. It was administered for patients with cranial nerve palsies, intracranial extension, or skull base erosion. From 1978 to 1987 (IRS-II and early IRS-III), the dosing protocol consisted of 13 courses of intrathecal chemotherapy. From 1987 to 1991 (IRS-III), the protocol was adjusted by age and the total duration was decreased to four courses. After 1991 (IRS-IV), no intrathecal chemotherapy was administered. When comparing zero to seven to 13 doses of chemotherapy, there was no difference in OS between the three groups.¹²²⁴

In summary, the available evidence shows similar survival with VAC- or VAI-based chemotherapy protocols. Intensified chemotherapy protocols have not demonstrated additional survival benefit. While sinonasal RMS was represented within PM-RMS, extrapolation should be

TABLE XXIII. A. 3 Evidence surrounding role of chemotherapy in pediatric rhabdomyosarcoma.

Study	Year	LOE	Study Design	Study groups	Clinical endpoints	Conclusions
Sparber-Sauer et al. ¹²³¹	2022	2	Randomized controlled trial	Four-drug (VAIA) (<i>n</i> = 78) versus six-drug chemo (CEVAIE) (<i>n</i> = 75) in PM-RMS	1. OS 2. EFS 3. Grades 3/4 toxicities	1. Improved EFS for PM-RMS but no difference in EFS or OS in entire cohort 2. No difference in grade 3/4 toxicities
Oberlin et al. ¹²³⁴	2012	2	Randomized controlled trial	IVA (<i>n</i> = 86) versus six-drug chemo (CEVAIE) combo (<i>n</i> = 83) in PM-RMS All patients <3 years of age assigned to CEVAIE	1. OS 2. EFS 3. Toxicities	1. No difference in survival between three- and six-drug regimens 2. Higher rates of grade 3/4 leukopenia, neutropenia, thrombocytopenia, and stomatitis in six-drug regimen cohort including all nonmetastatic RMSs
Arndt et al. ¹²³³	2009	2	Randomized controlled trial	VAC (<i>n</i> = 302) versus VAC/VTC (<i>n</i> = 292) in intermediate-risk RMS	OS	No overall survival difference between two chemotherapy regimens
Crist et al. ¹²²⁶	2001	2	Randomized controlled trial	VAC (<i>n</i> = 235) versus VAI (<i>n</i> = 222) versus VIE (<i>n</i> = 236) in RMS, IRS stage 2/3	FFS	No difference according to chemotherapy regimen for cohort that included IRSG 2 and 3 PM-RMS
Crist et al. ¹²³²	1995	2	Randomized controlled trial	VAC (<i>n</i> = 58) versus VACA and cisplatin (<i>n</i> = 113) versus VACA, cisplatin, and etoposide (<i>n</i> = 118) in RMS IRSG 3	1. OS 2. PFS 3. CR	No difference in CRS or survival among the three chemotherapy regimens
Maurer et al. ¹²²⁷	1993	2	Randomized controlled trial	Randomized chemotherapy protocol Received VAC or VACA (<i>n</i> = 144) in PM-RMS IRSG 3	1. OS 2. CR	1. 5-year OS of 67% in cohort of PM-RMS patients receiving chemotherapy 2. 5-year CR: 73% 3. No difference between two chemotherapy regimens
Koscielniak et al. ¹²⁴⁶	2022	3	Prospective cohort	Risk stratified. IVA: Standard (embryonal, NO PM-RMS). VAIA ± maintenance: other higher risk PM-RMS (<i>n</i> = 114)	EFS	1. 5-year EFS of 65% for all PM-RMSs in cohort 2. Different chemotherapy regimen depending on RMS type and nodal disease
Arndt et al. ¹²³³	2009	3	Prospective cohort	VAC (<i>n</i> = 101) in PM-RMS with intracranial extension	1. OS 2. FFS	4-year OS of 71% and 4-year FFS of 68% in patients with PM-RMS with intracranial extension

(Continues)

done cautiously. The majority of patients in these studies were IRSG 3, meaning they either did not have initial surgery or had unresectable disease. Additionally, other studies have shown that not all subsites of PM-RMS carry similar prognosis and have suggested subdivision into

favorable and unfavorable PM site. Unfavorable PM sites include paranasal sinus, infratemporal fossa, and PPF, while nasal cavity is a favorable PM site.^{1224,1225} Intrathecal chemotherapy does not appear to confer survival benefit in high-risk PM-RMS.

TABLE XXIII.A.3 (Continued)

Study	Year	LOE	Study Design	Study groups	Clinical endpoints	Conclusions
Stevens et al. ¹²⁴⁴	2005	3	Prospective cohort	Group 1: IVA, CEV, IVE (induction) RT if less than CR (<i>n</i> = 27) in PM-RMS, <3 years of age Group 2: IVA or IVA + CEV All received RT (<i>n</i> = 85) in PM-RMS, ≥3 years of age	1. OS 2. EFS	1. Group 1: 5-year OS of 59%, 33% 5-year EFS in cohort treated with induction chemotherapy protocol 2. Group 2: 5-year OS of 65%, 62% 5-year EFS in cohort treated with CRT
Raney et al. ¹²²⁴	2002	3	Prospective cohort	Doses of intrathecal chemotherapy for PM-RMS with meningeal involvement, zero doses versus four versus 13 (<i>n</i> = 360)	OS	No OS benefit with administration of intrathecal chemotherapy ^a
Crist et al. ¹²²⁶	2001	3	Prospective cohort	Risk stratified protocol, all received chemotherapy (<i>n</i> = 222) in PM-RMS	FFS	No change in FFS from previous IRS studies for PM-RMS
Koscielniak et al. ¹²⁴⁷	1999	3	Prospective cohort	VAIA, adjuvant treatment based on response All received RT (<i>n</i> = 51) in PM-RMS stage 3	EFS	1. 5-year EFS 59% 2. 95% of PM-RMSs were Stage 3
Flamant et al. ¹²⁴³	1998	3	Prospective cohort	Low-risk PM-RMS: Induction IVA then IVA if PR or DP if less than PR High-risk PM-RMS, >5 years of age: same as low-risk except addition of RT after induction High-risk PM-RMS, <5 years of age: Induction IVA then IVA if PR or DP if less than PR If CR, then continued chemotherapy. If less than CR, then RT (<i>n</i> = 41) ^b	1. OS 2. EFS	1. 5-year OS of 58% for entire PM-RMS cohort 2. There were no low-risk PM-RMSs that were completely excised and only 22% were low-risk PM-RMSs
Crist et al. ¹²³²	1995	3	Prospective cohort	Risk stratified protocol, all received chemotherapy (<i>n</i> = 121) in PM-RMS IRSG 3	PFS	5-year PFS of 69% in cohort of PM-RMS patients

(Continues)

TABLE XXIII.A.3 (Continued)

Study	Year	LOE	Study Design	Study groups	Clinical endpoints	Conclusions
Koscielniak et al. ¹²⁴⁸	1992	3	Prospective cohort	VACA, adjuvant treatment based on response VACA or VAIA (<i>n</i> = 34) in PM-RMS IRSG 2 and 3	DFS	1. 5-year DFS 47% 2. 94% of PM-RMSs stage 3

Abbreviations: CEV, carboplatin + epirubicin + vincristine; CEVAIE, carboplatin + epirubicin + vincristine + actinomycin-D + ifosfamide + etoposide; CR, complete response rate; DFS, disease-free survival; DP, doxorubicin + cisplatin; EFS, event-free survival; FFS, failure-free survival; IVA/VAI, ifosfamide + vincristine + actinomycin D; IVAd, ifosfamide + vincristine + doxorubicin; IVE, ifosfamide + vincristine + etoposide; PFS, progression-free survival; VACA, vincristine + dactinomycin + cyclophosphamide + doxorubicin; VAIA, vincristine + dactinomycin + ifosfamide + doxorubicin.

^aFive-year OS values measured from figure survival curves.

^bHigh-risk PM-RMS defined as skull base erosion, cranial nerve palsy, or intracranial extension.

Role of chemotherapy in pediatric rhabdomyosarcoma

Aggregate grade of evidence	B (Level 2: six studies; Level 3: nine studies)
Benefit	Gradual improvement in survival in more recent studies with VAC or VAI protocol.
Harm	Chemotherapy side effects including pancytopenia and stomatitis. Some studies show higher rates of grade 3 and 4 toxicities with more aggressive chemotherapy regimens.
Cost	Cost of chemotherapy administration.
Benefits-harm assessment	Preponderance of benefits over harms.
Value judgments	There are no direct comparisons between chemotherapy and nonchemotherapy treatments. Failure to show survival benefit with addition of intrathecal chemotherapy.
Policy level	Recommendation
Intervention	Administer VAC- or VAI-based chemotherapy protocols in treatment of sinonasal RMS. Intrathecal chemotherapy for sinonasal RMS is not recommended.

5 | Role of surgery in adult rhabdomyosarcoma

Six studies were identified that included surgery treatment of adult RMS patients. All were retrospective and included both pediatric and adult patients. In three studies, there was no difference in outcomes between surgical and nonsurgical management options.^{119,1235,1236} The timing of surgery was not clear, and surgical selection criteria were not available. Li et al. described their experience in a primarily adult population.¹²³⁷ The 5-year OS for this cohort was 46.5%. Notably, the survival for these patients is worse than that reported in IRS clinical trials (5-year

OS of 73%).¹²²⁴ However, more recent data suggest a possible benefit in DMFS.¹²³⁸ The survival difference may be attributable to a higher ratio of adult patients with more aggressive histology, though this was not analyzed in the study. One additional study showed complete response in a limited number of patients who had an R0 surgical resection (Table XXIII.A.4).

Role of surgery in adult rhabdomyosarcoma

Aggregate grade of evidence	C (Level 4: six studies)
Benefit	Comparable survival between surgical and nonsurgical approaches.
Harm	Risk of surgical complications including anesthetic risks, blood loss, infection, CSF leak, and orbital injury. Potential disfiguring surgery for locally advanced cases.
Cost	Additional costs of surgery, perioperative care, and long-term postoperative care.
Benefits-harm assessment	Balance of benefits and harms.
Value judgments	Patients treated with upfront surgery or surgery alone are likely to be highly selected for less aggressive, resectable tumors. Most studies do not differentiate between upfront and salvage surgery.
Policy level	Option.
Intervention	May consider surgery in highly selected patients with resectable tumors and in salvage setting.

6 | Role of chemoradiation therapy in adult rhabdomyosarcoma

Only one study was identified that examined RT control rates prior to 2005 (pre-IMRT) and after 2005 (IMRT era) for nonmetastatic head and neck RMS. No patients

TABLE XXIII.A.4 Evidence surrounding role of surgery in adult rhabdomyosarcoma.

Study	Year	LOE	Study design	Study groups	Clinical endpoints	Conclusions
Kana et al. ¹²³⁸	2022	4	Retrospective cohort	Eight of 17 adult RMS patients underwent primary surgery	1. OS 2. Margin status	1. Surgery associated with improved DMFS 2. Eight of 13 patients had R0 resection 3. Surgical salvage employed for five patients
Barthere et al. ¹²⁴⁹	2020	4	Retrospective case series	Surgery with R0 resection ($n = 5$), adjuvant RT in adult PM-RMS	1. CR 2. Metastases	CR: 100% and metastases: 20%
Li et al. ¹²³⁷	2019	4	Retrospective case series	Surgery for resectable tumor with adjuvant therapy and possible salvage surgery in both adult and pediatric RMS ($n = 40$)	OS	46.5% OS in cohort treated with upfront surgical approach for resectable tumors
Unsal et al. ¹¹⁹	2017	4	Population-based database study (SEER)	Chemo alone ($n = 21$) versus surgery alone ($n = 25$) versus RT alone ($n = 107$) versus surgery and RT ($n = 55$)	DSS	1. 5-year DSS: 17.7% versus 50.8% versus 36.7% versus 35.9% ($p = 0.0595$) 2. Surgery alone group had best survival but not statistically significant
Thompson et al. ¹²³⁵	2013	4	Retrospective case series	CRT ($n = 10$) versus CRT + surgery ($n = 6$)	1. Recurrence 2. Mortality	No difference in rate of recurrence or death with surgery in addition to CRT
Sercarz et al. ¹²³⁶	1994	4	Retrospective case series	Surgery ($n = 1$) versus surgery + RT ($n = 3$) versus CRT ($n = 10$)	1. LRC 2. Distant control	1. LRC: 0% versus 66% versus 100%; distant control: 100% versus 33% versus 30% 2. Small single-institution case series without statistical analysis

Abbreviations: CRT, chemoradiation therapy; DSS, disease-specific survival; LRC, locoregional control; LRFS, locoregional failure/recurrence-free survival; OS, overall survival; RMS, rhabdomyosarcoma.

with sinonasal RMS underwent surgery. Compared to the pre-IMRT era, there was a lower locoregional recurrence rate with IMRT. In the IMRT group, a single sinonasal locoregional recurrence was observed in the study population.¹²³⁹ Most other studies involved combined CRT modalities.

In general, chemotherapy protocols for adult sinonasal RMS have been adapted from pediatric clinical trial protocols (i.e., vincristine based). Chemotherapy was most frequently administered with radiation. Three studies examined the 5-year OS of adult sinonasal RMS to be between 20.6% and 31.8%, notably lower than that of pediatric sinonasal RMS.^{1240–1242} A majority of patients in these studies received combined chemotherapy and radiation. The remaining studies identified were retrospective case series that examined chemotherapy response or survival and recurrence outcomes. Analysis of these studies was

limited due to variable chemotherapy protocols, small case numbers, and short follow-up periods (Table XXIII.A.5).

Role of chemoradiation therapy in adult rhabdomyosarcoma

Aggregate grade of evidence	C (Level 4: nine studies)
Benefit	Definitive treatment option for local, regional, and distant disease.
Harm	Acute and long-term CRT side effects.
Cost	Cost of CRT administration.
Benefits-harm assessment	Balance of benefits and harms

(Continued)

TABLE XXIII. A. 5 Evidence surrounding role of chemoradiation therapy in adult rhabdomyosarcoma.

Study	Year	LOE	Study design	Study groups	Clinical endpoints	Conclusions
Hahn et al. ¹²³⁹	2022	4	Retrospective case series	Pre-IMRT (<i>n</i> = 17) versus IMRT (<i>n</i> = 8) in head and neck RMS	1. LRC 2. Distant control	1. Improved LRC with IMRT 2. No difference in DC
Barthere et al. ¹²⁴⁹	2020	4	Retrospective case series	CRT (<i>n</i> = 25), usually concurrent, vincristine-based in PM-RMS	Response	CR: 56%; progressive disease: 20%; unknown/LTF: 4%
Ding et al. ¹²⁴⁰	2019	4	Retrospective case series	CRT (<i>n</i> = 17), Surgery, chemo, and RT (<i>n</i> = 7), Other treatment (<i>n</i> = 3). Vincristine-based, 56.7% Sinonasal RMS	1. LRFS 2. DMFS 3. OS	Worse overall survival for RMS compared to other sarcomas 20.6% vs. 66.9% (<i>p</i> = 0.001)
Stepan et al. ¹²⁴¹	2017	4	Retrospective database study (NCDB)	CRT (<i>n</i> = 90, 49.5%), surgery, chemo, and RT (<i>n</i> = 47, 25.8%), chemo only (<i>n</i> = 31, 17%), other (<i>n</i> = 14, 7.7%) in sinonasal RMS. Chemo regimen not specified.	OS	1. 5-year OS 28.4%; survival varied by RMS subtype and age of patient 2. Variable treatment according to clinical factors (e.g., metastases, intracranial involvement).
Thompson et al. ¹²⁵⁰	2017	4	Retrospective case series	CRT (<i>n</i> = 38), chemo only (<i>n</i> = 7), RT only (<i>n</i> = 4), unknown (<i>n</i> = 3). Some received surgical resection as part of treatment (<i>n</i> = 16) in Sinonasal tract alveolar RMS. Chemo not specified.	Outcome	1. Alive NED: 18, AWD: 7, Dead NED: 1, DWD: 26 2. Multimodality therapies involving chemotherapy regimens should be considered in sinonasal tract alveolar RMS due to a high likelihood of local and distant metastases
Szablewski et al. ¹²⁴²	2014	4	Retrospective case series	In entire group (<i>n</i> = 48; chemo: 75%, surgery: 68.8%). Chemo given as adjuvant, neoadjuvant, or both in sinonasal soft tissue sarcoma (48% RMS)	OS	1. Worse survival with RMS compared to other sarcomas 2. Differences in response noted according to surgical resection
Wagemans et al. ¹²⁵¹	2010	4	Retrospective case series	First line chemotherapy (<i>n</i> = 4) in sinonasal RMS. One received partial resection prior to chemo. Chemo included IVAd with/without etoposide, ifosfamide, cisplatin	1. CR 2. Mortality	1. PR: 75% and CR: 25% 2. Death: 75% during study follow-up

(Continues)

TABLE XXIII.A.5 (Continued)

Study	Year	LOE	Study design	Study groups	Clinical endpoints	Conclusions
Montone et al. ¹²⁵²	2009	4	Retrospective case series	CRT ($n = 10$), chemo not specified in PM-RMS	Outcome	AWD: 30%, NED: 30%, DOD: 20%, LTF: 20%
Nakhleh et al. ¹²⁵³	1991	4	Retrospective case series	Entire group: No treatment ($n = 3$), surgery and chemo ($n = 2$), surgery, RT, and chemo ($n = 1$). Chemo not specified in Sinonasal RMS	Outcome	AWD: 33%, DOD: 33%, LTF: 33%

Abbreviations: AWD, alive with disease; CRT, chemoradiation therapy; DMFS, distant metastasis-free survival; DOD, died of disease; DWD, died with disease; LRC, locoregional control; LRFS, locoregional failure/recurrence-free survival; LTF, lost to follow-up; NED, no evidence of disease; IVad, ifosfamide + vincristine + doxorubicin; OS, overall survival.

Value judgments	No direct comparison between different treatment approaches. Low-quality studies demonstrating response with poor long-term survival. Protocols for adult RMS have generally been adapted from pediatric RMS; however, these tumors have different biology, and treatment likely has different side effect profiles.
Policy level	Option.
Intervention	Further evidence needed to determine role of specific chemotherapy protocols in adult RMS. Consider RT for adults with sinonasal RMS, especially patients with unresectable disease.

7 | Induction chemotherapy for sinonasal rhabdomyosarcoma

Two trials using induction protocols for PM-RMS were identified. The MMT-84 and MMT-89 trials effectively employed induction approaches for young patients. In MMT-84, patients under 5 years of age with PM-RMS who achieved CR did not receive local RT.¹²⁴³ In MMT-89, patients under 3 years of age with PM-RMS who achieved CR did not receive local RT.¹²⁴⁴

Other trials also employed IC protocols; however, PM-RMS primaries were not included and instead all received RT. Merks et al. performed a systematic review of clinical trials and showed significant benefit with initial RT treatment for PM-RMS (results shown in Table XXIII.A.3).¹²²⁵ There was one study evaluating induction chemotherapy in CWS trials, but most PM-RMS were excluded from this analysis (Table XXIII.A.6).¹²⁴⁵

Induction chemotherapy for sinonasal rhabdomyosarcoma

Aggregate grade of evidence	C (Level 3: two studies)
Benefit	OS appears to be lower than that of patients treated with non-induction protocols from the same studies.
Harm	Chemotherapy side effects and additional risk of tumor progression while receiving induction.
Cost	Cost of chemotherapy administration unlikely to be significantly different from non-induction chemotherapy costs.
Benefits-harm assessment	Balance of benefits and harms.
Value judgments	Treatment with induction chemotherapy may identify subset of patients who will or will not benefit from definitive CRT. No direct comparison of induction to other protocols.
Policy level	Option.
Intervention	Induction chemotherapy protocols for sinonasal RMS are an option for bulky and locally advanced disease.

B | Sinonasal chondrosarcoma and osteosarcoma

Chondrosarcoma and osteosarcoma are malignant mesenchymal tumors that originate from cartilage and bone, respectively. Cases arising from soft tissues have been rarely reported. As for any nonepithelial malignancy, defining a tumor of sinonasal origin can be potentially

TABLE XXIII. A. 6 Evidence surrounding induction chemotherapy for sinonasal rhabdomyosarcoma.

Study	Year	LOE	Study design	Study groups	Clinical endpoints	Conclusions
Stevens et al. ¹²⁴⁴	2005	3	Prospective cohort	IVA, CEV, IVE, then evaluation RT if less than CR (<i>n</i> = 27) in PM-RMS <3 years old	1. OS 2. EFS	5-year OS of 59% in cohort treated with induction chemotherapy protocol
Flamant et al. ¹²⁵¹	1998	3	Prospective cohort	Induction IVA × three courses then IVA if PR or DP if less than PR After six courses, if CR, then continued chemo If less than CR, then RT (<i>n</i> = 14) in PM-RMS with high-risk meningeal involvement, <5 years old	1. OS 2. EFS	1. 5-year OS of 50% in cohort treated with an induction chemotherapy protocol 2. Planned randomized study abandoned due to poor compliance

Abbreviations: CEV, carboplatin + epirubicin + vincristine; IVA/VAI, ifosfamide + vincristine + actinomycin D; EFS, event-free survival; IVE, ifosfamide + vincristine + etoposide; OS, overall survival; RT, radiation therapy.

subjective, with some lesions being clearly centered on structures of the sinonasal tract (e.g., the nasal septum) and others located midway between the sinonasal tract and adjacent anatomical compartments (e.g., the hard palate/alveolar bone). Since from a clinical standpoint chondrosarcoma and osteosarcoma of the craniofacial skeleton exhibit similar challenges irrespective of their origin, the present review includes both these entities. Surgery has an undisputed role in the management of both diseases. Locally uncontrolled disease represents the main cause of cancer-specific mortality for both tumors, which have the propensity to extend through bones, particularly in the medullary part, and this emphasizes the importance of complementing surgery with other modalities. However, evidence that clearly delineates the indications to chemotherapy and RT is lacking.

Of note, the current section in ICSNT does not cover petroclival chondrosarcoma, which is discussed in ICSB 2019 section IX.B.⁵

1 | Chondrosarcoma

Based on the search strategy, seven articles with sufficient information on sinonasal chondrosarcomas were identified (Table XXIII.B.1).^{266,1254–1259} Overall, 183 patients affected by sinonasal chondrosarcoma were included in these articles. In two studies, chondrosarcomas of the anterior skull base, nonanterior skull base, and sinonasal tract were included together; data of cases centered on

the sinonasal tract could not be extracted and were hence estimated from the full series data. Thus, the overall denominator is 238 subjects. Most relevant data extracted from these publications are reported herein and then discussed in the last section of the paragraph.

Mean age at diagnosis was 45.5 years. Women were more frequently affected (132, 59.3%). Conventional chondrosarcoma was the most frequent type (182, 76.5%), followed by mesenchymal (24, 10.1%), myxoid (12, 5.0%), dedifferentiated (3, 1.3%), and clear cell subtype (2, 0.8%). In 15 (6.3%) cases, the histological subtype was not reported. Grade was not systematically reported. Clear cell and dedifferentiated subtypes have been reported to be associated with worse prognosis.¹²⁶⁰

The majority of patients received surgery (94.1%). Among those operated, 2.7% underwent curettage/biopsy, with the remaining treated with surgery aimed at achieving a maximal safe resection. The surgical resection was classified heterogeneously: 21.4% patients received resection with negative margins, 26.8% GTR with no information on microscopic margin status, 6.7% resection with microscopically involved margins, 20.1% STR with macroscopic residual disease, and 8% a “wide resection” with no details on macroscopic residual disease and margin status. In 14.3% patients, the surgical procedure was not detailed. The method of resection is available for 105 patients, of which 53.3% were operated on endoscopically.

The primary treatment included RT and chemotherapy in 35.3% and 3.8% patients, respectively. Thirty-six (15.1%) patients received proton beam RT, whereas the remain-

TABLE XXIII. B.1 Evidence surrounding sinonasal chondrosarcoma.

Study	Year	LOE	Study design	Study groups	Clinical endpoints	Conclusion
Rimmer et al. ¹²⁵⁹	2021	4	Retrospective database study (NCDB)	Sinonasal ChS ^a : 100/736	OS	<ol style="list-style-type: none"> 1. Sinonasal ChS is primarily treated with surgery and adjuvant RT 2. PBRT confers higher survival than conventional RT 3. 1-, 2-, 5-, and 10-year OS: 97.0%, 90.6%, 80.5%, and 74.9%, respectively
Simon et al. ¹²⁵⁸	2018	4	Retrospective case series	Sinonasal ChS ^a : 13/47 [§]	CSS	<ol style="list-style-type: none"> 1. CSS is not decreased in patients receiving surgery alone 2. A surgery only strategy could be considered leaving PBRT for cases of relapse 3. 5- and 10-year CSS: 95.2%
Vaz-Guimaraes et al. ¹²⁵⁷	2017	4	Retrospective case series	Sinonasal ChS ^a : 14/35 ^{c,§}	<ol style="list-style-type: none"> 1. CSS 2. RFS 	<ol style="list-style-type: none"> 1. Endoscopic transnasal surgery is a good option to achieve maximal safe resection 2. 3-year CSS and RFS: 91.1% and 83.7% 3. 5-year CSS and RFS: 90.5% and 80.8%
Guo et al. ²⁶⁶	2013	4	Retrospective case series	Sinonasal ChS ^a : 24/24	CSS	<ol style="list-style-type: none"> 1. Early diagnosis and adequate surgical resection are essential to ensure satisfactory outcomes 2. Local progression is the main cause of death 3. 5-year CSS: 83.3%
Prado et al. ¹²⁵⁶	2009	4	Retrospective case series	Sinonasal ChS ^a : 11/16	OS	<ol style="list-style-type: none"> 1. Early diagnosis and adequate surgical resection are essential to ensure satisfactory outcomes 2. 5-year OS: 56.4%
Knott et al. ¹²⁵⁵	2003	4	Retrospective case series	Sinonasal ChS ^a : 13/13	<ol style="list-style-type: none"> 1. OS 2. CSS 	<ol style="list-style-type: none"> 1. Sinonasal MeC is an aggressive subtype of ChS, with predilection for young women 2. MeC mandates for aggressive surgery and adjuvant therapy 3. 1-year OS and CSS: 81.8%^b 4. 3-, 5-, and 10-year OS and CSS: 63.6%^b
Gadwal et al. ¹²⁵⁴	2000	4	Retrospective case series	Pediatric sinonasal ChS ^a : 8/14	<ol style="list-style-type: none"> 1. OS 2. CSS 	<ol style="list-style-type: none"> 1. Pediatric craniofacial ChS is more frequently low-grade and associated with favorable prognosis 2. 1-, 3-, 5-, and 10-year OS and CSS: 100.0%^b

Abbreviations: ChS, chondrosarcoma; CSS, chondrosarcoma-specific survival; FS, frozen section; MeC, mesenchymal chondrosarcoma; OS, overall survival; PBRT, proton beam radiotherapy; RFS, recurrence-free survival; RT, radiation therapy.

^aReported as the ratio between patients affected by a sinonasal chondrosarcoma as per the definition reported in Material and Methods and total number of patients.

^bCalculated.

^cEstimated based on breakdown by extension.

[§]Subsequent row values refer to the entire series and single-patient data could not be extracted.

ing underwent photon-based RT. One- and 3-year OS and DSS estimates were in the range of 63.3%–100%. Five- and 10-year OS and DSS survival were in the range of 56.4%–100%, with five of seven studies reporting estimates >80% at 5 years. RFS was 60.7%–83.7% at 3 years and 42.9%–80.8% at 5 years. Considering the 91 patients with single-patient data available, 1-, 3-, 5-, and 10-year OS estimates were 92.3%, 81.2%, 75.7%, and 73.0%, respectively. The main cause of cancer-specific death was local recurrence or progression with compression of vital structures. Only three cases (1.3%) of distant metastases were reported. However, de Souza et al. published a systematic review including publications on chondrosarcomas of the mandible and maxilla in the period 1950–2017 and found distant metastasis in 29 of 169 (17.2%) cases.¹²⁶¹ Nodal primary involvement and nodal recurrence were rare.

Advanced age, large tumor volume, and need for combined surgery were associated with worse prognosis.¹²⁵⁷ Proton beam RT was found to significantly increase PFS.¹²⁵⁸ In the analysis of their entire series including also nonsinonasal, skull base chondrosarcomas, Rimmer et al. found that proton beam RT was associated with higher OS compared with photon-based RT.¹²⁵⁹

Sinonasal chondrosarcoma mostly affects patients around their fifth decade of life. Although a predilection for the female gender was found in this review, other studies showed a slight male prevalence.¹²⁶¹ Maffucci syndrome and other enchondromatosis such as the Ollier disease are predisposing factors.¹²⁶² Conventional chondrosarcoma is the most frequently represented subtype, which is further graded from I to III based on histomorphology. Mesenchymal and myxoid subtype have been reported in the sinonasal tract, whereas other subtypes are extremely rare. Mesenchymal chondrosarcoma, which harbors the typical *HEY1::NCOA2* fusion,¹²⁶³ is associated with more aggressive behavior, with a higher propensity to recur and metastasize.¹²⁵⁵ However, mesenchymal chondrosarcoma of the craniofacial area shows less aggressive behavior compared with other anatomical sites.¹²⁶³

Surgical resection classification is nonhomogenous, with some studies distinguishing GTR versus STR and others reporting on margin status. If one considers the anatomical site, which does not allow for wide-margin resection around tumor surfaces, the frequent need for multibloc (with multiple oriented specimens) resection, the constraints of frozen section on bone, and the propensity of chondrosarcomas to invade the medullary niches and Haversian system of grossly normal surrounding bones, defining resection based on margin status may be unreliable.

Chemotherapy is rarely included in the treatment of sinonasal chondrosarcoma, mostly in the mesenchymal and dedifferentiated subtypes. In contrast, one third of

patients received RT. However, the role of adjuvant RT is debated.¹²⁶⁴ While there is evidence that adjuvant RT improves PFS, its effect on OS is less clear.^{1258,1265} The discrepancy between PFS and OS may be attributable to the successful treatment of recurrences or slow progression, thus justifying reserving RT for cases that are deemed to be high risk for recurrence (e.g., recurrent tumors, moderate-to-high-grade tumors, very extensive disease, multiple neoplastic microscopic foci in the resection bed). Particle therapy is reported to be more advantageous than photon RT in sinonasal and skull base chondrosarcoma.¹²⁵⁹ Based on the available data, no definite conclusions on the need for adjuvant RT can be drawn. Thus, postoperative RT should be discussed in a multidisciplinary setting on a case-by-case basis, taking into consideration factors such as tumor subtype, grade, completeness of resection, and salvageability of recurrence, as well as patients age, comorbidities, and goals of treatment.

2 | Osteosarcoma

Nineteen articles with sufficient information on sinonasal osteosarcomas have been identified (Table XXIII.B.2).^{1266–1283} Overall, 310 patients were included. In 10 studies, osteosarcoma of the superior craniofacial area and mandible were included together. In these papers, data of cases centered on the sinonasal tract could not be extracted and were estimated from the full-series data. Thus, the overall denominator was 551 subjects. Most relevant data extracted from these publications are reported herein and then discussed in the last section of the paragraph.

Mean age at diagnosis was 36.7 years. Males were more frequently affected (340, 61.7%). Considering the 13 studies specifying previous exposure to radiation, 130 of 459 (28.3%) patients had secondary or “RT-associated” osteosarcoma. Chondroblastic type was the most frequent (23.8%), followed by conventional “not otherwise specified” (11.3%), osteoblastic (10.3%), fibroblastic (8.0%), telangiectatic (1.3%), dedifferentiated (1.1%), and other rare subtypes. Histologic subtype was not specified in 39.2% of patients. Tumor grade was classified as high in 41.2%, intermediate in 4.2%, and low in 12.0% and was not specified in 42.6% cases.

The majority of patients received surgery (95.1%). Of these, 5.6% had macroscopic residual disease after surgery (R2). GTR (i.e., non-R2) was achieved in 81.7% patients, with microscopically negative (R0), “close” (with no metric definition), positive (R1), and not specified margin status in 51.7%, 1.1%, 17.4%, and 11.4% cases, respectively. In 5.8% cases, the resection was classified as “incomplete” with no specification on the microscopic versus

TABLE XXIII. B.2 Evidence surrounding sinonasal osteosarcoma.

Study	Year	LOE	Study design	Study groups	Clinical endpoints	Conclusion
Low et al. ¹²⁸²	2020	4	Retrospective case series	Sinonasal OsS ^a : 14/14	OS	<ol style="list-style-type: none"> 1. Old age and advanced local extension are associated with worse prognosis 2. 1-, 3-, 5-, and 10-year OS: 85.1%,^d 67.0%,^d 47.9%,^d and 35.9%,^d respectively
Kontio et al. ¹²⁸¹	2019	4	Retrospective case series	Sinonasal OsS ^a : 11/20	Recurrence rate	<ol style="list-style-type: none"> 1. Surgery is the mainstay of treatment in craniofacial OsS 2. Adjuvant RT is indicated in case of involved/close margins
Bouaoud et al. ¹²⁸⁰	2019	4	Retrospective case series	Sinonasal OsS ^a : 14/35 ^b	RFS	<ol style="list-style-type: none"> 1. Neoadjuvant chemotherapy confers no benefit in patients affected by craniofacial high-grade OsS 2. 3-year RFS: 76% 3. Eight (22.9%) deaths, seven cancer related
ElKordy et al. ¹²⁷⁸	2018	4	Retrospective case series	Sinonasal OsS ^a : 6/21 ^b (5, 2 sinonasal)	<ol style="list-style-type: none"> 1. OS 2. RFS 	<ol style="list-style-type: none"> 1. Radiological and pathological diagnosis alongside with adequate surgical resection are the most critical aspects in craniofacial OsS 2. 5-year OS: 75%–80%^c; 5-year RFS: 50%–60%^c; six (28.6%) local recurrences; one (4.8%) distant recurrence
Krishnamurthy and Palaniappan ¹²⁷⁹	2018	4	Retrospective case series	Sinonasal OsS ^a : 5/14 ^b (0)	RFS	<ol style="list-style-type: none"> 1. Negative-margin resection and multimodality treatment are essential to improve outcomes 2. 5-year RFS: 47.6%; two (14.3%) local recurrences; six (42.9%) distant recurrences
Boon et al. ¹²⁷⁶	2016	4	Retrospective case series	Sinonasal OsS ^a : 38/77 ^b (19)	OS	<ol style="list-style-type: none"> 1. In patients younger than 75 years of age who undergo surgery for high-grade or intermediate-grade craniofacial OsS, (neo)adjuvant chemotherapy is indicated as it decreases the risk for local recurrence 2. 5-year OS: 55%; 14 (18.2%) local recurrences, seven (9.1%) local and distant recurrences, four (5.2%) distant recurrences
Liao et al. ¹²⁷⁷	2016	4	Retrospective case series	Sinonasal OsS ^a : 33/45 ^b (45)	OS	<ol style="list-style-type: none"> 1. Postirradiation OsS in patients treated for NPC is associated with dismal prognosis 2. Surgery combined with postoperative chemotherapy could be a valuable treatment strategy 3. 1-, 2-, 3-, and 5-year OS: 53.3%,^c 35.6%,^c 13.5%,^c and 0%,^c respectively

(Continues)

TABLE XXIII.B.2 (Continued)

Study	Year	LOE	Study design	Study groups	Clinical endpoints	Conclusion
Demicco et al. ¹²⁷⁴	2010	4	Retrospective case series	Sinonasal OsS ^a : 9/15 (0)	OS	<ol style="list-style-type: none"> 1. Low-grade OsS are effectively treated with wide surgery alone 2. 5-year OS: 100%^d
Luna-Ortiz et al. ¹²⁷⁵	2010	4	Retrospective case series	Sinonasal OsS ^a : 21/21 (1)	<ol style="list-style-type: none"> 1. OS 2. RFS 	<ol style="list-style-type: none"> 1. Early diagnosis and adequate treatment consisting of R0 surgery with RT and/or chemotherapy are essential to improve outcomes 2. 2- and 5-year OS: 100%^d and 90.0%^d, respectively 3. 2- and 5-year RFS: 44.9%^d and 29.9%^d, respectively
Guadagnolo et al. ¹²⁸³	2009	4	Retrospective case series	Sinonasal OsS ^a : 54/119 ^b (16)	<ol style="list-style-type: none"> 1. OS 2. CSS 3. RFS 	<ol style="list-style-type: none"> 1. Surgery is the mainstay of treatment in craniofacial OsS 2. Adjuvant RT is indicated in case of margin involvement/unclear status
Jasnau et al. ¹²⁷²	2008	4	Retrospective case series	Sinonasal OsS ^a : 12/49 ^b	<ol style="list-style-type: none"> 1. OS 2. RFS 	<ol style="list-style-type: none"> 1. Failure to achieve local control is associated with poor survival 2. 5- and 10-year OS: ~75%^c and ~65%^c, respectively
Laskar et al. ¹²⁷³	2008	4	Retrospective case series	Sinonasal OsS ^a : 21/50 ^b (0)	OS	<ol style="list-style-type: none"> 1. Surgery is the mainstay of treatment in craniofacial OsS 2. Adjuvant RT is indicated in case of adverse factors such as margin involvement
Thiele et al. ¹²⁹¹	2008	4	Retrospective case series	Sinonasal OsS ^a : 7/12 ^b (0)	OS	R0 surgery and high-dose chemotherapy represent the most effective treatment strategy for craniofacial OsS
Fernandes et al. ¹²⁷¹	2007	4	Retrospective case series	Sinonasal OsS ^a : 7/16 ^b (1)	OS	Surgery with postoperative chemotherapy for high-grade OsS is an adequate treatment strategy
Nakayama et al. ¹²⁶⁹	2005	4	Retrospective case series	Sinonasal OsS ^a : 5/10 (2)	OS	<ol style="list-style-type: none"> 1. Osteolytic OsS are more frequently of high grade and associated with worse prognosis 2. 5-year OS: 100%
Liu et al. ¹²⁷⁰	2005	4	Retrospective case series	Sinonasal OsS ^a : 8/15 (15)	OS	<ol style="list-style-type: none"> 1. Post-RT OsS in patients treated for NPC is associated with dismal prognosis 2. Surgery combined with pre- and postoperative chemotherapy could be a valuable treatment strategy
Panda et al. ¹²⁶⁸	2003	4	Retrospective case series	Sinonasal OsS ^a : 12/12	OS	<ol style="list-style-type: none"> 1. 1- and 2-year OS: 80.8%^d 2. 5-year OS: 21.5%^d <p>Six (50.0%) local recurrences, one (8.3%) distant recurrence</p>
Patel et al. ¹²⁶⁷	2002	4	Retrospective case series	Sinonasal OsS ^a : 26/44 (6)	<ol style="list-style-type: none"> 1. OS 2. CSS 	<ol style="list-style-type: none"> 1. Margin involvement is the only factor affecting OS and CSS in craniofacial OsS 2. 3-year local control rate: 50%–78%

(Continues)

TABLE XXIII.B.2 (Continued)

Study	Year	LOE	Study design	Study groups	Clinical endpoints	Conclusion
Mardinger et al. ¹²⁶⁶	2001	4	Retrospective case series	Sinonasal OsS ^a : 7/13	OS	<ol style="list-style-type: none"> 1. Craniofacial OsS differs from OsS of the long bones in its biological behavior 2. Because of differences in tumor characteristics, chemotherapy did not alter the prognosis 3. 3- and 5-year OS: 90%^d and 64%^d

Abbreviations: CSS, chondrosarcoma-specific survival; OS, overall survival; OsS, osteosarcoma; R0, no residual disease; R1, microscopically involved margin; RFS, recurrence-free survival; RT, radiation therapy.

^aReported as the ratio between patients affected by a sinonasal osteosarcoma as per the definition reported in Material and Methods and total number of patients; non-osteosarcoma cancers are excluded; number of postirradiation osteosarcomas is reported in round parentheses.

^bSubsequent row values refer to the entire series and single-patient data could not be extracted.

^cExtracted from survival curves.

^dCalculated.

macroscopic residual disease. In 2.0% patients, the surgical procedure was not described.

Chemotherapy and RT were part of the primary treatment in 48.8% and 24.9% of patients, respectively. Survival outcomes were heterogeneous, with the 3-year OS estimate ranging from 0% to 100%. In 10 of 19 studies, the 5-year OS estimate was >50%. Overall, RFS was low, with estimates from 44.9% to 78% at 2–3 years, 40%–60% at 5 years, and 35%–47% at 10 years. Considering the 87 patients with single-patient data available, 1-, 3-, 5-, and 10-year OS estimates were 87.9%, 69.4%, 51.8%, and 47.1%, respectively. Local recurrence was the main modality of treatment failure. Nodal primary involvement and nodal recurrence were rare and limited to high-grade tumors. Distant recurrence was reported in 8.9% of patients. All distant metastases occurred in patients with either high-grade osteosarcomas or with no specification on tumor grade. However, cumulative incidence of distant recurrence was 26% and 28% at 5 and 10 years, respectively.¹²⁸³

The following negative prognostic factors were identified: male gender for RT-associated osteosarcomas,¹²⁷⁰ female gender for primary osteosarcomas,¹²⁷⁵ post-RT presentation,¹²⁸³ high/intermediate grade,^{1273,1276,1283,1284} nonmaxillary sinonasal/skull base localization,¹²⁷³ microscopic margin involvement,^{1273,1276,1277,1279,1280,1283} R2 surgery,¹²⁷² and low-to-null neoplastic bone formation at imaging.¹²⁷⁰ The prognostic role of age is debated.^{1276,1282}

The prognostic effect of including chemotherapy in treatment, most frequently in the neoadjuvant setting, is controversial: some studies demonstrated a prognostic benefit,^{1276,1277} thus advocating for its use in high-grade primary osteosarcomas and RT-associated osteosarcomas, while other studies failed to show a survival advantage.¹²⁸⁰ A single study showed that RT provides a survival benefit in patients with involved surgical margins or unknown margin status.¹²⁸³

Sinonasal osteosarcoma (i.e., including osteosarcoma of the maxilla and adjacent bones) mostly affects patients around their fourth decade of life, with a slight predilection for the male gender, and represents roughly 6% of all osteosarcomas.¹²⁸⁵ Secondary osteosarcoma of the sinonasal tract include RT-associated lesions and those arising in the context of Paget's disease.¹²⁸⁶ Craniofacial osteosarcoma also represents the most frequent secondary tumor in hereditary retinoblastoma survivors previously treated with RT.¹²⁸⁷ The maxilla is more frequently involved than other bones of the sinonasal area.¹²⁸⁶ Conventional osteosarcoma is the most common, with the chondroblastic and osteoblastic subtypes being most frequently reported. Fibroblastic conventional osteosarcoma has also been reported, whereas nonconventional subtypes such as the telangiectatic, dedifferentiated, and sclerosing are anecdotal. The majority of sinonasal osteosarcomas reported in the literature are of high grade.

Most studies on sinonasal osteosarcoma report microscopic margin status. Approximately half of the patients undergo R0 surgery. Microscopic margin status has been described in several studies as a relevant prognostic factor. Other prognostic factors include gender, RT-associated presentation, grade, gross residual disease, and degree of bone formation at imaging. Chemotherapy most likely has a role in the treatment of sinonasal osteosarcomas, although the evidence is not as robust as in pediatric osteosarcomas.¹²⁸⁸ Roughly half of patients received chemotherapy as part of their primary treatment, most frequently in the neoadjuvant setting. Boon et al. demonstrated that neoadjuvant chemotherapy reduces local recurrence in high- and intermediate-grade head and neck osteosarcoma irrespective of age and completeness of resection.¹²⁷⁶ Liao et al. showed increased survival in RT-associated gnathic osteosarcoma treated with surgery and adjuvant chemotherapy over surgery alone.¹²⁷⁷ A

meta-analysis of 184 patients showed that chemotherapy improves survival when adverse features such as high-grade tumors, positive margins, and recurrence were present.¹²⁸⁹ On the other hand, Bouaoud et al. did not find any benefit and reported a potential deleterious effect.¹²⁸⁰ Thus, no clear conclusion on the indications for (neo)adjuvant chemotherapy can be drawn based on the available evidence, but most studies are in favor of its use in selected cases.

The role of adjuvant RT is less controversial. Patel et al. suggested that adjuvant RT should be considered in case of positive or close margins.¹²⁶⁷ Guadagnolo et al. demonstrated that incorporating RT confers a prognostic advantage for disease control and survival only when surgical margins are involved or uncertain.¹²⁸³ Proton beam RT has been suggested as a potential strategy for local control in patients with unresectable or incompletely resected craniofacial osteosarcomas.¹²⁹⁰

C | Other sarcomas

This section discusses rare primary sinonasal sarcomas, including biphenotypic sinonasal sarcoma (BSNS), fibrosarcoma, angiosarcoma, leiomyosarcoma, malignant peripheral nerve sheath tumor (MPNST), Ewing sarcoma (ES), adamantinoma-like ES (ALES), and synovial sarcoma. Literature search did not meet ICAR inclusion criteria for liposarcoma. Table XXIII.C.1 includes a summary of important findings from this review.

Diagnosis of sinonasal sarcoma requires biopsy; if safe, a large specimen should be collected to reduce the high rate of initial misdiagnosis (46%).¹²⁹² Surgical excision is the preferred treatment for resectable lesions and is associated with the highest survival rates.¹²⁹³ Tumor size, histologic grade, and margin status impact survival in patients with head and neck sarcoma.¹²⁹⁴ Sercarz et al. demonstrated that 63% of patients with sinonasal non-rhabdomyosarcoma with positive surgical margins recurred; 50% were successfully salvaged (follow-up range 2–12 years).¹²³⁶ Twelve patients with positive margins received adjuvant RT, 41.7% of whom had no further evidence of disease.¹²³⁶ O'Sullivan et al. report encouraging results using preoperative neoadjuvant RT (50–60 Gy) in head and neck soft tissue sarcoma with 5-year OS \geq 83% for patients with negative or microscopically positive margins.¹²⁹⁵ Treatment with chemotherapy or RT has not demonstrated improved outcomes, although randomized studies are lacking.¹²⁹⁵ Nevertheless, use of RT has increased from 55% between 1973 and 2008 to 64% from 2009 to 2014.^{51,1296}

TABLE XXIII.C.1 Other primary sarcomas of sinonasal tract.

	Biphenotypic			
	Fibrosarcoma	Sinonasal Sarcoma	Leiomyosarcoma	Angiosarcoma
Age at presentation, years; mean (range)	55 ^{a, 49}	52 (24–85) ^{1301,1302}	46 (10–87) ¹³¹²	47 (13–81) ¹³¹⁶
Sex (M:F)	1:1 ⁴⁹	2:3 ^{1301–1303}	1:1 ¹³¹²	3:2 ¹³¹⁶
Histologic characteristics	Spindle cells in chevron, herringbone or storiform pattern	Low-grade spindle cells, herringbone pattern; +S100, smooth muscle actin, muscle-specific actin; <i>PAX3::MAML3</i> fusion gene	Spindle cells; +SMA, desmin, and/or caldesmon; S100 -, RBI protein loss (75% of cases)	Spindled/epithelioid cells with hemorrhage/necrosis, CD31 and ERG+; HHV-8-
Primary treatment recommendations	Sx \pm RT	Sx \pm RT	Sx \pm CTX/RT	Sx, neoadjuvant/ adjuvant CTX \pm RT
Overall survival (follow-up duration)	71.7% (5 years) ⁴⁹	>95% ^{1301,1302}	66% (mean 38 months) ¹³¹²	44%–86% ^{51,1317,1323}
				45% (5 years) ¹³²⁴
				>49% (5 years) ^{1329,1331}
				62 (38–81) ^{1329,1331}
				31 (5–55) ¹³²⁴
				2:1 ¹³²⁴
				1:1 ¹³²⁹
				Spindle cells, perivascular accentuation; +S100, SOX10; -H3K27me3 protein
				Spindle cells (monophasic/ biphasic/poorly differentiated); t(X;18)(p11;q11) translocation; + TLE1
				Small round blue cells; +CD99, nuclear NKX2.2; <i>EWSR1</i> gene rearrangement

Abbreviations: CTX, chemotherapy; MPNST, malignant peripheral nerve sheath.

^aRange not reported.

Studies suggest an improved prognosis of these sarcoma subtypes compared to sinonasal rhabdomyosarcoma.^{51,1242} The largest study on sinonasal sarcomas included 352 patients with all sarcoma histologies; 50% had “miscellaneous” subtypes that include the less common pathologies discussed here. Maxillary sinus tumors exhibited poorer outcomes versus all other sinonasal subsites. Sphenoid sarcoma had the best prognosis; 5-year survival was 63% versus 41% for maxillary sinus tumors—thus postulating that maxillary sinus tumors may present at a more advanced stage.⁵¹ However, Martin et al. studied sinonasal sarcoma outcomes using the SEER database and did not corroborate these findings.¹²⁹⁶ Age also affects prognosis.⁵¹ Five-year survival for patients <10 years old was 63.1%; 54.5% of patients received RT, but this did not improve 5-year survival.¹²⁹⁶

Disease stage significantly predicts OS.²⁶⁵ Negative surgical margins and the absence of metastatic lymphadenopathy significantly improve prognosis for patients with nonrhabdomyosarcoma sinonasal sarcoma.^{1236,1297–1299} No significant survival difference has been shown between endoscopic and open surgical resection; the approach should be dictated by tumor extent, surgeon expertise, and location.²⁶⁵ ES, leiomyosarcoma, and MPSNT are associated with improved overall 5-year survival versus other sarcomatous lesions, including fibrosarcoma and synovial sarcoma.²⁶⁵

1 | Fibrosarcoma

Fibrosarcoma presents at a mean age of 54.5 years and affects males and females equally.⁴⁹ Once considered a common adult sarcoma, refinements in microscopic criteria and ancillary testing have led fibrosarcoma to be regarded as a diagnosis of exclusion, and it is probably exceptionally rare. Histologically, spindle cells are arranged in chevrons, herringbone, or storiform pattern. Bland appearance may contribute to initial benign misdiagnosis.¹³⁰⁰ High mitotic rate and tumor cellularity, as well as male sex, associate with higher mortality risk.¹³⁰⁰ In fibrosarcoma, 64.1% have regional nodal disease.⁴⁹ However, among other types of non-rhabdomyosarcomatous lesions, the cervical metastatic rate is significantly lower (3%–30%).^{265,1296} Fibrosarcoma 5-year DSS is 77.8%; OS is 71.7%, improved from earlier 20th century reports of 21%.^{49,1293} Patients treated surgically had significantly improved prognosis versus those treated with RT alone (DSS 33.3% for RT alone). Surgery alone versus surgery followed by RT was associated with improved 5-year DSS (87.5% vs. 76.2%), likely due to selection bias.⁴⁹

2 | Biphenotypic sinonasal sarcoma

Females predominate in BSNS (61%–69%).^{1301–1303} Histologically, BSNS is a cellular, low-grade spindle cell neoplasm with elongated nuclei arranged in a “herringbone” pattern and a low mitotic rate. Many tumors exhibit a potentially distracting respiratory epithelial hyperplasia regarded as entrapment of benign epithelium, underscoring the need for ample biopsy material. Of note, BSNS is not PET avid.¹³⁰⁴ The *PAX3::MAML3* fusion gene is commonly associated, although other fusion genes exist.^{1305–1307} Tumor cells demonstrate a neural and myogenic phenotype with S100, smooth muscle actin, and muscle-specific actin staining in >90% of cases; none express SOX10 or cytokeratin, aiding in separation from synovial sarcoma and MPNST.^{1301,1302,1308,1309} β -Catenin is often positive (>80% cases) but is not specific^[24].¹⁴³² Bony invasion occurs in 21%–57% of cases.^{1301,1302} Surgery is the most common management modality. Local recurrence rates range between 32% and 44%, but OS approaches 100%.^{1301,1302} Though tumors may be locally aggressive with >20% demonstrating orbital or skull base involvement, no cervical or distant metastases have been identified, and only two deaths have been reported.^{1308,1310} Adjuvant RT following surgery results in an equivalent recurrence rate of 33.3%, though the margin status of these patients was unknown, undermining the assessment of adjuvant RT influence.¹³¹¹ Adjuvant chemotherapy is rarely indicated, except with positive margins or unresectable disease.¹³¹¹ Literature-reported recurrences have occurred within 60 months of treatment.¹³⁰⁹ Importantly, the recent recognition of this distinct histological entity limits the duration of follow-up within the literature and may impact our understanding of long-term survival outcomes.

3 | Leiomyosarcoma

History of CRT or retinoblastoma increases the risk of leiomyosarcoma.^{1312,1313} Leiomyosarcoma demonstrates smooth muscle differentiation and may arise post-RT and concomitantly with other tumors, such as retinoblastoma. Spindled tumor cells label with smooth muscle actin (SMA), desmin, and/or caldesmon, and S100 expression is absent. RB1 protein loss occurs in 75% of cases. EBV-associated smooth muscle tumors may mimic leiomyosarcoma, but are considered a borderline tumor category, many with a transplantation history and multifocal disease.¹³¹³ Sinonasal leiomyosarcoma is treated with surgery in 93% of cases; 35% of patients receive adjuvant RT and/or chemotherapy.^{1312–1315} High-grade leiomyosarcoma

(elevated mitotic rate, necrosis) demonstrates increased risk of local recurrence or distant metastasis.^{1313,1315} Five-year DSS for leiomyosarcoma of all head and neck subsites was 52.7% for poorly differentiated lesions and 87.6% for well-differentiated tumors.¹³¹⁵ OS is 66% at mean follow-up of 38 months; distant metastasis is rare (8.1%).¹³¹²

4 | Angiosarcoma

Sinonasal angiosarcomas typically present as nodular purple/red lesions. Angiography and embolization may be useful in the workup and treatment.¹³¹⁶ Histologically, these vasoformative neoplasms infiltrate submucosa and bone as ramifying channels lined by spindle or epithelioid cells accompanied by necrosis and/or hemorrhage.¹³¹⁶ Tumors express endothelial markers CD31 and ERG.¹³¹⁶ HHV8 is negative, excluding Kaposi sarcoma. Risk of recurrence is reported at 38%, and OS is 40%–60% (mean follow-up: 121 months in one study), a significantly improved prognosis compared with nonsinonasal head and neck soft tissue angiosarcoma.^{1298,1316}

5 | Ewing sarcoma

Sinonasal ES has fewer than 100 cases reported. Though skeletal ES originates in long bones and affects children, sinonasal ES affects any age (mean 32 years; range 7–70 years).¹³¹⁷ Histologically, hypercellular sheets of small round blue cells with monotonous nuclei and occasional rosette formation necessitate broad testing to navigate the microscopic differential diagnosis.¹³¹⁷ ES consistently shows diffuse membrane CD99 positivity and nuclear NKX2.2 staining.¹³¹⁷ ALES is a rare subtype of ES exhibiting basaloid appearance, epithelial differentiation, and prominent mitoses. ALES is differentiated from classical ES by positive staining for cytokeratin, p63, and p40, an immunoprofile that overlaps with SCC.¹³¹⁸ *EWSR1* gene rearrangement is observed on molecular fluorescence in situ hybridization (FISH) testing in ES and ALES, with molecular confirmation of partners frequently required.¹³¹⁷ ES is chemo- and radiosensitive, but surgical excision with neoadjuvant/adjuvant therapy remains the primary treatment modality for resectable disease; multimodality therapy including chemotherapy is essential.^{1317,1319,1320} Adjuvant RT doses range from 50.4 to 55.8 Gy.¹³²⁰ In appropriate candidates, endoscopic resection can be used to achieve a negative margin resection.¹³²¹ Advanced tumors may be especially good candidates for neoadjuvant chemotherapy before surgery. ES of the head and neck is associated with improved prognosis versus

other subsites.¹³²² Metastatic disease occurs in 17% of cases.¹³¹⁷ Published mortality rates range from 14% to 56%.^{51,1317,1323} Data on sinonasal ALES are limited, though isolated reports suggest it may be more aggressive than sinonasal ES.¹³¹⁸

6 | Synovial sarcoma

Sinonasal synovial sarcoma has approximately 30 reported cases.^{1324,1325} SS exhibits calcifications on CT and a characteristic “triple sign,” possessing hypo-, iso-, and hyperintense signal on T2-weighted MRI.¹³²⁵ Treatment involves endoscopic or open surgery for resectable lesions. Disease progression or recurrence within 5 years ranges between 45% and 100%.^{1325,1326} Adjuvant chemotherapy and/or RT are often used, especially for high-grade/advanced lesions; RT dose ranges from 60 to 70 Gy.^{1320,1325,1326} Microscopically, this spindle cell sarcoma may be monophasic, biphasic (with glandular elements), or poorly differentiated.¹³²⁵ SS is positive for *SS18::SSX* fusion-specific antibody (E9×9V) and/or an *SSX*-specific antibody (E5A2C) that show strong diffuse nuclear staining¹³²⁷ and variably positive for CD99, B-cell lymphoma (BCL)-2, and cytokeratin.¹³²⁵ Identifying the pathognomonic t(X;18)(p11;q11) translocation may be diagnostically helpful for SS in uncommon anatomic locations.¹³²⁸ Outcomes data are limited, but studies suggest a recurrence rate of approximately 66% within 2 years and a 5-year DSS of 45% for sinonasal SS.^{1324,1325}

7 | Malignant peripheral nerve sheath tumor

MPNSTs arise from peripheral nerves, from precursor benign nerve tumors, or in patients with neurofibromatosis type 1 (NF-1). Patients with NF-1 have a lifetime risk of 10% for development of MPNST, and tumors develop at a younger age.¹³²⁹ Microscopic hallmarks include fascicles of alternating hypo- and hypercellular spindle cells with perivascular accentuation. The presence of heterologous elements, especially skeletal muscle (formerly, triton tumor), is seen in more aggressive MPNSTs and may connote a worse prognosis. Limited staining for S100 and SOX10 with complete loss of H3K27me3 expression is compatible with MPNST, but the diagnosis remains challenging.¹³³⁰ Prognosis is improved relative to other head and neck subsites.¹³²⁹ Definitive surgical therapy is recommended; CRT therapy alone has worse outcomes.¹³²⁹ Five-year OS for all head and neck MPNST with rhabdomyoblastic differentiation is 49%, with sinonasal subsite being a favorable prognostic factor.^{1329,1331}

XXIV | SINONASAL NEUROECTODERMAL AND NEUROENDOCRINE CARCINOMAS

A | Olfactory neuroblastoma

Olfactory neuroblastoma, also known as esthesioneuroblastoma (ONB), is a rare malignancy of the anterior skull base.¹³³² This tumor demonstrates neuroendocrine differentiation and is believed to originate from the olfactory neuroepithelium in the upper nasal cavity.^{71,1333} ONB falls on the spectrum of neuroendocrine tumors and retains neuroendocrine features including expression of neuroendocrine markers and neurosecretory vesicles.^{1333,1334} No known risk factors have been identified for this tumor. ONB has previously been reported to have a bimodal age distribution.⁷⁰ However, more recent large studies have demonstrated a true unimodal distribution with a peak between the fourth and sixth decades.¹³³⁵ In this section, we performed an evidence-based update to the ICSB 2019 (Section VIII.A) regarding endoscopic skull base surgery and expand on several additional aspects of management related to ONB.⁵

1 | Impact of Hyams grade on outcomes

Hyams et al. developed the only grading system based on histologic maturation and differentiation that has been shown to be of prognostic value, particularly in complementing current staging systems.^{1336–1339} Multiple studies have shown that Hyams grade allows for the identification of aggressive locoregional disease and subsequent prediction of poor DFS and may enable stratification for adjuvant therapy.^{510,1333,1340,1341} The independent prognostic utility of Hyams grading was demonstrated by Kane et al. and the ability to predict metastasis and OS was further confirmed in a recent meta-analysis by Goshtasbi et al.^{1342,1343}

Table XXIV.A.1 summarizes evidence surrounding impact of Hyams grade on outcomes of ONB.

Impact of Hyams grade on outcomes

Aggregate grade of evidence	B (Level 2: three studies; Level 4: five studies)
Benefit	Understanding Hyams grade provides prognostic information that may guide adjuvant therapy and treatment of the neck.

(Continued)

Harm	Grading may be prone to misinterpretation and requires pathologist expertise.
Cost	There are no studies investigating the costs of histological grading of ONB.
Benefits–harm assessment	Preponderance of benefits over harms.
Value judgments	High grade tumors appear to have more aggressive biological behavior (more prone to recurrence, nodal metastases) and may require more aggressive upfront treatment.
Policy level	Recommendation.
Intervention	Hyams grading should be routinely assessed when sampling tissue for ONB cases, as knowledge of the grade may impact treatment strategies.

2 | Staging systems

Historically, the most commonly used prognosticator is the Kadish staging system.¹³⁴⁴ Kadish developed this staging system with the analysis of data from 17 patients and published this work in 1976. Later, Morita et al. performed a retrospective analysis on 49 patients treated at the Mayo Clinic between 1951 and 1990 and proposed the modified Kadish staging system.¹³⁴⁵ In 1992, Dulguerov et al. proposed a modified version incorporating radiographic findings.¹³⁴⁶ While the Dulguerov system has been shown to be superior to the Kadish–Morita system in a recent individual patient data meta-analysis of publicly available data, a recent analysis of the NCDB determined that, in general, current clinical staging systems do not adequately predict survival over 10 years.^{248,1347} Analyzing the largest reported cohort of over 400 ONB patients, Lechner et al. showed that the Kadish–Morita staging system appeared to be superior to the alternative Dulguerov staging system and that better delineation between stage groups was observed in the former, in comparison with the substantial overlap between Dulguerov T1, T2, and T3.¹⁵ However, in line with the analysis of the SEER database by Joshi et al., they did not observe a statistically significant difference in survival between Kadish A and B tumors. As dural infiltration/invasion was found to be a significant prognostic indicator in their cohort (in line with early findings in craniofacial surgery and expanding on recent work), a modified staging system was devised, combining the A and B groups and separating the C group into those with and without dural infiltration, termed the Kadish-INSICA (International Network for Sinonasal Cancer Research) Staging System.^{246,1348,1349} Further research to validate this system is required to confirm prognostic value (Table XXIV.A.2).

TABLE XXIV.A.1 Evidence surrounding impact of Hyams grade on outcomes of ONB.

Study	Year	LOE	Study design	Study groups	Clinical endpoints	Conclusions
Meerwein et al. ¹³⁷⁶	2021	2	Systematic review and meta-analysis	33 studies; <i>N</i> = 128 patients with ONB	DFS	Kadish stage C/D and Hyams grading III/IV significantly affected DFS
Vuong et al. ¹³⁷⁷	2021	2	Systematic review and meta-analysis	33 studies; <i>N</i> = 492 with ONB	1. RFS 2. MFS 3. OS	1. RFS and OS were higher in Hyams grade I and II but lower in Hyams III/IV 2. RT offered survival advantage in grades III/IV 3. Chemotherapy did not offer survival benefit to any Hyams subgroup
Goshtasbi et al. ¹³⁴²	2019	2	Systematic review and meta-analysis	37 studies; <i>N</i> = 1088 with ONB	OS	1. OS rates between low and high grades were as follows: 5-year 81.2% versus 60.9% and 10-year 64.0% versus 40.6% 2. 5- and 10-year OS HR between low versus high grades were 3.39 (95% CI: 2.09–5.49; <i>p</i> < 0.001) and 3.03 (95% CI: 1.82–5.06; <i>p</i> < 0.001)
Ziai et al. ¹³⁴⁵	2021	4	Retrospective case series	<i>N</i> = 43 with ONB	OS	5-year OS rates in patients with low-grade versus high-grade tumors were 86% versus 63% (<i>p</i> = 0.1)
Wolfe et al. ¹³⁴⁶	2020	4	Retrospective case series	<i>N</i> = 39 with ONB	1. OS 2. DFS	1. 5-year cumulative OS and DFS were 83% and 72%, respectively 2. 5-year OS for low Hyams grade versus high Hyams grade was 95% versus 61% (<i>p</i> = 0.041) 3. High-grade and node-positive patient had worse DFS
Singh et al. ¹³⁴⁷	2019	4	Retrospective case series	<i>N</i> = 21 with ONB	1. Recurrence 2. OS	1. Recurrence rate was 80% in surgery alone group, which came down to 43.7% if surgery was supplemented with other modalities 2. Survival rates significantly dropped with increasing tumor stage (63.6% in stages A and B vs. 30% in stages C and D) and grade (100% in grades 1/2 vs. 31.25% in grades 3/4)
Wertz et al. ²⁴⁸	2018	4	Retrospective case series	<i>N</i> = 41 with ONB	1. PFS 2. OS	1. PFS at 5, 10, and 15 years was 69%, 48%, and 27%, respectively 2. OS at 5, 10, and 15 years was 97%, 92%, and 83%, respectively Stage and Hyams grade did not influence survival
Woods et al. ¹³⁷⁸	2018	4	Retrospective case series	<i>N</i> = 32 with ONB	OS	5-year survival was 65% Stage and Hyams grade prognostic for survival

Abbreviations: DFS, disease-free survival; ONB, olfactory neuroblastoma (esthesioneuroblastoma); OS, overall survival; PFS, progression-free survival.

TABLE XXIV.A.2 Evidence surrounding staging systems for ONB.

Study	Year	LOE	Study design	Study groups	Clinical endpoints	Conclusions
Meerwein et al. ¹³⁷⁶	2021	2	Systematic review and meta-analysis	33 studies; <i>N</i> = 128 patients with ONB	DFS	Kadish stage C/D and Hyams grading III/IV significantly affected DFS
Arnold et al. ¹³⁷⁹	2020	2	Systematic review and meta-analysis	21 studies; <i>N</i> = 399 patients with ONB	OS	<ol style="list-style-type: none"> 1. Increasing age, treatment with chemotherapy, and positive or unreported margin status portended worse DFS ($p < 0.05$) 2. Both Kadish and Dulguerov staging systems were prognostic for worse DFS and OS ($p < 0.05$), with Kadish C representing a heterogeneous group
Safi et al. ¹³⁵⁰	2020	2	Systematic review and meta-analysis	<i>N</i> = 94 patients with pediatric ONB	OS	<p>5-year survival 44%–91%</p> <p>At presentation, 90% are Kadish B/C</p>
Duo et al. ¹³⁶⁴	2022	4	Retrospective database study (SEER)	<i>N</i> = 513 patients with ONB	OS	<ol style="list-style-type: none"> 1. 5-year OS of patients who underwent RT versus non-RT were 85.3% versus 70.4% and 10-year OS were 68.2% versus 56.8% in stage C patients 2. In Kadish A/B, RT was not an independent prognostic factor for OS of modified Kadish stage A and B patients
Lechner et al. ¹⁵	2022	4	Retrospective case series	<i>N</i> = 404 patients with ONB	OS	<ol style="list-style-type: none"> 1. 5- and 10-year DFS was 67.6% (95% CI: 60.7%–73.6%) and 51.9% (95% CI: 43.8%–59.4%), respectively 2. Dural infiltration at presentation was a significant predictor of OS and DFS in primary cases ($n = 278$, HR = 2.22, 95% CI: 1.37–3.59)
Liu et al. ¹³⁸⁰	2021	4	Retrospective database study (SEER)	<i>N</i> = 826 patients with ONB	OS	Predictors of cause-specific mortality for ONB included age, tumor stage, surgery, and chemotherapy
Sun et al. ¹³⁸¹	2021	4	Retrospective case series	<i>N</i> = 142 patients with ONB	OS	<ol style="list-style-type: none"> 1. 5-year OS for patients with Kadish stages A, B, and C was 100%, 83.6%, and 64.2%, respectively 2. 5-year OS for Morita stages A, B, C, and D was 100%, 83.6%, 70.7%, and 50.0%, respectively
Yang et al. ¹³⁸²	2020	4	Retrospective case series	<i>N</i> = 154 patients with ONB	OS	Model of multiple tumor history, orbital invasion, carotid canal invasion, modified Kadish stage, delivery sequence of RT and surgery, and sequence of chemotherapy and surgery predicted outcome better than conventional staging systems

(Continues)

TABLE XXIV.A.2 (Continued)

Study	Year	LOE	Study design	Study groups	Clinical endpoints	Conclusions
Joshi et al. ⁴¹³	2019	4	Retrospective database study (NCDB)	N = 883 patients with ONB	OS	5- and 10-year survival for Kadish staging was 86.3% and 67.2% for Kadish A; 89.6% and 82.7% for Kadish B; 81.8% and 61.5% for Kadish C; and 60.0% and 29.5% for Kadish D
Singh et al. ¹³⁴⁷	2019	4	Retrospective case series	N = 21 patients with ONB	OS	Survival rates significantly dropped with increasing tumor stage (63.6% in stages A/B vs. 30% in stages C/D) and grade (100% in grades 1/2 vs. 31.3% in grades 3/4)
Orton et al. ¹³⁶⁵	2018	4	Retrospective database study (NCDB)	N = 931 patients with ONB	OS	5-year OS was 86%, 90%, 76%, and 61% in Kadish stages A, B, C, and D, respectively
Wertz et al. ²⁴⁸	2018	4	Retrospective case series	N = 41 patients with ONB	OS	Stage and Hyams grade did not influence survival
Woods et al. ¹³⁷⁸	2018	4	Retrospective case series	N = 32 patients with ONB	OS	Stage and Hyams grade prognostic for survival
Carey et al. ¹³⁸³	2017	4	Retrospective database study (NCDB)	N = 1225 patients with ONB	OS	OS was associated with Kadish stage, grade, treatment sequence, margin status, Charlson/Deyo score, age, and gender ($p < 0.05$)
Konuthula et al. ¹³⁸⁴	2017	4	Retrospective database study (NCDB)	N = 1167 patients with ONB	OS	5-year survival was 80.0% for Kadish A, 87.7% for Kadish B, 77.0% for Kadish C, and 49.5% for Kadish D
Xiong et al. ¹³⁶⁶	2017	4	Retrospective database study (NCDB)	N = 1167 patients with ONB	OS	The treatment characteristics between A/B could not explain survival differences

Abbreviations: DFS, disease-free survival; NCDB, National Cancer DataBase; ONB, olfactory neuroblastoma (esthesioneuroblastoma); OS, overall survival; PFS, progression-free survival; RT, radiation therapy; SEER, Surveillance, Epidemiology, and End Results.

Staging systems in ONB

Aggregate grade of evidence	B (Level 2: three studies; Level 4: 13 studies)
Benefit	Staging ONB extent provides prognostic information that may guide adjuvant therapy and allow for ease of communication to multidisciplinary and cross-institutional teams.
Harm	There are multiple staging systems with unique criteria, with overlapping and sometimes conflicting prognostic value.
Cost	There are no studies investigating the costs of ONB staging.
Benefits-harm assessment	Preponderance of benefits over harm.

Value judgments	Some staging systems (i.e., Kadish) were initially developed in the pre-endoscopic era and may not take into consideration all relevant prognosticators. Newer staging systems have not been fully validated.
Policy level	Recommendation.
Intervention	ONB staging systems are a useful measure for describing tumors, prognostication, and treatment planning, though other important tumor factors (e.g., grade, dural invasion) must also be considered.

3 | Management of the neck

This section is an evidence-based update to ICSB 2019 regarding management of the neck.⁵ In the past 5 years since that consensus statement, there have

(Continued)

been additional studies that met inclusion criteria pertaining to management of the neck in ONB patients (Table XXIV.A.3).^{15,412,457,1346,1350–1354} Many of these studies supported prior findings that patients who present with positive neck disease have significantly worse outcomes.^{412,1346,1351} As with prior reports, neck dissection was recommended for patients with clinically node positive disease.^{412,1346}

Kuan et al. queried 381 cases of ONB in the SEER database and identified an overall cervical nodal metastasis rate of 8.7%, with a predominance of level II disease (6.6%).¹³⁵⁴ Multiple positive nodes were identified in 4.5% of cases. Male sex ($p = 0.009$) and higher tumor grade ($p = 0.009$) were found to be predictors of cervical metastases. However, when analyzed through multivariate regression, the presence of cervical nodal disease was not found to be significantly predictive of OS or DFS, suggesting that other disease and patient characteristics, particularly age and tumor grade, are stronger drivers of survival.

In a single-institution study of 39 patients, Wolfe et al. reported pathologically confirmed nodal disease at surgery in eight patients (21%) and delayed nodal recurrences in seven patients (18%).¹³⁴⁶ The time to delayed nodal recurrence was a median of 59 months and one case at 16 years. The most common site of neck recurrence was level II (85%) and level III (42%). They reported a 27% 10-year nodal recurrence rate for patients who did not undergo ENI.¹³⁴⁶ Five of these patients who were treated with surgery alone (all Kadish stage A) did not have any recurrences or deaths with a median follow-up of 44 months. Based on these collective results and prior studies, this group recommended ENI for patients with Kadish C and D disease.¹³⁴⁶

In a single-institution study of 139 patients, Abdelmeguid et al. reported cervical lymphadenopathy at presentation in 17 patients (12.2%) and delayed nodal recurrence in 23 patients (16.5%).⁴¹² The most common site of neck recurrence was level II in 13 patients and level I in nine patients. Among 31 patients who underwent ENI, two developed neck recurrence (6.4%), whereas 20 patients (34.4%) who did not undergo ENI developed neck recurrence. Of note, the two patients who received ENI and developed regional recurrence had isolated intraparotid nodal spread, which was outside the radiation field. This group noted that ENI would be the most beneficial option for younger patients with Kadish C stage disease.⁴¹²

In a single-institution study of 143 patients, McMullan et al. reported regional disease in 13.8% of patients at presentation.¹³⁵¹ Thirty-two patients (22.4%) developed delayed neck recurrence at a median of 57 months with one case at 20 years.¹³⁵¹ In a multi-institutional study of 404 ONB patients, 11 of 65 patients who had not received

ENI had recurrence in the neck (16.9%) versus zero of 26 patients who received ENI.¹⁵ Among these 11 patients, nine presented with Kadish C disease.¹⁵ However, ENI did not impact OS in this multi-institutional international study.

In summary, in these updated studies, cervical lymphadenopathy on presentation has been noted in 9%–21% of ONB patients, and neck dissection followed by adjuvant RT is supported for these patients.¹³⁴⁶ Delayed neck recurrence is seen in approximately 20% of patients at a median time of approximately 57–59 months after diagnosis. This delayed presentation of neck recurrence suggests that neck surveillance should be performed beyond 5 years. Collectively these updated data support ENI administration for patients with Kadish C, Kadish D, or high-grade Hyams (III or IV) disease. The role of ENI for Kadish A, Kadish B, or low-grade Hyams disease is less clear and should be guided by high-risk features and an individualized evaluation with a radiation oncologist.

Elective management of the N0 neck in ONB

Aggregate grade of evidence	C (Level 2: two studies; Level 4: eight studies).
Benefit	Treatment of clinically positive neck disease assists in disease control. Delayed regional involvement in the neck is common with a median time to recurrence of approximately 5 years. Elective treatment of the neck with irradiation, particularly in patients with high-stage/grade disease, shows significantly reduced evidence of nodal recurrence but does not significantly impact OS.
Harm	Neck dissection can lead to complications including hematoma, infection, cranial nerve palsies, chyle leak, among others. RT of the neck is associated with xerostomia, skin changes, and long-term toxicity.
Cost	There are no studies investigating the costs of upfront or delayed treatment of the N0 neck.
Benefits-harm assessment	Preponderance of benefits over harms (N+ neck). Balance of benefits and harms (N0 neck).
Value judgments	Elective treatment of the N0 neck is likely to prevent long-term regional recurrence in ONB patients with high-stage/grade disease and may lead to improved DFS.
Policy level	Recommendation for treating N+ neck. Option for treating N0 neck.

(Continued)

TABLE XXIV.A.3 Evidence surrounding management of the neck in ONB.

Study	Year	LOE	Study design	Study groups	Clinical endpoints	Conclusions
Wu et al. ⁴⁷	2022	2	Systematic review and meta-analysis	22 studies; <i>N</i> = 104 ONB with orbital invasion	OS	<ol style="list-style-type: none"> For ONB with orbital invasion, median duration of survival was 124.0 months and 5-year OS was 67.1% Patients with orbital invasion and lymph node metastasis had worse outcomes
Safi et al. ³³	2020	2	Systematic review and meta-analysis	Seven studies; <i>N</i> = 94 with pediatric ONB	OS	At presentation, positive lymph nodes present 20%
Abdelmeguid et al. ⁴¹²	2022	4	Retrospective case series	<i>N</i> = 139 patients with ONB	OS	Delayed neck recurrence was lower in irradiated N0 neck (6.4% vs. 34%)
McMillian et al. ⁴²	2022	4	Retrospective case series	<i>N</i> = 143 patients with ONB	OS	Delayed regional nodal metastasis occurred in 22% of patients (median 57 months)
Cranmer et al. ¹³⁷¹	2020	4	Retrospective database study (SEER)	<i>N</i> = 797 patients with ONB	<ol style="list-style-type: none"> OS DSS 	<ol style="list-style-type: none"> In adjusted multivariable analyses, chemotherapy treatment was associated with inferior DSS Among the subset with local or regional disease treated with surgery and/or RT, chemotherapy remained associated with inferior outcomes This analysis does not support chemotherapy to improve either DSS or OS in primary ONB/ON treatment, after controlling for known ONB prognostic factors available from SEER
Song et al. ⁴⁵⁷	2020	4	Retrospective case series	<i>N</i> = 217 patients with ONB	OS	Multivariate analysis demonstrated lymph node status, orbital invasion, and the combination of surgery and RT to be independent prognostic factors
Wolfe et al. ¹³⁴⁶	2020	4	Retrospective case series	<i>N</i> = 39 patients with ONB	<ol style="list-style-type: none"> OS DFS 	High Hyams grade and node-positive patient had worse DFS
Joshi et al. ⁴¹³	2019	4	Retrospective database study (NCDB)	<i>N</i> = 883 patients with ONB	OS	Age, Charlson–Deyo comorbidity score, hospital volume, and nodal status were found to be predictors of survival
Kuan et al. ¹³³⁵	2019	4	Retrospective database study (NCDB)	<i>N</i> = 381 patients with ONB	<ol style="list-style-type: none"> Cervical nodal metastases OS DFS 	<ol style="list-style-type: none"> Overall cervical metastasis rate was 8.7%; level II most common 4.5% cases had multiple positive nodal basins Male sex and higher tumor grade predicted nodal metastases Nodal metastases did not predict OS and DFS and multivariate regression
Klironomos et al. ¹³⁵²	2018	4	Retrospective case series	<i>N</i> = 10 ONB by endoscopic surgery	OS	<ol style="list-style-type: none"> Delayed neck recurrence 20% No local recurrence in mean 75 months follow-up

Abbreviations: DFS, disease-free survival; DSS, disease-specific survival; NCDB, National Cancer DataBase; ONB, olfactory neuroblastoma (esthesioneuroblastoma); OS, overall survival; PFS, progression-free survival; RT, radiation therapy; SEER, Surveillance, Epidemiology, and End Results.

TABLE XXIV.A.4 Evidence surrounding management of the orbit in ONB.

Study	Year	LOE	Study design	Study groups	Clinical endpoints	Conclusions
Wu et al. ¹³⁵⁵	2022	2	Systematic review and meta-analysis	22 studies; <i>N</i> = 104 ONB with orbital invasion	OS	<ol style="list-style-type: none"> For ONB with orbital invasion, median duration of survival was 124.0 months and 5-year OS was 67.1% Patients with orbital invasion and lymph node metastasis had worse outcomes
Song et al. ¹³⁸⁵	2020	4	Retrospective case series	<i>N</i> = 217 patients with ONB	OS	<ol style="list-style-type: none"> 5-year OS was 80.0% Multivariate analysis demonstrated lymph node status, orbital invasion, and the combination of surgery and RT to be independent prognostic factors
Yang et al. ¹³⁸²	2020	4	Retrospective case series	<i>N</i> = 154 patients with ONB	OS	Model of multiple tumor history, orbital invasion, carotid canal invasion, modified Kadish stage, delivery sequence of RT and surgery, and sequence of chemotherapy and surgery predicted outcome better than conventional staging systems
Li et al. ⁴⁹⁵	2019	4	Retrospective case series	<i>N</i> = 60 ONB with orbital invasion	OS	Invasion of either the extraocular muscles or the eye globe was not a contraindication for eye-sparing surgery with RT or surgery/RT

Abbreviations: ONB, olfactory neuroblastoma (esthesioneuroblastoma); OS, overall survival; RT, radiation therapy.

Intervention	In a node-positive neck, the role of surgical treatment and adjuvant radiation for ONB patients is well established. However, in patients with a clinically N0 neck and high Hyams grade (III/IV) or Kadish C/D stage, ENI should be considered. Long-term surveillance (>5 years) of the neck is recommended.
--------------	--

4 | Management of the orbit

ONB has a propensity for invasion of adjacent structures including the orbit (Table XXIV.A.4). Indeed, multiple studies have reported rates of orbital invasion in ONB ranging from 10% to 38%.^{412,1351,1355} Orbital invasion has repeatedly been demonstrated to be a negative prognostic factor. A multi-institutional international retrospective study of 404 patients with ONB reported orbital invasion to be associated with worse OS and DFS (HR 2.9 and 3.1, respectively) on univariate Cox regression analysis.^{15,412} Another single-institution study of 143 patients treated from 1960 to 2020 also reported an association with orbital invasion and worse OS (HR 3.2, *p* = 0.02).¹³⁵¹ However, no

association was observed in this study with orbital invasion and DFS or DMFS.¹³⁵¹

The field as a whole has gravitated toward orbital preservation treatment where oncologically safe. However, due in part to the rare nature of ONB, there are few studies addressing orbital preservation. Furthermore, the ability to achieve disease control in the setting of orbital preservation may depend on the degree of orbital involvement. A retrospective review of 16 cases of ONB identified six patients with periorbital or lacrimal sac involvement at the time of surgery. In these cases, the periorbita was resected and the orbit was spared without evidence of decreased survival.¹³⁵⁶ IC has been proposed by some groups for ONB with significant local invasion including the orbit.^{1357,1358} Su et al. reported their experience with IC in 15 cases of advanced ONB and reported success in orbital preservation in three cases, and a higher chemotherapy response rate was observed in Hyams grade III and IV tumors. Lastly, another retrospective study of 60 ONB patients with orbital invasion reported an orbital preservation approach using RT with or without orbit-preserving surgery.⁴⁹⁵ However, patients with more significant orbital involvement (grade II/III vs. grade I) were noted to have worse OS and PFS.⁴⁹⁵ In this study, grade I was defined as bone wall invasion,

whereas grade II was defined as invasion of extraconal fat and grade III as involvement of extraocular muscles, globe, orbital apex, or optic nerve.

Management of the orbit in ONB

Aggregate grade of evidence	C (Level 2: one study; Level 4: three studies)
Benefit	Potential for orbital preservation with induction chemotherapy approaches.
Harm	Orbital invasion is associated with decreased OS.
Cost	Not evaluated in current studies.
Benefits-harm assessment	Balance of benefits and harms.
Value judgments	There are some data to suggest that orbital preservation may be feasible in select cases.
Policy level	Option.
Intervention	Consider induction chemotherapy for advanced cases with significant local or orbital invasion, especially if high-grade tumors. Further studies are necessary to determine the balance between orbital exenteration and orbital preservation approaches for ONB.

5 | Unilateral resection and smell preservation

Inherent to an oncologic resection of an ONB is olfactory loss. Traditional open and endoscopic approaches remove the cribriform plate bilaterally, resulting in postoperative anosmia. Given the morbidity of olfactory loss, there has been some interest in unilateral resection of ONB, whenever oncologically feasible, with the aim of smell preservation (Table XXIV.5).^{1359–1361}

Nakagawa et al. reported 12 patients from 10 tertiary referral hospitals in Japan between 2008 and 2016 who underwent unilateral ONB resection with the intent of olfactory preservation.¹³⁶⁰ Six patients had Dulguerov stage T1, three had T2, and three had T3 disease. They achieved negative margin resections in all patients. In this study, olfaction was assessed via interview and retained in 11 patients (92%), nine of whom received RT. The 12th patient could smell after surgery; however, they developed smell loss after RT. With a mean follow-up of 43.8 months, there were no recurrences reported. Tajudeen et al. reported a multi-institutional retrospective review of 14 patients who underwent unilateral endoscopic ONB resection with preservation of one olfactory bulb between 2003 and 2015.¹³⁶¹ Six patients had Kadish B, six had Kadish C, and two had Kadish stage D. All patients had nega-

tive margin resections and completed adjuvant RT. Four patients had chemotherapy. The University of Pennsylvania Smell Identification Test (UPSIT), performed at a mean of 37.3 months, demonstrated that six patients (43%) had residual smell function; two patients (14%) had normal or mildly reduced smell function. There were no recurrences with a mean follow-up of 51.3 months.

In a study by Van Gompel et al., the authors evaluated the ability of five board-certified skull base surgeons to determine the degree of involvement of the olfactory bulbs or tracts based on preoperative imaging.¹³⁶² The authors analyzed 26 patients histopathologically and reported the olfactory bulb or tract was involved in 85% of cases, with unilateral or no involvement in 65% of cases. The authors reported that the surgeons could predict or overcall bulb/tract involvement 96% of the time based on preoperative imaging. We note, however, that the absolute surgeon prediction accuracy was significantly lower.

In a relevant anatomical study by Gomez Galarce et al., the authors examined 17 cadaveric specimens (34 sides) and elucidated the anatomical distribution and density of olfactory fila.¹³⁶³ Interestingly, 88% of specimens had olfactory fila that crossed midline. In specimens with crossing olfactory fila, 20% of the fila crossed the nasal septum at the midline. The authors suggest that in some patients with unilateral tumors with septal involvement, it may not be cogent to preserve the contralateral olfactory epithelium, even when clinically and radiographically clear.¹³⁶³

The primary goal of surgery for ONB is an oncologic resection and any attempt for a unilateral resection and smell preservation should not compromise this goal. The LOE is not sufficient to support unilateral resection for smell preservation as a recommendation. In select cases, this approach might be an option.

Unilateral resection and smell preservation in ONB

Aggregate grade of evidence	D (Level 4: three studies)
Benefit	Potential for some smell preservation if unilateral structures are preserved.
Harm	Not achieving an R0 resection given more limited approach. Possibility of smell loss regardless of unilateral approach given contralateral intracranial dissection, or RT side effect.
Cost	There are no studies investigating cost.
Benefits-Harms Assessment	Preponderance of benefits over harms if negative margins can be obtained through unilateral resection.
Value judgments	Smell preservation must not compromise oncologic resection.

(Continued)

TABLE XXIV.5 Evidence surrounding unilateral resection and smell preservation in ONB.

Study	Year	LOE	Study design	Study groups	Clinical endpoints	Conclusions
Nakagawa et al. ¹³⁶⁰	2018	4	Retrospective case series	N = 22 ONB by endoscopic surgery	OS	21 out of 22 (95%) alive at last follow-up
Van Gompel et al. ¹³⁶²	2018	4	Retrospective case series	N = 26 ONB imaging review by skull base surgeons to predict olfactory bulb involvement	Correlation of radiographic and pathologic olfactory bulb involvement by tumor	1. Unilateral or no pathologic olfactory involvement in 65% on pathology 2. Surgeon prediction of olfactory bulb involvement was appropriate or overread (96%)
Tajudeen et al. ¹³⁶¹	2016	4	Retrospective case series	N = 14 patients undergoing unilateral ONB resection (seven received postoperative RT)	1. Olfaction (UPSIT) 2. OS 3. Recurrence	1. Six (43%) patients had residual smell function, with two having near-normal to normal function 2. No cases had disease recurrence

Abbreviations: ONB, olfactory neuroblastoma (esthesioneuroblastoma); OS, overall survival.

Policy level	Option.
Intervention	Unilateral resection in an attempt to preserve olfactory function may be an option in select cases of limited extent unilateral tumors with negative margin resections.

6 | Role of radiation therapy

RT has long played an important role in the management of ONB with traditional modalities such as external beam, IMRT, carbon-ion (CIRT), and more recently proton beam therapy (PBT) (Table XXIV.A.6). RT has been used in various forms as neoadjuvant, adjuvant, and as definitive therapy for ONB. The most common use of RT is adjuvant therapy after surgical resection. A total of nine studies reported improved OS at 3–5 years for patients who underwent postoperative RT.^{253,484,521,1347,1364–1368} All studies found adjuvant RT safe with minimal side effects. When stratified by Kadish staging, two specific studies found that adjuvant RT only improved survival for patients with Kadish C and D tumors.^{1364,1365} Two studies examined the definitive use of IMRT and one study with PBT for treatment of ONB.^{486,526,557} Bao et al. reported acceptable 3-year OS with IMRT alone.⁴⁸⁶ Another study by Nakamura demonstrated that PBT as primary therapy was safe and effective, especially for Kadish A tumors where 5-year OS was 100%.⁵²⁶ The use of CIRT was also investigated in three studies and found to be effective with acceptable late toxicities as definitive therapy, specifically for advanced disease (Kadish C/D).^{472,557,558} Another study reported that delays in, or prolonged duration of, RT may be associated with

decreased survival.¹³⁶⁹ Lastly, two studies reported no additional benefit to the use of adjuvant RT in the postoperative setting.⁴⁸⁸ Liu et al. demonstrated that surgery followed by IMRT did not improve OS.⁴⁸⁸ Kiyofuji et al. reported that planned postoperative IMRT after a margin negative surgical resection for low-grade ONB (Hyams I/II) did not provide benefit in tumor control.¹³⁷⁰

Role of radiation therapy in ONB

Aggregate grade of evidence	C (Level 2: two studies; Level 4: 14 studies)
Benefit	Improved OS at 3 and 5 years when used as adjuvant therapy.
Harm	Generally safe, especially with newer modalities, with some late toxicities.
Cost	There are no studies investigating cost.
Benefits–Harms Assessment	Preponderance of benefits over harms.
Value judgments	Current conclusions based on limited high-quality studies. Larger studies are needed.
Policy level	Option.
Intervention	Postoperative adjuvant RT is effective, especially in cases with positive margins, and higher grade or Kadish stage tumors.

7 | Role of systemic therapy

Chemotherapy has been explored for the treatment of ONB with variable response rates reported in adults (Table XXIV.A.7). Treatment typically consists of

TABLE XXIV.A.6 Evidence surrounding the role of radiation therapy for ONB.

Study	Year	LOE	Study design	Study groups	Clinical endpoints	Conclusions
Vuong et al. ¹³⁷⁷	2021	2	Systematic review and meta-analysis	33 studies; <i>N</i> = 492 patients with ONB	OS	RT offered survival advantage in Hyams grades III/IV
Marinelli et al. ¹³⁸⁶	2018	2	Systematic review and meta-analysis	48 studies; <i>N</i> = 118 ONB presenting with distant disease	OS	Multimodality therapy offered benefit over single or no therapy
Duo et al. ¹³⁶⁴	2022	4	Retrospective database study (SEER)	<i>N</i> = 513 patients with ONB	OS	5-year OS rates of patients who underwent RT versus non-RT were 85.3% versus 70.4%
Tsutsumi et al. ¹³⁶⁹	2022	4	Retrospective database study (NCDB)	<i>N</i> = 814 patients with ONB	OS	Delays during, and prolongation of RT, for ONB appears to be associated with decreased OS
Vuong et al. ¹³⁸⁷	2022	4	Retrospective database study (SEER)	<i>N</i> = 733 patients with ONB	OS	Surgery and adjuvant RT is associated with improved patient survival
Wang et al. ¹³⁸⁸	2021	4	Retrospective case series	<i>N</i> = 37 ONB with frontal lobe involvement	1. OS 2. PFS	Patients who received surgery combined with CRT showed better OS (89.4% vs. 53.6%, <i>p</i> = 0.001) and PFS (87.8% vs. 53.6%, <i>p</i> = 0.001) compared with those who did not undergo surgery
Zeng et al. ⁴⁸⁴	2021	4	Retrospective case series	<i>N</i> = 64 patients with ONB	OS	Surgery and RT had best survival
Liu et al. ⁴⁸⁸	2020	4	Retrospective case series	<i>N</i> = 37 patients with ONB	1. OS 2. PFS 3. LRC 4. DMFS	Similar OS, PFS, LRC, and DMFS between groups
Song et al. ¹³⁸⁵	2020	4	Retrospective case series	<i>N</i> = 217 patients with ONB	OS	Multivariate analysis demonstrated lymph node status, orbital invasion, and the combination of surgery and RT to be independent prognostic factors
Yang et al. ¹³⁸²	2020	4	Retrospective case series	<i>N</i> = 154 patients with ONB	OS	Model of multiple tumor history, orbital invasion, carotid canal invasion, modified Kadish stage, delivery sequence of RT and surgery, and sequence of chemotherapy and surgery predicted outcome better than conventional staging systems
Kim et al. ²⁵³	2019	4	Retrospective case series	<i>N</i> = 28 patients with ONB	OS	Patients with adjuvant RT had a 5-year PFS of 46.7%, whereas those treated with surgery alone had a 5-year PFS of 19.4% (<i>p</i> = 0.01)

(Continues)

TABLE XXIV.A.6 (Continued)

Study	Year	LOE	Study design	Study groups	Clinical endpoints	Conclusions
Li et al. ¹⁶⁴	2019	4	Retrospective case series	N = 60 ONB with orbital invasion	OS	<ol style="list-style-type: none"> 5-year OS of 63.5%; 46 received surgery plus RT, with a 5-year OS of 70.7% Invasion of either the extraocular muscles or the eye globe was not a contraindication for eye-sparing surgery with RT or surgery/RT
Miller et al. ¹³⁸⁹	2019	4	Retrospective case series	N = 38 patients with ONB	OS	Patients who received platinum-based CRT did not exhibit improved survival compared to surgery/RT alone
Singh et al. ¹³⁴⁷	2019	4	Retrospective case series	N = 21 patients with ONB	Recurrence	Recurrence rate was 80% in surgery alone group, which decreased to 43.7% if surgery was supplemented with other modalities
Orton et al. ¹³⁶⁵	2018	4	Retrospective database study (NCDB)	N = 931 patients with ONB	OS	<p>Adjuvant RT decreased mortality (HR 0.53, $p < 0.01$)</p> <p>5-year OS was 85% versus 53% versus 29% for primary surgery, RT, and chemotherapy</p>
Carey et al. ¹³⁸³	2017	4	Retrospective database study (NCDB)	N = 1225 patients with ONB	OS	<ol style="list-style-type: none"> OS was associated with Kadish stage, grade, treatment sequence, margin status, Charlson/Deyo score, age, and gender Surgery with RT had lower risk of death compared to surgery alone (OR 0.61; 95% CI: 0.40–0.95)

Abbreviations: DMFS, distant metastasis-free survival; DSS, disease-specific survival; LRC, locoregional control; NCDB, National Cancer DataBase; ONB, olfactory neuroblastoma (esthesioneuroblastoma); OS, overall survival; PFS, progression-free survival; RT, radiation therapy; SEER, Surveillance, Epidemiology, and End Results.

platinum-based regimens combined with etoposide or other agents. As an adjuvant treatment, two recent SEER database studies over a 40-year time period did not detect an improvement in OS with the addition of chemotherapy.¹³⁷¹ This finding was further corroborated by a large international multi-institutional retrospective study of 404 cases with an HR of 1.07 for OS and 1.40 for DFS.¹⁵ When combined with RT as definitive treatment, chemotherapy may have some benefit in adult patients; however, this is particularly true for pediatric ONB that is regarded as chemosensitive.^{1335,1372,1373} In a multi-institutional retrospective review of 24 cases of pediatric ONB (<21 years of age), an 84% objective response rate was observed in patients who received neoadjuvant chemotherapy.¹³⁷³ In an NCDB study of 1411 ONB patients, 45 of which were pediatric (<18 years of age), use of chemotherapy was more common and the

pediatric group had an 87% 10-year OS compared to 66% for adults. However, due to low patient numbers and variable treatment paradigms, the full impact of chemotherapy in pediatric ONB remains unknown.¹³³⁵

Neoadjuvant chemotherapy has recently been advocated by several groups for locally advanced or unresectable disease.^{1357,1358} One retrospective study reported that this approach aided in achieving a negative margin resection in 80% of patients (4/5) for which a negative margin resection was not initially believed to be attainable. Additionally, of a series of 15 patients who underwent IC, a 78% response rate (7/9 patients) in the high Hyams grade group compared to 50% (3/6 patients) in the low Hyams grade group was observed.¹³⁵⁷ Seven patients had a complete response and three patients were able to avoid orbital exenteration using this approach.¹³⁵⁷ Although these are low patient numbers, these results suggest that neoadju-

TABLE XXIV.A.7 Evidence surrounding the role of systemic therapy in ONB.

Study	Year	LOE	Study design	Study groups	Clinical endpoints	Conclusions
Vuong et al. ¹³⁷⁷	2021	2	Systematic review and meta-analysis	33 studies; <i>N</i> = 492 patients with ONB	OS	Chemotherapy did not offer survival benefit to any Hyams subgroup
Arnold et al. ¹³⁷⁹	2020	2	Systematic review	21 studies; <i>N</i> = 399 patients with ONB	1. OS 2. DFS	Increasing age, treatment with chemotherapy, and positive or unreported margin status portended worse DFS (<i>p</i> < 0.05)
Marinelli et al. ¹³⁸⁶	2018	2	Systematic review and meta-analysis	48 studies; <i>N</i> = 118 ONB presenting with distant disease	OS	Multimodality therapy offered benefit over single or no therapy
Vuong et al. ¹³⁸⁷	2022	4	Retrospective database study (SEER)	<i>N</i> = 733 patients with ONB	OS	The use of chemotherapy did not confer survival advantage
Brisson et al. ¹³⁷²	2021	4	Retrospective database study (SEER)	<i>N</i> = 636 patients with ONB	OS	The only patient population that derived benefit from CT were patients who did not receive surgery and were treated with CT and/or RT (HR 0.3, 95% CI: 0.14–0.61, <i>p</i> < 0.001)
Liu et al. ¹³⁸⁰	2021	4	Retrospective database study (SEER)	<i>N</i> = 826 patients with ONB	OS	Predictors of cause-specific mortality for ONB included age, tumor stage, surgery, and chemotherapy
Wang et al. ¹³⁸⁸	2021	4	Retrospective case series	<i>N</i> = 37 ONB with frontal lobe involvement	1. OS 2. PFS	Patients who received surgery combined with RT/CRT showed better OS and PFS compared with those who did not undergo surgery
Crammer et al. ¹³⁷¹	2020	4	Retrospective database study (SEER)	<i>N</i> = 797 patients with ONB	1. OS 2. DSS	<ol style="list-style-type: none"> In adjusted multivariable analyses, chemotherapy was associated with inferior DSS Among the subset with local or regional disease treated with surgery and/or RT, chemotherapy remained associated with inferior DSS This analysis does not support chemotherapy to improve either DSS or OS in primary ONB/ON treatment, after controlling for known ONB prognostic factors available from SEER
Yang et al. ¹³⁸²	2020	4	Retrospective case series	<i>N</i> = 154 patients with ONB	OS	Model of multiple tumor history, orbital invasion, carotid canal invasion, modified Kadish stage, delivery sequence of RT and surgery, and sequence of chemotherapy and surgery predicted outcome better than conventional staging systems

(Continues)

TABLE XXIV.A.7 (Continued)

Study	Year	LOE	Study design	Study groups	Clinical endpoints	Conclusions
Miller et al. ¹³⁸⁹	2019	4	Retrospective case series	N = 38 patients with ONB	OS	Patients who received platinum-based CRT did not exhibit improved survival compared to surgery/RT alone
Orton et al. ¹³⁶⁵	2018	4	Retrospective database study (NCDB)	N = 931 patients with ONB	OS	5-year OS was 85% versus 53% versus 29% for primary surgery, RT, and chemotherapy
Carey et al. ¹³⁸³	2017	4	Retrospective database study (NCDB)	N = 1225 patients with ONB	OS	Adjuvant chemotherapy did not offer survival advantage
Su et al. ¹³⁵⁷	2017	4	Retrospective case series	N = 15 Advanced ONB with induction chemotherapy	1. DFS 2. OS	5-year DFS and OS were 71% and 78%, respectively

Abbreviations: CRT, chemoradiation therapy; DFS, disease-free survival; DSS, disease-specific survival; LRC, locoregional control; NCDB, National Cancer DataBase; ONB, olfactory neuroblastoma (esthesioneuroblastoma); OS, overall survival; PFS, progression-free survival; RT, radiation therapy; SEER, Surveillance, Epidemiology, and End Results.

vant/IC may play a beneficial role for patients who present with extensive locally invasive or unresectable disease.

The effectiveness of immunotherapy in ONB has not yet been reported. However, PD-L1 expression, a key immune checkpoint pathway, has been reported in ONB, suggesting a potential role for immune checkpoint blockade.¹¹² A recent study of 32 ONB patients found that poorer DFS was associated with high transforming growth factor beta (TGF- β) signaling and postulated that given its immunosuppressive function that concomitant TGF- β and immune checkpoint blockade may be beneficial in restoring an ONB tumor immune response.¹³⁷⁴ An active immunotherapy clinical trial at the National Institutes of Health using bifunctional PD-L1/TGF- β blockade is currently available for patients with recurrent or metastatic ONB (NCT05012098). Somatostatin receptor 2 (*SSTR2*) has been reported to be highly expressed in ONB and is potentially amenable to targeting with peptide receptor radionuclide therapy such as ¹⁷⁷Lu-DOTA-TATE.^{15,1375} Indeed, several small studies have reported efficacy in recurrent or metastatic ONB, necessitating further investigation.⁴⁵³

Table XXIV.8 includes additional studies relevant to survival outcomes in ONB during the updated review period.

Role of systemic therapy in ONB

Aggregate grade of evidence	C (Level 2: three studies; Level 4: 10 studies)
Benefit	Potential benefit for neoadjuvant chemotherapy in locally advanced or unresectable cases.
Harm	Possible side effects from systemic therapy. Etoposide may be associated with bone marrow suppression leading to pancytopenia, while platinum-based agents may lead to renal, neurological, and otologic impairment.
Cost	Not evaluated in current studies.
Benefits-Harms Assessment	Balance of benefits and harms.
Value judgments	There are some data to suggest that neoadjuvant chemotherapy may be of value in select cases. No current ability to select for possible responders before treatment.
Policy level	Option.
Intervention	Consider neoadjuvant chemotherapy for locally advanced cases. Further studies are necessary to determine the benefit of other systemic treatment approaches for ONB.

TABLE XXIV.8 Other studies relevant to survival outcomes for ONB.

Study	Year	LOE	Study design	Study groups	Clinical endpoints	Conclusions
Mays et al. ⁹⁷	2018	3	Retrospective cohort	N = 35 ONB without skull base involvement	DFS	1. 5- and 10-year DFS were 89% and 78% 2. Resection of bone but not of dura/bulb affected DFS
Sharma et al. ⁸⁴	2022	4	Retrospective database study (SEER)	N = 561 patients with ONB	1. DSS 2. OS	Socioeconomic status associated with lower 5-year DSS
Barinsky et al. ⁸⁵	2021	4	Retrospective database study (NCDB)	N = 533 patients with ONB	OS	1. Endoscopic cases had higher 5-year OS (81.9% vs. 75.6%, $p = 0.030$) 2. After multivariate regression, survival benefit to endoscopic surgery nonsignificant (HR 0.644; 95% CI: 0.392–1.058; $p = 0.083$)
Berger et al. ⁶	2021	4	Retrospective database study (NCDB)	N = 1411 patients with ONB	IS	10-year OS in the pediatric cohort was higher compared to the adult cohort (87% vs. 66%, $p < 0.05$)
Burnhan et al. ⁸⁶	2021	4	Retrospective database study (SEER)	N = 882 patients with ONB	1. DSS 2. OS	There was a long-term DSS decline of geriatric compared to pediatric cases after 100 months
Goshtasbi et al. ⁸⁷	2021	4	Retrospective database study (NCDB)	N = 1601 patients with ONB	OS	Worse prognosis was seen at low-facility centers when binarizing patients according to median case volume (HR 1.280; CI: 1.017–1.611; $p = 0.03$)
Mikhael et al. ⁸⁸	2021	4	Retrospective database study (SEER)	N = 987 patients with ONB	1. DS	1. 5-year DSS was 81.0% (West), 79.8% (East), 67.4% (Midwest), and 72.7% (South); $p = 0.018$ 2. 10-year DSS was 74.0% (West), 73.7% (East), 60.9% (Midwest), and 63.6% (South); $p = 0.017$
Wu et al. ⁸⁹	2022	4	Retrospective case series	N = 82 patients with ONB	OS	Isocitrate dehydrogenase 2 (IDH2) mutation-positive tumors had more aggressive behavior and conferred a poor prognosis
Cai et al. ⁹⁰	2021	4	Retrospective case series	N = 42 patients with ONB	1. OS 2. DFS	1. The 5-year OS and DFS rates were 89.1% and 79.2%, respectively 2. The overall surgical complication incidence was 9.52% (one cerebrospinal fluid rhinorrhea, one cervical hematoma, and two epileptic seizures)
Dumont et al. ⁹¹	2020	4	Retrospective case series	N = 18 Pediatric ONB	OS	5-year OS and event-free survival were 44.4%

(Continues)

TABLE XXIV.8 (Continued)

Study	Year	LOE	Study design	Study groups	Clinical endpoints	Conclusions
Navarro-Fernandez et al. ⁹²	2020	4	Retrospective case series	N = 12 Pediatric ONB	1. PFS 2. OS	1. The surgical complication rate was 8.3% 2. PFS was 41 months and mean OS was 63.6%
Classe et al. ⁹³	2019	4	Retrospective case series	N = 45 patients with ONB	OS	A Ki67% \geq 25 was associated with poorer survival. Overall survival was 68.9%
Gallia et al. ⁹⁴	2018	4	Retrospective case series	N = 20 ONB by endoscopic surgery	1. OS 2. DSS 3. RFS	5-year OS, DSS, and RFS were 92.9%, 100%, and 92.9%, respectively
Gram et al. ⁹⁵	2018	4	Retrospective case series	N = 14 patients with ONB	OS	5-year OS was 90% (95% CI: 61–99%)
Konig et al. ⁹⁶	2018	4	Retrospective case series	N = 20 patients with ONB	1. OS 2. DSS	1. OS and DSS were 92.9% at 2 years, 70.7% at 5 years, and 70.7% at 10 years of follow-up 2. Nasal stenosis in 70%
Yin et al. ⁸⁷	2018	4	Retrospective database study (SEER)	N = 876 patients with ONB	1. OS 2. DSS	1. OS and DSS rates of 69% and 78% at 5 years 2. Patients age >60 years presented significantly poor OS and DSS on multivariate analysis
Yu et al. ⁹⁸	2018	4	Retrospective case series	N = 20 ONB with intracranial involvement	DFS	1. 5- and 8-year DFS were 69% and 54% 2. 37% had recurrence and 65% of those involved the dura 3. Salvage treatments were effective
Yuan et al. ⁶¹	2018	4	Retrospective case series	n = 44 patients with ONB	1. OS 2. PFS	5-year OS and PFS were 42.7% and 39.1%, respectively, with 10-year rates of 28.9% and 21.7%
Schmidt et al. ⁹⁹	2017	4	Retrospective case series	N = 11 patients with ONB	1. OS 2. DFS	10-year OS and DFS were 68.2% and 46.7%

Abbreviations: CRT, chemoradiation therapy; DFS, disease-free survival; DSS, disease-specific survival; LRC, locoregional control; NCDB, National Cancer DataBase; ONB, olfactory neuroblastoma (esthesioneuroblastoma); OS, overall survival; PFS, progression-free survival; RFS, recurrence-free survival; RT, radiation therapy; SEER, Surveillance, Epidemiology, and End Results.

B | Sinonasal undifferentiated carcinoma and variants

Undifferentiated sinonasal carcinomas have some of the poorest outcomes among head and neck cancers. They are typically locally advanced at presentation, necessitating multimodality therapy. Sinonasal undifferentiated carcinoma (SNUC) was first described by Frierson et al. in 1986.¹³⁹⁰ It was considered a diagnosis of exclusion but served as a “wastebasket” for unknown, poorly differentiated SNM.¹³⁹¹ Further delineation and re-examination of this entity have frequently resulted in a change in diagnosis from SNUC to one of the more recently defined entities, such as *SMARBI*-deficient or NUT carcinoma.^{1071,1392,1393} The management of this disease has likewise continued to

evolve and there is growing evidence supporting the use of IC. This section expounds on ICSB 2019 (Section VIII.C), including the multimodality therapy for SNUC with the addition of two recently identified categories: NUT and SWI/SNF-deficient carcinoma. Endoscopic versus open surgery in the management of SNUC was discussed in the prior review and will not be addressed here.

1 | Sinonasal undifferentiated carcinoma

SNUC has historically made up 3%–5% of sinonasal carcinomas.⁹⁸ The male-to-female ratio is typically high around 2–3:1.^{28,1394} Although SNUC can be diagnosed at any age, the median is approximately 50–55 years.^{1394–1396}

The pathological features are typically high grade with nests, sheets, or ribbons of undifferentiated cells without glandular or squamous features. Testing for keratins, including pancyokeratin (AE1/AE3) and cytokeratins 7, 8, and 18, is often positive.¹³⁹³ S100 and Epstein–Barr virus tests are negative.¹³⁹⁷ IDH2 hotspot mutations are identified in a significant subset of SNUCs, and IDH2(R172S) is the most common. IDH-mutant SNUC demonstrates a hypermethylation phenotype, and DNA-based profiling studies show that IDH-mutant SNM constitutes a distinct group from IDH-wild-type tumors.^{1398–1400} Presently, no morphologic or immunohistochemical differences between SNUC that are IDH-mutant or wild-type are recognized. Imaging differentiates SNUC from other SNM. SNUC has consistently been found to have a lower ADC ratio than ACC and a higher FDG avidity than ONB, metastatic tumors, or ACC on PET imaging.^{200,223,1127,1401}

Orbital and skull base invasions are frequent; 80% of tumors are T3 or T4 at diagnosis.^{499,1394,1396} Surgery with adjuvant RT or CRT and definitive CRT both have demonstrated survival benefit over surgery or RT alone.^{1394,1402} Trimodality treatment has had variable superiority over bimodality treatment.^{499,1394,1403} Some studies have suggested better outcomes with surgery plus adjuvant therapy than with definitive CRT, but this is possibly related to selection bias based on resectability.^{367,1404,1405} While the preponderance of studies show that patients treated with surgery with negative margins followed by RT or CRT have favorable survival, margin status has not been consistently reported as a prognostic indicator and resectable patients remain in the minority.^{367,1406} Radiation doses greater than 60 Gy have been associated with improved survival.^{499,1397} A growing body of evidence supports the potential benefit of IC. Around half of patients will experience disease recurrence within 3 years of treatment.^{497,1396} Five-year survival rates range from 35% to 81%.^{499,1395,1403,1407} Numerous mutations are being considered for novel targeted therapeutics.^{1399,1408–1410} Several prospective studies are currently underway (e.g., NCT00707473, NCT02099175, and NCT02099188), but none have been published to date. Evidence surrounding surgical management of SNUC was discussed in ICSB 2019 and will not be addressed here.⁵

XXIV.B.I.A. Elective management of the neck

Regional metastases are found in approximately 15% of patients (range 5%–30%). Metastases are more common with advanced disease, particularly skull base invasion, and have been associated with poorer prognosis.^{497,1394–1396,1405,1411,1412} A dozen studies have evaluated the evidence for elective neck treatment for SNUC, but all have been retrospective cohort studies or case series. These were systematically reviewed in a meta-analysis by Faisal et al., which demonstrated an 80%

lower risk of regional recurrence for patients undergoing elective neck treatment (OR 0.20; 95% CI: 0.08–0.49; $p = 0.0004$).¹⁴¹² This has traditionally included lymph node levels I through III.

Several caveats exist to the recommendation for neck treatment. It is worth noting that 83% of patients in the aforementioned meta-analysis had T4 disease, and 96% had T3 or higher, so there was not an adequate sample to demonstrate the benefit of elective neck treatment for nonadvanced SNUC. The question of unilateral versus bilateral neck treatment has also not been answered. Ahn et al. demonstrated that the incidence of nodal metastases is greatest with nonethmoidal tumors, although the incidence of nodal metastases for nasal/ethmoid sinus tumors was also significant at 15%.²²⁹ Consideration of bilateral elective neck treatment may be most warranted for advanced midline tumors or nonethmoidal tumors with significant contralateral involvement. Although the authors of the systematic review recommend END over ENI for staging accuracy and sequela mitigation, it is unknown whether one treatment is superior.¹⁴¹² It is also not known if adjuvant neck radiation should be withheld if an END does not yield disease.¹⁴¹³ Proponents of ENI point to the advantage of the ability of RT to treat retropharyngeal nodes, a common drainage basin for the posterior nasal cavity and the ethmoid sinus. The retropharyngeal nodes are not easily accessible or salvageable after recurrence with surgery, and their inclusion in radiotherapy fields is without significant additional morbidity and well tolerated. Regardless of the outcome of END, the retropharyngeal nodal basin needs to be treated during postoperative RT to the primary tumor, particularly for locally advanced tumors and/or early-stage tumors involving posterior nasal cavity/ethmoid sinus.

a | Role of neoadjuvant/induction chemotherapy

Several studies support the use of IC for SNUC; however, this is not universal.^{497,1402,1403,1414,1415} In particular, neoadjuvant therapy response appears to best serve as a guide for determining subsequent treatment—namely, surgery with adjuvant RT versus definitive CRT.¹⁴⁰³ Amit et al. found that patients who had a partial or complete response to IC had a 5-year DSS rate of 81% when treated with definitive CRT, compared to 51% for those receiving surgery with adjuvant RT or CRT. In patients who did not respond to IC and were not treated with surgical resection, 5-year DSS was 0%. Still, DSS appears to be better for patients who received IC followed by surgery with adjuvant treatment than for other cohorts who underwent bi- and trimodality treatment without neoadjuvant therapy.^{1395,1402} One study found preoperative radiation to be associated with a 78% greater likelihood of negative margins, although this analysis included numerous types of malignancies.¹⁴¹⁶

Bimodality and trimodality treatments confer an oncological advantage over single-modality therapy (Table XXIV.B.1). Most, but not all, studies found that trimodality therapy was superior to bimodality. There are sufficient data to support the use of neoadjuvant chemotherapy response as a guide for treatment. Patients who respond to neoadjuvant chemotherapy followed by definitive chemoradiation appear to do particularly well. Elective treatment of the neck with either surgery and/or radiation is recommended for T3–4 disease. A radiation dose greater than 60 Gy is optimal.

Treatment of SNUC

Aggregate grade of evidence	B (Level 2: three studies; Level 3: six studies; Level 4: 24 studies)
Benefit	Bimodality, and more so trimodality, therapy is beneficial over single modality. Elective neck treatment is associated with lower regional recurrence rates, most commonly with levels I-III.
Harm	Single-modality treatment yields poorer OS and RFS. Greater regional recurrence rates occur in patients without elective neck treatment.
Cost	Not evaluated in current studies.
Benefits-harm assessment	Preponderance of benefits over harms.
Value judgments	While early studies suggested the greatest benefit was associated with surgery with adjuvant therapy, more recent studies have supported trimodality treatment or neoadjuvant chemotherapy followed by CRT in responders, especially in patients who cannot be resected with negative margins or without significant morbidity.
Policy level	Recommendation.
Intervention	Multimodal treatment with elective neck treatment for SNUC is recommended. Neoadjuvant chemotherapy response as a guide for treatment can be considered.

2 | NUT carcinoma

NUT carcinoma represents 1%–2% of SNM (Table XXIV.B.2).^{1417,1418} The disease is named for its characteristic translocation of the nuclear protein on the testis (NUTM1). The previous name, NUT midline carcinoma, was changed because the tumor is not restricted to midline structures. NUT carcinoma can also occur in the lungs, salivary gland, pancreas, genitourinary structures, bone, and soft tissues.¹⁴¹⁹ It predominantly affects teens and young adults, aged 10–30 years, although this be

partly due to the higher use of cytogenetic analysis in this age group. Patients typically present with nonspecific complaints of nasal obstruction, epistaxis, orbital symptoms, and pain.¹⁴¹⁸ The disease occurs in slightly more female than male patients.^{1418,1420} On imaging, the tumor appears as an aggressive, infiltrating mass, often with orbital and dural invasion. MRI shows hypointensity on T1 and heterogeneity on T2.¹¹⁹² Bony hyperostosis has been described.

Histological evaluation typically reveals nests of tumor cells in the submucosa without surface epithelial involvement. The hallmarks of NUT carcinoma are lack of pleomorphism, monotonous primitive round cells, and areas of abrupt keratinization.¹⁴¹⁹ These tumors harbor a characteristic translocation involving *NUTM1* on chromosome 15q14.6 with the bromodomain-containing protein 4 (*BRD4*) gene on 19p13.1.¹⁴²¹ *BRD4::NUTM1* gene rearrangement identified with FISH is considered the gold standard for diagnosis.¹⁴²² Alternatively, NUT nuclear immunohistochemical stain can be used and has a reported sensitivity and specificity, respectively, of 100% and 87%.¹⁴¹⁹ Patients with non-*BRD4::NUTM1* fusions (*BRD3-* or *NSD3-NUTM1*) have significantly better survival than those with *BRD4::NUTM1* fusions, independent of metastatic disease extent at presentation.¹⁴²³

NUT carcinomas are among the most aggressive tumors of the sinonasal tract. The NUT carcinoma registry (www.nmcregistry.org) is a central repository for cases and has contributed to studies that assisted with NUT carcinoma being considered a unique entity by the WHO.^{17,1068} This registry was used for the largest series, which included 29 cases.¹⁴²⁰ Half of the patients with this disease have locoregional or distant metastases at diagnosis.^{1420,1424} Due to the small number of reported cases, treatment data are limited. The single published cohort study reported a survival benefit in patients who underwent surgery with adjuvant CRT rather than definitive CRT.¹⁴²⁰ Notably, surgical resection with negative resection margins conferred a 2-year OS of 80%, superior than resection with positive margins or debulking. A sample of patients who underwent neoadjuvant chemotherapy appears to have better OS outcomes than previously reported cohorts, but comparative analysis was restricted by sample size.¹⁴²⁵ One recent case described a short-lived response with a regimen for Ewing sarcoma (i.e., vincristine, cyclophosphamide, and doxorubicin).¹⁴²⁶ However, platinum compounds are the most commonly used chemotherapeutic agents.¹⁴²⁰ BET bromodomain inhibitors, which target the *BRD4* portion of *BRD4::NUTM1*, demonstrated promise in a xenograft model, and clinical trials are currently ongoing (e.g., NCT03936465).^{1427,1428} Nevertheless, NUT carcinoma is almost uniformly fatal. The median survival is 5–13 months.^{1420,1424,1425}

TABLE XXIV. B.1 Evidence surrounding multimodal treatment of sinonasal undifferentiated carcinoma.

Study	Year	LOE	Study design	Study groups	Clinical endpoints	Conclusion
Faisal et al. ¹⁴¹²	2020	2	Systematic review and meta-analysis	255 patients from 12 studies: ENT (126), no ENT (129)	OS	80% lower risk of regional failure with ENT
Morand et al. ¹³⁹⁴	2017	2	Systematic review and meta-analysis	390 total from 29 studies: Treatment known: Sx + CRT (61), CRT (49), Sx + RT (37), RT (24), palliative (16), Sx (14)	OS	Bi- or trimodal treatment is superior to single modality
Reiersen et al. ¹⁴⁴¹	2012	2	Systematic review and meta-analysis	167 patients from 30 studies: C (6), RT (21), CRT (36), Sx (15), Sx + C (1), Sx + RT (46), Sx + CRT (34), no Tx (8)	OS	Trend for better OS with surgery with RT or CRT
Amit et al. ¹⁴⁰³	2019	3	Retrospective cohort	IC (all patients): CRT (60), CRT + Sx (31), Sx + RT (4)	OS	OS benefit for IC guide for CRT or surgery with RT/CRT
Kuo et al. ¹⁴⁰²	2017	3	Retrospective cohort	Sx (37), Sx + RT (32), Sx + CRT (157), Sx + C (14), RT (16), CRT (120), C (25), no Rx (34)	OS	OS benefit from CRT or surgery with CRT
van der Laan et al. ¹⁴⁰⁴	2016	3	Systematic review and meta-analysis	Sx (15), RT (43), C (7), Sx + RT (54), Sx + C (2), Sx + CRT (110), CRT (85), palliative (31)	DFS	Better DFS for surgery with RT than CRT
Fu et al. ¹⁴¹⁶	2016	3	Retrospective cohort	Induction RT + Sx (23), Sx + RT (61)	1. Margin control 2. OS 3. DFS 4. LRFS 5. RFS	Neoadjuvant RT associated with negative margins
Chamberlain et al. ¹⁴⁴²	2016	3	Retrospective cohort	CRT (16), Sx + CRT (11), Sx + RT (4)	OS	CNS involvement associated with poorer outcomes
Chambers et al. ¹⁴⁰⁵	2015	3	Retrospective cohort	Sx + RT (142), RT (111) Sx (33); C not defined	OS	Better OS with surgery and adjuvant RT
Lehrich et al. ¹⁴¹⁵	2020	4	Retrospective Database Study (NCDB)	No IC (370), (70), IC + Sx + RT (15), IC + Sx (3), IC + RT (52)	OS	IC not associated with improved OS
London et al. ¹⁴¹⁴	2020	4	Retrospective case series	CRT (8), IC + CRT (8), palliative (3), Sx + CRT (2)	OS	Nonstatistically analyzed trend supporting IC
Workman et al. ¹³⁹⁵	2019	4	Retrospective case series	Sx + CRT (22), CRT (4), Sx (1)	OS	Nodal disease at presentation associated with worse OS

(Continues)

TABLE XXIV.B.1 (Continued)

Study	Year	LOE	Study design	Study groups	Clinical endpoints	Conclusion
de Bonnecaze et al. ⁴⁹⁷	2018	4	Retrospective case series	CRT (29), Sx + CRT (14), Sx + RT (6), other (5)	1. OS 2. DFS	IC associated with improved DFS
Gamez et al. ⁴⁹⁹	2017	4	Retrospective case series	Sx + CRT (16), Sx + RT, IC + Sx + CRT (8), RT (4), CRT (3)	OS	Trimodal treatment with >60 Gy superior to bimodal
Khan et al. ³⁶⁷	2017	4	Retrospective Database (NCDB)	Sx + CRT (169), CRT (146)	OS	Better OS for surgery with surgery than CRT when resectable
Bhasker et al. ¹⁴⁴³	2017	4	Retrospective case series	Sx + RT (3), Sx + CRT (4), RT (6), CRT (4), PRT (4)	OS	Supports surgery with adjuvant treatment
Kuan et al. ¹⁴⁰⁷	2016	4	Retrospective Database Study (SEER)	Sx + RT (150), RT (108), Sx (32), none (22), unknown (16)	1. OS 2. DFS	Kadish stage, age, and radiation associated with OS, DFS
Ahn et al. ²²⁹	2016	3	Retrospective Database Study (SEER)	No neck dissection (104), neck dissection (7)	Metastasis	Nonnasal, non-ethmoid tumors associated with metastasis
Lopez et al. ¹³⁹⁷	2015	4	Retrospective case series	Sx + CRT (10), Sx + RT (1), C + Sx + CRT (3), CRT (3)	OS	Supports surgery with adjuvant RT
Gray et al. ¹⁴⁴⁴	2015	4	Retrospective case series	Sx + CXT (8) CRT (3)	OS	Improved OS with HPV-associated SNUC
Liao et al. ¹⁴⁴⁵	2014	4	Retrospective case series	Sx + CRT (7), CRT (7), RT (1)	OS	Trend toward OS benefit with CRT
Christopherson et al. ¹⁴⁴⁶	2014	4	Retrospective case series	Sx + CRT (10), Sx + RT (5), CRT (6), RT (2)	OS	Supports surgery with adjuvant CRT
Su et al. ¹⁴⁴⁷	2014	4	Retrospective case series	Sx + CRT (4), Sx + RT (4), RT (4)	OS	Endoscopic surgery comparable to open
Al-Mamgani et al. ¹⁴¹³	2013	4	Retrospective case series	CRT (7), C + Sx + RT (7), Sx + RT (5), Sx + CRT (2)	OS	Recommend three- or two-modality treatment
Yoshida et al. ¹⁴⁴⁸	2013	4	Retrospective case series	CRT (6), Sx (6), Sx + CRT (4)	OS	Trend supporting surgery with CRT
Millard et al. ¹⁴⁴⁹	2013	4	Retrospective case series	Sx + CRT (6), Sx with RT (5), CRT (1), Sx (1), IC + Sx + RT (1)	OS	Support primary CRT followed by surgery, ENT
Xu et al. ¹⁴⁵⁰	2013	4	Retrospective case series	No Rx (2, 5), single modality (7, 42), CRT (4, 37), Sx + RT (3, 22), Sx + CRT (4, 34)	OS	Multimodal treatment associated with better OS
Mourad et al. ¹⁴⁵¹	2013	4	Retrospective case series	Sx (3), Sx + CRT (5), CRT + Sx (7), CRT (3)	1. OS 2. DFS	Trimodal therapy associated with better DFS
Lee et al. ¹⁴⁵²	2012	4	Retrospective case series	CRT (4), Sx + CRT (4), Sx + RT (3), RT (3)	OS	Supports surgical resection with CRT

(Continues)

TABLE XXIV.B.1 (Continued)

Study	Year	LOE	Study design	Study groups	Clinical endpoints	Conclusion
Revenaugh et al. ¹⁴⁵³	2011	4	Retrospective case series	Sx + CRT(4), CRT (4), IC + Sx + CRT (4), Sx + RT(1), RT (1)	OS	Comparable outcomes with endoscopic versus open resection
Lin et al. ¹⁴⁵⁴	2010	4	Retrospective case series	Sx + CRT (6), Sx + RT (5), CRT (5), RT (5)	OS	Trend toward better OS with chemoradiation
Tanzler et al. ¹⁴¹¹	2008	4	Retrospective case series	Sx + RT (9), RT (5), Sx (1)	OS	Supports surgery with RT
Chen et al. ¹⁴⁰⁶	2008	4	Retrospective case series	Sx + RT or CRT (17), IC + Sx (2), CRT (2)	OS	Importance of gross total resection in outcomes

Abbreviations: CRT, chemoradiation therapy; DFS, disease-free survival; LRFS, locoregional failure/recurrence-free survival; OS, overall survival; RFS, recurrence-free survival; RT, radiation therapy; Sx, surgical therapy.

TABLE XXIV.B.2 Evidence surrounding management of sinonasal NUT carcinoma.

Study	Year	LOE	Study design	Study groups	Clinical endpoints	Conclusion
Chau et al. ¹⁴²⁰	2016	3	Retrospective cohort	Sx + RT or CRT (22), C ± Sx or RT (11), CRT (6)	OS	OS 9.7 months, DFS 6.6 months, trimodal treatment outcomes better
Hafstrom et al. ¹⁴¹⁷	2020	4	Retrospective case series	Sx + RT (1), CRT (1), Sx + CRT (1), Sx + C (1)	Prevalence	NUT make up 1.1% of poorly differentiated sinonasal carcinomas
Kumar et al. ⁵⁵	2018	4	Retrospective case series	C (5), CRT (7), RT (3), Sx (3)	OS	Median OS of 5.5 months
Kakkar et al. ¹⁴³²	2018	4	Retrospective case series	Head and Neck NUT midline carcinoma (5)	Clinicopathologic characteristics	NUT IHC recommended for all poorly differentiated carcinomas
Minato et al. ¹⁴⁵⁵	2018	4	Retrospective case series	CRT (4)	Clinicopathologic characteristics	NUT tends to involve frontal and ethmoidal sinuses
Fang et al. ¹⁴²²	2013	4	Retrospective case series	RT (2), CRT (1), None (1)	Clinicopathologic characteristics	NUT gene rearrangements are the gold standard for diagnosis
Bishop and Westra ¹⁴¹⁸	2012	4	Retrospective case series	Sx + CRT (3)	Clinicopathologic characteristics	NUT make up 2% of all sinonasal carcinomas

Abbreviations: C, chemotherapy; CRT, chemoradiation therapy; IHC, immunohistochemistry; OS, overall survival; RT, radiation therapy; Sx, surgical therapy.

Aggregate grade of evidence: D (Level 3: one study; Level 4: six studies)

3 | SWI/SNF complex-deficient sinonasal carcinomas

SMARCB1 (*INI1*)- and *SMARCA4* (*BRG1*)-deficient sinonasal carcinomas both are the result of inactivation of the SWItch/Sucrose Non-Fermentable (*SWI/SNF*) subfamily of ATP-dependent chromatin remodeling complexes (Table XXIV.B.3).¹⁴²⁹ *SMARCB1*-deficient sinonasal adenocarcinoma are exceptionally rare and are not specifically addressed herein.¹⁴³⁰ The names are derived from tumor-suppressor genes on chromosome 22q11.2,

which are a core subunit in the *SWI/SNF* complex, which includes *SMARCB1*, *SMARCA2*, and *SMARCA4*. The largest series to date is 39 cases.¹⁴³¹ These tumors affect slightly more male than female patients.¹⁴³² The mean age for patients with *SMARCB1*- and *SMARCA4*-deficient carcinomas is 54 years (range 28–78) and 44 years (range 20–67), respectively.^{1431,1433} Patients with these tumors frequently present with facial pain, eye symptoms, and nasal obstruction.¹⁴³⁴

Histologic evaluation of these tumors reveals a growth pattern of rounded nests of cells with areas that have a cord- or sheet-like pattern. There is a mixed pattern of cells with a predominance of basaloid morphology; however, some cells have a rhabdoid appearance.^{1431,1435,1436} *SMARCB1*-deficient carcinoma can be low to high grade,

TABLE XXIV.B.3 Evidence surrounding *SMARCB1* (*INI1*)- and *SMARCA4* (*BRG1*)-deficient sinonasal carcinomas.

Study	Year	LOE	Study design	Study groups	Clinical endpoints	Conclusion
Ayyanar et al. ¹⁴³⁶	2021	4	Retrospective case series	<i>SMARCB1</i> : Sx + CRT (3)	Clinicopathologic characteristics	Mixed pattern of cells with a predominance of basaloid morphology
McLean-Holden et al. ¹⁴²⁹	2021	4	Retrospective case series	<i>SMARCB1</i> (6), <i>SMARCA4</i> (2): Treatment not reported	Clinicopathologic characteristics	1. <i>SMARCB1</i> lower grade than <i>SMARCA4</i> 2. Cytomorphology not an accurate predictor
Mittal et al. ¹⁴³⁴	2021	4	Retrospective case series	<i>SMARCB1</i> (17): Treatment not reported	OS	12% alive without disease at 1 year
Agaimy et al. ¹⁴³³	2020	4	Retrospective case series	<i>SMARCA4</i> : C (3), Sx + RT (1), Sx (1), palliative (1), unknown (4)	Disease related mortality	66% disease related mortality (median of 3 months)
Chitguppi et al. ¹⁴⁵⁶	2020	4	Retrospective case series	<i>SMARCB1</i> : Sx + CRT (2), IC + CRT (4)	1. OS 2. DFS	<i>SMARCB1</i> significantly worse DFS and OS than SNUC
Allard et al. ¹⁴⁵⁷	2018	4	Retrospective case series	<i>SMARCB1</i> (4): Treatment not reported	Clinicopathologic characteristics	Suspected for high-grade carcinomas with nonkeratinizing squamous or rhabdoid morphology
Agaimy et al. ¹⁴³¹	2017	4	Retrospective case series	<i>SMARCB1</i> : Sx + CRT (22), Sx (4), CRT (5), palliative (5), unknown (6)	OS	1. Median age of 52 years 2. 30% survival at a median follow-up of 2 years
Laco et al. ¹⁴⁵⁸	2017	4	Retrospective case series	<i>SMARCB1</i> : Sx + RT (3), Sx + CRT (1)	Clinicopathologic characteristics	Higher methylation of <i>RASSF1</i> gene
Shatzkes et al. ¹⁴³⁷	2016	4	Retrospective case series	<i>SMARCB1</i> (17): Treatment not reported	Radiographic features	Avid contrast enhancement, intermediate-low T2 signal, FDG avid, calcifications, periosteal reaction
Agaimy et al. ¹⁴³¹	2015	4	Retrospective case series	<i>SMARCB1</i> : Sx + RT or CRT (11)	Clinicopathologic characteristics	1. Undifferentiated basaloid “blue” appearance 2. Strong expression of pancytokeratin
Bell ¹⁴⁵⁹	2015	4	Retrospective case series	<i>SMARCB1</i> : Sx + CRT (3), IC + Sx + CRT (1)	Clinicopathologic characteristics	Basaloid/rhabdoid morphology, restricted to the sinonasal tract
Bishop et al. ¹⁴⁴⁰	2014	4	Retrospective case series	<i>SMARCB1</i> : Sx + RT (5), Sx + CRT (3), Sx (1)	Clinicopathologic characteristics	First identification and description of pathogenesis

Abbreviations: CRT, chemoradiation therapy; DFS, disease-free survival; IC, induction chemotherapy; OS, overall survival; RT, radiation therapy; Sx, surgical therapy.

while *SMARCA4*-deficient carcinoma tends to be higher grade.¹⁴²⁹ Both tumors are positive for pancytokeratin and AE1/AE3, while *SMARCB1* and *SMARCA4* are diffusely negative for INI1 and BRG1, respectively.¹⁴³⁵ These tumors typically originate in the ethmoid sinus with local invasion into the orbit or anterior cranial fossa.¹⁴³⁷ Both tumors can occur outside the sinonasal tract, including the soft tissues of the neck.¹⁴³⁸ There is moderate diffusion restriction on MRI with low to intermediate signal on T2.^{1192,1437} These tumors have calcifications in half of cases and occasionally

have aggressive periosteal reactions, visualized as a “hair on end” appearance.

Outcomes for patients with *SMARCB1*- and *SMARCA4*-deficient carcinoma are worse than those for SNUC patients.¹⁴³⁹ *SMARCB1*- and *SMARCA4*-deficient carcinomas are clinically aggressive, and patients usually present with local invasion.¹⁴³⁵ The vast majority of patients present with advanced disease, and half present with locoregional or distant metastasis.^{1431,1434,1440} While reports of long-term outcomes are scarce, studies show a

median OS of 12 months and 12%–30% survival at 1–2 years for patients with *SMARCB1*-deficient carcinoma.^{1431,1439} The only reported outcome for *SMARCA4*-deficient sinonasal carcinoma is 66% disease-related mortality (median 3 months).¹⁴³³

Treatment typically includes a combination of surgery and adjuvant RT with or without chemotherapy, although this recommendation is extrapolated from studies of SNUC. It is unknown whether *SMARCB1*-deficient carcinoma responds to IC similarly to SNUCs, but *SMARCB1*-deficient carcinoma was not explicitly excluded from the aforementioned study of IC in SNUC.^{1403,1431,1440} The *SWI/SNF* complex and suppression of cyclin D1 transcription may be future therapeutic targets.^{1432,1438}

C | Neuroendocrine carcinoma

According to the 5th edition of the WHO classification of head and neck tumors, large-cell neuroendocrine carcinomas (LcNEC) and small-cell neuroendocrine carcinomas (ScNEC, sometimes SmCC) are poorly differentiated, high-grade representatives of sinonasal tumors with neuroendocrine differentiation (STND) that are of epithelial origin (sinonasal neuroendocrine carcinomas, or SNEC).^{17,1459} As sinonasal ScNEC and LcNEC are rare tumors that have been only recently clearly classified, the existing literature that specifically addresses these entities (and that does not combine different sinonasal tumors into one group) is clearly limited. This section serves as an update to the complementary ICSB 2019 document (Section VIII.C).⁵

1 | Clinical presentation, epidemiology, and specific risk factors

Similar to other SNM, ScNEC and LcNEC usually present with nonspecific symptoms such as nasal obstruction, epistaxis, rhinorrhea, exophthalmos, and headache.^{1460–1462} As ectopic hormone production (e.g., ACTH, beta-MSH, calcitonin, serotonin, or ADH) may be present in only 1% of cases, corresponding symptoms are not a reliable indicator of disease.¹⁴⁰⁴ In an extensive retrospective study by Patel et al., the incidence of SNECs (with a large proportion of LcNEC and ScNEC) is reported to be as low as 0.015 cases per 100,000 and shows a marked (yet nonspecific) increase in incidence over time.⁴⁸ In a smaller case series, however, Sjöstedt et al. described a 10% increase in diagnosis of SNEC over a 34-year period.⁵² This finding most likely supports improved methods in diagnosis with various ancillary techniques. The mean age of the affected patients is between 49.2 and 62.5 years.^{1349,1404,1417,1460,1461,1463} There seems to be a slight to marked predominance of the male

sex in most studies.^{48,1349,1417,1460–1463} Previous irradiation (e.g., for NPC) has been suggested as an important risk factor.¹⁴⁶⁴ Alos et al. described positivity for p16 in 14 of 19 SNEC cases. However, HPV DNA could not be detected, so a larger scale HPV association seems unlikely.¹⁴⁶⁵

2 | Molecular profiling, histologic subtypes, and impact of grade

By definition, sinonasal ScNEC and LcNEC are poorly differentiated, high-grade malignancies, with its specific histological features being identical to their more common pulmonary counterparts. The tumors typically show nests of uniform round cells that infiltrate surrounding tissue, with an immunohistochemical positivity for cytokeratin (e.g., CKAE1/AE3, CK8) and neuroendocrine cell markers such as synaptophysin or chromogranin, while S100 and TTF-1 are negative.^{1171,1349} PNI and lymphovascular invasion are infrequently observed. The differentiation between LcNEC and ScNEC is mostly performed based on the variation in mean cellular sizes, but in ScNEC, the nucleoli are typically absent or inconspicuous, whereas in LcNEC, they are more irregular and prominent.¹¹⁷¹ LcNEC can be differentiated from SNUC as the latter shows a neuroendocrine differentiation only on an immunohistochemical or ultrastructural level, whereas the former also features morphologic (i.e., light microscopy) characteristics of neuroendocrine differentiation.^{1171,1459} A recent study on molecular profiling of poorly differentiated neuroendocrine carcinoma of the head and neck region (including five sinonasal ScNECs and seven sinonasal LcNECs) has revealed—for the sinonasal cases—a high Ki-67 index of >60% in all cases, universal loss of Rb, an overexpression of p53 in 90% of cases, and an infrequent occurrence of various potentially targetable mutations.¹⁴⁶⁶ Yet, none of the sinonasal cases in the mentioned study showed a mutational burden high enough for indicating immunotherapy (>10 mutations/mutational burden), so a strong role for immunotherapy seems unlikely. Ultimately, utmost care in the determination of the right histopathological diagnosis seems warranted as treatment recommendations and prognosis depend accordingly.¹⁴⁶⁷

3 | Workup and staging

The staging classification of the AJCC 8th edition has most commonly been used. There seem to be no specific imaging features with regard to LcNEC or ScNEC (such as intratumoral calcifications that can be found in olfactory neuroblastoma), so a combination of CT and MRI is advisable for local tumor assessment.^{1461,1462} Felix-

Ravelo et al. described a lower 18F-FDG-PET uptake in SNEC compared to other sinonasal carcinomas, which might hinder the assessment of tumor sizes using this type of diagnostic measure.²⁰⁰ With regard to localization, both ScNEC and LcNEC are most often primarily localized in the nasal cavity and in the ethmoid sinus, but infiltration into the skull base, the cranial fossa, or the orbit is common.^{48,1417,1460–1462} The available studies show that SNECs are typically first diagnosed at an advanced stage (70%–80% as IV), whereas initial regional and distant metastases are rare.^{48,200,1417,1460,1461,1463,1464,1468–1471}

4 | Treatment strategies

The treatment strategies for sinonasal ScNEC and LcNEC vary immensely between the available studies (Table XXIV.C.1) and are often not given in much detail. Furthermore, the information from the available literature does not help to provide detailed recommendations for each distinct entity, but rather for different histopathologies grouped together (e.g., STND or SNEC). In the curative setting, however, a multimodality approach has been commonly applied and seems to be advantageous over single-modality treatment. According to a meta-analysis by van der Laan et al., surgery with adjuvant RT is the therapy of choice with regard to improved DSS for SNEC.¹⁴⁰⁴ In their evaluation, there seemed to be no benefit for the additional use of adjuvant chemotherapy. These results, however, cannot be easily extrapolated to sinonasal ScNEC and LcNEC, as these distinct entities were not defined according to the current WHO classification in this study. In another retrospective analysis on SNEC derived from the SEER database, Patel et al. equally concluded that surgery with or without adjuvant RT showed a significantly better outcome regarding DSS than RT alone.⁴⁸ For poorly differentiated neuroendocrine carcinomas, including ScNEC and LcNEC, these conclusions are confirmed in a retrospective single-center analysis by Likhacheva et al.¹⁴⁶⁸

The role of neoadjuvant chemotherapy has recently been investigated in smaller trials and seems to provide favorable results. Following standard treatment regimens for extrapulmonary neuroendocrine carcinomas, two cycles of a combination of cisplatin and etoposide are typically used.¹⁴⁷² In an initial, small prospective trial from 2002 that included 10 sinonasal NECs, the use of neoadjuvant chemotherapy showed promising long-term outcomes.⁵⁴⁰ Another single-center study investigated the role of neoadjuvant chemotherapy in locally advanced and borderline resectable SNEC and ONB. For SNEC, a response rate of 92.3% was shown, but the intensity of response showed no significant correlation to median PFS,

and the rate of grade III–IV toxicity was close to 75% in the whole group investigated.¹⁴⁷³ In a multicenter retrospective analysis from Italy, Turri-Zanoni et al. reported on the value of adding neoadjuvant chemotherapy to multimodal treatment for 98 tumors with neuroendocrine differentiation, of which 22 were SNECs (12 ScNEC and 10 LcNEC). In this group, neoadjuvant chemotherapy, which was administered in 10 out of 22 cases, was associated with improved OS and DFS on multivariate analysis.¹³⁴⁹

In conclusion, a multimodal approach, most likely including neoadjuvant chemotherapy, seems warranted for the treatment of sinonasal ScNEC and LcNEC with curative intent, though high-level evidence is missing. At this time, several prospective trials (e.g., NCT02099175, NCT02099188, NCT00707473) are aiming to shed more light on this topic.

Treatment strategies for SNEC

Aggregate grade C (Level 2: one study; Level 3: two studies; of evidence Level 4: five studies)	
Benefit	In aggregate, surgery and RT confer survival benefit for both ScNEC and LcNEC.
Harm	Morbidity of treatment should be factored into the clinical decision-making process.
Cost	No cost studies have been performed.
Benefits–harm assessment	Preponderance of benefits over harms.
Value judgments	There may be an emerging role for neoadjuvant chemotherapy in management of SNEC, likely in higher grade tumors.
Policy level	Recommendation.
Intervention	Surgery and RT remain the mainstay for primary management of SNEC. Induction chemotherapy may be considered for patients with locally advanced disease, metastases, and/or high-grade tumors.

5 | Recurrence and survival

Recurrences for SNEC are very common and occur both locoregionally as well as systemically. The incidence of recurrence varies widely in the available literature but seems to be higher (up to 73%) than other malignant sinonasal tumors.^{1349,1460,1461,1464,1468} Treatment strategies for recurrent tumors have not been addressed in detail in the available literature, so current recommendations correspond to those for other sinonasal tumors.

Concerning survival, common grouping of different histopathological entities again makes it difficult to draw coherent conclusions from the available studies. The literature suggests that the OS for SNEC varies between 42.6%

TABLE XXIV.C.1 Evidence surrounding treatment of sinonasal neuroendocrine carcinoma.

Study	Year	LOE	Study design	Study groups	Clinical endpoints	Conclusion
Van der Laan et al. ¹⁴⁰⁴	2016	2	Systematic review and meta-analysis	701 SNEC patients including 115 ScNEC and 459 SNUC/LcNEC	DSS	<ol style="list-style-type: none"> 1. Surgery ± RT resulted in better DSS for all treatment groups than RT/CRT 2. No added benefit from adjuvant chemotherapy 3. Outcome improved over time, possibly due to improved surgical techniques 4. Study limited by mixed pathologies
Turri-Zanoni et al. ¹³⁴⁹	2017	3	Retrospective cohort	98 STND including 12 ScNEC and 10 LcNEC	<ol style="list-style-type: none"> 1. OS 2. DFS 	The incorporation of neoadjuvant chemotherapy resulted in better OS and DFS on both uni- and multivariate analysis
Keilin et al. ¹⁴⁷⁴	2022	4	Retrospective case series	13 SNEC patients	OS	<ol style="list-style-type: none"> 1. 5-year OS 74.6% 2. Primary surgery for low-grade SNEC and primary CRT for high-grade SNEC 3. Five of seven who completed CRT required salvage surgery
Patil et al. ¹⁴⁷³	2016	4	Retrospective case series	25 STND including 13 SNEC	Response rate to neoadjuvant chemotherapy	<ol style="list-style-type: none"> 1. Response rate to neoadjuvant chemotherapy: 92.3% 2. No measurable correlation between response and PFS 3. 76% grade III–IV toxicities 4. Study limited by mixed pathologies
Patel et al. ⁴⁸	2015	4	Database study	201 SNEC including 52 ScNEC/LcNEC	DSS	Surgery ± RT resulted in better DSS than RT
Likhacheva et al. ¹⁴⁶⁸	2011	4	Retrospective case series	20 SNEC including 13 ScNEC/LcNEC	DFS	Surgery ± RT resulted in better DFS than CRT
Mitchell et al. ¹⁴⁶⁰	2011	4	Retrospective case series	28 SNEC	DSS	No significant differences in DSS between Surgery, Surgery + RT, and CRT
Fitzek et al. ⁵⁴⁰	2002	4	Retrospective review of prospectively enrolled case series	19 STND including 10 SNEC	<ol style="list-style-type: none"> 1. OS 2. LRC 	<ol style="list-style-type: none"> 1. Neoadjuvant chemotherapy followed by RT resulted in good outcome (OS 74%, LRC 88%) 2. Study limited by mixed pathologies and no control group

Abbreviations: CT, chemotherapy; DFS, disease-free survival; DSS, disease-specific survival; LcNEC, large-cell neuroendocrine carcinoma; LCR, local control rate; LRC, locoregional control; OS, overall survival; RT, radiation therapy; S, surgery; ScNEC, small-cell neuroendocrine carcinoma; SNEC, sinonasal neuroendocrine carcinoma; SNUC, sinonasal undifferentiated carcinoma; STND, sinonasal tumors with neuroendocrine differentiation.

and 66.9%.^{48,1349,1464,1468} A distinction between ScNEC and LcNEC survival is only performed in a single case series.¹³⁴⁹ In this study, patients with LcNECs tended to fare better (5-year OS 52.5%) than those with an ScNEC (5-year OS 33.3%), but the difference did not prove to be significant. Unsurprisingly, Mitchell et al. and Patel et al. showed that survival for advanced-stage disease was significantly worse compared to early-stage disease.^{1404,1460} Both studies also described a significantly better DSS for nasal

cavity primary site rather than in the ethmoid or maxillary sinus, which might be attributable to the fact that nasal cavity tumors become symptomatic at an earlier stage.

D | Sinonasal mucosal melanoma

SNMM is an infrequently occurring sinonasal tumor, accounting for approximately 5% of sinonasal neoplasms

and less than 1% of melanomas. Of mucosal melanomas arising in the head and neck region, 60%–70% arise in the nasal cavity and paranasal sinuses.^{12,391,1475–1477} When arising in the sinonasal cavity, the anatomic site of origin is most commonly the nasal cavity (70%), following by the maxillary sinus (13%) and ethmoid sinus (6%).³⁶⁶ SNMM is considered and managed as a distinct entity from cutaneous melanoma; its incidence has been increasing since 1960.¹⁴⁷⁸ It is noncutaneous and arises from melanocytes within the sinonasal mucosa. Moreover, SNMM has a distinct pattern of tumorigenesis, genetic mutational landscape, and molecular profile compared to cutaneous melanoma, with essentially no UV light mutational signature within its genetic mutational landscape.^{366,1479–1481}

1 | Survival and prognostic factors

SNMM is a uniquely aggressive neoplasm with poor survival. The reported 5-year OS for all patients is 22%–28%.^{1477,1482,1483} With localized disease only (N0), the reported 5-year OS is 25%. However, when regional lymph node metastases are present (N+) at the time of diagnosis, the 5-year OS is reduced to 3.9% or less.^{1482,1483} In contrast, the 5-year OS for cutaneous melanoma with localized disease is >95%.¹⁴⁸⁴ Recurrence after treatment is common with local recurrence in 18%–46%, regional recurrence in 11%–18%, and distant metastases in 35% of patients.^{269,1485,1486}

This poor survival is reflected in the AJCC's unique staging system for SNMM.^{391,1484,1487} In this system, SNMM T-stage is limited to T3 and T4 disease, effectively indicating that each presenting tumor is a minimum of Stage III. However, as compared to most head and neck malignancies in which clinical staging is highly correlated with survival, SNMM staging has been shown to poorly correlate with prognosis.^{1487,1488} It should be noted that current AJCC staging for SNMM does not include any histopathologic or proliferative factors, in contrast to staging of cutaneous melanoma.

Several prognostic factors have been shown to be associated with SNMM survival. Evaluations of pooled data from the SEER and NCDB have shown that primary SNMM of the nasal cavity has improved survival compared to the paranasal sinuses. In addition, older age, positive nodal status, distant metastases, and increased tumor volume have also been associated with worsened OS.^{391,1483,1489–1491}

2 | Histopathologic findings

The histopathologic hallmark of SNMM is intraepithelial melanocytic proliferation and atypia. Select tumors

may demonstrate spindled, epithelioid, or small cell morphology.^{391,1492,1493} Satellite or skip mucosal lesions are also common in 26% of patients and have been shown to be associated with worsened rates of local control.¹⁴⁹⁴ Classic histopathologic markers of SNMM include S100, SOX10, and HMB45.^{1493,1495} The presence of brisk TILs has been associated with improved RFS. Additionally, patients with amelanotic lesions are more likely to present with higher stage tumors and less likely to have brisk TILs and worsened RFS.^{1481,1496} Higher Ki67 and mitotic rate indices have also been associated with worsened 5-year OS and RFS.^{1481,1496–1498} Patients on immunotherapy with a Ki67 of <40% have been shown to have improved 3-year OS compared to those with higher Ki67.¹⁴⁸¹

3 | Surgical resection

Following the treatment paradigm of cutaneous melanoma as well as the majority of SNM, surgical resection remains the primary treatment modality for SNMM tumors that are resectable (Table XXIV.D.1).^{269,278,366,1483,1499–1501} Complete tumor resection with negative margins is the goal of surgical intervention, including resection of all skip lesions when present.^{1499,1501}

In several institutional series and large database studies, surgical resection with negative margins has been associated with improved OS and RFS¹⁵⁰² compared to surgery with positive margins or no surgery at all.^{360,365,366,1503,1504} In an NCDB study of 1874 SNMM patients, surgical resection with negative margins was associated with improved OS; however, resection with positive margins was not independently associated with worse OS.¹⁵⁰² Another population-based analysis of 446 SNMM patients found that a negative-margin surgical resection was associated with improved OS compared to a positive-margin surgical resection; there was no difference in OS for patients who underwent a positive-margin surgical resection and no surgery at all.³⁶⁵ Another study of 1373 patients with head and neck mucosal melanoma (79% of which were sinonasal) found that undergoing surgery (HR 0.45; $p < 0.001$) and obtaining negative margins (HR 0.52; $p < 0.001$) were both associated with improved survival, even after controlling for tumor size, stage, and comorbidities.¹⁵⁰³ Although the majority of literature supports a negative margin surgical resection to improve OS, one institutional study of 72 patients undergoing surgery for SNMM found that no particular surgical factor was associated with OS including margin status, tumor stage, or surgical approach utilized.²⁷¹

The selection of surgical technique is largely based upon surgeon expertise, tumor extent, and ability to achieve negative margins.^{1499,1501,1505–1507} Traditionally,

TABLE XXIV.D.1 Evidence surrounding surgical resection of sinonasal mucosal melanoma.

Study	Year	LOE	Study design	Study groups	Clinical endpoints	Conclusion
Hur et al. ²⁷⁹	2019	2	Systematic review and meta-analysis	SNMM patients who underwent endoscopic, open, or combined resection (<i>n</i> = 510)	1. OS 2. DFS	1. OS improved in endoscopic compared to open resection 2. No difference in DFS between endoscopic and open resection
Guo et al. ¹⁴⁸¹	2022	4	Retrospective case series	SNMM patients at single institution with tissue available for analysis (<i>n</i> = 45)	1. OS 2. RFS	1. Higher Ki67 and mitotic rates were associated with worsened OS and RMFS 2. Brisk tumor-infiltrating lymphocytes (TILs) were associated with improved RMFS 3. Patients on immunotherapy with Ki67 <40% had better 3-year OS than those with higher Ki67 index
Elsamna et al. ³⁶⁵	2021	4	Retrospective database study (NCDB)	SNMM patients in NCDB 2010–2015 (<i>n</i> = 446)	1. OS 2. Margin status effect on OS	1. 2-year OS 72% for negative margins, 36% for positive margins, 16% for no surgery 2. OS following surgery with positive margins was not statistically better than no surgery at all
Ganti et al. ³⁶⁶	2020	4	Retrospective database study (NCDB)	SNMM patients in NCDB 2004–2015 (<i>n</i> = 1874)	OS	1. OS 24% 2. Increased age and distant metastasis associated with decreased survival 3. T4 disease associated with worse survival 4. Negative surgical margins associated with improved survival 5. Immunotherapy associated with improved survival in metastatic disease
Low et al. ¹⁴⁸³	2020	4	Retrospective database study (SEER)	SNMM patients in SEER database 1973–2015 (<i>n</i> = 328)	1. OS 2. DSS	1. Regional nodal and distant metastasis associated with decreased survival 2. Maxillary and frontal sinus primary tumor associated with decreased survival 3. Increased age associated with poor survival
Farber et al. ²⁷⁸	2019	4	Retrospective database study (NCDB)	SNMM patients in NCDB 2010–2015 (<i>n</i> = 686)	1. OS 2. 30-day mortality 3. 90-day mortality 4. Readmission, LOS	1. No difference in OS between endoscopic and open surgery 2. No difference in 30- and 90-day mortality between endoscopic and open surgery 3. Endoscopic surgery has more unplanned readmissions 4. Open surgery with longer LOS

(Continues)

TABLE XXIV.D.1 (Continued)

Study	Year	LOE	Study design	Study groups	Clinical endpoints	Conclusion
Amit et al. ¹⁵⁶⁸	2018	4	Retrospective case series	SNMM patients at a single institution (<i>n</i> = 198)	1. OS 2. DSS 3. DFS	1. 5-year OS 38% 2. 5-year DSS 58% 3. 5-year DFS 27% 4. 5-year OS better for nasal cavity primary (43%) versus paranasal sinus (20%) 5. Distant metastasis most common cause of treatment failure 6. Presentation with distant metastasis associated with poor survival
Lundberg et al. ²⁷⁴	2018	4	Retrospective case series	SNMM patients at a single institution (<i>n</i> = 58)	OS	1. 5-year OS survival 28% 2. No difference in OS between endoscopic and open resection
Cao et al. ²⁶⁷	2017	4	Retrospective case series	SNMM patients at a single institution (<i>n</i> = 34)	OS	1. No difference in OS between endoscopic and open resection 2. No difference in DFS between endoscopic and open resection
Dreno et al. ¹⁵⁸³	2017	4	Retrospective case series	SNMM patients at a single institution (<i>n</i> = 44)	OS	Nasal cavity primary tumor with improved survival over paranasal sinus primary
Miglani et al. ²⁷²	2017	4	Retrospective case series	SNMM patients at a single institution (<i>n</i> = 22)	1. OS 2. DFS	1. No difference in 5-year OS and DFS between endoscopic resection and open 2. Local control improved in endoscopic resection
Konuthula et al. ¹³⁸⁴	2016	4	Retrospective database study (NCDB)	SNMM patients in NCDB 2004–2010 (<i>n</i> = 695)	OS	5-year OS 22%, mean survival 38.4 ± 1.7 months
Lombardi et al. ¹⁵⁰⁴	2016	4	Retrospective case series	SNMM patients at a single institution (<i>n</i> = 58)	OS	1. 3-year OS 44% 2. 5-year OS 29% 3. Increased risk of death with positive margins and male sex 4. No difference in OS between endoscopic and open approaches
Won et al. ²⁶⁹	2015	4	Retrospective case series	SNMM patients from 15 hospitals in South Korea (<i>n</i> = 155)	1. OS 2. Recurrence rate 3. Rate of satellite/skip lesions	1. 3-year OS 49% 2. 5-year OS 40% 3. Increased survival and decreased local recurrence in those undergoing endoscopic resection versus open 4. RT decreased local recurrence, no impact on survival 5. 26% had skip or satellite lesions

(Continues)

open approaches including craniofacial resections and lateral rhinotomies were the preferred surgical technique. However, the development of endoscopic techniques has introduced an alternative surgical option. Many SNMM

tumors are amenable to purely endoscopic techniques with the ability to achieve a negative margin resection.^{1085,1508} Yet, open or combined open/endoscopic approaches may be preferred if there is tumor invasion into the soft tissue of

TABLE XXIV.D.1 (Continued)

Study	Year	LOE	Study design	Study groups	Clinical endpoints	Conclusion
Tajudeen et al. ¹⁵⁰²	2014	4	Retrospective case series	SNMM patients at a single institution (n = 14)	1. OS 2. RFS 3. Frozen section and final pathology correlation	1. 5-year RFS 23%, OS 35% 2. Positive margins and perineural/lymphovascular invasion associated negatively affected RFS and OS 3. Nine patients with frozen path-30 specimens negative on frozen pathology, confirmed to be negative on final pathology
Lund et al. ¹⁴⁸²	2012	4	Retrospective case series	SNMM patients at a single institution (n = 115)	1. OS 2. DFS	1. 5-year OS survival 28% and DFS 23.7% 2. 5-year DFS was higher with endoscopic than open but no difference in longer term
Dauer et al. ¹⁴⁹⁴	2008	4	Retrospective case series	SNMM patients at a single institution (n = 61)	1. DSS 2. Local recurrence	1. 49% 3-year DSS, 22% 5-year DSS 2. Local recurrence increased in patients with skip lesions

Abbreviations: DFS, disease-free survival; DSS, disease-specific survival; NCDB, National Cancer DataBase; OS, overall survival; RFS, recurrence-free survival; SEER, Surveillance, Epidemiology, and End Results; SNMM, sinonasal mucosal melanoma.

the cheek/nose, palate involvement, extensive intracranial involvement, dural involvement laterally over the orbit, or when orbital exenteration is necessary.¹⁴⁹⁹ As noted above, the ability to achieve a negative margin resection is the most key when selecting a surgical approach for a given tumor. Secondary important considerations include associated postoperative morbidity and QOL.^{1509–1513}

A growing body of literature has demonstrated comparable survival rates between open and endoscopic approaches for SNM.^{1085,1508} For SNMM in particular, Lombardi et al. studied 58 patients who underwent surgical resection of SNMM. After correcting for tumor stage, they found no difference in OS or DSS between the endoscopic and open resection groups.¹⁵⁰⁴ Similarly, Miglani et al. reported their institutional experience with 22 patients undergoing surgical resection of SNMM. In this cohort, there was no difference in OS or DSS for endoscopically resected tumor group compared to open resection group. The presenting tumor stage was similar between both groups. However, the endoscopic group had improved local control compared to the open resection group.²⁷² In a series of patients treated at MD Anderson, SNMM patients undergoing endoscopic-assisted resection had improved 2-year survival compared to open approaches, although this study was not controlled for tumor stage.²³² Large-institutional SNMM cohorts by Lund et al. (115 patients) and Lundberg et al. (58 patients) demonstrated comparable OS for endoscopically resected SNMM compared to open approaches.^{274,1482} The UK national guidelines on head and neck mucosal melanomas advocate for an endoscopic endonasal surgery whenever feasible.¹⁵¹⁴

However, given the aggressiveness of SNMM, some patients present with locally advanced disease in which a negative margin resection is not possible. In these cases, a variety of approaches have been utilized. IC regimens have been described in cases of unresectable SNMM to allow for tumor bioselection, mirroring such regimens for SNUC and ONB.¹³⁵⁸ In an 18-patient series, those patients who had a partial or complete response to IC had improved 5-year OS compared to those who had no response (39% vs. 8%; HR 2.79, 95% CI: 0.75–10.35). Of these 18 patients, six patients went on to surgery and orbital preservation was achieved in all cases.¹⁵¹⁵ Similarly, early experience with induction immunotherapy regimens has also been described for locally unresectable SNMM or patients presenting with metastatic disease.^{1516–1518}

Role of surgery for sinonasal mucosal melanoma

Aggregate grade of evidence	C (Level 2: one study; Level 4: 16 studies)
Benefit	Surgical resection with negative margins appears to be associated with improved OS and potentially RFS. When possible, it appears that endoscopic resection has equivalent results to open resection for OS and DSS.
Harm	Surgical morbidity is largely related to selection of surgical approach and site of the tumor.

(Continued)

Cost	Cost comparison analyses have not been undertaken.
Benefits–harm assessment	Preponderance of benefits over harms.
Value judgments	Surgical resection with negative margins is beneficial to improve OS.
Policy level	Recommendation.
Intervention	Surgical resection is the first-line therapy for SNMM when resection with negative margins can be achieved; when feasible, endoscopic resection should be considered. In cases of locally advanced or metastatic SNMM, the morbidity of radical surgical resection should be weighed against the poor survivability of this tumor; nonsurgical options may be considered in these cases.

4 | Impact of cutaneous melanoma markers and genetic mutations

Although UV-light exposure is the most well-known predisposing factor for cutaneous melanoma, risk factors for SNMM are much less well defined (Table XXIV.D.2). SNMM patients tend to present later in life and do not have a specific sex predilection or association with alcohol or tobacco consumption.^{1519,1520} When SNMM tumors have been assessed for genetic mutations, only about 40% of tumors have identifiable recognized mutations.^{1476,1520} Moreover, the tumor mutation burden of SNMM is not high compared to other malignancies and is not predictive tumor immunogenicity as measured by lymphocyte and T-cell infiltrate into tumor tissue.¹⁵²¹

The mitogen-activated protein kinase (*MAPK*) pathway is a key component of cutaneous melanoma development. Dysregulation of this pathway occurs due to activation of *BRAF* or *RAS* genes, leading to increased cellular proliferation.^{1522–1525} In cutaneous melanomas, *BRAF* mutations are the most identified mutations and are present in 50%–70% of cases.¹⁵²⁵ Thus, in cases of advanced cutaneous melanoma, *BRAF* inhibitor therapies such as vemurafenib have proven to be viable treatment options. In a landmark phase III clinical trial, patients with previously untreated metastatic cutaneous melanoma with *BRAF* V600E mutations were randomly assigned to receive vemurafenib or standard-of-care chemotherapy (dacarbazine). At 6 months, the OS was 84% in the vemurafenib group and 64% in the dacarbazine group. Vemurafenib was associated with a relative reduction of 63% in risk of death and of 74% in the risk of disease progression ($p < 0.001$ for both comparisons).¹⁵²⁶ These data, along with additional subsequent studies, have pushed *BRAF* inhibitor

therapy to the forefront of locally advanced and metastatic cutaneous melanoma.^{1527–1531}

Although *BRAF* inhibitor therapy has been instrumental in improving survival in cutaneous melanoma, similar advances in SNMM have proven to be elusive. Across numerous studies, *BRAF* mutation rates in SNMM have been 0%–8% of cases.^{1476,1496,1520,1532,1533} In light of this, *BRAF* inhibitor therapy has a limited role in the current treatment of the majority of SNMM patients.

In contrast to *BRAF* mutations, it appears that *NRAS* mutations are the most identified genetic mutation in SNMM patients in 14%–30% of patients.^{123,124,1476,1520,1534} *NRAS* mutations also stimulate the *MAPK* pathway by activating *MEK* followed by *ERK*, thus mediating cell proliferation.^{1534–1536} *NRAS* mutations may also occur more commonly when the primary tumor is located in the paranasal sinuses compared to the nasal cavity.¹²⁴

As opposed to *BRAF* mutations where specific targeted agents are available, no such specific agent exists for *NRAS* mutations. However, there are several agents in clinical trials that target downstream *NRAS*-dependent signaling cascades, most notably *MEK*.¹⁵³⁴ Several *MEK* inhibitors have been studied in clinical trials including binimetinib and pimasertib.¹⁵³⁷ Although some early data demonstrated improved survival in *NRAS*-mutated melanomas compared to standard-of-care chemotherapy regimens, these results were not felt to be clinically significant and *MEK* inhibitors are not currently approved in *NRAS*-mutated melanomas.^{1538,1539}

5 | Impact of PD-L1 and immunotherapy

Host immune systems have the ability to selectively recognize and destroy pathogens or unhealthy cells, including cancer cells. Immune checkpoints are present to prevent T-cells from inadvertently destroying healthy cells, as may occur in autoimmune diseases. In select cases, cancer cells can exploit these naturally occurring immune checkpoints to prevent the host immune system from recognizing them and thus triggering them for destruction, often referred to as “immune evasion.”¹¹⁸

One such immune evasion mechanism that is highly prevalent across several malignancies, including melanoma, involves the programmed death-1 receptor (PD-1) and PD-L1. PD-1 is a receptor that is expressed on the surface of activated cytotoxic T-cells. PD-1 acts as an immune checkpoint by stimulating apoptosis of cytotoxic T-cells and reducing apoptosis of suppressive regulatory T-cells. PD-L1 is the ligand that binds PD-1 and activates it, thus causing downstream immunosuppressive effects.^{1540,1541} PD-L1 is also highly expressed in many mucosal melanomas.^{1541,1542} PD-L1 expression

TABLE XXIV.D.2 Evidence surrounding impact of cutaneous melanoma markers and genetic mutations.

Study	Year	LOE	Study design	Study groups	Clinical endpoints	Conclusion
Colombino and Paliogiannis ¹²²	2019	4	Retrospective case series	SNMM patients with tissue available for 25-gene panel ($n = 25$)	<ol style="list-style-type: none"> 1. Mutational profile 2. DNA damage analysis for UV radiation induced damage 3. Genetic mutation correlation with high mitotic rate 	<ol style="list-style-type: none"> 1. <i>BRAF</i> (32%) most common mutation; <i>KIT</i> and <i>RAS</i> next most common 2. 28% had evidence of UV damage versus 90% in cutaneous melanoma 3. Nine out of 11 (82%) patients with high mitotic rate had pathologic mutation
Amit et al. ¹⁵²⁰	2017	4	Retrospective case series	SNMM patients with tissue available for genomic DNA extraction ($n = 66$)	<ol style="list-style-type: none"> 1. OS 2. Mutation status 	<ol style="list-style-type: none"> 1. Mutation status was not correlated with survival 2. 40% of cases with identifiable mutation 3. <i>NRAS</i> (30%) most common mutation, then <i>BRAF</i> (8%) and <i>KIT</i> (5%) (in contrast to cutaneous melanoma where <i>BRAF</i> mutation is present 50%–70% of cases)
Turri-Zanoni et al. ¹²³	2013	4	Retrospective case series	SNMM patients with tissue available for IHC, FISH, and DNA sequencing ($n = 32$)	<ol style="list-style-type: none"> 1. Mutational profile 2. OS by mutation 	<ol style="list-style-type: none"> 1. <i>NRAS</i> (22%) and <i>KIT</i> (13%) most common 2. Amplification of <i>RREB1</i> (100%) and loss of <i>MYB</i> (765) in many cases 3. <i>KIT</i> expression (97%) 4. <i>MAPK</i> and <i>PI3K/Akt</i> pathway activated in all cases (100%) 5. No mutational profile associated with survival difference
Zebary et al. ¹²⁴	2013	4	Retrospective case series	SNMM patients with tissue available for mutation screening ($n = 56$)	<ol style="list-style-type: none"> 1. OS by mutation 2. Mutational profile by primary site 3. OS by primary site 	<ol style="list-style-type: none"> 1. No difference in OS based on mutation 2. <i>NRAS</i> (14%) most common mutation, followed by <i>BRAF</i> and <i>KIT</i> (4% each) 3. More likely to have mutation (<i>NRAS</i>, <i>KIT</i>, or <i>BRAF</i>) in paranasal sinus primary 4. Worse survival in paranasal sinus primary

Abbreviations: OS, overall survival; SNMM, sinonasal mucosal melanoma.

in the mucosal melanoma tumor microenvironment is both a prognostic and predictive biomarker.^{1543,1544} PD-L1 expression in the tumor microenvironment is present in 44% of mucosal melanomas, which is slightly higher than that of cutaneous melanomas.

Pembrolizumab and nivolumab are targeted monoclonal antibodies that bind and block PD-1 on lymphocytes, thus preventing binding of PD-L1 ligands, subsequently preventing deactivation of the immune response.

The end effect is increased immune system activation and destruction of tumor cells.¹⁵⁴⁵ These agents were approved in 2014 for use in patients with metastatic or unresectable cutaneous melanoma after demonstrating an improvement in OS.^{1546–1548} Subsequent studies have increased the indications for these agents to include nonsmall-cell lung cancer, recurrent head and neck squamous cell carcinoma, renal cell cancer, and others.^{1549–1552} Given the efficacy in cutaneous melanoma, there has been recent

increasing interest and utilization of these agents in mucosal melanoma, as well.

Another prevalent immune evasion mechanism involves cytotoxic T-lymphocyte-associated protein 4 (CTLA-4). CTLA-4 is an immune checkpoint receptor protein that also downregulates immune response.¹⁵⁴⁶ Ipilimumab was developed as a monoclonal antibody that binds CTLA-4, thus blocking inhibitory signals produced by the tumor microenvironment and allowing improved immunosurveillance for tumor cells.^{1540,1553,1554} This was one of the first immunotherapies to be approved for advanced or metastatic cutaneous melanoma after phase III clinical trials demonstrated improved OS.¹⁵⁵⁵ Despite early promising results, ipilimumab response was noted in a relatively small number of patients and the response tended to wane over time, with a distinct plateau noted around year 3 of treatment.¹⁵⁵⁶ In addition, medication side effects and AEs are not uncommon with ipilimumab including pneumonitis, dermatitis, and enterocolitis, with grade 3–4 AEs occurring in 18% of patients.¹⁵⁵⁷

In a phase III clinical trial of ipilimumab-resistant patients with metastatic cutaneous melanoma without *BRAF* mutation, nivolumab demonstrated higher 1-year OS than standard chemotherapy (dacarbazine) (72.9% vs. 42.1%). The median PFS was 5.1 months in the nivolumab group compared to 2.2 months in the dacarbazine group.¹⁵⁵⁸ Moreover, in a randomized phase III trial CheckMate 037, patients with unresectable or metastatic cutaneous melanoma who progressed through ipilimumab demonstrated a better objective response to nivolumab than standard chemotherapy and fewer grade 3–4 AEs.¹⁵⁵⁹ Other work has demonstrated superiority of pembrolizumab as monotherapy (OS, PFS, toxicity) in metastatic melanoma (majority of subjects had cutaneous melanoma, but a subset of subjects had mucosal melanoma) compared to ipilimumab monotherapy or other standard chemotherapy regimens in KEYNOTE trials 002 and 006.^{1509,1560–1562} Thus, immunotherapy regimens have become increasingly utilized over traditional chemotherapy regimens for patients with advanced and metastatic melanoma (Table XXIV.D.3).

For mucosal melanoma specifically (all sites), the first large, pooled analysis was reported in 2017. In this pooled analysis of mucosal melanoma patients from several phase III clinical trials, combination therapy of nivolumab and ipilimumab (37%) demonstrated superiority compared to monotherapy with either nivolumab (23%) or ipilimumab (8%). Additionally, grade 3–4 adverse treatment events were noted in 8.1% of mucosal melanoma patients receiving nivolumab monotherapy versus 40% receiving combination therapy.¹⁵⁵⁰ Moreover, pembrolizumab data for mucosal melanoma patients were pooled from all KEYNOTE trials and analyzed. In this pooled analysis,

pembrolizumab monotherapy following previous treatment failure and disease progression demonstrated a durable response in some patients showing an objective response rate of 19%, disease control rate of 31%, median PFS of 2.8 months, and median OS of 11.3 months.¹⁵⁶⁰

Although data on immunotherapy specifically for SNMM are scarce, a pooled NCDB data multivariate analysis demonstrated that survival following immunotherapy was improved for patients with metastatic disease, but not those without metastases (HR 0.14, 95% CI: 0.04–0.49).³⁶⁶ A separate NCDB database study comparing the efficacy of immunotherapy for SNMM compared to cutaneous melanoma found that the addition of immunotherapy improved OS in metastatic cutaneous melanoma (HR 0.57; 95% CI: 0.49–0.66; $p < 0.0001$) but not in metastatic SNMM (HR 1.1; 95% CI: 0.67–1.7; $p = 0.75$).¹⁵⁶³ Another NCDB analysis of head and neck mucosal melanoma (79% of which were sinonasal) found that immunotherapy was associated with improved OS on multivariate analysis after controlling for tumor stage, size, site, age, and comorbidities.¹⁵⁰³ An NCDB study of mucosal melanoma of the head and neck (all sites; 71.8% of which were sinonasal) found that surgery and adjuvant immunotherapy had improved OS compared to surgery alone. An international multicenter retrospective analysis found that immune checkpoint blockade (e.g., ipilimumab, pembrolizumab, nivolumab) was associated with improved OS when administered for recurrent/persistent disease as compared to no treatment, which in turn had superior OS as compared to cases treated with biochemotherapy (e.g., interleukin, interferon).¹⁵⁶⁴ Additionally, surgery with adjuvant immunotherapy and RT had improved OS compared to surgery and RT.¹⁵⁶⁵

Role of immunotherapy in sinonasal mucosal melanoma

Aggregate grade of evidence	C (Level 1: one study; Level 4: seven studies)
Benefit	Immunotherapy has proven efficacy as an adjuvant therapy for metastatic cutaneous melanoma. Early experience has also demonstrated efficacy as an adjunctive therapy for advanced or metastatic SNMM and may improve OS, although the robust responses do not equal the efficacy noted for metastatic cutaneous melanoma.
Harm	The potential harm of immunotherapy includes rash, fever, nausea, and more severe immune-related adverse events including enterocolitis, pneumonitis, and hepatitis, particularly when used in combination therapy.

(Continued)

TABLE XXIV.D.3 Evidence surrounding impact of PD-L1 and immunotherapy in sinonasal mucosal melanoma treatment.

Study	Year	LOE	Study design	Study groups	Clinical endpoints	Conclusion
D'Angelo et al. ¹⁵⁵⁰	2017	2	RCT	Nivolumab or nivolumab plus ipilimumab in advanced (stage III or IV) melanoma patients (<i>n</i> = 121 mucosal melanoma patients; mucosal site not specified)	<ol style="list-style-type: none"> Complete or partial response (ORR) Duration of response (median PFS) Rate of Grade 3 or 4 complications 	<ol style="list-style-type: none"> 53% ORR for nivolumab monotherapy with PD-L1 expression $\geq 5\%$; 12.2% ORR if PD-L1 $\leq 5\%$ 14% ORR for ipilimumab monotherapy with PD-L1 expression $\geq 5\%$; 9.5% ORR if PD-L1 $\leq 5\%$ 60% ORR for combination nivolumab/ipilimumab with PD-L1 expression $\geq 5\%$; 33% ORR if PD-L1 $\leq 5\%$ PFS for combination nivolumab/ipilimumab was 5.9 months for mucosal melanoma Nivolumab monotherapy 8.1% complication rate Combination nivolumab/ipilimumab 40% complication rate
Abiri et al. ¹⁵⁶⁵	2022	4	Retrospective database study (NCDB)	Head and neck mucosal melanoma patients from the NCDB 2004–2017 (<i>n</i> = 1910 total patients, of which 1371 were SNMM subsite)	OS	<ol style="list-style-type: none"> Immunotherapy independent predictor of improved survival SI and SRI improved survival over SR Immunotherapy confers survival benefit in SNMM, when subgrouped No survival benefit in SI relative to SRI
Lechner et al. ¹⁵⁶⁴	2022	4	Retrospective cohort	SNMM patients across 11 institutions (four United States, seven Europe) (<i>n</i> = 505)	<ol style="list-style-type: none"> OS DFS 	<ol style="list-style-type: none"> 15.2% received biochemotherapy (e.g., interferon, interleukin), 27.3% received immune checkpoint inhibitors (ipilimumab, pembrolizumab, nivolumab) In recurrent/persistent SNMM, OS was superior for immune checkpoint blockade versus no treatment, which was in turn superior to biochemotherapy
Ganti et al. ³⁶⁶	2020	4	Retrospective database study (NCDB)	SNMM patients in NCDB 2004–2015 (<i>n</i> , SNMM = 1874)	OS	Immunotherapy associated with improved survival in metastatic disease (HR 0.14)
Klebaner et al. ¹⁵⁶³	2020	4	Retrospective database study (NCDB)	SNMM patients in NCDB 2012–2015 (<i>n</i> , SNMM = 794)	OS	Immunotherapy was not associated with OS in metastatic SNMM

(Continues)

TABLE XXIV.D.3 (Continued)

Study	Year	LOE	Study design	Study groups	Clinical endpoints	Conclusion
Kaunitz et al. ¹⁵⁴³	2017	4	Retrospective case series	IHC analysis of melanoma from acral, mucosal, uveal, and sun-damaged sites (<i>n</i> , mucosal melanoma = 36)	PD-L1 expression analysis of TIL	<ol style="list-style-type: none"> Mucosal melanoma (sinus, oropharynx, anogenital)—16 out of 36 (44%) expressed PD-L1 (similar to cutaneous melanoma expression, 35%) Higher expression of PD-L1 in spindle cell subtypes of mucosal melanoma 15 out of 16 PD-L1-positive mucosal melanoma cases had high rate of TIL
Liu et al. ¹⁵⁸⁴	2017	4	Retrospective case series	IHC analysis of SNMM PD-L1 (<i>n</i> = 86)	<ol style="list-style-type: none"> PD-1, PD-L1, IDO-1, expression OS based on PD-1, PD-L1, and IDO-1 	<ol style="list-style-type: none"> Expression: PD-1 (48%), PD-L1 (54%), and IDO-1 (58%) No significant association between PD-L1 expression and prognosis In stage III, IVA, and IVB patients, PD-1 expression was associated with better outcome, but PD-L1-negative and IDO-1-positive patients had worse outcome
Thierauf et al. ¹⁵⁸⁵	2015	4	Retrospective case series	IHC analysis and clinical outcome study on patients with head and neck mucosal melanoma (<i>n</i> = 23)	<ol style="list-style-type: none"> PD-L1 expression OS by PD-L1 RFS 	<ol style="list-style-type: none"> 13% PD-L1 expression Mean OS 42.5 months for PD-L1-negative versus 121 months for PD-L1-positive tumors. PD-L1 positivity associated with improved RFS

Abbreviations: DFS, disease-free survival; DSS, disease-specific survival; IDO-1, indoleamine 2,3-dioxygenase; NCDB, National Cancer DataBase; OS, overall survival; PD-L1, programmed death-ligand 1; RFS, recurrence-free survival; SEER, Surveillance, Epidemiology, and End Results; SI, surgery + immunotherapy; SNMM, sinonasal mucosal melanoma; SR, surgery + radiation; SRI, surgery + RT + immunotherapy; TIL, tumor-infiltrating lymphocytes.

Cost	Immunotherapy is expensive; however, cost comparison analyses have not been undertaken.
Benefits-harm assessment	Balance of benefits and harms.
Value judgments	OS is likely improved in advanced and metastatic SNMM with adjuvant immunotherapy, but the duration and clinical significance are not well defined. In addition, the cost and adverse events associated with immunotherapy must be considered.
Policy level	Option.
Intervention	Adjuvant immunotherapy should be considered as a treatment option in advanced or metastatic SNMM.

6 | Role of neck treatment

The role of neck treatment in SNMM is not well defined (Table XXIV.D.4). The presence of cervical lymph node metastases at the time of SNMM diagnosis occurs in 7%–8% of patients.^{1477,1483} When present at diagnosis, the presence of regional nodal metastases adversely affects survival; the 5-year OS rates in N+ patients are reported to be 0%–4%.^{1482,1483} In a systematic review of regional disease control in SNMM, the cumulative regional recurrence rate after treatment was 18.4%. In patients who were clinically N0 at presentation, the cumulative regional recurrence rate was 17% (median follow-up 22 months).¹⁴⁸²

However, END has not historically been performed for SNMM in clinically N0 necks due to the relatively low rate of occult nodal metastases.¹⁴⁸³ A recent systematic review and meta-analysis found that END is performed in only 0.4% of SNMM cases.¹⁴⁸² The recent UK national guidelines on the management of head and neck mucosal

TABLE XXIV.D.4 Evidence surrounding role of neck treatment in sinonasal mucosal melanoma.

Study	Year	LOE	Study design	Study groups	Clinical endpoints	Conclusion
De Virgilio et al. ¹⁴⁸⁶	2021	2	Systematic review	SNMM patients undergoing treatment, with or without neck dissection (<i>n</i> = 936)	RRR	<ol style="list-style-type: none"> 1. Cumulative RRR, regardless of presenting N status, was 18% 2. Clinical N0 necks who did not have elective neck dissection had RRR 17% 3. END performed in 0.4% of cases, limiting ability to draw conclusions on effect of END
Low et al. ¹⁴⁸³	2020	4	Retrospective database study (SEER)	SNMM patients in SEER database 1973–2015 (<i>n</i> = 328)	OS	Patient presentation with clinically involved regional nodes was associated with a <4% 5-year OS
Nenclares et al. ¹⁵¹⁴	2020	4	Expert consensus based on retrospective data (UK National Guidelines)	Head and neck mucosal melanoma guidelines, reviewing retrospective publications (<i>n</i> not specified)	Evidence-based clinical recommendations	<ol style="list-style-type: none"> 1. Consider SLNB if positivity will influence adjuvant therapy or clinical trial entry 2. If SLNB positive, completion neck dissection not recommended 3. If SLNB not technically feasible, consider END for appropriate levels only if it will influence adjuvant therapy
Oliver et al. ¹⁵⁰³	2019	4	Retrospective database study (NCDB)	All head and neck mucosal melanoma patients in NCDB 2004–2015 (<i>n</i> = 1373)	<ol style="list-style-type: none"> 1. OS 2. Factors associated with improved 2-year OS 	Neck dissection not associated with improved 2-year OS
Torabi et al. ²⁴¹	2019	4	Retrospective database study (NCDB)	Head and neck mucosal melanoma patients with clinically negative necks in NCDB 2004–2015 (<i>n</i> , SNMM = 275)	OS	<ol style="list-style-type: none"> 1. No difference in OS between END and no END (42% vs. 43% 3-year OS) 2. 23 ENDS performed
Amit et al. ¹⁵²⁰	2017	4	Retrospective case series	SNMM patients at a single institution (<i>n</i> = 198)	<ol style="list-style-type: none"> 1. RRR 2. DSS 	<ol style="list-style-type: none"> 1. Regional recurrence 30% in those who underwent therapeutic neck dissection versus 17% who presented with cN0 neck 2. Presence of regional lymph node metastasis not associated with OS or DSS
Lund et al. ¹⁴⁸²	2012	4	Retrospective case series	SNMM patients at a single institution (<i>n</i> = 115)	<ol style="list-style-type: none"> 1. OS 2. DSS 	0% survival at 5 years with clinically positive regional nodes at presentation

Abbreviations: DSS, disease-specific survival; NCDB, National Cancer DataBase; OS, overall survival; RRR, regional recurrence rate; SEER, Surveillance, Epidemiology, and End Results; SLNB, sentinel lymph node biopsy; SNMM, sinonasal mucosal melanoma.

melanoma advocate against END for SNMM.¹⁵¹⁴ Conversely, other head and neck sites of mucosal melanoma such as the oral cavity are associated with higher rates of nodal involvement and END are more commonly performed in these cases.^{1566,1567}

In a large institutional review of regional lymph node metastases in SNMM, Amit et al. reported that therapeutic neck dissection was completed in 23 patients (11.6%). In this cohort, regional nodal recurrence occurred in seven patients who had lymph node metastasis at the time of presentation (30.4%) and in 30 of those who had N0 disease at the time of presentation (17.1%). Delayed metastases to the contralateral lymph nodes were present in seven patients (3.5%). In contrast to other large population-based studies, the authors found that the presence of regional lymph node metastases was not associated with OS or DSS.¹⁵⁶⁸ In a recent NCDB study, Oliver et al. report that completion of a neck dissection was not associated with OS in a multivariate analysis controlling for several variables, including tumor stage and size.¹⁵⁰³

Paralleling the popularity of sentinel lymph node biopsy (SLNB) for cutaneous melanoma, SLNB has emerged as a potential option for mucosal melanoma. Although injection of the primary site by nuclear medicine physician can be technically challenging, preliminary experiences of SLNB have been reported for SNMM.^{1569–1571} Conceptually, the role of SLNB for SNMM would be to more accurately stage disease and guide adjuvant therapies. The current UK national guidelines advocate consideration of SLNB for accessible SNMM when positivity will influence adjuvant therapy or inclusion in a clinical trial; however, they do not recommend completion neck dissection when the SLNB is positive.¹⁵¹⁴

Treatment of the neck in sinonasal mucosal melanoma

Aggregate grade of evidence	C (Level 2: one study; Level 4: six studies)
Benefit	Neck dissection may reduce risk of regional recurrence (low level evidence) but has not been shown to be associated with OS.
Harm	Potential harm of neck dissection includes cranial nerve injury, shoulder dysfunction, and vascular injury.
Cost	Cost comparison analyses have not been undertaken.
Benefits-harm assessment	Balance of benefits and harms.
Value judgments	Neck dissection for clinically positive lymph nodes may be considered but must be weighed against other options including immunotherapy.

(Continued)

Policy level	Option.
Intervention	Neck dissection for clinically positive cervical lymph nodes may be considered within the context of the patient's overall treatment plan.

7 | Role of radiation therapy

RT has played a prominent role in the treatment of SNMM (Table XXIV.D.5). Across several studies, RT is used in the treatment of SNMM in 44%–58% of cases.^{366,1482,1565} In the majority of cases, RT is utilized in an adjuvant setting following surgery with a typical dose-fractionation schedule of about 60 Gy in 30 fractions or a biologically equivalent regimen.^{269,368,1482,1572–1574} Elective neck RT in the clinically N0 neck is infrequently utilized.¹⁵⁷⁵ However, primary monotherapy with RT or RT with systemic therapy may be selected in cases of unresectable tumors or metastatic disease.^{1403,1485}

The efficacy of RT for SNMM with regard to survival has been explored in a number of studies. A systematic review of head and neck mucosal melanoma (all sites) found that patients who underwent surgery and adjuvant RT had improved OS and improved local control compared to those who underwent surgery alone.¹⁵⁷³ However, other studies focusing specifically on SNMM have shown mixed data. In a large multicenter study, patients who underwent adjuvant RT following surgery demonstrated a decreased local recurrence rate ($p = 0.001$), but without impact on OS.²⁶⁹ Mirroring these results, a 2016 NCDB study of 695 SNMM patients found no difference in OS between patients undergoing surgery alone versus surgery with adjuvant RT.³⁶⁸ Another population-based study of 1373 patients found that negative margin surgery, immunotherapy, and treatment in the modern era were associated with improved OS (controlling for age, sex, comorbidities, tumor size, and stage); however, RT was not associated with OS.¹⁵⁰³ Caspers et al. also reported an institutional experience with 51 patients, of which 84% of patients underwent surgery and adjuvant RT. Adjuvant RT was associated with improved local control but had no effect on OS or DSS.³⁶⁴ In another single-institutional series, Manton et al. reported no association between RT use and OS, LRC, or distant control.¹⁵⁷⁶ Moreno et al. report similar results with adjuvant RT being associated with improved LRC but with no effect on OS.²³² Finally, a large international multicenter study of 505 SNMM cases did find an OS benefit in patients receiving both surgery and adjuvant RT compared to surgery alone.¹⁵⁶⁴ In summary, adjuvant RT is likely associated with local control, but the impact on OS remains unclear.

TABLE XXIV.D.5 Evidence surrounding the role of radiation therapy in sinonasal mucosal melanoma.

Study	Year	LOE	Study design	Study groups	Clinical endpoints	Conclusion
Grant-Freemantle et al. ¹⁵⁷³	2021	1	Systematic review	22 studies; Head and neck mucosal melanoma (site not specified, <i>n</i> = 2489)	1. OS 2. Local recurrence 3. Distant metastasis	1. SR has a lower risk of death compared to surgery alone 2. SR has a reduced risk of local recurrence versus surgery alone 3. SR does not influence distant metastasis
Zenda et al. ¹⁵⁸⁶	2016	3	Prospective cohort	SNMM patients at a single institution treated with proton beam RT only (60 Gy in 15 fractions) (<i>n</i> = 32)	1. Local control rate 2. OS	1. 1-year local control = 75% 2. 3-year OS = 46.1%
Lechner et al. ¹⁵⁶⁴	2022	3	Retrospective cohort	SNMM patients across 11 institutions (four United States, seven Europe) (<i>n</i> = 505)	1. OS 2. DFS	1. Surgery and adjuvant RT associated with improved OS compared to surgery alone 2. RT conferred no significant impact on DFS
Manton et al. ¹⁵⁷⁶	2019	4	Retrospective case series	SNMM patients at a single institution (<i>n</i> = 31)	1. OS 2. LRC 3. Distant control	Stage, primary site, smoking status, margin status, time to treatment, and RT not associated with OS, LRC, or distant control
Oliver et al. ¹⁵⁰³	2019	4	Retrospective database study (NCDB)	All head and neck mucosal melanoma patients in NCDB 2004–2015 (<i>n</i> = 1373)	1. OS 2. Factors associated with improved 2-year OS	RT not associated with improved 2-year OS
Caspers et al. ³⁶⁴	2018	4	Retrospective case series	SNMM patients at a single institution (<i>n</i> = 51)	1. OS 2. DSS 3. Local recurrence 4. Distant metastasis	1. Adjuvant RT associated with improved local control 2. No difference in distant metastasis between surgery versus surgery with RT
Konuthula et al. ¹⁵⁷⁴	2016	4	Retrospective database study (NCDB)	All SNMM patients in NCDB 2004–2010	OS	No difference in OS between surgery alone and surgery with adjuvant RT
Samstein et al. ¹⁵⁷⁹	2016	4	Retrospective case series	SNMM patients at a single institution (<i>n</i> = 78)	1. OS 2. DSS	RT is associated with improved local control but not survival benefit
Won et al. ²⁶⁹	2015	4	Retrospective case series	SNMM patients from 15 hospitals in South Korea (<i>n</i> = 155)	1. OS 2. Recurrence rate	RT decreased local recurrence, no impact on OS
Moreno and Hanna ¹⁵⁰⁶	2010	4	Retrospective case series	SNMM patients at a single institution (<i>n</i> = 58)	1. OS 2. Local recurrence	1. Adjuvant RT associated with improved local control 2. Adjuvant RT did not affect OS
Bachar et al. ⁴⁰⁰	2008	4	Retrospective case series	Head and neck patients at a single institution (<i>n</i> , SNMM = 49)	1. DFS 2. Local, regional, distant recurrence 3. Median survival	1. 5-year local control rate 13% for RT only (<i>n</i> = 21) versus 30% for surgery with RT 2. Median survival for surgery alone, RT alone, and combined therapy: 31, 28, and 21 months, respectively

Abbreviations: DFS, disease-free survival; DSS, disease-specific survival; NCDB, National Cancer DataBase; OS, overall survival; RT, radiation therapy; SEER, Surveillance, Epidemiology, and End Results; SNMM, sinonasal mucosal melanoma; SR, surgery + RT.

The role of RT as a primary treatment modality is not well defined. Reports in the literature mainly describe primary RT as a modality to treat unresectable or metastatic disease. Several studies have shown that primary RT has little effect on OS or PFS in patients with SNMM.^{400,1477,1503,1509,1577–1579} On the other hand, primary proton beam RT for SNMM has been described in a multicenter phase II study. Thirty-two patients were enrolled and received 60 Gy in 15 fractions and the median follow-up time was 36 months. The 3-year OS was 46.1% and 3-year PFS was 36.4%; 15 patients developed metastatic disease during the 36-month follow-up.^{1580,1581} The role of proton beam RT compared to traditional RT modalities has not been well studied.

The role of RT in unresectable or metastatic mucosal melanoma has also been investigated in combination with systemic immunotherapy. In a multicenter retrospective study of 225 patients with unresectable or metastatic mucosal melanoma patients (all sites; 57% in the head and neck region), patients were divided into treatment groups including PD1 inhibitor therapy (PD1) alone versus PD1 + RT versus PD1 + CTLA4 inhibitor therapy (CTLA4) + RT. All groups had similar baseline characteristics with regard to tumor site and stage. In this study, there was no difference in OS or PFS between the PD1-only cohort versus PD1 + RT cohort or the PD1-alone cohort versus PD1 + CTLA4 + RT cohorts. Subsequent Cox multivariate analysis indicated that the addition of RT to PD1 or PD1 + CTLA4 did not have a positive impact on OS or PFS.¹⁵⁸²

Role of radiation therapy in sinonasal mucosal melanoma

Aggregate grade of evidence	C (Level 1: one study; Level 3: two studies; Level 4: eight studies)
Benefit	There is evidence that adjuvant RT improves local control of SNMM; however, RT has not been consistently associated with improved OS.
Harm	Potential harm of RT includes cost, mucositis, osteoradionecrosis, nasal synechia, hyposmia, dysgeusia, and diminished vision.
Cost	Cost comparison analyses have not been undertaken.
Benefits-harm assessment	Balance of benefits and harms.
Value judgments	Adjuvant RT should be considered to improve local control.
Policy level	Option.

(Continued)

Intervention	Adjuvant RT should be considered for patients with SNMM as part of multimodality therapy. The benefit to local control should be weighed against the side effects of RT treatment.
--------------	--

XXV | NASOPHARYNGEAL MALIGNANCIES

A | Nasopharyngeal carcinoma

NPC is a special type of cancer in the sinonasal tract that has a wide geographical variation in incidence. The cancer has the highest incidence in South China and areas of high concentration of migrants from South China.^{1587,1588} NPC has been proposed to have a multifactorial etiology, including genetic susceptibility, EBV infection, and environmental factors.^{1589,1590} The histological subtype of cancer in the high-risk population (endemic NPC) is of a poorly differentiated or undifferentiated type, and is invariably associated with EBV.¹⁷ NPC in the nonendemic region is more likely well-differentiated SCC. Endemic NPC is highly sensitive to RT, and is primarily treated with nonsurgical therapy. Surgery has a role in endemic NPC in salvage of radiation failures, recurrence, and second primary tumors. Surgery has a more significant role for other rare non-nasopharyngeal histological subtypes (e.g., malignant salivary gland tumors) that are generally more radioresistant. There has been significant improvement in the prognosis of NPC, driven by advances in imaging, RT, and chemotherapy. Emerging RT techniques such as adaptive radiotherapy and heavy particle radiotherapy have theoretical advantages in the treatment of NPC, especially in advanced-stage disease. However, there is limited availability for those newer radiation techniques and a lack of randomized clinical trials comparing those to standard radiotherapy techniques. There have been many trials evaluating various chemotherapy regimens over the last 20 years. Direct comparison of different agents in different regimens on a large scale through phase III trials is very challenging. The use of network meta-analyses provides indirect comparison of various chemotherapy regimens.

1 | WHO subtypes

Despite the existence of several histomorphological classification systems for NPC and their terminology differences, these classifications correlate with the tumor's biological behavior, etiology, clinical prognosis, and response to treatment. EBV has long been known to be implicated in tumorigenesis in endemic countries,¹⁵⁹¹ whereas

HPV found in nonendemic areas has been identified to be another viral cause of NPC.¹⁵⁹² According to the 5th edition of the WHO Classification of Head and Neck Tumors, NPC is classified into three major histological categories: keratinizing, nonkeratinizing, and basaloid SCC (Table XXV.1).¹⁷ Traditionally, undifferentiated SCC was separately classified but is now grouped under nonkeratinizing tumors.

Keratinizing SCC of the nasopharynx, which involves overt squamous differentiation in the form of keratinization and intercellular bridges, appears similar to conventional SCCs of the other head and neck sites. Despite some debate, keratinizing SCC is usually considered more radioresistant and has a worse prognosis than the nonkeratinizing type.^{1589,1593–1598} Different studies have reported varying results on the correlation between EBV and keratinizing SCC, with a positive association more commonly found in endemic areas.^{1599,1600}

Nonkeratinizing SCC can be further divided into undifferentiated and differentiated subtypes. The undifferentiated subtype typically exhibits a syncytium of tumor cells with large and vesicular nuclei, prominent nucleoli, and indistinct cell borders. By contrast, tumor cells of the differentiated subtype have relatively well-defined cell borders and usually present as a plexiform pattern that resembles urothelial carcinoma of the genitourinary tract. Both subtypes are strongly associated with EBV. Additionally, it is not uncommon to observe a mix of differentiated and undifferentiated components. Although some studies have reported better survival rates for patients with tumors of the undifferentiated subtype,^{1601–1603} the morphological separation of the two subtypes is regarded as being more of academic interest than clinical importance because of their similar etiology and prognosis.^{1595,1596,1604,1605}

Basaloid SCC of the nasopharynx, the rarest of the three histological categories of NPC, shares an identical morphology with that of basaloid SCC of other primary sites. It is characterized by large round basaloid tumor nests with comedo-type necrosis as well as an occasional cribriform-like pattern and stromal hyalinization, resembling a solid-type ACC. Some cases have been reported to be associated with EBV.¹⁶⁰⁶ Patients with this type of tumor have been found to have good 1- and 5-year survival comparable to patients with the nonkeratinizing type, but have similar sharply decreased 10-year survival as that observed with the keratinizing type.¹⁶⁰⁷

Aggregate grade of evidence: B (Level 4: nine studies)

2 | The role of EBV in NPC

NPC has long been proven to be associated with EBV. Previously, NPC had no reliable tumor markers in clinical

practice. Since 1970, various anti-EBV antibodies have been evaluated as diagnostic and prognostic markers of NPC.^{1608–1611} After more than 30 years of studies, serological antibody tests have been shown to be of little help in the clinical management of NPC and have rarely been investigated in recent years. The major reason for this may be that the antibody titer remains persistently high in most patients in remission after treatment^{1612,1613} and has no significant impact on survival.¹⁶¹⁴ In addition, there is no reliable cutoff value for differentiating between recurrence and remission.

With recent advances in molecular biology, PCR-based techniques make it possible to detect trace amounts of biomolecules in a wide array of biological samples. In 1999, Lo et al. first successfully developed real-time quantitative PCR to quantify circulating EBV DNA in patients with NPC.¹⁶¹⁵ Their series of studies^{1615–1621} and another comprehensive study¹⁶²² prompted routine use in the management of these patients. Since then, many subsequent reports have shown higher sensitivity and specificity for detecting cell-free EBV DNA in the plasma and serum of NPC patients. In addition, the quantification of circulating EBV DNA has been demonstrated to be highly correlated with tumor burden and patient survival, differential diagnosis of recurrence/remission, and early prediction of treatment response.^{1618,1623}

EBV DNA serum testing is now accepted as a useful tool in real-world practice. Table XXV.2 lists the application values of EBV DNA serum tests in clinical practice. First, the presence of circulating EBV DNA can serve as a diagnostic marker for the detection of NPC in healthy controls and patients without NPC. Five meta-analysis studies showed a pooled sensitivity of 0.69–0.89, specificity of 0.84–0.96, positive likelihood of 4.81–14.66, and a negative likelihood of 0.12–0.25.^{1624–1628} Second, serum EBV DNA can provide useful information to guide NPC treatment, including aiding in treatment outcome prediction and risk grouping,^{1629–1633} supplementing the TNM staging system,^{1634–1640} determining adjuvant therapy for post-RT patients with residually detectable lab values,^{1641,1642} and early prediction of treatment response in recurrent/metastatic^{1643–1645} and locally advanced patients.¹⁶⁴⁵ Finally, EBV DNA can replace various anti-EBV antibodies as a screening marker for NPC in the general population. A large prospective study conducted in Hong Kong enrolled 20,174 asymptomatic persons using the serum EBV DNA test for NPC screening between July 2013 and February 2016.¹⁶⁴⁶ Thirty-four new cases of NPC were diagnosed among 309 participants (1.5%) who were persistently positive for circulating EBV DNA. These patients with NPC had a significantly higher proportion in the early stage than those in the historical cohort (71% vs. 20%, $p < 0.001$) and superior PFS

TABLE XXV.1 Evidence surrounding World Health Organization subtypes in nasopharyngeal carcinoma.

Study	Year	LOE	Study design	Study groups	Clinical endpoints	Conclusion
Stepan et al. ¹⁷³³	2021	4	Retrospective database study (NCDB)	9995 (1661 UNKSCC, 2370 DNKSCC, 5964 KSCC)	OS	KSCC had worse OS than DNKSCC (aHR 0.67, 95% CI: 0.60–0.74, $p < 0.001$) and UNKSCC (aHR 0.55, 95% CI: 0.48–0.63, $p < 0.001$)
Argirion et al. ¹⁶⁰⁵	2020	4	Retrospective database study (SEER)	6284 (1413 UNKSCC, 968 DNKSCC, 2815 KSCC)	5-year RS	KSCC (males 41.9% and females 41.5%) had worse RS than DNKSCC (males 63.1% and females 63.4%) and UNKSCC (males 65.8% and females 70.1%)
Pan et al. ¹⁵⁹³	2020	4	Retrospective database study (SEER)	4085 (2203 NKSCC, 1929 KSCC, 53 BSCC)	DSS	<ol style="list-style-type: none"> 3-year DSS rates were KSCC (61.76%), NKSCC (79.57%), and BSCC (77.55%) 5-year DSS rates were KSCC (55.07%), NKSCC (72.09%), and BSCC (74.03%) After adjusting these covariates by using multivariate analysis, patients with KSCC had a worse prognosis than those with NKSCC (HR 0.6, 95% CI: 0.53–0.67, $p < 0.001$) or BSCC (HR 0.51, 95% CI: 0.31–0.86, $p = 0.011$)
Unsal et al. ¹⁶⁰⁷	2019	4	Retrospective database study (SEER)	82 BSCC	DSS	<ol style="list-style-type: none"> BSCC had fair short-term but poor long-term survival 1-year DSS: BSCC 87.7%, NKSCC 90.8%, KSCC 67.1% ($p < 0.0001$) 5-year DSS: BSCC 60.7%, NKSCC 58.2%, KSCC 40.7% ($p < 0.0001$) 10-year DSS: BSCC 29.8%, NKSCC 38.2%, KSCC 27.9% ($p < 0.0001$)
Wu et al. ¹⁵⁹⁴	2019	4	Retrospective database study (SEER)	2845 (778 UNKSCC, 849 DNKSCC, 1218 KSCC)	DSS	<ol style="list-style-type: none"> 0–5 years: DNKSCC had worse DSS than UNKSCC >5 years: DNKSCC had comparable DSS with UNKSCC 0–3 years: KSCC had worse DSS than UNKSCC >3 years: KSCC had comparable DSS with UNKSCC For the entire cohort, KSCC had poorer DSS than UNKSCC (HR 2.323, 95% CI: 1.636–3.297, $p < 0.001$) and UNKSCC (HR 1.435, 95% CI: 0.945–2.111, $p = 0.067$)
Ruuskanen et al. ¹⁶⁰⁴	2018	4	Retrospective database study (Finnish Cancer Registry database)	207 (132 UNKSCC, 31 DNKSCC, 42 KSCC)	<ol style="list-style-type: none"> OS DSS 	<ol style="list-style-type: none"> KSCC had worse OS than UNKSCC, but there were no OS differences between DNKSCC and UNKSCC The 5-year DSS and OS of all patients treated between 1990 and 1999 were 58% and 49%, and those between 2000 and 2009 were 66% and 63%, respectively KSCC had worse OS than UNKSCC (aHR 1.84, 95% CI: 1.13–2.99, $p = 0.01$), but there were no OS differences between DNKSCC and UNKSCC (aHR 1.60, 95% CI: 0.89–2.87, $p = 0.12$)

(Continues)

TABLE XXV.1 (Continued)

Study	Year	LOE	Study design	Study groups	Clinical endpoints	Conclusion
Zang et al. ¹⁷³⁴	2018	4	Retrospective case series	301 (210 UNKSCC, 91 DNKSCC)	1. OS 2. DMFS	DNKSCC had worse OS (HR 1.982, 95% CI: 1.317–2.526, $p = 0.007$) and DMFS (HR 1.845, 95% CI: 1.118–3.047, $p = 0.017$) than UNKSCC
Colaco et al. ¹⁵⁹⁷	2013	4	Retrospective database study (Christie cancer registry database)	128 (87 NKSCC, 16 KSCC)	OS	KSCC had worse OS (HR 2.7, 95% CI: 1.3–5.5, $p = 0.034$) than NKSCC
Cheung et al. ¹⁶⁰²	2012	4	Retrospective case series	259 (10 DNKSCC, 249 UNKSCC)	1. OS 2. DSS 3. DMFS	DNKSCC had worse DMFS, DSS and OS ($p < 0.05$) than UNKSCC

Abbreviations: AHZ, adjusted hazard ratios; BSCC, basaloid SCC; DMFS, distant metastasis-free survival; DNKSCC, nonkeratinizing SCC, differentiated type; DSS, disease-specific survival; KSCC, keratinizing SCC; NKSCC, nonkeratinizing SCC; OS, overall survival; PYNEH, regional tertiary hospital in Hong Kong; UNKSCC, nonkeratinizing SCC, undifferentiated type; RS, relative survival; SEER, Surveillance, Epidemiology, and End Results.

($p < 0.001$). Later, they refined the blood test using novel sequencing-based analysis¹⁶⁴⁷ and differential methylation pattern analysis¹⁶⁴⁸ with improved PPV.

Role of EBV assessment in NPC

Aggregate grade of evidence	A (Level 1: 10 studies; Level 2: two studies; Level 3: four studies; Level 4: seven studies)
Benefit	A blood test for quantification of circulating EBV DNA is an ideal biomarker for the clinical management of patients with NPC. It has high sensitivity and specificity for the detection of NPC and correlates with tumor burden, patient survival, diagnosis of recurrence/remission, and early prediction of treatment response.
Harm	Need for repeat blood draws; EBV not associated with every NPC subtype.
Cost	The EBV DNA blood test has a lower cost than other diagnostic interventions, such as MRI and PET scan.
Benefits-harm assessment	Preponderance of benefits over harms.

(Continued)

Value judgments	Cumulative evidence suggests that EBV DNA serum testing can provide valuable information to guide clinical decision-making. However, elevated circulating EBV DNA levels during posttreatment follow-up only suggested tumor relapse and did not indicate the tumor location. Diagnostic imaging studies such as CT, MRI, and PET may aid to localize the exact site and extent of the recurrence. Another problem is that PCR-based techniques may produce discrepancies in different laboratories, even when using the same primer/probe sets and experimental conditions. Harmonization between international laboratories, which involves the standardization of buffers and calibrators, is feasible and significantly reduces the variability.
Policy level	Recommendation.
Intervention	The EBV DNA serum test should be used as a routine clinical test for patients with NPC for screening, diagnosis, and monitoring treatment response.

TABLE XXV. 2 Evidence surrounding EBV DNA in NPC.

Study	Year	LOE	Study design	Study groups	Clinical endpoints	Conclusion
Diagnostic role of circulating EBV DNA						
Liu et al. ¹⁶²⁸	2021	1	Systematic review and meta-analysis	87 studies, 23,474 subjects (8382 NPCs, 15,089 controls)	Pooled sensitivity 0.76, specificity 0.96, positive likelihood 14.66, negative likelihood 0.19	EBV DNA detection has higher diagnostic accuracy in NPC
Sun et al. ¹⁶²⁷	2014	1	Systematic review and meta-analysis	10 studies, 2520 subjects (617 NPCs, 1903 controls)	Pooled sensitivity 0.69, specificity 0.84, positive likelihood 4.81, negative likelihood 0.25	EBV DNA could be a useful tumor marker for NPC diagnosis
Song and Yang ¹⁶²⁶	2013	1	Systematic review and meta-analysis	27 studies, 4486 subjects (1554 NPCs, 2932 controls)	Pooled sensitivity 0.75, specificity 0.87, positive likelihood 6.98, negative likelihood 0.18	EBV DNA has high sensitivity and specificity in the diagnosis of NPC
Han et al. ¹⁶²⁵	2012	1	Systematic review	18 studies, 4133 subjects (1492 NPCs, 2641 controls)	Pooled sensitivity 0.73, specificity 0.89, positive likelihood 8.84, negative likelihood 0.19	EBV DNA detection in plasma or serum has high sensitivity and specificity in the diagnosis of NPC
Liu et al. ¹⁶²⁴	2011	1	Systematic review and meta-analysis	15 studies, 2393 subjects (1140 NPCs, 1253 controls)	Pooled sensitivity 89.1%, specificity 85.0%, positive likelihood 7.118, negative likelihood 0.122	The detection of EBV DNA for the diagnosis of NPC has good sensitivity and specificity and might be helpful for the screening of NPC
1. Treatment strategy guidance of circulating EBV DNA						
2-1 Aids in the treatment outcome prediction and risk grouping						
Qu et al. ¹⁶³³	2020	1	Systematic review and meta-analysis	22 studies, 8128 NPCs	1. OS 2. PFS 3. DMFS	Pre-, mid-, and post-EBV DNA levels have prognostic impact in NPC patients, particularly post-DNA levels

(Continues)

TABLE XXV.2 (Continued)

Study	Year	LOE	Study design	Study groups	Clinical endpoints	Conclusion
Xie et al. ¹⁶³²	2019	1	Systematic review and meta-analysis	40 studies, 27,235 NPCs	OS	<ol style="list-style-type: none"> When cutoff values of 2000, 0, and 0 copies/mL were used for pre-DNA, mid-DNA, and post-DNA, patients with values above these cutoffs were associated with >2.5-fold increased risk of death (all $p < 0.05$) Higher pre-DNA, detectable mid-DNA, and detectable post-DNA levels are significantly correlated with poorer outcomes
Liu et al. ¹⁶³¹	2017	1	Systematic review	16 studies, 7698 NPCs	<ol style="list-style-type: none"> OS PFS DFS RFS DMFS 	High EBV DNA levels indicate poor prognosis and reduced long-term survival in patients with newly diagnosed NPC
Zhang et al. ¹⁶³⁰	2016	1	Systematic review and meta-analysis	23 studies, 10,732 NPCs	OS	<ol style="list-style-type: none"> Pooled HR for OS: pre-DNA 2.78, post-DNA 5.43 High expression levels of EBV DNA predict poor prognosis in NPC
Zhang et al. ¹⁶²⁹	2015	1	Systematic review and meta-analysis	14 studies, 7836 NPCs	<ol style="list-style-type: none"> OS PFS DMFS LRFS 	Pre-DNA, mid-DNA, post-DNA, and EBV DNA clearance rates are prognostic factors for survival in NPC patients
2-2. Supplement to the TNM staging system						
Hui et al. ¹⁶³⁹	2020	2	Prospective cohort	Training set (745 NPCs) Internal validation (340 NPCs) External validation (837 NPCs)	OS	Combining post-DNA levels and TNM staging improved risk stratification in NPC patients
Lee et al. ¹⁶³⁷	2019	3	Prospective cohort	518 NPCs	<ol style="list-style-type: none"> OS PFS DSS 	Combined stage groups revealed better survival prediction compared to the 8th edition of the TNM staging system
Kitpanit et al. ¹⁶³⁸	2019	3	Prospective cohort	205 NPCs	OS	Integration of pre-DNA into the 8th edition of the TNM staging improved outcome prediction, especially for patients who may benefit from treatment intensification
Li et al. ¹⁶⁴⁰	2021	4	Retrospective case series	2354 NPCs (training set 1372, internal validation 672, external validation 310)	PFS	Combined staging system can outperform conventional TNM staging groups for predicting survival rates

(Continues)

3 | The role of HPV in NPC

HPV+ NPC is relatively rare compared to EBV+ NPC in endemic areas, and thus there are few associated studies (Table XXV.3). Wu et al. analyzed HPV status from the SEER database and found that the incidence of HPV-associated NPC patients was 2.3% among 9943 head and

neck SCC patients. They found that HPV infection was not a clinically prognostic marker for NPC patients, although controversial results were noted in some studies.^{1649–1656} In a large study conducted in Southern China, among 1328 NPC patients, there were 91.9% EBV+, 7.7% HPV+, and only 0.6% coinfecting with both viruses. They found that EBV-/HPV+ NPC patients was associated with signifi-

TABLE XXV.2 (Continued)

Study	Year	LOE	Study design	Study groups	Clinical endpoints	Conclusion
Guo et al. ¹⁶³⁶	2019	4	Retrospective case series	979 NPCs	1. OS 2. PFS	Incorporating EBV DNA into staging provided better hazard consistency, hazard discrimination, outcome prediction, and sample size balance than the 8th edition of the TNM staging system
Zhang et al. ¹⁶³⁵	2016	4	Retrospective case series	1467 NPCs	1. OS 2. PFS 3. DMFS 4. LRFS	Pre-DNA is a strong prognostic factor for NPC patients when complemented with TNM staging
Leung et al. ¹⁶³⁴	2006	4	Retrospective case series	376 NPCs	1. DSS 2. DMFS 3. LRFS	Pre-DNA load is an independent prognostic factor to the TNM staging in NPC Combined pre-DNA with staging data defines better risk grouping and improves risk discrimination in early-stage disease
2-3. Adjuvant therapy for postradiation residual EBV DNA patients						
Chan et al. ¹⁶⁴²	2018	2	Prospective randomized trial	216 out of 789 NPCs with detectable post-DNA; 104 out of 216 randomized to adjuvant chemotherapy × six cycles	RFS	1. Adjuvant chemotherapy with cisplatin and gemcitabine did not improve RFS for NPC with detectable post-DNA 2. 5-year RFS rate: 49.3% versus 54.7% ($p = 0.75$)
Twu et al. ¹⁶⁴¹	2014	4	Retrospective case series	85 out of 625 NPCs with detectable post-DNA; adjuvant oral chemotherapy for 1 year: yes/no = 33/52	1. OS 2. Recurrence	1. Adjuvant oral tegafur-uracil can reduce recurrence and improve OS in patients with detectable post-DNA 2. Recurrent rates: 45.5% versus 71.2% ($p = 0.0323$). 3. 5-year OS: 71.6% versus 28.7% ($p < 0.0001$).
2-4. Early prediction of treatment response in recurrent/metastatic and locally advanced patients						
Ma et al. ¹⁶⁴⁵	2018	3	Prospective cohort	58 NPCs (33 recurrent/metastatic, 25 locally advanced)	1. OS 2. PFS 3. PET response	Early PET response (>50% drop in sum of max SUV of target lesions) and EBV DNA clearance (≤ 10 days) predict improved survival and treatment response
Hsu et al. ¹⁶⁴⁴	2012	4	Retrospective case series	73 metastatic NPCs	1. CR 2. OS	1. Plasma EBV DNA clearance rates are significant predictors for metastatic NPC treatment outcomes 2. Half-life of EBV DNA clearance rate ≤ 4 versus >4 days: CR rate 80.0% versus 37.8% ($p = 0.001$); 2-year OS 59.5% versus 24.4% ($p = 0.003$)

(Continues)

cantly better local tumor control and survival compared to EBV+/HPV- NPC patients.¹⁶⁵⁷ Another study conducted in Canada noted that, among 29 HPV-associated NPC cases, mostly were White patients. Furthermore, HPV+ NPC patients have larger primary tumors with greater local

symptom burden but similar outcomes compared with EBV+ NPC patients.¹⁶⁵¹ In Wu et al.'s retrospective study, among 78 NPC patients over 19 years, there were only 12 HPV+ NPC patients. They found that EBV+ NPC patients were younger and less frail than HPV+ NPC patients, and

TABLE XXV.2 (Continued)

Study	Year	LOE	Study design	Study groups	Clinical endpoints	Conclusion
Wang et al. ¹⁶⁴³	2010	4	Retrospective case series	34 recurrent/metastatic NPCs	1. CR 2. OS	1. Clearance rates of plasma EBV DNA during the first month of chemotherapy predict treatment response and survival 2. Half-life of EBV DNA clearance rate ≤ 4 versus > 4 days: CR rate 70.6% versus 11.8% ($p = 0.0017$); 2-year OS 79.4% versus 29.4% ($p = 0.0055$)
2. Screening role of circulating EBV DNA						
Chan et al. ¹⁶⁴⁶	2017	3	Nonrandomized cohort	20,174 participants	PFS Sensitivity 97.1%, specificity 98.6%	1. Circulating EBV DNA useful in screening for early asymptomatic NPC compared to historical cohort (stage I or II 71% vs. 20%, $p < 0.001$) 2. Outcomes were better in participants who were identified by screening than those of the historical cohort (3-year PFS 97% vs. 70%, $p < 0.001$)

Abbreviations: AIC, Akaike information criterion; CR, complete response; mid-DNA, mid-treatment plasma EBV DNA; NPC, nasopharyngeal carcinoma; OS, overall survival; PRFS, progression-free survival; pre-DNA, pretreatment plasma EBV DNA; post-DNA, posttreatment plasma EBV DNA; RFS, relapse-free survival; RPA, recursive partitioning analysis.

no cases showed coinfection. OS was insignificant between the two groups of patients after adjusting for the Karnofsky Performance Scale and age.¹⁶⁵² Further studies are needed to elucidate how HPV infection interplays with EBV and its role in NPC.

Aggregate grade of evidence: C (Level 1: one study; Level 2: one study; Level 4: 11 studies)

4 | Role of surgery in NPC

RT and CRT are the main treatment strategies for patients with primary NPC,¹⁶⁵⁸ whereas surgery is typically considered in patients with local residual or recurrent disease. Recently, endoscopic nasopharyngectomy (ENPG) has become an effective treatment for NPC, demonstrating good survival outcomes and low complication rates compared with re-irradiation and various traditional open surgical treatments, such as the maxillary swing, transpalatal, midface degloving, and transinfratemporal fossa approaches (Table XXV.4).^{5,1659–1661} ENPG is also covered in ICSB 2019 (Section VIII.E) and this section serves as an update.⁵

ENPG can be used to resect radioresistant and/or recurrent tumors directly, thereby avoiding the severe side effects of re-irradiation. However, because of the infiltrative behavior of NPC and the complex structures adjacent to the recurrent tumor, especially with scarring and inflammation following RT, the identification of key anatomical landmarks during ENPG is paramount for

achieving maximal tumor resection as well as for preventing complications such as ICA injury. Meticulous preoperative evaluation and a full understanding of the surgical anatomy are essential to prevent damage to nearby critical neurovascular structures.¹⁶⁶²

The first ENPG was reported in 2005.¹⁶⁶³ In 2013, Castelnovo et al. reported the first classification of ENPGs into three types.¹⁶⁶⁴ In 2020, Liu et al. categorized ENPG into four types based on anatomical structures and the NPC staging system.¹⁶⁶⁵ Both studies reported promising outcomes with the technique. In their study on 410 patients with recurrent NPC, Zou et al. found that ENPG and IMRT were associated with improvements in both OS and distant metastasis-free survival compared with conventional two-dimensional RT in early recurrent disease.¹⁶⁶⁶ Yang et al. conducted the largest meta-analysis involving 23 studies with a combined 792 patients with recurrent NPC, whereupon they revealed that ENPG had comparable and possibly better outcomes than IMRT.¹⁶⁶⁷ Although there have been several studies focusing on ENPG outcomes, only one RCT conducted in China has been carried out to date.¹⁶⁶⁸ The study showed better 3-year OS in the ENPG group than in the IMRT group in patients with resectable locally recurrent NPC as well as better DFS and RFS.¹⁶⁶⁸ Currently available data suggest that ENPG is a promising option for many patients with early-stage local recurrent NPC, with minimal complications. For patients with advanced-stage recurrent NPC, long-term follow-up is needed to evaluate the eventual morbidity from and efficacy of the procedure.

TABLE XXV. 3 Evidence surrounding HPV DNA in NPC.

Study	Year	LOE	Study design	Study groups	Clinical endpoints	Conclusion
Isayeva et al. ¹⁷³⁵	2012	1	Systematic review	154 NPC (47 HPV+)	Prevalence of HPV	Weighted prevalence of HPV DNA detection in 154 NPC patients is 31.1% (95% CI: 20.3%–44.5%)
Tham et al. ¹⁷³⁶	2021	2	Systematic review	1919 NPC (1600 EBV+/HPV–, 141 EBV–/HPV+, 68 EBV+/HPV+, 110 EBV–/HPV–)	Prevalence of EBV and HPV	WHO type I NPC: EBV–/HPV– (56.4%), EBV–/HPV+ (21.5%) WHO type II/III: EBV+/HPV– (87.5%)
Huang et al. ¹⁶⁵¹	2022	4	Retrospective case–control	570 NPC (29 HPV+, 422 EBV+)	1. LRC 2. Distant control 3. OS	HPV neither correlates with nor predicts survival in NPC
Wu et al. ¹⁶⁵²	2022	4	Retrospective case series	78 NPC (43 EBV+, 12 HPV+, 23 EBV–/HPV–)	OS	1. OS time was not significantly different between the EBV+ and HPV+ groups EBV–/HPV– tumors had worst OS 2. Viral status not a significant predictor of OS
Simon et al. ¹⁶⁵³	2020	4	Retrospective case–control	98 NPC (66 EBV+, 18 HPV+, 14 EBV/HPV–)	OS	There was no statistically significant difference in survival between the three groups ($p = 0.61$)
Verma et al. ¹⁶⁵⁴	2020	4	Retrospective case series	343 NPC (205 EBV+, 21 HPV+, 12 viral negative, 105 unknown)	OS	Viral status was not prognostic for OS
Ruuskanen et al. ¹⁷³⁷	2019	4	Retrospective case series	150 NPC (93 EBV+, 21 HPV+, 36 EBV–/HPV–)	1. OS 2. DSS	OS better among patients with EBV+ and HPV+ compared to EBV–/HPV–
Wotman et al. ¹⁶⁵⁵	2019	4	Database study [SEER]	517 NPC (180 HPV+, 337 HPV–)	DSS	No significant difference in DSS between HPV+ and HPV– NPC patients
Verma et al. ¹⁶⁵⁰	2018	4	Database study [NCDB]	956 NPC (308 HPV+, 648 HPV–)	OS	HPV neither correlates with nor predicts survival in NPC
Jiang et al. ¹⁷³⁸	2016	4	Retrospective case series	86 (44 EBV+, 35 EBV–, seven indeterminate; 40 HPV+, 26 HPV–, 20 no tissue sample; 13 EBV+/HPV+)	1. OS 2. PFS 3. LRC	1. p16 overexpression is associated with improved PFS and LRC in patients with EBV-positive NPC 2. p16 expression may complement EBV status in predicting treatment outcomes for NPC patients
Atighechi et al. ¹⁷³⁹	2014	4	Retrospective case series	41 NPC (9 HPV+, 32 HPV–)	1. OS 2. Recurrence	1. HPV type 16 and 18 most common subtypes 2. HPV+ patients had better prognosis and lower recurrence rates
Stenmark et al. ¹⁷⁴⁰	2014	4	Retrospective case series	61 NPC (26 EBV+/HPV–, 18 HPV+/EBV–, 17 EBV–/HPV–)	1. OS 2. PFS 3. LRC	1. High-risk HPV infection may play an etiologic role in the development of nonendemic EBV– NPC 2. Compared with EBV+ NPC, HPV+ and EBV–/HPV– NPC are associated with worse outcomes

(Continues)

TABLE XXV.3 (Continued)

Study	Year	LOE	Study design	Study groups	Clinical endpoints	Conclusion
Huang et al. ¹⁶⁵⁶	2011	4	Retrospective case-control	43 NPC (15 HPV+, 28 HPV-)	Prevalence of HPV	No association between oncogenic HPV and carcinogenesis or prognosis of WHO II and III NPCs in Taiwanese patients

Abbreviations: LRC, local-regional control; NCDB, National Cancer DataBase; OS, overall survival; PFS, progression-free survival; SEER, Surveillance, Epidemiology, and End Results.

Role of nasopharyngectomy for NPC

Aggregate grade of evidence	C (Level 2: two studies; Level 4: 17 studies)
Benefit	ENPG has become an effective treatment for patients with early local recurrent NPC, demonstrating good survival outcomes and low complication rates. It avoids not only the severe side effects caused by re-irradiation but also complications (e.g., functional problems and cosmetic morbidities) that may be encountered during traditional open approaches.
Harm	Positive margins, especially around critical neurovascular structures; risk of ICA injury leading to intraoperative and postoperative hemorrhage; wound infection; injury to surrounding critical neurovascular structures.
Cost	ENPG may have a lower cost than re-irradiation because of the relatively shorter treatment duration and ensuring faster recovery.
Benefits-harm assessment	Balance of benefits and harms.
Value judgments	Current data suggest that ENPG is a promising treatment option for most patients with early-stage local recurrent NPC, with minimal complications. However, only one RCT has been conducted. Although selected patients with advanced-stage recurrent NPC may benefit from ENPG, long-term follow-up is needed to evaluate the eventual morbidity from and efficacy of the procedure.
Policy level	Option.
Intervention	ENPG is a good option for early local recurrent NPC (rT1 and rT2 and select rT3 lesions), with limited complications and promising outcomes. Meticulous preoperative evaluation and a full understanding of the surgical anatomy are important to prevent significant complications such as ICA injury.

5 | Primary radiation therapy of the primary site

NPC is one of the first cancers successfully treated with primary RT (Table XXV.5).¹⁶⁶⁹ Conventional two-dimensional radiotherapy (2DRT) techniques had been used for treatment of NPC since the 1960s until the advent of 3DRT and IMRT. There are many critical structures at risk (SARs) adjacent to tumors of the skull base, especially in locally advanced cases. With 2DRT technique, the radiation tolerance of these structures limits the dose of radiation that can be delivered to the primary tumor without significant toxicity. With 3DRT and IMRT, high-dose RT can be contoured to the tumor, ensuring better delivery of adequate radiation dosage without surpassing the dose limit for SARs. Multiple phase II trials have shown the efficacy of IMRT in local control and reducing toxicities. A large phase III RCT showed better LRC with IMRT compared to 2DRT in T4 and N2 disease, improved OS in N2 and stage III disease, and marginally improved OS in stage IVA disease. Two-dimensional RT is associated with more acute and late toxicities.¹⁶⁷⁰ Two meta-analyses, one including phase II/III RCTs and one including additional nonrandomized cohorts, showed that IMRT has superior OS and PFS with reduced late toxicities compared to 2DRT techniques.^{1671,1672} Therefore, IMRT is strongly recommended in treatment of all stages of NPC both for superior disease control and less toxicity.

Role of IMRT in treatment of NPC

Aggregate grade of evidence	A (Level 1: two studies; Level 2: three studies)
Benefit	IMRT improves OS and LRC in locally advanced NPC and reduces long-term toxicities including xerostomia, trismus, and temporal lobe neuropathy in all stages.
Harm	IMRT has no additional harm compared to conventional 2DRT.

(Continued)

TABLE XXV. 4 Evidence surrounding nasopharyngectomy in nasopharyngeal carcinoma (NPC) treatment.

Study	Year	LOE	Study design	Study groups	Clinical endpoints	Conclusion
Newton et al. ¹⁷⁴¹	2021	2	Systematic review	Review of 66 previously published studies	OS	<ol style="list-style-type: none"> 1. Surgery and re-RT for recurrent NPC have similar long-term survival 2. Surgical approaches to rNPC may offer similar survival while avoiding RT-associated morbidity and mortality.
Liu et al. ¹⁶⁶⁸	2021	2	RCT	Recurrent T1–3 NPC who underwent: (1) ENPG (<i>n</i> = 100) or (2) IMRT (<i>n</i> = 100)	OS	<ol style="list-style-type: none"> 1. ENPG significantly improved 3-year OS compared with IMRT 2. Pharyngeal mucositis: 5% ENPG, 26% IMRT
Zhang et al. ¹⁷⁴²	2021	4	Retrospective case-control	Recurrent T1–2 NPC who underwent: (1) ENPG + LDRT (<i>n</i> = 37) or (2) IMRT (<i>n</i> = 132)	<ol style="list-style-type: none"> 1. Survival 2. QOL 3. Late RT-related sequelae 	<ol style="list-style-type: none"> 1. ENPG + LDRT provided satisfactory survival outcomes, improved QOL, and reduced the incidence of RT-related sequelae 2. Xerostomia: 24.3% 3. ENPG + LDRT, 46.2% IMRT
Thamboo et al. ¹⁷⁴³	2021	4	Retrospective case series	Recurrent T1–2 NPC who underwent ENPG (<i>n</i> = 13)	<ol style="list-style-type: none"> 1. OS 2. LRFS 3. Complication rates 	<ol style="list-style-type: none"> 1. 5-year LRFS and OS were 53.9% and 84.6% 2. Minor complication rate 52.6% 3. Major operative complication rate 0.0% 4. Late complication rate 23.1%
Liu et al. ¹⁶⁶⁵	2021	4	Retrospective case series	Recurrent T1–4 NPC who underwent ENPG (<i>n</i> = 101)	<ol style="list-style-type: none"> 1. OS 2. LRFS 	2-year OS and LRFS were 76.2% and 53.6%, respectively
Li et al. ¹⁷⁴⁴	2021	4	Retrospective case series	Recurrent T1–4 NPC who underwent ENPG (<i>n</i> = 189)	OS	1-, 3-, and 5-year OS rates were 82.2%, 59.5%, and 43.6%, respectively
Wang et al. ¹⁷⁴⁵	2021	4	Retrospective case series	Recurrent T2–3 NPC who underwent ENPG with ICA pretreatment (<i>n</i> = 37)	<ol style="list-style-type: none"> 1. OS 2. PFS 3. LRFS 4. DMFS 	<ol style="list-style-type: none"> 1. 2-year OS, PFS, LRFS, and DMFS were 88.7%, 72.0%, 72.0%, and 97.3%, respectively 2. Postoperative complications: Grade 1–2 16.2%, grade 3–5 13.5%.
Wong et al. ¹⁷⁴⁶	2020	4	Retrospective case series	Recurrent T3–4 NPC who underwent ENPG (<i>n</i> = 12)	<ol style="list-style-type: none"> 1. OS 2. DFS 3. DSS 	<ol style="list-style-type: none"> 1. 5-year OS, DFS, and DSS were 50.0%, 25.0%, and 58.3%, respectively 2. No severe operative complications were reported
Tang et al. ¹⁷⁴⁷	2019	4	Retrospective case series	Recurrent T1–4 NPC who underwent ENPG (<i>n</i> = 55)	<ol style="list-style-type: none"> 1. OS 2. LRFS 	<ol style="list-style-type: none"> 1. 1-year OS and LRFS were 98% and 93%, respectively 2. One (1.8%) patient had ICA injury intraoperatively 3. No major postoperative complications
Liu et al. ¹⁷⁴⁸	2017	4	Retrospective case series	Recurrent T1–4 NPC who underwent ENPG (<i>n</i> = 91)	<ol style="list-style-type: none"> 1. OS 2. DFS 	<ol style="list-style-type: none"> 1. 2-year OS and DFS were 64.8% and 57.5%, respectively 2. 5-year OS and DFS were 38.3% and 30.2%, respectively 3. No serious complications were reported

(Continues)

TABLE XXV. 4 (Continued)

Study	Year	LOE	Study design	Study groups	Clinical endpoints	Conclusion
Vlantis et al. ¹⁷⁴⁹	2017	4	Retrospective case series	Recurrent T1–2 NPC who underwent ENPG (<i>n</i> = 18)	1. OS 2. DFS	1. 2-year OS and DFS were 100% and 90%, respectively 2. Postoperative complication rate was 55.6%
Weng et al. ¹⁷⁵⁰	2017	4	Retrospective case series	Recurrent T1–4 NPC who underwent: (1) ENPG + CRT (<i>n</i> = 36) and (2) CRT (<i>n</i> = 26)	1. OS 2. DFS	ENPG + CRT group had better OS than CRT alone group
Wong et al. ¹⁷⁵¹	2017	4	Retrospective case series	rT3–4 NPC who underwent ENPG (<i>n</i> = 15)	1. OS 2. DFS 3. DSS	1. 2-year OS, DFS, and DSS were 66.7%, 40%, and 73%, respectively 2. No severe operative complications were reported
You et al. ¹⁷⁵²	2015	4	Retrospective case–control	rT1–3 NPC who underwent: (1) ENPG (<i>n</i> = 72) and (2) IMRT (<i>n</i> = 72)	OS	Compared with IMRT, salvage ENPG may be more effective for maximizing survival (77.1% vs. 55.5%) and decreasing complications (12.5% vs. 65.3%).
Zou et al. ¹⁶⁶⁶	2015	4	Retrospective case series	rT1–4 NPC who underwent: (1) ENPG (<i>n</i> = 92), (2) IMRT (<i>n</i> = 218), and (3) 2DRT (<i>n</i> = 100)	1. OS 2. DMFS	ENPG and IMRT are associated with an improved OS and DMFS in patients with recurrent NPC compared to two-dimensional conventional RT in early recurrence
Castelnuovo et al. ¹⁶⁶⁴	2013	4	Retrospective case series	rT1–4 NPC who underwent ENPG	1. OS 2. DFS 3. DSS	1. 5-year OS, DSS, and DFS were 75.1%, 80.9%, and 58.1%, respectively 2. No major complications were reported
Ho et al. ¹⁷⁵³	2012	4	Retrospective case series	rT1–3 NPC who underwent ENPG (<i>n</i> = 13)	1. OS 2. DFS	1. 2-year OS and DFS were 100% and 69.2%, respectively 2. Overall minor complication rate was 52.6% 3. No major complications
Chen et al. ¹⁷⁵⁴	2009	4	Retrospective case series	rT1–3 NPC who underwent ENPG (<i>n</i> = 37)	1. OS 2. LRFS 3. PFS	1. 2-year OS, LRFS, and PFS were 84.2%, 86.3%, and 82.6%, respectively 2. No severe complications were observed
Ko et al. ¹⁷⁵⁵	2009	4	Retrospective case series	rT1–3 NPC who underwent ENPG (<i>n</i> = 28)	1. OS 2. DFS	1. 2-year OS and DFS were 59.4 and 57.6%, respectively 2. Three patients had nasopharynx osteonecrosis and one patient developed hypoglossal nerve dysfunction

Abbreviations: DFS, disease-free survival; DSS, disease-specific survival; ENPG, endoscopic nasopharyngectomy; IMRT, intensity modulated radiation therapy; LDRT, low-dose radiotherapy; LPFS, local progression-free survival; LRC, local-regional control; OS, overall survival; PFS, progression-free survival.

TABLE XXV. 5 Evidence surrounding radiation therapy in NPC treatment.

Study	Year	LOE	Study design	Study groups	Clinical endpoints	Conclusion
Du et al. ¹⁶⁷²	2019	1	Systematic review and meta-analysis	13,304 NPC patients from 10 studies (two RCTs + eight nonrandomized trial) IMRT versus 2DRT	<ol style="list-style-type: none"> 5-year OS 5-year PFS, LRFS, DMFS Toxicities 	<ol style="list-style-type: none"> IMRT was associated with a better 5-year OS, LRFS, and PFS compared to 2DRT group IMRT was associated with significantly lower rate of late xerostomia, trismus, and temporal lobe neuropathy
Co et al. ¹⁶⁷¹	2016	1	Systematic review and meta-analysis	717 patients from three RCTs IMRT versus 2DRT	<ol style="list-style-type: none"> 1-year LRC, DMFS, OS Xerostomia 	<ol style="list-style-type: none"> IMRT showed better yet statistically insignificant results than 2DRT in terms of LRC and regional control However, differences were only observed in T4, N2, and stage III disease Xerostomia was better in IMRT than in conventional 2DRT
Tang et al. ¹⁶⁷⁴	2022	2	Open-label, noninferiority, phase III RCT	446 NPC patients with N0-N1 disease (UICC/AJCC 7th edition) of WHO type II or III IMRT to primary, RP LN, and neck disease IC + CRT or CRT alone in patients with stage II-IVA WNI group: both the upper neck (levels II, III and VA) and lower neck (levels IV and VB) were encompassed by low-dose target volume in the uninvolved neck UNI group: elective irradiation to bilateral upper neck lymphatic areas only in case of neck-node negative disease; WNI to ipsilateral neck and UNI to contralateral neck in case of unilateral neck nodal disease	<ol style="list-style-type: none"> RRFS OS, DMFS Acute and late toxicities 	<ol style="list-style-type: none"> 3-year RRFS was similar in UNI and WNI groups No significant difference between UNI versus WNI group in 3-year OS No statistically significant difference in acute RT-related toxic effect between the groups Incidence of late toxicity was lower in UNI group than WNI group, including hypothyroidism, skin toxicity, dysphagia, and neck tissue damage

(Continues)

TABLE XXV.5 (Continued)

Study	Year	LOE	Study design	Study groups	Clinical endpoints	Conclusion
Lertbutsayanukul et al. ¹⁶⁷⁶	2018	2	Randomized phase II/III study	<p>209 NPC patients treated with CRT to T2–4 or positive nodal disease for maximum seven cycles + adjuvant chemotherapy SEQ-IMRT</p> <ul style="list-style-type: none"> - two plans: 2 Gy × 25 Fr to low-risk PTV, followed by sequential boost (2 Gy × 10 Fr) to high-risk PTV SIB-IMRT - 56 Gy to low-risk PTV and 70 Gy to high-risk PTV, in 33 Fr 	<ol style="list-style-type: none"> 1. Acute and late toxicities 2. 3-year PFS and OS 3. LPFS, RPFS, DMFS 	<ol style="list-style-type: none"> 1. No significant difference in cumulative incidence of grade 3–4 acute or late toxicities between SEQ versus SIB group 2. Significant improved 3-year RPFS in SIB group compared with SEQ group 3. No significant differences in SEQ versus SIB group for complete response rate, 3-year PFS, and 3-year OS, PFS, LPFS, and DMFS
Peng et al. ¹⁶⁷⁰	2012	2	Prospective RCT	616 NPC patients IMRT versus 2DRT Chemotherapy for stage III and IV if not contraindicated	<ol style="list-style-type: none"> 1. 5-year LRC, OS 2. Acute and late toxicity 	<ol style="list-style-type: none"> 1. IMRT group had higher LRC rate compared with 2DRT, yet the difference was only significant in T4 after disease stage stratification 2. IMRT group had higher RC rate compared with 2DRT and the difference was only significant in N2 disease 3. IMRT group had higher OS rate compared with 2DRT and the difference was significant in stage III and N2 disease 4. More frequent acute toxicities were observed in 2DRT group (acute hearing loss, xerostomia) and also for late toxicities (cranial nerve palsy, trismus, neck fibrosis, xerostomia, and hearing loss)
Lee et al. ¹⁶⁷⁸	2021	2	Systematic review	369 patients in nine retrospective studies Comparison of proton versus photon therapy, concurrent chemotherapy used for all studies	<ol style="list-style-type: none"> 1. 2-year LRFS, PFS, and OS 2. Acute and late toxicities 	<ol style="list-style-type: none"> 1. Proton therapy had similar 2-year LRFS, PFS, and OS compared with IMRT 2. Significantly lower mucositis and feeding tube rates in proton therapy group versus IMRT 3. All other acute and late effects were improved with proton therapy, but not statistically significant

(Continues)

TABLE XXV.5 (Continued)

Study	Year	LOE	Study design	Study groups	Clinical endpoints	Conclusion
Huang et al. ¹⁶⁷³	2018	2	Systemic review and meta-analysis	2521 NPC patients in nine comparative studies (one RCT + eight retrospective cohort) ILNSI versus ILNPI IMRT in three studies, 2DRT in two studies, 2DRT or IMRT or 3DRT in four studies	1. 3-year OS 2. RRFS, DFS, DMFS, and lymph node recurrence	1. No significant difference between ILNSI and ILNPI group in 3-year OS, RRFS, DFS, and DMFS 2. Ipsilateral lymph node recurrence rates are similar in ILNSI and ILNPI groups
Nishimura et al. ¹⁶⁷⁷	2020	3	Phase II single arm study	75 NPC patients (Stage II-IV) treated with adaptive IMRT and concurrent chemotherapy	1. 3-year OS 2. 3-year PFS	1. 3-year OS 88% 2. 3-year PFS 71% 3. 15 (20%) developed grade 3 late toxicities 4. Grade 2 xerostomia 26%, 12%, and 9% at 1, 2, and 3 years, respectively

Abbreviations: CRT, concurrent chemoradiation; CTV, clinical target volume; DMFS, distant metastasis-free survival; Fr, fractions; IC, induction chemotherapy; ILNSI, ipsilateral lower neck sparing irradiation; ILPSI, ipsilateral lower neck prophylactic irradiation; LPFS, local progression-free survival; NPC, nasopharyngeal carcinoma; OS, overall survival; PFS, progression-free survival; PTV, planning target volume; RP, retropharyngeal; RPFS, regional progression-free survival; RRFS, regional recurrence-free survival; SEQ, sequential boost; SIB, simultaneous integrated boost; UICC, Union for International Cancer Control; UNI, upper neck irradiation; WNI, whole-neck irradiation.

Cost	IMRT significantly increases the time needed for radiotherapy planning and the direct cost of RT. However, reduction in late toxicities translates to long-term cost savings, which would be very hard to measure. Exact cost comparison analyses accounting for those would be very difficult to perform.
Benefits-harm assessment	Preponderance of benefits over harms.
Value judgments	Patients should be treated with IMRT whenever possible.
Policy level	Strong recommendation.
Intervention	IMRT is the current standard of care for primary radiation treatment of NPC.

6 | Elective radiation treatment of the NO neck

NPC has high propensity for bilateral cervical lymph node metastasis that can be clinically apparent or occult. Traditionally, bilateral upper and lower cervical lymphatics

have been included in the radiation field regardless of the nodal stage of the disease. This approach may contribute to increased soft tissue fibrosis of the neck and dysphagia. Several retrospective nonrandomized cohort studies were performed to determine if the ipsilateral lower neck could be omitted in the radiation planning in patients with clinically node-negative NPC. A meta-analysis in 2018 showed that there was no difference in 3-year OS, regional relapse-free survival, and DMFS between ipsilateral lower neck sparing irradiation versus ipsilateral lower neck prophylactic irradiation and it was found that both groups had similar nodal recurrence rate. However, the quality of the studies included were variable and there was a large heterogeneity in the treatment protocol between the included studies.¹⁶⁷³ Objective measurement of long-term swallowing function and neck fibrosis is also missing in the studies. More recently, a large RCT showed that with careful patient selection using both MRI and PET/CT, reducing the field of radiation in the contralateral lower neck resulted in improved QOL but not inferior survival outcomes.¹⁶⁷⁴ Further clinical trials are in process to confirm these results.

Elective treatment of the NO neck and avoidance of radiating lower neck lymphatics in NPC

Aggregate grade of evidence	B (Level 1: one study; Level 2: one study)
Benefit	Omitting the uninvolved lower neck lymphatics may reduce the short- and long-term toxicities of RT without jeopardizing survival.
Harm	Potential increase in nodal failure and worsening of survival outcomes.
Cost	May need multiple investigations including MRI and PET/CT to confirm the extent of nodal metastasis. No direct cost analysis available.
Benefits-harm assessment	Balance of benefits and harms
Value judgments	Patients should be counseled about the extent and field of neck radiation as it relates both to disease control and toxicity/side effects. Potential benefit in toxicity reduction may be negated by increase in treatment failures.
Policy level	Option.
Intervention	Patients may be able to avoid RT to the uninvolved lower neck lymphatics if MRI and PET imaging modalities confirmed the absence of cervical nodal metastasis or nodal disease limited to one side of the neck.

7 | Adaptive radiotherapy

Adaptive radiotherapy is based on the principle of adjusting radiation as treatment progresses, to account for changes in tumor volume and patient anatomy that occur during treatment. Retrospective studies have demonstrated dosimetric and clinical advantages of adaptive radiotherapy in NPC, including reduced tumor volumes, better sparing of SARs, and improved patient-reported outcomes.¹⁶⁷⁵ There are few prospective studies on pre-planned adaptive radiotherapy for NPC. A phase III RCT compared sequential IMRT to IMRT with simultaneous integrated boost (SIB) to the high-risk and low-risk planning target volumes. The trial showed similar 3-year OS (86.3% vs. 83.8%; $p = 0.938$), 3-year PFS (72.7% vs. 73.4%; $p = 0.488$), and grade 3/4 acute toxicities. However, there was a trend toward significantly higher late toxicities with SIB (12.1% vs. 4.9%; $p = 0.062$).¹⁶⁷⁶ More recently, a Japanese phase II single-arm study of 75 patients of stage II-IVB NPC treated with an adaptive IMRT plan after 46 Gy/23 fractions for a total of 70 Gy/35 fractions demonstrated a 3-year OS of 88% and PFS of 71%.¹⁶⁷⁷ Fifteen (20%)

developed grade 3 late toxicities, while grade 2 xerostomia was noted in 26%, 12%, and 9% at 1, 2, and 3 years after starting IMRT, respectively. Prospective randomized studies on adaptive radiotherapy aiming at identification of patient, dosimetric, radiomics, and biological triggers of adaptive radiotherapy are warranted to determine the selection criteria for adaptive radiotherapy.

Role of adaptive radiation therapy in treatment of NPC

Aggregate grade of evidence	C (Level 2: one study; Level 3: one study)
Benefit	Adjustment of the radiation field to account for change in tumor size and patient anatomy, theoretically improving tumor contouring and reducing unnecessary radiation to surrounding critical structures.
Harm	Increased cost. Increased complexity of treatment delivery. Potential undertreatment of tumor.
Cost	Increased cost due to mid-treatment imaging and increased labor cost due to the need for replanning. No economic studies available.
Benefits-harm assessment	Balance of benefits and harms.
Value judgments	Promising concept but not enough data to conclude. Potential benefit in reducing marginal miss and unnecessary radiation to critical structures. Prospective trials should be designed to identify patient groups and disease factors that would benefit from adaptive radiotherapy.
Policy level	Option.
Intervention	Adaptive radiotherapy for NPC may have an emerging role given its ability to improve QOL, though this must be balanced with the risk of undertreatment.

8 | Role of proton therapy

Newer radiation modalities like proton or carbon ion therapy have a theoretical advantage in treating NPC especially in locally advanced tumors where the tumor is close to critical structures like brainstem or optic chiasm. However, at the time of writing, proton or carbon ion therapy is still not widely available and no major phase III trials have been conducted to compare the efficacy of proton therapy to standard IMRT. A meta-analysis on the available retrospective studies and phase II trials on the use of proton and carbon ion therapy for treatment of NPC showed no difference in 2-year survival outcome but a significantly lower rate of tube feeding and mucositis.¹⁶⁷⁸ Proton therapy has nonstatistically significant improvement in acute

and late effects of RT. Further large-scale phase III trials are required to define the role of proton therapy in NPC treatment.

Role of proton therapy in treatment of NPC

Aggregate grade of evidence	C (Level 2: one study)
Benefit	Proton therapy has improved radiation dose falloff, potentially reducing the dosage to normal tissue adjacent to the tumor.
Harm	Potential risk of marginal miss as the radiation fall off is sharp. Potential “hot spots” resulting in areas of overtreatment.
Cost	Proton therapy is significantly more expensive than IMRT and is not widely available.
Benefits-harm assessment	Balance of benefits and harms.
Value judgments	Not enough data to conclude. Patient groups that would benefit from proton radiotherapy have not been well defined. Cost may decrease in the future with increased availability of proton treatment facilities. Large-scale phase III trials with economic analysis are required to define the role of proton radiotherapy in the treatment of NPC.
Policy level	Option.
Intervention	Proton therapy may be considered as primary modality for treatment of NPC at available facilities for the potential benefits of sparing critical SARs.

9 | Role of concurrent chemoradiation therapy

The landmark Intergroup-0099 trial in 1999 first established the benefit of adding chemotherapy during radiotherapy to improve disease control for NPC.¹⁶⁷⁹ Since then, multiple large RCTs have confirmed the benefit of concurrent CRT. The meta-analysis from the NPC-MAC group summarized the benefit of CRT (Table XXV.6).¹⁶⁵⁸ CRT improves all survival measures including PFS, LRC, distant control, and cancer mortality. The main agent for CRT is cisplatin, usually administered as a 30–40 mg/m² weekly or 80–100 mg/m² every 3 weeks. Most trials on CRT included advanced-stage III and IV cancers with a few studies also including T2N1 stage II cancers. A large RCT with T1-2N1M0 or T2N0M0 stage II NPC patients, randomized to CRT with weekly cisplatin versus RT alone, showed significant benefit of CRT in OS, PFS, and DMFS at 5¹⁶⁸⁰ and 10 years.¹⁶⁸¹ It is unclear whether patients with T2N0

(stage II) cancers would still benefit from the addition of chemotherapy in the era of IMRT. A meta-analysis in 2018 showed no added benefit of concurrent chemotherapy in stage II NPC when treated with IMRT.¹⁶⁸² A recent phase III RCT showed that for small-volume T2N1 and T3N0 disease, concurrent chemotherapy can be omitted when patients are treated with IMRT.¹⁶⁸³

When comparing the different dosing regimen of cisplatin, a meta-analysis showed that there is minimal difference in survival between a weekly regimen and 3-week regimen, but the toxicity profiles are different.¹⁶⁸⁴ The weekly regimen has less nausea and vomiting and can be administered in a day-chemotherapy clinic setting. However, the 3-week regimen has less marrow suppression and anemia. There was no severe nephrotoxicity (grade 3–4) noted in both regimes and there was no significant difference in the occurrence of mild nephrotoxicity.

EGFR monoclonal antibodies such as cetuximab have been used as adjunct treatment for head and neck SCC. The addition of anti-EGFR antibodies with or without concurrent chemotherapy during RT has only been studied in small-scale cohort studies or retrospective studies. There are no phase III RCTs studying the effect of anti-EGFR when administered during RT. A large retrospective case-controlled study showed no difference in DFS, locoregional failure/recurrence-free survival (LRFS), DMFS, and OS in the anti-EGFR + RT group versus CRT group.¹⁶⁸⁵ Therefore, EGFR antibodies could be considered as an alternative treatment to cisplatin for patients with poor cisplatin tolerance based on this study. A meta-analysis consisted of four cohorts and one case-controlled study comparing CRT versus CRT + cetuximab showed no difference in OS, while there was benefit in DMFS, LRFS, and DFS. However, there were more grade 3 and 4 skin rash, mucositis, and dermatitis in the group treated with additional cetuximab. Another meta-analysis on 12 small cohorts also showed no survival benefits for addition of anti-EGFR to CRT.¹⁶⁸⁶ Therefore, the addition of cetuximab during CRT is not recommended.

Role of concurrent chemoradiation therapy in treatment of advanced-stage NPC

Aggregate grade of evidence	A (Level 1: one meta-analysis of 4800 patients in 19 trials)
Benefit	The addition of concurrent chemotherapy to radiation in advanced-stage NPC improves OS (HR 0.79), and absolute increase in OS at 5 years is 6.3%.
Harm	Increased acute toxicities with CRT.

(Continued)

TABLE XXV. 6 Evidence surrounding concurrent chemoradiation in NPC treatment.

Study	Year	LOE	Study design	Study groups	Clinical endpoints	Conclusion
Liu et al. ¹⁶⁸²	2018	1	Meta-analysis	1302 patients with stage II NPC in seven studies IMRT alone versus IMRT plus concurrent chemotherapy	1. OS 2. PFS, DMFS, and LRFS	1. No significant survival benefit in CRT versus RT alone in OS, PFS, DMFS, or LRFS 2. CRT significantly increases the risk of acute grade 3–4 leukopenia compared with RT alone
Baujat et al. ¹⁷⁵⁶ , Blanchard et al. ¹⁶⁵⁸	2006, update 2015	1	Meta-analysis	4806 patients from 19 trials (1753 patients from eight trials in prior meta-analysis) RT versus CRT regimens, with focus on role of chemotherapy	1. OS 2. PFS 3. Event-free survival	1. Addition of chemotherapy to RT significantly improved OS 2. Interaction between treatment effect on OS and the timing of chemotherapy was significant, in favor of CRT plus adjuvant chemotherapy and CRT without adjuvant chemotherapy and suggested that these two schedules are very close in terms of benefit 3. Chemotherapy was not associated with increase in noncancer mortality 4. CRT plus adjuvant chemotherapy was associated with the highest frequency of acute toxicities
Tang et al. ¹⁶⁸⁴	2021	2	Systematic review with pooled analysis	1515 patients from six studies Weekly versus triweekly cisplatin dosing	1. 5-year OS 2. 5-year FFS, DMFS, and LRFS 3. Toxicities	1. No significant difference between weekly versus triweekly groups in terms of 5-year OS, FFS, DMFS, and LRFS 2. Significantly higher incidence of anemia and lower incidence of vomiting in weekly group versus triweekly group 3. Cisplatin 30 mg/m ² with at least six cycles could be a more feasible concurrent strategy than 40 mg/m ² /week 4. Both cisplatin 80 mg/m ² and 100 mg/m ² CRT have highly treatment compliance in triweekly regimens and with no obvious differences in survival responses
Wang et al. ¹⁷⁵⁷	2019	2	Meta-analysis	1744 patients of stage II–IVb NPC in five retrospective studies Cisplatin-based CRT with or without cetuximab	1. OS 2. DMFS, LRFS and DFS 3. Adverse events	1. CTX + CRT group significantly improved 3-year DFS and DMFS compared with CRT group 2. No significant improvement in OS and LRFS 3. CTX + CRT group was associated with more grade 3–4 skin rash, mucositis, and dermatitis, and no significant difference in weight loss, hematological, and gastrointestinal adverse events

(Continues)

TABLE XXV. 6 (Continued)

Study	Year	LOE	Study design	Study groups	Clinical endpoints	Conclusion
Yuan et al. ¹⁶⁸⁶	2015	2	Meta-analysis	821 patients in 12 cohorts Conventional treatment (RT or CRT) vs combination treatment (adding anti-EGFR monoclonal antibodies to conventional treatment)	1. CR rate for primary tumor and metastatic lymph nodes 2. DMFS	1. Combination treatment improved the CR rate of primary NPC and metastatic lymph nodes, also 1-year DMFS rate 2. No significant difference in 2- and 3-year DMFS rates
Chen et al. ¹⁶⁸⁷ et al. ¹⁶⁸¹	2011, upda 2019	2	RCT	230 patients with stage II (T1-2N1M0 or T2N0M0) NPC (Chinese 1992 staging system) of WHO type II/III NPC RT versus CRT	1. OS 2. PFS, DMFS and LRFS	1. CRT group had significantly improved outcome for stage II NPC compared with RT group in terms of 5-year OS, PFS, and DMFS 2. CRT group significantly improved 10-year OS, PFS, DSS, and DMFS compared with RT group 3. No significant difference in 5- and 10-year LRFS rate for CRT versus RT groups 4. Survival benefit of chemotherapy mainly reflected in T2N1 population after reclassifying the patients in AJCC 7th edition, but did not show superiority in T1N1 and T2N0 patients 5. CRT arm experienced significantly more acute grade 3–4 toxic effects than in RT group, and the rate of late toxic effects did not increase statistically significantly in both 5 and 10 years
You et al. ¹⁶⁸⁵	2017	3*	Retrospective case-control study	1837 patients with stage II–IVb NPC, 3:1 matched cohort for cisplatin + IMRT versus (CTX)/NTZ + IMRT	1. 3-year DFS 2. 3-year OS, PFS, LRFS, and DMFS	1. No difference in DFS between CTX/NTZ group and cisplatin group 2. No difference in 3-year LRFS, DMFS, and OS 3. Significantly increased hematologic toxicities and gastrointestinal reactions were observed in the cisplatin group 4. Increased rate of CTX related-skin reaction and mucositis was observed in the CTX group

Abbreviations: CR, complete response; CTX, cetuximab; DMFS, distant metastasis-free survival; LRFS, locoregional failure/recurrence-free survival; NTZ, nimotuzumab; NPC, nasopharyngeal carcinoma; OS, overall survival; PFS, progression-free survival; RRFS, regional recurrence-free survival.

*Upgraded given large sample size.

Cost	Addition of chemotherapy incurs increase in treatment cost. Cost comparison analyses have not been undertaken.
Benefits-harm assessment	Preponderance of benefits over harms.
Value judgments	Addition of concurrent chemotherapy is justified in advanced-stage NPC, unless patient has reduced performance status.
Policy level	Strong recommendation.
Intervention	Concurrent chemotherapy with cisplatin is recommended for advanced-stage NPC. There is no difference in survival outcomes for weekly cisplatin regimen versus every 3 weeks dosing.

Role of concurrent chemoradiation therapy in treatment of early-stage NPC

Aggregate grade of evidence	A (Level 1: two studies; Level 2: one study)
Benefit	Addition of concurrent chemotherapy during RT improves survival in advanced-stage NPC, but the benefit is less clear in earlier stage disease.
Harm	Addition of concurrent chemotherapy significantly increases the risk of acute grade 3–4 neutropenia.
Cost	Addition of chemotherapy increases treatment cost. Cost comparison analyses have not been undertaken.
Benefits-harm assessment	Preponderance of harms over benefits.
Value judgments	Except for T2N1 disease with bulky lymph node metastasis, addition of chemotherapy may not improve survival especially for patients receiving IMRT. Routine CRT is not routinely recommended in stage II NPC as it is associated with increased toxicity with unclear survival benefits.
Policy level	Recommendation against
Intervention	CRT with cisplatin should only be considered in stage II patients with bulky nodal disease.

Role of anti-EGFR in treatment of NPC

Aggregate grade of evidence	B (Level 2: two studies; Level 3: one study)
Benefit	Addition of anti-EGFR to RT may be considered in patients who are not eligible for platinum-based chemotherapy. Concurrent anti-EGFR therapy was reported to have similar survival outcomes as CRT in one retrospective cohort study.

(Continued)

Harm	Additional toxicities from anti-EGFR especially in addition to CRT. The true effect on oncological control is unclear.
Cost	Cost comparison analyses have not been undertaken.
Benefits-harm assessment	Balance of benefits and harms.
Value judgments	Routine use of anti-EGFR with radiation is not advised as its efficacy has not been assessed in prospective randomized controlled trials.
Policy level	Option.
Intervention	Concurrent anti-EGFR treatment with RT could be considered only in advanced-stage NPC patients who have contraindications for concurrent cisplatin chemotherapy. Addition of anti-EGFR to CRT is not advisable as there is no evidence to support survival benefit and there is increased toxicity.

10 | Role of induction/neoadjuvant chemotherapy

Induction (neoadjuvant) chemotherapy (IC) has been used in treating locoregionally advanced head and neck cancer since early 2000s. Multiple trials of IC with conventional RT and before the era of CRT, 3DCRT, and IMRT had been performed and had shown some benefits in survival or local control in NPC (Table XXV.7). However, with the advent of CRT and IMRT, the role of IC needs to be redefined. Theoretically, there are two benefits of IC. In patients with advanced nodal disease, IC can target occult distant metastases. For advanced local disease, especially disease with significant intracranial extension, IC can shrink the tumor, allowing the radiation oncologist to plan RT with adequate tumor coverage while protecting critical SARs.

A phase III RCT in 2016 demonstrated the benefit of cisplatin, fluorouracil, and docetaxel (TPF) IC in addition to CRT with IMRT in OS and failure-free survival (FFS).^{1687,1688} Another RCT using mitomycin, epirubicin, cisplatin, and 5-FU or leucovorin (MEPFL) as IC agents followed by CRT showed improved 5-year DFS in the IC arm.¹⁶⁸⁹ The above two studies used three or more agents as IC, which has increased toxicities. A phase III RCT comparing IC with TPF versus cisplatin and 5-fluorouracil (PF) showed similar survival benefits, with omission of docetaxel that in the TPF group was responsible for increased grade 3–4 toxicities to the hematological system.¹⁶⁹⁰ More recently, Zhang et al. reported the results of a large phase III RCT with stage 3 and 4 NPC, comparing IC using gemcitabine (G) 1 g/m² on day 1 and day 8 + cisplatin (P)

TABLE XXV. 7 Evidence surrounding induction chemotherapy in NPC treatment.

Study	Year	LOE	Study design	Study groups	Clinical endpoints	Conclusion
Liu et al. ¹⁶⁹²	2022	1	Network meta-analysis	2496 patients from seven RCTs who received IC + CRT	<ol style="list-style-type: none"> OS LRFS, DMFS, CR Grade 3 or 4 AE 	<ol style="list-style-type: none"> IC + CRT improved OS, LRRFS, and DMFS, and had a trend toward better CR rates compared with CRT group, but with more grade 3–4 AEs GP group had the most favorable OS benefit and longer DMFS and manageable AEs TPF provided the first exact probability of efficacy in LRFS, ranking second in OS, and with highest rates of grade 3 or above AEs
Yang et al. ¹⁶⁹³	2021	2	Phase III RCT	228 patients with stage III to IVB (except T3N0) NPC IC + CRT vs CRT alone	<ol style="list-style-type: none"> EORTC QLQ-C30 EORTC QLQ-H&N35 	<ol style="list-style-type: none"> IC + CRT group seemed to have better long-term QOL outcomes compared with CRT alone Subgroup analysis showed the better QOL outcomes are significant in 2DRT group
Jin et al. ¹⁶⁹⁰	2019	2	Multicenter open-label randomized noninferiority trial	276 patients with stage III or IV NPC (AJCC 2009) of WHO types II/III TPF + CRT versus PF + CRT	<ol style="list-style-type: none"> PFS LC, OS, AEs 	<ol style="list-style-type: none"> No significant difference in OS or PFS between TPF versus PF groups Increased frequencies of grade 3 or 4 neutropenia, anemia, and thrombocytopenia in TPF group versus PF group
Sun et al. ¹⁶⁸⁷ et al. ¹⁷⁵⁸	2016, upda 2019	2	Open-label, phase III, multicenter RCT	480 patients with stage III-IVB (except T3-4N0) NPC from 10 institutions IC + CRT versus CRT alone	<ol style="list-style-type: none"> FFS OS, DMFS, LRFS, and response rates Toxicities 	<ol style="list-style-type: none"> Significant increase in 5-year OS in IC + CRT group than in the CRT group Significant increase in 5-year FFS in IC + CRT group versus CRT alone group, DMFS, and LRFS High complete response rate in 16 weeks after the end of RT was observed in both groups with no significant difference FFS benefits were primarily observed in patients with N1 disease, stage IVA, pretreatment LDH \geq 170 U/l, or pretreatment plasma EBV DNA \geq 6000 copies/mL Significantly higher rate of grade 3 or 4 AEs during the entire treatment course in IC + CRT group versus CRT alone group; no significant difference in late toxicities between groups

(Continues)

TABLE XXV.7 (Continued)

Study	Year	LOE	Study design	Study groups	Clinical endpoints	Conclusion
Zhang et al. ¹⁶⁹¹	2019	2	Multicenter phase III RCT	480 patients with stage III to IVB NPC of WHO type II or III IC + CRT versus CRT alone	1. 3-year RFS 2. OS, DRFS, LRRFS	1. IC + CRT group had significantly improved 3-year RFS and OS compared with CRT alone group 2. IC + CRT had better 3-year DRFS, but not LRFS, than CRT alone group
Hong et al. ¹⁶⁸⁹	2018	2	Phase III RCT (TCOG 1303)	479 patients with stage IVA or IVB (AJCC 5th edition) NPC from 11 institutions IC + CRT versus CRT alone	1. 5-year DFS 2. CR and PR 3. DFFS and OS	1. Significantly higher DFS in IC + CRT arm than in CRT arm after stratifying for N3b disease and LDH; no significant difference in DMFS and OS 2. IC + CRT arm had significantly higher rate of grade 3 or 4 toxicities 3. The overall response and CR rate were higher in ICRT arm

Abbreviations: AE, adverse event; CR, complete response; DMFS, distant metastasis-free survival; EORTC-QLQ-C30, European Organization for Research and Treatment of Cancer Core QOL Questionnaire; EORTC-QLQ-H&N35, European Organization for Research and Treatment of Cancer Quality of Life Questionnaire in Head and Neck Cancer; FFS, failure-free survival; IC, induction chemotherapy; LRFS, locoregional failure/recurrence-free survival; NPC, nasopharyngeal carcinoma; OS, overall survival; PF, cisplatin, 5-fluorouracil; PFS, progression-free survival; PR, partial response; TPF, docetaxel, cisplatin, 5-fluorouracil.

80 mg/m² on day 1, every 3 weeks for three cycles followed by CRT with every 3-week cisplatin versus CRT with 3 weekly cisplatin alone. The results showed that IC + CRT resulted in improved OS, RFS, and DMFS but not LRFS at 3 years after treatment. The HR for OS in the IC + CRT group is 0.43.¹⁶⁹¹ A network meta-analysis comparing different IC regimens showed that gemcitabine and cisplatin (GP) combination IC has the greatest benefit in OS with manageable toxicities. TPF came second in terms of improvement in OS and highest in terms of LRFS but also had the highest rate of grade 3 and 4 adverse effects.¹⁶⁹² A unique RCT evaluating the QOL of IC + CRT versus CRT alone found that the IC arm seems to have superior long-term QOL in both the global scores and specific head and neck QOL scores, presumably due to the lower dose to critical normal structures spared by IC. The study, however, did not compare the acute toxicities in the IC + CRT group versus the CRT alone group.¹⁶⁹³

Role of induction chemotherapy in treatment of NPC

Aggregate grade of evidence	A (Level 1: one study; Level 2: five studies)
Benefit	Induction chemotherapy improves most survival parameters, with GP for three cycles having the best OS followed by TPF.

(Continued)

Harm	Use of IC increases grade 3 and 4 adverse events with TPF having the highest number of adverse events. However, long-term QOL may be similar or even better than CRT alone.
Cost	Cost comparison analyses have not been undertaken.
Benefits-harm assessment	Preponderance of benefits over harms.
Value judgments	For patients with high performance status and minimal co-morbidity, IC would improve the survival. However, IC increases the toxicity of treatment and may not be tolerated by patients with less-than-optimal performance status or comorbidities. Nevertheless, IC with GC regimen has survival benefits that justify the increased cost and toxicity during treatment.
Policy level	Strong recommendation.
Intervention	IC with GP or TPF, for three cycles before definitive CRT, should be considered for advanced-stage NPC (stage III-IVB, excluding T3N0) in patients who can tolerate the treatment.

11 | Role of adjuvant chemotherapy

In the modern era, the majority of NPC failures are distant failures as IMRT and CRT provide excellent LRC.

TABLE XXV. 8 Evidence surrounding adjuvant chemotherapy in NPC treatment.

Study	Year	LOE	Study design	Study groups	Clinical endpoints	Conclusion
Ribassin-Majed et al. ¹⁶⁹⁶	2017	1	Network meta-analysis	5144 patients from 20 trials (91% are stage III/IV) RT alone versus IC + RT versus RT + AC versus IC + RT + AC versus CRT versus IC + CRT versus CRT + AC	1. 5-year OS 2. PFS, LRC and DMFS 3. Severe acute toxicity	1. CRT + AC, CRT, and IC + CRT had highest effect on OS 2. Addition of AC to CRT ranked better than CRT alone but only PFS was statistically significant. 3. No statistically significant difference between IC + CRT and CRT + AC in all parameters 4. CRT + AC and RT + AC are the most toxic regimens, potential toxicity of AC
Chen et al. ¹⁶⁹⁵	2015	1	Network meta-analysis	2144 patients in eight studies RT versus CRT with or without AC	1. OS 2. LRFS, DMFS 3. Severe acute toxicity (\geq grade 3)	1. CRT + AC and CRT were both significantly better than RT alone in terms of OS and DMFS 2. Ranking probabilities showed CRT + AC was ranked superior to CRT for OS, LRFS, and DMFS, yet no significant differences were found between the two for all outcomes 3. Severe adverse events occurred more often following CRT compared with RT alone 4. No significant differences of severe adverse event existed between the CRT + AC and CRT arms in the initial phase
Yan et al. ¹⁶⁹⁷	2015	1	Network meta-analysis	5576 patients with stage III/IV, nonmetastatic NPC, in 25 RCTs	1. OS 2. Grade 3 and above adverse events	1. AC does not appear to improve survival following CRT 2. Number and breadth of adverse events are considerably greater in patients who received chemotherapy
Chen et al. ¹⁶⁹⁸	2021	2	Phase III RCT	406 patients with stage III/IVA NPC (excluding T3-4N0 and T3N1 disease) CRT with or without IC + AC	1. 3-year FFS 2. 3-year OS, DMFS, and LRFS 3. Safety and QOL	1. 3-year FFS was significantly higher in AC arm than observation arm 2. 3-year OS, DMFS, and LRFS were significantly higher in AC arm than observation group 3. Benefit from metronomic capecitabine was observed irrespective of receipt of induction chemotherapy 4. Grade 3 adverse events in 17% in AC group and 6% observation arm 5. No meaningful deterioration of QOL associated with AC arm

(Continues)

Adjuvant chemotherapy (AC) was proposed as an attempt to curb distant failures in advanced-stage nonmetastatic NPC (stage III–IVB) (Table XXV.8). Traditionally, cisplatin and its derivatives were the drug of choice. However, most

patients are heavily exposed to platinum agents during CRT treatment and potentially during IC as well. This limits the tolerability of additional adjuvant platinum-based chemotherapy. A large phase III RCT comparing

TABLE XXV. 8 (Continued)

Study	Year	LOE	Study design	Study groups	Clinical endpoints	Conclusion
Chen et al. ¹⁶⁹⁴	2012	2	Phase III RCT	408 patients with stage III/IV NPC (except T3-4N0) CRT versus CRT + AC	1. 2-year FFS 2. 2-year OS, DMFS, and LRFS	1. 2-year FFS 86% in CRT + AC versus 84% in CRT 2. 2-year OS 94% in CRT + AC versus 92% in CRT 3. 2-year DMFS 88% in CRT + AC versus 86% in CRT 4. 2-year LRFS 98% in CRT+ AC versus 95% in CRT 5. All not statistically significantly different

Abbreviations: AC, adjuvant chemotherapy; CRT, chemoradiation; DMFS, distant metastasis-free survival; FFS, failure-free survival; IC, induction chemotherapy; LRFS, locoregional failure/recurrence-free survival; NPC, nasopharyngeal carcinoma; OS, overall survival; PFS, progression-free survival; PR, partial response; RT, radiation therapy.

CRT + AC with CRT alone showed no improvement in FFS at 2 years.¹⁶⁹⁴ The AC regimen studied consisted of 80 mg/m² adjuvant cisplatin and 800 mg/m² per day fluorouracil for 120 h every 4 weeks for three cycles. Other agents have also been studied in prospective trials and therefore comparing the use of various agents in different stages of disease is difficult. The use of network meta-analysis partly solves this problem. Most network meta-analysis failed to show any improvement in survival with AC.^{1695–1697} A recent phase III RCT using oral chemotherapy capecitabine for 1 year (oral metronomic capecitabine 650 mg/m² body surface area twice daily or 1 year) did show improvement in OS and both locoregional and DMFS.¹⁶⁹⁸ The other advantage of the oral drug is the tolerability and minimal deterioration in QOL during treatment. Further studies are needed to confirm the benefits of this treatment approach.

Role of adjuvant chemotherapy in treatment of NPC

Aggregate grade of evidence	A (Level 1: three studies; Level 2: two studies)
Benefit	Adjuvant chemotherapy with oral metronomic capecitabine 650 mg/m ² body surface area twice daily for 1 year showed improvement in OS, LRFS, and DMFS at 3 years.
Harm	Network meta-analysis showed no benefit of AC with cisplatin agents. Severe toxicities with adjuvant cisplatin chemotherapy due to prior treatment with platinum-based regimen.
Cost	Cost comparison analyses have not been undertaken.

(Continued)

Benefits-harm assessment

Balance of benefits and harms.

Value judgments

AC with oral capecitabine may be beneficial but need to await further clinical trials to confirm. Cisplatin-based AC does not show any benefit across multiple trials. For these reasons, routine AC with cisplatin agents is not recommended as there is potential for severe toxicities and minimal survival benefits.

Policy level

Option.

Intervention

Adjuvant chemotherapy with oral capecitabine can be considered in advanced-stage NPC. Consider recruitment of patients with advanced-stage NPC that have completed definitive CRT to clinical trials for adjuvant chemotherapy with newer agents.

12 | Treatment for metastatic disease

Systemic dissemination is one of the major reasons for treatment failure in NPC. Platinum-based chemotherapy has been the standard first-line treatment for metastatic NPC (Table XXV.9).¹⁶⁹⁹ A systematic review from 56 studies showed that combination treatment regimen with platinum-based chemotherapy significantly improved PFS compared with monotherapy, despite the increased occurrence of grade 3 and 4 hematological toxicities.¹⁷⁰⁰ A meta-analysis evaluating the efficacy of the commonly used first-line chemotherapy regimens in metastatic disease showed that combination of taxane plus platinum resulted in the highest 1-year OS rate of 79% and disease control rate (DCR) of 92%.¹⁷⁰¹ Triplet combination offered the best short-term efficacy in that meta-analysis; however, it failed to improve prognosis and was associated with intolerable higher incidence of adverse effects.

TABLE XXV. 9 Evidence surrounding treatment of metastatic NPC.

Study	Year	LOE	Study design	Study groups	Clinical endpoints	Conclusions
Wang and Shen ¹⁷⁰⁵	2021	1	Meta-analysis	3402 metastatic NPC patients from 16 studies CRT versus chemotherapy alone	1. OS 2. PFS 3. ORR, DCR	1. CRT group had significantly improved OS and PFS compared with chemotherapy alone group 2. CRT group had significantly improved ORR and DCR compared with chemotherapy alone group
Wang et al. ¹⁷⁰⁶	2020	1	Systemic review and meta-analysis	452 patients with recurrent/metastatic NPC treated with anti PD-1/PD-L1 alone, from eight studies	1. ORR, DCR 2. PFS, OS 3. Drug-related AEs	1. In recurrent/metastatic NPC patients treated with anti-PD-1 therapy, the pooled ORR was 27%, DCR was 63%, 6-month PFS rate was 49%, 1-year PFS rate was 25%, and 1-year OS rate was 61% 2. Pooled incidence of any grade of AEs was 94% and grade 3–5 AEs was 20%
Ma et al. ¹⁷⁰¹	2018	1	Systemic review and meta-analysis	973 patients with recurrent/metastatic NPC from 16 studies Four arms - FP: 5-FU + platinum - GP: gemcitabine + platinum - TP: taxanes + platinum - Triplet combination regimen	1. ORR 2. DCR, 6-month PFS, and 1-year OS	1. Triplet combination regimen demonstrated the best short-term efficacy with a highest ORR, DCR, and 6-month PFS rate, while 1-year OS rate was little lower than TP regimen 2. TP regimen showed a highest 1-year OS rate and good short-term efficacy with ORR of 0.6 and a DCR of 0.92, comparable with triplet combination therapy 3. Efficacy of GP regimen fell between FP and TP regimens 4. FP regimen had the lowest ORR and 1-year OS rate
Prawira et al. ¹⁷⁰⁰	2017	1	Systematic review	2267 patients from 56 studies - Combination regimen versus single agent regimen in first-line setting - Platinum-based versus nonplatinum-based regimen in first-line setting - Molecularly targeted agents	1. PFS, OS 2. ORR	1. Use of combination therapy in the first-line setting had a statistically significant PFS improvement over single agent, yet combination therapy regimen was more likely to report grade 3–4 hematological toxicities 2. Platinum-containing regimen in the first-line setting had improved PFS and improved ORR, yet with more occurrence of grade 3–4 hematological toxicities 3. Molecularly targeted agents (include pazopanib, gefitinib, and cetuximab ± carboplatin) had lower median OS than that estimated from all studies
Chan et al. ¹⁷¹⁰	2021	2	Multicenter, open-label, randomized phase III study	233 patients with platinum pretreated EBV-positive recurrent/metastatic NPC of WHO types II/III, then treated with pembrolizumab versus standard chemotherapy	1. OS 2. PFS, OS, DoR	No significant differences between pembrolizumab and chemotherapy groups in OS, median PFS, ORR, median DOC, and OS in either ITT or in patients with PD-L1 CPS ≥1

(Continues)

TABLE XXV.9 (Continued)

Study	Year	LOE	Study design	Study groups	Clinical endpoints	Conclusions
Mai et al. ¹⁷¹³	2021	2	Multicenter phase III RCT	289 treatment-naive recurrent/metastatic NPC patients treated with toripalimab + GC versus placebo + GC	<ol style="list-style-type: none"> 1. PFS 2. ORR 3. DoR 4. Grade ≥ 3 AE 	<ol style="list-style-type: none"> 1. Significant improvement in median PFS was detected in toripalimab arm compared with placebo arm, and this improvement was observed across key subgroups, including PD-L1 expression 2. Risk of progression or death was decreased in toripalimab group by 59% when compared with placebo 3. ORR was significantly higher in toripalimab arm than in placebo arm, and DoR was significantly longer in toripalimab arm 4. Incidence of grade ≥ 3 AEs was similar between the two arms, except for immune-related AEs, which were more frequent in toripalimab arm compared with placebo arm
Yang et al. ¹⁷¹⁴	2021	2	Multicenter, randomized, double-blind phase III trial	263 patients with treatment-naive recurrent/metastatic NPC from 28 hospitals treated with camrelizumab + GC versus placebo + GC	<ol style="list-style-type: none"> 1. PFS 2. ORR, DCR, DoR 3. AEs 	<ol style="list-style-type: none"> 1. Camrelizumab group had significantly longer PFS than placebo group 2. 87.3% of the camrelizumab group and 80.6% of placebo group achieved objective response and median duration of response was longer with camrelizumab group than in placebo 3. No significant differences in grade 3 or worse AEs in camrelizumab versus placebo groups, with the most common events being leukopenia, neutropenia, anemia, and thrombocytopenia
You et al. ¹⁷⁰⁴	2020	2	Multicenter phase III RCT	126 patients with metastatic NPC who demonstrated complete or partial response following three cycles of PF, then treated with CRT versus chemotherapy alone	<ol style="list-style-type: none"> 1. 2-year OS 2. PFS, ORR 	<ol style="list-style-type: none"> 1. Chemotherapy + RT improved 2-year OS and PFS compared with chemotherapy alone group 2. ORR was comparable between the two groups at the end of six cycles of chemotherapy 3. No significant differences in acute hematological or GI toxic effects were observed in both arms
Wang et al. ¹⁷⁰⁹	2021	2	Single-arm, multicenter, phase II clinical trial	190 patients with recurrent/metastatic NPC refractory to standard chemotherapy treated with toripalimab until PD	<ol style="list-style-type: none"> 1. ORR 2. DoR, PFS, OS, DCR 3. Toxicity 	<ol style="list-style-type: none"> 1. ORR was 20.5% with median DoR 12.8 months and DCR of 40.0% 2. Median PFS was 1.9 months and median OS was 17.4 months 3. ORR was higher in PD-L1-positive patients at 27.1% compared to 19.4% in PD-L1-negative patients, though was not statistically significant 4. Grade 3–5 AEs occurred in 14.2% of patients

(Continues)

TABLE XXV.9 (Continued)

Study	Year	LOE	Study design	Study groups	Clinical endpoints	Conclusions
Yang et al. ¹⁷⁰⁷	2021	2	Phase II multicenter, open-label, single-arm	156 patients from eight hospitals with stage IVb NPC, who failed first-line platinum-base chemotherapy and second-line single agent or combined chemotherapy treated with camrelizumab	<ol style="list-style-type: none"> ORR DCR TTR PFS OS 	<ol style="list-style-type: none"> ORR was 28.2%, DCR was 54.5%, TTR was 8.3 weeks Median PFS was 17.4 months 33% of patients had grade ≥ 3 AEs
Lv et al. ¹⁷¹²	2019	2	Pooled analysis of trials	536 patients with recurrent/metastatic NPC from seven trialsSix different treatment regimens <ul style="list-style-type: none"> - Pembrolizumab - Nivolumab - JS001 - Camrelizumab - Chemotherapy - Camrelizumab + chemotherapy 	<ol style="list-style-type: none"> Grade 1–5 AEs and grade 3–5 AEs ORR 	<ol style="list-style-type: none"> Nivolumab (54.2%) and pembrolizumab (74.1%) exhibited the optimal safety regarding grade 1–5 AEs, whereas camrelizumab (16.1%) and nivolumab (17.4%) had the lowest grade 3–5 AEs Treatment discontinuation due to AEs was most commonly recorded in pembrolizumab (18.5%), followed by camrelizumab + chemotherapy (13.0%) and JS001 (9.8%) and lowest in camrelizumab (2.2%) As first-line therapy, camrelizumab + chemotherapy achieved higher ORR than with chemotherapy alone; when nivolumab was used as first-line therapy (in treatment-naïve patients), its ORR increased to 40.0% As second- or later-line therapy, ORR was higher with camrelizumab (34.1%) followed by pembrolizumab (26.3%), JS001 (23.3%), and nivolumab (19.0%) Pooled ORR was 28.4% for PD-L1-positive and 17.4% for PD-L1-negative patients
Ma et al. ¹⁷⁰⁸	2018	2	Multicenter phase II study	44 patients with pretreated recurrent/metastatic NPC treated with nivolumab until PD	<ol style="list-style-type: none"> ORR DoR, OS, PFS 	<ol style="list-style-type: none"> ORR was 20.5% (CR $n = 1$, PR $n = 8$), median DoR was 9.3 months, DCR was 54.5% Median OS was 17.1 months and median PFS was 2.8 months 1-year OS was 59% and PFS was 19.3% No statistical correlation between ORR and biomarkers

(Continues)

Two phase III studies on efficacy of different platinum-based regimens done a few years later showed that GP had a significantly higher objective response rate (ORR), PFS, and OS compared with 5-FU¹⁷⁰² or docetaxel¹⁷⁰³ plus platinum-based regimen.

There is no universal recommendation on the role of locoregional RT of the nasopharynx and neck in metastatic NPC patients. A multicenter phase III study on addition of locoregional RT to chemotherapy in patients with de novo metastatic NPC showed that chemotherapy plus

TABLE XXV. 9 (Continued)

Study	Year	LOE	Study design	Study groups	Clinical endpoints	Conclusions
Fang et al. ¹⁷¹¹	2018	3	Two single-arm, phase I trials	93 patients with pretreated recurrent/metastatic NPC (23 treatment naïve patients) treated with camrelizumab monotherapy or combination therapy (camrelizumab + gemcitabine + cisplatin followed by camrelizumab maintenance)	1. Safety and tolerability 2. Preliminary antitumor activity (objective response/stable disease), PFS	<p>Monotherapy trial:</p> <ol style="list-style-type: none"> 16% had grade 3 or 4 treatment-related AEs 9% had treatment-related serious AE ORR 34%, disease control in 59% with median follow-up 9.9 months <p>Combination trial:</p> <ol style="list-style-type: none"> 87% had grade 3 or 4 treatment-related AEs ORR 91%, disease control in 100%, median follow-up 10.2 months Median PFS not reached, 6- and 12-month PFS 86% and 61%

Abbreviations: AE, adverse events; CPS, combined positive score; CRT, chemoradiation; DCR, disease control rate; DoR, duration of response; GC, gemcitabine + cisplatin; ITT, intention-to-treat; LN, lymph node; NPC, nasopharyngeal carcinoma; ORR, objective response rate; OS, overall survival; PD, disease progression; PF, cisplatin + 5-fluorouracil; PFS, progression-free survival; PR, partial response; RT, radiation therapy; TTR, time to response.

locoregional RT improved 2-year OS and PFS, with no significant increase in acute hematological or gastrointestinal toxic effects.¹⁷⁰⁴ The finding was consistent with a meta-analysis comparing chemotherapy plus locoregional RT with chemotherapy alone in this group of patients, which also revealed improvement in ORR and DCR with locoregional RT.¹⁷⁰⁵

Immunotherapy with checkpoint inhibitors against PD-1 or PD-L1 offered promising pooled DCR of 63% and ORR of 27% in patients who are refractory to first-line treatment in a meta-analysis.¹⁷⁰⁶ Phase II trials on monotherapy of camrelizumab (CAPTAIN study),¹⁷⁰⁷ nivolumab (NCI-9742),¹⁷⁰⁸ and toripalimab (POLARIS-02)¹⁷⁰⁹ on patients with refractory metastatic NPC revealed ORR of 28.2%, 20.5%, and 20.5% and DCR of 54.5%, 54.5%, and 40.0%, respectively. However, the phase III KEYNOTE-122 study¹⁷¹⁰ on pembrolizumab failed to demonstrate a significant benefit compared with standard chemotherapy as second-line therapy. A phase I trial on camrelizumab monotherapy as second-line treatment revealed ORR of 34% and DCR of 59%.¹⁷¹¹ Meanwhile in the same study, combination of camrelizumab with GP in treatment-naïve patients provided an ORR of 91% and DCR of 100% with median follow-up time of 10.2 months. A pooled analysis comparing different immunotherapy regimens with chemotherapy alone showed that camrelizumab offered higher ORR, followed by pembrolizumab, as second- or later-line therapy.¹⁷¹² Two phase III trials on combination of immunotherapy with systemic chemotherapy were conducted later to evaluate its efficacy and safety.

Combination of toripalimab¹⁷¹³ or camrelizumab¹⁷¹⁴ with GP in recurrent or metastatic NPC patients as first-line treatment provided improvement in median PFS, ORR, and duration of response, with no significant increase in grade 3–5 AEs.

Treatment of metastatic NPC: Chemotherapy

Aggregate grade of evidence	A (Level 1: three studies; Level 2: one study)
Benefit	Combination regimen of platinum-based chemotherapy improves OS and PFS in metastatic NPC.
Harm	Increase in occurrence of grade 3–4 hematological toxicities.
Cost	Combination regimen of platinum-based chemotherapy might increase the cost. Cost comparison analyses have not been undertaken.
Benefits-harm assessment	Preponderance of benefits over harms.
Value judgments	Patients with metastatic NPC should be treated with combination regimen of platinum-based chemotherapy as first-line treatment.
Policy level	Strong recommendation.
Intervention	Platinum-based combination chemotherapy, preferably with gemcitabine, is the current first-line treatment for metastatic NPC.

Treatment of metastatic NPC: Radiation therapy

Aggregate grade of evidence	B (Level 1: one study; Level 2: one study)
Benefit	Systemic chemotherapy with locoregional RT improves survival and disease control in patients with metastatic NPC.
Harm	Systemic chemotherapy with locoregional RT has no significant increase in severe adverse events.
Cost	Combination of locoregional RT increases the time needed for radiotherapy planning. Cost comparison analyses have not been undertaken.
Benefits-harm assessment	Preponderance of benefits over harms.
Value judgments	Addition of locoregional RT to nasopharynx and/or neck could be considered in metastatic NPC.
Policy level	Recommendation.
Intervention	Systemic chemotherapy plus locoregional RT could be considered for disease control in patients presenting with previously untreated metastatic NPC.

Treatment of metastatic NPC: Immunotherapy

Aggregate grade of evidence	B (Level 1: one study; Level 2: seven studies; Level 3: one study)
Benefit	Immunotherapy improves survival parameters when being used as first-line therapy, in combination with chemotherapy. Immunotherapy also provides satisfactory disease control when being used as monotherapy in first-line treatment.
Harm	Use of immunotherapy may lead to drug-related adverse events especially immune-related adverse events.
Cost	Cost comparison analyses have not been undertaken.
Benefits-harm assessment	Preponderance of benefits over harms.
Value judgments	Immunotherapy would improve the survival in patients who are refractory to first-line platinum-based combination chemotherapy, with no significant increase in grade 3 or above adverse events. However, immunotherapy caused more immune-related events compared with traditional treatment. In light of this, survival benefits justify the possibly increased cost and short-term morbidities during treatment.

(Continued)

Policy level	Recommendation.
Intervention	Immunotherapy with GP should be considered as first-line treatment for metastatic NPC in patients who are refractory to first-line treatment. Immunotherapy as monotherapy may be considered as first-line therapy in patients who cannot tolerate platinum-based combination chemotherapy.

B | Low-grade nasopharyngeal papillary adenocarcinoma

Low-grade nasopharyngeal papillary adenocarcinoma (LGNPPAc) is a rare malignancy accounting for only 0.5% of tumors originating from the nasopharynx (Table XXV.10).¹⁷¹⁵ The reported age range at diagnosis is between 11 and 64 years, with no sex predilection.¹⁷¹⁶ In 1988, Wenig et al.¹⁷¹⁶ first referred to a primary nasopharyngeal papillary adenocarcinoma arising from the surface mucosal epithelium as an LGNPPAc, because this entity was found to have the biological potential of low-grade malignancy. Most LGNPPAc of mucosal origin have a papillary configuration, are of low grade, and can be identified by their light microscopic appearance.¹⁷¹⁷ These tumors are known to express thyroid transcription factor-1 (TTF-1) but are negative for thyroglobulin (TG) expression.¹⁷¹⁸ The pathogenesis of LGNPPAc remains controversial. While NPC is often associated with EBV, there is no known association between LGNPPAc and EBV.^{1719–1721}

Patients often present with complaints of nasal obstruction, bloody rhinorrhea, and epistaxis.^{1716,1717,1722} Main symptoms of LGNPPAc are secondary to involvement of the nasopharynx and compression of surrounding structures. In some patients, snoring, hearing loss due to middle ear effusion, and swallowing dysfunction can be present.^{1722–1724}

Typically, LGNPPAc presents as a polypoid or pedunculated mass on the roof of the nasopharynx. LGNPPAc was mostly localized on the roof of the nasopharynx, posterior margin of the nasal septum, and lateral wall (i.e., torus tubarius).^{1718,1722,1724–1728} Most cases are early stage (T1, with no evidence of metastases) at diagnosis.^{1715–1717,1719,1721,1722,1729,1730} CT typically shows a round mass in the nasopharynx or posterior margin of the nasal septum. MRI demonstrates moderate T1 signal, high T2 signal, and contrast enhancement.¹⁷²²

Treatment of LGNPPAc usually involves surgery, with generally favorable prognosis.¹⁷¹⁶ Early-stage tumors can be directly resected by endoscopic endonasal nasopharyngectomy.^{1731,1732} Adjuvant RT can reduce

TABLE XXV.10 Evidence for the treatment of Low-grade nasopharyngeal papillary adenocarcinoma (LGNPPAc).

Study	Year	LOE	Study design	Study groups	Clinical endpoints	Conclusions
Lai et al. ¹⁷²²	2021	4	Retrospective case series	28 T1N0M0 patients Endoscopic surgery (<i>n</i> = 23) Preoperative RT + endoscopic surgery (<i>n</i> = 3) Endoscopy surgery + postoperative RT (<i>n</i> = 2)	Recurrence rate	1. All patients were alive without evidence of lymphatic or distant metastases in the follow-up period (range 7 to 121 months) 2. Two patients (7%, 2/28) experienced disease recurrence
Huang et al. ¹⁷²¹	2019	4	Retrospective case series	Five T1N0M0 patients with LGNPPAc Endoscopic surgery (<i>n</i> = 3) Endoscopic surgery + postoperative RT (<i>n</i> = 2)	Recurrence rate	All five patients were followed up for 6 months to 8.8 years, without recurrence or metastasis
Booth et al. ¹⁷³⁰	2019	4	Database study (SEER)	25 patients with LGNPPAc treated with surgery, RT, or surgery + RT	DSS	1. 1-year DSS: 94.4% 2. 5-year DSS: 85.7% 3. 10-year DSS: 71%
Kuan et al. ¹⁷¹⁵	2017	4	Database study (SEER)	22 patients with LGNPPAc treated with surgery, RT, or surgery + RT	1. OS 2. DDS	1. OS: 226.9 months 2. DDS: 444.0 months
Pineda-Daboin et al. ¹⁷¹⁷	2006	4	Retrospective case series	11 patients with LGNPPAc two patients with TL-LGNPPAc treated with surgery	Clinical outcome	1. Follow-up period for all patients from the time of the initial diagnosis ranged from 5 to 20 years 2. All patients are alive with no evidence of disease.
Wenig et al. ¹⁷¹⁶	1988	4	Retrospective study	Nine patients with LGNPPAc treated with surgery versus preoperative RT + surgery versus surgery + postoperative RT	Clinical outcome	At 6 years and 9 months of follow-up, all patients were alive without recurrence or metastasis

Abbreviations: DSS, disease-specific survival; OS, overall survival; RT, radiation therapy; SEER, Surveillance, Epidemiology, and End Results.

the risk of local recurrence if positive margins are obtained.^{1721,1726,1728}

Wenig et al.¹⁷¹⁶ reported the clinical outcome of nine patients with LGNPPAc. In nine cases, all tumors were resected via an open transpalatal approach. Three patients received preoperative or postoperative RT. At the median follow-up (6 years and 9 months), all patients were alive without recurrence or metastasis. A similar study by Pineda-Daboin et al. reporting surgical outcomes of 13 patients revealed that all patients were alive without recurrence or metastasis at 5–20 years follow-

up.¹⁷¹⁷ Taken together, the overall 5-year survival rate was 100%.

Lai et al.¹⁷²² analyzed the treatment efficacy of EEA for a cohort of 28 LGNPPAc patients. Among 28 patients, 23 patients underwent endoscopic surgery alone, three patients received preoperative RT (to decrease tumor volume), and two patients received postoperative RT. All patients were alive without evidence of regional or distant metastases in the follow-up period (range 7–121 months). Two patients (7%, 2/28) experienced local disease recurrence. Huang et al.¹⁷²¹ reported a case series of five patients

with LGNPPAc. Three patients underwent endoscopic surgery alone and two patients underwent endoscopic surgery and postoperative RT. All five patients were followed up for 6 months to 8.8 years, without recurrence or metastasis.

Booth et al. queried the SEER database and reported outcomes of surgery versus RT alone in LGNPPAc.¹⁷³⁰ Five-year DSS rates were significantly improved for patients who had surgical resection as compared with RT alone. DSS rates for LGNPPAc were 100% for surgery alone, 100% for surgery combined with RT, and 33% for RT alone, indicating that LGNPPAc is relatively radioresistant. Kuan et al.¹⁷¹⁵ also conducted a retrospective cohort study of LGNPPAc using the SEER database, which reported that OS and DDS for LGNPPAc were 226.9 and 444.0 months, respectively. There are no dedicated studies on chemotherapy for treatment of LGNPPAc or comparison of open versus endoscopic approaches.

Overall, NPPAc is a slow-growing tumor with excellent prognosis. Surgery can be an effective treatment for early-stage disease and adjuvant RT can reduce tumor recurrence when positive margins are obtained. There are insufficient data to assess clinic outcomes of advanced LGNPPAc.

XXVI | SINONASAL LYMPHOMA

A | B and T cell lymphomas

Sinonasal lymphomas are rare and represent <1% of all head and neck cancers.^{1759,1760} Lymphomas are classically divided into Hodgkin and non-Hodgkin subtypes. Non-Hodgkin lymphomas are additionally divided into mature B-cell, mature T-cell, or natural killer (NK)/T-cell phenotypic subtypes, based on cell of origin, histopathology, and IHC.³ When compared to other extranodal lymphoma sites, paranasal sinus lymphoma has a worse OS, higher rate of primary recurrence, and higher likelihood for disease dissemination.^{1761–1763}

BCLs make up the majority of cases and have a more favorable prognosis, whereas NK/T-cell lymphomas (ENKTL) represent a minority of cases and are often more aggressive.^{1764,1765} BCLs have multiple subtypes, with DLBCL being the most common (42%–94%).^{1766–1769} EBV seems to have a causative role in ENKTL development that has been described by multiple groups.^{1770–1772} ENKTL also commonly causes extensive midface destruction and can also occur in the aerodigestive tract or elsewhere in the body.^{1773–1777}

There have been consistent geographic associations with sinonasal lymphomas; Western populations have mainly B-cell subtypes, while Asian and South American populations have predominantly NK/T-cell and T-cell subtypes.^{1778–1780} ENKTL is the most common subtype of sinonasal lymphoma in the Asian population, whereas DLBCL is more common in patients in Western countries.^{1775,1781} Interestingly, BCLs have been noted to arise more commonly from the paranasal sinuses and ENKTL more commonly involving the nasal cavity.¹⁷⁸² Sinonasal lymphomas often present with either local or systemic manifestations of disease. In local disease, patients generally present with nonspecific sinonasal symptoms.¹⁷⁸³ In systemic disease, generalized constitutional symptoms occur, including fever, night sweats, weight loss, and regional lymphadenopathy.¹⁷⁸⁴ Given the nonspecificity of presentation, there is often significant delay in diagnosis.^{1785,1786}

B | Diagnostic considerations

The cornerstone of any patient evaluation centers around complete history and physical examination (Table XXVI.1). Sinonasal lymphoma is no different with most patients initially being evaluated for sinonasal symptoms as their chief complaint.¹⁷⁸⁷ The most likely subtype of lymphoma varies with geography, with B-cell being more common in Europe and North America and ENKTL arising more frequently in Asia and South America.^{1774,1788,1789}

Regardless of the location of consultation, history should focus on the nature of the symptoms and duration. A retrospective series examining the most common presenting symptoms suggests that most patients present with nonspecific complaints, most often sinonasal symptoms that can be easily confused for CRS.^{1785,1787,1790–1792} Interestingly, there has been report of the impact of comorbid CRS on ENKTL stage finding that the duration of CRS symptoms correlated with the stage of disease at the time of diagnosis.¹⁷⁹³ Whether the milieu of chronic inflammation predisposes to tumorigenesis or if ENKTL symptoms are simply misdiagnosed for CRS and present later after progress remains unknown.

Systemic symptoms may be present in BCL (especially in cases with systemic involvement), while they are relatively rare in ENKTL.¹⁷⁹⁴ In a series of head and neck lymphoma patients, only 13% of ENKTL patients were diagnosed with B symptoms at the time of presentation.¹⁷⁹⁵ Unfortunately, diagnosis remains difficult in many circumstances due to the rarity of the tumor and lack of specific presenting symptoms.^{1796,1797}

TABLE XXVI.1 Evidence surrounding the diagnosis of sinonasal lymphoma.

Study	Year	LOE	Study design	Study groups	Clinical endpoints	Conclusion
Gong et al. ¹⁸⁸⁵	2018	3	Prospective cohort	Patients with ENKTL; patients' CSF was tested before and after cytarabine chemotherapy	Protein expression after treatment	<ol style="list-style-type: none"> Following cytarabine treatment, IGFBP2, SERPINC1, AMBP, and GPX3 were reduced and CPE was increased Authors suggest these could be markers for treatment response
King et al. ¹⁸⁰⁹	2017	3	Retrospective cohort	Primary, nodal, and multifocal sites on head and neck MRI were compared between 31 Waldeyer's ring (WR) and 15 sinonasal (SN) DLBCL, and between 27 patients with disease confined to the head and neck and 16 patients with disease beyond the neck	Radiological evaluation of head and neck MRI	Lymphatic WR DLBCLs were less locally aggressive but had greater propensity to nodal spread than extra-lymphatic SN DLBCLs
Wang et al. ¹⁸⁰⁸	2014	3	Retrospective cohort	PROPELLER DUO DW-MRI was performed in 23 patients with sinonasal lymphomas and 28 patients with carcinomas histologically confirmed at 3T MRI	Difference in apparent diffusion coefficients between sinonasal lymphomas and carcinomas	PROPELLER DUO DW-MRI can effectively differentiate sinonasal lymphomas from carcinomas
Iguchi et al. ¹⁸¹¹	2012	3	Retrospective cohort	122 patients with hematolymphoid malignancies in the head and neck from January 2004 to December 2010	<ol style="list-style-type: none"> Histopathological examinations Classification of hematolymphoid malignancies 	Most common histopathology was DLBCL (54.9%), followed by follicular lymphoma (8.2%) and peripheral T-cell lymphoma (8.2%)
Kane et al. ¹⁸¹²	2009	3	Retrospective cohort	98 total cases of primary non-Hodgkin's lymphoma and plasmacytoma of oral-sinonasal region recorded over 4 years, 39 cases showing varied plasmablastic differentiation	Minimum morphological criteria required to diagnose PBL were (1) predominant population of plasmablasts, (2) high mitotic and/or apoptotic index, and (3) absence of neoplastic plasma cells	Classic plasmablastic morphology and limited immunohistochemical panel can render a reliable diagnosis of PBL

(Continues)

TABLE XXVI.1 (Continued)

Study	Year	LOE	Study design	Study groups	Clinical endpoints	Conclusion
Nakamura et al. ¹⁸⁰⁶	1997	3	Retrospective cohort	CT data and clinical outcomes of 24 patients with Stage 1 and 2 non-Hodgkin's lymphoma	1. Site of primary tumor 2. OS	B-cell primary lymphoma of the maxillary sinus has a good prognosis in contrast to T-cell lymphomas that originate from midline structures
Eide et al. ¹⁷⁹²	2022	4	Retrospective case series	85 sinonasal lymphoma patients	1. Signs and symptoms 2. DSS	Facial swelling was most common presenting symptom
Lei et al. ¹⁷⁹³	2022	4	Retrospective case series	214 ENKTL patients treated at a single institution	Treatment outcomes	1. 5-year OS was 73.4%, PFS was 51.1% 2. Length of CRS symptoms correlated with stage at diagnosis (not true for non-UAT ENKTL) 3. Patients without CRS had a significantly better PFS 4. CRS did not affect response to treatment
Desai et al. ¹⁸¹³	2021	4	Retrospective case series	25 cases of primary sinonasal tract DLBCL	Histopathological analysis	DLBCL primary to the sinonasal tract is histopathologically heterogeneous
Chen et al. ¹⁸⁰³	2020	4	Retrospective case series	59 ENKTL and 27 DLBCL patients treated at a single institution	Imaging Findings	1. ENKTL tended to be located in the nasal cavity, heterogeneous intensity, internal necrosis, and solid component 2. DLBCL located more often in sinus, homogenous, mild enhancement, septal enhancement, and with intracranial/orbital involvement
He et al. ¹⁸⁰⁴	2019	4	Retrospective case series	60 patients with ENKTL and 26 patients with DLBCL treated at a single institution with MRI scans	Imaging findings	ENKTLs localized in the nasal cavity with poor to moderate enhancement, DLBCLs were located in the paranasal sinuses with intense enhancement
Murakami et al. ¹⁸¹⁵	2019	4	Retrospective case series	Clinicopathological analysis of 151 sinonasal malignant lymphoma patients in an HTLV-1 endemic area in Fukuoka, Japan	1. OS 2. Lymphoma subtype analysis	1. OS was significantly different among three distinct DLBCL patient groups 2. Primary DLBCL of the sinonasal tract is a distinct disease entity of DLBCL
Storck et al. ¹⁷⁹⁵	2019	4	Retrospective case series	221 patients with head and neck lymphoma treated at a single institution, (193 NHL, 28 HL, one ENKTL)	Presenting symptoms	1. Patients rarely have B symptoms (only 13%) 2. Presentation is nonspecific making diagnosis challenging 3. Biopsies should be performed when suspecting sinonasal lymphoma

(Continues)

TABLE XXVI.1 (Continued)

Study	Year	LOE	Study design	Study groups	Clinical endpoints	Conclusion
Varelas et al. ¹⁸³⁵	2019	4	Retrospective database study (SEER)	1273 cases of DLBCL of the sinonasal tract	<ol style="list-style-type: none"> 1. Prognostic disease-specific survival 2. OS 	<ol style="list-style-type: none"> 1. Most common primary sites of DLBCL were maxillary sinus (36.1%) and nasal cavity (34.5%) 2. Nasal cavity more common among Asian/Pacific Islands (43.4%) 3. Maxillary sinus more common for Caucasians (36.3%) and African Americans (42.1%) 4. OS was 70% at 2 years, 54% at 5 years, and 38% at 10 years
Zhiyan et al. ¹⁸³⁰	2018	4	Retrospective case series	17 patients treated for ENKTL at a single institution	<ol style="list-style-type: none"> 1. Presenting symptoms 2. Treatment outcomes 	<ol style="list-style-type: none"> 1. Angiocentric/destructive pathology 2. Tumor cells expressed several markers (CD3, CD43, CD56, TIA-1, granzyme B, perforin) and EBV+ 3. CXRT was given but treatment outcomes were poor
Arora et al. ¹⁷⁸⁷	2017	4	Retrospective case series	Nine patients treated in India over 2 years	<ol style="list-style-type: none"> 1. Presenting symptoms 2. Treatment outcomes 	<ol style="list-style-type: none"> 1. Sinonasal symptoms are the most common presenting symptoms 2. Bhutan may be endemic for EBV/ENKTL 3. Necrosis and angiocentricity are common 4. Chemotherapy (SMILE/CHOP) and radiotherapy were used based on stage of disease
Carreras et al. ¹⁸¹⁴	2017	4	Retrospective case series	Clinicopathological characteristics of 29 primary sinonasal DLBCL	Microarray DNA hybridization of DLBCL	<ol style="list-style-type: none"> 1. Sinonasal DLBCL has a characteristic genomic profile 2. High RGS1 IHC expression is associated with poor OS
McKelvie et al. ¹⁸¹⁷	2016	4	Retrospective case series	13 patients with ENKTL treated at multiple institutions (10 patients with sinonasal disease)	Histopathology	Biopsies with small lymphocytic infiltrates, chronic inflammation, surface ulceration, and microscopic bone invasion should alert pathologist to ENKTL
Vahamurto et al. ¹⁷⁹⁷	2016	4	Retrospective case series	142 patients treated over almost 40 years at single institution (five ENKTL)	Presenting symptoms	<ol style="list-style-type: none"> 1. 84% were primary lesions 2. Presenting symptoms were primarily nonspecific nasal complaints 3. Nasopharynx followed by nasal cavity was the most common subsite
Tusaliu et al. ¹⁷⁸²	2015	4	Retrospective case series	Patients treated at a single institution	Presenting symptoms	Note that diagnosis remains challenging due to nonspecific presentation
Miyake et al. ¹⁷⁹⁰	2014	4	Retrospective case series	Seven patients treated at a single institute	Presenting symptoms	Presenting symptoms are not specific, multiple biopsies may be necessary

(Continues)

TABLE XXVI.1 (Continued)

Study	Year	LOE	Study design	Study groups	Clinical endpoints	Conclusion
Termote et al. ¹⁸⁰¹	2014	4	Retrospective case series	Three patients treated at a single center with ENKTL involving the orbit	1. Presenting symptoms 2. Treatment outcomes	1. All three patients passed away despite CXRT 2. All three ultimately had extraocular muscle involvement and presented with painless eyelid swelling
Toda et al. ¹⁸¹⁶	2013	4	Retrospective case series	Clinicopathologic review of 39 patients with localized nasal/paranasal DLBCL	Comparison between DLBCL subtypes with nongerminial center B-cell-like (non-GCB) and germinal center B-cell-like (GCB)	1. Non-GCB subtype was previously thought to show poor prognosis 2. Prognosis for localized nasal/paranasal DLBCL patients was good irrespective of subclassification
Li et al. ¹⁸³¹	2012	4	Retrospective case series	82 patients with ENKTL treated at a single center	Survival	1. Elevated beta-2 microglobulin was defined as >2.5 mg/L 2. Patients with high B2M at diagnosis had worse 5-year OS (35.2% vs. 73.6%) and worse PFS (27.5% vs. 55.9%)
Tababi et al. ¹⁸⁸⁶	2012	4	Retrospective case series	15 patients with ENKTL treated at a single institution	1. Survival 2. Treatment response	1. Nine patients died and only four remain in remission at follow-up 46 months 2. Addition of chemotherapy did not improve outcomes in advanced stage
Yen et al. ¹⁷⁹¹	2012	4	Retrospective case series	33 patients treated for SN lymphoma at a single institution	Presenting symptoms	1. As many as 37.5% of patients were referred for rhinitis and/or sinusitis 2. Many patients required multiple biopsies for definitive diagnosis
Sands et al. ¹⁷⁸⁵	2008	4	Retrospective case series	Four patients treated at a single institution	1. Presenting symptoms 2. Survival	1. All patients had false-negative biopsies, leading to treatment delay 2. 50% OS
Bisdas et al. ¹⁸⁰⁵	2007	4	Retrospective case series	Three patients with primary BCL of the sphenoid sinus	1. Morphological CT and MR imaging 2. Perfusion CT imaging and proton MR spectroscopy	1. Inhomogeneous contrast agent enhancement as well as bony erosion of the sphenoid sinus were identified on CT and MRI 2. Cross-sectional imaging is not sufficient to establish the diagnosis of a primary NHL in the sphenoid sinus
Falcao et al. ¹⁸²⁶	2007	4	Retrospective case series	Three patients treated at a single institution who underwent immunophenotyping via flow cytometry in the leukemic phase	Histopathology	1. Nasal biopsies showed CD3+ and CD56+ cells 2. Tumor cells were detected in marrow and peripheral blood 3. All patients died within 48 months of diagnosis despite treatment

(Continues)

TABLE XXVI.1 (Continued)

Study	Year	LOE	Study design	Study groups	Clinical endpoints	Conclusion
Ou et al. ¹⁸⁰⁰	2007	4	Retrospective case series	24 patients with biopsy proven ENKTL	Imaging findings	<ol style="list-style-type: none"> 1. CT and MRI findings are nonspecific 2. Bony erosion and local invasion are common
Woo et al. ¹⁷⁸⁴	2004	4	Retrospective case series	50 patients with extranodal NHL	OS	<ol style="list-style-type: none"> 1. 49 patients had ENKTL 2. Higher mortality rates were noted in chemotherapy alone group, but combination CRT failed to show significantly better survival (5-year OS was 35.1%)
Lin et al. ¹⁸⁸⁷	2003	4	Retrospective case series	15 patients treated for ENKTL at a single institution	<ol style="list-style-type: none"> 1. Survival 2. Histopathology 	Demonstration of mixed lineage (NK and T cell) via histopathology
Altemani et al. ¹⁸⁸⁸	2002	4	Retrospective case series	25 patients with midface lymphoma treated in Brazil	<ol style="list-style-type: none"> 1. Presenting symptoms 2. Patient survival 	<ol style="list-style-type: none"> 1. ENKTL was more common than BCL 2. No racial association with ENKTL 3. ENKTL shows an aggressive phenotype similar to Asian studies with EBV association
Takahash et al. ¹⁸⁸⁹	2001	4	Retrospective case series	20 patients with ENKTL and hemophagocytic syndrome	Survival	<ol style="list-style-type: none"> 1. Two clinical groups: one at the terminal stage of disease, the other at time of presentation 2. Poor prognosis thought to be due to resistance to chemotherapy
Borges et al. ¹⁸⁰⁷	2000	4	Retrospective case series	Nine patients with midline granuloma	<ol style="list-style-type: none"> 1. Histopathology 2. Imaging findings 	<ol style="list-style-type: none"> 1. Lesions were consistent with either ENKTL or Granulomatosis with Polyangiitis (GPA) 2. ENKTL was positive for CD 20, 45, and 45RO 3. There were no imaging findings found to differentiate NK/T cell and GPA
Gaal et al. ¹⁷⁸⁹	2000	4	Retrospective case series	15 patients with ENKTL treated at a single North American institute; 12 had sinonasal lesions	Histopathology	Despite being less common, histology of North American lymphoma is similar to Asian samples
Ooi et al. ¹⁷⁹⁹	2000	4	Retrospective case series	Nine patients with radiologic imaging and biopsy proven ENKTL	Imaging findings	<ol style="list-style-type: none"> 1. Presence of bone erosion is suggestive of the disease but not diagnostic 2. Involvement of hard palate, orbit, and nasopharynx was found in 50% of cases
Harabuchi et al. ¹⁸²²	1998	4	Retrospective case series	18 patients with ENKTL treated at a single institution	<ol style="list-style-type: none"> 1. OS 2. Histopathologic features 	<ol style="list-style-type: none"> 1. Poor prognosis with median survival of 6 months 2. EBER detected in 16 out of 18 patients

(Continues)

TABLE XXVI.1 (Continued)

Study	Year	LOE	Study design	Study groups	Clinical endpoints	Conclusion
Kohshima et al. ¹⁸²⁸	1997	4	Retrospective case series	Eight patients with ENKTL	Histopathology	<ol style="list-style-type: none"> Two cases were CD3+CD56+ and six were CD3-CD56+, all showed EBV+ FasL and perforin were expressed, suggesting both paths are used in tumor cytotoxicity
Van de Rijn et al. ¹⁷⁸⁸	1997	4	Retrospective case series	33 cases of ENKTL treated in Guatemala	Presenting symptoms	<ol style="list-style-type: none"> 88% showed null or T-cell phenotype and EBV in situ hybridization The frequency and presentation in Guatemala were similar to Asian and Peruvian series
Yang et al. ¹⁸⁹⁰	1997	4	Retrospective case series	34 patients with sinonasal lymphomas at Taichung Veterans General Hospital	<ol style="list-style-type: none"> Clinicopathologic data OS 	5-year OS was 63% with mean survival time of 84.2 months
Dictor et al. ¹⁸²¹	1996	4	Retrospective case series	12 cases of NK/T-cell lymphoma, 23 cases of rhinitis, 10 cases of GPA	Histopathology	<ol style="list-style-type: none"> EBER ISH+ was found in all ENKTL EBER ISH was strongly suggestive of absence of ENKTL
Kanavaros et al. ¹⁸⁹¹	1996	4	Retrospective case series	55 patients with upper aerodigestive non-Hodgkin's lymphoma; 27 had sinonasal lymphoma; 23 were ENKTL	Histopathology	EBV is strongly associated with sinonasal localization and expression of ENKTL antigens
Gorp et al. ¹⁸⁹²	1995	4	Retrospective case series	13 patients with ENKTL treated at a single center	<ol style="list-style-type: none"> OS Treatment response 	XRT with or without chemotherapy performed better than chemotherapy alone
Lee et al. ¹⁸¹⁸	1994	4	Retrospective case series	13 sinonasal and 18 Waldeyer's ring lymphomas treated at a single center	Histopathology	<ol style="list-style-type: none"> EBER+ in 12 SN lymphomas with T-cell phenotype EBER+ and ENKTL were found to be angiodestructive/angiocentric
Suzumiya et al. ¹⁸²⁹	1994	4	Retrospective case series	Nine patients with non-Hodgkin's SN lymphoma	Histopathology	Eight of the cases had TCR-CD56+ markers, suggesting NK cell lineage
Arber et al. ¹⁸²⁰	1993	4	Retrospective case series	14 patients with sinonasal lymphoma treated in Peru	Histopathology	<ol style="list-style-type: none"> In 13 of the patients (11 ENKTL) EBV RNA was detected CD 43+ was found in EBV-infected cells Similar to cohorts from Asia
Aviles et al. ¹⁸¹⁹	1992	4	Retrospective case series	65 patients with sinonasal or hard palate lymphoma	<ol style="list-style-type: none"> Histopathology treatment response 	<ol style="list-style-type: none"> Angioinvasive lesions had worse prognosis Combined therapy should be considered for angioinvasive lymphoma

(Continues)

TABLE XXVI.1 (Continued)

Study	Year	LOE	Study design	Study groups	Clinical endpoints	Conclusion
Kojima et al. ¹⁸⁹³	1992	4	Retrospective case series	20 NHL of the sinonasal cavity treated at a single center	1. Histopathology 2. Treatment outcomes	2-year survival was worse for ENKTL than B cell
Marsot-Dupuch et al. ¹⁸⁰²	1992	4	Retrospective case series	13 patients with diagnosis of lethal midline granuloma	Imaging findings	1. Eight of the 13 had ENKTL; CT was useful for bony erosion and planning radiotherapy 2. MRI also helpful for defining extent of disease versus trapped secretions
Weiss et al. ¹⁸⁹⁴	1992	4	Retrospective case series	Eight sinonasal and 10 Waldeyer's ring non-Hodgkin lymphoma patients	Evidence of EBV DNA using in situ hybridization	1. B-cell and T-cell sinonasal NHL are associated with EBV in Western as well as in Asian patients 2. EBV may have a role in oncogenesis in NHL of the upper aerodigestive tract

Abbreviations: DLBCL, diffuse large B-cell lymphoma; DSS, disease-specific survival; ENKTL, extranodal NK/T-cell lymphoma; NHL, non-Hodgkin's lymphoma; OS, overall survival; SEER, Surveillance, Epidemiology, and End Results.

A comprehensive head and neck physical exam is encouraged for all patients and is of special concern in patients with concern for malignancy. Attention should be paid to cranial nerve deficits, which are suggestive of more aggressive disease.¹⁷⁹⁸ Nasal endoscopy is the standard of care for patients with sinus complaints and should be included when evaluated for sinonasal lymphoma as well.¹ In addition to the initial diagnosis, nasal endoscopy plays an important role in evaluation of the extent of disease and local invasion. Examination for invasion of local structures is important given that at the time of diagnosis in one series, 50% of ENKTL patients had involvement of the hard palate, orbit, and/or nasopharynx, and it is not uncommon in BCL.¹⁷⁹⁹ Indeed, local destruction of structures is a hallmark of ENKTL.¹⁸⁰⁰ In cases of orbital invasion, patients may experience painless eyelid swelling and extraocular muscle involvement with ophthalmoplegia.¹⁸⁰¹

Aggregate grade of evidence: C (Level 4: 11 studies)

C | Imaging for lymphoma

There are multiple options for imaging of lymphoma of the head and neck. Both CT and MRI are generally recommended to evaluate bony destruction and soft tissue invasion, respectively.^{1799,1800,1802} A number of studies have noted that ENKTL and DLBCL can be differentiated on MRI in most patients, with ENKTL more commonly located in the nasal cavity with a heterogeneous appearance and DLBCL was more likely to be in the paranasal sinus and homogeneous.^{1803–1806} It is worth noting that some authors have noted that ENKTL and

granulomatosis with polyangiitis can look similar on diagnostic imaging.¹⁸⁰⁷ DW-MRI has also been helpful in differentiating NK/T-cell and DLBCL.¹⁸⁰⁸ Wang et al. also noted the ability of DW-MRI in differentiating lymphomas from other carcinomas with lower ADC for sinonasal lymphoma.¹⁸⁰⁸ Finally, King et al. examined MRIs of patients with Waldeyer's ring and sinonasal DLBCL and found that nodal and multifocal diseases were predictors of metastatic disease beyond the neck.¹⁸⁰⁹

In addition to locoregional imaging, full body scans are important for complete staging and prognostication. Most commonly, PET/CT is performed to evaluate hypermetabolic lesions. Alternatively, contrasted chest, abdomen, and pelvis CT scans can be obtained, but potentially may miss nonclinically enlarged lymph nodes that harbor disease. The cost-benefit ratio between these two imaging paradigms has not been well studied in ENKTL and there have been no studies to date on full-body imaging in sinonasal lymphoma.

D | Histopathology

Obtaining the correct pathologic diagnosis is critical for the management of sinonasal lymphoma. This involves biopsy of the lesion and collaboration with a head and neck pathology team for analysis. Sufficient tissue should be obtained from the biopsy to enable appropriate hematopathological analysis including at least one paraffin block representative of tumor.¹⁸¹⁰ In addition to performing a biopsy and histological analysis, several studies have examined laboratory markers, flow cytometry, and

IHC workup of the tissue in order to aid in diagnosis. While many lesions can be biopsied in the office with adequate topical anesthesia, biopsy under general anesthesia may be necessary if initial biopsies are nondiagnostic, in more vascular tumors, or if preferred by the patient.

In both BCL and ENKTL, IHC, in situ hybridization, and flow cytometry should be used to establish the diagnosis.^{1811,1812} The pattern of positive and negative markers allows the pathologist to diagnose the lymphoma subtype in question. Desai et al. evaluated 25 cases of DLBCL, compared tumors arising from the nasopharynx and maxillary sinus, and noted that primary sinonasal DLBCL is histopathologically heterogeneous.¹⁸¹³ NCCN guidelines recommend immunotyping for *CD20*, *CD3*, *CD5*, *CD10*, *CD45*, *BCL2*, *BCL6*, Ki-67, *IRF4/MUM1*, and *MYC*.¹⁸¹⁰ In addition, NCCN recommends cell surface marker analysis by flow cytometry with peripheral blood and/or biopsy specimens: kappa/lambda ratio, *CD45*, *CD3*, *CD5*, *CD19*, *CD10*, and *CD20*.¹⁸¹⁰ Carreras et al. performed a review of 29 patients with primary sinonasal DLBCL and with DNA microarray analysis found a characteristic genomic profile and that high *RGS1* immunohistochemical expression is associated with poor OS.¹⁸¹⁴ Murakami et al. investigated histological subtypes of lymphoma in patients newly diagnosed with malignant lymphoma in the human T-cell leukemia virus type 1 (HTLV-1) endemic area of Japan and found differing survival patterns among DLBCL based on presence of sinonasal tract involvement.¹⁸¹⁵ In another analysis by Toda et al., germinal center and nongerminal center subtypes of DLBCL were compared and found to have no difference in OS.¹⁸¹⁶

With regard to ENKTL, multiple authors have commented on the difficulty of establishing a diagnosis due to the significant amount of tissue necrosis associated.¹⁷⁹⁰ It has been suggested that biopsies with small lymphocytic infiltrates, chronic inflammation, surface ulceration, and bone invasion should make the clinician suspicious for undiagnosed ENKTL in the right clinical context.¹⁸¹⁷ Typical pathologic findings include angiocentricity and angiodestruction.^{1818,1819} EBV in situ testing (EBER) and EBV systemic viral loads are a routine part of the workup given the etiologic role of the virus in ENKTL development.^{1818,1820–1824} IHC panels should include TIA1, CD2, cytoplasmic CD3epsilon, CD5, and CD56 to establish the diagnosis. Flow cytometry targets include CD2, CD3, CD4, CD5, CD7, CD8, CD56, TCR alpha/beta, and TCR gamma/delta.^{1774,1775,1825–1830} Some authors have advocated for testing $\beta 2$ microglobulin ($\beta 2M$) in serum as they have noted worse survival with increasing levels of $\beta 2M$.¹⁸³¹

Histopathologic diagnosis of sinonasal lymphoma and subtypes

Aggregate grade of evidence	C (Level 3: five studies; Level 4: 11 studies; five studies BCL, 11 studies ENKTL)
Benefit	Obtaining an accurate pathologic diagnosis is critical to determining the treatment regimen. Additional testing (e.g., IHC, ISH) helps elucidate the correct clinical diagnosis as determined by the pathologist.
Harm	A potential delay in care or increased costs could result from immunohistochemical and other testing. Biopsy carries risks of pain and bleeding and rare risk of damage to intracranial or orbital contents (depending on the location of the lesion).
Cost	There are no clinical studies examining the cost of obtaining a biopsy, laboratory testing, and resulting pathologic diagnosis in the workup of sinonasal lymphoma.
Benefits-harm assessment	Preponderance of benefits over harms.
Value Judgements	A head and neck and/or hematopathologist with experience in sinonasal lymphoma may benefit the treatment team. Additional studies are needed examining histopathological features predictive of outcomes in sinonasal lymphoma.
Policy level	Recommendation.
Intervention	Determination of an accurate pathologic diagnosis, particular cell type, is critical for guiding treatment for sinonasal lymphoma. Adjunctive laboratory and immunohistochemical testing, specifically flow cytometry and molecular diagnostics, may aid in obtaining diagnosis and may further characterize prognosis for the patient.

E | B-cell sinonasal lymphoma treatment

1 | Role of chemotherapy

BCLs and the most common subtype, DLBCL, are treated predominantly with chemotherapeutic regimens (Table XXVI.2). The most common regimen is CHOP (cyclophosphamide, doxorubicin, vincristine, prednisone) with the addition of rituximab (R-CHOP).¹⁸¹⁰ There are no level 1 studies examining this chemotherapy regimen for

TABLE XXVI.2 Evidence surrounding sinonasal B-cell lymphoma (BCL) treatment.

Study	Year	LOE	Study design	Study groups	Clinical endpoints	Conclusion
Eriksen et al. ¹⁷⁶⁹	2022	3	Retrospective cohort study with pathological confirmation of patients from Danish national cancer registry	205 patients with sinonasal BCL, 163 patients with DLBCL	<ol style="list-style-type: none"> 1. Clinicodemographic characteristics 2. Treatment response 3. OS 	<ol style="list-style-type: none"> 1. DLBCL was the predominant subtype (80%) 2. Sinonasal BCL incidence 0.14/100,000 person-years 3. DLBCL 5-year OS 56% 4. Immunotherapy and rituximab increased OS for DLBCL patients
Vahamurto et al. ¹⁸⁴³	2019	3	Retrospective cohort	46 patients with sinonasal DLBCL: 21 with CHOP or CHOP-like chemotherapy 25 with CHOP + Rituximab	<ol style="list-style-type: none"> 1. Risk of progression 2. OS 	Addition of rituximab to chemotherapy as well as CNS-directed chemotherapy reduced the risk of progression and death and translated into better OS
Lee et al. ¹⁸³⁶	2015	3	Retrospective cohort	80 patients with primary sinonasal tract DLBCL treated with R-CHOP chemotherapy at 22 institutions in Korea	<ol style="list-style-type: none"> 1. OS 2. Response rate 3. Relapse rate 	<ol style="list-style-type: none"> 1. No significant difference in was found in the response rate or OS between groups 2. Patients with sinonasal DLBCL treated with R-CHOP have a relatively low CNS relapse rate and better OS compared to previous studies with CHOP
Laskin et al. ¹⁸³⁴	2005	3	Retrospective cohort	44 patients with primary paranasal sinus lymphoma	<ol style="list-style-type: none"> 1. Response rates 2. Sites of relapse 3. OS 	<ol style="list-style-type: none"> 1. 5- and 10-year OSs were 48% and 41% 2. Intrathecal chemoprophylaxis improved OS from 20% to 51%
Shikama et al. ¹⁸⁹⁵	2001	3	Multicenter retrospective cohort	42 patients with non-Hodgkin's lymphoma of the paranasal sinuses at 25 Japanese institutions	<ol style="list-style-type: none"> 1. OS 2. DFS 	<ol style="list-style-type: none"> 1. 30 out of 42 patients treated with CRT 2. 5-year OS and DFS of all patients were 57% and 59%, respectively
Lehrich et al. ¹⁷⁶⁴	2021	4	Retrospective database study (NCDB)	2073 patients with sinonasal DLBCL	<ol style="list-style-type: none"> 1. OS 2. Survival by treatment modality 	<ol style="list-style-type: none"> 1. Patients treated with CRT had improved OS compared to those treated with chemotherapy alone. 2. Patients receiving immunotherapy had significantly improved OS after 2012
Brown et al. ¹⁸⁴⁴	2021	4	Retrospective database study (NCDB)	2222 patients with sinonasal DLBCL	<ol style="list-style-type: none"> 1. OS 2. Survival by treatment modality 	<ol style="list-style-type: none"> 1. OS was 62% at 5 years and 42% at 10 years 2. CRT + immunotherapy offers increased survival in patients with advanced disease

(Continues)

TABLE XXVI.2 (Continued)

Study	Year	LOE	Study design	Study groups	Clinical endpoints	Conclusion
Varelas et al. ¹⁸³⁵	2019	4	Retrospective database study (SEER)	1273 cases of DLBCL of the sinonasal tract	1. Clinicodemographic factors 2. OS	1. Most common primary sites were maxillary sinus and nasal cavity 2. OS was 70% at 2 years and 54% at 5 years 3. Chemotherapy and RT were associated with improved prognosis
Han et al. ¹⁸⁴⁰	2017	4	Retrospective database study (SEER)	1119 nasopharyngeal lymphoma cases (77.5% BCL)	1. OS 2. DSS	1. Advanced age, higher Ann Arbor stage, and ENKTL histology associated with worse OS and DSS 2. RT associated with improved OS and DSS
Steele et al. ¹⁸³⁹	2016	4	Retrospective case series	18 patients with sinonasal lymphoma	1. OS 2. Survival by treatment modality	1. Survival rates by lymphoma subtype were 56% for BCL 2. CRT resulted in significantly higher OS rates than chemotherapy alone
Lombard et al. ¹⁸⁹⁶	2015	4	Retrospective case series	22 patients with non-Hodgkin lymphoma of the sinonasal cavity	OS	1. OS was 82% at 12 months and 73% at 36 months 2. Prognosis depends on histologic type, Ann Arbor stage at diagnosis, and the therapeutic options
Kanamuri et al. ¹⁷⁶⁵	2014	4	Retrospective database study (SEER)	852 cases of sinonasal DLBCL in SEER	1. DSS 2. Survival by treatment modality	1. Survival is significantly improved for those treated with RT 2. Involvement of multiple sinuses is a negative prognostic factor
Oprea et al. ¹⁸³³	2005	4	Retrospective case series	14 consecutive DLBCL cases treated with CHOP	Complete or partial remission (CR and PR)	1. With a CHOP or CHOP-like chemotherapy regimen, 10 achieved CR and three PR 2. During 80-month follow-up, seven relapsed or progressed (four in the CNS) 3. Consider CNS prophylaxis in sinonasal lymphoma
Proulx et al. ¹⁷⁶⁶	2003	4	Retrospective case series	23 patients with extranodal non-Hodgkin's lymphoma of the paranasal sinuses	OS	1. OS for the entire group at 10 years was 78% 2. Combined-modality approach with locoregional RT and systemic chemotherapy is recommended
Quraishi et al. ¹⁸⁹⁷	2001	4	Retrospective case series	24 patients with non-Hodgkin's lymphoma of paranasal sinuses	OS	1. OS at 5 years was 40% 2. DSS was 62%
Hausdorff et al. ¹⁸³⁸	1997	4	Retrospective case series	16 consecutive patients with paranasal sinus lymphoma treated with chemotherapy and RT	1. Clinical response 2. OS	1. Combined modality therapy with CNS prophylaxis improves outcome compared with RT alone 2. 5-year OS was 29%

(Continues)

TABLE XXVI.2 (Continued)

Study	Year	LOE	Study design	Study groups	Clinical endpoints	Conclusion
Cooper and Ginsberg ¹⁸³⁷	1992	4	Retrospective case series	Four consecutive patients with paranasal sinus lymphoma treated with 6 weeks of chemotherapy followed by RT and CNS prophylaxis	Clinical resolution of disease	1. All patients had complete response to treatment 2. One patient developed an osteogenic sarcoma in the radiation field 32 months after treatment

Abbreviations: CRT, chemoradiation therapy; DLBCL, diffuse large B-cell lymphoma; DFS, disease-free survival; DSS, disease-specific survival; ENKTL, extranodal NK/T-cell lymphoma; NCDDB, National Cancer DataBase; OS, overall survival; SEER, Surveillance, Epidemiology, and End Results.

treatment of sinonasal lymphoma. Current NCCN guidelines for sinonasal lymphoma chemotherapy regimens have been extrapolated from level 1 evidence in BCLs outside of the sinonasal tract.^{1810,1832} Current regimens include R-CHOP for three cycles for nonbulky disease or R-CHOP for five cycles for bulky disease (≥ 7.5 cm).¹⁸¹⁰

Oprea et al. present a case series of 14 consecutive patients with sinonasal DLBCL treated with CHOP or a CHOP-like regimen.¹⁸³³ Ten patients achieved complete remission and three achieved partial remission. During the 80-month follow-up period, seven relapsed or progressed (with four developing CNS disease).¹⁸³³ The authors recommend considering CNS prophylaxis for sinonasal lymphoma. Similarly, Laskin et al. reviewed 44 patients with primary paranasal sinus lymphoma and found that intrathecal chemoprophylaxis, added to a regimen of chemotherapy and local irradiation, was associated with an improved OS from 20% to 50%.¹⁸³⁴ In an analysis of the SEER registry, Varelas et al. found that chemotherapy was associated with an improved prognosis in 1273 cases of sinonasal DLBCL.¹⁸³⁵ Future studies are needed to examine additional chemotherapeutic regimens in sinonasal lymphoma treatment.

Role of chemotherapy: B-cell lymphoma

Aggregate grade of evidence	B (Level 3: four studies; Level 4: eight studies)
Benefit	Chemotherapy has been associated with improved survival in patients with sinonasal BCL.
Harm	Risks of morbidity from chemotherapeutic regimens, including R-CHOP for three or five cycles, and any potential morbidity from CNS prophylaxis regimens.

(Continued)

Cost	There have been no clinical studies examining the cost of chemotherapy in the treatment of sinonasal lymphoma.
Benefits-harm assessment	Preponderance of benefits over harms.
Value judgments	When considering chemotherapeutic treatment, clinicians should have a detailed conversation with their patients about the risks and benefits of the treatment along with a realistic discussion of potential treatment outcomes. CNS prophylaxis may be considered, and some studies have shown a potential survival benefit.
Policy level	Recommendation.
Intervention	Chemotherapy is the preferred option in the treatment of sinonasal BCL. The most common regimens include CHOP or CHOP-like therapy.

2 | Role of radiation therapy

The exact role of RT in the management of B-cell sinonasal lymphoma is controversial. Traditionally, in nonsinonasal localized DLBCL, RT has been used in patients with bulky disease, partial chemotherapeutic response, extranodal disease, or unacceptable toxicity from prior chemotherapy.¹⁸³⁶ In sinonasal lymphoma, RT has been used more commonly due to the extranodal disease presence and oftentimes bulky symptomatic tumor.

Several studies have found survival benefit in B-cell sinonasal lymphoma patients treated with RT. In their analysis of the SEER registry, Varelas et al. found that RT was associated with improved prognosis in 1273 cases of sinonasal DLBCL.¹⁸³⁵ In another SEER analysis, Kanamuri examined 852 patients with sinonasal DLBCL and also found improved survival with RT.¹⁷⁶⁵ In a series of four patients with sinonasal lymphoma treated with 6 weeks of chemotherapy followed by RT and CNS prophylaxis, all patients had complete treatment response,

although one patient developed an osteogenic sarcoma in the radiation field 32 months after treatment.¹⁸³⁷ Hausdorf et al. reviewed 16 consecutive patients with sinonasal lymphoma and reported that multimodal therapy with CNS prophylaxis improved outcomes as compared with RT alone.¹⁸³⁸ Similarly, Proulx et al. recommend a combined modality approach with locoregional RT and systemic chemotherapy.¹⁷⁶⁶ In their institutional series, Steele et al. reviewed 18 patients with sinonasal lymphoma and found that a combination of chemotherapy and RT resulted in significantly higher survival rates than chemotherapy alone (OS 70% vs. 29%).¹⁸³⁹

In contrast, Lee et al. performed a retrospective analysis of 88 patients with sinonasal DLBCL treated with R-CHOP alone ($n = 59$) or R-CHOP with RT ($n = 21$).¹⁸³⁶ Despite having higher Ann Arbor stage patients in the R-CHOP alone group, there were no significant differences in the response rate or OS between the two groups.¹⁸³⁶ For nasopharyngeal lymphoma, Han et al. found in a cohort of 1119 patients (77.5% BCL) that RT was an independent predictor of survival.¹⁸⁴⁰ Given these divergent findings, future work should examine the precise indications and potential benefits of RT in B-cell sinonasal lymphoma.

Role of radiation therapy: B-cell lymphoma

Aggregate grade of evidence	C (Level 3: one study; Level 4: eight studies)
Benefit	RT may help reduce the disease burden in patients with bulky disease, partial chemotherapeutic response, and extranodal involvement. Some studies have shown improved survival in sinonasal DLBCL patients who received RT in addition to chemotherapy.
Harm	Potential morbidity from radiation treatment.
Cost	There are no studies examining the cost of RT in sinonasal BCL.
Benefits-harm assessment	Balance of benefits and harms.
Value judgments	RT should be considered in the treatment of sinonasal lymphoma as an adjunct to chemotherapy in patients with bulky, symptomatic disease, advanced stage, or a partial response to chemotherapy. Patients should be counseled regarding the potential morbidity of RT as well as the uncertain impact on survival.
Policy level	Option.
Intervention	The addition of RT to chemotherapeutic regimens should be considered for sinonasal BCL patients with symptomatic (i.e., cranial nerve palsies), bulky disease or advanced stage.

3 | Role of immunotherapy

The advent of immunotherapy treatments, most significantly rituximab, an anti-CD20 monoclonal antibody, has dramatically improved survival and related outcomes for sinonasal BCL patients.¹⁸⁴¹ Rituximab has a relatively low side effect profile compared to other treatment regimens including CHOP for sinonasal lymphoma.¹⁸⁴¹ Nonetheless, there are severe potential side effects including infusion-related reactions, severe skin and mouth reactions, hepatitis B reactivation, or progressive multifocal leukoencephalopathy.¹⁸⁴²

Vahamurto et al. performed a retrospective cohort study examining 46 sinonasal DLBCL patients.¹⁸⁴³ Twenty-two patients received CHOP or CHOP-like chemotherapy and 25 received R-CHOP (CHOP with rituximab). The R-CHOP group had a significantly reduced risk of progression (RR 0.368, $p = 0.045$) and death (RR 0.245, $p = 0.032$) and translated into better survival (5-year PFS, 67% vs. 38%, $p = 0.037$; 5-year OS, 81% vs. 48%, $p = 0.020$).¹⁸⁴³ Eriksen et al. reviewed 205 patients in the Danish National Lymphoma Registry with B-cell sinonasal lymphoma and found that immunotherapy increased survival for DLBCL patients.¹⁷⁶⁹

Lehrich et al. performed a retrospective review of the NCDB and found that, after 2012, patients receiving immunotherapy had significantly improved OS.¹⁷⁶⁴ In another NCDB analysis, multimodal therapy (e.g., chemotherapy, RT, immunotherapy) was found to offer increased survival in patients with advanced disease.¹⁸⁴⁴ Further studies are needed to examine the role of other immunotherapeutics in sinonasal lymphoma.

Role of immunotherapy: B-cell lymphoma

Aggregate grade of evidence	B (Level 3: two studies; Level 4: two studies)
Benefit	The addition of rituximab to CHOP treatment regimens significantly improves survival for patients with sinonasal BCL.
Harm	Potential morbidity, including infusion-related reactions and severe skin and mouth reactions, from the addition of immunotherapy to chemotherapeutic treatment regimens.
Cost	There are no clinical studies addressing the cost of immunotherapeutics in the treatment of sinonasal lymphoma.
Benefits-harm assessment	Preponderance of benefits over harms.

(Continued)

Value judgments	Patients should be counseled on the risks of rituximab treatment as well as the potential benefits including improved OS.
Policy level	Recommendation.
Intervention	Rituximab should be added to CHOP for the treatment of sinonasal BCL given survival benefits.

F | Extranodal natural killer/T-cell sinonasal lymphoma treatment

Chemotherapy and RT are the mainstays of treatment for ENKTL. The sequence of treatment is dependent on disease stage and site. In patients with stage I or II disease, curative therapy is determined based on the patient's functional status. In patients who cannot tolerate chemotherapy, RT alone may be offered. There have been several studies that suggest that RT improves LRC.^{1766,1839,1845} In patients who can tolerate chemotherapy, combined modality therapy with both chemotherapy and RT is generally recommended. Lehigh et al. found that CRT appeared to confer a survival benefit when compared to chemotherapy or RT alone, for both early- and late-stage ENKTL patients.¹⁸⁴⁶ The preferred regimen for concurrent treatment is RT and three courses of DeVIC (dexamethasone, etoposide, ifosfamide, and carboplatin). Alternatively, RT and cisplatin followed by three cycles of VIPD (etoposide, ifosfamide, cisplatin, and dexamethasone) could be considered. Other options if concurrent treatment is not pursued are the “sandwich” regimen (pegaspargase, gemcitabine, oxaliplatin [P-GEMOX] × two cycles followed by RT, and then another two to three rounds of P-GEMOX) or sequential regimen (for stage I and II, modified steroid [dexamethasone], methotrexate, ifosfamide, pegaspargase, and etoposide [SMILE] two to four cycles followed by RT).^{1787,1847} There are no robust studies for guidance on differential survival benefits for a particular patient and no recommendation can be made on differential survival by treatment regimen. For stage III/IV ENKTL, outcomes are generally poor regardless of treatment method used. Clinical trials, combined modality therapy (identical to those listed for stage I/II), and asparaginase-containing regimens with or without RT (modified SMILE four to six cycles—steroid [dexamethasone], DDGP [dexamethasone, cisplatin, gemcitabine, pegaspargase]) are options for patients with advanced disease.¹⁸⁴⁸

There have been several studies that suggest anthracycline regimens (e.g., CHOP) are insufficient for disease control, resulting in the current recommendations for treatment.^{1773,1777,1849–1854} In general, it has been suggested that stage I and II diseases do not need CNS prophylaxis, while stages III and IV should be offered CNS prophylaxis.¹⁸⁵⁵ Several known negative prognostic factors

have been included in the Prognostic Index of Natural Killer lymphoma (PINK) and include age >60 years, stage III or IV disease, distant lymph node involvement, and nonnasal disease.¹⁸⁵⁶

The role of immunotherapy in ENKTL has not been well described to date, and the primary indication for immunotherapy has been for refractory or otherwise untreatable disease. Current recommendations favor enrollment in a clinical trial to allow for data collection, but pembrolizumab and nivolumab have been used when immunotherapy is desired. Future research into outcomes and appropriate patient selection is needed. Table XXVI.3 summarizes evidence surrounding sinonasal ENKTL treatment.

Role of chemotherapy: Extranodal NK/T-cell lymphoma

Aggregate grade of evidence	C (Level 4: 24 studies)
Benefit	Chemotherapy is a cornerstone to ENKTL treatment, and current evidence suggests a survival benefit with treatment.
Harm	Chemotherapeutics are known to be toxic with common side effects including hematologic disturbances (e.g., pancytopenia), which can be severe and life threatening.
Cost	Cost of treatment is significant, especially if several cycles of therapy are required for effect.
Benefits-harm assessment	Preponderance of benefits over harms.
Value judgments	In patients with severe comorbidities, RT alone or enrollment in clinical trials can be considered.
Policy level	Recommendation.
Intervention	Chemotherapy, as the first-line treatment, should be offered to patients with ENKTL if they are able to tolerate treatment, despite its known toxicities.

Role of radiation therapy: Extranodal NK/T-cell lymphoma

Aggregate grade of evidence	C (Level 4: 24 studies)
Benefit	RT has been demonstrated to improve LRC and recommended for almost all treatment paradigms outside clinical trials.
Harm	RT has significant potential morbidity in terms of damage to adjacent tissue, including risks of vision loss and brain necrosis in extreme cases.

(Continued)

TABLE XXVI.3 Evidence surrounding sinonasal ENKTL treatment.

Study	Year	LOE	Study design	Study groups	Clinical endpoints	Conclusion
He et al. ¹⁸⁹⁸	2021	4	Retrospective database study (SEER)	714 patients treated nationally for ENKTL	1. OS 2. DSS	1. Nonnasal ENKTLs have shown improved OS over time 2. There has been no change in survival in nasal ENKTL 3. Univariate analysis showed lack of RT was associated with shorter OS/DSS, but this was not significant on multivariate analysis
Lehrich et al. ¹⁸⁴⁶	2021	4	Retrospective database review (NCDB)	785 patients with ENKTL	OS	1. CRT confers OS benefit compared to chemotherapy or RT alone for both early- and late-stage cohorts 2. Older age, paranasal sinus site, more comorbidities, and higher Ann Arbor stage predicted worse OS 3. RT and chemotherapy associated with improved OS
Gupta et al. ¹⁸⁴⁷	2018	4	Retrospective case series	16 patients with stage I or II disease treated with SMILE regimen and RT at 45–50 Gy	1. OS 2. PFS	1. 2-year OS was 74% and 2-year PFS was 70% 2. SMILE may offer reasonable control at the cost of significant toxicity
Wu et al. ¹⁸⁹⁹	2017	4	Retrospective case series	105 patients with ENKTL treated with RT (median dose 50 Gy) with 40 patients receiving chemotherapy as well (unspecified regimen)	Prognostic value of imaging characteristics	1. 5-year OS was 72.8% 2. PFS 65.2%
Niu et al. ¹⁹⁰⁰	2016	4	Retrospective case series	215 patients treated at a single institution (all stage IE or IIE); 211 received CRT and four received RT. CHOP or CHOP-like regimen used in 175, L-asparaginase in 31 patients, and five received other chemotherapy regimen. Median RT dose was 55 Gy	1. OS 2. Risk factors for treatment failure	OS was higher for nasal than extra-nasal ENKTL (68.2 vs. 46%) at 5 years
Steele et al. ¹⁸³⁹	2016	4	Retrospective case series	Five ENKTL patients treated at a single institution, with four patients undergoing combined CRT (unspecified regimen)	OS	1. OS for ENKTL group was found to be 40% 2. Survival benefit was seen with CRT compared to chemotherapy alone

(Continues)

TABLE XXVI.3 (Continued)

Study	Year	LOE	Study design	Study groups	Clinical endpoints	Conclusion
Michot et al. ¹⁹⁰¹	2015	4	Retrospective case series	13 patients treated at a single institution (all stage IE or IIE) treated with two cycles of ESHAP and RT (40 Gy dose), followed by consolidation dose of two to three rounds of ESHAP	<ol style="list-style-type: none"> OS Adverse side effects 	<ol style="list-style-type: none"> 2-year survival was 72% 92% experienced grade 2 or 3 neutropenia
Coha et al. ¹⁸⁴⁹	2014	4	Retrospective case series	Three patients with ENKTL treated at a single institution; two treated with CHOP (and RT), one had CHOP (two rounds) but passed away prior to completing treatment	OS	Anthracycline regimens (e.g., CHOP) are insufficient for disease control
Youssef et al. ¹⁹⁰²	2012	4	Retrospective case series	23 patients with ENKTL treated at a single institution 10 received CRT and nine received chemotherapy alone Several chemotherapy regimens included, with some including etoposide and asparaginase	OS	Study noted resistance to asparaginase-based protocols
Kim et al. ¹⁸⁵⁵	2010	4	Retrospective case series	208 ENKTL patients treated at a single center; 138 treated with anthracycline chemotherapy (with or without RT), 60 patients nonanthracycline (IMEP, SMILE, or VIPD) regimens, five RT only, and five supportive care	Development of CNS disease	<ol style="list-style-type: none"> 12 patients developed CNS disease (5.76%) ENKTL international prognostic index groups I and II do not need CNS prophylaxis, while III and IV should receive it
Ma et al. ¹⁸⁵³	2010	4	Retrospective case series	64 patients with early-stage sinonasal ENKTL (stage IE or IIE); 23 treated with RT and 41 treated with CRT using anthracycline-based chemotherapy	<ol style="list-style-type: none"> OS PFS 	<ol style="list-style-type: none"> 5-year OS for RT was 57.9% and CRT was 61.5%, no significant difference between treatments Chemotherapy does not improve survival in early-stage disease

(Continues)

TABLE XXVI.3 (Continued)

Study	Year	LOE	Study design	Study groups	Clinical endpoints	Conclusion
Guo et al. ¹⁸⁵⁰	2008	4	Retrospective case series	57 patients with Stage I and II disease treated with combined CRT (CHOP—cyclophosphamide, Adriamycin, vincristine, prednisone), six patients with stage III or IV who underwent CHOP who underwent RT if remission achieved	1. OS 2. PFS	There may be benefit to PFS with oral nitrosourea, but no difference in OS
Wang et al. ¹⁸⁵⁴	2007	4	Retrospective case series	53 patients with stage IE/IIIE disease treated with CHOP chemotherapy followed by RT (median 45 Gy)	1. OS 2. PFS	1. 2-year OS was 75.6% and 2-year PFS was 61.8% 2. Chemotherapy followed by RT produced suboptimal outcomes
Kim et al. ¹⁹⁰³	2006	4	Retrospective case series	43 patients with ENKTL (29 nasal/nasopharynx, 14 upper aerodigestive) treated with CEOP-B (cyclophosphamide, epirubicin, vincristine, prednisone) 26 had chemotherapy alone, 17 had CRT	1. OS 2. Treatment response	1. Overall response was 67.4% 2. Local relapse higher in chemotherapy-only group, but RT did not improve survival 3. CEOP-B has limited role in ENKTL treatment
Lee et al. ¹⁸⁵²	2005	4	Retrospective case series	90 patients with ENKTLs of any site treated with anthracycline chemotherapy ± RT, nonanthracycline chemotherapy ± RT, RT alone, or supportive care only	1. OS 2. Treatment response	Higher survival in upper aerodigestive disease versus other location (54% vs. 20%)
Kim et al. ¹⁸⁵¹	2004	4	Retrospective case series	84 patients with sinonasal lymphoma (19 B cell, 27 T cell, 34 ENKTL); 45 patients underwent RT alone (median 50.4 Gy), chemotherapy was left to physician discretion	1. OS 2. DSS	5-year OS was 37%, DSS 37% for ENKTL, results not specified by treatment type

(Continues)

TABLE XXVI.3 (Continued)

Study	Year	LOE	Study design	Study groups	Clinical endpoints	Conclusion
Li et al. ¹⁷⁷⁷	2004	4	Retrospective case series	77 patients with sinonasal ENKTL treated at a single center; 12 treated with RT, 28 chemotherapy alone, 37 treated with CRT (RT 40–50 Gy; chemotherapy CHOP, E-CHOP, or ESHAP)	<ol style="list-style-type: none"> OS Disease response 	Achievement of complete response only prognostic factor that was significant
Proulx et al. ¹⁷⁶⁶	2003	4	Retrospective case series	Eight patients with ENKTL treated at a single institution with combined RT (three of the total 23 patients including other lymphomas received chemotherapy, unspecified which pathology they represented)	OS	<ol style="list-style-type: none"> 5-year estimated OS was 88% Early stage responded well to RT, but distant failure remains a problem
Hahn et al. ¹⁷⁷³	2002	4	Retrospective case series	20 patients with ENKTL treated at a single institution (14 within the nasal cavity or nasopharynx). Seven received RT only, four chemotherapy only, nine CRT (chemotherapy 6 weeks Adriamycin-containing regimen, RT 40–45 Gy)	<ol style="list-style-type: none"> OS Treatment response 	<ol style="list-style-type: none"> Complete remission was 65% for ENKTL OS was 13 months for ENKTL Difference between treatment modalities not calculated
Ribrag et al. ¹⁸⁴⁵	2001	4	Retrospective case series	20 patients with stage I or II ENKTL treated at a single institution. Six treated with RT (two subsequently received chemotherapy), two received CRT, and 12 received initial chemotherapy (CHOP or CHOP-like) (nine of which went on to receive RT)	OS	Initial chemotherapy for early disease performed worse than upfront RT

(Continues)

TABLE XXVI.3 (Continued)

Study	Year	LOE	Study design	Study groups	Clinical endpoints	Conclusion
Aviles et al. ¹⁹⁰⁴	2000	4	Retrospective case series	108 patients with ENKTL treated with 45 Gy RT followed by combination chemotherapy—cyclophosphamide, epirubicin, vincristine, prednisone, and bleomycin (given every 21 days for six cycles)—at a single institution	1. OS 2. DFS	1. Complete response achieved in 99 patients (91.7%) with treatment 2. 8-year OS 82%, 90%, and 84% and DFS 79%, 83%, and 80% 3. No prognostic factors were found to be significant
Rodriguez et al. ¹⁹⁰⁵	2000	4	Retrospective case series	13 patients treated at a single institution	OS	1. OS 38% at 9 years, one patient alive with disease 2. Response to doxorubicin-based therapeutics is worse than other non-Hodgkin lymphomas
Sakata et al. ¹⁹⁰⁶	1997	4	Retrospective case series	16 patients with ENKTL treated at a single institution, all received RT and 14 also underwent chemotherapy (VEPA before RT in the majority of patients)	OS	1. 5-year OS was 22% 2. Authors suggest a more aggressive treatment regimen including >50 Gy RT
Senan et al. ¹⁹⁰⁷	1992	4	Retrospective case series	Eight cases of ENKTL treated at a single institution with 45–50 Gy RT and alkylating agents (unspecified)/prednisolone for relapse	OS	1. Six remained alive (at undesignated time point), two died of unrelated causes, four required chemotherapy for salvage (OS 75%) 2. No recommendation given based on small number
Yi et al. ¹⁸⁴⁸	2022	N/A	Nonsystematic review	N/A	N/A	1. ENKTL is resistant to anthracycline-based chemotherapeutics 2. L-Asparaginase therapy with or without RT shows promise 3. Future directions include immune-checkpoint inhibitors, histone deacetylase inhibitors, and monoclonal antibodies

Abbreviations: CRT, chemoradiation therapy; DFS, disease-free survival; DSS, disease-specific survival; ENKTL, extranodal NK/T-cell lymphoma; NCDB, National Cancer DataBase; OS, overall survival; SEER, Surveillance, Epidemiology, and End Results.

Cost	There is significant cost to the intervention including institutional costs for equipment and patient time and morbidity from treatment.
Benefits-harm assessment	Preponderance of benefits over harms.
Value judgments	Patients who have received previous head and neck radiation deserve careful consideration of the morbidity of reirradiation given increased side effects.
Policy level	Recommendation.
Intervention	RT should be offered to all patients undergoing treatment for ENKTL for LRC benefits.

G | Extramedullary plasmacytoma

Extramedullary plasmacytomas (EMPs) are rare malignancies composed of monoclonal plasma cells. EMPs are a subset of solitary plasmacytomas (SPs) and lie on the disease spectrum of plasma cell dyscrasias. EMPs are positioned between monoclonal gammopathy of undetermined significance (MGUS), which is premalignant and often clinically silent, and multiple myeloma (MM).¹⁸⁵⁷ SPs are characterized by their isolated, localized nature, compared to MM, which is disseminated. SPs can be further subdivided into EMPs, which arise from extraosseous soft tissue, and solitary plasmacytoma of bone (SPB), which has a bony origin. The chief clinical impact of EMPs and SBPs, other than symptoms arising from the mass, is the risk posed by their possible progression to MM.

In 2014, the International Myeloma Working Group (IMWG) has proposed diagnostic criteria to separate these clinicopathological entities in light of differences in treatment options and prognostic implications. It recommended that SPs be diagnosed on the basis of (1) biopsy-proven solitary bone (SPB) or soft tissue (EMP) lesion showing clonal plasma cells, (2) normal bone marrow studies, (3) normal skeletal survey and MRI (or CT) of the spine and pelvis, and (4) an absence of end-organ damage such as hypercalcemia, renal insufficiency, anemia, or bone lesions that can be attributed to a lymphoplasmacytic cell proliferative disorder.¹⁸⁵⁸

If marrow studies demonstrate infiltration of clonal plasma cells, but these remain <10% of all nucleated cells, these lesions are classified as “solitary plasmacytoma with minimal marrow involvement” and carry a poorer prognosis than EMPs with no marrow involvement. The presence of over 10% of clonal plasma cells in marrow studies raises the suspicion of MM or smoldering MM.

1 | Presentation

SPs are rare and represent less than 5% of all blood cell dyscrasias.¹⁸⁵⁹ EMPs make up about one third of these disorders,¹⁸⁶⁰ with an incidence of 0.04–3 per 100,000.¹⁸⁶¹ EMPs can occur anywhere in the body, but most frequently arise in the head and neck region, accounting for approximately 1% of all head and neck tumors.¹⁸⁶¹ They have a predilection for the nasal cavity, paranasal sinuses, and nasopharynx.¹⁸⁶² Other sites of involvement include the oropharynx, salivary glands, and larynx. SPs of the skull base are most commonly found at the sphenoclivar region; other common skull base sites include the petrous apex and orbital roof.¹⁸⁶³

EMPs most frequently affect middle-aged patients, and the diagnosis is usually made in the fifth decade of life.¹⁸⁶¹ Patients typically present between 30 and 60 years of age, although EMP has been diagnosed in children as young as 5. Males are two to three times more likely to be affected.¹⁸⁶¹ EMPs have been reported in association with EBV and HIV infection, although a causal relationship has not been definitively established.^{1864,1865}

EMPs have been found to have a lower rate of conversion to MM (10%–30%),¹⁸⁶⁶ as compared to SBPs, which have a progression rate reported between 48% and 85%.¹⁸⁶¹ Conversion to MM appears to be most likely within the first 2 years of diagnosis, but it has been described up to 15 years later.¹⁸⁶⁷ Once MM develops, the 10-year OS has been reported to be under 10%.¹⁸⁶¹ That said, there are observations that the prognosis for those who develop MM from an initial EMP could be more favorable than those who directly developed MM.¹⁸⁶⁷

The clinical presentation of sinonasal EMPs varies with the anatomical location of the tumor.¹⁸⁶¹ Nasal obstruction and epistaxis are the most frequently reported symptoms. Patients with maxillary sinus involvement may present with facial swelling or pain, while those with tumor extension to the orbit may have diplopia, visual changes, or proptosis. Headache can also be a feature but is less common and nonspecific. Patients with skull base EMPs may present with cranial nerve palsies resulting in ptosis, diplopia, hearing loss, or imbalance. In many of these patients, the diagnosis may only be made in retrospect after initial surgical resection.¹⁸⁶³ On nasal endoscopy, the tumors present as a fleshy, hyperemic, or hemorrhagic¹⁸⁶⁸ mass with contact bleeding.¹⁸⁶⁹ There may be associated superficial ulceration¹⁸⁷⁰ and necrosis. Larger lesions may cause a visible mass of the maxilla, palate, or orbit.¹⁸⁷¹

2 | Workup

Traditional X-ray methods have largely been supplanted by cross-sectional imaging modalities such as CT and MRI, as these are superior in assessing the extent of local disease and excluding distant lesions. On CT imaging, EMPs often appear as solitary enhancing soft tissue lesions. There may be local remodeling of adjacent bone or lytic bone destruction consistent with its malignant nature.¹⁸⁷² On MRI sequences, EMPs are generally isointense to muscle on T1, are iso- to hyperintense on T2, and enhance heterogeneously with gadolinium-based contrast.¹⁸⁷³ Areas of necrosis, vascular encasement, or infiltration of adjacent structures may be seen. CT and MRI serve complementary roles as CT is better able to delineate bony anatomy and areas of erosion or dehiscence, whereas MRI provides superior soft tissue definition and can assist in distinguishing areas of tumor from inspissated secretions and surrounding anatomical structures. However, imaging alone is often insufficient to reliably distinguish EMPs from other SNM and histology is required to make the diagnosis.

Nuclear studies also play a useful role in the evaluation of EMPs. Although the use of gallium and thallium radioisotopes has been described previously,¹⁸⁷⁴ recent interest has centered on the use of PET fused with CT (PET-CT). These are useful in confirming the diagnosis of EMP by excluding distant lesions and were proposed as an alternative to whole-body MRI by the IMWG in 2017.¹⁸⁷⁵ PET-CT was found to be the imaging technique with greatest sensitivity and specificity for detecting clonal plasma cells, particularly outside the bone marrow. PET-CTs could yield prognostic information based on the degree of 18-FDG uptake, and are also useful as follow-up studies to assess treatment response.¹⁸⁷⁶

Laboratory tests are required in the diagnostic process to exclude other diagnoses on the plasma cell dyscrasia spectrum. All patients suspected of having EMPs should have a bone marrow aspiration and trephine biopsy that uses a wide caliber needle obtaining a greater sampling. Serum and urine protein electrophoresis are helpful in evaluating an “M” spike that indicates monoclonal paraproteinemia. Its persistence after initial treatment indicates a poorer prognosis.²⁰ Immunofixation electrophoresis can provide further specific information on the type of “M” protein and can be used to monitor patients for posttreatment response or relapse. Serum free light chains can also be quantified and serve a similar role.¹⁸⁷⁷

Histopathological analysis of biopsy specimens often reveals a monomorphic population of neoplastic plasma cells, which may have eccentric nuclei with chromatin arranged in a “cartwheel pattern,”¹⁸⁷⁸ cytoplasmic perinuclear hof, and abundant basophilic cytoplasm.¹⁸⁵⁷

Immunohistochemical staining is positive for CD138 (a protein specific to differentiated plasma cells) and epithelial membrane antigen and negative for CD45 (marker for hematopoietic cells) and CD20 (B-cell marker not found on plasma cells). Neoplastic cells are monoclonal with surface expression of kappa or lambda. These findings help distinguish EMPs from inflammatory processes that may be rich in plasma cells. An anaplastic subtype of EMPs has been described with characteristic increased number of mitotic figures.¹⁸⁷⁹ It may be difficult to distinguish EMPs from a low-grade BCL with significant plasma cell differentiation. Flow cytometry may be helpful in these cases, as EMPs rarely express CD45 and CD19.¹⁸⁸⁰

3 | Treatment

SPs, including EMPs, are radiosensitive, and RT is the primary treatment modality for these tumors. The latest NCCN guidelines recommend upfront RT with 40–50 Gy in 1.8–2.0 Gy fractions.¹⁸⁸¹ The evidence for the effectiveness of RT primarily stems from retrospective studies, with the largest study showing a 5-year OS rate of 74%, disease-free survival of 50%, and local control of 85%.¹⁸⁸²

Surgery is recommended primarily in the setting of spinal instability or neurological compromise due to mass effect, but these considerations are generally less applicable to sinonasal EMPs. As part of the diagnostic workup, some patients undergo surgical excision and good outcomes have been reported in some instances where negative margins have been achieved.^{1859,1861,1883} However, this remains controversial as others have found that surgery alone without adjuvant RT leads to poor local control.¹⁸⁸²

Chemotherapy has an uncertain role due to mixed evidence for its effectiveness. While some studies suggest that adjuvant chemotherapy could delay progression to MM, others have shown no benefit.¹⁸⁷⁶

4 | Prognosis and outcomes

Close follow-up is required to monitor for relapse and to watch for transformation to MM in those with persistent disease. This should be done initially on a 3- to 6-month basis but can be lengthened subsequently, especially in EMPs due to their better prognosis.¹⁸⁸¹ Blood and urine tests for “M” protein are helpful as its disappearance in patients with initially detectable levels gives further confirmation of successful ablation, and its reemergence could indicate relapse. Serial imaging is an important component of surveillance and MRI or PET-CT can be used. This should be performed on a yearly basis, ideally with the same modality that was used to make the initial diagno-

sis. Should progression to MM occur, systemic therapy will then be indicated with a possible role for bone marrow transplantation. Population-based studies have reported generally favorable outcomes, with 5- and 10-year outcomes greater than 80%,¹⁸⁸⁴ and pooled systematic reviews have reported somewhat lower survival rates (71.8% at median 39 months follow-up).¹⁸⁶¹

XXVII | METASTATIC TUMORS

Metastases of extranasal malignant tumors to the sinonasal region are extremely rare, with fewer than 200 cases described in the literature since 1947. Due to its low occurrence rate, the data hereby have been acquired by retrospective case reports and small case series. Similar to primary sinonasal tumors, the presenting symptoms of sinonasal metastases are nonspecific and determined by the involved sinonasal site and primary tumor pathology. Metastases tend to be quite vascular, and the most common presenting sign is epistaxis. Metastases originating from the nasal cavity and maxillary sinus often present with nasal obstruction, rhinorrhea, facial pain, and numbness, whereas headache, visual impairment, proptosis, and diplopia are more common with sphenoid sinus and orbital involvement. Skull base or cavernous sinus extension can result in cranial nerve dysfunction and visual alterations. Sometimes, the patient will experience symptoms related to the primary disease (e.g., shortness of breath for lung cancer).^{1908,1909}

The most common metastatic tumor affecting the sinonasal region is renal cell carcinoma (RCC), which accounts for 50% of cases. However, most primary tumors can result in sinonasal metastases, and the most frequently reported are lung, breast, gastrointestinal tract, liver, urogenital, thyroid, and skin malignancies. Rarely are sinonasal metastases derived from an unknown origin. Primary sinonasal tumors and local extension of a primary tumor involving the oral cavity, orbit, and intracranial cavity should also be considered. The maxillary sinus is involved in 36%–50% of cases, followed by the sphenoid, ethmoid, and frontal sinuses and nasal cavity.^{159,1910–1914} A very small number of cases of metastasis to the nasal tip and septum have been reported.¹⁹¹⁵ Mean age and risk factors for patients with sinonasal metastases vary depending on the primary tumor pathology. Sinonasal involvement can be synchronous with the primary presentation but can also present more than a decade after the original tumor is diagnosed. Generally, since metastatic disease indicates an advanced stage of the primary disease, the prognosis is grim at the point of presentation and is often associated with poor QOL and mortality. However, early detection and diagnosis, coupled with aggressive treat-

ment, may improve sinonasal symptoms and, in selected cases, prolong survival.^{1910–1912}

Hematogenous, lymphatic, and direct spread of tumor have been postulated as the source for sinonasal metastases. Intravasation of tumor cells from the primary site into blood vessels and through the vertebral valveless low-pressure venous plexus (Batson plexus), which communicates among the deep pelvic veins, intercostal, vena cava, and the azygos system, may allow tumor cells to disseminate from the caval system through the valveless epidural space and into the sinonasal region in a retrograde fashion.^{1908,1916} Additionally, tumor cells might also travel through the arterial circulation into the head and neck system in an anterograde fashion. The rich blood supply of the maxillary sinus may explain its higher metastases frequency. Lymphatic dissemination might occur when cells spread in a retrograde fashion from regional lymph nodes through the thoracic duct, the intercostal, mediastinal, or supraclavicular lymph vessels to the sinonasal region.^{1912,1917} Another suggested pathway is directly from an adjacent site, such as transcribriform spread from a meningeal lesion.¹⁹¹⁸

Initial evaluation is similar to the workup of a primary sinonasal tumor workup and includes a thorough history, a physical examination that includes endoscopy, and an assessment of the oral cavity, neck, and cranial nerves (including visual acuity and fields). As with any sinonasal neoplasm, imaging studies should be obtained prior to biopsy to appreciate the nasal anatomy, tumor epicenter and extent, vascularity, and appropriate surgical approach. There are no known radiographic findings specific to metastases. A CT with contrast can demonstrate bony erosion and remodeling, enhancement and vascularity, orbital, foramina, and skull base invasion, and overall, the tumor aggressiveness. MRI can show soft tissue involvement, tumor vascularity, neurovascular, leptomeningeal, and mucosal spread. A tissue biopsy should be obtained to establish the diagnosis. Once confirmed as metastatic disease, appropriate evaluation within a multidisciplinary team is required. Whole-body staging scans (e.g., PET/CT) might also be required for complete primary tumor anatomical localization, evaluation for other metastatic spread, and staging assessment. For patients with a known history of malignancy, lab studies including complete metabolic panels, which may indicate a specific extranasal origin (e.g., hyponatremia related to RCC) or a paraneoplastic syndrome, urinalysis, and specific biomarkers such as carcinoembryonic antigen (CEA) and prostate-specific antigen (PSA) may be useful as part of the workup.^{1910,1919,1920}

Several factors should be taken into account when tailoring a patient- and disease-specific treatment strategy. Significant prognostic factors include the biological

behavior of the primary tumor, the extent of metastases (oligometastatic or extensively disseminated disease), and the availability of effective systemic therapy. The prognosis in the majority of cases is poor. Improving patient QOL is usually the goal of treatment with pain relief, bleeding prevention, and alleviation of other symptoms. Most patients should be treated with palliative intention.^{1910,1912,1921}

Historically, management of sinonasal metastatic disease focused on palliative RT, and the role of surgery was typically limited to biopsy and tumor debulking. Given the rarity of sinonasal metastatic disease, most reported information is limited to case reports and case series. RT has been reported to be effective in symptom control and, occasionally, improved PFS even for tumors like RCC, which tend to be radioresistant.^{1922,1923} While there is an unclear relationship between the response rate and the radiation dose for sinonasal metastasis of any origin, various radiotherapy regimens were reported, with no apparent benefit to specific regimen.^{1912,1922–1924} A recent clinical trial suggested that patients with a limited number of metastases of diverse primary tumor origins and nonsinonasal metastases sites could be cured if all lesions are eradicated when treated with stereotactic ablative RT.¹⁹²⁵ This concept might eventually be extrapolated to the sinonasal region but requires further investigation. In addition, RT may be given as an urgent treatment to alleviate pain, reduce bleeding, and shrink the lesion.^{1922,1926,1927}

In recent years, with the evolution of EEA, a paradigm shift toward including the option for surgical treatment, while maintaining the oncologic principles of exposure, adequate margins, and reconstruction, may be suitable for selected patients with metastatic disease.^{1910,1912} EEA has been reported to provide symptom relief and improved QOL while minimizing morbidity and might be considered for select patients.^{1928,1929} For instance, surgical resection for a synchronous oligometastatic focus of disease may prolong survival.^{1923,1930,1931} For disseminated metastatic disease, surgical resection may provide symptomatic palliation. Depending on the primary tumor, concomitant systemic chemotherapy, hormonal therapy, immunotherapy, or radioactive iodine ablation may be appropriate adjuvant treatment.^{1910,1912,1922,1930} Given the relative rarity of sinonasal metastatic disease, each case should be carefully assessed in a multidisciplinary fashion to determine the best mode of treatment.

XXVIII | OTHER MALIGNANT LESIONS

A variety of other malignant neoplasms may originate within the nasal cavity or paranasal sinuses, including malignant germ cell tumors, carcinosarcoma, and teratocarcinosarcoma.^{1932–1937} These are extremely rare

tumors and can be confused with other pathologic entities before detailed histologic analysis has been completed. Presenting signs and symptoms are often nonspecific, mostly encompassing symptoms of nasal obstruction and recurrent epistaxis, among other symptoms such as facial pain and pressure.^{1932,1938} As with other sinonasal neoplasms, both CT and MRI work in concordance, delineating involvement of surrounding neurovascular and orbital structures. PET/CT imaging may provide some added benefit to rule out the possibility of metastatic disease to the nasal cavity and paranasal sinuses, as opposed to primary tumor originating within the sinonasal tract.^{1933,1934} In this particular group of tumors, demographics and immunohistochemical stains may provide value toward diagnosis and optimal treatment selection.

A | Germ cell tumors

Malignant germ cell tumors are most often found within the testes and ovaries, as implied by the germ cell origin. Extragenital germ cell tumors may occur in up to 20% of cases and are often found within midline structures along the axial skeleton including the retroperitoneum, the anterior mediastinum, and the suprasellar space, to name but a few.^{1935–1938} The head and neck subsite as a whole only accounts for roughly 1% of all extragenital malignant germ cell tumors; even less common are primary sinonasal germ cell tumors.¹⁹³⁹ Germ cell tumors are classically divided into seminomatous germ cell tumors (SGCTs) and nonseminomatous germ cell tumors (NSGCTs), with the vast majority of extragenital tumors being the nonseminomatous type.¹⁹⁴⁰

SGCTs encompass seminomas, which may also be referred to as germinomas or dysgerminomas. It is quite unusual to find these outside of the gonads as noted by very few case reports in the literature.^{1941,1942} When seminoma has been reported within the sinonasal cavity, it has been in the setting of distant metastasis from a primary gonadal site. Extrapolating from primary gonadal seminomatous tumors, however, they are extremely sensitive to RT and/or chemotherapy and should be treated accordingly.¹⁹⁴²

NSGCTs are far more common than seminomas outside of the gonads and may be found within the sinonasal cavity with no clear primary gonadal source. The most common type of malignant germ cell tumor encountered within the sinonasal cavity is the yolk sac tumor (YST), also commonly referred to as endodermal sinus tumor.^{1943,1944} Often found in younger patients and in females, these tumors can be pure or mixed, with most of them being the mixed type.^{1945–1947} Mixed YSTs are often found in conjunction with other germ cell tumor components, such as embryonal cell carcinoma or teratoma. A few diagnostic

features seem to be fairly consistent with diagnosis of YST, including the classic histologic appearance of Schiller–Duval bodies.^{1706,1948–1951} These are described as sheets of cuboidal cells with variable atypia that can be seen in single lines surrounding blood vessels. IHC may also elucidate some key features, including identification of alpha fetoprotein (AFP) and SALL-4 expression.^{1952,1953} Serum AFP is often elevated, which can become particularly important as a serum biomarker for cancer surveillance.¹⁹⁵⁴ Given the rarity of these tumors, treatment modalities are widely variable. They often include multimodal treatment, including surgery, RT, and chemotherapy. Many of these are quite sensitive to chemotherapy and a variety of agents have been previously used.^{1955–1958} This includes chemotherapeutics such as bleomycin, etoposide, cisplatin, carboplatin, ifosfamide, vincristine, 5-fluorouracil, and others.^{1706,1943–1961} Although tumors may be responsive to multiple forms of therapy, recurrence is commonly local, and early metastases may be present in up to 50% of cases.¹⁹⁶¹

Choriocarcinoma represents another form of NSGCT that may be found within the nasal cavity or paranasal sinuses. It can occur primarily within the sinonasal cavity or be metastatic from a primary gonadal site.^{1962,1963} These may resemble many other tumors radiographically and histologically, but unique to these NSGCTs is the staining pattern and elevated serum levels of beta human chorionic gonadotropin (β -hCG).^{1946,1964} Again, this is a particular tumor marker that can help with diagnosis but can also aid in prognostication and cancer surveillance. These are extremely rare as primary tumors in the sinonasal cavity, but when encountered they have been treated with maximal surgical resection followed by systemic therapy.^{1964–1967} This often mimics treatment of primary gonadal choriocarcinoma, starting with cisplatin, etoposide, and ifosfamide (often referred to as VIP).^{1962–1968}

B | Carcinosarcoma

Carcinosarcoma represents another rare malignancy that may occur in the sinonasal cavity.^{1935,1969–1974} It is considered a biphasic subtype of sarcomatoid carcinoma, with biphasic growth patterns of both epithelial and mesenchymal components (rather than a collision tumor).^{1975–1977} Demographically, there seems to be a slight preponderance in males and elderly patients.¹⁹⁷⁷ It is more often encountered elsewhere in the head and neck, including the laryngopharynx and salivary glands. Commonly affected sinonasal subsites include the nasal cavity, followed by the maxillary sinus.^{1975–1978} Again, as these tumors are exceedingly rare, there is no standard for definitive management. Treatment is often multimodal, including radical surgical

resection when feasible, followed by adjuvant RT.^{1979–1981} Local recurrence remains considerably high, with frequent reports of distant metastatic disease.^{1982–1985}

C | Teratocarcinosarcoma

Initially referred to as nasal blastoma, teratocarcinosarcoma is now an increasingly recognized malignant sinonasal neoplasm that encompasses features of epithelial, mesenchymal, and malignant teratoma.^{1986–1993} It is often encountered in the nasal cavity and ethmoid sinus, with 20% of tumors demonstrating intracranial extension at initial presentation.^{1994–2001} A triphasic growth pattern is noted, including the benign and malignant epithelial and mesenchymal components along with primitive neuroectodermal (teratoid) elements.^{2002–2008} Microscopically, these tumors often demonstrate “fetal appearing” squamous epithelium and clear cytoplasm with large nucleoli, arranged in a teratoid or organoid appearance.^{2009–2014} Despite the implication of the precursor “terato,” no germ cell features are encountered in this tumor histologically.^{2013,2014} As such, many authors believe these tumors are not of germ cell origin but instead originate from totipotent cells in the olfactory fossa, although several other postulated theories exist regarding underlying histogenesis. Treatment is with multimodality therapy, most often reported through case reports and case series.^{1434,2014–2051} However, despite the rarity of this tumor there have been two systematic reviews published, the most recent of which was published in January 2021 by Chapurin et al.²⁰⁵² A total of 127 patients were identified after review, with outcome data only available for 58 patients. The median age was 50 years and there is a strong male predilection (83%). The vast majority of patients were treated with surgery plus adjuvant RT or CRT. With a mean follow-up of 21 months, the recurrence rate was 38% and 2-year OS was 55%. Kaplan–Meier analysis shows an OS advantage for patients who are treated with multimodal therapy, but no differences in disease recurrence. These findings are similar to a prior systematic review published in 2014.²⁰⁵³

To conclude, other rare malignant neoplasms can be encountered within the nasal cavity or paranasal sinuses. They often lack distinguishing clinical or radiographic features compared to more common SNM. Demographics may lend some clues, but ultimately the final diagnosis is predicated on tissue biopsy. IHC and serum markers, such as β -hCG and AFP, can be important not only for diagnosis but also for prognosis and tumor surveillance. There is a paucity of data, and many treatment options are extrapolated from case reports, case series, and systematic reviews when available. Accordingly, these patients warrant dis-

cussion at multidisciplinary tumor conferences and should receive comprehensive care and multimodal therapy when feasible.

SECTION IV: MORBIDITY, QUALITY OF LIFE, AND SURVEILLANCE

XXIX | RISK FACTORS FOR SURGICAL COMPLICATIONS

A | Primary surgery

Surgery is part of the standard treatment for sinonasal tumors and is also an option for salvage in cases of recurrence. The most common surgical complications encountered during sinonasal tumor surgery include bleeding, infection, CSF leak, meningitis, diplopia and other visual disturbance, orbital and intracranial injury, ORN, and secondary CRS.^{14,68,313,2054} Most studies involving sinonasal tumors and its treatment outcomes are retrospective. Research of this topic is challenging because of the low incidence of these tumors and heterogeneous histologic subtypes. In many cases, the use of suitable surgical instruments and binarial access is recommended for better execution of the procedures and allows for improved surgical performance. Both practices may reduce the incidence of complications, especially in cases where conventional techniques may not afford for adequate resection.⁶⁸

Benign lesions, such as IP, have been preferentially resected with endoscopic techniques with generally low complication rate. Most complications encountered are minor and include epistaxis, epiphora, or temporary maxillary nerve paresthesia. Less frequently, major complications, such as CSF leak and orbital injury, are related to tumor invasion of the orbit and skull base.⁶⁷⁴ Surgical management of vascularized tumors, particularly JNA, has intraoperative massive blood loss as the major surgical complication. Preoperative angiography allows for evaluation of tumor blood supply and possible embolization to decrease intraoperative bleeding. According to Boghani et al.⁷⁶⁷ in a systematic review that included 85 articles and 1047 patients who underwent primary resection of JNA, preoperative embolization significantly reduced intraoperative bleeding in cases operated by endoscopic or combined approach. Another review with meta-analysis published by Overdevest et al. analyzed 828 cases of JNA submitted to embolization and found blood supply originating from the ICA system in 35.6% of patients and bilateral supply in 30.8%, both associated with a significant increase in intraoperative bleeding.²⁰⁵⁵

Dodhia et al. analyzed 448 patients who underwent surgery for sinonasal tumors, of which 404 had an open

approach.²⁰⁵⁰ They found an overall complication rate of 36.8%, with severity reaching 13.6% in cases. The only factor associated with a higher perioperative risk of surgical complications was advanced T stage, often represented by orbital or intracranial invasion, although, in univariate analysis, these factors alone were not statistically significant for increased risk of surgical complications. A large multicenter review conducted by Ganly et al. evaluated 1193 patients, who underwent open CFR of malignant sinonasal tumors with skull base involvement.²⁰⁵⁶ They reported an overall complication rate of 36.3%, with the most frequent being those related to the surgical wound (19.8%), followed by CNS complications (e.g., CSF leak, meningitis, pneumocephalus) in 16.2% of cases. On multivariate analysis, the presence of comorbidities, previous RT, and dural or cerebral invasion were the only predictors for surgical complications. In the same study, the presence of comorbidity was the only significant risk factor for perioperative mortality (RR 1.9, $p = 0.05$). Beswick et al. prospectively followed 142 patients undergoing resection of malignant sinonasal tumors, 69% by endoscopic access and 31% by open or combined approach.¹⁴ They concluded that factors such as age, sex, comorbidity status, T stage, and chemotherapy before or after surgery were not associated with a higher risk of early or late complications. However, adjuvant RT was associated with a higher risk of complications ($p = 0.013$) in patients undergoing open or combined resection.

The introduction of vascularized nasoseptal flaps by Hadad et al. for reconstruction of surgical defects in accesses to the skull base has been effective to reduce the risk of postoperative CSF leak.²⁴⁴ In cases where the use of the nasoseptal flaps is not possible, lateral nasal wall or pericranium flaps may be an option.¹⁴¹ The rate of postoperative CSF leak is particularly frequent in large anterior cranial fossa defects and tumors with posterior fossa involvement.²⁰⁵⁷ Overweight and obese patients tend to be more likely to develop postoperative leaks when compared to patients with body mass index $<25 \text{ kg/m}^2$.²⁰⁵⁸ Factors that lead to increased ICP, such as patients with intracranial hypertension, are associated with a decreased success rate in CSF leak repair. In these patients, external CSF diversion (e.g., lumbar drainage) could be considered for reducing ICP.²⁰⁵⁹ For a comprehensive discussion of the evidence surrounding skull base reconstruction, please refer to ICSB 2019 sections X (Reconstruction) and XI.A (Risk Factors for Postoperative CSF Leaks) and associated updated reviews on this topic.^{5,2060}

Aggregate grade of evidence: C (Level 2: one study; Level 3: five studies)

B | Patient and demographic factors

Age, sex, ethnicity, and socioeconomic status, as well as tobacco and alcohol use, were not associated with a higher risk of surgical complications in some series.^{14,2054} On the other hand, a large retrospective cohort found a positive association between the presence of comorbidities and surgical complications, but the severity of comorbidities was not rated.²⁰⁵⁶ Another review analyzed demographic and patient factors in patients undergoing surgery for SNM. They used the Charlson comorbidity index to stratify preoperative comorbidities and Clavien–Dindo grade to specify the level of complications, and no statistical association was found between these variables.²⁰⁵⁴ Bashjawish et al. evaluated the relationship between age and surgical complications, and concludes that there was no significant difference in the incidence of complications between elderly and nonelderly patients undergoing resection of nasal tumors.²⁰⁶¹ The same conclusion about age as a risk factor for surgical complications was reported by Lepera et al. when analyzing 203 patients who underwent endoscopic resection of sinonasal and anterior skull base tumors.³⁷⁰ There is no consensus in the literature on demographic factors, comorbidities, and their impact on risk of surgical complications, so the authors suggest that a careful and individualized evaluation is always recommended, considering the risks and benefits of surgical treatment.²⁰⁶²

Aggregate grade of evidence: C (Level 3: three studies; Level 4: one study)

C | Types of approach

Open CFR was traditionally the gold standard treatment for sinonasal tumors. In the last three decades, the use of endoscopic techniques, either alone or in combination with open approaches, has become more common.⁶ The endoscopic approach is widely used for treatment of benign tumors and, in carefully selected cases, shown to be a safe option with similar oncological results in the management of malignant tumors.²⁸⁰ A systematic review and meta-analysis by Lu et al. pooled 900 patients undergoing open or endoscopic surgery for treatment of SNM and concluded that there was no significant difference in major complication rate between the two approaches (RR 0.68; $p = 0.12$).³¹³ In contrast, a systematic review and meta-analysis published by Meccariello et al. that included 39 studies of 1732 patients with sinonasal adenocarcinomas treated with endoscopic techniques showed a different result.²⁵⁹ They concluded that endoscopic and endoscopic-assisted approaches were associated with lower rates of major complications (6.6% and 25.9%, respectively) when compared to open approaches (36.4%; $p < 0.01$).

Aggregate grade of evidence: C (Level 2: two studies; Level 3: two studies)

D | Salvage surgery

Salvage (or rescue) surgery is considered in patients with a tumor recurrence, more commonly indicated in case of malignant tumors with curative intent. Most studies that address risk factors for surgical complications are focused on primary surgery. Kaplan et al., in a case series that analyzed 42 patients underwent salvage surgery, found an overall complication rate of 28.6%.⁴¹⁷ The most frequent complications were CSF leak ($n = 4$), ORN ($n = 2$), and epidural abscess ($n = 2$). One patient had a carotid blowout and one patient required orbital decompression. Teshima et al. analyzed the outcomes of 48 patients undergoing surgery for malignancy involving the skull base, of which 30 were salvage cases.²⁰⁶³ They concluded that patients undergoing RT or CRT had a significantly higher risk of developing severe intraoperative complications when compared to those who did not have prior treatment. Similarly, anterolateral skull base resection was associated with a higher rate of complications. Patients undergoing salvage surgery are at higher risk of surgical complications, longer hospital stays, and higher mortality rates compared with those undergoing primary surgery.³⁷⁸

Aggregate grade of evidence: C (Level 3: two studies; Level 4: one study)

Table XXIX.1 summarizes evidence surrounding risk factors for surgical complications in sinonasal tumors.

XXX | QUALITY OF LIFE INSTRUMENTS

QOL is broadly defined by the WHO as an “individual’s perception of their position in life in the context of the culture and value systems in which they live, and in relation to their goals, expectations, standards, and concerns.”²⁰⁶⁴ Survey instruments developed to assess QOL may examine elements of general overall health-related QOL, disease-specific QOL, and symptom-specific QOL. There is no single instrument developed specifically for all sinonasal tumors, although many questionnaires exist that may be appropriate in certain clinical situations. For example, sinonasal tumors may involve the anterior skull base, and several instruments exist to assess QOL in patients undergoing skull base surgery.^{2065–2067} Additionally, disease-specific QOL instruments have been developed for NPC. Ultimately, the choice of specific instruments depends on tumor pathology, treatment type, and goals of the assessment.

TABLE XXIX.1 Evidence surrounding risk factors for surgical complications in sinonasal tumors.

Study	Year	LOE	Study design	Study groups	Clinical endpoints	Conclusion
Lu et al. ³¹³	2019	2	Systematic review and meta-analysis	900 patients included from 10 studies 399 (44%) Endoscopic resection 501 (56%) open resection	1. Types of approach 2. Complication rate 3. Recurrence rate 4. Length of stay	1. OR and ER showed comparable complications rate (RR 0.68 $p = 0.12$) and recurrence (RR = 0.84 $p = 0.35$) 2. ER was associated with shorter LOS (-2, 9 days, $p < 0.01$)
Meccariello et al. ²⁵⁹	2015	2	Systematic review and meta-analysis	39 articles including 1732 patients underwent surgery for sinonasal adenocarcinomas 431 endoscopic 31 endoscopic-assisted surgery 1270 open surgery	1. Types of approach 2. Complication rate	1. Growing evidence suggests that endoscopic nasal resection of nasal tumor is safe 2. Endoscopic and endoscopic-assisted resection showed lower rates of complications (6.6% and 25.9%) compared to open approaches (36.4%, $p < 0.01$)
Boghani et al. ⁷⁶⁷	2013	2	Systematic review	1047 JNA patients underwent surgery from 85 studies	1. Types of approach 2. Recurrence rate 3. Intraoperative blood loss	Endoscopic resection was associated with lower intraoperative blood loss and recurrence when compared with open resection
Beswick et al. ¹⁴	2021	3	Prospective cohort	142 patients included 98 endoscopic resection 44 open/combined resection	1. Type of surgical approach 2. Gender 3. Adjuvant radiation	1. A lower complication rate was seen in male patients 2. Surgical approaches had similar complication rates between types 3. Open/CR was associated with increased odds of complication after accounting for RT
Dodhia et al. ²⁰⁵⁴	2021	3	Retrospective cohort	448 patients underwent surgery for Sinonasal or skull base malignancy	1. Mortality rate 2. Complication rate 3. Comorbidities and demographic factors 4. T stage	1. 30-day mortality rate: 1.6% 2. Overall complication rate of 36.8%, severe complication of 13.6% 3. Advanced T stage was only factor associated with postoperative complications
Bashjawish et al. ²⁰⁶¹	2019	3	Retrospective cohort	920 patients underwent surgery for SNM	1. Age (Elderly) 2. Complication rate	Elderly status was not an independent risk factor for surgical complications
Teshima et al. ²⁰⁶³	2018	3	Retrospective cohort	30 patients underwent salvage surgery for tumors involving the skull base 18 patients received RT or CRT previously	1. Complication rate 2. RT/CRT status 3. Salvage surgery	CRT or particle RT was significantly associated with a high risk of severe complications after salvage surgery

(Continues)

TABLE XXIX.1 (Continued)

Study	Year	LOE	Study design	Study groups	Clinical endpoints	Conclusion
Overdevest et al. ²⁰⁵⁵	2017	3	Retrospective review and Systematic review and Meta-analysis	854 JNA cases underwent surgery after angiographic embolization	<ol style="list-style-type: none"> 1. Complication rate 2. Intraoperative blood loss 3. ICA/bilateral supply 	<ol style="list-style-type: none"> 1. ICA supply in 35.6% of tumors and bilateral supply in 30.8% 2. ICA/bilateral arterial supply was associated with increased operative blood loss 3. Complex vascular contributions to JNA are frequent, underreported, and related with increased blood loss
Kaplan et al. ⁴¹⁷	2015	3	Retrospective cohort	42 patients with local recurrence SNM treated by salvage surgery	<ol style="list-style-type: none"> 1. Salvage surgery 2. Complication rate and predictors 3. Histologic subtype 	Complications occurred in 28.6% of patients and were associated only with high-risk histologic subtype ($p = 0.04$)
Suh et al. ²⁸⁰	2013	3	Retrospective cohort	49 patients underwent surgery for SNM: 36 endoscopic approach and 13 endoscopic-assisted approach	<ol style="list-style-type: none"> 1. Types of approach 2. Oncological outcomes 3. Medical complication rate 4. Surgical complication rate 	<ol style="list-style-type: none"> 1. Surgical and medical complications were more frequent with open approaches than pure endoscopic ones 2. Although further studies are required, ER may be used in selected patients with similar oncological results and less morbidity
Ganly et al. ²⁰⁵⁶	2005	3	Retrospective cohort (multicenter)	1193 patients underwent CFR for malignant tumors of the skull base from 17 institutions.	<ol style="list-style-type: none"> 1. Complication rate and predictors 2. Mortality rate 3. Comorbidity 	Factors that are predictive of complications included medical comorbidity, prior radiation, and dural and brain invasion
Goshtasbi et al. ²⁰⁶²	2020	4	Retrospective Database study (NSQIP)	95 patients underwent skull base surgery for ONB resection	<ol style="list-style-type: none"> 1. Short-term adverse event 2. ASA score 3. Time of surgery 4. Length of stay 5. Preoperative hematocrit and albumin levels 	1. Postoperative morbidities in ONB resection were associated with longer operation time, increased LOS, higher ASA, and lower preoperative hematocrit or albumin levels
Lehrich et al. ³⁷⁸	2020	4	Retrospective Database Study (NCDB)	3011 patients included 2804 primary surgery 207 salvage surgery	<ol style="list-style-type: none"> 1. Primary surgery 2. Salvage surgery 3. OS outcomes 4. Length of stay 	SS patients had longer LOS and higher 30-day and 90-day mortality when compared to PS

Abbreviations: CFR, craniofacial resection; ICA, internal carotid artery; JNA, nasopharyngeal angiofibroma (formerly juvenile nasopharyngeal angiofibroma); NCDB, National Cancer DataBase; OS, overall survival; RT, radiotherapy; SNM, sinonasal malignancy.

A | Skull base QOL instruments

The first QOL instrument to be developed specifically for skull base pathologies was the Anterior Skull Base Surgery QOL questionnaire (ASBS-Q). It is a 35-item question instrument for patients undergoing open skull base approaches. Several sinonasal tumors including IP, SCC, ONB, ACC, adenocarcinoma, and melanoma were included in its initial development and analysis. It is composed of six domains (performance, physical function, vitality, pain, influence on emotions, and specific symptoms) and demonstrated sufficient reliability and validity. The instrument was validated by testing its agreement with the hypothesized effect of certain clinical variables (e.g., malignancy, adjuvant radiation) on domain scores. The instrument was also able to differentiate between patient groups with different health statuses (e.g., older patients achieved lower scores in the performance and physical function domains than younger patients), further demonstrating its validity. High internal consistency was demonstrated by Cronbach's alpha >0.8 in all domains.²⁰⁶⁸ The minimal clinically important difference (MCID) has been determined as 0.4 (8%, score range 1–5).²⁰⁶⁹

The Skull Base Inventory (SBI) is a comprehensive instrument of 41 items designed for patients with anterior or central skull base pathologies undergoing endoscopic or open surgical approaches. It was developed using a population of 138 patients with several sinonasal tumors such as ONB, ACC, and adenocarcinoma, in addition to intracranial skull base pathologies such as pituitary adenoma, craniopharyngioma, or meningioma. There are 11 domains including cognitive, emotional, family, financial, social, spiritual, endocrine, nasal, neurologic, visual, and other.²⁰⁷⁰ The endocrine domain may be less relevant to patients with sinonasal tumors, especially for those who do not undergo adjuvant therapy. Psychometric properties were tested in a multi-institutional study of 180 patients. Concurrent validity was assessed by comparing the SBI to the ASBS-Q and the nasal domain of the SBI to the Sino-Nasal Outcomes Test-22 (SNOT-22). There was very strong correlation with the SBI and moderate correlation of the nasal domain with SNOT-22. In assessing construct validity, three out of six hypotheses were satisfied and one displayed a trend toward satisfaction. While it was hypothesized that QOL would be worse in patients receiving adjuvant therapy or in those with malignant disease, these hypotheses were not satisfied by the SBI. Cross-cultural and convergent validity were also found to be acceptable. Responsiveness was demonstrated by significant mean differences between preoperative and 2-week postoperative total scores and among seven of the domains.^{2065,2070}

The Endoscopic Endonasal Sinus and Skull Base Surgery Questionnaire (EES-Q) is a multidimensional

instrument to assess general health-related QOL as well as sinonasal morbidity following endoscopic endonasal surgery. The EES-Q consists of 30 questions across three domains (physical, psychological, social). It was validated in a total sample of 300 patients undergoing endoscopic skull base surgery predominantly for pituitary adenoma, as well as patients undergoing endoscopic sinus surgery. Of note, 15 patients with IP were included and seven medial maxillectomies were performed.²⁰⁷¹ A subsequent study validated the instrument by demonstrating significant positive and negative correlations between the EES-Q and the SNOT-22 and postoperative health status. The SNOT-22 is a 22-item disease-specific QOL instrument that has been validated in patients with CRS. It is widely used to assess nasal morbidity across all pathology, despite not being validated in patients with sinonasal or skull base tumors. The EES-Q has also demonstrated excellent test-retest reliability with intraclass correlation coefficients (ICCs) of 0.9 or greater across the three domains. The instrument also demonstrated responsiveness to clinical change when measured preoperatively and 3 months postoperatively.²⁰⁷²

Sinonasal QOL is of particular importance for patients undergoing EEA. The Sino-Nasal Outcome Test for Neurosurgery (SNOT-NC) and Anterior Skull Base Nasal Inventory (ASK Nasal-12) were developed specifically to assess sinonasal symptom-specific outcomes and do not assess general health-related QOL. The SNOT-NC was modeled after the SNOT-22 and consists of 23 items across five domains (nasal discomfort, sleep problems/reduced productivity, ear and head discomfort, visual impairment, and olfactory disturbance). It was validated in a sample of 102 patients with sellar pathology and found to have good reliability, although retest reliability has not been performed.²⁰⁷³ Similarly, the ASK Nasal-12 was also validated in a sample of 104 patients with pituitary adenomas undergoing endoscopic transsphenoidal approaches. It consists of 12 items in one domain reported as a single score.²⁰⁷⁴

De Almeida reviewed the nine QOL instruments specific to anterior and central skull base pathology including Acromegaly QOL (AcroQOL), ASBS-Q, Quality of Life Satisfaction Hypopituitarism (QLS-H), Pituitary adenoma QOL, Addison's disease QOL (AddiQOL), QOL for Growth Hormone Deficiency (QOL-AGHDA), Hormone Deficiency-Dependent Quality of Life (HDQOL), Princess Margaret Hospital Midface Dysfunction Scale (MDS), and Cushing QOL. Seven of these instruments examined pituitary pathology QOL, one measures midface dysfunction, and another measures general skull base pathology. Three instruments (ASBQ, QLS-H, and QOL-AGHDA) demonstrated reliability as assessed by both internal consistency and reproducibility. Three instruments (Pituitary QOL, AddiQOL, and MDS) failed to demonstrate some form of

validity as measured by responsiveness, or content, criterion, concurrent, or construct validity.²⁰⁷⁵ Many of these instruments assess QOL affected by endocrine changes associated with pituitary pathology that may not be relevant to treatment of sinonasal tumors.

B | Head and neck cancer QOL instruments

General head and neck cancer QOL questionnaires have also been applied to patients with sinonasal tumors as well. The European Organization for Research and Treatment of Cancer (EORTC) Quality of Life Questionnaire (QOL)-C30 and corresponding module for head and neck neoplasms (H&N35) have been validated in many cultures. The EORTC QLQ-C30 and H&N35 were developed to measure cancer-specific and site-specific QOL and have demonstrated good reliability and validity. The EORTC QLQ-C30 contains 30 questions across five functional scales, nine symptom scales, financial difficulty, and one global health status scale. The Spanish version of the QLQ-H&N35 applied both QLQ-C30 and QLQ-H&N35 instruments to 193 Mexican patients with tumors of the head and neck, including tumors of the nasal cavity and paranasal sinuses. This demonstrated internal consistency. Each questionnaire has beneficial subscales and is more informative about the patient's overall status when used together.²⁰⁷⁶

C | Nasopharyngeal carcinoma QOL instruments

NPC represents a distinct subtype of SNM given its anatomic location, higher incidence in Asia, and accepted first-line treatment of RT with or without chemotherapy. QOL has been studied in patients with NPC using generalized health QOL surveys and head and neck questionnaires including the EORTC QLQ-C30 and H&N35, University of Washington QOL (UW-QOL), Medical Outcomes Study 36-item short-form health survey (SF-36), and functional assessment of cancer therapy (FACT) scales. However, given the uniqueness of this tumor and population, several QOL instruments have been developed for and studied specifically in NPC.²⁰⁷⁷

In the initial validation of EORTC QLQ-C30 and H&N35, NPC only represented a small percentage of the total studied cancer population. These instruments have been translated to Chinese and studied separately in a population of 100 NPC patient undergoing active treatment or surveillance. Both questionnaires demonstrated high internal consistency (Cronbach's alpha >0.7 in all but one

scale) and test-retest reliability at 2 weeks (ICC 0.33–0.82 for QLQ-C30 and 0.71–0.8 for H&N35). There was moderate to high correlation when compared to the Taiwan standard version 1.0 of SF-36 implying validity.²⁰⁷⁸

Given that radiotherapy is standard-of-care treatment for NPC, the Quality of Life Radiation Therapy Instrument and Head & Neck Module (QOL-RTI/H&N) has been translated to Chinese and studied in the NPC population. This is a general scale of 24 items on a 0–10 Likert scale assessing function, emotion, family/socioeconomics, and general QOL. The H&N module contains seven more specific symptom domains. It was studied in a series of 238 patients with NPC and found to have good test-retest reliability (ICC > 0.8). Internal consistency was variable (Cronbach's alpha 0.41–0.77) with the lowest values in the emotion and family domains. Confirmatory factor analysis was used to demonstrate construct validity. Responsiveness was tested after 28 days of treatment with effect sizes ranging from 0.22 to 1.23. In general, effect sizes were greater in the function and H&N domains compared to emotion, family, and general domains. The instrument had good operability and was completed in an average of 9.8 min.²⁰⁷⁹ The QOL impact of oral rehabilitation with dental prostheses was assessed specifically in a small sample of NPC patients in Turkey using the Liverpool Oral Rehabilitation Questionnaire version 3 (LORQv3) and was found to have reasonable criterion validity when compared with UW-QOL, good internal consistency (Cronbach's alpha 0.71–0.82), and moderate to perfect test-retest reliability (kappa 0.62–1.00) in the sample.²⁰⁸⁰

The FACT general scale (FACT-G) was appended with an NPC disease-specific subscale (NPCS) to create the Functional Assessment of Cancer Therapy—Nasopharyngeal (FACT-NP). The FACT-NP consists of the standard 27-item questionnaire assessing physical, social/family, emotional, and function well-being, as well as additional 11 items focused on NPC-specific concerns such as swallowing, communication, neck movement, hearing, smell, nasal blockage, and so forth. It was demonstrated to have high internal consistency (Cronbach's alpha 0.87–0.90) and test-retest reliability (ICC 0.73–0.88). It demonstrated good responsiveness to clinical change when administered preoperatively and again 3 months after completion of RT (effect sizes >0.6). The FACT-NP showed moderate to strong correlation with the QOL-RTI/H&N inferring suggesting concurrent validity.²⁰⁸¹

The Quality of Life Scale of Nasopharyngeal Carcinoma Patients (QOL-NPC-V2) is a questionnaire developed specifically for use in Chinese patients with NPC to assess physical functioning and health status in the past 2 weeks. The updated version of the scale contains 33

items on a 1–5 Likert scale across four domains (physical function, psychological function, social function, and side effects).²⁰⁷⁷ In a sample of 487 patients, it was determined to have good internal consistency (Cronbach's alpha 0.72–0.84), reliability (ICC > 0.8), and validity as evidenced by correlation with QOL-NP, FACT-G, and FACT-H&N, as well as by confirmatory factor analysis.^{2077,2082}

The Chinese QOL Instruments for Cancer Patients (QLICP v 2.0) was developed to assess QOL specifically in Chinese patients. It contains a general module for most patients (32 items) as well as short modules for specific diseases, including NPC, consisting of 11 items.²⁰⁸³ The structure is hierarchical and broken into items, facets, domains, and overall. The four domains include physical, psychosocial, and social QOL, as well as common symptoms/side effects. It generally demonstrated acceptable overall validity and reliability; however, a large ceiling effect was noted in some facets and low responsiveness was identified in some domains, leading the authors to suggest improvements prior to widespread use.

Additional QOL instruments have been developed specifically for other cultures. The CV-IOR-CyC-01 is a 65-item questionnaire of three domains and two ungrouped questions on perceived health and health-related QOL used to assess QOL of head and neck cancer patients. The instrument explores health-related QOL in detail and is adapted to Cuban society and culture. It demonstrated acceptable internal consistency (Cronbach's alpha 0.79–0.90) and validity in a large sample of patients, of which a small number had NPC.²⁰⁸⁴

Given the variety of QOL instruments available, it can be challenging to determine which are most appropriate (Table XXX.1). Deckard examined three validated QOL instruments (ASBQ, SNOT-20, and European Quality-of-Life-5 Dimension [EQ-5D]) and one endoscopy scale (Lund–Kennedy Endoscopic [LKE]) in a cohort of 71 patients following both benign and malignant sinus and skull base tumor resection.²⁰⁸⁵ The most common pathology included IP, JNA, and SCC. Most surgical approaches were endoscopic (78.8%), followed by combined endoscopic and open (21.1%). Forty-nine percent of patients received a form of postoperative adjuvant therapy. A strong correlation was found between the ASBS-Q and SNOT-20 instruments and between ASBS-Q and the EQ-5D; however, the EQ-5D did not differentiate between any of the assessed variables in the study and may be too general for use in this setting. The LKE correlated moderately with SNOT-20 and weakly with the other instruments. This highlights that there is not one ideal instrument to measure QOL in patients undergoing treatment for sinonasal and skull neoplasms. Use of multiple instruments may provide more useful complementary information depending on the goals of the assessment.

Assessment of QOL in sinonasal tumors

Aggregate level of evidence	B (Level 1: one study; Level 2: eight studies; Level 3: nine studies; Level 4: one study)
Benefit	QOL outcomes for patients with sinonasal tumors have been studied with reliable instruments that have been validated for sinonasal disorders or head and neck malignancies.
Harm	No consensus has been made for the best instrument for assessing QOL in sinonasal tumors.
Cost	Time (interviewer, patient, data entry, and data analysis); survey fatigue especially with multiple instruments
Benefits–harm assessment	Preponderance of benefits over harms.
Value judgments	Since there is no well-defined superior metric, multiple metrics may be needed for full evaluation of QOL outcomes. More studies directly comparing QOL metrics should be performed specific to sinonasal tumor outcomes.
Policy level	Recommendation.
Intervention	QOL surveys should be utilized during the management of patients with sinonasal tumors to monitor patient outcomes, as they have the potential to provide valid and reliable information on outcomes for patients with sinonasal tumors.

XXXI | QUALITY OF LIFE FOR SINONASAL NEOPLASMS

A | Quality of life for benign neoplasms

1 | Baseline and postoperative QOL differences

Historically, open resection of sinonasal tumors resulted in high morbidity with lasting impact on patients' QOL.²⁰⁸⁸ The advent of endoscopic surgery avoids the morbidity associated with external incisions required for open resection, but the impact on sinonasal and overall QOL was not significantly investigated until the early 2010s. Several recent studies have investigated the impact of minimally invasive endoscopic resection of both benign and malignant sinonasal tumors.^{2085,2089–2094} Early studies focused on QOL outcomes following endoscopic skull base surgery, and Harrow and Batra in 2013 reported on sinonasal QOL after endoscopic resection of sinonasal tumors. In this series, patients with benign tumors, predominantly IP (46%), recorded mean preoperative SNOT-20 scores of

TABLE XXX.1 Evidence surrounding quality of life instruments for sinonasal neoplasms and masses.

Study	Year	LOE	Study design	Study groups	Clinical endpoints	Conclusion
de Almeida et al. ²⁰⁷⁵	2012	1	Systematic review	Systematic review of studies evaluating the QOL instruments for anterior or central skull base pathology (<i>n</i> = 9) <ul style="list-style-type: none"> • AcroQOL • ASB-QOL • QLS-H • Pituitary adenoma QOL • AddiQOL • QOL-AGHDA • HDQOL • MDS • Cushing QOL 	Systematic review of anterior or central skull base QOL instruments	<ol style="list-style-type: none"> 1. Nine instruments identified 2. Seven address QOL for pituitary pathology, one measures symptoms for midface dysfunction, one measures QOL for skull base pathology in general 3. Three instruments demonstrated internal consistency and reproducibility (ASB-QOL, QLS-H and QOL-AGHDA)
Forner et al. ²⁰⁶⁵	2021	2	Cross-sectional study	Patients undergoing endoscopic or open anterior skull base surgery at five institutions (<i>n</i> = 180) <ul style="list-style-type: none"> • Intracranial tumors (<i>n</i> = 116) • Vascular tumors (<i>n</i> = 7) • Other (ONB, craniopharyngioma, chondrosarcoma, and others) (<i>n</i> = 47) • Missing diagnoses (<i>n</i> = 10) 	Assess the reliability and validity of the SBI in patients with anterior and central skull base pathology undergoing endoscopic and open approaches	The SBI has internal consistency, reliability, and validity in patients undergoing endoscopic and open approaches for anterior or central skull base pathology
Larjani et al. ²⁰⁸⁶	2016	2	Cross-sectional study	Patients surgically treated for anterior or central skull base pathology (<i>n</i> = 52). <ul style="list-style-type: none"> • ONB (<i>n</i> = 7) • Craniopharyngioma (<i>n</i> = 4) • Pituitary adenoma (<i>n</i> = 14) • Adenocarcinoma (<i>n</i> = 3) • Meningioma (<i>n</i> = 5) • Chordoma (<i>n</i> = 9) • Cavernous hemangioma (<i>n</i> = 2) • ACC, hemangioma, hemangiopericytoma, chondrosarcoma, JNA, leiomyosarcoma, osteosarcoma, SCC (<i>n</i> = 1 each) 	To establish the discriminative and evaluative properties of the SBI	The SBI demonstrated preliminary reliability and validity for discriminative use

(Continues)

TABLE XXX.1 (Continued)

Study	Year	LOE	Study design	Study groups	Clinical endpoints	Conclusion
Su et al. ²⁰⁸²	2016	2	Cross-sectional study	Chinese patients with NPC (<i>n</i> = 487)	Develop and validate the QOL-NPC (version 2) in the Chinese population	The QOL-NPC (version 2) is valid, reliable, and responsive in Chinese patients with NPC
Chen et al. ²⁰⁷⁹	2014	2	Cross-sectional study	Chinese patients with head and neck cancer (<i>n</i> = 238) <ul style="list-style-type: none"> • NPC (<i>n</i> = 170) • Non-NPC (<i>n</i> = 68) 	Develop and validate the Chinese version of the QOL-RTI/H&N	The Chinese QOL-RTI/H&N has good reliability, validity, and responsiveness in Chinese patients with head and neck cancer
Peker et al. ²⁰⁸⁰	2014	2	Cross-sectional study	Turkish patients with head and neck cancer who underwent prosthetic rehabilitation (<i>n</i> = 46) <ul style="list-style-type: none"> • Maxillary obturator prostheses treated by surgery alone (<i>n</i> = 15) • Maxillary obturator prostheses treated by surgery + RT, with or without chemotherapy (<i>n</i> = 23). • NPC patients without maxillary defects wearing conventional dental prosthesis treated by RT with or without chemotherapy (<i>n</i> = 8) 	<ol style="list-style-type: none"> 1. Culturally adapt the LORQv3 for Turkish-speaking head and neck cancer patients who had undergone rehabilitation 2. Evaluate psychometric properties 	The Turkish version of LORQv3 has internal consistency and test-retest reliability in prosthetically rehabilitated patients with head and neck cancer
Carrillo et al. ²⁰⁷⁶	2013	2	Cross-sectional study	Mexican patients with head and neck cancer (<i>n</i> = 139) <ul style="list-style-type: none"> • Nasal or paranasal sinus cancers (<i>n</i> = 11) • NPC (<i>n</i> = 8) • Maxillary antrum cancers (<i>n</i> = 4) • Nonsinonasal head and neck cancers (<i>n</i> = 170) 	Develop and validate a Mexican Spanish version of the EORTC-QLQ-H&N35 in a Mexican population with H&N cancer	The Mexican Spanish version of the QLQ-H&N35 has good reliability and validity in Mexican patients with head and neck cancer
Tong et al. ²⁰⁸¹	2009	2	Cross-sectional study	Patients with NPC (<i>n</i> = 357)	Develop and validate the FACT-NP survey	The FACT-NP has good reliability and validity in patients with NPC

(Continues)

TABLE XXX.1 (Continued)

Study	Year	LOE	Study design	Study groups	Clinical endpoints	Conclusion
Lo et al. ²⁰⁸⁷	2004	2	Cross-sectional study	Chinese patients with head and neck cancer (<i>n</i> = 138) <ul style="list-style-type: none"> • Nasopharynx (<i>n</i> = 106) • Paranasal sinus (<i>n</i> = 8) • Nonsinonasal (<i>n</i> = 24) 	Validate the QOL-RTI/H&N for Chinese patients with Head & Neck cancer who were treated with radiation therapy	The Chinese version of the QOL-RTI/H&N survey is a reliable and valid tool for measuring QOL in Chinese patients with H&N cancer
Lugo-Alonso et al. ²⁰⁸⁴	2017	3	Cross-sectional study	Cuban patients with head and neck cancer (<i>n</i> = 520) <ul style="list-style-type: none"> • Oral or mesopharyngeal cancer (<i>n</i> = 270) • Laryngeal cancer (<i>n</i> = 228) • NPC (<i>n</i> = 22) 	Construct and validate an instrument to measure QOL in Cuban patients with head and neck cancer	The 65 item CV-IOR-CyC-01 survey has good validity and interpretability in the Cuban population with head and neck cancer
Wu et al. ²⁰⁸³	2016	3	Cross-sectional study	Chinese patients with NPC (<i>n</i> = 121)	Develop and validate a Quality of Life in Cancer Patients survey specific to patients with NPC in the Chinese population (QLICP-NA V2.0)	The QLICP-NA V2.0 has some validity, reliability, and responsiveness but needs improvements before being applied broadly in Chinese patients with NPC
ten Dam et al. ²⁰⁷²	2018	3	Prospective cohort	Patients with paranasal sinus and skull base pathology (<i>n</i> = 100). <ul style="list-style-type: none"> • Anterior skull base: pituitary adenoma (<i>n</i> = 28) • Paranasal sinus pathology: CRS, mucocele, IP (<i>n</i> = 72) 	Evaluate the test-retest reliability, construct validity and responsiveness of the EES-Q	The EES-Q is a reliable and acceptable disease specific tool for HRQoL assessment after endoscopic endonasal sinus or anterior skull base surgery
ten Dam et al. ²⁰⁷¹	2017	3	Prospective cohort	Patients undergoing EEA for sinonasal and skull base pathology <ul style="list-style-type: none"> • Sinus pathology (<i>n</i> = 207) • CRS (<i>n</i> = 165) • Anterior skull base pathology (<i>n</i> = 93) 	Develop a multi-dimensional disease-specific HRQoL instrument for patients undergoing EEA to assess nasal morbidity after treatment	A 30-item EES-Q was developed with high internal consistency for all three HRQoL domains

(Continues)

TABLE XXX.1 (Continued)

Study	Year	LOE	Study design	Study groups	Clinical endpoints	Conclusion
Deckard et al. ²⁰⁸⁵	2015	3	Prospective cohort	Patients with sinonasal and skull base tumors (<i>n</i> = 71) <ul style="list-style-type: none"> • Benign tumors (IP, JNA, pituitary adenoma, and others) (<i>n</i> = 39) Malignant tumors (SCC, ONB, adenocarcinoma, ACC, and others) (<i>n</i> = 32)	Evaluate postoperative QOL after endoscopic resection of sinus and skull base neoplasms using validated outcomes measures (SNOT-20, ASBQ, EQ-5D, and LKE scores) and perform correlation of the various metrics	Concurrent use of multiple instruments may better discern QOL outcomes after endoscopic tumor surgery
Amit et al. ²⁰⁶⁹	2012	3	Systematic review and meta-analysis of retrospective case series	Patients undergoing endoscopic or open extirpation of anterior skull base tumors, benign or malignant (<i>n</i> = 118) evaluated with ASBQ <ul style="list-style-type: none"> • Retrospective evaluation (<i>n</i> = 79) Prospective evaluation (<i>n</i> = 39)	Determine the clinical significance of ASBQ scores	The MCID of the ASBQ was 0.4
de Almeida et al. ²⁰⁷⁰	2012	3	Retrospective cohort study with development of instrument	Patients who underwent endoscopic or open approach for <ul style="list-style-type: none"> • An anterior or central skull base pathology (<i>n</i> = 138) • Endoscopic/anterior (<i>n</i> = 17; ONB, meningioma, encephalocele) • Endoscopic/central (<i>n</i> = 48; pituitary adenoma, chordoma, craniopharyngioma) • Open/anterior (<i>n</i> = 48; ONB, SCC, hemangiopericytoma, adenocystic) • Open/central (<i>n</i> = 25, chordoma, chondrosarcoma, craniopharyngioma) 	Systematic review to identify relevant QOL instruments and develop a disease-specific QOL questionnaire for anterior and central skull base pathology	<ol style="list-style-type: none"> 1. 41 questions with 11 disease-specific domains SBI was developed 2. No reliability, validity and responsiveness testing done

(Continues)

TABLE XXX.1 (Continued)

Study	Year	LOE	Study design	Study groups	Clinical endpoints	Conclusion
Gil et al. ²⁰⁶⁸	2004	3	Cross-sectional study	Patients surgically treated for anterior skull base tumors ($n = 35$) <ul style="list-style-type: none"> • Meningioma ($n = 9$) • Mucocele ($n = 7$) • IP ($n = 3$) • Osteoma ($n = 2$) • SCC ($n = 2$) • ONB ($n = 2$) • ACC ($n = 1$) • Adenocarcinoma, sarcoma, meningioencephalocele, melanoma, malignant schwannoma, plasmacytoma, fibrous dysplasia, epidermoid cyst, angiofibroma ($n = 1$ each) 	Develop and validate a cancer specific multidimensional instrument for QOL assessment in patients undergoing open anterior skull base surgery	A 35-question ASBQ with six QOL domains was developed with good internal reliability and test-retest reliability
Chie et al. ²⁰⁷⁸	2003	3	Prospective cohort	Taiwanese patients with NPC ($n = 100$) <ul style="list-style-type: none"> • 50 NPC patients under active treatment • 50 NPC patients under follow-up 	Validation of the Taiwan Chinese version of the EORTC-QLQ-C30 and the EORTC QLQ-H&N35	The Taiwan Chinese version of the EORTC-QLQ-C30 and the EORTC-QLQ-H&N35 had moderate to high test-retest reliability and high internal consistency in most scales and could show expected differences between patients in active treatment and follow-up group
Gu et al. ²⁰⁷⁷	2009	4	Prospective cohort	Chinese patients with NPC ($n = 433$)	Develop a QOL-NPC scale in the Chinese population	The QOL-NPC was created, but did not undergo reliability or validity testing

Abbreviations: AcroQOL, Acromegaly QOL; AddiQOL, Addison's disease QOL; ASB-QOL, Anterior Skull Base QOL; ASBQ, Anterior Skull Base Questionnaire; EES-Q, Endoscopic Endonasal Sinus and Skull Base Surgery Questionnaire; EORTC-QLQ-C30, European Organization for Research and Treatment of Cancer Core QOL Questionnaire; EORTC-QLQ-H&N35, European Organization for Research and Treatment of Cancer Quality of Life Questionnaire in Head and Neck Cancer; EQ-5D, European Quality-of-life-5 Dimension; FACT-NP, Functional Assessment of Cancer Therapy—Nasopharyngeal; HDQOL, Hormone Deficiency-Dependent Quality of Life; LORQv3, Liverpool Oral Rehabilitation Questionnaire version 3; MDS, Princess Margaret Hospital Midface Dysfunction Scale; QLS-H, Quality of Life Satisfaction Hypopituitarism; QOL-AGHDA, QOL for Growth Hormone Deficiency; QOL-NPC, QOL for Nasopharyngeal Carcinoma; QOL-RTI/H&N, Quality of life Radiation Therapy Instrument for Head and Neck; SBI, Skull Base Inventory.

1.11.²⁰⁸⁹ Postoperatively, a significant reduction in overall mean SNOT-20 scores was identified at both 3 (-0.43 ; $p = 0.005$) and 6 (-0.53 ; $p = 0.002$) months. The same group in 2015 reported 2-year follow-up data among a group of 32 patients with IP who underwent minimally invasive endoscopic tumor resection.⁴ The mean preoperative SNOT-20 of this cohort was 1.04, and, similar to the prior study, at 6 months there was a significant reduction in overall SNOT-20 scores (-0.51 ; $p = 0.01$). Despite overall SNOT-20 scores being reduced at the 1- and 2-year follow-

ups, this failed to reach statistical significance. The authors attribute this finding to patient dropout at these latter time points.

Glicksman et al. prospectively enrolled patients with benign sinonasal tumors and reported QOL data in 81 patients.²⁰⁹³ Most tumors were IP, similar to prior studies. Average baseline total SNOT-22 was 25.9 and decreased significantly to 15.7, 11.4, 12.8, and 12.9 at 3, 6, 12, and 24 months, respectively. Among all of these studies, rhinologic and sleep subdomain scores contributed the most

to baseline QOL impact.^{2089,2090,2093} As such, Harrow et al. and Derousseau et al. reported the most significant improvement in these subdomains postoperatively.^{2089,2090} Glicksman et al. demonstrated significant improvement in all subdomains of the SNOT-22 in their cohort, although the rhinologic and sleep components appeared to account for the largest component of improvement in SNOT-22.²⁰⁹³ Importantly, Harrow and Batra note that the mean difference in 40% of their benign tumor cohort met the minimal clinically important difference (MCID) for the SNOT-20 questionnaire.²⁰⁸⁹ The mean difference of total SNOT-22 scores in the Glicksman et al.⁷ cohort met the MCID of the SNOT-22, but the authors did not specifically comment on the percentage of patients who met the MCID. Of note, the MCID of these questionnaires is calculated for CRS patients and not tumor patients, and it is important to make a distinction between statistical significance and clinical significance particularly when investigating QOL. Three other studies only reported postoperative data, but suggested that postoperative SNOT-20 and SNOT-22 scores were comparable to those of normal healthy controls.^{2085,2091,2092}

2 | Differences between benign and malignant neoplasms

Comparison of QOL improvements between benign and malignant sinonasal tumors has also been investigated. Current data suggest that patients with benign sinonasal neoplasms experience significant sinonasal QOL improvement following minimally invasive endoscopic resection.^{2089,2090,2093} Consistently across these studies, patients with malignant tumors tended to have higher baseline SNOT-20 or SNOT-22 scores, and also tended to have less consistent QOL improvement after surgery. Improvement in SNOT-20 in patients with malignant tumors in Harrow and Batra's series failed to reach statistical significance at any time point postoperatively. In fact, only the sleep subdomain demonstrated a significant improvement at 6 months postoperatively. Similarly, Derousseau et al. did not report any significant improvement in SNOT-20 among patients with malignant tumors.²⁰⁹⁰ However, within the sleep and psychological subdomain, a significant reduction in SNOT-20 score was noted at 1 and 2 years postoperatively in the malignant tumor group. Contrary to the prior two studies, however, Glicksman et al. recorded significant improvements in overall SNOT-22 within both their benign and malignant tumor cohorts at all time points.²⁰⁹³ Similarly, all SNOT-22 subdomain scores demonstrated significant improvement in both groups. The authors report that the overall trajectory of improvement was similar between the groups, although the malignant group maintained relatively

higher scores at all time intervals.²⁰⁹³ Deckard et al. noted that postoperative sinonasal QOL was significantly better in benign tumor patients according to the anterior skull base questionnaire and SNOT-20.²⁰⁸⁵ Together, these findings suggest that patients with benign tumors tend to have less severe QOL impacts at baseline. Additionally, benign tumor patients consistently experience statistically significant QOL improvement after surgery, while improvements in those with malignant tumors are less predictable, and may be impacted by the requirement for adjuvant therapy.

3 | Morbidity related to extended maxillary approaches

Expanded endoscopic approaches to sinonasal tumors have allowed surgeons to extirpate progressively more advanced tumors through a purely endoscopic approach. How these expanded approaches affect disease outcomes, namely, recurrence rate, complications, and survival, has been extensively investigated (Table XXXI.A.1). However, evaluation of QOL using validated metrics is less commonly reported. In their series of 37 patients with sinonasal IP, van Samkar and Georgalas did not find any difference in SNOT-22 scores among patients who required medial maxillectomy for tumor resection compared to those who underwent standard endoscopic surgical techniques for tumor removal.²⁰⁹¹ Additionally, Bertazzoni et al. reviewed their series of 48 patients who underwent the Sturmman–Canfield procedure (removal of the entire medial wall of the maxillary sinus, sectioning of the nasolacrimal duct, and enlargement of the pyriform aperture laterally up to the infraorbital foramen, similar to the modified endoscopic Denker technique) for resection of maxillary sinus IP.^{2092,2095} The study only included postoperative data, but the mean SNOT-22 score in this series was 5.94. The mean follow-up in this series was 66.3 months, though the authors do not comment on the time point at which the SNOT-22 questionnaire was filled out by patients. Although there is no control group in this series, the low mean SNOT-22 score suggests that this expanded approach may not significantly impact overall sinonasal QOL. Finally, Lin and Chen reported their series of 21 patients who underwent the endoscopic prelacrimal approach for a variety of benign maxillary sinus lesions.²⁰⁹⁴ Median postoperative SNOT-22 scores were 8.0 in those with papillomas and 13.5 in patients with non-papilloma pathology. Within the papilloma group, despite a reduction in overall SNOT-22 from 17.5 preoperatively to 8.0 postoperatively, statistical significance was not met. However, with mean total SNOT-22 scores of a control population reported to be 12.0, these data would suggest that the expanded prelacrimal approach for benign maxil-

TABLE XXXI.A.1 Evidence surrounding morbidity related to extended maxillary approaches.

Study	Year	LOE	Study design	Study groups	Clinical endpoints	Conclusion
Glicksman et al. ²⁰⁹³	2018	3	Prospective cohort	1. Benign tumors (<i>n</i> = 81) 2. Malignant tumors (<i>n</i> = 64)	SNOT-22	1. Lower preoperative SNOT-22 scores in benign tumors 2. Reduction in SNOT-22 scores at all time intervals in both benign and malignant tumors 3. Rhinologic, sleep, and psychological domains had greatest impact on QOL in benign tumors 4. Benign and malignant tumors had similar trend in improvement, but malignant had higher scores at all time points
Derausseau et al. ²⁰⁹⁰	2015	3	Prospective cohort	1. IP (<i>n</i> = 32) 2. Malignant tumors (<i>n</i> = 72)	SNOT-20	1. Baseline rhinologic and sleep domains have largest impact 2. Significant reduction in SNOT-20 at 6 months postoperatively (1.04 > 0.53) 3. Overall and all subdomains significantly lower in benign compared to malignant at 6 months
Deckard et al. ²⁰⁸⁵	2015	3	Prospective cohort	1. Benign (<i>n</i> = 39) 2. Malignant (<i>n</i> = 32)	1. SNOT-20 2. ASBQ 3. EQ-5D	1. Only postoperative data 2. Benign tumors had significantly improved ASBQ and SNOT-20 scores as compared to malignant tumors
Harrow and Batra ²⁰⁸⁹	2013	3	Prospective cohort	1. Benign (<i>n</i> = 45) 2. Malignant (<i>n</i> = 49)	SNOT-20	1. Lower preoperative SNOT-20 scores in benign tumors 2. Baseline rhinologic and sleep domains have largest impact 3. Significant reduction in mean SNOT-20 postoperatively in benign (1.11 > 0.58) 4. Insignificant reduction in SNOT-20 postoperatively in malignant tumors
Lin and Chen ²⁰⁹⁴	2020	4	Retrospective case series	1. Papilloma (<i>n</i> = 9) 2. Nonpapilloma (<i>n</i> = 12)	1. SNOT-22 2. VAS for overall health	1. QOL after prelacrima approach to maxillary sinus 2. Preop SNOT-22 and VAS were better in the papilloma group, but only the nonpapilloma group demonstrated significant improvement postoperatively 3. No difference in postoperative VAS or SNOT-22 between papilloma and nonpapilloma groups

(Continues)

TABLE XXXI.A.1 (Continued)

Study	Year	LOE	Study design	Study groups	Clinical endpoints	Conclusion
Bertazzoni et al. ²⁰⁹²	2017	4	Retrospective case series	IP (<i>n</i> = 59)	SNOT-22	<ol style="list-style-type: none"> 1. Only postoperative data after Sturmann–Canfield procedure (modified endoscopic Denker) 2. Mean and median SNOT-22 scores consistent with general population 3. Rhinologic and sleep subdomains have greatest impact
van Samkar and Georgalas ²⁰⁹¹	2015	4	Retrospective case series	IP (<i>n</i> = 34)	SNOT-22	<ol style="list-style-type: none"> 1. Only postoperative data 2. Postoperative SNOT-22 scores comparable to general population 3. No QOL impact in those undergoing medial maxillectomy compared to standard endoscopic approaches

Abbreviations: ASB-QOL, Anterior Skull Base QO; EQ-5D, European Quality-of-life-5 Dimension; IP, inverted papilloma; QOL, quality of life; SNOT, Sino-Nasal Outcome Test; VAS, visual analog scale.

lary sinus tumors does not significantly impair sinonasal QOL.²⁰⁹⁶

Aggregate grade of evidence: C (Level 3: four studies; Level 4: three studies)

B | Quality of life for malignant neoplasms

1 | Baseline QOL

SNM, and its associated surgical interventions, can cause significant morbidity.^{14,267,476,1199,2097–2099} With advancements in surgical technique and multidisciplinary interventions, greater focus has been placed on optimizing posttreatment QOL and minimizing morbidity while maximizing survival (Table XXXI.B.1).^{1513,2054} Patients with SNM can present with variable symptoms, including epistaxis, nasal obstruction, rhinorrhea, seizures, orbital pathology, cranial nerve palsies, and headaches, among others.^{267,2097,2098,2100} Overall, QOL research is limited by the fact that the questionnaires typically used are validated for clinical conditions other than SNM specifically.^{2085,2090,2093,2101–2103} Glicksman et al. calculated a mean baseline total SNOT-22 score of 37 (range 0–110) in patients with SNM, and Derousseau et al. computed a baseline SNOT-20 score of 1.13 (range 0–5) in a cohort of patients with sinonasal and skull base tumors.^{2090,2093} Deckard showed that advanced T stage was associated with worse baseline QOL.²⁰⁸⁵

Aggregate level of evidence: C (Level 3: five studies; Level 4: two studies)

2 | Postoperative QOL

Several studies have shown that QOL can improve postoperatively. In Glicksman's analysis, patients who underwent surgery experienced statistically and clinically significant improvements in total SNOT-22 and subdomain scores 6, 12, and 24 months postoperatively compared to baseline.²⁰⁹³ While Derousseau's study described similar total and subdomain SNOT-20 scores at 6 months postoperatively when compared to preoperative scores, the SNOT-20 total score and psychological and sleep subdomain scores did improve 1 and 2 years after surgery.²⁰⁹⁰

Certain baseline characteristics may predict worse postoperative QOL. Phillips et al. showed that less social support, single relationship status, and higher T-stage classification independently predicted more severe post-treatment anxiety and depression.²¹⁰³ Worse social support also independently predicted lower overall QOL. Smoking has also been shown to be predictive for diminished postoperative QOL, based on the SNOT-20.²⁰⁹⁰

3 | Morbidity related to orbital resection or orbitotomy

Controversy exists regarding the indications for orbital exenteration and orbital preservation, and management

TABLE XXXI.B.1 Evidence surrounding baseline QOL in sinonasal malignancies.

Study	Year	LOE	Study design	Study groups	Clinical endpoints	Conclusions
Philips et al. ²¹⁰³	2020	3	Retrospective cohort	81 patients with SNM who underwent definitive treatment, 87% of whom underwent surgery	1. Posttreatment QOL 2. Predictors of QOL	1. 34% of patients had scores suggestive of borderline depression or anxiety, and 14.8% had scores associated with significant depression or anxiety 2. Worse social support independently predicted lower overall QOL
Glicksman et al. ²⁰⁹³	2018	3	Prospective cohort	82 patients who underwent endoscopic resection of SNM	SNOT-22 scores 1. Baseline 2. Up to 24 months after surgery	1. Mean baseline total SNOT-22 score: 37.0 (95% CI: 32.0–42.1) 2. Postoperative SNOT-22 scores: 28.5 (95% CI: 23.4–33.7) at 6 months, 26.5 (95% CI: 20.4–32.5) at 12 months, and 26.5 (95% CI: 20.8–32.2) at 24 months 3. Statistically significant improvement in all SNOT-22 subdomains at all time points
Cao et al. ²⁶⁷	2017	3	Retrospective cohort	33 patients with sinonasal mucosal melanoma who underwent resection	1. Baseline symptoms 2. Perioperative complications	1. Epistaxis and nasal obstruction were the most common presenting symptoms 2. No patients experienced severe perioperative complications
Deckard et al. ²⁰⁸⁵	2015	3	Prospective cohort	71 patients with sinonasal and skull base tumors, 39 of which were malignant	1. SNOT-22 2. ASBQ 3. EQ-5D 4. LKE scores	1. Patients with higher T-stage tumors had worse SNOT-20, ASBQ, and LKE scores than those with lower T-stage tumors 2. Patients with malignant tumors had worse SNOT-20, ASBQ, and LKE scores than those with benign tumors
Derousseau et al. ²⁰⁹⁰	2015	3	Prospective cohort	72 patients with SNM who underwent endoscopic resection	1. Baseline SNOT-20 score 2. Postoperative change in SNOT-20 score	1. Baseline SNOT-20 score: 1.13 2. Postoperative change in SNOT-20 score: 0 (6 months), –0.22 (1 year), –0.29 (2 years) 3. No statistical change in total SNOT-22 score or rhinologic or ear/face subdomain scores between the preoperative and postoperative time points 4. Statistically significant improvement in SNOT-22 psychological and sleep subdomain scores between the preoperative and 1- and 2-year postoperative time points
Goel et al. ²¹⁰²	2019	4	Retrospective database study (National Readmissions Database)	5346 patients who underwent resection of SNM	Incidence of baseline frailty	7.4% of patients were defined as frail at baseline

(Continues)

TABLE XXXI.B.1 (Continued)

Study	Year	LOE	Study design	Study groups	Clinical endpoints	Conclusions
Bisogno et al. ²¹⁰⁰	2012	4	Retrospective case series	Nine patients with ONB, four of whom underwent surgical resection	1. Baseline symptoms 2. Long-term sequelae	1. Baseline symptoms included recurrent epistaxis (2), nasal obstruction (1), seizures (1), exophthalmos (1), proptosis (1), cranial nerve palsy (1), and headache (1) 2. Long-term sequelae included chronic sinusitis (1), hyposmia (1), chronic headache (1), and facial bone hypoplasia (1)

Abbreviations: ASB-QOL, Anterior Skull Base QOL; LKE, Lund–Kennedy endoscopy score; ONB, olfactory neuroblastoma; QOL, quality of life; SNM, sinonasal malignancy; SNOT, Sino-Nasal Outcome Test; VAS, visual analog scale.

decisions intend to balance the associated morbidity of surgery and other treatments against the risk of recurrence (Table XXXI.B.2).^{166,2104} Surgical complications have been reported with both orbital exenteration and orbital preservation. Traylor et al. studied 180 patients who underwent orbital exenteration for malignancies, 40 of which were for sinonasal primary tumors.²¹⁰⁵ The 30-day postoperative complication rate was 15%, with surgical site infections, CSF leak, and pneumonia being the most frequent. The most common Clavien–Dindo grade was II (9%), followed by IIIa (2%) and IVa (2%). Sugawara et al. evaluated 15 patients who underwent CFR with orbital exenteration for SNM involving the orbital apex; they reported a postoperative infection rate of 33% but no new neurologic deficits in any patients postoperatively.¹⁶⁶ Spiegel and Varvares described a series of four patients with intracranial complications (three with large abscesses, one with symptomatic epidural enhancement) after orbital exenteration who were successfully treated with free flap obliteration of the orbital cavity.²¹⁰⁴

Rajapurker et al. studied 19 patients who underwent resection of SNM with orbital preservation and found globe malposition ($n = 2$), enophthalmos ($n = 3$), and diplopia ($n = 2$) among the postoperative sequelae.⁵¹¹ Imola et al.'s analysis found a higher (63%) rate of globe malposition after orbital preservation surgery.³³⁸ Stern et al. studied 18 patients who underwent orbital preservation surgery and found that resection of the orbital floor led to a 39% rate of ectropion compared to a rate of 20% with preservation of the floor.²¹⁰⁶ Li et al. reported a variety of complications after orbital exenteration or orbitotomy, including local wound infection, CSF leak requiring reoperation, intracranial abscess necessitating drainage, and intraorbital infection requiring orbital decompression.¹⁶⁴ However, Li's study did not clearly delineate whether the complications were found in the orbitotomy or in the exenteration cohorts.

Multiple authors have described the ophthalmic functional outcomes associated with orbital preservation strategies in the management of SNM. The treatment outcomes in this population reflect either primary surgery, neoadjuvant or adjuvant therapies, or revision surgery for tumor recurrence.^{164,220,336,338,511,2106} Because many orbital preservation patients receive multimodal therapy, it can be difficult to assess the relative contribution of each therapy to specific outcomes. These ocular and orbital sequelae can include visual loss, cataract formation, dry eye, keratitis, keratopathy, ectropion, enophthalmos, diplopia, epiphora, among others. Imola et al. found that 91% of patients who underwent orbital preservation surgery had a useful seeing eye (range of follow-up: 2–10.5 months after surgery) and 74% had no change in vision.³³⁸ However, 41% had one or more ocular symptoms, two patients had only light perception, and one had no light perception. Looking further, Ferrari et al. reported functional eye rates reaching 92.8% and 86.6% when measured 5 and 10 years after orbital preservation treatment, respectively.²²⁰ Similarly, Turri-Zanoni described a 4% rate of nonfunctional eye after orbital preservation.¹⁶⁵ In patients with ONB who had orbital invasion, Li et al. showed that 63% of patients treated with orbital preservation and RT had no visual impairment or grade 1 visual impairment, while 9% had grade 2, 11% grade 3, and 13% grade 4.⁴⁹⁵ Looking specifically at outcomes after orbital floor resection, Stern found a variety of potential functional impairments, including ectropion, enophthalmos, diplopia, keratitis, and no light perception.²¹⁰⁶ Ferrari et al. found that tumor involvement of extraconal fat was predictive of worse orbital dysfunction-free survival.²²⁰ Despite these positive reports, it should be noted that these outcomes are reported retrospectively with the potential for significant selection bias in the patients offered this intervention.

While there is a fairly well-defined body of literature on surgical complication rates and functional orbital out-

TABLE XXXI.B.2 Evidence surrounding morbidity related to orbital resection/orbitotomy for sinonasal tumors.

Study	Year	LOE	Study design	Study groups	Clinical endpoints	Conclusions
Traylor et al. ²¹⁰⁵	2021	3	Retrospective cohort	180 patients who underwent orbital exenteration for malignancies. 40 of these were for sinonasal primary tumors	<ol style="list-style-type: none"> 30-day postoperative complications Clavien–Dindo classification 	<ol style="list-style-type: none"> 15% of patients had 30-day postoperative complications, including surgical site infections (7%), CSF leak (2%), pneumocephalus (<1%), cerebral edema (<1%), epidural hematoma (<1%), and pneumonia (3%) Clavien–Dindo classification: Grade I (0), Grade II (9%), Grade IIIa (2%), Grade IIIb (<1%), Grade IVa (2%), Grade IVb (0), and Grade V (<1%)
Li et al. ⁴⁹⁵	2019	3	Retrospective case series	72 patients with ONB who underwent resection (53% endoscopic) and RT. Seven (10%) had orbital exenteration and 65 (90%) orbital preservation	Visual impairment	Orbital preservation group: 63% had no or grade 1 visual impairment, 9% had grade 2 visual impairment, 11% grade 3, and 13% grade 4
Imola and Schramm ³³⁸	2002	3	Retrospective cohort	66 patients who underwent resection of SNM involving the orbit: 12 orbital exenteration and 54 orbital preservation	<ol style="list-style-type: none"> Functional outcomes Change in vision Other ocular sequelae 	<ol style="list-style-type: none"> 91% of patients had a useful seeing eye, 41% of whom had one or more ocular symptoms 40 patients had no subjective change in vision, nine had partial loss of vision with continued serviceable vision, two had partial loss with non-serviceable residual vision, two had only light perception, and one no light perception 34 patients had globe malposition. Additional findings included ectropion (11), blepharitis (18), corneal exposure keratopathy (6), epiphora (7), dryness (5), optic atrophy (2), and cataract formation (4)
Stern et al. ²¹⁰⁶	1993	3	Retrospective cohort	18 patients who underwent total maxillectomy with resection of orbital floor versus 10 patients with preservation of orbital floor	Functional outcomes after <ol style="list-style-type: none"> Orbital floor resection Orbital floor preservation 	<ol style="list-style-type: none"> Resection of orbital floor outcomes: no light perception (2), ectropion (7), enophthalmos (3), keratitis (4), keratopathy (2), diplopia (4), and optic atrophy (1) Preservation of orbital floor outcomes: ectropion (2), epiphora (1), keratitis (1), and local tumor recurrence followed by exenteration (1)

(Continues)

TABLE XXXI.B.2 (Continued)

Study	Year	LOE	Study design	Study groups	Clinical endpoints	Conclusions
Ferrari et al. ²²⁰	2021	4	Retrospective case series	123 patients with SNM: 76 underwent orbital preservation surgery and 47 orbital exenteration	<ol style="list-style-type: none"> 1. Functional outcomes 2. Predictors of orbital dysfunction-free survival 	<ol style="list-style-type: none"> 1. 92.8% and 86.6% of patients at 5 and 10 years, respectively, who underwent orbital preservation surgery had functional eyes 2. Four patients in the preservation group ultimately required orbital exenteration for recurrence 3. Involvement of extraconal fat was predictive of worse orbital dysfunction-free survival rates
Li et al. ¹⁶⁴	2020	4	Retrospective case series	88 patients with sinonasal tumors: 72 underwent surgery and radiation (seven orbital exenteration and 65 orbital preservation)	Postoperative complications	Postoperative complications included local wound infection (2), CSF leak requiring reoperation (1), intracranial abscess requiring drainage (1), and intraorbital infection requiring orbital decompression (1)
Rauchenwald et al. ²¹⁰⁷	2020	4	Retrospective case series	Two patients who underwent orbital exenteration with free flap reconstruction	Postoperative <ol style="list-style-type: none"> 1. SNOT-22 2. NOSE 3. Nasal endoscopy 	<ol style="list-style-type: none"> 1. SNOT-22: responses for nasal obstruction and need to blow nose ranged from “none” to “moderate” 2. NOSE: one patient had mild nasal obstruction and the second had moderate obstruction 3. Nasal endoscopy: Patent nasal cavities on postoperative endoscopy
Turri-Zanoni et al. ¹⁶⁵	2019	4	Retrospective case series	163 patients with sinonasal tumors involving the orbit: 38 underwent orbital exenteration and 125 orbital preservation	Postoperative functional outcomes	<ol style="list-style-type: none"> 1. 96% of patients with orbital preservation had a functional eye, while 4% had a nonfunctional eye 2. Enophthalmos (21), diplopia (9), and epiphora (7) were common sequelae
Sugawara et al. ¹⁶⁶	2015	4	Retrospective case series	15 patients with SNM involving the orbital apex treated with CFR and orbital exenteration	<ol style="list-style-type: none"> 1. New postoperative neurological deficits 2. Perioperative complications 	<ol style="list-style-type: none"> 1. No new postoperative neurological deficits 2. Five patients (33%) had postoperative infections.
Rajapurkar et al. ⁵¹¹	2012	4	Retrospective case series	19 patients with SNM who underwent orbital preservation surgery	Postoperative functional outcomes	<ol style="list-style-type: none"> 1. 11 out of 16 had no functional impairments 2. Functional impairments related to surgery included diplopia (2), globe malposition (3), and enophthalmos (2)
Spiegel and Varvares ²¹⁰⁴	2007	4	Retrospective case series	Four patients who underwent orbital exenteration and developed intracranial complications	Postoperative complications	<ol style="list-style-type: none"> 1. Three patients developed had large brain abscesses 2. One patient had epidural enhancement and neurologic symptoms 3. Three patients underwent free flap obliteration of the orbital cavity with subsequent resolution of symptoms

Abbreviations: CRF, craniofacial resection; NOSE, Nasal Obstruction Symptom Evaluation; RT, radiation therapy; SNM, sinonasal malignancy; SNOT, Sino-Nasal Outcome Test.

comes, the literature on sinonasal outcomes associated with orbitotomy and orbital resection is more limited. To prevent nasal obstruction associated with free flap reconstruction after orbital exenteration, Rauchenwald et al. performed nasal splinting for 4 weeks after surgery.²¹⁰⁷ Postoperatively, one patient had mild nasal obstruction based on the NOSE questionnaire, and the second patient had moderate nasal obstruction. Both had patent nasal cavities on postoperative endoscopy. SNOT-22 line-item responses for nasal obstruction and need to blow nose ranged from “none” to “moderate.”

Aggregate level of evidence: C (Level 3: three studies; Level 4: eight studies)

4 | Morbidity related to intradural resection

Morbidity from intradural resection can include olfactory dysfunction, neurocognitive symptoms (anxiety, emotional burden, memory deficits, visual motor speed, frontal lobe executive function), cerebrovascular complications, intracranial infections, central endocrine dysfunction, and visual symptoms (e.g., vision changes, diplopia) (Table XXXI.B.3).²⁰⁹⁸ Mehta et al. reviewed 252 patients with SNM involving the skull base (89% of which required durotomy) and found an overall perioperative complication rate of 28%, including 18% who had major complications (Clavien–Dindo grades IIIb–V).¹⁷⁹ Complications included symptomatic pneumocephalus, epidural hematoma, CSF leak, diplopia, wound complications, and infection. Yeung et al. evaluated 17 patients with T4b SNM with intracranial extension who underwent salvage resection and calculated a 35% perioperative complication rate, including CSF leak (18%), free flap congestion (6%), subcortical infarct without sequelae (6%), and death (6%, $n = 1$).²¹⁰⁸ Ziai et al. showed statistically similar rates of complications between 21 patients who underwent dural resection and 16 patients who had no dural resection.²¹⁰⁹ Complications included meningitis ($n = 1$), abscess ($n = 1$), other infection ($n = 6$), and pneumocephalus ($n = 1$).

Various patient-reported outcome measures have been used to characterize the QOL impact of transdural/intradural surgery. Tyler et al. showed no difference in postoperative QOL between extradural ($n = 29$) and transdural ($n = 9$) resection of SNM, based on the global EQ-5D visual analog scale.²¹¹⁰ Patients with extradural versus intradural surgery had similar scores on the disease-specific MD Anderson Symptom Inventory-Head and Neck (MDASI-22), and Anterior Skull Base Questionnaire (ASBQ) when measured a median of 65 months after treatment. Advanced T-stage tumors, however, were associated with worse ASBQ total scores.²¹¹⁰ Based on the MDASI-22, diminished taste (25%) and mucus in throat

(20%) were cited by patients as two of their most severe symptoms. In the ASBQ, symptoms reported as being most severe included those involving sense of smell (40% of patients), nasal secretions (39%), and taste (39%). However, none of these instruments are designed or able to measure frontal lobe function and to date, no neuropsychiatric or neurocognitive studies of this patient population exist. Furthermore, the multimodality therapies deployed in this T4 disease again muddy the impact of surgery and RT on morbidity.

Postoperative hyposmia/anosmia is a specific concern in the treatment of ONB.^{374,1361,2111} Sun et al. studied SNOT-22 scores in patients with Kadish stage C esthesioneuroblastoma a median of 42.3 months after endoscopic resection and found worsened olfactory scores compared to preoperative baseline.²¹¹¹ Tajudeen et al. administered the UPSIT to 14 patients with ONB who underwent endoscopic unilateral resection with preservation of one contralateral olfactory bulb, followed by a full course of adjuvant RT.¹³⁶¹ After a mean of 37.3 months after treatment, six (43%) of patients had residual smell function, two (14%) of whom had normal or only mildly reduced smell function. Schreiber et al. demonstrated that patients who underwent transnasal craniectomy with unilateral resection had higher rates of subjective olfactory preservation (46% vs. 0%), compared to those who underwent bilateral resection.³⁷⁴ However, by objective UPSIT testing, 82% of the unilateral resection group patients had anosmia, whereas 18% had severe hyposmia. The median UPSIT score for the unilateral resection group was 12 (range 5–27), while scores in the bilateral resection group were not reported. In the pediatric population, Maggiore et al. showed in a case report that preservation of the contralateral olfactory bulb enabled normal postoperative olfactory function, with a postoperative UPSIT of 38.²¹¹²

Aggregate level of evidence: C (Level 3: three studies; Level 4: four studies)

XXXII | QOL AFTER MULTIMODALITY TREATMENT FOR SINONASAL MALIGNANCIES

As treatment outcomes of SNM continue to improve, there is increasing focus on the long-term treatment side effects and QOL of survivors. This shift is occurring throughout oncology but is particularly important in SNM due to the proximity of the treatment field to critical structures (i.e., optic apparatus, cranial nerves, brain). Newer modalities including proton beam therapy and immunotherapy attempt to optimize oncologic outcomes while minimizing morbidity associated with traditional therapies, which has increasingly led to the inclusion of QOL and functional

TABLE XXXI.B.3 Evidence surrounding morbidity related to intradural resection for sinonasal tumors.

Study	Year	LOE	Study design	Study groups	Clinical endpoints	Conclusions
Tyler et al. ²¹¹³	2019	3	Cross-sectional study	114 patients who underwent treatment (<i>n</i> = 38 extradural and nine transdural) for sinonasal or nasopharyngeal carcinoma	Specific QOL scores using 1. EQ-5D VAS 2. ASBQ 3. MDASI-22 4. Comparison of QOL scores	1. Mean EQ-5D VAS score of 71.1 (22.3) 2. Mean ASBQ sum score of 128.3 (26.4) 3. Mean MDASI-22 composite score of 47.3 (35.1) 4. No difference in EQ-5D, VAS, ASBQ, and MDASI-22 scores with extradural versus transdural surgery 5. Patients had similar EQ-5D VAS scores as the general population 12 months after treatment
Schreier et al. ³⁷⁴	2018	3	Retrospective cohort	54 patients with sinonasal adenocarcinoma: 27 underwent unilateral endoscopic resection with transnasal craniectomy (uERTC) and 27 patients bilateral (bERTC)	1. Complication rate 2. Olfaction 3. SNOT-22 score	1. Most common complications were epistaxis (2), postoperative fever (3), lacrimal stenosis (4), CSF leak (2), and pulmonary embolism (2) 2. 46% of patients after uERTC had olfactory function, with a median UPSIT of 12 (range 5–27) 3. Statistically similar postoperative SNOT-22 scores between uERTC and bERTC (median 13.5 vs. 11.0)
Ziai et al. ²¹⁰⁹	2018	3	Retrospective cohort	37 patients with SNM, 21 of whom underwent dural resection and 16 who did not	Postoperative complications	1. Complications included CSF leak, infection, meningitis, abscess, and pneumocephalus 2. Patients who underwent dural resection had higher but statistically insignificant postoperative complication rates 3. Similar rate of CSF leaks between groups
Mehta et al. ¹⁷⁹	2022	4	Retrospective case series	252 patients with SNM involving the anterior skull base with a mean follow-up of 6.5 years	1. Complications and associated factors 2. Ophthalmological outcomes	1. 28% overall complication rate 2. Complications included symptomatic pneumocephalus (7%), epidural hematoma (7%), CSF leak (5%), wound complications (4%), and infection (3%)—18% major complication rate (Clavien–Dindo classification [grades IIIb, IV, and V]) 3. 2.9% had ocular findings (5% permanent), with the most common being diplopia
Yeung et al. ²¹⁰⁸	2021	4	Retrospective case series	17 patients with T4b SNM with intracranial extension who underwent salvage resection	Perioperative complications	Six of 17 patients had perioperative complications, including CSF leak (<i>n</i> = 3), free flap congestion and edema (<i>n</i> = 1), subcortical infarct without long-term sequelae (<i>n</i> = 1), and death (<i>n</i> = 1) from pneumonia and cardiogenic shock

(Continues)

TABLE XXXI.B.3 (Continued)

Study	Year	LOE	Study design	Study groups	Clinical endpoints	Conclusions
Sun et al. ²¹¹¹	2021	4	Retrospective case series	26 patients who underwent endoscopic resection of Kadish stage C ONB and were evaluated a median of 42.3 months after surgery	Change in SNOT-22 score	<ol style="list-style-type: none"> Improvement in postoperative SNOT-22 question scores for frustration/restlessness/irritability, difficulty falling asleep, nasal obstruction, waking up tired, and waking up at night SNOT-22 score for olfaction worsened after surgery
Tajudeen et al. ¹³⁶¹	2016	4	Retrospective case series	14 patients with ONB who underwent endoscopic resection with preservation of one olfactory bulb and adjuvant RT	Posttreatment UPSIT scores	<ol style="list-style-type: none"> UPSIT scores (mean 37.3 months after treatment) ranged from 8 to 38 Six (43%) patients had residual smell function, two (14%) of whom had normal or mildly reduced smell

Abbreviations: ASB-QOL, Anterior Skull Base QOL; bETC, bilateral endoscopic resection with transnasal craniectomy; EQ-5D VAS, validated global [(EuroQol-5D) Visual Analog Scale; FACT-NP, Functional Assessment Cancer Therapy—Nasopharynx; HADS, Hospital Anxiety Depression Scale; MDASI-22, MD Anderson Symptom Inventory-Head and Neck (MDASI-HN); ONB, olfactory neuroblastoma; QOL, quality of life; SNM, sinonasal malignancy; SNOT, Sino-Nasal Outcome Test; uERTC, Unilateral endoscopic resection with transnasal craniectomy; UW-QOL, University of Washington-Quality Life.

outcomes in trials. Here, we review the data on treatment morbidity and QOL outcomes in SNM.

A | General QOL following multimodality treatment

As noted in a focus group study examining symptoms that persistently affect QOL after SNM treatment, multimodality SNM treatment impacts multiple aspects of QOL including visual changes, nasal crusting, memory changes, loss of work and hobby, and change in family relationships (Table XXXII.1).²⁰⁷⁵ In a recent review by Noel et al., the authors found that physical QOL in survivors tended to be affected by physical symptoms such as headache and nasal congestion, while emotional QOL was affected by social isolation and cognitive changes.²⁰⁶⁶ In most studies, QOL is worse in the first several months after treatment but improves in most domains over time.^{2088,2114–2116} Similarly, performance status has also been shown to improve with time after treatment.²¹¹⁷ A recent study by Fisher et al. examined general health-related QOL (HRQOL) after SNM treatment via the SF-36 and found HRQOL equivalent to controls without SNM at a median of 9 years after treatment.²¹¹⁸

Despite improvements of many general QOL metrics over time, multiple studies have shown that symptoms related to the sinonasal region do not completely resolve in many patients. Recent studies by Tyler et al. and Phillips et al. found that patients had decreased sinonasal

QOL, as measured by the Anterior Skull Base Questionnaire (ASBQ) and the FACT-NP questionnaires, respectively, at a median of 2 and 5 years after completion of therapy.^{2103,2113} Furthermore, both studies found that diminished sinonasal-specific QOL was associated with worse general QOL and symptoms of anxiety and depression. Lee et al. examined a large national database and found that diagnoses of mental health disorders increased from 22% to 31% after SNM diagnosis. All treatment modalities were associated with increased odds of development of mental health disorder, but receipt of RT was associated with the highest odds for development.²¹¹⁹ Substantial rates of depression and anxiety are also noted in multiple other studies.^{2088,2120,2121}

Due to the proximity to critical brain structures, neurocognitive effects frequently follow SNM treatment. Sharma et al. found that 63% of patients experienced neurocognitive deficits in at least one domain after treatment for SNM, and patients self-reported impaired memory.⁴⁹⁰

General QOL following multimodality treatment

Aggregate level of evidence	C (Level 1: one study; Level 3: six studies; Level 4: two studies)
-----------------------------	--

Benefit	Treatment of SNM is critical to long-term survival and disease control.
---------	---

(Continued)

TABLE XXXII.1 Evidence surrounding general QOL after treatment for SNM.

Study	Year	LOE	Study design	Study groups	Clinical endpoints	Conclusion
de Almeida et al. ²⁰⁷⁰	2012	1	Retrospective cohort and systematic review	138 patients undergoing endoscopic or open skull base surgery for anterior or central lesions	<ol style="list-style-type: none"> 1. Postoperative physical complaints 2. Physical and nonphysical QOL domains 3. Themes identified from focus groups 	<ol style="list-style-type: none"> 1. In the focus groups, the top categories mentioned were sight, lost work, hobbies, crusting, memory, family relations, energy, headache, smell, and social relations 2. Of the nonphysical domains, social and financial domains were referenced more in the open surgery group and spiritual, family, emotional, and cognitive domains more in the endoscopic group 3. Of the physical domains, visual was referenced more in the open group and nasal and endocrine more in the endoscopic group
Phillips et al. ²¹⁰³	2021	3	Retrospective cohort	181 patients treated for SNM with various modalities (surgery, chemotherapy, and/or RT)	QOL as measured by the HADS and FACT-NP scores	<ol style="list-style-type: none"> 1. 15% of patients had HADS subscale scores >11, indicating severe anxiety or depression 2. On the FACT-NP, physical well-being had the highest median score and emotional/functional well-being had the lowest 3. Advanced T stage, single status, and worse social support were associated with higher HADS scores, and worse social support was associated with worse FACT-NP scores
Fisher et al. ²¹¹⁸	2021	3	Multicenter cross-sectional study	<ol style="list-style-type: none"> 1. 89 patients with skull base meningiomas 2. 84 patients with convexity meningiomas 3. 65 caregivers (controls) 	<ol style="list-style-type: none"> 1. QOL as measured by the SF-36 and EORTC QLQ-BN20 questionnaires 2. Neurocognitive functioning 	<ol style="list-style-type: none"> 1. General QOL on the SF-36 was similar between patients with skull base meningiomas and convexity meningiomas as well as controls at median of 9-year follow-up 2. Patients treated with RT had lower QOL in bodily pain and vitality domains than patients treated with surgery 3. 44% of skull base meningioma patients had deficits in at least one domain of neurocognitive functioning
Lee et al. ²¹¹⁹	2020	3	Retrospective database study (MarketScan database)	6760 patients with sinonasal/skull base cancer in the MarketScan database	Frequency of mental health disorders pre- and postdiagnosis	<ol style="list-style-type: none"> 1. Mental health disorders increased postdiagnosis versus prediagnosis 2. Patients with mental health disorders were more likely to be female and have a smoking history 3. RT was more strongly associated with development of a mental health disorder than surgery or chemotherapy

(Continues)

TABLE XXXII.1 (Continued)

Study	Year	LOE	Study design	Study groups	Clinical endpoints	Conclusion
Tyler et al. ²¹¹³	2020	3	Cross-sectional study	114 patients with sinonasal or nasopharyngeal malignancy treated with surgery, RT, and/or chemotherapy	QOL as measured by the EQ-5D VAS, MDASI, and ASBQ	<ol style="list-style-type: none"> 1. On the MDASI, xerostomia was the most burdensome symptom, followed by problems tasting food and difficulty swallowing/chewing 2. On the ASBQ, poor smell had the highest burden, followed by nasal secretions, poor sense of taste, and lack of energy 3. Advanced T3/T4 tumors were associated with worse ASBQ total scores
Abergel et al. ²¹¹⁴	2010	3	Prospective cohort	17 patients with malignant skull base tumors undergoing open anterior skull base surgery with or without RT	<ol style="list-style-type: none"> 1. QOL as measured by the ASBQ at 6 months 2. QOL as measured by the ASBQ at 12 months 	<ol style="list-style-type: none"> 1. QOL in patients with malignant tumors decreased from preoperatively to 6 months postoperatively, but increased back to baseline by 12 months postoperatively 2. For patients with malignant tumors, decreases in QOL at 6 months and subsequent increases at 12 months were seen in the role emotional, specific symptoms, pain, vitality, and physical function domains
Palme et al. ²¹²⁰	2009	3	Cross-sectional study	27 patients with skull base tumors (20 malignancy) undergoing surgery with postoperative RT ($n = 16$) and chemotherapy ($n = 2$)	QOL as measured by the FACT-HN, CES-D, ALHR, and MDS at a median follow-up of 5 years	<ol style="list-style-type: none"> 1. Based on the ALHR, most patients were very satisfied with their lives 2. Based on the CES-D, there were higher rates of depression in this cohort 3. On the MDS, 69% and 61% reported disturbance of smell and nasal crusting, respectively 4. Postop RT was associated with reduced FACT-HN subscale scores
Martinez-Devesa et al. ²¹²¹	2006	3	Cross-sectional study	18 patients treated for skull base malignancy with surgery and/or RT	QOL as measured by the UW-QOL and HADS	<ol style="list-style-type: none"> 1. Patients with ASB malignancy scored lower than those with lateral skull base malignancy on UW-QOL scale 2. For those with ASB tumors, taste, mood, anxiety, activity, and recreation were the worst individual domains 3. Three and four patients had probable anxiety and depression, respectively

(Continues)

TABLE XXXII.1 (Continued)

Study	Year	LOE	Study design	Study groups	Clinical endpoints	Conclusion
Sharma et al. ⁴⁹⁰	2020	4	Retrospective case series	27 patients previously treated with IMRT for SNM without recurrence	<ol style="list-style-type: none"> 1. Neurocognitive function 2. Brain abnormalities on MRI 3. QOL as measured by various scales 	<ol style="list-style-type: none"> 1. 17 patients (63%) had impaired cognitive function in at least one domain; the most affected domains were sustained attention and delayed verbal recall 2. Three participants had structural changes on MRI, all of whom had RT doses to the brain >60 Gy 3. Sleep deprivation and fatigue were the dominant factors for QOL deterioration 4. For self-reported cognitive function, memory was most affected

Abbreviations: ALHR, Atkinson Life Happiness Rating; ASBQ, Anterior Skull Base Questionnaire; CES-D, Center for Epidemiological Studies Depression Scale; EORTC QLQ-BN20, EORTC QOL Questionnaire: Brain Tumor Module; EQ-5D VAS, EuroQOL 5 Dimension Visual Analogue Scale; FACT-HN, Functional Assessment of Cancer Therapy: Head and Neck; FACT-NP, Functional Assessment of Cancer Therapy: Nasopharynx; HADS, Hospital Anxiety and Depression Scale; IMRT, intensity modulated radiation therapy; MDASI, MD Anderson Symptom Inventory; MDS, Midface Dysfunction Score; QOL, quality of life; RT, radiation therapy; SNM, sinonasal malignancy; UW-QOL, University of Washington QOL Score; VAS, visual analog scale.

Harm	SNM treatment affects multiple aspects of QOL, including physical aspects, such as sinonasal symptoms, as well as emotional aspects, with increased rates of mental health disorders and neurocognitive deficits. Most studies show that QOL is worse in the first several months after treatment but improves with time.
Cost	Cost comparison analyses have not been undertaken.
Benefits–harm assessment	Preponderance of benefits over harms.
Value judgments	Treatment of SNM does cause long-term side effects and decreased QOL; however, most symptoms improve with time after treatment. Most patients have persistently decreased sinonasal QOL, as well as a long-term elevated risk of mental health disorders and neurocognitive deficits.
Policy level	Recommendation.
Intervention	QOL is expected to decrease following treatment for SNM, and treating providers should counsel patients on this accordingly. Patients should expect to have worse symptoms, particularly with regard to sinonasal symptoms, in the first several months, but these should gradually improve with time. Providers should be aware of increased rates of cognitive deficits and mental health disorders in this population.

B | Morbidity following surgical treatment

Surgery is the cornerstone of treatment for most SNM, and its accompanying morbidity is at the forefront for survivorship (Table XXXII.2). A multicenter collaborative retrospective study by Ganly et al. found a 36% rate of acute postoperative complications and 5% mortality after open CFR.²⁰⁵⁶ A recent single-institution study of primarily open surgery for SNM revealed a 14% rate of Clavien–Dindo complication (grade ≥ 3) and 30-day mortality rate of 2%.²⁰⁵⁴ Gray et al. found that 17 out of 31 patients undergoing open CFR experienced delayed complications, most commonly orbital.²¹²² However, the applicability of these and similar studies may be limited by recent technological and treatment innovations.^{185,2114,2123}

Endoscopic and combined resection are thought to reduce morbidity of the surgical approach. With the increased adoption of endoscopic surgery, its side effect profile has come under critical review. A review by Su et al. concluded that endoscopic surgery is associated with decreased complications and faster recovery.^{1084,2056} A more recent multi-institutional cohort study by Beswick et al. found that open resection was associated with a threefold odds of complication compared to endoscopic resection.¹⁴ On the other hand, endoscopic resection has been associated with increased nasal morbidity, including hyposmia, nasal crusting, thick nasal discharge, epistaxis, and postnasal drip.²⁰⁸⁸ In addition, many patients expe-

TABLE XXXII.2 Evidence surrounding QOL after surgical treatment for SNM.

Study	Year	LOE	Study design	Study groups	Clinical endpoints	Conclusion
Bhenswala et al. ²¹²⁵	2019	2	Meta-analysis of prospective cohort studies	1025 patients undergoing EEA for skull base pathologies, including 137 with SNM	SNOT-22 scores preoperatively and postoperatively up to 96 weeks	<ol style="list-style-type: none"> SNOT-22 scores initially decreased after surgery at <4 weeks but subsequently improved to better than baseline by 12 weeks Intranasal pathology was associated with worse preoperative SNOT-22 scores than intracranial pathology alone, and this difference persisted at 52 weeks
Beswick et al. ¹⁴	2021	3	Prospective cohort	<ol style="list-style-type: none"> 44 patients undergoing resection of SNM via an open/combined approach 98 patients undergoing resection of SNM via EEA 	Surgical complications	<ol style="list-style-type: none"> 16% of patients had a complication, including CSF leak, visual changes, meningitis, and CRS Adjuvant RT was not associated with odds of complications Male sex was associated with decreased odds of complication and open resection was associated with increased odds of complication
Glicksman et al. ²⁰⁹³	2018	3	Prospective cohort	145 patients with malignant ($n = 64$) or benign ($n = 81$) sinonasal tumors undergoing endoscopic tumor resection	SNOT-22 scores preoperatively and over a 2-year follow-up period	<ol style="list-style-type: none"> SNOT-22 scores were higher in patients with malignant disease at baseline There was an improvement in SNOT-22 scores from baseline to 2 years in patients with malignant tumors Much of the improvement in sinonasal QOL was seen in rhinologic and sleep subdomains Decreased SNOT-22 scores were seen in those who received adjuvant RT or chemotherapy
Upadhyay et al. ²¹³²	2017	3	Prospective cohort	42 patients undergoing endoscopic resection of skull base tumors with NSF ($n = 7$) and without NSF ($n = 35$)	Olfaction as measured by the UPSIT at baseline and various points postoperatively	<ol style="list-style-type: none"> Patients undergoing NSF reconstruction had deterioration of olfaction from baseline to 6 weeks, but this improved to baseline by 3 months postoperatively Patients without NSF had no difference between baseline and 6-week postoperative olfaction, and had improvement by 3 months
Derousseau et al. ²⁰⁹⁰	2015	3	Prospective cohort	<ol style="list-style-type: none"> 72 patients with SNM undergoing EEA 32 patients with IP (control) 	SNOT-20 scores over 2 years after surgery	<ol style="list-style-type: none"> In the SNM group, overall and rhinologic subdomain SNOT-20 scores did not improve over 2 years, while they did improve in the IP group Improvement in psychologic and sleep subdomains was seen at 1 and 2 years History of smoking was associated with higher overall scores

(Continues)

TABLE XXXII.2 (Continued)

Study	Year	LOE	Study design	Study groups	Clinical endpoints	Conclusion
Deckard et al. ²⁰⁸⁵	2015	3	Prospective cohort	Patients with benign (<i>n</i> = 39) and malignant (<i>n</i> = 32) sinonasal and skull base neoplasms	QOL as measured by the SNOT-20, ASBQ, and EQ-5D	<ol style="list-style-type: none"> 1. Malignant tumors were associated with worse ASBQ and SNOT-20 scores 2. T3/T4 tumor stage and postoperative CRT were associated with worse ASBQ and SNOT-20 scores 3. There was no significant difference between patients undergoing open and endoscopic resection
Harvey et al. ²¹³⁰	2015	3	Prospective cohort	118 patients with skull base tumors, including 34% with malignant tumors undergoing endoscopic resection with NSF (<i>n</i> = 42) or without NSF (<i>n</i> = 76)	SNOT-22 and NSS at baseline and at last follow-up	<ol style="list-style-type: none"> 1. There was no significant difference between patients with and without NSF on the SNOT-22 or NSS 2. Patients who received adjuvant RT had higher postoperative SNOT-22 and NSS than those who did not
Hanson et al. ²¹³¹	2015	3	Prospective cohort	36 patients undergoing endoscopic anterior skull base surgery with NSF reconstruction	SNOT-22 scores, NSS, and endoscopic evaluation at baseline and 90 days postoperatively	<ol style="list-style-type: none"> 1. SNOT-22 and NSS did not significantly change from pre- to postoperatively 2. Endoscopic evaluation revealed worsened postoperative scores compared to preoperatively for both flap- and nonflap sides, though this did not appear to affect QOL outcomes
Harrow and Batra et al. ²⁰⁸⁹	2013	3	Prospective cohort	94 patients undergoing endoscopic resection of benign (<i>n</i> = 45) and malignant (<i>n</i> = 49) sinonasal tumors	<ol style="list-style-type: none"> 1. Preop QOL 2. Postop QOL 	<ol style="list-style-type: none"> 1. In patients with SNM, there was no change in mean overall SNOT-20 score from baseline to 6 months 2. Improvement was only seen in the sleep subdomain 3. There was improvement in SNOT-20 scores from baseline to 6 months in patients not receiving adjuvant treatment, but not in those who did
Cavel et al. ²¹²⁸	2012	3	Retrospective cohort	41 patients with skull base tumors undergoing EEA	QOL as measured by the ASBQ administered within 6 months of surgery	<ol style="list-style-type: none"> 1. 75% had improvement or no change in QOL postoperatively 2. Improved scores were found in the physical symptom domain and worse scores were found in the specific symptom domain postoperatively 3. Most common symptoms were impaired smell, loss of appetite, nasal secretions, epiphora, visual disturbances, and interference with social, work, and family life 4. Female patients reported lower scores than the males in all domains

(Continues)

TABLE XXXII.2 (Continued)

Study	Year	LOE	Study design	Study groups	Clinical endpoints	Conclusion
McCoul et al. ²¹¹⁶	2012	3	Prospective cohort	85 patients undergoing endoscopic skull base surgery for a variety of pathologies	Health-related QOL as measured by the SNOT-22 and ASBQ	<ol style="list-style-type: none"> 1. SNOT-22 scores worsened initially postoperatively but improved by 1 year 2. GTR and type of grafting material predicted improved SNOT-22 scores at later follow-up 3. There was strong correlation between SNOT-22 and ASBQ scores
Pant et al. ²¹¹⁵	2010	3	Prospective cohort	51 patients undergoing endonasal skull base surgery for a variety of skull base lesions	Health-related QOL as measured by the ASBS and SNOT-22	<ol style="list-style-type: none"> 1. There was a significant improvement in SNOT-22 scores over time from 1 to 3 and >12 months after surgery 2. More than 75% of patients achieved their best postop SNOT-22 scores by 12 months 3. Patients identified loss of smell/taste, nasal obstruction, postnasal drip, waking up at night, and lack of a good night's sleep as the most important items affecting their health
Ganly et al. ²⁰⁵⁶	2005	3	Multicenter retrospective cohort	1193 patients undergoing open craniofacial resection of malignant tumors of the skull base	Postoperative mortality and complications	<ol style="list-style-type: none"> 1. There was a 5% postoperative mortality rate and a 36% postoperative complication rate including wound complications (20%), CNS complications (16%), systemic complications (5%), and orbital complications (2%) 2. Medical comorbidities, prior RT, dural invasion, and brain invasion were associated with complications
Sun et al. ²¹¹¹	2021	4	Retrospective case series	26 patients undergoing EEA of Kadish C ONB, with RT ($n = 25$) and/or chemotherapy ($n = 16$)	Preoperative and 6-month postoperative SNOT-22 scores	Mean SNOT scores for difficulty falling asleep, difficulty with nasal breathing, waking up at night, waking up tired, and frustration/restlessness/irritability improved postoperatively, whereas olfactory function worsened
Schreiber et al. ³⁷⁴	2018	4	Retrospective case series	54 patients with ITAC treated with unilateral ($n = 27$) or bilateral ($n = 27$) endoscopic resection	<ol style="list-style-type: none"> 1. Olfaction, taste, and QOL 2. Functional outcomes 	<ol style="list-style-type: none"> 1. 45% of those with unilateral surgery had preserved olfaction versus 0% with bilateral 2. There was no association between reconstruction technique or adjuvant therapy with olfaction 3. Median SNOT-22 values were equivalent in both groups
Tajudeen et al. ¹³⁶¹	2016	4	Retrospective case series	14 patients undergoing unilateral ONB resection (seven received postoperative RT)	Olfaction (UPSIT)	<ol style="list-style-type: none"> 1. Six (43%) patients had residual smell function, with two having near-normal to normal function 2. No cases had disease recurrence

(Continues)

TABLE XXXII.2 (Continued)

Study	Year	LOE	Study design	Study groups	Clinical endpoints	Conclusion
Castelnuovo et al. ¹⁶⁶⁴	2013	4	Retrospective case series	153 patients treated for skull base and SNM via EEA	ASBQ scores before, 1 month after, and 1 year after surgical treatment	<ol style="list-style-type: none"> Scores decreased from baseline to 1 month postoperatively, but increased again to baseline by 1 year Lower postoperative scores were associated with older age, extended surgical approach, and receipt of postoperative RT
Mine et al. ¹⁸⁵	2011	4	Retrospective case series	32 patients with SNM undergoing combined CFR	<ol style="list-style-type: none"> Surgical complications KPS on discharge 	<ol style="list-style-type: none"> There was a 47% surgical complication rate, most commonly local infection Other complications included frontal lobe contusion, dysphagia, speech disturbance, altered facial sensation, visual disturbance, and facial motor impairment KPS on discharge was 90 in 13 patients, 80 in 6, and 70 or less in the remainder

Abbreviations: ASBQ, Anterior Skull Base Questionnaire; EQ-5D, EuroQOL 5 Dimension questionnaire; EEA, endoscopic endonasal approach; KPS, Karnofsky Performance Scale; NSS, Nasal Symptom Score; RT, radiation therapy; SNM, sinonasal malignancy; SNOT, Sino-Nasal Outcome Test; UPSIT, University of Pennsylvania Smell Identification Test.

rience visual complications, including diplopia, enophthalmos, epiphora, dacryocystitis, and visual loss.²⁰⁸⁸ De Almeida et al. found that those undergoing endoscopic tumor resection were more than five times as likely to report postoperative nasal symptoms.²⁰⁷⁵ A literature review by the same group, however, found conflicting evidence regarding the superiority of neurologic and visual outcomes with either approach, and Deckard et al. found no difference in sinonasal or general QOL between open and endoscopic groups.^{2085,2124} Overall, the literature is limited by selection bias, with endoscopic approaches tending to encompass lower stage tumors, and low levels of evidence, as RCTs are not feasible.

Examining morbidity of the endoscopic approach in more detail, Bhenswala et al. performed a meta-analysis of postoperative SNOT-22 scores, and found that scores initially worsened within the first month after surgery by 6.23 points, but subsequently improved to above baseline by 12 weeks (3.52 points) and 52 weeks (5.96).²¹²⁵ This trajectory is confirmed by multiple other reports.^{2090,2093,2126,2127} Pant et al. found a similar timeline of symptom duration as measured by the SNOT-22, and patients identified loss of smell/taste, nasal obstruction, postnasal drip, waking up at night, and lack of a good night sleep as the most important items affecting them.²¹¹⁵ In contrast, Harrow et al. and Cavel et al. both found that patients had persistent symptoms postoperatively.^{2089,2128} Impaired

smell, appetite loss, recurrent nasal secretions, visual disturbances, and interference with work and family life were identified by patients as most bothersome.²¹²⁸ Many patients who undergo endoscopic resection of their tumors received postoperative RT and chemotherapy as well, adding to their morbidity.

Olfactory disturbance has received particular attention due to its anatomic association with surgical technique. Schreiber et al. examined a cohort of patients with ITAC and found, as expected, that unilateral surgery was associated with greater olfactory preservation.³⁷⁴ Tajudeen et al. reported similar findings with unilateral approach to ONB.¹³⁶¹ A review of olfactory outcomes after EEA by Yin et al. found that hyposmia was commonly cited as a significant patient complaint.¹⁵¹² The literature is varied on exact incidence, however, as the degree of smell loss is highly dependent on if tumors involve the olfactory groove and histology, with up to 100% anosmia seen in some studies on olfactory neuroblastoma.^{2111,2129}

The method of skull base reconstruction and NSF use has also received considerable attention in the literature. Pant et al. found better ASBQ scores in patients who did not receive NSF.²¹¹⁵ In contrast, Harvey et al. found no difference in postoperative nasal symptom score and SNOT-22 scores between the cohort with and without NSF.²¹³⁰ Similarly, Hanson et al. found no significant difference in sense of smell in patients undergoing NSF versus those

who were not.²¹³¹ Both Upadhyay et al. and Jalessi et al. found that NSF's were associated with temporary olfactory loss, but that this improved by 3–6 months.^{2132,2133}

While a detailed discussion is beyond the scope of this review, SNM frequently presents with regional lymph node metastases requiring upfront neck dissection and/or radiation to the neck. Common adverse effects of neck radiation include neck tightness, fibrosis, pharyngoesophageal stenosis, hypothyroidism, and weakness of neck muscles.²¹³⁴ Common adverse effects of neck dissection include neck and shoulder discomfort, skin numbness, lymphedema, and reduced shoulder mobility.^{2135,2136} Neck morbidity has been assessed with multiple different tools including the Disabilities of the Arm, Shoulder and Hand scale (DASH), Neck Disability Index (NDI), and Shoulder Disability Questionnaire (SDQ).^{2137–2139} Studies have found high rates of neck and shoulder disability following surgical and/or radiation treatment of the neck, and that neck and shoulder disability is linked to inferior QOL.²¹⁴⁰ Additional literature review related to morbidity following endoscopic surgical treatment of skull base pathologies is covered in ICSB 2019 (Section XI.C).⁵

Morbidity following surgical treatment

Aggregate level of evidence	C (Level 2: one study; Level 3: 12 studies; Level 4: five studies)
Benefit	Endoscopic surgical approaches are associated with decreased postoperative complications and faster recovery compared to open surgical approaches.
Harm	Surgical treatment of SNM has been found to cause long-term sinonasal symptoms and decreased sinonasal-specific QOL. Sinonasal symptoms are worst in the first month after surgery but improve with time, back to or exceeding the presurgical baseline.
Cost	Cost comparison analyses have not been undertaken.
Benefits–harm assessment	Preponderance of benefits over harms.
Value judgments	Surgical treatment of SNM is associated with long-term side effects and morbidity. While overall serious complications and morbidity are lower with the endoscopic approach, the endoscopic approach does cause increased sinonasal morbidity, which has been shown to affect sinonasal-specific and general QOL.

(Continued)

Policy level	Recommendation to attempt endoscopic surgical approach when feasible in order to preserve QOL. Recommendation to anticipate the QOL implications of surgical treatment when treating SNM.
Intervention	Endoscopic surgical resection of SNM is associated with decreased postoperative QOL, particularly in sinonasal domains. Open surgical resection is associated with higher rates of serious postoperative complications. QOL tends to improve with time after surgery and returns to baseline in many studies.

C | Morbidity following radiation treatment

NCCN guidelines dictate the use of RT in the adjuvant setting for all but the lowest risk tumors after surgery or as an alternative for definitive treatment for T3/T4a or T4b tumors, commonly integrating chemotherapy.¹⁹⁶ Older studies examined the impact of traditional external beam radiation therapy (EBRT), finding the potential for severe toxicity.^{1213,2141,2142} With the advent of IMRT, there has been better sparing of normal tissue compared to conventional two-dimensional or three-dimensional conformal RT techniques.²¹⁴³ Acute toxicities of sinonasal RT include fatigue, dermatitis, dysgeusia, xerostomia, nasal and orbital irritation, and mucositis, while late side effects typically involve ocular and neurologic toxicities, permanent dry mouth, hearing loss typically when given with cisplatin chemotherapy, and hypopituitarism.^{476,2144,2145} Patel et al. examined a cohort of 129 patients undergoing RT for SNM and found that 21% had acute grade 3 or more toxicity, most commonly dermatologic side effects or dysphagia, findings that are replicated in other similar studies.^{2145,476,550} The vast majority of studies confirm worse sinonasal QOL and symptom burden in patients receiving adjuvant RT versus no adjuvant treatment, though confounded by the fact that the addition of adjuvant RT is associated with more extensive and aggressive tumors.^{2085,2089,2093,2120,2127,2130} Severe late side effects, such as blindness and brain necrosis, are found much less commonly, and their incidence is proportional to the tissue volume receiving high-dose RT.^{490,2144,2146}

In the previously irradiated setting, the morbidities of RT can be further intensified. Bahig et al. examined longitudinal QOL via the MDASI and the ASBQ questionnaires in a cohort of SNM patients undergoing re-irradiation. They found initial decreases in QOL at the end of treatment, but most scores returned to normal by the end of the 12-month evaluation period.⁴⁴³ In line with these findings, Fan et al.

examined palliative re-irradiation in a cohort of head and neck cancer patients, including 21 patients with SNM, and found an 11% rate of grade 3 toxicities but no grade 4–5 toxicities.²¹⁴⁷

D | Morbidity following proton therapy

In contrast to photon therapy, proton beam radiation's "Bragg peak" property has the advantage of depositing the radiation without exit dose yielding a lower dose to the adjacent normal tissues.²¹⁴⁸ McDonald et al. compared proton therapy in SNM and NPC patients and found that proton therapy was associated with lower opiate pain medication requirements and lower rates of gastrostomy tube dependence than IMRT. Pasalic et al. examined a cohort of 64 patients treated with protons and found that 20% of patients experienced acute severe toxicities, most commonly dermatitis, mucositis, and pain.²⁵⁵ Russo et al. found in a similar cohort of 54 patients treated with proton therapy that 15% of patients experienced grade 3 toxicities and 11% experienced grade 4 toxicities, most commonly ocular toxicities and sinonasal fistulae, while Fan et al. examined 86 patients receiving proton therapy and found a 24% rate of acute grade 3 toxicities and a 6% rate of late grade 3 toxicities, including ORN, soft tissue fibrosis and necrosis, and vision loss.^{442,528,2149} While proton beam's main focus has been on toxicity reduction compared to photon-based RT, the application of proton for SNM may improve survival. Patel et al. performed a meta-analysis comparing charged particle versus photon therapy and found improved OS and DFS, with a caveat that noncomparative cohorts were the focus of this analysis. They found a higher rate of neurologic side effects in the charged particle group but otherwise equivalent rates of toxicity. The most common toxicities in both groups were hematologic, followed by head and neck and eye-related toxicities.⁴⁵⁸ Fan et al. also showed further improvement of local control with intensity-modulated proton therapy versus standard three-dimensional proton therapy for SNM.⁴⁴² An option for proton therapy has been added to the most recent NCCN guidelines.^{196,458}

One of the more common RT complications in the sinonasal region is the development of temporal lobe necrosis (TLN). This was examined by McDonald et al. in a cohort of 66 patients treated with proton therapy for skull base and SNM, and the authors found a 3-year TLN incidence of 12%, 6% of which was grade 2 or

higher, occurring on average 21 months after completion of therapy.²¹⁵⁰ A more recent review by Kitpanit et al. examined patients receiving proton therapy for various head and neck subsites in which the field included the skull base and found a 6% rate of TLN, 2% of which was grade 2 or higher.²¹⁵¹ Although a promising technology with robust retrospective evidence for its efficacy, there is limited prospective evidence for reduced toxicity with proton therapy in SNM. A phase two prospective study is currently enrolling (NCT01586767).²¹⁵²

E | Osteoradionecrosis

An important complication of SNM RT is the development of skull base ORN. The literature on ORN incidence in SNM is limited due to the heterogeneity of tumors, though most studies on NPC have found a 0.5%–1% incidence in patients receiving definitive RT, with the risk increased with larger tumors and prior surgery, as well as RT doses over 70 Gy.^{2153–2155} It typically presents with foul odor, headache, and recurrent epistaxis, with exam showing exposed bone, surrounding necrotic tissue, and purulent debris, and occurs with a mean latency of 3–15 years.^{2154,2156} Serious complications can occur, including CSF leak, carotid blowout, meningitis, venous sinus thrombosis, and brain abscesses.²¹⁵⁴ Medical treatment is typically attempted first, with both pentoxifylline and vitamin E commonly used.^{2154,2157} Hyperbaric oxygen (HBO) is also frequently attempted, and small case series have suggested efficacy in treating maxillary ORN, though a large multicenter study in mandibular ORN failed to show any significant benefit.^{2154,2158,2159} In addition, there is some concern that HBO may promote cancer growth and recurrence, although data are conflicting.²¹⁶⁰ Surgical excision is indicated for patients without improvement or at risk for serious complications and includes thorough debridement and reconstruction with local or free flaps.^{2154,2161} Habib et al. reported a cohort of 31 skull base ORN patients treated surgically, with 23 out of 31 treated with free flap reconstruction and the remainder with primary closure. Fourteen percent of those treated with free flaps demonstrated recurrence, in contrast with 50% of those closed primarily ($p = 0.04$).²¹⁶² Mortality has been suggested to be higher when ORN involves the sphenoid, and treatment necessitates evaluation and management of the ICA (e.g., balloon occlusion testing).²¹⁶³ Table XXXII.3 summarizes evidence surrounding QOL after RT for SNM.

TABLE XXXII.3 Evidence surrounding QOL After radiation therapy for SNM.

Study	Year	LOE	Study design	Study groups	Clinical endpoints	Conclusion
Patel et al. ⁴⁵⁸	2014	2	Systematic review and meta-analysis of observational studies	Patients with SNM treated with photon therapy ($n = 1186$) or charged particle therapy ($n = 286$)	Treatment toxicities	<ol style="list-style-type: none"> 1. Patients treated with charged particle therapy experienced more neurological toxic effects than those treated with photon therapy 2. There was no significant difference in other toxic effects
Patel et al. ⁴⁷⁶	2020	3	Retrospective cohort	129 patients treated for primary SNM	Posttreatment complications and RT toxicity	<ol style="list-style-type: none"> 1. 10% of patients had major surgical complications, including seroma, wound infection, fistula, and hemorrhage 2. Mucositis, xerostomia, taste alteration, and dermatitis were the most common low-grade RT toxicities 3. 21% had grade 3+ acute RT toxicity, including dysphagia or mucositis and dermatologic, wound, ocular, and auditory toxicity 4. After RT, 20% of patients had CRS requiring surgery
Adeberg et al. ²¹⁴⁵	2020	3	Prospective cohort	23 patients with head and neck ACC receiving cetuximab and carbon ion boost followed by IMRT	<ol style="list-style-type: none"> 1. Grade 2/3 CTCAEs 2. Grade 4/5 CTCAEs 	<ol style="list-style-type: none"> 1. No patients experienced grade 4 or 5 AEs 2. The most common grade 2 or 3 AEs were pain, weight loss, fatigue, rash, dermatitis, mucositis, dysphagia, and xerostomia
Bahig et al. ⁴⁴³	2020	3	Prospective cohort	39 patients receiving re-RT for a recurrent or new skull base tumor	Score on the MDASI and ASBQ pretreatment and at various points posttreatment	<ol style="list-style-type: none"> 1. Patients showed worse fatigue, lack of appetite, and drowsiness on the MDASI and physical function on the ASBQ at the end of treatment versus baseline, but these returned to baseline at subsequent follow-up 2. There was no difference in scores for patients treated with fractionated RT and stereotactic RT
Fan et al. ²¹⁴⁷	2020	3	Retrospective cohort	166 patients with recurrent head and neck cancer and previous RT treated with palliative quad-shot RT	Treatment toxicities	<ol style="list-style-type: none"> 1. The most common grade 1–2 toxicities were dermatitis and xerostomia 2. 10% of patients experienced grade 3 acute toxicities, most commonly dysphagia, and 2% experienced grade 3 late toxicities 3. There were no grade 4 or 5 toxicities

(Continues)

TABLE XXXII.3 (Continued)

Study	Year	LOE	Study design	Study groups	Clinical endpoints	Conclusion
Kitpanit et al. ²¹⁵¹	2020	3	Retrospective cohort	234 patients with head and neck cancer receiving proton therapy to the skull base	Temporal lobe RT necrosis	<ol style="list-style-type: none"> 1. Temporal lobe RT necrosis occurred in 6% of patients and was grade 3+ in 1% of patients 2. Risk of temporal lobe RT necrosis was correlated with the volume of temporal lobe receiving high doses of RT
Habib et al. ²¹⁶²	2020	3	Retrospective cohort	31 patients with skull base ORN following skull base surgery and RT	<ol style="list-style-type: none"> 1. Treatment modality 2. Treatment outcomes 3. Predictors of recurrence 	<ol style="list-style-type: none"> 1. All patients were treated surgically, and 38% were also treated medically (with HBO, antibiotics, and/or dressing changes) prior to surgery 2. 23 patients were treated with free flaps and eight with primary closure 3. Recurrence was seen in 14% of patients treated with a free flap versus 50% with primary closure 4. Ongoing cancer treatment ($p = 0.02$) was associated with increased recurrence risk
Han et al. ²¹⁵³	2018	3	Retrospective cohort	1348 patients with NPC treated with external beam RT	Skull base ORN	<ol style="list-style-type: none"> 1. Skull base ORN occurred in 1% of patients at a mean latency of 46 months 2. T stage, total RT dose to the nasopharynx, skull base inclusion in the RT field, and anemia were associated with increased ORN odds
McDonald et al. ²¹⁴⁹	2016	3	Retrospective cohort	Patients with sinonasal, nasal cavity, or nasopharyngeal cancer receiving proton RT ($n = 14$) or IMRT ($n = 26$)	Opiate pain medication requirement and gastrostomy tube dependence	Patients receiving proton therapy had lower opiate requirement and lower gastrostomy tube dependence compared to those receiving IMRT
Jensen et al. ⁵⁵⁰	2015	3	Prospective cohort	53 patients (34% paranasal sinus) with malignant salivary gland tumors of the head and neck treated with IMRT and dose-escalated carbon ion therapy	AEs	<ol style="list-style-type: none"> 1. Acutely, 26% of patients experienced grade 3 mucositis, 38% of patients experienced AEs of the ear, and 89% of patients reported loss of taste 2. The most common late AEs were grade 1 xerostomia, hearing impairment, and ocular toxicity
McDonald et al. ²¹⁵⁰	2015	3	Retrospective cohort	66 patients treated with proton therapy for skull base chordoma, chondrosarcoma, ACC, or SNM	Temporal lobe RT necrosis	<ol style="list-style-type: none"> 1. The 3-year incidence of RT necrosis was 12.4%, and 5.7% for grade 2 or higher 2. Median time to development was 21 months 3. A higher volume of temporal lobe receiving >60 Gy RT was associated with increased odds of developing temporal lobe RT necrosis

(Continues)

TABLE XXXII.3 (Continued)

Study	Year	LOE	Study design	Study groups	Clinical endpoints	Conclusion
Koto et al. ²¹⁴⁶	2014	3	Prospective cohort	39 patients with skull base tumors treated with carbon ion RT	RIBI as assessed by MRI and clinical symptoms of brain injury	<ol style="list-style-type: none"> 1. The 5-year likelihood of grade 2+ RIBI and grade 2+ clinical symptoms were 25% and 7%, respectively 2. Brain volume receiving >50 Gy was a risk factor for development of grade 2+ RIBI 3. RIBI most frequently developed in the ipsilateral temporal lobe
Fan et al. ⁴⁴²	2021	4	Retrospective case series	86 patients with paranasal sinus tumors receiving intensity-modulated proton therapy	Treatment toxicities	<ol style="list-style-type: none"> 1. 21% of patients experienced acute grade 3 toxicities, most commonly mucositis and dermatitis 2. 6% of patients experienced late grade 3 toxicities, most commonly vision loss 3. 49% of patients experienced late grade 1–2 toxicities, most commonly epiphora and brain necrosis
Daoudi et al. ²¹⁶³	2020	4	Retrospective case series	Seven patients with sphenoid ORN treated with medical management, endovascular treatment, and/or surgery	<ol style="list-style-type: none"> 1. Management of sphenoid ORN 2. Survival rate at follow-up 	<ol style="list-style-type: none"> 1. Four patients underwent ICA occlusion due to active bleeding or at-risk ICA 2. Five patients underwent endoscopic endonasal debridement with temporoparietal fascial flap coverage of exposed bone 3. One patient received pentoxifylline, tocopherol, and clodronate 4. Survival at a mean of 24 months was 57%
Pasalic et al. ⁵²²	2020	4	Retrospective case series	64 patients with SNM treated with proton beam therapy	PROMs and toxicity as measured by the CTCAE, XeQoLS, MDASI, and FACT scales	<ol style="list-style-type: none"> 1. The most common grade 3+ acute AEs were dermatitis, mucositis, pain, and dysphagia 2. From baseline, the following PROMs worsened: acute–subacute XeQoLS physical functioning, pain, personal/psychological distress, and social functioning; acute–subacute MDADI physical function; and acute–subacute FACT-HN subscale 3. No PROMs were worse in the chronic period (>90 days) compared to baseline.

(Continues)

TABLE XXXII.3 (Continued)

Study	Year	LOE	Study design	Study groups	Clinical endpoints	Conclusion
Huang et al. ²¹⁶¹	2018	4	Retrospective case series	162 patients with skull base ORN	<ol style="list-style-type: none"> 1. Treatment indications 2. Treatment modality 3. Treatment efficacy 	<ol style="list-style-type: none"> 1. 36% of patients required surgery due to complications 2. Most common treatment indications were blowout bleeding, CNS infection, pain, or recurrent bloody discharge 3. The majority of patients received free vastus lateralis flap reconstruction. 4. Surgery was effective in managing complications in all patients
Russo et al. ⁵²⁸	2016	4	Retrospective case series	54 patients with stage 3/4 sinonasal SCC undergoing proton beam RT with or without prior surgical resection	Treatment toxicities	There were 14 grade 3+ toxicities, including ocular toxicity, sinonasal cutaneous fistula, facial cellulitis, flap dehiscence requiring revision, and trismus
Gavriel et al. ²¹⁵⁸	2016	4	Retrospective case series	21 patients receiving treatment with HBO for maxillary bone ORN that occurred after photon RT for tumor	<ol style="list-style-type: none"> 1. Response to treatment 2. Further management required 	<ol style="list-style-type: none"> 1. Patients received a mean number of 26 HBO sessions 2. Four patients developed HBO complications (three with otologic signs requiring myringotomy tubes) 3. 85% of patients had clinical improvement after HBO, seen as healing tissue over bone 4. Five patients required surgical reconstruction during 2-year follow-up
Huang et al. ²¹⁵⁶	2006	4	Retrospective case series	15 patients with skull base ORN after RT for NPC	<ol style="list-style-type: none"> 1. Symptoms 2. Exam and imaging findings 3. Treatment options 	<ol style="list-style-type: none"> 1. Frequent symptoms included foul odor, headache, and epistaxis 2. CT characteristically showed extensive bone destruction 3. Nine patients received surgery and six patients received conservative treatment, including nasal rinsing, antibiotics, and HBO

Abbreviations: ACC, adenoid cystic carcinoma; AE, adverse events; ASBQ, Anterior Skull Base Questionnaire; CTCAE, Common Terminology Criteria for Adverse Events; FACT-HN, Functional Assessment of Cancer Therapy: Head and Neck; HBO, hyperbaric oxygen; MDASI, MD Anderson Symptom Inventory; ORN, osteoradionecrosis; RIBI, radiation-induced brain injury; RT, radiation therapy; SCC, squamous cell carcinoma; SNM, sinonasal malignancy; XeQoLS, Xerostomia QOL Scale.

Morbidity following radiation treatment including osteoradionecrosis

Aggregate level of evidence	C (Level 2: one study; Level 3: 12 studies; Level 4: six studies)
Benefit	RT is associated with improved disease control for most pathologies and stages of SNM. Proton beam may reduce RT morbidity, but data are mixed.
Harm	SNM RT is associated with both early and late toxicities, including mucositis, dermatitis, nasal morbidity, xerostomia, and dysphagia. Severe side effects, such as blindness and brain necrosis, are proportional to the volume and dose of RT, and the morbidity of RT is intensified in the re-irradiation setting. Skull base ORN is rare and management is primarily surgical.
Cost	Cost comparison analyses have not been undertaken.
Benefits-harm assessment	Preponderance of benefits over harms.
Value judgments	Treatment of SNM with RT is frequently indicated for improved disease control; however, it does cause both short- and long-term morbidities. Proton beam RT may be considered to reduce side effects. For ORN, medical management may be attempted but management is typically surgical.
Policy level	Recommendation.
Intervention	RT is associated with improved local control and survival for many tumors but leads to impaired QOL, principally affecting sinonasal symptoms. Acute symptoms are common, as are long-term toxicities. Proton therapy can be considered for a reduction in morbidity. Skull base ORN can be managed medically or surgically, with growing evidence suggesting safety and efficacy.

F | Morbidity following chemotherapy

For SNM, chemotherapy is usually given as either induction or concurrently with radiation in the definitive or adjuvant setting. Depending on pathology, IC is typically with docetaxel/cisplatin/5-fluorouracil (5FU) (TPF), cisplatin or carboplatin/etoposide, or cyclophosphamide/doxorubicin/vincristine. Most chemotherapy trials include patients from all head and neck subsites, not just SNM. In a trial comparing TPF to cisplatin/5FU alone in the induction setting for unresectable head and neck cancer, the most frequent severe AEs were

neutropenia, leukopenia, thrombocytopenia, anemia, alopecia, stomatitis, infections, nausea, vomiting, anorexia, diarrhea, and hearing loss, consistent with the literature.^{2164–2166} For platin/etoposide regimens, the most frequent severe AEs reported are secondary to myelosuppression, with severe neutropenia seen in many patients.^{2167,2168} Multiple trials have examined cyclophosphamide/doxorubicin/vincristine, and the most common severe AEs are myelosuppression, infection, alopecia, and neuropathy.^{1832,2169,2170} A meta-analysis by Kim et al. comparing patients receiving IC with TPF plus CRT versus those receiving CRT alone found higher rates of myelosuppression in the IC cohort, with no difference in the rates of nonhematologic toxicities.²¹⁷¹ These authors also found a higher risk of not completing CRT in the IC cohort, a finding that is replicated in other studies.²¹⁷²

CRT is frequently used in SNM, with a variety of regimens used depending on tumor histology. Overall, cisplatin is best studied and most widely applied. Typical adverse effects of CRT are due to both the AEs from the chemotherapeutic agents themselves as well as in-field RT effects, and include hematologic side effects, mucositis, stomatitis, and dermatitis.^{2173,2174} Ye et al. retrospectively analyzed a multi-institutional cohort of 349 patients with head and neck cancer of all subsites treated with CRT with cisplatin or cetuximab and found grade 3/4 toxicities in 58% and 45% in each group, respectively, most commonly oral mucositis and radiation dermatitis, as well as a 34% and 20% rate of unplanned hospital admissions, respectively, consistent with other similar studies.^{2175,2176} In an RCT by Bonner et al. comparing CRT with cetuximab versus RT alone, the authors found no exacerbation of RT-related AEs, including xerostomia, pain, and mucositis, with the addition of cetuximab.²¹⁷⁷

Intra-arterial chemotherapy for SNM is performed with the goal of maximizing chemotherapy dose to the tumor while minimizing systemic toxicity. An RCT by Rasch et al. compared intra-arterial to IV cisplatin concurrent with chemoradiation for stage IV head and neck cancer of multiple subsites. They found lower rates of grade 3 or more renal toxicity and a higher rate of grade 3 or more neurologic toxicity in the intra-arterial group versus the IV group, but no other significant difference in toxicities.²¹⁷⁸ Long-term follow-up from this trial after a median of 7.5 years showed higher rates of dysphagia and esophageal toxicity in the intravenous group, but no difference in xerostomia, mucositis, or nephrotoxicity.²¹⁷⁹ A cohort study by Homma et al. examining specifically SNM patients similarly found moderate rates of toxicity with intra-arterial chemotherapy concurrent with RT, with the most common acute toxicities including mucositis and nausea/vomiting, and most common late toxicities including osteonecrosis, brain necrosis, and ocular/visual

problems.⁴⁵⁴ Intra-arterial treatment is technically more difficult to apply, limited to specific centers, and in the absence of a clear advantage in disease control and survival, IV treatment is far more commonly used.

G | Morbidity following immunotherapy

Nivolumab and pembrolizumab are the principal immunotherapy agents used in SNM. Both drugs block the PD-1 receptor on lymphocytes, preventing PD-L1 and PD-L2 binding and therefore upregulating T-cell-mediated killing of cancer cells.²¹⁸⁰ Common AEs include fatigue, nausea, rash, pruritus, and depressed appetite.^{2181–2186} Immune-related AEs (irAEs) are of particular concern and have been found to occur in 27% of patients, with high-grade irAEs in 6%.²¹⁸¹ Serious AEs may include pneumonitis, adrenal insufficiency, hypothyroidism, colitis, acute liver injury, and Stevens–Johnson syndrome.^{2183–2185,2187,2188} Fatal AEs have been found to occur in 0.4% of patients treated with PD-1 and PD-L1 inhibitors, commonly pneumonitis, hepatitis, colitis, neurologic events, and myocarditis.²¹⁸¹ Overall, however, the side effects of immunotherapy on average are less than those seen with single-agent chemotherapy agents based on RCT data.^{2182,2189} Table XXXII.4 summarizes evidence surrounding QOL after chemotherapy and immunotherapy for SNM.

Morbidity following chemotherapy and immunotherapy

Aggregate level of evidence	B (Level 1: two studies; Level 2: nine studies. Level 3: eight studies)
Benefit	Chemotherapy, either in the induction or adjuvant setting, is indicated for many SNMs to improve disease control. Immunotherapy and intra-arterial chemotherapy both attempt to reduce toxicity while improving disease control.
Harm	AEs from systemic chemotherapy are very common, with almost all patients having at least low-grade AEs and more severe AEs occurring in approximately half of patients, depending on the study and agent. Intra-arterial chemotherapy spares some systemic toxicity but may increase local toxicity. Immunotherapy has less side effects than conventional chemotherapy and can have both immune-related side effects and nonimmune-related side effects.
Cost	Cost comparison analyses have not been undertaken.
Benefits–harm assessment	Preponderance of benefits over harms.

(Continued)

Value judgments	Chemotherapy may improve survival in many SNM but is associated with adverse side effects that impact QOL. Specific side effects vary by agent.
Policy level	Recommendation.
Intervention	Chemotherapy in the induction or adjuvant setting is associated with decreased QOL, with specific AEs varying by specific agent. While many of the AEs are short term, long-term toxicities that impact QOL are common. It is important to weigh the effects of chemotherapy on QOL against the potential benefits for disease control.

In conclusion, various treatment modalities carry different side effect profiles, and long-term QOL is an important consideration in treatment planning for this group of patients. With the increasing awareness of the importance of long-term QOL for SNM patients, shared decision-making must focus not only on oncologic outcomes but also the factors that matter most to patients.

XXXIII | SURVEILLANCE

A | Timing and schedule

Despite the extensive literature published on the timing and schedule for the surveillance of head and neck malignancy, there is a paucity of evidence to support a universal schedule for surveillance of SNM and benign disease. The most recent guidelines set forth by the NCCN suggest careful and regular follow-up for head and neck malignancies with the option to use FDG-PET/CT for surveillance a minimum of 12 weeks following definitive treatment or contrast-enhanced CT or MRI between 8 and 10 weeks posttreatment.²⁵⁸ Evaluation with FDG-PET/CT prior to 12 weeks increases the rate of false-positive results due to residual inflammation from RT and/or surgical resection.²¹⁹² In addition to imaging, routine clinical examination is recommended every 1–3 months for the first year, then every 2–6 months for the second year, followed by every 4–8 months for years 3 through 5, and then annual exams after year 5. Currently, the accepted standard is to extrapolate these recommendations to encompass sinonasal tumors; however, these tumors generally behave differently. Given this, the presented discussion and recommendations largely reflect SNM, though some special consideration is given to IP, where there have been focused studies on this topic.

While these principles have generally been adopted for all head and neck malignancies, disease of the sinonasal subsite encompasses a wider breadth of pathology than classically seen in other aerodigestive tract sub-

TABLE XXXII.4 Evidence surrounding QOL after chemotherapy and immunotherapy for SNM.

Study	Year	LOE	Study design	Study groups	Clinical endpoints	Conclusion
Kim et al. ²¹⁷¹	2016	1	Meta-analysis of RCTs	Patients with locally advanced head and neck cancer treated with IC with TPF plus CRT (<i>n</i> = 651) or CRT alone (<i>n</i> = 629)	<ol style="list-style-type: none"> 1. Treatment toxicities 2. Treatment compliance 	<ol style="list-style-type: none"> 1. Patients undergoing IC plus CRT had higher rates of grade 3/4 neutropenia, anemia, and thrombocytopenia 2. There was no difference in the rates of nonhematologic toxicities 3. Patients undergoing IC were less likely to complete CRT
Abdel-Rahman and Fouad ²¹⁸⁸	2016	1	Meta-analysis of RCTs	6671 patients receiving immune checkpoint inhibitors versus standard chemotherapy, placebo, or everolimus	Development of pneumonitis	There was a 3.96 odds ratio of all-grade pneumonitis and a 2.87 odds ratio for high-grade pneumonitis following treatment with immune checkpoint inhibitors
Cohen et al. ²¹⁸⁹	2019	2	RCT	Patients with recurrent, progressive, or metastatic head and neck SCC failing platinum therapy, then receiving pembrolizumab (<i>n</i> = 247) versus standard methotrexate, docetaxel, or cetuximab (<i>n</i> = 248)	Incidence of AEs	<ol style="list-style-type: none"> 1. There was a lower incidence of grade 3+ AEs in the pembrolizumab group than the standard therapy group 2. The most common AE in the pembrolizumab group was hypothyroidism and in the standard group was fatigue 3. Four patients in the pembrolizumab group suffered treatment-related death versus two patients in the standard of care group
Ghi et al. ²¹⁶⁵	2017	2	RCT	421 patients with locally advanced head and neck cancer receiving CRT (<i>n</i> = 208) versus IC TPF followed by CRT (<i>n</i> = 206)	<ol style="list-style-type: none"> 1. Treatment toxicities 2. Treatment compliance 	<ol style="list-style-type: none"> 1. The most common grade 3+ toxicity during IC was neutropenia 2. During CRT, there was significantly higher rates of neutropenia in the IC group, and higher rates of skin rash (likely due to cetuximab) in the CRT group 3. Receipt of IC did not affect compliance to CRT
Heukelom et al. ²¹⁷⁹	2016	2	RCT	237 patients with inoperable head and neck cancer treated with IA cisplatin plus RT (<i>n</i> = 118) versus IV cisplatin plus RT (<i>n</i> = 119)	Severe late treatment toxicities	<ol style="list-style-type: none"> 1. 38% of patients experienced grade 3+ toxicity 2. Late esophageal toxicity was more frequent in the IV group 3. There were no other differences in toxicity rates between the IV and IA groups

(Continues)

TABLE XXXII.4 (Continued)

Study	Year	LOE	Study design	Study groups	Clinical endpoints	Conclusion
Ferris et al. ²¹⁸²	2016	2	RCT	361 patients with recurrent head and neck cancer failing platinum chemotherapy receiving either nivolumab (<i>n</i> = 236) versus standard systemic chemotherapy (methotrexate, docetaxel, or cetuximab; <i>n</i> = 111)	<ol style="list-style-type: none"> 1. Treatment related AEs 2. QOL as assessed by the QLQ-C30 and QLQ-H&N35 	<ol style="list-style-type: none"> 1. There was a 13% rate of grade 3/4 AEs in the nivolumab group, most commonly fatigue, versus a 35% rate in the standard group, most commonly neutropenia 2. During therapy, QOL was stable in the nivolumab group but worse in the standard group 3. The most frequent AEs in the nivolumab group were fatigue, nausea, rash, decreased appetite, and pruritis 4. Two treatment-related deaths occurred in the nivolumab group (pneumonitis and hypercalcemia)
Chow et al. ²¹⁸⁵	2016	2	RCT	132 patients with recurrent/metastatic head and neck SCC receiving pembrolizumab	Treatment-related AEs	<ol style="list-style-type: none"> 1. AEs occurred in 62%, most commonly fatigue, hypothyroidism, and decreased appetite 2. Grade 3+ AEs occurred in 9%, most commonly decreased appetite, facial swelling, and pneumonitis
Paccagnella et al. ²¹⁶⁶	2010	2	RCT	101 patients with stage 3–4 head and neck cancer receiving CRT (<i>n</i> = 50) versus IC with TPF followed by CRT (<i>n</i> = 51)	Treatment toxicities	<ol style="list-style-type: none"> 1. The most common grade 3+ toxicity during IC was neutropenia, followed by alopecia 2. There was no difference in toxicities during CRT between the IC and no-IC cohorts
Rasch et al. ²¹⁷⁸	2010	2	RCT	237 patients with inoperable head and neck cancer treated with IA cisplatin plus RT (<i>n</i> = 118) versus IV cisplatin plus RT (<i>n</i> = 119)	Treatment toxicities	<ol style="list-style-type: none"> 1. The IV group had higher rates of renal toxicity 2. The IA group had higher rates of neurological toxicities 3. There was no difference between the groups in the rates of hematologic toxicities or other toxicities
Vermorken et al. ²¹⁹⁰	2007	2	RCT	Patients with locally advanced head and neck cancer treated with either IC with TPF (<i>n</i> = 177) versus IC with PF (<i>n</i> = 181)	Toxicity of treatment	<ol style="list-style-type: none"> 1. Patients receiving TPF had higher rates of grade 3+ alopecia, leukopenia, and neutropenia 2. Patients receiving PF had higher rates of grade 3+ thrombocytopenia, nausea, vomiting, stomatitis, and hearing loss 3. There was a 2.3% death rate in the TPF group and 5.5% rate in the PF group

(Continues)

TABLE XXXII.4 (Continued)

Study	Year	LOE	Study design	Study groups	Clinical endpoints	Conclusion
Bonner et al. ²¹⁷⁷	2006	2	RCT	424 patients with locally advanced head and neck cancer treated with RT alone ($n = 213$) versus CRT with cetuximab ($n = 211$)	Treatment toxicities	<ol style="list-style-type: none"> 1. There were higher rates of grade 3+ acneiform-rash in the CRT group 2. There was no difference in rates of other grade 3+ toxicities
Bernadach et al. ²¹⁷²	2021	3	Retrospective cohort	113 patients treated with IC with TPF	Treatment toxicities	<ol style="list-style-type: none"> 1. The most common grade 3+ toxicities were neutropenia, nausea/vomiting, mucositis, diarrhea, anemia, and thrombocytopenia 2. Grade 5 febrile neutropenia occurred in 6% of patients
Tsan et al. ²¹⁷⁴	2021	3	Prospective cohort	54 adults with head and neck cancer treated with CRT	QOL, symptoms, and hope as measured by the FACT-HN, MDASI, and HHI, pre-, during, and posttreatment	<ol style="list-style-type: none"> 1. QOL declined during treatment but rose back to baseline by 1 month after treatment and superior to baseline at 3 months 2. Symptom interference decreased over time after treatment 3. Symptom burden initially increased during treatment but declined back to pretreatment levels at 1 and 3 months posttreatment 4. "Hope" remained steady throughout the study
Mehra et al. ²¹⁸⁷	2018	3	Prospective cohort	192 patients receiving pembrolizumab for recurrent, metastatic, or persistent HNSCC	Treatment-related AEs	<ol style="list-style-type: none"> 1. At a median of 9 months after treatment, 64% of patients experienced AEs, most frequently fatigue, rash, pruritis, and appetite decrease, and 13% of patients experienced grade 3/4 AEs, most commonly ALT and AST elevations 2. The most common immune-related AEs were hypothyroidism (28 patients, two of which were grade 3) and pneumonitis (five patients, two grade 3)
Seiwert et al. ²¹⁸³	2016	3	Prospective cohort	60 patients with PD-L1-positive head and neck cancer treated with pembrolizumab	Drug-related AEs	<ol style="list-style-type: none"> 1. 63% of patients had AEs of any grade, most commonly fatigue, pruritis, nausea, decreased appetite, and rash 2. 17% of patients had grade 3/4 AEs, most commonly elevated AST or ALT, or hyponatremia

(Continues)

TABLE XXXII.4 (Continued)

Study	Year	LOE	Study design	Study groups	Clinical endpoints	Conclusion
Ye et al. ²¹⁷⁵	2013	3	Prospective cohort	349 adults with locally advanced head and neck cancer treated with CRT with cisplatin (<i>n</i> = 262) versus cetuximab (<i>n</i> = 87)	Treatment toxicities	<ol style="list-style-type: none"> 1. There was equivalent grade 3+ mucositis, enteral feeding, and weight loss in both groups 2. Higher rates of nausea/emesis and unplanned or prolonged hospitalization were seen in the cisplatin group 3. Higher rates of RT dermatitis and acneiform rash were seen in the cetuximab group 4. Two patients in each group died of treatment-related complications
Nishimura et al. ²¹⁷³	2009	3	Retrospective cohort	Patients with untreated stage 3/4 maxillary sinus SCC treated with IC with 5FU, methotrexate, and leucovorin with IA cisplatin (<i>n</i> = 16) versus CRT with 5FU, methotrexate, and leucovorin with IA cisplatin (<i>n</i> = 15) versus RT only (<i>n</i> = 9)	Treatment toxicities	<ol style="list-style-type: none"> 1. In the IC cohort, the most common grade 3/4 toxicities were nausea/vomiting, anemia, and neutropenia 2. In the CRT cohort, the most common grade 3/4 toxicities were nausea/vomiting, dermatitis, dysphagia, mucositis, and pain 3. In the RT only cohort, the most common grade 3/4 toxicity was dermatitis
Homma et al. ²¹⁹¹	2009	3	Prospective cohort	47 patients with T3+ nasal and SNM treated with IA cisplatin and EBRT	Treatment toxicities	<ol style="list-style-type: none"> 1. 75% of patients experienced acute grade 3/4 toxicity, most commonly leukopenia, mucositis, and fevers 2. Late AEs included ORN, brain necrosis, and ocular/visual problems
Vermorken et al. ²¹⁶⁴	2007	3	Prospective cohort	103 patients with recurrent and/or metastatic head and neck cancer that failed platinum-based therapy and then received cetuximab, with or without platinum	<ol style="list-style-type: none"> 1. Treatment-related AEs 2. KPS 	<ol style="list-style-type: none"> 1. Six patients had cetuximab infusion reactions, and one patient died of an infusion reaction to cetuximab 2. Median pretreatment KPS was 80 and declined during treatment 3. 46% of patients receiving single-agent cetuximab had grade 3/4 AEs, most commonly dyspnea, vomiting, and asthenia 4. No skin reactions were grade 3 or higher

Abbreviations: AE, adverse events; CRT, chemoradiation therapy; 5FU, 5-fluorouracil; HNSCC, head and neck squamous cell carcinoma; IA, intra-arterial; IC, induction chemotherapy; PF, cisplatin and 5-fluorouracil; QLQ-C30, EORTC Core QOL Questionnaire; QLQ-H&N35, EORTC QOL Questionnaire: Head and Neck Module; FACT-HN, Functional Assessment of Cancer Therapy: Head and Neck; HHI, Herth Hope Index; KPS, Karnofsky Performance Scale; MDASI, MD Anderson Symptom Inventory; ORN, osteoradionecrosis; RT, radiation therapy; TPF, docetaxel, cisplatin, and 5-fluorouracil.

sites and many tend to behave differently. Many of these pathologies tend to recur locally as opposed to regionally, though this is highly dependent on tumor biology and local recurrence of benign disease, notably IP, is also possible. Furthermore, sinonasal inflammation can persist long after treatment, leading to increased FDG avidity and altering the accuracy of FDG-PET/CT.²¹⁹³ Given the variability in pathology and the differences in biology of the sinonasal mucosa, the general principles applied to head and neck malignancies should not be universally applied. Ideally, the posttreatment examination and surveillance practice should be tailored to the specific tumor.

There are no studies evaluating the ideal timing for clinical follow-up in patients with sinonasal tumors; however, many authors report their follow-up protocols.^{216,369,373,402,418,419,431,1153,1161,2194,2195} Despite being institutionally dependent, there are a few themes that may be highlighted. Regardless of tumor biology, most authors utilize clinical examination with nasal endoscopy every 1–6 (median 3) months in the first year with varying de-escalation of intervals in the subsequent years. Depending on the tumor type, posttreatment imaging is performed between 2 and 12 months following completion of therapy with FDG-PET/CT being used for SNM and CT or MRI being used for benign disease.

In order to develop recommendations on timing, it is important to consider tumor biology and recurrence patterns. Of the 35 included studies, 22 studies reported RFS and time to recurrence. For all tumors, the mean time to recurrence ranged from 8 to 138.1 months, with the majority of the recurrences occurring within the first 5 years.^{216,369,373,402,418,419,431,701,720,721,741,1086,1135,1153,1161,1166,1397,1417,1931,2194–2201} Notably this group consists of benign and malignant tumors, including ACC and ONB, known for late recurrence. Notably, ACC and ONB pose risks for recurrence as up to 10 years following primary treatment and this should be taken into consideration when developing a surveillance protocol.^{419,430,1417} Furthermore, for benign neoplasms (e.g., IP), the mean time to recurrence ranges from 8.0 to 45.5 months with a maximum of 253.2 months, suggesting that longer follow-up is necessary.^{5,15,17,19–21,24,25,27,29,2202} While there are no studies investigating specific surveillance intervals and protocols, it is conceivable that follow-up duration should be at least 5 years, with certain disease etiologies (e.g., IP, ACC, ONB) requiring longer or even lifelong follow-up.

B | Role of assessment based on physical exam, signs, and symptoms

Due to the anatomy of the paranasal sinuses, tumors of this region are often asymptomatic given the large poten-

tial space, especially in a postoperative setting. Recurrent tumors have an opportunity to grow larger due to lack of defined tissue planes to prevent growth, resulting in advanced stage by the time symptoms are apparent. This is in contrast to the majority of head and neck malignancies, where new symptoms are an early indicator of recurrence and recommendations for long-term imaging are based on physical exam findings and symptoms.^{1,31,32} Three studies assessed the impact of patient symptoms on the diagnosis of recurrence (Table XXXIII.1).^{7,11,12} Workman et al. assessed factors associated with recurrence in patients with recurrent SNM and determined that up to 49% of patients had symptoms at the time of recurrence diagnosis.¹¹ Furthermore, the majority of symptomatic recurrences were seen in stage IVB tumors and predicted worse survival, suggesting that development of symptoms is a late presentation in SNM recurrence. Zocchi et al. assessed risk factors associated with recurrence of SNM and reported that recurrence was diagnosed based on symptoms in only 6.3% of cases.¹² Of these cases, 25% were due to presence of distant metastases. Despite this, there was no significant difference in timing of diagnosis and OS between patients diagnosed symptomatically compared to endoscopically or via advanced imaging. Conversely, Nyquist et al. demonstrated that, of 67 patients with recurrent SNM, 19 (28.4%) patients were symptomatic, which ultimately led to a diagnosis of recurrence in conjunction with further workup.⁷ Diagnosis was ultimately made by endoscopy in 10 patients, physical exam in two patients, and imaging in seven patients.

Given the unrestricted paths for tumor growth in the paranasal sinuses, tumors generally have room for expansion before symptoms become apparent, making diagnosis based on difficult. Symptoms are also generally nonspecific and may be limited only to epistaxis or nasal obstruction.³³ Furthermore, without the use of nasal endoscopy, physical exam is limited and generally only useful for detection of regional metastases. Despite the low yield in diagnosis, a comprehensive physical examination should be performed at each clinical visit following treatment. Despite this, Khalili et al. demonstrated that the presence of patient symptoms (e.g., intractable facial pain, recurrence epistaxis, severe headache, neck masses, cranial neuropathies) increases the PPV of both nasal endoscopy and imaging for detection of recurrence.¹⁴ Additionally, in a cohort of SNM patients, Nyquist et al. demonstrated that physical exam detected recurrence in only 3.0% of cases; however, all of these patients were symptomatic.⁷

TABLE XXXIII.1 Evidence surrounding the use of physical exam and symptoms in the surveillance of sinonasal tumors.

Study	Year	LOE	Study design	Study groups	Clinical endpoints	Conclusions
Nyquist et al. ²¹⁹⁵	2021	3	Retrospective cohort	231 patients treated for SNM	1. DFS 2. Recurrence rate	Recurrence was detected on physical examination in 2.0% of cases
Zocchi et al. ⁴¹⁹	2020	3	Retrospective cohort	417 patients treated for SNM.	Recurrence rates	Only 6.3% of recurrences were detected by symptoms
Workman et al. ⁴²¹	2019	3	Retrospective cohort	55 patients with history of definitive treatment of SNM with recurrence	1. DFS 2. OS 3. Recurrence rate	Rates of symptomatology are lower in recurrent SNM than in other recurrent cancers of the head and neck

Abbreviations: DFS, disease-free survival; OS, overall survival; SNM, sinonasal malignancy.

Role of surveillance based on physical exam, signs, and symptoms

Aggregate grade of evidence	C (Level 3: three studies)
Benefit	Early detection of recurrent tumors with possibility of timely intervention.
Harm	Missing a diagnosis of a recurrent or persistent tumor given relatively low rates of detection.
Cost	Direct costs: consultation fees and travel costs.
Benefits-harm assessment	Preponderance of benefits over harms.
Value judgments	Physical examination of the paranasal sinuses is difficult given the anatomic location. Exam findings should focus on cranial neuropathies, ocular findings, and new-onset lymphadenopathy.
Policy level	Recommendation.
Intervention	Symptoms and physical exam findings often present in advanced disease. A complete history and physical examination should be performed at each posttreatment examination. Screening of symptoms should include presence of new onset epistaxis, intractable facial pain, and cranial neuropathies.

C | Role of endoscopy

Postoperative nasal endoscopy is generally regarded as the standard of care for surveillance, especially following surgical resection. Given that the most common site of failure in SNM is local and that external visualization of the sinonasal tract is difficult, direct visualization of the primary site using nasal endoscopy is important.³⁴ Despite this hypothetical advantage, only three studies assessed the impact of nasal endoscopy for sinonasal

tumor surveillance (Table XXXIII.2). The rates of diagnosis of primary recurrence using nasal endoscopy ranged from 20.8% to 34.3%.^{7,12,14} Khalili et al. demonstrated that nasal endoscopy had a sensitivity and specificity of 25% and 89%, respectively, and a PPV of 13% in asymptomatic patients. In patients with symptoms, the PPV of nasal endoscopy increased to 85%.¹⁴ Nyquist et al. demonstrated that, in the setting of local recurrences, half would be diagnosed via nasal endoscopy and that nasal endoscopy diagnoses more primary recurrences when surgical resection has been performed.⁷ Furthermore, in patients with recurrent disease, nasal endoscopy tends to identify smaller, more superficial recurrences that may be more amenable to salvage surgery, while imaging tends to identify larger sized recurrences.¹⁴

Role of endoscopy for surveillance

Aggregate grade of evidence	C (Level 3: two studies; level 4: one study).
Benefit	Detection of a primary tumor recurrence, assess extent of involvement, and evaluation for feasibility of resection.
Harm	Risk of local tissue trauma and potential to miss recurrence deep to mucosa.
Cost	Direct costs: procedure fees and consultation fees.
Benefits-harm assessment	Preponderance of benefits over harms.
Value judgments	Direct visualization of the paranasal sinuses with rigid or flexible endoscopes should be performed, especially for postsurgical patients.
Policy level	Recommendation.
Intervention	Nasal endoscopy should be performed at each surveillance visit to assess for local tumor recurrence within the sinonasal tract, as well as assess mucosal health and side effects (e.g., crusting).

TABLE XXXIII.2 Evidence surrounding the use of nasal endoscopy in the surveillance of sinonasal tumors.

Study	Year	LOE	Study design	Study groups	Clinical endpoints	Conclusions
Nyquist et al. ²¹⁹⁵	2021	3	Retrospective cohort	231 patients treated for SNM	1. DFS 2. Recurrence rate	Recurrence was detected by nasal endoscopy in 34.3% of cases
Zocchi et al. ⁴¹⁹	2020	3	Retrospective cohort	417 patients treated for SNM	Recurrence rates	Endoscopy identified 21% of recurrences
Khalili et al. ⁴¹⁸	2016	4	Retrospective case series	109 patients with primary SNM that underwent successful definitive treatment	Diagnostic utility	Endoscopy has comparable specificity and a predilection toward identifying superficial local recurrences highly amenable to salvage therapy

Abbreviations: DFS, disease-free survival; SNM, sinonasal malignancy.

D | Role of imaging

Imaging undoubtedly plays a vital role in tumor surveillance (Table XXXIII.3). While nasal endoscopy can reveal changes and recurrences in the visible mucosa of the sinonasal tract, imaging provides the advantage of visualizing change deep to the mucosa, as can often be seen in SNM recurrence. This includes structures of the orbit, anterior and middle cranial fossae, and PPF/ITF.³⁵ Structural and functional imaging studies are useful in this scenario with the mainstay of structural imaging being MRI. MRI offers superior soft tissue definition and allows for evaluation of PNI.¹⁹ The use of imaging increases the likelihood of detection of recurrent or residual disease compared to endoscopy alone, with rates of detection ranging from 49% to 62.7%.^{7,12,14} Khalili et al. demonstrated that the PPV for MRI was significantly greater compared to FDG-PET/CT and CT (84% vs. 46% and 44%, respectively).¹⁴ In contrast, FDG-PET/CT has an average NPV of 94.4% ± 7.3%, which is useful in ruling out recurrence at primary, regional, and distant sites.^{4,36–40} Despite this, the modality of choice is controversial and largely institutionally dependent.

Controversy exists on the appropriate timing of imaging in tumor surveillance. While data from head and neck malignancy suggest a posttreatment FDG-PET/CT at 12 weeks, there is some evidence to suggest this timing may not be appropriate in SNM given differences in sinonasal mucosal inflammation following treatment. Two studies retrospectively evaluated the optimal timing of posttreatment FDG-PET/CT for the diagnosis of recurrence in SNM.^{3,41} Schwartz et al. investigated the level of FDG avidity in FDG-PET/CT imaging and reported that inflammation does not resolve until greater than 5 months following completion of treatment.³ Conversely, Ozturk et al. found that FDG-PET/CT had 100% sensitivity and specificity for detecting recurrence at all sites when performed between 1 and 3 months following completion of

treatment; however, the population and imaging intervals were heterogeneous.^{38,41} There are no studies assessing the optimal time intervals for imaging studies in surveillance of SNT.

The type of imaging used for surveillance also depends on the site. MRI provides superior detail for evaluation of the primary site, while FDG-PET/CT provides improved diagnostic information for regional and distant failure. Only one study assessed the diagnostic accuracy of MRI in the diagnosis of recurrence; however, only PPV was reported. The authors noted that PPV was superior for MRI compared to FDG-PET/CT for local recurrence (84% vs. 46%).¹⁴ They furthermore concluded that FDG-PET/CT has higher false-negative rates, likely due to the inflammatory nature of the sinonasal mucosa. Despite these findings, the PPV for FDG-PET/CT ranges from 43% to 97% with more consistent sensitivity, specificity, and NPV.^{4,14,36–40} These findings suggest that FDG-PET/CT is highly sensitive with a high NPV, making this an invaluable modality to rule out recurrence, though the PPV is variable. A summary of the diagnostic utility measures can be seen in Table XXXIII.4 for SNM.

Role of imaging for surveillance

Aggregate grade of evidence C (Level 3: seven studies; level 4: one study).

Benefit	Detection of recurrent disease that cannot be detected though physical exam or nasal endoscopy (e.g., lateral frontal sinus, submucosal, intracranial, intraorbital).
Harm	Minimal harm of radiation and allergic reaction from radioisotopes. Potential for unnecessary testing leading to financial consequences.
Cost	Direct costs: variable cost depending on institution and imaging protocols

(Continued)

Benefits–harm assessment	Preponderance of benefits over harms.
Value judgments	FDG-PET/CT should be used for evaluation of regional or distant metastases, while MRI is the treatment of choice for surveillance of the primary site (i.e., superior soft tissue definition). CT can be considered but has less sensitivity compared to MRI.
Policy level	Recommendation.
Intervention	Posttreatment imaging should be performed to detect residual or recurrent disease. MRI and/or FDG-PET/CT should be the modality of choice. Multiple scans provide for adequate comparison of changes across time. The timing is left to provider discretion, but FDG-PET/CT should be performed 12 weeks following completion of treatment and MRI should be performed within 8–10 weeks following treatment.

E | Differences in surveillance practices based on histology

There were no studies assessing the impact of tumor histology on the specific intervals or modalities of surveillance; however, based on the pooled evidence, it can be implied that histology is paramount. While tumors of the head and neck generally consist of SCC and its subtypes, sinonasal tumors are vastly different and tumor biology strongly dictates the necessary follow-up interval and modality for surveillance. Given the paucity of data in the literature, it is necessary to infer recommendations by assessing the natural course of each tumor, benign and malignant.

Differences in surveillance practices based on histology

Aggregate grade of evidence	D (no dedicated studies)
Benefit	Detection of recurrent or residual sinonasal tumors.
Harm	Missing late or early recurrence of disease; unnecessary testing or examinations.
Cost	None.
Benefits–harm assessment	Insufficient evidence.
Value judgments	Sinonasal tumors behave differently from other head and neck tumors. Surveillance should be tailored to specific tumor histology and biologic behavior.
Policy level	No recommendation.

(Continued)

Intervention	Tumor histology should be taken into consideration when determining the appropriate surveillance protocols. Most tumors recur within the first 5 years; however, certain pathologies (e.g., IP, ONB) have propensity for recurrence greater than 10 years following definitive treatment.
--------------	---

F | Surveillance of sinonasal malignancies

While current dogma suggests that FDG-PET/CT is useful for surveillance of regional or distant metastatic disease, this is generally based on clinical studies for HNSCC, which has a higher propensity for regional failure. In general, SNM tends to fail locally, though this is dependent on the tumor histology. The median recurrence rate for SNM in the included studies was 30.7% (range 17.6%–73.9%), with the majority of recurrences being local. When assessing tumor subtype, HPC had the lowest rates of recurrence and mucosal melanoma had the highest rates.^{373,402,419,1417,2197} The DFS is also dependent on tumor subtype, with SNUC, SNEC, and melanoma having the shortest DFS and salivary gland tumors, adenocarcinomas, and ONB having the longest.^{216,373,418,419,431,1086,1153,1161,1166,1397,1417,1931,2195–2197} Other than descriptions of DFS and OS, no studies evaluated differences in surveillance including modalities, timing, and duration based on tumor histology.

G | Surveillance of inverted papilloma

While IP is a benign tumor, there is a risk for malignant degeneration and recurrence of the primary tumor, necessitating long-term surveillance.²² Of the included studies, 11 studies assessed long-term follow-up for IP.^{369,701,720,721,741,1135,2194,2198–2201} There was a wide range for mean time to recurrence ranging from 8 to 45.5 months, with maximum time to recurrence being 253.2 months. The rates of recurrence were also variable with a mean rate of recurrence of 16.1% ± 9.1%. The method for diagnosis of recurrence was inconsistent across included studies with nasal endoscopy and imaging being used. Many authors advocated the use of nasal endoscopy for surveillance.^{216,369,701,2199,2200} Both MRI and CT were used for evaluation of recurrent lesions at variable schedules. Only one compared different surveillance strategies.⁷⁴¹ The authors compared findings from CT, MRI, and nasal endoscopy on patients with recurrent IP and demonstrated that MRI revealed the presence of the recurrent tumor in all cases compared to the other modalities. CT was equiv-

TABLE XXXIII.3 Evidence surrounding the use of imaging in the surveillance of sinonasal tumors.

Study	Year	LOE	Study design	Study groups	Clinical endpoints	Conclusions
Thakar et al. ²²⁰³	2020	3	Prospective cohort	18 patients with JNA	Diagnostic utility of MRI and PSMA-PET/CT	PSMA-PET/CT had higher PPV and specificity compared to MRI
Workman et al. ⁴²¹	2017	3	Retrospective cohort	78 patients with SNM who underwent treatment and had posttreatment FDG-PET/CT	Diagnostic utility of FDG-PET/CT	FDG-PET/CT can detect treatable recurrences that can be missed with structural imaging with high sensitivity and NPV
Schwartz et al. ²¹⁹³	2016	3	Retrospective cohort	76 patients with nonlocally recurrent SNM who underwent FDG-PET/CT	DFS, recurrence rates, diagnostic utility of FDG-PET/CT	The posttreatment sinonasal skull base is characterized by prolonged periods of hypermetabolism, which affects FDG-PET/CT accuracy
Lamarre et al. ¹⁹⁷	2012	3	Retrospective cohort	31 patients with SNM	Diagnostic utility of FDG-PET/CT	FDG-PET/CT has low PPV for detection of primary site recurrence
Harvey et al. ⁴²⁰	2010	3	Retrospective cohort	34 patients with SNM	Diagnostic utility of FDG-PET/CT	FDG-PET/CT is highly sensitive; however, posttreatment mucosal inflammation may alter the accuracy
Rho et al. ²²⁰⁴	2010	3	Retrospective cohort	22 patients with maxillary sinus cancer who underwent FDG-PET/CT	Diagnostic utility of FDG-PET/CT	FDG-PET/CT is highly sensitive and specific for the detection of recurrence in the maxillary sinus
Gil et al. ²¹⁶	2007	3	Prospective cohort	47 patients with skull base tumors	Diagnostic utility of FDG-PET/CT	Postoperative follow-up using PET/CT enables early detection of tumor recurrence and guides endoscopic biopsies
Khalili et al. ⁴¹⁸	2016	4	Retrospective case series	109 patients with primary SNM who underwent successful definitive treatment	Diagnostic utility of FDG-PET/CT	<ol style="list-style-type: none"> 1. Imaging is superior to endoscopy in terms of sensitivity, accuracy, and NPV 2. MRI more reliably predicts sinonasal cancer recurrence than either FDG-PET/CT or CT alone

Abbreviations: ¹⁸F-FDG, fluorodeoxyglucose F 18; CT, computed tomography; DFS, disease-free survival; JNA, nasopharyngeal angiofibroma (formerly juvenile nasopharyngeal angiofibroma); OS, overall survival; PET, positron emission tomography; PSMA, prostate-specific membrane antigen; SNM, sinonasal malignancy.

ocal in 40% of cases and nasal endoscopy only visualized 50% of tumors. Multiple factors appeared to influence rates of recurrence and surveillance decisions. Nakayama et al. used annual CT or MRI for surveillance when the tumor attachment point was not identified intraoperatively.²¹⁹⁴ Similarly, Jiang et al. used posttreatment CT for surveillance when the primary site was difficult to visualize on postoperative nasal endoscopy.²¹⁹⁹ Furthermore, attachment in the frontal sinus or to the opticocarotid recess in sphenoid sinus IP showed increased risk for recurrence, necessitating closer follow-up.^{369,720,1135}

XXXIV | RESEARCH OPPORTUNITIES AND FUTURE DIRECTIONS

Despite the rarity and heterogeneity of sinonasal tumors, the interest in investigating pathophysiology, diagnosis, treatment, and prognostication is increasing rapidly. While the literature has historically classified sinonasal tumors by anatomical subsite, there is increasing focus on histopathology in studying and classifying each tumor type. The current literature on specific histopathologies primarily relies on retrospective case series and retro-

TABLE XXXIII. 4 Summary of the diagnostic utility of imaging studies for the detection of recurrence in sinonasal malignancies.

Study	Date	Modality	Site	Sensitivity	Specificity	PPV	NPV
Gil et al. ²¹⁶	2007	FDG-PET/CT	Primary site	77%	81%	83%	76%
Harvey et al. ⁴²⁰	2010	FDG-PET/CT	Primary site	100%	40%	54%	100%
Khalili et al. ⁴¹⁸	2016	CT	Local	NR	NR	44%	NR
		FDG-PET/CT	Local	NR	NR	46%	NR
		MRI	Local	NR	NR	84%	NR
Lamarre et al. ¹⁹⁷	2012	FDG-PET/CT	All sites	90%	90%	NR	NR
		FDG-PET/CT	Local	77%	84%	56%	93%
		FDG-PET/CT	Regional	100%	89%	NR	NR
		FDG-PET/CT	Distant	83%	95%	63%	98%
Ozturk et al. ²²⁰⁵	2019	FDG-PET/CT	Local	84%	95%	84%	95%
		FDG-PET/CT	Regional	91%	99%	91%	99%
		FDG-PET/CT	Distant	81%	99%	97%	96%
Rho et al. ²²⁰⁴	2010	FDG-PET/CT	Local	86%	93%	86%	93%
Workman et al. ⁴²¹	2017	FDG-PET/CT	All sites	75%	96%	43%	99%

spective study of publicly available databases or registries. Prospective trials constitute only a small fraction of the evidence base limited to more common pathologies while neglecting rarer entities. Moreover, many principles relevant to oncologic care in the sinonasal tract have been gleaned from research focused on tumors in other sites of the head and neck, which at best only incorporate a subset of patients with sinonasal primaries. Recent understanding for need to classify sinonasal tumor types based upon pathophysiology—for example, specific molecular mutations—combined with the relative rarity of sinonasal tumors underscores not only the need for more in-depth studies but also collaborative multicenter investigations in order to collect sufficient numbers of cases and fully capture the breadth of each tumor type.

A | Basic/translational research opportunities

Contemporary understanding of cancer biology driven by genomic and molecular signatures continues to evolve across all fronts, and sinonasal oncology has benefitted tremendously from this surge in knowledge and new techniques. As part of the wave of precision medicine common to all tumor research is understanding and providing prognostic and treatment data based on tissue analysis.^{421,2206} This is a multidisciplinary, potentially multicenter, effort that would require the creation and maintenance of tissue biospecimen banks and an infrastructure for patient recruitment, tissue collection and processing, molecular analysis, and critical interpretation of the resulting data.

This approach has recently been applied to IP research, which is more prevalent than malignancies, and has drawn new insights in our understanding of IP pathogenesis and prognosis.^{659,669,1140} Recent developments in the ability to perform single-cell RNA sequencing have provided novel insights into heterogeneity within skull base tumors as well as the surrounding host tissues, which may have value in sinonasal oncologic research as well.^{2207–2209} Complementary to this endeavor is the identification and validation of novel biomarkers for sinonasal tumors, such as predicting clinical behavior or screening for recurrence. With increasing availability of next-generation sequencing capabilities—including single-cell sequencing—and bioinformatic approaches, the potential for significant new insights into pathogenesis and predictors of treatment response and immunotherapies has never been greater. We identify as ongoing research needs in a tumor-specific manner:

- Understanding for the tumor microenvironment at the single-cell level of the heterogeneity in tumor genetics and epigenetics, the surrounding mucosal environment, and the inflammatory response.
- Synthesis of genomic/molecular data with clinicopathologic behavior, response to treatment, and long-term outcomes.
- Application of new bioinformatic techniques to assimilate and interpret complex genomic data.
- Development of preclinical models (e.g., cell lines, in vitro models, animal) of sinonasal cancer biology that can be used to study tumor behavior and treatment response.

B | Clinical and outcomes research opportunities

Collaborative research is a major cornerstone of study of oncologic outcomes, as the joint efforts of diverse backgrounds can bring about synergistic insights, especially for rare and complex tumors like those originating from the sinonasal tract. Thus, there is a pressing need for motivated investigators to spearhead prospective, multi-institutional, and multidisciplinary registry-based research that provides not only highly granular but also consistent, comparable, and compatible data. Clear definitions of outcome measures, treatment modalities, and independent variables (e.g., tumor involvement and primary site) are paramount, facilitating statistical reporting and meta-analyses. Additionally, the design of outcome studies should strive to balance appropriate representation of patient populations such as biologic sex, race/ethnicity, and socioeconomic factors. A strong effort should be made toward developing clinical trials with the same scientific rigor as those developed by the medical and radiation oncology communities. Several early examples of this type of innovative research have recently surfaced.^{14–16,1564,2210–2215} With multiple specialties involved in the care of these complex patients, the sinonasal oncologic community can leverage divergent backgrounds and expertise to drive the field forward. We identify as ongoing research needs in a tumor-specific manner:

- Increasing well-balanced clinical trials across all treatment modalities (surgery, chemotherapy, RT, immunotherapy), especially for rarer pathologies.
- Creation of evidence-based practice guidelines backed by high-level clinical studies (e.g., RCTs).
- Improvement of data granularity, consistency/compatibility across studies, reproducibility (e.g., core outcome measures), and precision.

C | Public health/policy

As sinonasal tumors are rare, the thrust of care generally lies at the level of referral centers and subspecialists. Due to the ability of sinonasal tumors to expand within the nasal cavity and paranasal sinuses with only vague and nonspecific presenting signs and symptoms, most tumors are discovered at an advanced stage. Thus, there is a major opportunity to educate first-line providers, thereby increasing their awareness of these conditions. This could, in turn, result in prompt referrals and possibly workup whenever “danger signs” are identified. For specific condi-

tions with higher prevalence and well-defined risk factors, enactment of evidence-based screening protocols may be feasible. An example of this is NPC screening for first-degree relatives of patients in Hong Kong, where the disease is endemic.²²¹⁶ Finally, further research in the areas of disparities and differences in outcomes and access to care based on sex, race/ethnicity, and socioeconomic status is needed to create unique specific screening and treatment plans for patients of various backgrounds. We identify as ongoing research needs in a tumor-specific manner:

- Methods for education of providers in various specialties and points of care (e.g., primary care, emergency department) regarding concerning signs/symptoms and “red flags” that may be suspicious for sinonasal tumors, thus prompting earlier referral and/or workup/intervention.
- Determination of streamlined, informative, and cost-effective means to screen, diagnose, and stage SNM patients.
- Improved understanding of healthcare disparities in sinonasal tumor care, as well as differences in incidence, prognosis, presentation, access to care, and treatment strategies based on sex, race/ethnicity, socioeconomic status, and other social determinants of health.

D | Diagnosis, workup, and staging

To date, comprehensive workup of the patient is confined to assessing signs and symptoms, endoscopic examination, and radiographic studies. Despite this multimodal approach, it remains highly challenging to diagnose sinonasal tumors, and there are very few disease-specific indicators that provide clinically meaningful information upfront, with clinicians requiring tissue analysis to guide therapy. Novel applications of imaging have been reported, such as the use of ⁶⁸Gallium-DOTATATE for detection of ONB.^{2217,2218} The WHO will likely continue to refine their tumor classification system based on new insights in molecular/genomic analytics, biomarkers, and tumor biology (e.g., SNUC as stratified into multiple diseases through DNA methylation-based classification).²²¹⁹ Traditional staging systems also may not capture all meaningful prognostic information, and there is a need to rethink and potentially redesign informative staging systems that integrate these critical features (e.g., Hyams grade in ONB, mutational burden). With the rise of artificial intelligence applications in medicine as a whole, systematic assessment of unique indicators of tumor behavior based on radiology and pathology may emerge.^{2220–2222} We identify as ongoing research needs in a tumor-specific manner:

- Identification of new/alternative strategies, biomarkers, and imaging modalities to more accurately diagnose patients with sinonasal tumors, especially malignancies at an earlier stage.
- Development of enhanced imaging modalities that evaluate the extent of involvement of sinonasal tumors, in particular orbital and intracranial involvement. Tumor-specific biomarkers may also help to determine early metastases that are not detected with current modalities.
- Defining and validating radiographic and histopathologic signatures of specific tumors, with refinement of tumor biology classification. Multicenter radiomic approaches with external validation could significantly alter this paradigm as seen in other specialties (e.g., mammography).
- Development of novel staging systems integrating prognostically relevant data for specific histopathologies.

E | Treatment strategies

Many of these treatment concepts described here are drawn from the prior ICSB 2019 document (Section XIV.B), which have insightfully highlighted many of these gaps. As we have pushed the boundaries and limits of surgical treatment with new techniques and approaches, the same questions remain regarding margin analysis and the balance between efficacy and functional preservation. We now recognize that treatment strategies should follow a histopathologic-specific strategy, and the trend toward a precision tumor- and patient-specific approach will continue. IC has shown promise with treating locally advanced tumors and has the potential for orbit and skull base preservation. Immunotherapy has changed our treatment of mucosal melanoma and may have a role for metastatic disease. Appropriate selection of treatment candidates would be crucial in fitting these modalities into the current paradigm. Finally, as oncologic principles evolve and surgical techniques further develop, there will be gradual convergence of the roles of rhinologists and head and neck surgeons in the surgical management of these patients, with targeted selection of open, endoscopic, and combined approaches, likely in a team-based fashion (e.g., regular joint participation in tumor board conferences). We identify as ongoing research needs:

- Development of precision, histopathology-specific, and patient-specific treatment algorithms based on tumor and patient factors.
- Identification of methodology for appropriate selection of surgical candidates based on patient and tumor factors, and balancing this with nonsurgical treatment options (e.g., chemotherapy and RT).

- Refining the understanding of the concept of resectability as surgical advances progress.
- Developing well-designed studies comparing oncologically sound endoscopic versus open/combined approaches, particularly for malignancies, to elucidate the impact of approach on survival and QOL.
- Tailoring sampling of adequate margins based on histopathology.
- Determining the role of induction chemotherapy in the management algorithm for locally advanced and/or metastatic SNM, understanding when organ preservation should be attempted, and identifying which histopathologies respond best.
- Determining the role of immunotherapy in management of various SNM, particularly mucosal melanomas.
- Improving the understanding of how RT and/or chemotherapy affects oncologic resection and skull base reconstructive outcomes, with development of algorithms that incorporate these considerations.
- Identifying strategies for balancing morbidity related to different modalities of treatment, including different forms of RT.

F | Survivorship, QOL, and long-term care

As treatment becomes more effective and patients have a higher likelihood of long-term survival, the issues of survivorship, managing QOL, and surveillance become increasingly important. Unlike for other head and neck cancers, no QOL instruments are specifically validated for sinonasal tumors, and there is an opportunity to enrich our understanding of QOL outcomes before, during, and after treatment. With post-RT patients who survive longer, radiation-related side effects, such as skull base ORN and brain necrosis, will become more prevalent, with a need to develop effective treatment and prevention strategies whenever possible. Finally, most of the literature on surveillance strategy has been based on nonsinonasal head and neck mucosal tumors. As we deepen our understanding of sinonasal tumor biology, seldom is “achieving cure” simply based on patients having no evidence of disease for 5 years following treatment completion. Further work into duration and means of long-term surveillance will be critical, especially for a class of diseases where symptoms are not the primary means of detection of recurrence.⁴³¹ We identify as ongoing research needs in this area:

- Consensus identification of suitable generic and disease-specific QOL instruments for assessing outcomes in sinonasal tumor patients, and/or design and validation of new instruments for this purpose.

- Characterization of long-term adverse effects of treatment, ranging from secondary conditions that may have significant health risks (e.g., radiation necrosis, second primary) to those with QOL implications (e.g., sinusitis, chronic rhinitis).
- Development of optimal long-term surveillance protocols based on histopathology, and which imaging modalities (e.g., MRI, PET) are most appropriate at which intervals.

XXXV | CONCLUSION

ICSNT represents an unprecedented, concerted effort to bring together experts from around the world and across disciplines to synthesize the current evidence of sinonasal tumor care, focusing on essential topics such as general principles, benign and malignant histopathologies, QOL, and survivorship. The evidence level is overall highly heterogeneous, with many noted areas of additional investigation needed, and would likely benefit from a team-based approach given the rarity of many pathologies. As our understanding deepens and there is increased recognition of this class of diseases, new questions and avenues of investigation will be generated, with future versions of ICSNT again focusing on critical updates and major paradigm shifts. We sincerely hope that ICSNT serves as an informative and useful resource for clinicians of all training levels and areas of expertise who are united across the front to face the challenges of sinonasal tumors.

ACKNOWLEDGMENTS

This research was supported (in part) by the Intramural Research Program of the Center for Cancer Research, National Cancer Institute (N. R. London Jr.). The authors thank Mary Jo Tutchko for administrative support and Jennifer C. Westrick, MSLIS, AHIP for her contribution to the search strategy.

CONFLICT OF INTEREST STATEMENT

E. C. Kuan: Consultant for Stryker and 3-D Matrix; royalties from Springer Books

N. D. Adappa: Consultant for Acclarent

D. M. Beswick: Grant support from Cystic Fibrosis Foundation, International Society of Inflammation and Allergy of the Nose, and the CORE/Sue Ann and John L. Weinberg Foundation; honoraria and consulting fees on medicolegal cases and at Garner Health (equity)

N. R. London Jr.: Grant funding from Merck Sharp & Dohme, LLC regarding HPV-related sinonasal malignancies; holds stock in Navigen Pharmaceuticals

C. S. Betz: Consultant for Medtronic, Bristol-Myers Squibb, and Brainlab

B. S. Bleier: Consultant for Olympus, Karl Storz, Medtronic, and Stryker; equity interest in SoundHealth, Dicer Therapeutics, and Inquis Medical; royalties from Thieme

R. K. Chandra: Consultant for Olympus, Lyra Therapeutics, Optinose, and Regeneron

A. U. Luong: Current PI on clinical trials for Sanofi; consultant to ENTvantage, Lyra Therapeutics, Maxwell Biosciences, Medtronic, SoundHealth, and Stryker

S. N. Markovic: Grant funding from BMS and Sorrento Pharma

Z. M. Patel: Consultant/advisory board member for Medtronic, Optinose, Dianotic, Regeneron/Sanofi, Ethicon Johnson & Johnson, Mediflix, Consumer Medical, and Wyndly; equity: Olfera Therapeutics

A. J. Psaltis: Consultant for Medtronic, ENT Technologies, and Fusetech; speakers bureau with Sequiris; shareholder with Chitogel

P. Schafhausen: Consultant with Bristol-Myers Squibb/Celgene and Merck Serono/MSD

B. A. Senior: Consultant for Stryker, Lyra Therapeutics, and Neuroent

S. K. Wise: Consultant for Chitogel, NeurENT, Optinose, and SoundHealth

B. A. Woodworth: Consultant for Cook Medical and Medtronic

P.-J. Wormald: Royalties from Medtronic, Integra, and Fusetech; consultant for Neilmed and Stryker


J. N. Palmer: Consultant for Acclarent and Optinose

A. Chua: Consultant for Acclarent and MicrogenDx

None of the above conflicts of interest are relevant to the content of ICSNT. The other authors declare no conflicts of interest.

ORCID

Edward C. Kuan MD, MBA  <https://orcid.org/0000-0003-3475-0718>


Eric W. Wang MD  <https://orcid.org/0000-0002-1180-5854>


Daniel M. Beswick MD  <https://orcid.org/0000-0001-8612-5442>

Marilene B. Wang MD  <https://orcid.org/0000-0002-2799-6325>

Jeremiah A. Alt MD, PhD  <https://orcid.org/0000-0003-0560-5028>

Benjamin S. Bleier MD  <https://orcid.org/0000-0003-0783-8861>

Claudio Callejas MD  <https://orcid.org/0000-0002-6993-4456>

Garret Choby MD  <https://orcid.org/0000-0002-3745-2727>

Gianluca Dalfino MD  <https://orcid.org/0000-0002-1380-4206>

Jean Anderson Eloy MD  <https://orcid.org/0000-0003-2893-7818>

Christina H. Fang MD  <https://orcid.org/0000-0001-6047-2788>

Nyssa F. Farrell MD  <https://orcid.org/0000-0003-1510-4008>

Marco Ferrari MD, PhD  <https://orcid.org/0000-0002-4023-0121>

Christos Georgalas PhD, DLO, MRCS(Ed), FRCS(ORL-HNS)  <https://orcid.org/0000-0003-1158-020X>

Jessica W. Grayson MD  <https://orcid.org/0000-0002-2131-8005>

Richard J. Harvey MD  <https://orcid.org/0000-0002-6942-8975>

Claire Hopkins MD, PhD  <https://orcid.org/0000-0003-3993-1569>

Ian M. Humphreys DO  <https://orcid.org/0000-0002-6832-754X>

Peter H. Hwang MD  <https://orcid.org/0000-0002-0786-4675>

Aria Jafari MD  <https://orcid.org/0000-0002-5254-3221>

Adam J. Kimple MD, PhD  <https://orcid.org/0000-0003-1670-8401>

Devyani Lal MD  <https://orcid.org/0000-0002-7593-2385>

Ming-Ying Lan MD, PhD  <https://orcid.org/0000-0001-5565-9580>

Amber U. Luong MD, PhD  <https://orcid.org/0000-0001-6078-8010>

Cem Meço MD  <https://orcid.org/0000-0001-8372-8045>

Kazuhiro Omura MD, PhD  <https://orcid.org/0000-0002-4337-4745>

Richard R. Orlandi MD, MBA  <https://orcid.org/0000-0001-5374-9144>

Zara M. Patel MD  <https://orcid.org/0000-0003-2072-982X>

Ahmad R. Sedaghat MD, PhD  <https://orcid.org/0000-0001-6331-2325>

Brent A. Senior MD  <https://orcid.org/0000-0002-1503-3150>

Timothy L. Smith MD  <https://orcid.org/0000-0002-6424-7083>


Kristine A. Smith MD, FRCSC  <https://orcid.org/0000-0002-7026-5819>


Carl H. Snyderman MD, MBA  <https://orcid.org/0000-0002-8920-4522>


Charles C. L. Tong MD  <https://orcid.org/0000-0002-4471-5134>


Thibaut van Zele MD, PhD  <https://orcid.org/0000-0002-6031-4293>

Tae-Bin Won MD, PhD  <https://orcid.org/0000-0003-2266-3975>

Bradford A. Woodworth MD  <https://orcid.org/0000-0003-3292-9167>

William C. Yao MD  <https://orcid.org/0000-0002-9845-2165>

Chien-Fu Yeh MD, PhD  <https://orcid.org/0000-0002-7812-2230>

Bing Zhou MD  <https://orcid.org/0000-0002-3411-0537>

REFERENCES

- Orlandi RR, Kingdom TT, Hwang PH, et al. International Consensus Statement on Allergy and Rhinology: Rhinosinusitis. *Int Forum Allergy Rhinol.* 2016;6(Suppl. 1):S22-209. <https://doi.org/10.1002/alr.21695>
- Patel ZM, Holbrook EH, Turner JH, et al. International Consensus Statement on Allergy and Rhinology: Olfaction. *Int Forum Allergy Rhinol.* 2022;12(4):327-680. <https://doi.org/10.1002/alr.22929>
- Wise SK, Damask C, Roland LT, et al. International Consensus Statement on Allergy and Rhinology: Allergic Rhinitis - 2023. *Int Forum Allergy Rhinol.* 2023;13(4):293-859. <https://doi.org/10.1002/alr.23090>
- Wise SK, Lin SY, Toskala E, et al. International Consensus Statement on Allergy and Rhinology: Allergic Rhinitis. *Int Forum Allergy Rhinol.* 2018;8(2):108-352. <https://doi.org/10.1002/alr.22073>
- Wang EW, Zanation AM, Gardner PA, et al. ICAR: endoscopic skull-base surgery. *Int Forum Allergy Rhinol.* 2019;9(S3):S145-S365. <https://doi.org/10.1002/alr.22326>
- Lund VJ, Stammberger H, Nicolai P, et al. European position paper on endoscopic management of tumours of the nose, paranasal sinuses and skull base. *Rhinol Suppl.* 2010;22:1-143.
- Rudmik L, Smith TL. Development of an evidence-based review with recommendations using an online iterative process. *Int Forum Allergy Rhinol.* 2011;1(6):431-437. <https://doi.org/10.1002/alr.20095>
- Page MJ, McKenzie JE, Bossuyt PM, et al. The PRISMA 2020 statement: an updated guideline for reporting systematic reviews. *BMJ.* 2021;372:n71. <https://doi.org/10.1136/bmj.n71>
- American Academy of Pediatrics Steering Committee on Quality Improvement and Management. Classifying recommendations for clinical practice guidelines. *Pediatrics.* 2004;114(3):874-877. <https://doi.org/10.1542/peds.2004-1260>
- Abdou R, Baredes S. Population-based results in the management of sinonasal and ventral skull base malignancies. *Otolaryngol Clin North Am.* 2017;50(2):481-497. <https://doi.org/10.1016/j.otc.2016.12.019>
- Franchi A, ed. *Pathology of Sinonasal Tumors and Tumor-like Lesions.* Springer; 2020.
- Lund VJ. Sinonasal malignant melanoma. *Adv Otorhinolaryngol.* 2020;84:185-196. <https://doi.org/10.1159/000457937>
- Chiu AG, Ramakrishnan VR, Suh JD. *Sinonasal Tumors.* Jaypee Brothers Medical Publishers; 2012. <https://books.google.com/books?id=dsi9BAAQAQBAJ>
- Beswick DM, Hwang PH, Adappa ND, et al. Surgical approach is associated with complication rate in sinonasal malignancy: a multicenter study. *Int Forum Allergy Rhinol.* 2021;11(12):1617-1625. <https://doi.org/10.1002/alr.22833>

15. Lechner M, Takahashi Y, Turri-Zanoni M, et al. Clinical outcomes, Kadish-INSICA staging and therapeutic targeting of somatostatin receptor 2 in olfactory neuroblastoma. *Eur J Cancer*. 2022;162:221-236. <https://doi.org/10.1016/j.ejca.2021.09.046>
16. Ferrari M, Mattavelli D, Tomasoni M, et al. The MUSES*: a prognostic study on 1360 patients with sinonasal cancer undergoing endoscopic surgery-based treatment: *MULTI-institutional collaborative Study on Endoscopically treated Sinonasal cancers. *Eur J Cancer*. 2022;171:161-182. <https://doi.org/10.1016/j.ejca.2022.05.010>
17. WHO Classification of Tumours Editorial Board. *WHO Classification of Head and Neck Tumours*. 5th ed. International Agency for Research on Cancer; 2022. <https://publications.iarc.fr/Book-And-Report-Series/Who-Classification-Of-Tumours>
18. Oxford Centre for Evidence-based Medicine (CEBM). *OCEBM Levels of Evidence*. Accessed October 27, 2021. <https://www.cebm.ox.ac.uk/resources/levels-of-evidence/ocebmllevels-of-evidence>
19. Hennessey PT, Reh DD. Benign sinonasal neoplasms. *Am J Rhinol Allergy*. 2013;27(3_suppl):S31-S34. <https://doi.org/10.2500/ajra.2013.27.3893>
20. Curado MP, Edwards B, Shin HR, et al. *Cancer Incidence in Five Continents Volume IX*. IARC Scientific Publications; 2007. Accessed April 3, 2023. <https://publications.iarc.fr/Book-And-Report-Series/Iarc-Scientific-Publications/Cancer-Incidence-In-Five-Continents-Volume-IX-2007>
21. Silverberg E, Grant RN. Cancer statistics, 1970. *CA Cancer J Clin*. 1970;20(1):11-23.
22. Dulguerov P, Jacobsen MS, Allal AS, Lehmann W, Calcaterra T. Nasal and paranasal sinus carcinoma: are we making progress? A series of 220 patients and a systematic review. *Cancer*. 2001;92(12):3012-3029. [https://doi.org/10.1002/1097-0142\(20011215\)92:12\(3012::aid-cnrc10131\)3.0.co;2-e](https://doi.org/10.1002/1097-0142(20011215)92:12(3012::aid-cnrc10131)3.0.co;2-e)
23. Surveillance, Epidemiology, and End Results Program. *U.S. County Population Data - 1969-2020*. SEER. Accessed April 3, 2023. <https://seer.cancer.gov/popdata/index.html>
24. National Program of Cancer Registries, 2001 submission (2005-2019). Centers for Disease Control and Prevention; 2022.
25. De Angelis R, Sant M, Coleman MP, et al. Cancer survival in Europe 1999-2007 by country and age: results of EURO-CARE-5—a population-based study. *Lancet Oncol*. 2014;15(1):23-34. [https://doi.org/10.1016/S1470-2045\(13\)70546-1](https://doi.org/10.1016/S1470-2045(13)70546-1)
26. Unsal AA, Kılıç S, Dubal PM, Baredes S, Eloy JA. A population-based comparison of European and North American sinonasal cancer survival. *Auris Nasus Larynx*. 2018;45(4):815-824. <https://doi.org/10.1016/j.anl.2017.09.009>
27. Busco S, Buzzoni C, Mallone S, et al. Italian cancer figures—report 2015: the burden of rare cancers in Italy. *Epidemiol Prev*. 2016;40(1 Suppl 2):1-120. <https://doi.org/10.19191/EP16.1S2.P001.035>
28. Youlden DR, Cramb SM, Peters S, et al. International comparisons of the incidence and mortality of sinonasal cancer. *Cancer Epidemiol*. 2013;37(6):770-779. <https://doi.org/10.1016/j.canep.2013.09.014>
29. Dutta R, Dubal PM, Svider PF, Liu JK, Baredes S, Eloy JA. Sinonasal malignancies: a population-based analysis of site-specific incidence and survival. *Laryngoscope*. 2015;125(11):2491-2497. <https://doi.org/10.1002/lary.25465>
30. Turner JH, Reh DD. Incidence and survival in patients with sinonasal cancer: a historical analysis of population-based data. *Head Neck*. 2012;34(6):877-885. <https://doi.org/10.1002/hed.21830>
31. Anjum W, Maken RN, Nisar H, Fatima I, Masood M, Shahid AB. Epidemiology and treatment outcomes of sinonasal tumors: a single institute's experience in Pakistan. *J Coll Physicians Surg Pak*. 2019;29(4):356-360. <https://doi.org/10.29271/jcpsp.2019.04.356>
32. Ansa B, Goodman M, Ward K, et al. Paranasal sinus squamous cell carcinoma incidence and survival based on surveillance, epidemiology, and end results data, 1973 to 2009. *Cancer*. 2013;119(14):2602-2610. <https://doi.org/10.1002/cncr.28108>
33. Myers LL, Nussenbaum B, Bradford CR, Teknos TN, Esclamado RM, Wolf GT. Paranasal sinus malignancies: an 18-year single institution experience. *Laryngoscope*. 2002;112(11):1964-1969. <https://doi.org/10.1097/00005537-200211000-00010>
34. Roush GC. Epidemiology of cancer of the nose and paranasal sinuses: current concepts. *Head Neck Surg*. 1979;2(1):3-11. <https://doi.org/10.1002/hed.2890020103>
35. Melroy CT, Senior BA. Benign sinonasal neoplasms: a focus on inverting papilloma. *Otolaryngol Clin North Am*. 2006;39(3):601-617, x. <https://doi.org/10.1016/j.otc.2006.01.005>
36. Re M, Gioacchini FM, Bajraktari A, et al. Malignant transformation of sinonasal inverted papilloma and related genetic alterations: a systematic review. *Eur Arch Otorhinolaryngol*. 2017;274(8):2991-3000. <https://doi.org/10.1007/s00405-017-4571-2>
37. Syrjänen S, Syrjänen K. HPV-associated benign squamous cell papillomas in the upper aero-digestive tract and their malignant potential. *Viruses*. 2021;13(8):1624. <https://doi.org/10.3390/v13081624>
38. Scholtz AW, Appenroth E, Kammen-Jolly K, Scholtz LU, Thumfart WF. Juvenile nasopharyngeal angiofibroma: management and therapy. *Laryngoscope*. 2001;111(4, Pt. 1):681-687. <https://doi.org/10.1097/00005537-200104000-00022>
39. Franchi A, Miligi L, Palomba A, Giovannetti L, Santucci M. Sinonasal carcinomas: recent advances in molecular and phenotypic characterization and their clinical implications. *Crit Rev Oncol Hematol*. 2011;79(3):265-277. <https://doi.org/10.1016/j.critrevonc.2010.08.002>
40. Dutta M, Saha J, Biswas G, Chattopadhyay S, Sen I, Sinha R. Epidermoid cysts in head and neck: our experiences, with review of literature. *Indian J Otolaryngol Head Neck Surg*. 2013;65(Suppl. 1):14-21. <https://doi.org/10.1007/s12070-011-0363-y>
41. Patel ZM, Li J, Chen AY, Ward KC. Determinants of racial differences in survival for sinonasal cancer. *Laryngoscope*. 2016;126(9):2022-2028. <https://doi.org/10.1002/lary.25897>
42. Ranasinghe VJ, Stubbs VC, Reny DC, Fathy R, Brant JA, Newman JG. Predictors of nodal metastasis in sinonasal squamous cell carcinoma: a national cancer database analysis. *World J Otorhinolaryngol Head Neck Surg*. 2020;6(2):137-141. <https://doi.org/10.1016/j.wjorl.2020.01.006>
43. Desai PB, Bukatko AR, Simpson MC, et al. Comorbidity burden and nonclinical factors associated with sinonasal

- cancer all-cause mortality. *Laryngoscope*. 2020;130(6):1443-1449. <https://doi.org/10.1002/lary.28223>
44. Sharma RK, Schlosser RJ, Beswick DM, et al. Racial and ethnic disparities in paranasal sinus malignancies. *Int Forum Allergy Rhinol*. 2021;11(11):1557-1569. <https://doi.org/10.1002/alr.22816>
 45. Sanghvi S, Patel NR, Patel CR, Kalyoussef E, Baredes S, Eloy JA. Sinonasal adenoid cystic carcinoma: comprehensive analysis of incidence and survival from 1973 to 2009. *Laryngoscope*. 2013;123(7):1592-1597. <https://doi.org/10.1002/lary.24085>
 46. Chapurin N, Totten DJ, Louis PC, et al. Sinonasal small cell carcinoma—case series of a rare malignancy. *Ear Nose Throat J*. 2022;101(6):392-395. <https://doi.org/10.1177/0145561320964640>
 47. Chapurin N, Totten DJ, Morse JC, et al. Treatment of sinonasal teratocarcinoma: a systematic review and survival analysis. *Am J Rhinol Allergy*. 2021;35(1):132-141. <https://doi.org/10.1177/1945892420959585>
 48. Patel TD, Vazquez A, Dubal PM, Baredes S, Liu JK, Eloy JA. Sinonasal neuroendocrine carcinoma: a population-based analysis of incidence and survival. *Int Forum Allergy Rhinol*. 2015;5(5):448-453. <https://doi.org/10.1002/alr.21497>
 49. Patel TD, Carniol ET, Vázquez A, Baredes S, Liu JK, Eloy JA. Sinonasal fibrosarcoma: analysis of the surveillance, epidemiology, and end results database. *Int Forum Allergy Rhinol*. 2016;6(2):201-205. <https://doi.org/10.1002/alr.21639>
 50. Kazi M, Awan S, Junaid M, Qadeer S, Hassan NH. Management of sinonasal tumors: prognostic factors and outcomes: a 10 year experience at a tertiary care hospital. *Indian J Otolaryngol Head Neck Surg*. 2013;65(Suppl 1):155-159. <https://doi.org/10.1007/s12070-013-0650-x>
 51. Wu AW, Suh JD, Metson R, Wang MB. Prognostic factors in sinonasal sarcomas: analysis of the surveillance, epidemiology and end result database. *Laryngoscope*. 2012;122(10):2137-2142. <https://doi.org/10.1002/lary.23442>
 52. Sjöstedt S, Jensen DH, Jakobsen KK, et al. Incidence and survival in sinonasal carcinoma: a Danish population-based, nationwide study from 1980 to 2014. *Acta Oncol*. 2018;57(9):1152-1158. <https://doi.org/10.1080/0284186X.2018.1454603>
 53. Kılıç S, Samarrai R, Kılıç SS, Mikhael M, Baredes S, Eloy JA. Incidence and survival of sinonasal adenocarcinoma by site and histologic subtype. *Acta Otolaryngol*. 2018;138(4):415-421. <https://doi.org/10.1080/00016489.2017.1401229>
 54. Mensi C, Consonni D, Sieno C, De Matteis S, Riboldi L, Bertazzi PA. Sinonasal cancer and occupational exposure in a population-based registry. *Int J Otolaryngol*. 2013;2013:672621. <https://doi.org/10.1155/2013/672621>
 55. Binazzi A, Ferrante P, Marinaccio A. Occupational exposure and sinonasal cancer: a systematic review and meta-analysis. *BMC Cancer*. 2015;15:49. <https://doi.org/10.1186/s12885-015-1042-2>
 56. Mohtashamipur E, Norpoth K, Lühmann F. Cancer epidemiology of woodworking. *J Cancer Res Clin Oncol*. 1989;115(6):503-515. <https://doi.org/10.1007/BF00391350>
 57. Benninger MS. The impact of cigarette smoking and environmental tobacco smoke on nasal and sinus disease: a review of the literature. *Am J Rhinol*. 1999;13(6):435-438. <https://doi.org/10.2500/105065899781329683>
 58. 't Mannetje A, Kogevinas M, Luce D, et al. Sinonasal cancer, occupation, and tobacco smoking in European women and men. *Am J Ind Med*. 1999;36(1):101-107. [https://doi.org/10.1002/\(sici\)1097-0274\(199907\)36:1<101::aid-ajim14>3.0.co;2-a](https://doi.org/10.1002/(sici)1097-0274(199907)36:1<101::aid-ajim14>3.0.co;2-a)
 59. Thun M, Peto R, Boreham J, Lopez AD. Stages of the cigarette epidemic on entering its second century. *Tob Control*. 2012;21(2):96-101. <https://doi.org/10.1136/tobaccocontrol-2011-050294>
 60. Kuijpers JHLP, Louwman MWJ, Peters R, Janssens GORJ, Burdorf AL, Coebergh JWW. Trends in sinonasal cancer in The Netherlands: more squamous cell cancer, less adenocarcinoma. A population-based study 1973-2009. *Eur J Cancer*. 2012;48(15):2369-2374. <https://doi.org/10.1016/j.ejca.2012.05.003>
 61. Oliver JR, Lieberman SM, Tam MM, et al. Human papillomavirus and survival of patients with sinonasal squamous cell carcinoma. *Cancer*. 2020;126(7):1413-1423. <https://doi.org/10.1002/cncr.32679>
 62. Sjöstedt S, von Buchwald C, Agander TK, Aanaes K. Impact of human papillomavirus in sinonasal cancer—a systematic review. *Acta Oncol*. 2021;60(9):1175-1191. <https://doi.org/10.1080/0284186X.2021.1950922>
 63. Kılıç S, Kılıç SS, Kim ES, et al. Significance of human papillomavirus positivity in sinonasal squamous cell carcinoma. *Int Forum Allergy Rhinol*. 2017;7(10):980-989. <https://doi.org/10.1002/alr.21996>
 64. Tendron A, Classe M, Casiraghi O, et al. Prognostic analysis of HPV status in sinonasal squamous cell carcinoma. *Cancers*. 2022;14(8):1874. <https://doi.org/10.3390/cancers14081874>
 65. Bishop JA, Guo TW, Smith DF, et al. Human papillomavirus-related carcinomas of the sinonasal tract. *Am J Surg Pathol*. 2013;37(2):185-192. <https://doi.org/10.1097/PAS.0b013e3182698673>
 66. Steenland K, Burnett C, Lalich N, Ward E, Hurrell J. Dying for work: the magnitude of US mortality from selected causes of death associated with occupation. *Am J Ind Med*. 2003;43(5):461-482. <https://doi.org/10.1002/ajim.10216>
 67. Peck BW, Van Abel KM, Moore EJ, Price DL. Rates and locations of regional metastases in sinonasal malignancies: the Mayo Clinic Experience. *J Neurol Surg B Skull Base*. 2018;79(3):282-288. <https://doi.org/10.1055/s-0037-1607288>
 68. Lund VJ, Clarke PM, Swift AC, McGarry GW, Kerawala C, Carnell D. Nose and paranasal sinus tumours: United Kingdom National Multidisciplinary Guidelines. *J Laryngol Otol*. 2016;130(S2):S111-S118. <https://doi.org/10.1017/S0022215116000530>
 69. Skolnik EM, Massari FS, Tenta LT. Olfactory neuroepithelioma. Review of the world literature and presentation of two cases. *Arch Otolaryngol*. 1966;84(6):644-653. <https://doi.org/10.1001/archotol.1966.00760030646011>
 70. Elkon D, Hightower SI, Lim ML, Cantrell RW, Constable WC. Esthesioneuroblastoma. *Cancer*. 1979;44(3):1087-1094. [https://doi.org/10.1002/1097-0142\(197909\)44:3<1087::AID-CNCR2820440343>3.0.CO;2-A](https://doi.org/10.1002/1097-0142(197909)44:3<1087::AID-CNCR2820440343>3.0.CO;2-A)
 71. Ow TJ, Bell D, Kupferman ME, Demonte F, Hanna EY. Esthesioneuroblastoma. *Neurosurg Clin N Am*. 2013;24(1):51-65. <https://doi.org/10.1016/j.nec.2012.08.005>
 72. Yin Z, Wang Y, Wu Y, et al. Age distribution and age-related outcomes of olfactory neuroblastoma: a population-based

- analysis. *Cancer Manag Res.* 2018;10:1359-1364. <https://doi.org/10.2147/cmar.s151945>
73. Husain Q, Kanumuri VV, Svider PF, et al. Sinonasal adenoid cystic carcinoma: systematic review of survival and treatment strategies. *Otolaryngol Head Neck Surg.* 2013;148(1):29-39. <https://doi.org/10.1177/0194599812464020>
 74. Sanghvi S, Patel NR, Patel CR, Kalyoussef E, Baredes S, Eloy JA. Sinonasal adenoid cystic carcinoma. *Laryngoscope.* 2013;123(7):1592-1597. <https://doi.org/10.1002/lary.24085>
 75. Amit M, Binenbaum Y, Sharma K, et al. Adenoid cystic carcinoma of the nasal cavity and paranasal sinuses: a meta-analysis. *J Neurol Surg B Skull Base.* 2013;74(03):118-125. <https://doi.org/10.1055/s-0033-1347358>
 76. Ellington CL, Kono SA, Owonikoko TK, et al. Adenoid cystic carcinoma of the head and neck (ACCHN) incidence and survival trends. *J Clin Oncol.* 2011;29(15_suppl):5580-5580. https://doi.org/10.1200/jco.2011.29.15_suppl.5580
 77. Thompson LDR, Penner C, Ho NJ, et al. Sinonasal tract and nasopharyngeal adenoid cystic carcinoma: a clinicopathologic and immunophenotypic study of 86 cases. *Head Neck Pathol.* 2013;8(1):88-109. <https://doi.org/10.1007/s12105-013-0487-3>
 78. Marcinow A, Ozer E, Teknos T, et al. Clinicopathologic predictors of recurrence and overall survival in adenoid cystic carcinoma of the head and neck: a single institutional experience at a tertiary care center. *Head Neck.* 2014;36(12):1705-1711. <https://doi.org/10.1002/hed.23523>
 79. Lupinetti AD, Roberts DB, Williams MD, et al. Sinonasal adenoid cystic carcinoma. *Cancer.* 2007;110(12):2726-2731. <https://doi.org/10.1002/cncr.23096>
 80. Välimaa H, Savolainen S, Soukka T, et al. Estrogen receptor-beta is the predominant estrogen receptor subtype in human oral epithelium and salivary glands. *J Endocrinol.* 2004;180(1):55-62. <https://doi.org/10.1677/joe.0.1800055>
 81. Shick PC, Riordan GP, Foss RD. Estrogen and progesterone receptors in salivary gland adenoid cystic carcinoma. *Oral Surg Oral Med Oral Pathol Oral Radiol Endod.* 1995;80(4):440-444. [https://doi.org/10.1016/s1079-2104\(05\)80338-5](https://doi.org/10.1016/s1079-2104(05)80338-5)
 82. Chung SY, Unsal AA, Kılıç S, Baredes S, Liu JK, Eloy JA. Pediatric sinonasal malignancies: a population-based analysis. *Int J Pediatr Otorhinolaryngol.* 2017;98:97-102. <https://doi.org/10.1016/j.ijporl.2017.04.032>
 83. Mansournia MA, Altman DG. Population attributable fraction. *BMJ.* 2018;360:k757. <https://doi.org/10.1136/bmj.k757>
 84. IARC Working Group on the Evaluation of Carcinogenic Risks to Humans. Arsenic, metals, fibres, and dusts. *IARC Monogr Eval Carcinog Risks Hum.* 2012;100(Pt C):11-465.
 85. Comba P, Battista G, Belli S, et al. A case-control study of cancer of the nose and paranasal sinuses and occupational exposures. *Am J Ind Med.* 1992;22(4):511-520. <https://doi.org/10.1002/ajim.4700220406>
 86. Acheson ED, Cowdell RH, Hadfield E, Macbeth RG. Nasal cancer in woodworkers in the furniture industry. *Br Med J.* 1968;2(5605):587-596. <https://doi.org/10.1136/bmj.2.5605.587>
 87. Mofidi A, Tompa E, Kalcevic C, McLeod C. Occupational exposure to wood dust and the burden of nasopharynx and sinonasal cancer in Canada. *Int J Environ Res Public Health.* 2022;19(3):1144. <https://doi.org/10.3390/ijerph19031144>
 88. d'Errico A, Pasian S, Baratti A, et al. A case-control study on occupational risk factors for sino-nasal cancer. *Occup Environ Med.* 2009;66(7):448-455. <https://doi.org/10.1136/oem.2008.041277>
 89. Bonzini M, Battaglia P, Parassoni D, et al. Prevalence of occupational hazards in patients with different types of epithelial sinonasal cancers. *Rhinology.* 2013;51(1):31-36. <https://doi.org/10.4193/Rhino11.228>
 90. Slack R, Young C, Rushton L. Occupational cancer in Britain. Nasopharynx and sinonasal cancers. *Br J Cancer.* 2012;107(Suppl 1):S49-55. <https://doi.org/10.1038/bjc.2012.118>
 91. IARC Working Group on the Evaluation of Carcinogenic Risks to Humans. Tobacco smoke and involuntary smoking. *IARC Monogr Eval Carcinog Risks Hum.* 2004;83:1-1438.
 92. Brinton LA, Blot WJ, Becker JA, et al. A case-control study of cancers of the nasal cavity and paranasal sinuses. *Am J Epidemiol.* 1984;119(6):896-906. <https://doi.org/10.1093/oxfordjournals.aje.a113812>
 93. Elgart K, Faden DL. Sinonasal squamous cell carcinoma: etiology, pathogenesis, and the role of human papilloma virus. *Curr Otorhinolaryngol Rep.* 2020;8(2):111-119. <https://doi.org/10.1007/s40136-020-00279-6>
 94. Greiser EM, Greiser KH, Ahrens W, et al. Risk factors for nasal malignancies in German men: the South-German Nasal cancer study. *BMC Cancer.* 2012;12:506. <https://doi.org/10.1186/1471-2407-12-506>
 95. Syrjänen K, Syrjänen S. Detection of human papillomavirus in sinonasal papillomas: systematic review and meta-analysis. *Laryngoscope.* 2013;123(1):181-192. <https://doi.org/10.1002/lary.23688>
 96. Sahnane N, Ottini G, Turri-Zanoni M, et al. Comprehensive analysis of HPV infection, EGFR exon 20 mutations and LINE1 hypomethylation as risk factors for malignant transformation of sinonasal-inverted papilloma to squamous cell carcinoma: comprehensive analysis of HPV infection, EGFR exon 20 mutations and LINE1 hypomethylation. *Int J Cancer.* 2019;144(6):1313-1320. <https://doi.org/10.1002/ijc.31971>
 97. Ferrelli F, Di Bari M, Moya-Plana A, et al. Association between human papillomavirus infection and malignant transformation of sinonasal inverted papilloma: a systematic review and meta-analysis. *Am J Otolaryngol.* 2022;43(6):103614. <https://doi.org/10.1016/j.amjoto.2022.103614>
 98. Llorente JL, López F, Suárez C, Hermsen MA. Sinonasal carcinoma: clinical, pathological, genetic and therapeutic advances. *Nat Rev Clin Oncol.* 2014;11(8):460-472. <https://doi.org/10.1038/nrclinonc.2014.97>
 99. Turri-Zanoni M, Gravante G, Castelnuovo P. Molecular biomarkers in sinonasal cancers: new frontiers in diagnosis and treatment. *Curr Oncol Rep.* 2022;24(1):55-67. <https://doi.org/10.1007/s11912-021-01154-3>
 100. Perrone F, Oggioni M, Birindelli S, et al. TP53, p14ARF, p16INK4a and H-ras gene molecular analysis in intestinal-type adenocarcinoma of the nasal cavity and paranasal sinuses. *Int J Cancer.* 2003;105(2):196-203. <https://doi.org/10.1002/ijc.11062>
 101. Holmila R, Bornholdt J, Heikkilä P, et al. Mutations in TP53 tumor suppressor gene in wood dust-related sinonasal cancer. *Int J Cancer.* 2010;127(3):578-588. <https://doi.org/10.1002/ijc.25064>
 102. Bossi P, Perrone F, Miceli R, et al. Tp53 status as guide for the management of ethmoid sinus intestinal-type adenocarci-

- noma. *Oral Oncol.* 2013;49(5):413-419. <https://doi.org/10.1016/j.oraloncology.2012.12.011>
103. Takahashi Y, Bell D, Agarwal G, et al. Comprehensive assessment of prognostic markers for sinonasal squamous cell carcinoma. *Head Neck.* 2014;36(8):1094-1102. <https://doi.org/10.1002/hed.23423>
 104. García-Inclán C, López F, Pérez-Escuredo J, et al. EGFR status and KRAS/BRAF mutations in intestinal-type sinonasal adenocarcinomas. *Cell Oncol.* 2012;35(6):443-450. <https://doi.org/10.1007/s13402-012-0103-7>
 105. Franchi A, Fondi C, Paglierani M, Pepi M, Gallo O, Santucci M. Epidermal growth factor receptor expression and gene copy number in sinonasal intestinal type adenocarcinoma. *Oral Oncol.* 2009;45(9):835-838. <https://doi.org/10.1016/j.oraloncology.2008.12.005>
 106. Volpi L, Bignami M, Lepera D, et al. Endoscopic endonasal resection of adenoid cystic carcinoma of the sinonasal tract and skull base. *Laryngoscope.* 2019;129(5):1071-1077. <https://doi.org/10.1002/lary.27485>
 107. Bell D, Bell AH, Bondaruk J, Hanna EY, Weber RS. In-depth characterization of the salivary adenoid cystic carcinoma transcriptome with emphasis on dominant cell type. *Cancer.* 2016;122(10):1513-1522. <https://doi.org/10.1002/cncr.29959>
 108. Ferrarotto R, Mitani Y, Diao L, et al. Activating NOTCH1 mutations define a distinct subgroup of patients with adenoid cystic carcinoma who have poor prognosis, propensity to bone and liver metastasis, and potential responsiveness to Notch1 inhibitors. *J Clin Oncol.* 2017;35(3):352-360. <https://doi.org/10.1200/jco.2016.67.5264>
 109. Ho AS, Kannan K, Roy DM, et al. The mutational landscape of adenoid cystic carcinoma. *Nat Genet.* 2013;45(7):791-798. <https://doi.org/10.1038/ng.2643>
 110. Lopez DC, Wadley AE, London NR Jr. Emerging concepts in sinonasal tumor research. *Curr Opin Otolaryngol Head Neck Surg.* 2022;30(1):33-39. <https://doi.org/10.1097/moo.0000000000000776>
 111. Lechner M, Liu J, Lund VJ. Novel biomarkers in sinonasal cancers: from bench to bedside. *Curr Oncol Rep.* 2020;22(10):106. <https://doi.org/10.1007/s11912-020-00947-2>
 112. Classe M, Yao H, Mouawad R, et al. Integrated multi-omic analysis of esthesioneuroblastomas identifies two subgroups linked to cell ontogeny. *Cell Rep.* 2018;25(3):811.e5-821.e5. <https://doi.org/10.1016/j.celrep.2018.09.047>
 113. Balss J, Meyer J, Mueller W, Korshunov A, Hartmann C, von Deimling A. Analysis of the IDH1 codon 132 mutation in brain tumors. *Acta Neuropathol.* 2008;116(6):597-602. <https://doi.org/10.1007/s00401-008-0455-2>
 114. Marcucci G, Maharry K, Wu YZ, et al. IDH1 and IDH2 gene mutations identify novel molecular subsets within de novo cytogenetically normal acute myeloid leukemia: a cancer and leukemia group B study. *J Clin Oncol.* 2010;28(14):2348-2355.
 115. Mullard A. FDA approves first-in-class cancer metabolism drug. *Nat Rev Drug Discov.* 2017;16(9):593. <https://doi.org/10.1038/nrd.2017.174>
 116. Colombino M, Lissia A, Franco R, et al. Unexpected distribution of cKIT and BRAF mutations among southern Italian patients with sinonasal melanoma. *Dermatology.* 2013;226(3):279-284. <https://doi.org/10.1159/000350683>
 117. Hermsen MA, Riobello C, García-Marín R, et al. Translational genomics of sinonasal cancers. *Semin Cancer Biol.* 2020;61:101-109. <https://doi.org/10.1016/j.semcancer.2019.09.016>
 118. Li J, Kan H, Zhao L, Sun Z, Bai C. Immune checkpoint inhibitors in advanced or metastatic mucosal melanoma: a systematic review. *Ther Adv Med Oncol.* 2020;12:1758835920922028. <https://doi.org/10.1177/1758835920922028>
 119. Unsal AA, Chung SY, Unsal AB, Baredes S, Eloy JA. A population-based analysis of survival for sinonasal rhabdomyosarcoma. *Otolaryngol Head Neck Surg.* 2017;157(1):142-149. <https://doi.org/10.1177/0194599817696292>
 120. Rushton L, Hutchings SJ, Fortunato L, et al. Occupational cancer burden in Great Britain. *Br J Cancer.* 2012;107(Suppl 1):S3-S7. <https://doi.org/10.1038/bjc.2012.112>
 121. Pippard EC, Acheson ED. The mortality of boot and shoe makers, with special reference to cancer. *Scand J Work Environ Health.* 1985;11(4):249-255. <https://doi.org/10.5271/sjweh.2223>
 122. Colombino M, Paliogiannis P. BRAF mutations and dysregulation of the MAP kinase pathway associated to sinonasal mucosal melanomas. *J Clin Med.* 2019;8(10):1577. <https://doi.org/10.3390/jcm8101577>
 123. Turri-Zanoni M, Medicina D, Lombardi D, et al. Sinonasal mucosal melanoma: molecular profile and therapeutic implications from a series of 32 cases. *Head Neck.* 2013;35(8):1066-1077. <https://doi.org/10.1002/hed.23079>
 124. Zebary A, Jangard M, Omholt K, Ragnarsson-Olding B, Hansson J. KIT, NRAS and BRAF mutations in sinonasal mucosal melanoma: a study of 56 cases. *Br J Cancer.* 2013;109(3):559-564. <https://doi.org/10.1038/bjc.2013.373>
 125. Roxbury CR, Ishii M, Richmon JD, Blitz AM, Reh DD, Gallia GL. Endonasal endoscopic surgery in the management of sinonasal and anterior skull base malignancies. *Head Neck Pathol.* 2016;10(1):13-22. <https://doi.org/10.1007/s12105-016-0687-8>
 126. Chatelet F, Simon F, Bedarida V, et al. Surgical management of sinonasal cancers: a comprehensive review. *Cancers.* 2021;13(16):3995. <https://doi.org/10.3390/cancers13163995>
 127. Sato Y, Morita M, Takahashi HO, Watanabe N, Kirikae I. Combined surgery, radiotherapy, and regional chemotherapy in carcinoma of the paranasal sinuses. *Cancer.* 1970;25(3):571-579. [https://doi.org/10.1002/1097-0142\(197003\)25:3\(571::aid-cncr2820250312\)3.0.co;2-n](https://doi.org/10.1002/1097-0142(197003)25:3(571::aid-cncr2820250312)3.0.co;2-n)
 128. Knekt PP, Ah-See KW, vd Velden LA, Kerrebijn J. Adenocarcinoma of the ethmoidal sinus complex: surgical debulking and topical fluorouracil may be the optimal treatment. *Arch Otolaryngol Head Neck Surg.* 2001;127(2):141-146. <https://doi.org/10.1001/archotol.127.2.141>
 129. Samant S, Robbins KT, Vang M, Wan J, Robertson J. Intra-arterial cisplatin and concomitant radiation therapy followed by surgery for advanced paranasal sinus cancer. *Arch Otolaryngol Head Neck Surg.* 2004;130(8):948-955. <https://doi.org/10.1001/archotol.130.8.948>
 130. de Almeida JR, Su SY, Koutourousiou M, et al. Endonasal endoscopic surgery for squamous cell carcinoma of the sinonasal cavities and skull base: oncologic outcomes based on treatment strategy and tumor etiology: endonasal endoscopic surgery for SCC of the sinonasal cavities and skull base.

- Head Neck*. 2015;37(8):1163-1169. <https://doi.org/10.1002/hed.23731>
131. Patel SK, Husain Q, Kuperan AB, Eloy JA, Liu JK. Utility of a rotation-suction microdebrider for tumor removal in endoscopic endonasal skull base surgery. *J Clin Neurosci*. 2014;21(1):142-147. <https://doi.org/10.1016/j.jocn.2013.02.031>
 132. König M, Osnes T, Jepsen P, Meling TR. Craniofacial resection of malignant tumors of the anterior skull base: a case series and a systematic review. *Acta Neurochir*. 2018;160(12):2339-2348. <https://doi.org/10.1007/s00701-018-3716-4>
 133. Omura K, Asaka D, Nayak JV, Tanaka Y. Transseptal access with crossing multiple incisions for improved pedicle control and septum preservation: "how I do it". *Am J Rhinol Allergy*. 2017;31(2):139-141. <https://doi.org/10.2500/ajra.2017.31.4416>
 134. Tosun F, Yildizoğlu Ü, Polat B, Durmaz A. Types of endoscopic endonasal resections for sinonasal malignancies. *J Craniofac Surg*. 2014;25(2):425-428. <https://doi.org/10.1097/SCS.0000000000000455>
 135. Kılıç S, Kılıç SS, Baredes S, et al. Comparison of endoscopic and open resection of sinonasal squamous cell carcinoma: a propensity score-matched analysis of 652 patients: endoscopic vs open resection of sinonasal SCC. *Int Forum Allergy Rhinol*. 2018;8(3):421-434. <https://doi.org/10.1002/alr.22040>
 136. Landsberg R, Cavel O, Segev Y, Khafif A, Fliss DM. Attachment-oriented endoscopic surgical strategy for sinonasal inverted papilloma. *Am J Rhinol*. 2008;22(6):629-634. <https://doi.org/10.2500/ajr.2008.22.3243>
 137. Pagella F, Pusateri A, Giourgos G, Tinelli C, Matti E. Evolution in the treatment of sinonasal inverted papilloma: pedicle-oriented endoscopic surgery. *Am J Rhinol Allergy*. 2014;28(1):75-81. <https://doi.org/10.2500/ajra.2014.28.3985>
 138. Trent MS, Goshtasbi K, Hui L, et al. A systematic review of definitive treatment for inverted papilloma attachment site and associations with recurrence. *Otolaryngol Head Neck Surg*. 2022;167(3):425-433. <https://doi.org/10.1177/01945998211051975>
 139. Castelnovo P, Battaglia P, Locatelli D, Delù G, Sberze F, Bignami M. Endonasal micro-endoscopic treatment of malignant tumors of the paranasal sinuses and anterior skull base. *Oper Tech Otolaryngol Head Neck Surg*. 2006;17(3):152-167. <https://doi.org/10.1016/j.otot.2006.06.002>
 140. Nakamaru Y, Suzuki M, Kano S, et al. The role of endoscopic resection for selected patients with sinonasal squamous cell carcinoma. *Auris Nasus Larynx*. 2021;48(1):131-137. <https://doi.org/10.1016/j.anl.2020.06.014>
 141. Homma A, Nakamaru Y, Lund VJ, et al. Endonasal endoscopic surgery for sinonasal squamous cell carcinoma from an oncological perspective. *Auris Nasus Larynx*. 2021;48(1):41-49. <https://doi.org/10.1016/j.anl.2020.11.018>
 142. Goudakos JK, Blioskas S, Nikolaou A, Vlachtsis K, Karkos P, Markou KD. Endoscopic resection of sinonasal inverted papilloma: systematic review and meta-analysis. *Am J Rhinol Allergy*. 2018;32(3):167-174. <https://doi.org/10.1177/1945892418765004>
 143. Nguyen B, Blasco M, Svider PF, et al. Recurrence of ventral skull base lesions attributed to tumor seeding: a systematic review. *World Neurosurg*. 2019;124:e395-e403. <https://doi.org/10.1016/j.wneu.2018.12.104>
 144. Moore MG, Lin DT, Deschler DG, Wang JJ, Chan AW. Risk of incisional recurrence after midface and anterior skull base surgery in sinonasal malignancies. *Skull Base*. 2011;21(2):87-92. <https://doi.org/10.1055/s-0030-1266762>
 145. Miller TC, Simental AA, Perez M. Sinonasal adenoid cystic carcinoma seeding to the tracheostomy site. *Laryngoscope*. 2006;116(4):661-662. <https://doi.org/10.1097/01.mlg.0000201987.41904.6c>
 146. Yu Y, El-Sayed IH, McDermott MW, et al. Dural recurrence among esthesioneuroblastoma patients presenting with intracranial extension. *Laryngoscope*. 2018;128(10):2226-2233. <https://doi.org/10.1002/lary.27126>
 147. Kennedy D, Hwang P. *Rhinology - Diseases of the Nose, Sinuses, and Skull Base*. 1st ed. Thieme; 2012.
 148. Johnson J, Rosen C. *Bailey's Head and Neck Surgery - Otolaryngology*. 5th ed. Lippincott Williams & Wilkins; 2013.
 149. Flint P, Haughey B, Lund V, et al. *Cummings Otolaryngology Head and Neck Surgery*. 7th ed. Elsevier; 2020.
 150. Schutte HW, Heutink F, Wellenstein DJ, et al. Impact of time to diagnosis and treatment in head and neck cancer: a systematic review. *Otolaryngol Head Neck Surg*. 2020;162(4):446-457. <https://doi.org/10.1177/0194599820906387>
 151. Choi KY, Amit M, Tam S, et al. Clinical implication of diagnostic and histopathologic discrepancies in sinonasal malignancies. *Laryngoscope*. 2021;131(5):E1468-E1475. <https://doi.org/10.1002/lary.29102>
 152. Lee JY. Unilateral paranasal sinus diseases: analysis of the clinical characteristics, diagnosis, pathology, and computed tomography findings. *Acta Otolaryngol*. 2008;128(6):621-626. <https://doi.org/10.1080/00016480701663417>
 153. Han MW, Lee BJ, Jang YJ, Chung YS. Clinical value of office-based endoscopic incisional biopsy in diagnosis of nasal cavity masses. *Otolaryngol Head Neck Surg*. 2010;143(3):341-347. <https://doi.org/10.1016/j.otohns.2010.05.019>
 154. Tabae A, Hsu AK, Kacker A. Indications, technique, safety, and accuracy of office-based nasal endoscopy with biopsy for sinonasal neoplasm. *Int Forum Allergy Rhinol*. 2011;1(3):225-228. <https://doi.org/10.1002/alr.20035>
 155. Gomes P, Gomes A, Salvador P, Lombo C, Caselhos S, Fonseca R. Clinical assessment, diagnosis and management of patients with unilateral sinonasal disease. *Acta Otorrinolaringol Esp*. 2020;71(1):16-25. <https://doi.org/10.1016/j.otorri.2018.11.002>
 156. Segal N, Gluck O, Bavnik Y, Plakht Y, Yakirevitch A. The usefulness of preoperative biopsy in unilateral nasal masses. *Allergy Rhinol*. 2014;5(2):53-55. <https://doi.org/10.2500/ar.2014.5.0082>
 157. Paz Silva M, Pinto JM, Corey JP, Mhoon EE, Baroody FM, Naclerio RM. Diagnostic algorithm for unilateral sinus disease: a 15-year retrospective review. *Int Forum Allergy Rhinol*. 2015;5(7):590-596. <https://doi.org/10.1002/alr.21526>
 158. Amin M, Edge S, Greene FL, et al. *AJCC Cancer Staging Manual*. 8th ed. Springer International Publishing; 2017. Accessed May 1, 2023. <https://link.springer.com/book/9783319406176>
 159. Robin TP, Jones BL, Gordon OM, et al. A comprehensive comparative analysis of treatment modalities for sinonasal malignancies. *Cancer*. 2017;123(16):3040-3049. <https://doi.org/10.1002/cncr.30686>
 160. Cracchiolo JR, Patel K, Migliacci JC, et al. Factors associated with a primary surgical approach for sinonasal squamous cell

- carcinoma. *J Surg Oncol*. 2018;117(4):756-764. <https://doi.org/10.1002/jso.24923>
161. Jafari A, Shen SA, Qualliotine JR, Orosco RK, Califano JA, DeConde AS. Impact of margin status on survival after surgery for sinonasal squamous cell carcinoma. *Int Forum Allergy Rhinol*. 2019;9(10):1205-1211. <https://doi.org/10.1002/alr.22415>
 162. Head and Neck Cancers (Version 2.2022). Accessed June 2, 2022. https://www.nccn.org/professionals/physician_gls/pdf/head-and-neck.pdf
 163. Cantu G, Solero CL, Miceli R, et al. Anterior craniofacial resection for malignant paranasal tumors: a monoinstitutional experience of 366 cases. *Head Neck*. 2012;34(1):78-87. <https://doi.org/10.1002/hed.21685>
 164. Li R, Tian S, Zhu Y, Zhu W, Wang S. Management of orbital invasion in sinonasal squamous cell carcinoma: 15 years' experience. *Int Forum Allergy Rhinol*. 2020;10(2):243-255. <https://doi.org/10.1002/alr.22465>
 165. Turri-Zanoni M, Lamberton A, Margherini S, et al. Multidisciplinary treatment algorithm for the management of sinonasal cancers with orbital invasion: a retrospective study. *Head Neck*. 2019;41(8):2777-2788. <https://doi.org/10.1002/hed.25759>
 166. Sugawara T, Aoyagi M, Ogishima T, et al. Extended orbital exenteration for sinonasal malignancy with orbital apex extension: surgical technique and clinical analysis. *J Neurosurg*. 2015;123(1):52-58. <https://doi.org/10.3171/2014.9.JNS141256>
 167. Yoo GH, Hocwald E, Korkmaz H, et al. Assessment of carotid artery invasion in patients with head and neck cancer. *Laryngoscope*. 2000;110(3 Pt 1):386-390. <https://doi.org/10.1097/00005537-200003000-00010>
 168. Yousem DM, Hatabu H, Hurst RW, et al. Carotid artery invasion by head and neck masses: prediction with MR imaging. *Radiology*. 1995;195(3):715-720. <https://doi.org/10.1148/radiology.195.3.7754000>
 169. Zhang H, Sun X, Yu H, et al. Assessment of internal carotid artery invasion with the endoscopic endonasal approach: implications of a new grading system and security strategy. *J Craniofac Surg*. 2021;32(3):1006-1009. <https://doi.org/10.1097/SCS.00000000000007045>
 170. Kalani MYS, Kalb S, Martirosyan NL, et al. Cerebral revascularization and carotid artery resection at the skull base for treatment of advanced head and neck malignancies. *J Neurosurg*. 2013;118(3):637-642. <https://doi.org/10.3171/2012.9.JNS12332>
 171. Lawton MT, Spetzler RF. Internal carotid artery sacrifice for radical resection of skull base tumors. *Skull Base Surg*. 1996;6(2):119-123. <https://doi.org/10.1055/s-2008-1058903>
 172. Yang T, Tariq F, Chabot J, Madhok R, Sekhar LN. Cerebral revascularization for difficult skull base tumors: a contemporary series of 18 patients. *World Neurosurg*. 2014;82(5):660-671. <https://doi.org/10.1016/j.wneu.2013.02.028>
 173. Ferrari M, Zanoletti E, Taboni S, et al. Resection of the internal carotid artery in selected patients affected by cancer of the skull base. *Head Neck*. 2022;44(4):1030-1042. <https://doi.org/10.1002/hed.26967>
 174. Ganly I, Patel SG, Singh B, et al. Craniofacial resection for malignant paranasal sinus tumors: report of an International Collaborative Study. *Head Neck*. 2005;27(7):575-584. <https://doi.org/10.1002/hed.20165>
 175. Howard DJ, Lund VJ, Wei WI. Craniofacial resection for tumors of the nasal cavity and paranasal sinuses: a 25-year experience. *Head Neck*. 2006;28(10):867-873. <https://doi.org/10.1002/hed.20432>
 176. Lund VJ, Howard DJ, Wei WI, Cheesman AD. Craniofacial resection for tumors of the nasal cavity and paranasal sinuses—a 17-year experience. *Head Neck*. 1998;20(2):97-105. [https://doi.org/10.1002/\(sici\)1097-0347\(199803\)20:2<97::aid-hed1>3.0.co;2-y](https://doi.org/10.1002/(sici)1097-0347(199803)20:2<97::aid-hed1>3.0.co;2-y)
 177. Suarez C, Llorente JL, Fernandez De Leon R, Maseda E, Lopez A. Prognostic factors in sinonasal tumors involving the anterior skull base. *Head Neck*. 2004;26(2):136-144. <https://doi.org/10.1002/hed.10358>
 178. Feiz-Erfan I, Suki D, Hanna E, DeMonte F. Prognostic significance of transdural invasion of cranial base malignancies in patients undergoing craniofacial resection. *Neurosurgery*. 2007;61(6):1178-1185; discussion 1185. <https://doi.org/10.1227/01.neu.0000306095.53388.fl>
 179. Mehta GU, Passer JZ, Raza SM, et al. The neurosurgical management of sinonasal malignancies involving the anterior skull base: a 28-year experience at The MD Anderson Cancer Center. *J Neurosurg*. 2021;136(6):1583-1591. <https://doi.org/10.3171/2021.5.JNS21772>
 180. Patel SG, Singh B, Polluri A, et al. Craniofacial surgery for malignant skull base tumors: report of an international collaborative study. *Cancer*. 2003;98(6):1179-1187. <https://doi.org/10.1002/cncr.11630>
 181. Patel S, Singh B, Stambuk H, et al. Craniofacial surgery for esthesioneuroblastoma: report of an international collaborative study. *J Neurol Surg B*. 2012;73(03):208-220. <https://doi.org/10.1055/s-0032-1311754>
 182. Abdelmeguid AS, Raza SM, Su SY, et al. Endoscopic resection of sinonasal malignancies. *Head Neck*. 2020;42(4):645-652. <https://doi.org/10.1002/hed.26047>
 183. Kim YS, Moon KS, Kim GW, et al. Role of craniofacial resection for malignant tumors involving the anterior skull base: surgical experience in a single institution. *Brain Tumor Res Treat*. 2015;3(2):81-88. <https://doi.org/10.14791/btrt.2015.3.2.81>
 184. Mattavelli D, Ferrari M, Bolzoni Villaret A, et al. Transnasal endoscopic surgery in selected nasal-ethmoidal cancer with suspected brain invasion: indications, technique, and outcomes. *Head Neck*. 2019;41(6):1854-1862. <https://doi.org/10.1002/hed.25621>
 185. Mine S, Saeki N, Horiguchi K, Hanazawa T, Okamoto Y. Craniofacial resection for sinonasal malignant tumors: statistical analysis of surgical outcome over 17 years at a single institution. *Skull Base*. 2011;21(4):243-248. <https://doi.org/10.1055/s-0031-1280686>
 186. Nishio N, Fujimoto Y, Fujii M, et al. Craniofacial resection for T4 maxillary sinus carcinoma: managing cases with involvement of the skull base. *Otolaryngol Head Neck Surg*. 2015;153(2):231-238. <https://doi.org/10.1177/0194599815586770>
 187. Saito K, Fukuta K, Takahashi M, Tachibana E, Yoshida J. Management of the cavernous sinus in en bloc resections of malignant skull base tumors. *Head Neck*. 1999;21(8):734-742. [https://doi.org/10.1002/\(sici\)1097-0347\(199912\)21:8<734::aid-hed9>3.3.co;2-o](https://doi.org/10.1002/(sici)1097-0347(199912)21:8<734::aid-hed9>3.3.co;2-o)
 188. Couldwell WT, MacDonald JD, Taussky P. Complete resection of the cavernous sinus—indications and technique. *World*

- Neurosurg.* 2014;82(6):1264-1270. <https://doi.org/10.1016/j.wneu.2013.08.026>
189. Yafit D, Duek I, Abu-Ghanem S, et al. Surgical approaches for infratemporal fossa tumor resection: fifteen years' experience of a single center. *Head Neck.* 2019;41(11):3755-3763. <https://doi.org/10.1002/hed.25906>
 190. Givi B, Liu J, Bilsky M, et al. Outcome of resection of infratemporal fossa tumors. *Head Neck.* 2013;35(11):1567-1572. <https://doi.org/10.1002/hed.23186>
 191. He Y, Yang H, Sun J, Zhang C, Zhu H, Liu Z. Prognostic factors in pterygopalatine and infratemporal fossa malignant tumours: a single institution experience. *J Craniomaxillofac Surg.* 2015;43(4):537-544. <https://doi.org/10.1016/j.jcms.2015.02.001>
 192. Hentschel SJ, Vora Y, Suki D, Hanna EY, DeMonte F. Malignant tumors of the anterolateral skull base. *Neurosurgery.* 2010;66(1):102-112; discussion 112. <https://doi.org/10.1227/01.NEU.0000362033.38035.25>
 193. König M, Osnes T, Bratland Å, Meling TR. Squamous cell carcinoma of the paranasal sinuses: a single center experience. *J Neurol Surg B Skull Base.* 2020;81(6):664-672. <https://doi.org/10.1055/s-0039-1694967>
 194. Kano S, Hayashi R, Homma A, et al. Effect of local extension sites on survival in locally advanced maxillary sinus cancer. *Head Neck.* 2014;36(11):1567-1572. <https://doi.org/10.1002/hed.23483>
 195. Vogl T, Bisdas S. Lymph node staging. *Top Magn Reson Imaging.* 2007;18(4):303-316.
 196. Pfister DG, Spencer S, Adelstein D, et al. Head and neck cancers, version 2.2020, NCCN clinical practice guidelines in oncology. *J Natl Compr Canc Netw.* 2020;18(7):873-898. <https://doi.org/10.6004/jnccn.2020.0031>
 197. Lamarre ED, Batra PS, Lorenz RR, et al. Role of positron emission tomography in management of sinonasal neoplasms - a single institution's experience. *Am J Otolaryngol Head Neck Med Surg.* 2012;33(3):289-295. <https://doi.org/10.1016/j.amjoto.2011.08.001>
 198. Maurer A, Meerwein CM, Soyka MB, et al. Whole-body hybrid positron emission tomography imaging yields clinically relevant information in the staging and restaging of sinonasal tumors. *Head Neck.* 2021;43(11):3572-3585. <https://doi.org/10.1002/hed.26856>
 199. Bossi P, Farina D, Gatta G, Lombardi D, Nicolai P, Orlandi E. Paranasal sinus cancer. *Crit Rev Oncol Hematol.* 2016;98:45-61. <https://doi.org/10.1016/j.critrevonc.2015.09.009>
 200. Felix-Ravelo M, Bey A, Arous F, Paris-Grandpierre S, Jankowski R, Nguyen DT. Relationship between ¹⁸F-FDG-PET and different types of sinonasal malignancies. *Acta Otolaryngol.* 2017;137(2):191-195. <https://doi.org/10.1080/00016489.2016.1219917>
 201. Gangl K, Nemeš S, Altörjai G, Pammer J, Grasl MC, Erovic BM. Prognostic survival value of retropharyngeal lymph node involvement in sinonasal tumors: a retrospective, descriptive, and exploratory study. *Head Neck.* 2017;39(7):1421-1427. <https://doi.org/10.1002/hed.24782>
 202. Kosugi Y, Suzuki M, Fujimaki M, et al. Radiologic criteria of retropharyngeal lymph node metastasis in maxillary sinus cancer. *Radiat Oncol.* 2021;16(1):190. <https://doi.org/10.1186/s13014-021-01917-z>
 203. Chweya CM, Low CM, Van Gompel JJ, Van Abel KM, Stokken JK, Choby G. Population-based analysis on the effect of nodal and distant metastases in sinonasal adenocarcinoma. *Head Neck.* 2021;43(1):128-136. <https://doi.org/10.1002/hed.26457>
 204. Marinelli JP, Van Gompel JJ, Link MJ, et al. Volumetric analysis of olfactory neuroblastoma skull base laterality and implications on neck disease. *Laryngoscope.* 2018;128(4):864-870. <https://doi.org/10.1002/lary.26843>
 205. Watarai J, Seino Y, Kobayashi M, Shindo M, Kato T. CT of retropharyngeal lymph node metastasis from maxillary carcinoma. *Acta Radiol.* 1993;34(5):492-495.
 206. Howell MC, Branstetter BF IV, Snyderman CH. Patterns of regional spread for esthesioneuroblastoma. *Am J Neuroradiol.* 2011;32(5):929-933. <https://doi.org/10.3174/ajnr.A2401>
 207. Weber AL, Stanton AC. Malignant tumors of the paranasal sinuses: radiologic, clinical, and histopathologic evaluation of 200 cases. *Head Neck Surg.* 1984;6(3):761-776.
 208. Abraham J. Imaging for head and neck cancer. *Surg Oncol Clin North Am.* 2015;24(3):455-471. <https://doi.org/10.1016/j.soc.2015.03.012>
 209. Rankin SC. Imaging of malignant sinus tumours. *Imaging.* 2003;15(3):127-140. <https://doi.org/10.1259/img.15.3.150127>
 210. Abdelmeguid AS, Bell D, Hanna EY. Sinonasal undifferentiated carcinoma. *Curr Oncol Rep.* 2019;21(3):26. <https://doi.org/10.1007/s11912-019-0776-4>
 211. Antoniou AJ, Marcus C, Subramaniam RM. Value of imaging in head and neck tumors. *Surg Oncol Clin N Am.* 2014;23(4):685-707. <https://doi.org/10.1016/j.soc.2014.07.001>
 212. Haerle SK, Soyka MB, Fischer DR, et al. The value of 18F-FDG-PET/CT imaging for sinonasal malignant melanoma. *Eur Arch Otorhinolaryngol.* 2012;269(1):127-133. <https://doi.org/10.1007/s00405-011-1664-1>
 213. Gilain L, Houette A, Montalban A, Mom T, Saroul N. Mucosal melanoma of the nasal cavity and paranasal sinuses. *Eur Ann Otorhinolaryngol Head Neck Dis.* 2014;131(6):365-369. <https://doi.org/10.1016/j.anorl.2013.11.004>
 214. Dumont B, Lemelle L, Cordero C, et al. Esthesioneuroblastoma in children, adolescents and young adults. *Bull Cancer.* 2020;107(9):934-945. <https://doi.org/10.1016/j.bulcan.2020.06.002>
 215. Jegoux F, Metreau A, Louvel G, Bedfert C. Paranasal sinus cancer. *Eur Ann Otorhinolaryngol Head Neck Dis.* 2013;130(6):327-335. <https://doi.org/10.1016/j.anorl.2012.07.007>
 216. Gil Z, Even-Sapir E, Margalit N, Fliss DM. Integrated PET/CT system for staging and surveillance of skull base tumors. *Head Neck.* 2007;29(6):537-545. <https://doi.org/10.1002/hed.20545>
 217. Meerwein CM, Maurer A, Stolzmann P, et al. Hybrid positron emission tomography imaging for initial staging of sinonasal tumors: total lesion glycolysis as prognosticator of treatment response. *Head Neck.* 2021;43(1):238-246. <https://doi.org/10.1002/hed.26476>
 218. Meerwein CM, Hullner M, Braun R, Soyka MB, Morand GB, Holzmann D. Current concepts in advanced sinonasal mucosal melanoma: a single institution experience. *Eur Arch Otorhinolaryngol.* 2019;276(8):2259-2265. <https://doi.org/10.1007/s00405-019-05458-w>
 219. Virarkar M, Saleh M, Ramani NS, Morani AC, Bhosale P. Imaging spectrum of NUT carcinomas. *Clin Imaging.*

- 2020;67:198-206. <https://doi.org/10.1016/j.clinimag.2020.07.025>
220. Ferrari M, Migliorati S, Tomasoni M, et al. Sinonasal cancer encroaching the orbit: ablation or preservation? *Oral Oncol.* 2021;114:105185. <https://doi.org/10.1016/j.oraloncology.2021.105185>
 221. Wild D, Eyrich GK, Ciernik IF, Stoeckli SJ, Schuknecht B, Goerres GW. In-line (18)F-fluorodeoxyglucose positron emission tomography with computed tomography (PET/CT) in patients with carcinoma of the sinus/nasal area and orbit. *J Craniomaxillofac Surg.* 2006;34(1):9-16.
 222. Ramakrishnan VR, Lee JY, O'Malley BW Jr, Palmer JN, Chiu AG. 18-FDG-PET in the initial staging of sinonasal malignancy. *Laryngoscope.* 2013;123(12):2962-2966. <https://doi.org/10.1002/lary.24317>
 223. Ozturk K, Gencturk M, Caicedo-Granados E, Li F, Cayci Z. Utility of FDG PET/CT in the characterization of sinonasal neoplasms: analysis of standardized uptake value parameters. *AJR Am J Roentgenol.* 2018;211(6):1354-1360. <https://doi.org/10.2214/AJR.18.19501>
 224. Zlochower AB, Steinklein JM. Doing great with DOTATATE: update on GA-68 DOTATATE positron emission tomography/computed tomography and magnetic resonance imaging for evaluation of sinonasal tumors. *Top Magn Reson Imaging.* 2021;30(3):151-158. <https://doi.org/10.1097/rmr.0000000000000289>
 225. Hesel JC, Bardales RH, Mukunyadzi P. Fine-needle aspiration biopsy cytology of malignant neoplasms of the sinonasal tract: a review of 22 primary and metastatic tumors. *Cancer.* 2003;99(2):105-112. <https://doi.org/10.1002/cncr.10956>
 226. He LJ, Xie C, Li Y, et al. Ultrasound-guided fine needle aspiration of retropharyngeal lymph nodes after radiotherapy for nasopharyngeal carcinoma: a novel technique for accurate diagnosis. *Cancer Commun.* 2018;38(1):1-8. <https://doi.org/10.1186/s40880-018-0286-z>
 227. Li JJ, He LJ, Luo GY, et al. Fine-needle aspiration of a retropharyngeal lymph node guided by endoscopic ultrasonography. *Endoscopy.* 2015;47(Suppl. 1):E449-E450. <https://doi.org/10.1055/s-0034-1392652>
 228. Dagan R, Bryant CM, Mendenhall WM, et al. Isolated leptomeningeal progression from sinonasal carcinomas: implications for staging workup and treatment. *Head Neck.* 2019;41(8):2647-2654. <https://doi.org/10.1002/hed.25741>
 229. Ahn PH, Mitra N, Alonso-Basanta M, et al. Nodal metastasis and elective nodal level treatment in sinonasal small-cell and sinonasal undifferentiated carcinoma: a surveillance, epidemiology and end results analysis. *Br J Radiol.* 2016;89(1058):20150488. <https://doi.org/10.1259/bjr.20150488>
 230. Dubal PM, Bhojwani A, Patel TD, et al. Squamous cell carcinoma of the maxillary sinus: a population-based analysis. *Laryngoscope.* 2016;126(2):399-404. <https://doi.org/10.1002/lary.25601>
 231. Ferrari M, Taboni S, Carobbio ALC, et al. Sinonasal squamous cell carcinoma, a narrative reappraisal of the current evidence. *Cancers.* 2021;13(11):2835. <https://doi.org/10.3390/cancers13112835>
 232. Moreno MA, Roberts DB, Kupferman ME, et al. Mucosal melanoma of the nose and paranasal sinuses, a contemporary experience from the M. D. Anderson Cancer Center. *Cancer.* 2010;116(9):2215-2223. <https://doi.org/10.1002/cncr.24976>
 233. Lewis JS, Castro EB. Cancer of the nasal cavity and paranasal sinuses. *J Laryngol Otol.* 1972;86(3):255-262. <https://doi.org/10.1017/s0022215100075216>
 234. Ketcham AS, Wilkins RH, Vanburen JM, Smith RR. A combined intracranial facial approach to the paranasal sinuses. *Am J Surg.* 1963;106:698-703. [https://doi.org/10.1016/0002-9610\(63\)90387-8](https://doi.org/10.1016/0002-9610(63)90387-8)
 235. Stammberger H. Endoscopic endonasal surgery—concepts in treatment of recurring rhinosinusitis. Part II. Surgical technique. *Otolaryngol Head Neck Surg.* 1986;94(2):147-156. <https://doi.org/10.1177/019459988609400203>
 236. Guntinas-Lichius O, Kreppel MP, Stuetzer H, Semrau R, Eckel HE, Mueller RP. Single modality and multimodality treatment of nasal and paranasal sinuses cancer: a single institution experience of 229 patients. *Eur J Surg Oncol.* 2007;33(2):222-228. <https://doi.org/10.1016/j.ejso.2006.10.033>
 237. Casler JD, Doolittle AM, Mair EA. Endoscopic surgery of the anterior skull base. *Laryngoscope.* 2005;115(1):16-24. <https://doi.org/10.1097/01.mlg.0000150681.68355.85>
 238. Goffart Y, Jorissen M, Daele J, et al. Minimally invasive endoscopic management of malignant sinonasal tumours. *Acta Otorhinolaryngol Belg.* 2000;54(2):221-232.
 239. Levine PA. Would Dr. Ogura approve of endoscopic resection of esthesioneuroblastomas? An analysis of endoscopic resection data versus that of craniofacial resection. *Laryngoscope.* 2009;119(1):3-7. <https://doi.org/10.1002/lary.20047>
 240. Snyderman CH, Carrau RL, Kassam AB, et al. Endoscopic skull base surgery: principles of endonasal oncological surgery. *J Surg Oncol.* 2008;97(8):658-664. <https://doi.org/10.1002/jso.21020>
 241. Torabi SJ, Spock T, Cardoso B, et al. Margins in sinonasal squamous cell carcinoma: predictors, outcomes, and the endoscopic approach. *Laryngoscope.* 2020;130(6):E388-E396. <https://doi.org/10.1002/lary.28315>
 242. Wellman BJ, Traynelis VC, McCulloch TM, Funk GF, Menezes AH, Hoffman HT. Midline anterior craniofacial approach for malignancy: results of en bloc versus piecemeal resections. *Skull Base Surg.* 1999;9(1):41-46. <https://doi.org/10.1055/s-2008-1058171>
 243. Harvey RJ, Nalavenkata S, Sacks R, et al. Survival outcomes for stage-matched endoscopic and open resection of olfactory neuroblastoma. *Head Neck.* 2017;39(12):2425-2432. <https://doi.org/10.1002/hed.24912>
 244. Hadad G, Bassagasteguy L, Carrau RL, et al. A novel reconstructive technique after endoscopic expanded endonasal approaches: vascular pedicle nasoseptal flap. *Laryngoscope.* 2006;116(10):1882-1886. <https://doi.org/10.1097/01.mlg.0000234933.37779.e4>
 245. Sigler AC, D'Anza B, Lobo BC, Woodard TD, Recinos PF, Sindwani R. Endoscopic skull base reconstruction: an evolution of materials and methods. *Otolaryngol Clin North Am.* 2017;50(3):643-653. <https://doi.org/10.1016/j.otc.2017.01.015>
 246. Rimmer J, Lund VJ, Beale T, Wei WI, Howard D. Olfactory neuroblastoma: a 35-year experience and suggested follow-up protocol. *Laryngoscope.* 2014;124(7):1542-1549. <https://doi.org/10.1002/lary.24562>

247. Karligkiotis A, Lepera D, Volpi L, et al. Survival outcomes after endoscopic resection for sinonasal squamous cell carcinoma arising on inverted papilloma. *Head Neck*. 2016;38(11):1604-1614. <https://doi.org/10.1002/hed.24481>
248. Wertz A, Hollon T, Marentette LJ, Sullivan SE, McHugh JB, McKean EL. Surgical treatment of olfactory neuroblastoma: major complication rates, progression free and overall survival. *J Neurol Surg B Skull Base*. 2018;79(2):151-155. <https://doi.org/10.1055/s-0037-1605593>
249. Tajudeen BA, Arshi A, Suh JD, et al. Esthesioneuroblastoma: an update on the UCLA experience, 2002-2013. *J Neurol Surg B Skull Base*. 2015;76(1):43-49. <https://doi.org/10.1055/s-0034-1390011>
250. Song CM, Won TB, Lee CH, Kim DY, Rhee CS. Treatment modalities and outcomes of olfactory neuroblastoma. *Laryngoscope*. 2012;122(11):2389-2395. <https://doi.org/10.1002/lary.23641>
251. Petruzzelli GJ, Howell JB, Pederson A, et al. Multidisciplinary treatment of olfactory neuroblastoma: patterns of failure and management of recurrence. *Am J Otolaryngol*. 2015;36(4):547-553. <https://doi.org/10.1016/j.amjoto.2015.02.008>
252. Mays AC, Bell D, Ferrarotto R, et al. Early stage olfactory neuroblastoma and the impact of resecting dura and olfactory bulb. *Laryngoscope*. 2018;128(6):1274-1280. <https://doi.org/10.1002/lary.26908>
253. Kim N, Lee CG, Kim EH, et al. Patterns of failures after surgical resection in olfactory neuroblastoma. *J Neurooncol*. 2019;141(2):459-466. <https://doi.org/10.1007/s11060-018-03056-0>
254. Barinsky GL, Azmy MC, Kilic S, et al. Comparison of open and endoscopic approaches in the resection of esthesioneuroblastoma. *Ann Otol Rhinol Laryngol*. 2021;130(2):136-141. <https://doi.org/10.1177/0003489420939582>
255. Devaiah AK, Andreoli MT. Treatment of esthesioneuroblastoma: a 16-year meta-analysis of 361 patients. *Laryngoscope*. 2009;119(7):1412-1416. <https://doi.org/10.1002/lary.20280>
256. Morgenstern PF, Ivasyk I, Anand VK, Schwartz TH. The evolution of endoscopic skull base surgery outcomes: defining the edge of the envelope. *World Neurosurg*. 2019;124:491-501. <https://doi.org/10.1016/j.wneu.2019.01.119>
257. Komotar RJ, Starke RM, Raper DMS, Anand VK, Schwartz TH. Endoscopic endonasal versus open repair of anterior skull base CSF leak, meningocele, and encephalocele: a systematic review of outcomes. *J Neurol Surg A Cent Eur Neurosurg*. 2013;74(4):239-250. <https://doi.org/10.1055/s-0032-1325636>
258. Fu TS, Monteiro E, Muhanna N, Goldstein DP, de Almeida JR. Comparison of outcomes for open versus endoscopic approaches for olfactory neuroblastoma: a systematic review and individual participant data meta-analysis. *Head Neck*. 2016;38(Suppl. 1):E2306-2316. <https://doi.org/10.1002/hed.24233>
259. Meccariello G, Deganello A, Choussy O, et al. Endoscopic nasal versus open approach for the management of sinonasal adenocarcinoma: a pooled-analysis of 1826 patients. *Head Neck*. 2016;38(Suppl. 1):E2267-2274. <https://doi.org/10.1002/hed.24182>
260. Mortuaire G, Leroy X, Vandenhende-Szymanski C, Chevalier D, Thisse AS. Comparison of endoscopic and external resections for sinonasal intestinal-type adenocarcinoma. *Eur Arch Otorhinolaryngol*. 2016;273(12):4343-4350. <https://doi.org/10.1007/s00405-016-4181-4>
261. Vergez S, Martin-Dupont N, Lepage B, De Bonnacaze G, Decotte A, Serrano E. Endoscopic vs transfacial resection of sinonasal adenocarcinomas. *Otolaryngol Head Neck Surg*. 2012;146(5):848-853. <https://doi.org/10.1177/0194599811434903>
262. Nicolai P, Villaret AB, Bottazzoli M, Rossi E, Valsecchi MG. Ethmoid adenocarcinoma—from craniofacial to endoscopic resections: a single-institution experience over 25 years. *Otolaryngol Head Neck Surg*. 2011;145(2):330-337. <https://doi.org/10.1177/0194599811403873>
263. Huber GF, Gengler C, Walter C, Roth T, Huber A, Holzmann D. Adenocarcinoma of the nasal cavity and paranasal sinuses: single-institution review of diagnosis, histology, and outcome. *J Otolaryngol Head Neck Surg*. 2011;40(1):34-39.
264. Grosjean R, Gallet P, Baumann C, Jankowski R. Transfacial versus endoscopic approach in the treatment of woodworker's nasal adenocarcinomas. *Head Neck*. 2015;37(3):347-356. <https://doi.org/10.1002/hed.23601>
265. Gore MR. Treatment, outcomes, and demographics in sinonasal sarcoma: a systematic review of the literature. *BMC Ear Nose Throat Disord*. 2018;18:4. <https://doi.org/10.1186/s12901-018-0052-5>
266. Guo L, Liu J, Sun X, Wang D. Sinonasal tract chondrosarcoma: 18-year experience at a single institution. *Auris Nasus Larynx*. 2014;41(3):290-293. <https://doi.org/10.1016/j.anl.2013.10.011>
267. Cao W, Guan B, Yu A, et al. Treatment and outcomes of endoscopic surgery and traditional open resection in sinonasal mucosal melanoma. *Acta Otolaryngol*. 2017;137(8):862-867. <https://doi.org/10.1080/00016489.2017.1300939>
268. Yin G, Guo W, Chen X, Huang Z. Prognosis of endoscopic surgery and traditional open resection in mucosal melanoma of the nasal cavity and paranasal sinus. *Melanoma Res*. 2019;29(1):47-52. <https://doi.org/10.1097/CMR.0000000000000516>
269. Won TB, Choi KY, Rhee CS, et al. Treatment outcomes of sinonasal malignant melanoma: a Korean multicenter study. *Int Forum Allergy Rhinol*. 2015;5(10):950-959. <https://doi.org/10.1002/alr.21558>
270. Swegal W, Koyfman S, Scharpf J, et al. Endoscopic and open surgical approaches to locally advanced sinonasal melanoma: comparing the therapeutic benefits. *JAMA Otolaryngol Head Neck Surg*. 2014;140(9):840-845. <https://doi.org/10.1001/jamaoto.2014.1321>
271. Sayed Z, Migliacci JC, Cracchiolo JR, et al. Association of surgical approach and margin status with oncologic outcomes following gross total resection for sinonasal melanoma. *JAMA Otolaryngol Head Neck Surg*. 2017;143(12):1220-1227. <https://doi.org/10.1001/jamaoto.2017.2011>
272. Miglani A, Patel SH, Kosiorek HE, Hinni ML, Hayden RE, Lal D. Endoscopic resection of sinonasal mucosal melanoma has comparable outcomes to open approaches. *Am J Rhinol Allergy*. 2017;31(3):200-204. <https://doi.org/10.2500/ajra.2017.31.4435>
273. Meng XJ, Ao HF, Huang WT, et al. Impact of different surgical and postoperative adjuvant treatment modalities on survival of sinonasal malignant melanoma. *BMC Cancer*. 2014;14:608. <https://doi.org/10.1186/1471-2407-14-608>

274. Lundberg M, Haapaniemi A, Hagstrom J, et al. Similar survival outcome after endoscopic and open approaches for sinonasal mucosal melanoma. *Rhinology*. 2019;57(2):132-138. <https://doi.org/10.4193/Rhin18.123>
275. Lund VJ, Wei WI. Endoscopic surgery for malignant sinonasal tumours: an eighteen year experience. *Rhinology*. 2015;53(3):204-211. <https://doi.org/10.4193/Rhino14.318>
276. Ledderose GJ, Leunig A. Surgical management of recurrent sinonasal mucosal melanoma: endoscopic or transfacial resection. *Eur Arch Otorhinolaryngol*. 2015;272(2):351-356. <https://doi.org/10.1007/s00405-014-3119-y>
277. Almutuawa DM, Strohl MP, Gruss C, et al. Outcomes of sinonasal mucosal melanomas with endoscopic and open resection: a retrospective cohort study. *J Neurooncol*. 2020;150(3):387-392. <https://doi.org/10.1007/s11060-020-03449-0>
278. Farber NI, Bavier RD, Crippen MM, Vatsa N, Hsueh WD, Eloy JA. Comparing endoscopic resection and open resection for management of sinonasal mucosal melanoma. *Int Forum Allergy Rhinol*. 2019;9(12):1492-1498. <https://doi.org/10.1002/alr.22422>
279. Hur K, Zhang P, Yu A, Kim-Orden N, Kysh L, Wrobel B. Open versus endoscopic approach for sinonasal melanoma: a systematic review and meta-analysis. *Am J Rhinol Allergy*. 2019;33(2):162-169. <https://doi.org/10.1177/1945892418822637>
280. Suh JD, Ramakrishnan VR, Chi JJ, Palmer JN, Chiu AG. Outcomes and complications of endoscopic approaches for malignancies of the paranasal sinuses and anterior skull base. *Ann Otol Rhinol Laryngol*. 2013;122(1):54-59. <https://doi.org/10.1177/000348941312200110>
281. Saedi B, Aghili M, Motiee M, Valadkhani S, Niazi AB, Safavi A. Surgical outcomes of malignant sinonasal tumours: open versus endoscopic surgical approaches. *J Laryngol Otol*. 2014;128(9):784-790. <https://doi.org/10.1017/S0022215114001583>
282. Rutland JW, Goldrich D, Loewenstern J, et al. The role of advanced endoscopic resection of diverse skull base malignancies: technological analysis during an 8-year single institutional experience. *J Neurol Surg B Skull Base*. 2021;82(4):417-424. <https://doi.org/10.1055/s-0040-1714115>
283. Parida PK, Gupta AK. Medial maxillectomy: a comparative study as a surgical procedure. *Otolaryngol Head Neck Surg*. 2008;138(2):192-199. <https://doi.org/10.1016/j.otohns.2007.10.018>
284. Nicolai P, Castelnuovo P, Bolzoni Villaret A. Endoscopic resection of sinonasal malignancies. *Curr Oncol Rep*. 2011;13(2):138-144. <https://doi.org/10.1007/s11912-011-0151-6>
285. Naunheim MR, Goyal N, Dedmon MM, et al. An algorithm for surgical approach to the anterior skull base. *J Neurol Surg B Skull Base*. 2016;77(4):364-370. <https://doi.org/10.1055/s-0036-1580598>
286. Krischek B, Carvalho FG, Godoy BL, Kiehl R, Zadeh G, Gentili F. From craniofacial resection to endonasal endoscopic removal of malignant tumors of the anterior skull base. *World Neurosurg*. 2014;82(6, Suppl.):S59-65. <https://doi.org/10.1016/j.wneu.2014.07.026>
287. Kim BJ, Kim DW, Kim SW, et al. Endoscopic versus traditional craniofacial resection for patients with sinonasal tumors involving the anterior skull base. *Clin Exp Otorhinolaryngol*. 2008;1(3):148-153. <https://doi.org/10.3342/ceo.2008.1.3.148>
288. Husain Q, Joshi RR, Cracchiolo JR, et al. Surgical management patterns of sinonasal malignancy: a population-based study. *J Neurol Surg B Skull Base*. 2019;80(4):371-379. <https://doi.org/10.1055/s-0038-1675233>
289. Hanna E, DeMonte F, Ibrahim S, Roberts D, Levine N, Kupferman M. Endoscopic resection of sinonasal cancers with and without craniotomy: oncologic results. *Arch Otolaryngol Head Neck Surg*. 2009;135(12):1219-1224. <https://doi.org/10.1001/archoto.2009.173>
290. Hagemann J, Roesner J, Helling S, et al. Long-term outcome for open and endoscopically resected sinonasal tumors. *Otolaryngol Head Neck Surg*. 2019;160(5):862-869. <https://doi.org/10.1177/0194599818815881>
291. Fu TS, Monteiro E, Witterick I, et al. Costs and perioperative outcomes associated with open versus endoscopic resection of sinonasal malignancies with skull base involvement. *J Neurol Surg B Skull Base*. 2017;78(5):430-440. <https://doi.org/10.1055/s-0037-1603907>
292. Farquhar D, Kim L, Worrall D, et al. Propensity score analysis of endoscopic and open approaches to malignant paranasal and anterior skull base tumor outcomes. *Laryngoscope*. 2016;126(8):1724-1729. <https://doi.org/10.1002/lary.25885>
293. Castelnuovo P, Turri-Zanoni M, Battaglia P, Antognoni P, Bossi P, Locatelli D. Sinonasal malignancies of anterior skull base: histology-driven treatment strategies. *Otolaryngol Clin North Am*. 2016;49(1):183-200. <https://doi.org/10.1016/j.otc.2015.09.012>
294. Caballero-García J, Cuétara Lugo EB, Lence-Anta JJ, González Fernández N, Hidalgo-González A, Kindelán-Agustín G. Endoscopic versus open surgery in patients with malignant sinonasal tumours and brain invasion. A case series study. *Neurocirugía*. 2022;33(4):165-175. <https://doi.org/10.1016/j.neucie.2021.04.005>
295. Buchmann L, Larsen C, Pollack A, Tawfik O, Sykes K, Hoover LA. Endoscopic techniques in resection of anterior skull base/paranasal sinus malignancies. *Laryngoscope*. 2006;116(10):1749-1754.
296. Batra PS, Citardi MJ. Endoscopic management of sinonasal malignancy. *Otolaryngol Clin North Am*. 2006;39(3):619-637, x-xi. <https://doi.org/10.1016/j.otc.2006.01.012>
297. Arnold A, Ziglinas P, Ochs K, et al. Therapy options and long-term results of sinonasal malignancies. *Oral Oncol*. 2012;48(10):1031-1037. <https://doi.org/10.1016/j.oraloncology.2012.04.005>
298. Jiang S, Fan R, Zhang H, Jiang W, Xie Z. Outcomes of endoscopic and open resection of sinonasal malignancies: a systematic review and meta-analysis. *Braz J Otorhinolaryngol*. 2022;88(Suppl. 5):S19-S31. <https://doi.org/10.1016/j.bjorl.2021.06.004>
299. Lenze NR, Quinsey C, Sasaki-Adams D, et al. Comparative outcomes by surgical approach in patients with malignant sinonasal disease. *J Neurol Surg B Skull Base*. 2021;83(Suppl. 2):e353-e359. <https://doi.org/10.1055/s-0041-1729978>
300. Durucu C, Baglam T, Karatas E, Mumbuc S, Kanlikama M. Surgical treatment of inverted papilloma. *J Craniofac Surg*. 2009;20(6):1985-1988. <https://doi.org/10.1097/SCS.0b013e3181bd2dc4>

301. Kim YM, Kim HS, Park JY, Koo BS, Park YH, Rha KS. External vs endoscopic approach for inverted papilloma of the sino-nasal cavities: a retrospective study of 136 cases. *Acta Otolaryngol.* 2008;128(8):909-914. <https://doi.org/10.1080/00016480701774982>
302. Liu Q, Yu H, Minovi A, et al. Management of maxillary sinus inverted papilloma via transnasal endoscopic anterior and medial maxillectomy. *ORL J Otorhinolaryngol Relat Spec.* 2010;72(5):247-251. <https://doi.org/10.1159/000317033>
303. Dean NR, Illing EA, Woodworth BA. Endoscopic resection of anterolateral maxillary sinus inverted papillomas. *Laryngoscope.* 2015;125(4):807-812. <https://doi.org/10.1002/lary.25033>
304. Wang F, Yang Y, Wang S, Chen H, Wang D, Wang Q. Management of maxillary sinus inverted papilloma via endoscopic partial medial maxillectomy with an inferior turbinate reversing approach. *Eur Arch Otorhinolaryngol.* 2017;274(12):4155-4159. <https://doi.org/10.1007/s00405-017-4749-7>
305. Wu V, Siu J, Yip J, Lee JM. Endoscopic management of maxillary sinus inverted papilloma attachment sites to minimize disease recurrence. *J Otolaryngol Head Neck Surg.* 2018;47(1):24. <https://doi.org/10.1186/s40463-018-0271-1>
306. Lee JT, Yoo F, Wang M, Vengerovich G, Suh JD. Modified endoscopic Denker approach in management of inverted papilloma of the anterior maxillary sinus. *Int Forum Allergy Rhinol.* 2020;10(4):533-538. <https://doi.org/10.1002/alr.22513>
307. Pagella F, Giourgos G, Matti E, Canevari FR, Carena P. Endoscopic treatment of maxillary inverted papilloma. *Rhinology.* 2011;49(3):369-374. <https://doi.org/10.4193/Rhino10.132>
308. Stavrakas M, Karkos PD, Tsinaslanidou Z, Constantinidis J. Endoscopic Denker's approach for the treatment of extensive sinonasal tumors: our experience. *Laryngoscope.* 2021;131(7):1458-1462. <https://doi.org/10.1002/lary.29235>
309. Yu QQ, Guan G, Zhang NK, et al. Intranasal endoscopic prelacrimal recess approach for maxillary sinus inverted papilloma. *Eur Arch Otorhinolaryngol.* 2018;275(9):2297-2302. <https://doi.org/10.1007/s00405-018-5078-1>
310. Suzuki M, Nakamura Y, Nakayama M, et al. Modified transnasal endoscopic medial maxillectomy with medial shift of preserved inferior turbinate and nasolacrimal duct. *Laryngoscope.* 2011;121(11):2399-2401. <https://doi.org/10.1002/lary.22326>
311. Arosio AD, Turri-Zanoni M, Sileo G, et al. Maxillary sinus floor infiltration: results from a series of 118 maxillary sinus cancers. *Laryngoscope.* 2022;132(1):26-35. <https://doi.org/10.1002/lary.29697>
312. Higgins TS, Thorp B, Rawlings BA, Han JK. Outcome results of endoscopic vs craniofacial resection of sinonasal malignancies: a systematic review and pooled-data analysis. *Int Forum Allergy Rhinol.* 2011;1(4):255-261. <https://doi.org/10.1002/alr.20051>
313. Lu VM, Ravindran K, Phan K, et al. Surgical outcomes of endoscopic versus open resection for primary sinonasal malignancy: a meta-analysis. *Am J Rhinol Allergy.* 2019;33(5):608-616. <https://doi.org/10.1177/1945892419856976>
314. Batra PS, Citardi MJ, Worley S, Lee J, Lanza DC. Resection of anterior skull base tumors: comparison of combined traditional and endoscopic techniques. *Am J Rhinol.* 2005;19(5):521-528.
315. Povolotskiy R, Farber NI, Bavier RD, Cerasiello SY, Eloy JA, Hsueh WD. Endoscopic versus open resection of non-squamous cell carcinoma sinonasal malignancies. *Laryngoscope.* 2020;130(8):1872-1876. <https://doi.org/10.1002/lary.28270>
316. Nicolai P, Battaglia P, Bignami M, et al. Endoscopic surgery for malignant tumors of the sinonasal tract and adjacent skull base: a 10-year experience. *Am J Rhinol.* 2008;22(3):308-316. <https://doi.org/10.2500/ajr.2008.22.3170>
317. Lawson W, Patel ZM. The evolution of management for inverted papilloma: an analysis of 200 cases. *Otolaryngol Head Neck Surg.* 2009;140(3):330-335. <https://doi.org/10.1016/j.otohns.2008.11.010>
318. Nakayama T, Tsunemi Y, Kuboki A, et al. Prelacrimal approach vs conventional surgery for inverted papilloma in the maxillary sinus. *Head Neck.* 2020;42(11):3218-3225. <https://doi.org/10.1002/hed.26376>
319. Nikakhlagh S, Taiebi S, Sistani Karampur L, Neici G, Saki N. The outcome of endoscopic surgery on patients with sinonasal inverted papilloma. *Jentashapir J Health Res.* 2015;6(4):30658. <https://doi.org/10.17795/jjhr-30658>
320. Lombardi D, Tomenzoli D, Buttà L, et al. Limitations and complications of endoscopic surgery for treatment for sinonasal inverted papilloma: a reassessment after 212 cases. *Head Neck.* 2011;33(8):1154-1161. <https://doi.org/10.1002/hed.21589>
321. Sham CL, Woo JKS, van Hasselt CA, Tong MCF. Treatment results of sinonasal inverted papilloma: an 18-year study. *Am J Rhinol Allergy.* 2009;23(2):203-211. <https://doi.org/10.2500/ajra.2009.23.3296>
322. Suzuki M, Nakamura Y, Yokota M, Ozaki S, Murakami S. Modified transnasal endoscopic medial maxillectomy through prelacrimal duct approach. *Laryngoscope.* 2017;127(10):2205-2209. <https://doi.org/10.1002/lary.26529>
323. Carrau RL, Segas J, Nuss DW, et al. Squamous cell carcinoma of the sinonasal tract invading the orbit. *Laryngoscope.* 1999;109(2 Pt 1):230-235. <https://doi.org/10.1097/00005537-199902000-00012>
324. Iannetti G, Valentini V, Rinna C, Ventucci E, Marianetti TM. Ethmoido-orbital tumors: our experience. *J Craniofac Surg.* 2005;16(6):1085-1091. <https://doi.org/10.1097/01.scs.0000164332.81428.ba>
325. McCary WS, Levine PA, Cantrell RW. Preservation of the eye in the treatment of sinonasal malignant neoplasms with orbital involvement. A confirmation of the original treatise. *Arch Otolaryngol Head Neck Surg.* 1996;122(6):657-659. <https://doi.org/10.1001/archotol.1996.01890180063015>
326. Suárez C, Ferlito A, Lund VJ, et al. Management of the orbit in malignant sinonasal tumors. *Head Neck.* 2008;30(2):242-250. <https://doi.org/10.1002/hed.20736>
327. Banks C, Husain Q, Bleier BS. Endoscopic endonasal intracanal orbit surgery. *World J Otorhinolaryngol Head Neck Surg.* 2020;6(2):100-105. <https://doi.org/10.1016/j.wjorl.2019.07.001>
328. Bleier BS, Healy DY, Chhabra N, Freitag S. Compartmental endoscopic surgical anatomy of the medial intraconal orbital space. *Int Forum Allergy Rhinol.* 2014;4(7):587-591. <https://doi.org/10.1002/alr.21320>
329. Chastain JB, Sindwani R. Anatomy of the orbit, lacrimal apparatus, and lateral nasal wall. *Otolaryngol Clin North Am.*

- 2006;39(5):855-864, v-vi. <https://doi.org/10.1016/j.otc.2006.07.003>
330. Shah J, Ting J, Sindwani R. Endoscopic orbital decompression: technical pearls and pitfalls of an evolving technique. *Am J Rhinol Allergy*. 2021;35(4):548-550. <https://doi.org/10.1177/1945892420965479>
 331. Stokken J, Gumber D, Antisdel J, Sindwani R. Endoscopic surgery of the orbital apex: outcomes and emerging techniques. *Laryngoscope*. 2016;126(1):20-24. <https://doi.org/10.1002/lary.25539>
 332. Maxfield AZ, Brook CD, Miyake MM, Bleier BS. Compartmental endoscopic surgical anatomy of the inferior intraconal orbital space. *J Neurol Surg B Skull Base*. 2018;79(2):189-192. <https://doi.org/10.1055/s-0037-1604405>
 333. Eisen MD, Yousem DM, Loevner LA, Thaler ER, Bilker WB, Goldberg AN. Preoperative imaging to predict orbital invasion by tumor. *Head Neck*. 2000;22(5):456-462. [https://doi.org/10.1002/1097-0347\(200008\)22:5<456::aid-hed3>3.0.co;2-n](https://doi.org/10.1002/1097-0347(200008)22:5<456::aid-hed3>3.0.co;2-n)
 334. Loevner LA, Sonners AI. Imaging of neoplasms of the paranasal sinuses. *Neuroimaging Clin N Am*. 2004;14(4):625-646. <https://doi.org/10.1016/j.nic.2004.07.005>
 335. Castelnovo P, Lambertoni A, Sileo G, et al. Critical review of multidisciplinary approaches for managing sinonasal tumors with orbital involvement. *Acta Otorhinolaryngol Ital*. 2021;41(Suppl. 1):S76-S89. <https://doi.org/10.14639/0392-100X-suppl.1-41-2021-08>
 336. Christianson B, Perez C, Harrow B, Batra PS. Management of the orbit during endoscopic sinonasal tumor surgery. *Int Forum Allergy Rhinol*. 2015;5(10):967-973. <https://doi.org/10.1002/alr.21563>
 337. Essig GF, Newman SA, Levine PA. Sparing the eye in craniofacial surgery for superior nasal vault malignant neoplasms: analysis of benefit. *Arch Facial Plast Surg*. 2007;9(6):406-411. <https://doi.org/10.1001/archfaci.9.6.406>
 338. Imola MJ, Schramm VL. Orbital preservation in surgical management of sinonasal malignancy. *Laryngoscope*. 2002;112(8 Pt 1):1357-1365. <https://doi.org/10.1097/00005537-200208000-00007>
 339. Lisan Q, Kolb F, Temam S, Tao Y, Janot F, Moya-Plana A. Management of orbital invasion in sinonasal malignancies. *Head Neck*. 2016;38(11):1650-1656. <https://doi.org/10.1002/hed.24490>
 340. Muscatello L, Fortunato S, Seccia V, Marchetti M, Lenzi R. The implications of orbital invasion in sinonasal tract malignancies. *Orbit*. 2016;35(5):278-284. <https://doi.org/10.1080/01676830.2016.1193532>
 341. Neel GS, Nagel TH, Hoxworth JM, Lal D. Management of orbital involvement in sinonasal and ventral skull base malignancies. *Otolaryngol Clin North Am*. 2017;50(2):347-364. <https://doi.org/10.1016/j.otc.2016.12.010>
 342. Reyes C, Patel M, Solares CA. Sinonasal malignancy and orbital exenteration sparing cancer surgery. *J Neurol Surg B Skull Base*. 2020;81(4):369-375. <https://doi.org/10.1055/s-0040-1713937>
 343. Safi AF, Behn L, Rothamel D, et al. Therapy of sinonasal malignancies invading the orbit-orbital exenteration versus preservation of the orbit plus radiotherapy. *J Craniomaxillofac Surg*. 2017;45(2):258-261. <https://doi.org/10.1016/j.jcms.2016.11.013>
 344. Vartanian JG, Toledo RN, Bueno T, Kowalski LP. Orbital exenteration for sinonasal malignancies: indications, rehabilitation and oncologic outcomes. *Curr Opin Otolaryngol Head Neck Surg*. 2018;26(2):122-126. <https://doi.org/10.1097/moo.0000000000000441>
 345. Cinar C, Arslan H, Bingol UA, Aydin Y, Cetinkale O. The new anatomical classification system for orbital exenteration defect. *J Craniofac Surg*. 2017;28(7):1687-1693. <https://doi.org/10.1097/scs.0000000000003746>
 346. Imre A, Imre SS, Pinar E, et al. Transection of nasolacrimal duct in endoscopic medial maxillectomy: implication on epiphora. *J Craniofac Surg*. 2015;26(7):e616-e619. <https://doi.org/10.1097/scs.0000000000002115>
 347. Rotsides JM, Franco A, Albader A, Casiano RR, Lieberman SM. Nasolacrimal duct management during endoscopic sinus and skull base surgery. *Ann Otol Rhinol Laryngol*. 2019;128(10):932-937. <https://doi.org/10.1177/0003489419848454>
 348. Sadeghi N, Joshi A. Management of the nasolacrimal system during transnasal endoscopic medial maxillectomy. *Am J Rhinol Allergy*. 2012;26(2):e85-e88. <https://doi.org/10.2500/ajra.2012.26.3737>
 349. Yeo NK, Wang JH, Chung YS, Jang YJ, Lee BJ. Contributing factors to prevent prolonged epiphora after maxillectomy. *Arch Otolaryngol Head Neck Surg*. 2010;136(3):229-233. <https://doi.org/10.1001/archoto.2010.18>
 350. Albonette-Felicio T, Rangel GG, Martínéz-Pérez R, Hardesty DA, Carrau RL, Prevedello DM. Surgical management of anterior skull-base malignancies (endoscopic vs. craniofacial resection). *J Neurooncol*. 2020;150(3):429-436. <https://doi.org/10.1007/s11060-020-03413-y>
 351. Reyes C, Bentley H, Gelves JA, Solares CA, Byrd JK. Recurrence rate after endoscopic vs. open approaches for juvenile nasopharyngeal angiofibroma: a meta-analysis. *J Neurol Surg B Skull Base*. 2019;80(6):577-585. <https://doi.org/10.1055/s-0038-1676562>
 352. Castelnovo P, Turri-Zanoni M, Battaglia P, Locatelli D, Dallan I. Endoscopic endonasal management of orbital pathologies. *Neurosurg Clin N Am*. 2015;26(3):463-472. <https://doi.org/10.1016/j.nec.2015.03.001>
 353. Kong DS, Young SM, Hong CK, et al. Clinical and ophthalmological outcome of endoscopic transorbital surgery for craniorbital tumors. *J Neurosurg*. 2018;131(3):667-675. <https://doi.org/10.3171/2018.3.Jns173233>
 354. Miller C, Bly R, Moe KS. Endoscopic orbital and periorbital approaches in minimally disruptive skull base surgery. *J Neurol Surg B Skull Base*. 2020;81(4):459-471. <https://doi.org/10.1055/s-0040-1713900>
 355. Ramakrishna R, Kim LJ, Bly RA, Moe K, Ferreira M. Transorbital neuroendoscopic surgery for the treatment of skull base lesions. *J Clin Neurosci*. 2016;24:99-104. <https://doi.org/10.1016/j.jocn.2015.07.021>
 356. Jeon C, Hong SD, Woo KI, et al. Use of endoscopic transorbital and endonasal approaches for 360° circumferential access to orbital tumors. *J Neurosurg*. 2020;135(1):103-112. <https://doi.org/10.3171/2020.6.JNS20890>
 357. Dallan I, Castelnovo P, Locatelli D, et al. Multiportal combined transorbital transnasal endoscopic approach for the management of selected skull base lesions: preliminary

- experience. *World Neurosurg.* 2015;84(1):97-107. <https://doi.org/10.1016/j.wneu.2015.02.034>
358. Karligkiotis A, Pistochini A, Turri-Zanoni M, et al. Endoscopic endonasal orbital transposition to expand the frontal sinus approaches. *Am J Rhinol Allergy.* 2015;29(6):449-456. <https://doi.org/10.2500/ajra.2015.29.4230>
 359. Tilak A, Purvis J, Peña-García A, et al. Above and beyond: periorbital suspension for endoscopic access to difficult frontal sinus pathology. *Laryngoscope.* 2022;132(3):538-544. <https://doi.org/10.1002/lary.29797>
 360. Al-Qurayshi Z, Liu A, Walsh JE. Presentation and outcomes of non-squamous cell carcinoma sinonasal malignancies: a national perspective. *Ann Otol Rhinol Laryngol.* 2022;131(4):420-426. <https://doi.org/10.1177/00034894211024783>
 361. Al-Qurayshi Z, Smith R, Walsh JE. Sinonasal squamous cell carcinoma presentation and outcome: a national perspective. *Ann Otol Rhinol Laryngol.* 2020;129(11):1049-1055. <https://doi.org/10.1177/0003489420929048>
 362. Antognoni P, Turri-Zanoni M, Gottardo S, et al. Endoscopic resection followed by adjuvant radiotherapy for sinonasal intestinal-type adenocarcinoma: retrospective analysis of 30 consecutive patients. *Head Neck.* 2015;37(5):677-684. <https://doi.org/10.1002/hed.23660>
 363. Bignami M, Lepera D, Volpi L, et al. Sinonasal non-intestinal-type adenocarcinoma: a retrospective review of 22 patients. *World Neurosurg.* 2018;120:e962-e969. <https://doi.org/10.1016/j.wneu.2018.08.201>
 364. Caspers CJI, Dronkers EAC, Monserez D, Wieringa MH, Baatenburg de Jong RJ, Hardillo JAU. Adjuvant radiotherapy in sinonasal mucosal melanoma: a retrospective analysis. *Clin Otolaryngol.* 2018;43(2):617-623. <https://doi.org/10.1111/coa.13033>
 365. Elsamna ST, Ahsanuddin S, Mir GS, et al. Surgical margin status and survival following resection of sinonasal mucosal melanoma. *Laryngoscope.* 2021;131(11):2429-2435. <https://doi.org/10.1002/lary.29574>
 366. Ganti A, Raman A, Shay A, et al. Treatment modalities in sinonasal mucosal melanoma: a national cancer database analysis. *Laryngoscope.* 2020;130(2):275-282. <https://doi.org/10.1002/lary.27995>
 367. Khan MN, Konuthula N, Parasher A, et al. Treatment modalities in sinonasal undifferentiated carcinoma: an analysis from the national cancer database. *Int Forum Allergy Rhinol.* 2017;7(2):205-210. <https://doi.org/10.1002/alf.21861>
 368. Konuthula N, Khan MN, Parasher A, et al. The presentation and outcomes of mucosal melanoma in 695 patients. *Int Forum Allergy Rhinol.* 2017;7(1):99-105. <https://doi.org/10.1002/alf.21831>
 369. Lee JJ, Roland LT, Licata JJ, et al. Morphologic, intraoperative, and histologic risk factors for sinonasal inverted papilloma recurrence. *Laryngoscope.* 2020;130(3):590-596. <https://doi.org/10.1002/lary.28078>
 370. Lepera D, Leone F, Volpi L, et al. Endoscopic endonasal approach for sinonasal and anterior skull base malignancies in the elderly. *Head Neck.* 2018;40(5):917-926. <https://doi.org/10.1002/hed.25045>
 371. Resto VA, Chan AW, Deschler DG, Lin DT. Extent of surgery in the management of locally advanced sinonasal malignancies. *Head Neck.* 2008;30(2):222-229. <https://doi.org/10.1002/hed.20681>
 372. Resto VA, Eisele DW, Forastiere A, Zahurak M, Lee DJ, Westra WH. Esthesioneuroblastoma: the Johns Hopkins experience. *Head Neck.* 2000;22(6):550-558. [https://doi.org/10.1002/1097-0347\(200009\)22:6<550::aid-hed2>3.0.co;2-0](https://doi.org/10.1002/1097-0347(200009)22:6<550::aid-hed2>3.0.co;2-0)
 373. Roth TN, Gengler C, Huber GF, Holzmann D. Outcome of sinonasal melanoma: clinical experience and review of the literature. *Head Neck.* 2010;32(10):1385-1392. <https://doi.org/10.1002/hed.21340>
 374. Schreiber A, Ferrari M, Mattavelli D, et al. Unilateral endoscopic resection with transnasal craniectomy for sinonasal intestinal-type adenocarcinoma: a bi-institutional case-control study on 54 patients. *Oral Oncol.* 2018;87:89-96. <https://doi.org/10.1016/j.oraloncology.2018.10.027>
 375. Shay A, Ganti A, Raman A, et al. Survival in low-grade and high-grade sinonasal adenocarcinoma: a national cancer database analysis. *Laryngoscope.* 2020;130(1):E1-E10. <https://doi.org/10.1002/lary.28052>
 376. Trope M, Triantafillou V, Kohanski MA, et al. Adenoid cystic carcinoma of the sinonasal tract: a review of the national cancer database. *Int Forum Allergy Rhinol.* 2019;9(4):427-434. <https://doi.org/10.1002/alf.22255>
 377. Wiseman SM, Popat SR, Rigual NR, et al. Adenoid cystic carcinoma of the paranasal sinuses or nasal cavity: a 40-year review of 35 cases. *Ear Nose Throat J.* 2002;81(8):510-514, 516-517.
 378. Lehrich BM, Yasaka TM, Goshtasbi K, Kuan EC. Outcomes of primary versus salvage surgery for sinonasal malignancies: a population-based analysis. *Laryngoscope.* 2021;131(3):E710-E718. <https://doi.org/10.1002/lary.28925>
 379. Andrianakis A, Kiss P, Pomberger M, Wolf A, Thurnher D, Tomazic PV. Sinonasal mucosal melanoma: treatment strategies and survival rates for a rare disease entity: a single center experience and review of literature. *Wien Klin Wochenschr.* 2021;133(21-22):1137-1147. <https://doi.org/10.1007/s00508-021-01847-6>
 380. Fu T, Chin CJ, Xu W, et al. Impact of neoadjuvant radiation on margins for non-squamous cell carcinoma sinonasal malignancies: radiation timing for sinonasal malignancies. *Laryngoscope.* 2018;128(12):2796-2803. <https://doi.org/10.1002/lary.27316>
 381. Kasemsiri P, Prevedello DMS, Otto BA, et al. Endoscopic endonasal technique: treatment of paranasal and anterior skull base malignancies. *Braz J Otorhinolaryngol.* 2013;79(6):760-779. <https://doi.org/10.5935/1808-8694.20130138>
 382. Pinheiro-Neto CD, Fernandez-Miranda JC, Wang EW, Gardner PA, Snyderman CH. Anatomical correlates of endonasal surgery for sinonasal malignancies. *Clin Anat.* 2012;25(1):129-134. <https://doi.org/10.1002/ca.22006>
 383. Musy PY, Reibel JF, Levine PA. Sinonasal undifferentiated carcinoma: the search for a better outcome. *Laryngoscope.* 2002;112(8):1450-1455. <https://doi.org/10.1097/00005537-200208000-00023>
 384. Chiu AG, Ma Y. Accuracy of intraoperative frozen margins for sinonasal malignancies and its implications for endoscopic resection of sinonasal melanomas: accuracy of intraoperative frozen margins for sinonasal malignancies. *Int Forum Allergy Rhinol.* 2013;3(2):157-160. <https://doi.org/10.1002/alf.21075>

385. Ishii M, Bishop JA, Gallia GL. Assessment of frozen section margin analysis during olfactory neuroblastoma surgery: frozen section performance in ONB surgery. *Laryngoscope*. 2017;127(8):1735-1741. <https://doi.org/10.1002/lary.26496>
386. Binahmed A, Nason RW, Abdoh AA. The clinical significance of the positive surgical margin in oral cancer. *Oral Oncol*. 2007;43(8):780-784. <https://doi.org/10.1016/j.oraloncology.2006.10.001>
387. Hinni ML, Zarka MA, Hoxworth JM. Margin mapping in transoral surgery for head and neck cancer. *Laryngoscope*. 2013;123(5):1190-1198. <https://doi.org/10.1002/lary.23900>
388. Meier JD, Oliver DA, Varvares MA. Surgical margin determination in head and neck oncology: current clinical practice. The results of an International American Head and Neck Society Member Survey. *Head Neck*. 2005;27(11):952-958. <https://doi.org/10.1002/hed.20269>
389. Hordijk GJ, Brons EN. Carcinomas of the maxillary sinus: a retrospective study. *Clin Otolaryngol Allied Sci*. 1985;10(5):285-288. <https://doi.org/10.1111/j.1365-2273.1985.tb00256.x>
390. Penel N, Mallet Y, Mirabel X, Van JT, Lefebvre JL. Primary mucosal melanoma of head and neck: prognostic value of clear margins. *Laryngoscope*. 2006;116(6):993-995. <https://doi.org/10.1097/01.mlg.00000217236.06585.a9>
391. Thompson LDR, Wieneke JA, Miettinen M. Sinonasal tract and nasopharyngeal melanomas: a clinicopathologic study of 115 cases with a proposed staging system. *Am J Surg Pathol*. 2003;27(5):594-611. <https://doi.org/10.1097/00000478-200305000-00004>
392. Miller CJ, Sobanko JF, Zhu X, Nunnciato T, Urban CR. Special stains in Mohs surgery. *Dermatol Clin*. 2011;29(2):273-286. <https://doi.org/10.1016/j.det.2011.01.003>
393. Stranahan D, Cherpelis BS, Glass LF, Ladd S, Fenske NA. Immunohistochemical stains in Mohs surgery: a review. *Dermatol Surg*. 2009;35(7):1023-1034. <https://doi.org/10.1111/j.1524-4725.2009.01179.x>
394. Chao KSC, Kaplan C, Simpson JR, et al. Esthesioneuroblastoma: the impact of treatment modality. *Head Neck*. 2001;23(9):749-757. <https://doi.org/10.1002/hed.1107>
395. Hoppe BS, Stegman LD, Zelefsky MJ, et al. Treatment of nasal cavity and paranasal sinus cancer with modern radiotherapy techniques in the postoperative setting—the MSKCC experience. *Int J Radiat Oncol Biol Phys*. 2007;67(3):691-702. <https://doi.org/10.1016/j.ijrobp.2006.09.023>
396. Sun M, Wang K, Qu Y, et al. Long-term analysis of multimodality treatment outcomes and prognosis of esthesioneuroblastomas: a single center results of 138 patients. *Radiat Oncol*. 2020;15(1):219. <https://doi.org/10.1186/s13014-020-01667-4>
397. Zafereo ME, Fakhri S, Prayson R, et al. Esthesioneuroblastoma: 25-year experience at a single institution. *Otolaryngol Head Neck Surg*. 2008;138(4):452-458. <https://doi.org/10.1016/j.otohns.2007.12.038>
398. Mays AC, Hanna EY, Ferrarotto R, et al. Prognostic factors and survival in adenoid cystic carcinoma of the sinonasal cavity. *Head Neck*. 2018;40(12):2596-2605. <https://doi.org/10.1002/hed.25335>
399. Seong SY, Hyun DW, Kim YS, et al. Treatment outcomes of sinonasal adenoid cystic carcinoma: 30 cases from a single institution. *J Craniomaxillofac Surg*. 2014;42(5):e171-e175. <https://doi.org/10.1016/j.jcms.2013.08.002>
400. Bachar G, Loh KS, O'Sullivan B, et al. Mucosal melanomas of the head and neck: experience of the Princess Margaret Hospital. *Head Neck*. 2008;30(10):1325-1331. <https://doi.org/10.1002/hed.20878>
401. Kingdom TT, Kaplan MJ. Mucosal melanoma of the nasal cavity and paranasal sinuses. *Head Neck*. 1995;17(3):184-189. <https://doi.org/10.1002/hed.2880170303>
402. Vandenhende C, Leroy X, Chevalier D, Mortuaire G. Sinonasal mucosal melanoma: retrospective survival study of 25 patients. *J Laryngol Otol*. 2012;126(2):147-151. <https://doi.org/10.1017/S0022215111002519>
403. Bilsky MH, Kraus DH, Strong EW, Harrison LB, Gutin PH, Shah JP. Extended anterior craniofacial resection for intracranial extension of malignant tumors. *Am J Surg*. 1997;174(5):565-568. [https://doi.org/10.1016/s0002-9610\(97\)00172-4](https://doi.org/10.1016/s0002-9610(97)00172-4)
404. Kraus DH, Sterman BM, Levine HL, Wood BG, Tucker HM, Lavertu P. Factors influencing survival in ethmoid sinus cancer. *Arch Otolaryngol Head Neck Surg*. 1992;118(4):367-372. <https://doi.org/10.1001/archotol.1992.01880040025005>
405. Qureshi SS, Chaukar DA, Talole SD, Dcruz AK. Clinical characteristics and outcome of non-squamous cell malignancies of the maxillary sinus. *J Surg Oncol*. 2006;93(5):362-367. <https://doi.org/10.1002/jso.20500>
406. Rutter MJ, Furneaux CE, Morton RP. Craniofacial resection of anterior skull base tumours: factors contributing to success. *ANZ J Surg*. 1998;68(5):350-353. <https://doi.org/10.1111/j.1445-2197.1998.tb04770.x>
407. Spiro JD, Soo KC, Spiro RH. Nonsquamous cell malignant neoplasms of the nasal cavities and paranasal sinuses. *Head Neck*. 1995;17(2):114-118. <https://doi.org/10.1002/hed.2880170207>
408. Michel G, Joubert M, Delemazure AS, Espitalier F, Durand N, Malard O. Adenoid cystic carcinoma of the paranasal sinuses: retrospective series and review of the literature. *Eur Ann Otorhinolaryngol Head Neck Dis*. 2013;130(5):257-262. <https://doi.org/10.1016/j.anorl.2012.09.010>
409. Miglani A, Hoxworth JM, Zarka MA, Lal D. Use of intraoperative negative margins reduces inverted papilloma recurrence. *Am J Rhinol Allergy*. 2018;32(1):57-60. <https://doi.org/10.2500/ajra.2018.32.4504>
410. Healy DY, Chhabra N, Metson R, Holbrook EH, Gray ST. Surgical risk factors for recurrence of inverted papilloma. *Laryngoscope*. 2016;126(4):796-801. <https://doi.org/10.1002/lary.25663>
411. Auger SR, Patel T, Ganti A, et al. Effect of margin status and pathological grade in treatment of sinonasal mucoepidermoid carcinoma. *Laryngoscope*. 2020;130(12):E750-E757. <https://doi.org/10.1002/lary.28499>
412. Abdelmeguid AS, Bell D, Roberts D, et al. Long-term outcomes of olfactory neuroblastoma: MD Anderson Cancer Center experience and review of the literature. *Laryngoscope*. 2022;132(2):290-297. <https://doi.org/10.1002/lary.29732>
413. Joshi RR, Husain Q, Roman BR, et al. Comparing Kadish, TNM, and the modified Dulguerov staging systems for esthesioneuroblastoma. *J Surg Oncol*. 2019;119(1):130-142. <https://doi.org/10.1002/jso.25293>

414. Ackall FY, Issa K, Barak I, et al. Survival outcomes in sinonasal poorly differentiated squamous cell carcinoma. *Laryngoscope*. 2021;131(4):E1040-E1048. <https://doi.org/10.1002/lary.29090>
415. Janecka IP, Sen C, Sekhar L, Curtin H. Treatment of paranasal sinus cancer with cranial base surgery: results. *Laryngoscope*. 1994;104(5 Pt 1):553-555. <https://doi.org/10.1002/lary.5541040508>
416. Thorup C, Sebbesen L, Danø H, et al. Carcinoma of the nasal cavity and paranasal sinuses in Denmark 1995–2004. *Acta Oncol*. 2010;49(3):389-394. <https://doi.org/10.3109/02841860903428176>
417. Kaplan DJ, Kim JH, Wang E, Snyderman C. Prognostic indicators for salvage surgery of recurrent sinonasal malignancy. *Otolaryngol Head Neck Surg*. 2016;154(1):104-112. <https://doi.org/10.1177/0194599815606699>
418. Khalili S, Worrall DM, Brooks S, et al. Endoscopy versus imaging: analysis of surveillance methods in sinonasal malignancy: analysis of surveillance methods in sinonasal malignancy. *Head Neck*. 2016;38(8):1229-1233. <https://doi.org/10.1002/hed.24413>
419. Zocchi J, Pietrobon G, Campomagnani I, et al. The role of a post therapeutic surveillance program for sinonasal malignancies: analysis of 417 patients. *Head Neck*. 2020;42(5):963-973. <https://doi.org/10.1002/hed.26069>
420. Harvey RJ, Pitzer G, Nissman DB, et al. PET/CT in the assessment of previously treated skull base malignancies. *Head Neck*. 2010;32(1):76-84. <https://doi.org/10.1002/hed.21147>
421. Workman AD, Glicksman JT, Parasher AK, et al. ¹⁸F-FDG PET/CT in routine surveillance of asymptomatic patients following treatment of sinonasal neoplasms. *Otolaryngol Head Neck Surg*. 2017;157(6):1068-1074. <https://doi.org/10.1177/0194599817722959>
422. Rogers JW, Greven KM, McGuirt WF, et al. Can post-RT neck dissection be omitted for patients with head-and-neck cancer who have a negative pet scan after definitive radiation therapy? *Int J Radiat Oncol Biol Phys*. 2004;58(3):694-697. [https://doi.org/10.1016/S0360-3016\(03\)01625-0](https://doi.org/10.1016/S0360-3016(03)01625-0)
423. Yao M, Smith RB, Graham MM, et al. The role of FDG PET in management of neck metastasis from head-and-neck cancer after definitive radiation treatment. *Int J Radiat Oncol Biol Phys*. 2005;63(4):991-999. <https://doi.org/10.1016/j.ijrobp.2005.03.066>
424. Brkovich VS, Miller FR, Karnad AB, Hussey DH, McGuff HS, Otto RA. The role of positron emission tomography scans in the management of the N-positive neck in head and neck squamous cell carcinoma after chemoradiotherapy. *Laryngoscope*. 2006;116(6):855-858. <https://doi.org/10.1097/01.mlg.0000214668.98592.d6>
425. Sagardoy T, Fernandez P, Ghafouri A, et al. Accuracy of (18) FDG PET-CT for treatment evaluation 3 months after completion of chemoradiotherapy for head and neck squamous cell carcinoma: 2-year minimum follow-up. *Head Neck*. 2016;38(Suppl. 1):E1271-1276. <https://doi.org/10.1002/hed.24204>
426. Fakhry N, Michel J, Colavolpe C, Varoquaux A, Dessi P, Giovanni A. Screening for distant metastases before salvage surgery in patients with recurrent head and neck squamous cell carcinoma: a retrospective case series comparing thoraco-abdominal CT, positron emission tomography and abdominal ultrasound. *Clin Otolaryngol*. 2012;37(3):197-206. <https://doi.org/10.1111/j.1749-4486.2012.02481.x>
427. Spector ME, Chinn SB, Rosko AJ, et al. Diagnostic modalities for distant metastasis in head and neck squamous cell carcinoma: are we changing life expectancy? *Laryngoscope*. 2012;122(7):1507-1511. <https://doi.org/10.1002/lary.23264>
428. Kim SA, Chung YS, Lee BJ. Recurrence patterns of sinonasal cancers after a 5-year disease-free period. *Laryngoscope*. 2019;129(11):2451-2457. <https://doi.org/10.1002/lary.27866>
429. Peacock JG, Harmsen WS, Link MJ, et al. Risk of delayed lymph node metastasis in clinically N0 esthesioneuroblastoma. *J Neurol Surg B Skull Base*. 2017;78(1):68-74. <https://doi.org/10.1055/s-0036-1584904>
430. Maina IW, Lehrich BM, Goshtasbi K, et al. Extraprimary local recurrence of esthesioneuroblastoma: case series and literature review. *World Neurosurg*. 2020;144:e546-e552. <https://doi.org/10.1016/j.wneu.2020.08.227>
431. Workman AD, Velasquez N, Khan NI, et al. Rates of symptomatology are lower in recurrent sinonasal malignancy than in other recurrent cancers of the head and neck: a multi-institutional study. *Int Forum Allergy Rhinol*. 2019;9(6):688-694. <https://doi.org/10.1002/alr.22310>
432. Mattavelli D, Tomasoni M, Ferrari M, et al. Salvage surgery in recurrent sinonasal cancers: proposal for a prognostic model based on clinicopathologic and treatment-related parameters. *Head Neck*. 2022;44(8):1857-1870. <https://doi.org/10.1002/hed.27102>
433. Ono T, Sakata K, Tanaka N, et al. Salvage surgery for a locally persistent or recurrent tumour in maxillary cancer patients who have undergone radiotherapy and concomitant intra-arterial cisplatin: implications for surgical margin assessment. *Int J Oral Maxillofac Surg*. 2019;48(5):567-575. <https://doi.org/10.1016/j.ijom.2018.10.019>
434. Tsushima N, Kano S, Suzuki T, et al. Salvage surgery improves the treatment outcome of patients with residual/recurrent maxillary sinus cancer after superselective intra-arterial cisplatin infusion with concomitant radiation therapy. *Eur Arch Otorhinolaryngol*. 2022;279(2):899-905. <https://doi.org/10.1007/s00405-021-06822-5>
435. Orlandi E, Cavalieri S, Granata R, et al. Locally advanced epithelial sinonasal tumors: the impact of multimodal approach. *Laryngoscope*. 2020;130(4):857-865. <https://doi.org/10.1002/lary.28202>
436. Gore MR, Zanation AM. Salvage treatment of local recurrence in esthesioneuroblastoma: a meta-analysis. *Skull Base*. 2011;21(1):1-6. <https://doi.org/10.1055/s-0030-1254406>
437. Gore MR, Zanation AM. Salvage treatment of late neck metastasis in esthesioneuroblastoma: a meta-analysis. *Arch Otolaryngol Head Neck Surg*. 2009;135(10):1030-1034. <https://doi.org/10.1001/archoto.2009.143>
438. Iwata H, Tatewaki K, Inoue M, Yokota N, Sato K, Shibamoto Y. Salvage stereotactic reirradiation using the CyberKnife for the local recurrence of nasal or paranasal carcinoma. *Radiother Oncol*. 2012;104(3):355-360. <https://doi.org/10.1016/j.radonc.2012.01.017>
439. Gao J, Hu J, Guan X, et al. Salvage carbon-ion radiation therapy for locoregionally recurrent head and neck malignan-

- cies. *Sci Rep.* 2019;9(1):4259. <https://doi.org/10.1038/s41598-019-39241-y>
440. Gogineni E, Zhang I, Rana Z, et al. Quality of life outcomes following organ-sparing SBRT in previously irradiated recurrent head and neck cancer. *Front Oncol.* 2019;9:836. <https://doi.org/10.3389/fonc.2019.00836>
 441. Hayashi K, Koto M, Ikawa H, et al. Feasibility of Re-irradiation using carbon ions for recurrent head and neck malignancies after carbon-ion radiotherapy. *Radiother Oncol.* 2019;136:148-153. <https://doi.org/10.1016/j.radonc.2019.04.007>
 442. Fan M, Kang JJ, Lee A, et al. Outcomes and toxicities of definitive radiotherapy and reirradiation using 3-dimensional conformal or intensity-modulated (pencil beam) proton therapy for patients with nasal cavity and paranasal sinus malignancies. *Cancer.* 2020;126(9):1905-1916. <https://doi.org/10.1002/ncr.32776>
 443. Bahig H, Ng SP, Pollard C, et al. A prospective evaluation of health-related quality of life after skull base re-irradiation. *Head Neck.* 2020;42(3):485-497. <https://doi.org/10.1002/hed.26037>
 444. Yamazaki H, Suzuki G, Aibe N, et al. Reirradiation for nasal cavity or paranasal sinus tumor—a multi-institutional study. *Cancers.* 2021;13(24):6315. <https://doi.org/10.3390/cancers13246315>
 445. Firlirk KS, Kondziolka D, Lunsford LD, Janecka IP, Flickinger JC. Radiosurgery for recurrent cranial base cancer arising from the head and neck. *Head Neck.* 1996;18(2):160-165; discussion 166. [https://doi.org/10.1002/\(SICI\)1097-0347\(199603/04\)18:2<160::AID-HED8>3.0.CO;2-#](https://doi.org/10.1002/(SICI)1097-0347(199603/04)18:2<160::AID-HED8>3.0.CO;2-#)
 446. Pollock BE, Iuliano BA, Foote RL, Gorman DA. Stereotactic radiosurgery for tumor-related trigeminal pain. *Neurosurgery.* 2000;46(3):576-582; discussion 582-583. <https://doi.org/10.1097/00006123-200003000-00010>
 447. Kano H, Niranjana A, Kondziolka D, Flickinger JC, Lunsford LD. The role of palliative radiosurgery when cancer invades the cavernous sinus. *Int J Radiat Oncol Biol Phys.* 2009;73(3):709-715. <https://doi.org/10.1016/j.ijrobp.2008.05.005>
 448. Clump DA, Leeman JE, Wegner RE, Burton SA, Mintz AH, Heron DE. Stereotactic radiosurgery for the treatment and palliation of base of skull metastases. *J Radiosurg SBRT.* 2013;2(3):217-223.
 449. Dröge LH, Hinsche T, Canis M, Alt-Epping B, Hess CF, Wolff HA. Fractionated external beam radiotherapy of skull base metastases with cranial nerve involvement. *Strahlenther Onkol.* 2014;190(2):199-203. <https://doi.org/10.1007/s00066-013-0460-9>
 450. Phan J, Pollard C, Brown PD, et al. Stereotactic radiosurgery for trigeminal pain secondary to recurrent malignant skull base tumors. *J Neurosurg.* 2018;130(3):812-821. <https://doi.org/10.3171/2017.11.JNS172084>
 451. Chan JYW, To VSH, Wong STS, Wei WI. Quality of dying in head and neck cancer patients: the role of surgical palliation. *Eur Arch Otorhinolaryngol.* 2013;270(2):681-688. <https://doi.org/10.1007/s00405-012-2059-7>
 452. Farber NI, Povolotskiy R, Bavier RD, Riccardi J, Eloy JA, Hsueh WD. Impact of palliative treatment on survival in sinonasal malignancies. *Int Forum Allergy Rhinol.* 2019;9(12):1499-1507. <https://doi.org/10.1002/alr.22432>
 453. Hasan OK, Ravi Kumar AS, Kong G, et al. Efficacy of peptide receptor radionuclide therapy for esthesioneuroblastoma. *J Nucl Med.* 2020;61(9):1326-1330. <https://doi.org/10.2967/jnumed.119.237990>
 454. Homma A, Sakashita T, Yoshida D, et al. Superselective intra-arterial cisplatin infusion and concomitant radiotherapy for maxillary sinus cancer. *Br J Cancer.* 2013;109(12):2980-2986. <https://doi.org/10.1038/bjc.2013.663>
 455. Jiang W, Mohamed ASR, Fuller CD, et al. The role of elective nodal irradiation for esthesioneuroblastoma patients with clinically negative neck. *Pract Radiat Oncol.* 2016;6(4):241-247. <https://doi.org/10.1016/j.prro.2015.10.023>
 456. Yin Z-z, Luo J-w, Gao L, et al. Spread patterns of lymph nodes and the value of elective neck irradiation for esthesioneuroblastoma. *Radiother Oncol.* 2015;117(2):328-332. <https://doi.org/10.1016/j.radonc.2015.10.002>
 457. Song X, Huang C, Wang S, Yan L, Wang J, Li Y. Neck management in patients with olfactory neuroblastoma. *Oral Oncol.* 2020;101:104505. <https://doi.org/10.1016/j.oraloncology.2019.104505>
 458. Patel SH, Wang Z, Wong WW, et al. Charged particle therapy versus photon therapy for paranasal sinus and nasal cavity malignant diseases: a systematic review and meta-analysis. *Lancet Oncology.* 2014;15(9):1027-1038. [https://doi.org/10.1016/S1470-2045\(14\)70268-2](https://doi.org/10.1016/S1470-2045(14)70268-2)
 459. Hoppe BS, Wolden SL, Zelefsky MJ, et al. Postoperative intensity-modulated radiation therapy for cancers of the paranasal sinuses, nasal cavity, and lacrimal glands: technique, early outcomes, and toxicity. *Head Neck.* 2008;30(7):925-932. <https://doi.org/10.1002/hed.20800>
 460. Dagan R, Uezono H, Bryant C, Holtzman AL, Morris CG, Mendenhall WM. Long-term outcomes from proton therapy for sinonasal cancers. *Int J Part Ther.* 2021;8(1):200-212. <https://doi.org/10.14338/IJPT-20-00068.1>
 461. Aljabab S, Lui A, Wong T, Liao J, Laramore G, Parvathaneni U. A combined neutron and proton regimen for advanced salivary tumors: early clinical experience. *Cureus.* 2021;13(5):e14844. <https://doi.org/10.7759/cureus.14844>
 462. Al-Mamgani A, Monserez D, van Rooij P, Verduijn GM, Hardillo JAU, Levendag PC. Highly-conformal intensity-modulated radiotherapy reduced toxicity without jeopardizing outcome in patients with paranasal sinus cancer treated by surgery and radiotherapy or (chemo)radiation. *Oral Oncol.* 2012;48(9):905-911. <https://doi.org/10.1016/j.oraloncology.2012.03.024>
 463. Douglas JG, Koh W-j, Austin-Seymour M, Laramore GE. Treatment of salivary gland neoplasms with fast neutron radiotherapy. *Arch Otolaryngol Head Neck Surg.* 2003;129(9):944-948. <https://doi.org/10.1001/archotol.129.9.944>
 464. Duprez F, Madani I, Morbée L, et al. IMRT for sinonasal tumors minimizes severe late ocular toxicity and preserves disease control and survival. *Int J Radiat Oncol Biol Phys.* 2012;83(1):252-259. <https://doi.org/10.1016/j.ijrobp.2011.06.1977>
 465. Filtenborg MV, Lilja-Fischer JK, Sharma MB, et al. Sinonasal cancer in Denmark 2008–2015: a population-based phase-4 cohort study from DAHANCA. *Acta Oncol.* 2021;60(3):333-342. <https://doi.org/10.1080/0284186x.2021.1874618>

466. Li G, Qiu B, Huang YX, et al. Cost-effectiveness analysis of proton beam therapy for treatment decision making in paranasal sinus and nasal cavity cancers in China. *BMC Cancer*. 2020;20(1):599. <https://doi.org/10.1186/s12885-020-07083-x>
467. Wang L, Fossati P, Paganetti H, et al. The biological basis for enhanced effects of proton radiation therapy relative to photon radiation therapy for head and neck squamous cell carcinoma. *Int J Part Ther*. 2021;8(1):3-13. <https://doi.org/10.14338/IJPT-20-00070.1>
468. Gordon K, Gulidov I, Fatkhudinov T, Koryakin S, Kaprin A. Fast and furious: fast neutron therapy in cancer treatment. *Int J Part Ther*. 2022;9(2):59-69. <https://doi.org/10.14338/IJPT-22-00017>
469. Laramore GE, Krall JM, Griffin TW, et al. Neutron versus photon irradiation for unresectable salivary gland tumors: final report of an RTOG-MRC randomized clinical trial. *Int J Radiat Oncol Biol Phys*. 1993;27(2):235-240. [https://doi.org/10.1016/0360-3016\(93\)90233-1](https://doi.org/10.1016/0360-3016(93)90233-1)
470. Jensen AD, Debus J. Cost-effectiveness analysis (CEA) of IMRT plus C12 boost vs IMRT only in adenoid cystic carcinoma (ACC) of the head and neck. *Radiat Oncol*. 2019;14(1):194. <https://doi.org/10.1186/s13014-019-1395-9>
471. Malouff TD, Mahajan A, Krishnan S, Beltran C, Seneviratne DS, Trifiletti DM. Carbon ion therapy: a modern review of an emerging technology. *Front Oncol*. 2020;10:82. <https://doi.org/10.3389/fonc.2020.00082>
472. Koto M, Demizu Y, Saitoh JI, et al. Definitive carbon-ion radiation therapy for locally advanced sinonasal malignant tumors: subgroup analysis of a multicenter study by the Japan Carbon-Ion Radiation Oncology Study Group (J-CROS). *Int J Radiat Oncol Biol Phys*. 2018;102(2):353-361. <https://doi.org/10.1016/j.ijrobp.2018.05.074>
473. Mizoe J-e, Hasegawa A, Jingu K, et al. Results of carbon ion radiotherapy for head and neck cancer. *Radiother Oncol*. 2012;103(1):32-37. <https://doi.org/10.1016/j.radonc.2011.12.013>
474. Zhang W, Hu W, Hu J, et al. Carbon ion radiation therapy for sinonasal malignancies: promising results from 2282 cases from the real world. *Cancer Sci*. 2020;111(12):4465-4479. <https://doi.org/10.1111/cas.14650>
475. Liang ZG, Kusumawidjaja G, Kazmi F, Wee JTS, Chua MLK. Intensity-modulated radiotherapy for paranasal sinuses and base of skull tumors. *Oral Oncol*. 2018;86:61-68. <https://doi.org/10.1016/j.oraloncology.2018.09.010>
476. Patel J, Chitguppi C, Vimawala S, et al. Treatment-related morbidity in patients treated for sinonasal malignancy. *Int Forum Allergy Rhinol*. 2020;10(4):526-532. <https://doi.org/10.1002/alr.22509>
477. Klymenko O, Buchberger AMS, Wollenberg B, et al. Radiooncological view on therapy outcome after multidisciplinary treatment of sinonasal tumors. *Cancers*. 2021;13(10):2364. <https://doi.org/10.3390/cancers13102364>
478. Korra H, Gandhi JB, Nanuvala P, Ardha A. Experiences and outcomes in olfactory neuroblastoma over a decade at a tertiary cancer center. *South Asian J Cancer*. 2022;11(4):336-339. <https://doi.org/10.1055/s-0041-1739181>
479. Laskar SG, Pai P, Sinha S, et al. Intensity-modulated radiation therapy for nasal cavity and paranasal sinus tumors: experience from a single institute. *Head Neck*. 2021;43(7):2045-2057. <https://doi.org/10.1002/hed.26669>
480. Owin N, Elsayad K, Rolf D, et al. Radiotherapy as part of treatment strategies in nasal cavity and paranasal sinus malignancies. *Anticancer Res*. 2021;41(3):1587-1592. <https://doi.org/10.21873/anticancer.14919>
481. Slevin F, Pan S, Mistry H, et al. A Multicentre UK study of outcomes for locally advanced sinonasal squamous cell carcinoma treated with adjuvant or definitive intensity-modulated radiotherapy. *Clin Oncol*. 2021;33(10):e450-e461. <https://doi.org/10.1016/j.clon.2021.05.012>
482. Swain M, Ghosh-Laskar S, Budrukkar A, et al. Concurrent chemoradiotherapy for locally advanced unresectable adenoid cystic carcinoma of head and neck: experience from a single institute. *Eur Arch Otorhinolaryngol*. 2021;278(11):4423-4431. <https://doi.org/10.1007/s00405-021-06654-3>
483. Ting DSJ, Rana-Rahman R, Ng JY, Wilkinson DJ, Ah-Kine D, Patel T. Clinical spectrum and outcomes of ocular and periorbital complications following external-beam radiotherapy for inoperable malignant maxillary sinus tumors. *Ocul Oncol Pathol*. 2021;7(1):36-43. <https://doi.org/10.1159/000511011>
484. Zeng Q, Tian Y, He Y, et al. Long-Term survival outcomes and treatment experience of 64 patients with esthesioneuroblastoma. *Front Oncol*. 2021;11:624960. <https://doi.org/10.3389/fonc.2021.624960>
485. Chen N, Yuan H, Fan W, et al. Multimodal treatment with orbital organ preservation in adult patients with locally advanced small-round-cell malignancy of the nasal cavity and paranasal sinus. *Front Oncol*. 2021;11:650385. <https://doi.org/10.3389/fonc.2021.650385>
486. Bao C, Hu W, Hu J, Dong Y, Lu JJ, Kong L. Intensity-modulated radiation therapy for esthesioneuroblastoma: 10-year experience of a single institute. *Front Oncol*. 2020;10:1158. <https://doi.org/10.3389/fonc.2020.01158>
487. Ferella L, Cavallo A, Miceli R, et al. Prognostic role of primary tumor, nodal neck, and retropharyngeal GTVs for unresectable sinonasal cancers treated with IMRT and chemotherapy. *Tumori*. 2020;106(1):39-46. <https://doi.org/10.1177/0300891619868006>
488. Liu T, Sun Q, Qin W, Chen X, Hu Q. Outcome and optimal treatment for esthesioneuroblastoma in the era of intensity-modulated radiation therapy: a single-center experience. *Cancer Manag Res*. 2020;12:8355-8362. <https://doi.org/10.2147/CMAR.S259921>
489. Sharma MB, Jensen K, Urbak SF, et al. A multidimensional cohort study of late toxicity after intensity modulated radiotherapy for sinonasal cancer. *Radiother Oncol*. 2020;151:58-65. <https://doi.org/10.1016/j.radonc.2020.07.029>
490. Sharma MB, Jensen K, Amidi A, Eskildsen SF, Johansen J, Grau C. Late toxicity in the brain after radiotherapy for sinonasal cancer: neurocognitive functioning, MRI of the brain and quality of life. *Clin Transl Radiat Oncol*. 2020;25:52-60. <https://doi.org/10.1016/j.ctro.2020.09.003>
491. Sharma MB, Jensen K, Friberg J, et al. Target coverage and local recurrences after radiotherapy for sinonasal cancer in Denmark 2008–2015. A DAHANCA study. *Acta Oncol (Madr)*. 2022;61(2):120-126. <https://doi.org/10.1080/0284186x.2021.2022199>

492. Wang Z, Qu Y, Wang K, et al. The value of preoperative radiotherapy in the treatment of locally advanced nasal cavity and paranasal sinus squamous cell carcinoma: a single institutional experience. *Oral Oncol.* 2020;101:104512. <https://doi.org/10.1016/j.oraloncology.2019.104512>
493. Frederic-Moreau T, Piram L, Bellini R, et al. Postoperative volumetric modulated arc therapy for sinonasal cancer: improved survival compared with 3D conformal radiation therapy. *Head Neck.* 2019;41(2):448-455. <https://doi.org/10.1002/hed.25410>
494. Guazzo E, Bowman J, Porceddu S, Webb L, Panizza B. Advanced adenoid cystic carcinoma of the skull base – the role of surgery. *Oral Oncol.* 2019;99:104466. <https://doi.org/10.1016/j.oraloncology.2019.104466>
495. Li R, Tian S, Zhu Y, et al. Management of orbital invasion in esthesioneuroblastoma: 14 years' experience. *Radiat Oncol.* 2019;14(1):107. <https://doi.org/10.1186/s13014-019-1313-1>
496. Lee WH, Choi SH, Kim SH, Choi EC, Lee CG, Keum KC. Elective neck treatment in clinically node-negative paranasal sinus carcinomas: impact on treatment outcome. *Radiat Oncol J.* 2018;36(4):304-316. <https://doi.org/10.3857/roj.2018.00416>
497. de Bonnecaze G, Verillaud B, Chaltiel L, et al. Clinical characteristics and prognostic factors of sinonasal undifferentiated carcinoma: a multicenter study. *Int Forum Allergy Rhinol.* 2018;8(9):1065-1072. <https://doi.org/10.1002/alr.22143>
498. Chopra S, Kamdar DP, Cohen DS, et al. Outcomes of non-surgical management of locally advanced carcinomas of the sinonasal cavity. *Laryngoscope.* 2017;127(4):855-861. <https://doi.org/10.1002/lary.26228>
499. Gamez ME, Lal D, Halyard MY, et al. Outcomes and patterns of failure for sinonasal undifferentiated carcinoma (SNUC): the Mayo Clinic Experience. *Head Neck.* 2017;39(9):1819-1824. <https://doi.org/10.1002/hed.24834>
500. Ahmad S, Le CH, Chiu AG, Chang EH. Incidence of intracranial radiation necrosis following postoperative radiation therapy for sinonasal malignancies. *Laryngoscope.* 2016;126(11):2445-2450. <https://doi.org/10.1002/lary.26106>
501. Amsbaugh MJ, Yusuf M, Silverman C, et al. Organ preservation with neoadjuvant chemoradiation in patients with orbit invasive sinonasal cancer otherwise requiring exenteration. *Radiat Oncol J.* 2016;34(3):209-215. <https://doi.org/10.3857/roj.2016.01739>
502. Askoxylakis V, Hegenbarth P, Timke C, et al. Intensity modulated radiation therapy (IMRT) for sinonasal tumors: a single center long-term clinical analysis. *Radiat Oncol.* 2016;11:17. <https://doi.org/10.1186/s13014-016-0595-9>
503. Burt LM, Orlandi RR, Hunt JP, et al. Function preservation and optimal outcomes—definitive chemoradiotherapy with multi-phase treatment planning for locally advanced sinonasal cancer. *J Radiat Oncol.* 2016;5(1):47-54. <https://doi.org/10.1007/s13566-015-0226-3>
504. Suh YG, Lee CG, Kim H, et al. Treatment outcomes of intensity-modulated radiotherapy versus 3D conformal radiotherapy for patients with maxillary sinus cancer in the postoperative setting: IMRT Versus 3D Conformal Radiotherapy. *Head Neck.* 2016;38(S1):E207-E213. <https://doi.org/10.1002/hed.23971>
505. Yin Z-z, Gao L, Luo J-w, et al. Long-term outcomes of patients with esthesioneuroblastomas: a cohort from a single institution. *Oral Oncol.* 2016;53:48-53. <https://doi.org/10.1016/j.oraloncology.2015.11.021>
506. Duru Birgi S, Teo M, Dyker KE, Sen M, Prestwich RJD. Definitive and adjuvant radiotherapy for sinonasal squamous cell carcinomas: a single institutional experience. *Radiat Oncol.* 2015;10:190. <https://doi.org/10.1186/s13014-015-0496-3>
507. Batth SS, Sreeraman R, Dienes E, et al. Clinical-dosimetric relationship between lacrimal gland dose and ocular toxicity after intensity-modulated radiotherapy for sinonasal tumours. *Br J Radiol.* 2013;86(1032):20130459. <https://doi.org/10.1259/bjr.20130459>
508. Fried DV, Zanation AM, Huang B, et al. Patterns of local failure for sinonasal malignancies. *Pract Radiat Oncol.* 2013;3(3):e113-e120. <https://doi.org/10.1016/j.prro.2012.07.001>
509. Guan X, Wang X, Liu Y, Hu C, Zhu G. Lymph node metastasis in sinonasal squamous cell carcinoma treated with IMRT/3D-CRT. *Oral Oncol.* 2013;49(1):60-65. <https://doi.org/10.1016/j.oraloncology.2012.07.009>
510. Kaur G, Kane AJ, Sughrue ME, et al. The prognostic implications of Hyam's subtype for patients with Kadish stage C esthesioneuroblastoma. *J Clin Neurosci.* 2013;20(2):281-286. <https://doi.org/10.1016/j.jocn.2012.05.029>
511. Rajapurkar M, Thankappan K, Sampathirao LMCS, Kuriakose MA, Iyer S. Oncologic and functional outcome of the preserved eye in malignant sinonasal tumors. *Head Neck.* 2013;35(10):1379-1384. <https://doi.org/10.1002/hed.23137>
512. Buiret G, Montbarbon X, Fleury B, et al. Inverted papilloma with associated carcinoma of the nasal cavity and paranasal sinuses: treatment outcomes. *Acta Otolaryngol.* 2012;132(1):80-85. <https://doi.org/10.3109/00016489.2011.620001>
513. Wiegner EA, Daly ME, Murphy JD, et al. Intensity-modulated radiotherapy for tumors of the nasal cavity and paranasal sinuses: clinical outcomes and patterns of failure. *Int J Radiat Oncol Biol Phys.* 2012;83(1):243-251. <https://doi.org/10.1016/j.ijrobp.2011.05.044>
514. Dirix P, Vanstraelen B, Jorissen M, Vander Poorten V, Nuyts S. Intensity-modulated radiotherapy for sinonasal cancer: improved outcome compared to conventional radiotherapy. *Int J Radiat Oncol Biol Phys.* 2010;78(4):998-1004. <https://doi.org/10.1016/j.ijrobp.2009.09.067>
515. Madani I, Bonte K, Vakaet L, Boterberg T, De Neve W. Intensity-modulated radiotherapy for sinonasal tumors: Ghent University Hospital update. *Int J Radiat Oncol Biol Phys.* 2009;73(2):424-432. <https://doi.org/10.1016/j.ijrobp.2008.04.037>
516. Hoppe BS, Nelson CJ, Gomez DR, et al. Unresectable carcinoma of the paranasal sinuses: outcomes and toxicities. *Int J Radiat Oncol Biol Phys.* 2008;72(3):763-769. <https://doi.org/10.1016/j.ijrobp.2008.01.038>
517. Daly ME, Chen AM, Bucci MK, et al. Intensity-modulated radiation therapy for malignancies of the nasal cavity and paranasal sinuses. *Int J Radiat Oncol Biol Phys.* 2007;67(1):151-157. <https://doi.org/10.1016/j.ijrobp.2006.07.1389>
518. Combs SE, Konkel S, Schulz-Ertner D, et al. Intensity modulated radiotherapy (IMRT) in patients with carcinomas of the paranasal sinuses: clinical benefit for complex shaped target volumes. *Radiat Oncol.* 2006;1:23. <https://doi.org/10.1186/1748-717X-1-23>

519. Duthoy W, Boterberg T, Claus F, et al. Postoperative intensity-modulated radiotherapy in sinonasal carcinoma: clinical results in 39 patients. *Cancer*. 2005;104(1):71-82. <https://doi.org/10.1002/cncr.21100>
520. Nakajima K, Iwata H, Hattori Y, et al. Spot scanning proton therapy for sinonasal malignant tumors. *Int J Part Ther*. 2021;8(1):189-199. <https://doi.org/10.14338/IJPT-D-20-00043.1>
521. Hu W, Hu J, Gao J, et al. Intensity-modulated particle beam radiation therapy in the management of olfactory neuroblastoma. *Ann Transl Med*. 2020;8(15):926. <https://doi.org/10.21037/atm-19-4790>
522. Pasalic D, Ludmir EB, Allen PK, et al. Patient-reported outcomes, physician-reported toxicities, and treatment outcomes in a modern cohort of patients with sinonasal cancer treated using proton beam therapy. *Radiother Oncol*. 2020;148:258-266. <https://doi.org/10.1016/j.radonc.2020.05.007>
523. Lee A, Kang J, Yu Y, et al. Trends and disparities of proton therapy use among patients with head and neck cancer: analysis from the national cancer database (2005-14). *Int J Part Ther*. 2019;5(4):1-10. <https://doi.org/10.14338/IJPT-19-00051.1>
524. Yu NY, Gamez ME, Hartsell WF, et al. A multi-institutional experience of proton beam therapy for sinonasal tumors. *Adv Radiat Oncol*. 2019;4(4):689-698. <https://doi.org/10.1016/j.adro.2019.07.008>
525. Dautruche A, Bolle S, Feuvret L, et al. Three-year results after radiotherapy for locally advanced sinonasal adenoid cystic carcinoma, using highly conformational radiotherapy techniques proton therapy and/or tomotherapy. *Cancer/Radiothérapie*. 2018;22(5):411-416. <https://doi.org/10.1016/j.canrad.2017.11.015>
526. Nakamura N, Zenda S, Tahara M, et al. Proton beam therapy for olfactory neuroblastoma. *Radiother Oncol*. 2017;122(3):368-372. <https://doi.org/10.1016/j.radonc.2016.12.020>
527. Dagan R, Bryant C, Li Z, et al. Outcomes of sinonasal cancer treated with proton therapy. *Int J Radiat Oncol Biol Phys*. 2016;95(1):377-385. <https://doi.org/10.1016/j.ijrobp.2016.02.019>
528. Russo AL, Adams JA, Weyman EA, et al. Long-term outcomes after proton beam therapy for sinonasal squamous cell carcinoma. *Int J Radiat Oncol Biol Phys*. 2016;95(1):368-376. <https://doi.org/10.1016/j.ijrobp.2016.02.042>
529. Lucas JT Jr, Ladra MM, MacDonald SM, et al. Proton therapy for pediatric and adolescent esthesioneuroblastoma. *Pediatr Blood Cancer*. 2015;62(9):1523-1528. <https://doi.org/10.1002/pbc.25494>
530. Saito T, Ishikawa H, Ohnishi K, et al. Proton beam therapy for locally advanced and unresectable (T4bN0M0) squamous cell carcinoma of the ethmoid sinus: a report of seven cases and a literature review. *Oncol Lett*. 2015;10(1):201-205. <https://doi.org/10.3892/ol.2015.3214>
531. Zenda S, Kawashima M, Arahira S, et al. Late toxicity of proton beam therapy for patients with the nasal cavity, para-nasal sinuses, or involving the skull base malignancy: importance of long-term follow-up. *Int J Clin Oncol*. 2015;20(3):447-454. <https://doi.org/10.1007/s10147-014-0737-8>
532. Herr MW, Sethi RKV, Meier JC, et al. Esthesioneuroblastoma: an update on the Massachusetts Eye and Ear Infirmary and Massachusetts general Hospital experience with craniofacial resection, proton beam radiation, and chemotherapy. *J Neurol Surg B Skull Base*. 2014;75(1):58-64. <https://doi.org/10.1055/s-0033-1356493>
533. Fukumitsu N, Okumura T, Mizumoto M, et al. Outcome of T4 (International Union Against Cancer Staging System, 7th edition) or recurrent nasal cavity and paranasal sinus carcinoma treated with proton beam. *Int J Radiat Oncol Biol Phys*. 2012;83(2):704-711. <https://doi.org/10.1016/j.ijrobp.2011.07.032>
534. Okano S, Tahara M, Zenda S, et al. Induction chemotherapy with docetaxel, cisplatin and S-1 followed by proton beam therapy concurrent with cisplatin in patients with T4b nasal and sinonasal malignancies. *Jpn J Clin Oncol*. 2012;42(8):691-696. <https://doi.org/10.1093/jjco/hys096>
535. Zenda S, Kohno R, Kawashima M, et al. Proton beam therapy for unresectable malignancies of the nasal cavity and paranasal sinuses. *Int J Radiat Oncol Biol Phys*. 2011;81(5):1473-1478. <https://doi.org/10.1016/j.ijrobp.2010.08.009>
536. Truong MT, Kamat UR, Liebsch NJ, et al. Proton radiation therapy for primary sphenoid sinus malignancies: treatment outcome and prognostic factors. *Head Neck*. 2009;31(10):1297-1308. <https://doi.org/10.1002/hed.21092>
537. Nishimura H, Ogino T, Kawashima M, et al. Proton-beam therapy for olfactory neuroblastoma. *Int J Radiat Oncol Biol Phys*. 2007;68(3):758-762. <https://doi.org/10.1016/j.ijrobp.2006.12.071>
538. Pommier P, Liebsch NJ, Deschler DG, et al. Proton beam radiation therapy for skull base adenoid cystic carcinoma. *Arch Otolaryngol Head Neck Surg*. 2006;132(11):1242. <https://doi.org/10.1001/archotol.132.11.1242>
539. Weber DC, Chan AW, Lessell S, et al. Visual outcome of accelerated fractionated radiation for advanced sinonasal malignancies employing photons/protons. *Radiother Oncol*. 2006;81(3):243-249. <https://doi.org/10.1016/j.radonc.2006.09.009>
540. Fitzek MM, Thornton AF, Varvares M, et al. Neuroendocrine tumors of the sinonasal tract. *Cancer*. 2002;94(10):2623-2634. <https://doi.org/10.1002/cncr.10537>
541. Novikov V, Musabaeva L, Gribova O. Combined modality treatment including neutron therapy for tumors of the nasal cavity and paranasal sinuses. *Adv Mat Res*. 2015;1084:365-368. <https://doi.org/10.4028/www.scientific.net/amr.1084.365>
542. Huber PE, Debus J, Latz D, et al. Radiotherapy for advanced adenoid cystic carcinoma: neutrons, photons or mixed beam? *Radiother Oncol*. 2001;59(2):161-167. [https://doi.org/10.1016/s0167-8140\(00\)00273-5](https://doi.org/10.1016/s0167-8140(00)00273-5)
543. Douglas JG, Laramore GE, Austin-Seymour M, Koh W, Stelzer K, Griffin TW. Treatment of locally advanced adenoid cystic carcinoma of the head and neck with neutron radiotherapy. *Int J Radiat Oncol Biol Phys*. 2000;46(3):551-557. [https://doi.org/10.1016/s0360-3016\(99\)00445-9](https://doi.org/10.1016/s0360-3016(99)00445-9)
544. Douglas JG, Laramore GE, Austin-Seymour M, et al. Neutron radiotherapy for adenoid cystic carcinoma of minor salivary glands. *Int J Radiat Oncol Biol Phys*. 1996;36(1):87-93. [https://doi.org/10.1016/s0360-3016\(96\)00213-1](https://doi.org/10.1016/s0360-3016(96)00213-1)
545. Buchholz TA, Shimotakahara SG, Weymuller EA, Laramore GE, Griffin TW. Neutron radiotherapy for adenoid cystic carcinoma of the head and neck. *Arch Otorhinolaryngol Head Neck Surg*. 1993;119(7):747-752. <https://doi.org/10.1001/archotol.1993.01880190043009>

546. Saroja KR, Mansell J, Hendrickson FR, Cohen L, Lennox A. An update on malignant salivary gland tumors treated with neutrons at Fermilab. *Int J Radiat Oncol Biol Phys.* 1987;13(9):1319-1325. [https://doi.org/10.1016/0360-3016\(87\)90223-9](https://doi.org/10.1016/0360-3016(87)90223-9)
547. Errington RD. Advanced carcinoma of the paranasal sinuses treated with 7.5 MeV fast neutrons. *Bull Cancer.* 1986;73(5):569-576.
548. Vikram B, Strong EW, Shah JP, Spiro RH. Radiation therapy in adenoid-cystic carcinoma. *Int J Radiat Oncol Biol Phys.* 1984;10(2):221-223. [https://doi.org/10.1016/0360-3016\(84\)90007-5](https://doi.org/10.1016/0360-3016(84)90007-5)
549. Kubo N, Kubota Y, Kawamura H, et al. Dosimetric parameters predictive of nasolacrimal duct obstruction after carbon-ion radiotherapy for head and neck carcinoma. *Radiother Oncol.* 2019;141:72-77. <https://doi.org/10.1016/j.radonc.2019.07.022>
550. Jensen AD, Nikoghosyan AV, Lossner K, et al. COSMIC: a regimen of intensity modulated radiation therapy plus dose-escalated, raster-scanned carbon ion boost for malignant salivary gland tumors: results of the prospective phase 2 trial. *Int J Radiat Oncol Biol Phys.* 2015;93(1):37-46. <https://doi.org/10.1016/j.ijrobp.2015.05.013>
551. Musha A, Kubo N, Okano N, et al. Prospective observational study of carbon-ion radiotherapy for non-squamous cell carcinoma of the head and neck in Gunma University. *J Oral Maxillofac Surg Med Pathol.* 2022;34(3):280-286. <https://doi.org/10.1016/j.ajoms.2021.10.012>
552. Bhattacharyya T, Koto M, Ikawa H, Hayashi K, Hagiwara Y, Tsuji H. Assessment of risk factors associated with development of oronasal fistula as a late complication after carbon-ion radiotherapy for head and neck cancer. *Radiother Oncol.* 2020;144:53-58. <https://doi.org/10.1016/j.radonc.2019.10.015>
553. Hagiwara Y, Koto M, Bhattacharyya T, et al. Long-term outcomes and toxicities of carbon-ion radiotherapy in malignant tumors of the sphenoid sinus. *Head Neck.* 2020;42(1):50-58. <https://doi.org/10.1002/hed.25965>
554. Hu W, Hu J, Huang Q, et al. Particle beam radiation therapy for sinonasal malignancies: single institutional experience at the Shanghai Proton and Heavy Ion Center. *Cancer Med.* 2020;9(21):7914-7924. <https://doi.org/10.1002/cam4.3393>
555. Hu W, Hu J, Huang Q, et al. Particle beam radiation therapy for adenoid cystic carcinoma of the nasal cavity and paranasal sinuses. *Front Oncol.* 2020;10:572493. <https://doi.org/10.3389/fonc.2020.572493>
556. Akbaba S, Ahmed D, Mock A, et al. Treatment outcome of 227 patients with sinonasal adenoid cystic carcinoma (ACC) after intensity modulated radiotherapy and active raster-scanning carbon ion boost: a 10-year single-center experience. *Cancers.* 2019;11(11):1705. <https://doi.org/10.3390/cancers11111705>
557. Liermann J, Syed M, Held T, et al. Advanced radiation techniques in the treatment of esthesioneuroblastoma: a 7-year single-institution's clinical experience. *Cancers.* 2018;10(11):457. <https://doi.org/10.3390/cancers10110457>
558. Suefujii H, Koto M, Demizu Y, et al. A retrospective multicenter study of carbon ion radiotherapy for locally advanced olfactory neuroblastomas. *Anticancer Res.* 2018;38(3):1665-1670. <https://doi.org/10.21873/anticancer.12399>
559. Toyomasu Y, Demizu Y, Matsuo Y, et al. Outcomes of patients with sinonasal squamous cell carcinoma treated with particle therapy using protons or carbon ions. *Int J Radiat Oncol Biol Phys.* 2018;101(5):1096-1103. <https://doi.org/10.1016/j.ijrobp.2018.04.041>
560. Sulaiman NS, Demizu Y, Koto M, et al. Multicenter study of carbon-ion radiation therapy for adenoid cystic carcinoma of the head and neck: subanalysis of the Japan Carbon-Ion Radiation Oncology Study Group (J-CROS) Study (1402 HN). *Int J Radiat Oncol Biol Phys.* 2018;100(3):639-646. <https://doi.org/10.1016/j.ijrobp.2017.11.010>
561. Ikawa H, Koto M, Takagi R, et al. Prognostic factors of adenoid cystic carcinoma of the head and neck in carbon-ion radiotherapy: the impact of histological subtypes. *Radiother Oncol.* 2017;123(3):387-393. <https://doi.org/10.1016/j.radonc.2017.04.026>
562. Saitoh JI, Koto M, Demizu Y, et al. A multicenter study of carbon-ion radiation therapy for head and neck adenocarcinoma. *Int J Radiat Oncol Biol Phys.* 2017;99(2):442-449. <https://doi.org/10.1016/j.ijrobp.2017.04.032>
563. Shirai K, Saitoh JI, Musha A, et al. Prospective observational study of carbon-ion radiotherapy for non-squamous cell carcinoma of the head and neck. *Cancer Sci.* 2017;108(10):2039-2044. <https://doi.org/10.1111/cas.13325>
564. Jensen AD, Nikoghosyan AV, Poulakis M, et al. Combined intensity-modulated radiotherapy plus raster-scanned carbon ion boost for advanced adenoid cystic carcinoma of the head and neck results in superior locoregional control and overall survival. *Cancer.* 2015;121(17):3001-3009. <https://doi.org/10.1002/cncr.29443>
565. Koto M, Hasegawa A, Takagi R, et al. Feasibility of carbon ion radiotherapy for locally advanced sinonasal adenocarcinoma. *Radiother Oncol.* 2014;113(1):60-65. <https://doi.org/10.1016/j.radonc.2014.09.009>
566. Morimoto K, Demizu Y, Hashimoto N, et al. Particle radiotherapy using protons or carbon ions for unresectable locally advanced head and neck cancers with skull base invasion†. *Jpn J Clin Oncol.* 2014;44(5):428-434. <https://doi.org/10.1093/jjco/hyu010>
567. Sasahara G, Koto M, Ikawa H, et al. Effects of the dose-volume relationship on and risk factors for maxillary osteoradionecrosis after carbon ion radiotherapy. *Radiat Oncol.* 2014;9(1):92. <https://doi.org/10.1186/1748-717X-9-92>
568. Takagi M, Demizu Y, Hashimoto N, et al. Treatment outcomes of particle radiotherapy using protons or carbon ions as a single-modality therapy for adenoid cystic carcinoma of the head and neck. *Radiother Oncol.* 2014;113(3):364-370. <https://doi.org/10.1016/j.radonc.2014.11.031>
569. Jensen AD, Nikoghosyan AV, Ecker S, Ellerbrock M, Debus J, Mütner MW. Carbon ion therapy for advanced sinonasal malignancies: feasibility and acute toxicity. *Radiat Oncol.* 2011;6:30. <https://doi.org/10.1186/1748-717X-6-30>
570. Mizoe J-E, Tsujii H, Kamada T, et al. Dose escalation study of carbon ion radiotherapy for locally advanced head-and-neck cancer. *Int J Radiat Oncol Biol Phys.* 2004;60(2):358-364. <https://doi.org/10.1016/j.ijrobp.2004.02.067>
571. Li R, Saluja K, Lin M, Hu Z, Cai Z, Zhu H. Sinonasal hamartomas: from nasal chondromesenchymal hamartoma to respiratory epithelial adenomatoid hamartoma. Report of six cases and review of the literature. *Int J Surg Pathol.* 2022;30(4):448-456. <https://doi.org/10.1177/10668969211064211>

572. Wenig BM, Heffner CDK. Respiratory epithelial adenomatoid hamartomas of the sinonasal tract and nasopharynx: a clinicopathologic study of 31 cases. *Ann Otol Rhinol Laryngol*. 1995;104(8):639-645. <https://doi.org/10.1177/000348949510400809>
573. Davison WL, Pearlman AN, Donatelli LA, Conley LM. Respiratory epithelial adenomatoid hamartomas: an increasingly common diagnosis in the setting of nasal polyps. *Am J Rhinol Allergy*. 2016;30(4):139-146. <https://doi.org/10.2500/ajra.2016.30.4338>
574. Ozolek JA, Hunt JL. Tumor suppressor gene alterations in respiratory epithelial adenomatoid hamartoma (REAH): comparison to sinonasal adenocarcinoma and inflamed sinonasal mucosa. *Am J Surg Pathol*. 2006;30(12):1576-1580.
575. Gauchotte G, Marie B, Gallet P, et al. Respiratory epithelial adenomatoid hamartoma: a poorly recognized entity with mast cell recruitment and frequently associated with nasal polyposis. *Am J Surg Pathol*. 2013;37(11):1678-1685. <https://doi.org/10.1097/PAS.0000000000000092>
576. Hawley KA, Pabon S, Hoschar AP, Sindwani R. The presentation and clinical significance of sinonasal respiratory epithelial adenomatoid hamartoma (REAH). *Int Forum Allergy Rhinol*. 2013;3(3):248-253. <https://doi.org/10.1002/alr.21083>
577. Lee JT, Garg R, Brunworth J, Keschner DB, Thompson LD. Sinonasal respiratory epithelial adenomatoid hamartomas: series of 51 cases and literature review. *Am J Rhinol Allergy*. 2013;27(4):322-328. <https://doi.org/10.2500/ajra.2013.27.3905>
578. Nguyen DT, Gauchotte G, Arous F, Vignaud JM, Jankowski R. Respiratory epithelial adenomatoid hamartoma of the nose: an updated review. *Am J Rhinol Allergy*. 2014;28(5):e187-e192. <https://doi.org/10.2500/ajra.2014.28.4085>
579. Issa MJA, Oliveira VRR, Nunes FB, et al. Prevalence of respiratory epithelial adenomatoid hamartomas (REAH) associated with nasal polyposis: an epidemiological study - how to diagnose. *Braz J Otorhinolaryngol*. 2022;88(Suppl. 5):S57-S62. <https://doi.org/10.1016/j.bjorl.2021.09.009>
580. Safi C, Li C, Tabaee A, Ramakrishna R, Riley CA. Outcomes and imaging findings of respiratory epithelial adenomatoid hamartoma: a systematic review. *Int Forum Allergy Rhinol*. 2019;9(6):674-680. <https://doi.org/10.1002/alr.22298>
581. Lorentz C, Marie B, Vignaud JM, Jankowski R. Respiratory epithelial adenomatoid hamartomas of the olfactory clefts. *Eur Arch Otorhinolaryngol*. 2012;269(3):847-852. <https://doi.org/10.1007/s00405-011-1713-9>
582. Nguyen DT, Jankowski R, Bey A, et al. Respiratory epithelial adenomatoid hamartoma is frequent in olfactory cleft after nasalization. *Laryngoscope*. 2020;130(9):2098-2104. <https://doi.org/10.1002/lary.28298>
583. Zhang SN, Jiang Y, Yu LG, et al. Analysis of clinical features of respiratory epithelial adenomatoid hamartoma in the nasal cavity. *Zhonghua Er Bi Yan Hou Tou Jing Wai Ke Za Zhi*. 2019;54(5):373-376. <https://doi.org/10.3760/cma.j.issn.1673-0860.2019.05.011>
584. Nguyen DT, Nguyen-Thi PL, Gauchotte G, Arous F, Vignaud JM, Jankowski R. Predictors of respiratory epithelial adenomatoid hamartomas of the olfactory clefts in patients with nasal polyposis. *Laryngoscope*. 2014;124(11):2461-2465. <https://doi.org/10.1002/lary.24778>
585. Ozolek JA, Barnes EL, Hunt JL. Basal/myoepithelial cells in chronic sinusitis, respiratory epithelial adenomatoid hamartoma, inverted papilloma, and intestinal-type and nonintestinal-type sinonasal adenocarcinoma: an immunohistochemical study. *Arch Pathol Lab Med*. 2007;131(4):530-537. <https://doi.org/10.5858/2007-131-530-MCICSR>
586. de Saint Hilaire T, Rumeau C, Gallet P, Nguyen-Thi PL, Jankowski R, Nguyen DT. Difference between respiratory epithelial adenomatoid hamartomas and small malignant tumours of the olfactory cleft on CT scans in forty-six patients. *Clin Otolaryngol*. 2017;42(6):1421-1425. <https://doi.org/10.1111/coa.12930>
587. Nagouas C, Bastier PL, De Gabory L. Respiratory epithelial adenomatoid hamartomas and olfactory function. *Rev Laryngol Otol Rhinol*. 2014;135(4-5):191-195.
588. Hawley KA, Ahmed M, Sindwani R. CT findings of sinonasal respiratory epithelial adenomatoid hamartoma: a closer look at the olfactory clefts. *AJNR Am J Neuroradiol*. 2013;34(5):1086-1090. <https://doi.org/10.3174/ajnr.A3345>
589. Lima NB, Jankowski R, Georgel T, Grignon B, Guillemin F, Vignaud JM. Respiratory adenomatoid hamartoma must be suspected on CT-scan enlargement of the olfactory clefts. *Rhinology*. 2006;44(4):264-269.
590. Braun JJ, Riehm S, Averous G, Billing A, Veillon F. MRI in respiratory epithelial adenomatoid hamartoma of nasal cavities. *J Neuroradiol*. 2013;40(3):216-219. <https://doi.org/10.1016/j.neurad.2012.04.002>
591. Bignami M, Volpi L, Karligkiotis A, et al. Endoscopic endonasal resection of respiratory epithelial adenomatoid hamartomas of the sinonasal tract. *Int Forum Allergy Rhinol*. 2014;4(12):961-965. <https://doi.org/10.1002/alr.21372>
592. Nguyen DT, Gauchotte G, Nguyen-Thi PL, Jankowski R. Does surgery of the olfactory clefts modify the sense of smell? *Am J Rhinol Allergy*. 2013;27(4):317-321. <https://doi.org/10.2500/ajra.2013.27.3907>
593. Al Hawat A, Mouchon E, De Bonnecaze G, Vergez S, Serrano E. Our experience with respiratory epithelial adenomatoid hamartomas of the olfactory cleft. *Eur Arch Otorhinolaryngol*. 2015;272(10):2867-2870. <https://doi.org/10.1007/s00405-014-3401-z>
594. Vira D, Bhuta S, Wang MB. Respiratory epithelial adenomatoid hamartomas. *Laryngoscope*. 2011;121(12):2706-2709. <https://doi.org/10.1002/lary.22399>
595. Yu Y, Tan CS, Koh LT. Not just another nasal polyp: chondro-osseous respiratory epithelial adenomatoid hamartomas of the sinonasal tract. *Laryngoscope Invest Otolaryngol*. 2021;6(3):376-385. <https://doi.org/10.1002/lio2.580>
596. Mason KA, Navaratnam A, Theodorakopoulou E, Chokkalingam PG. Nasal chondromesenchymal hamartoma (NCMH): a systematic review of the literature with a new case report. *J Otolaryngol Head Neck Surg*. 2015;44(1):28. <https://doi.org/10.1186/s40463-015-0077-3>
597. Vasta LM, Nichols A, Harney LA, et al. Nasal chondromesenchymal hamartomas in a cohort with pathogenic germline variation in DICER1. *Rhinol Online*. 2020;3:15-24. <https://doi.org/10.4193/rhinol/20.007>
598. Schultz KAP, Stewart DR, Kamihara J, et al. DICER1 tumor predisposition. In: Adam MP, Ardinger HH, Pagon RA, et al.,

- eds. *GeneReviews*[®] [Internet]. University of Washington; 1993.
599. Wangaryattawanich P, Agarwal M, Rath T. Imaging features of cartilaginous tumors of the head and neck. *J Clin Imaging Sci.* 2021;11:66. https://doi.org/10.25259/JCIS_186_2021
 600. Li Y, Yang Q-x, Tian X-t, Li B, Li Z. Malignant transformation of nasal chondromesenchymal hamartoma in adult: a case report and review of the literature. *Histol Histopathol.* 2013;28(3):337-344. <https://doi.org/10.14670/HH-28.337>
 601. Tiago RSL, Maia MS, Do Nascimento GMS, Correa JP, Salgado DC. Nasolabial cyst: diagnostic and therapeutical aspects. *Braz J Otorhinolaryngol.* 2008;74(1):39-43. [https://doi.org/10.1016/S1808-8694\(15\)30749-7](https://doi.org/10.1016/S1808-8694(15)30749-7)
 602. Sheikh AB, Chin OY, Fang CH, Liu JK, Baredes S, Eloy JA. Nasolabial cysts: a systematic review of 311 cases. *Laryngoscope.* 2016;126(1):60-66. <https://doi.org/10.1002/lary.25433>
 603. Tababi S, Chahed H, Sellami M, Beltaief N, Sahtout S, Besbes G. Fifty-four cases of nasolabial cysts. *Rev Stomatol Chir Maxillofac.* 2011;112(3):151-154. <https://doi.org/10.1016/j.stomax.2011.03.004>
 604. Boffano P, Gallesio C, Campisi P, Rocchia F. Diagnosis and surgical treatment of a nasolabial cyst. *J Craniofac Surg.* 2011;22(5):1946-1948. <https://doi.org/10.1097/SCS.0b013e31822ea751>
 605. Yuen HW, Julian CYL, Samuel CLY. Nasolabial cysts: clinical features, diagnosis, and treatment. *Br J Oral Maxillofac Surg.* 2007;45(4):293-297. <https://doi.org/10.1016/j.bjoms.2006.08.012>
 606. Wu CM, Su CY. Surgical experience of nasolabial cyst. *J Otolaryngol Soc Repub China.* 1997;32(2):121-124.
 607. Lassaletta Atienza L, Lopez-Rios Moreno F, Garcia Alvarez G, Ballestin C, Gallego Aranda I, Alvarez Vicent JJ. Nasoalveolar cyst. A report of 10 new cases and a review of the literature. *Acta Otorrinolaringol Esp.* 1998;49(7):533-536.
 608. Su CY, Chien CY, Hwang CF. A new transnasal approach to endoscopic marsupialization of the nasolabial cyst. *Laryngoscope.* 1999;109(7 1):1116-1118. <https://doi.org/10.1097/00005537-199907000-00020>
 609. Chao WC, Huang CC, Chang PH, Chen YL, Chen CW, Lee TJ. Management of nasolabial cysts by transnasal endoscopic marsupialization. *Arch Otorhinolaryngol Head Neck Surg.* 2009;135(9):932-935. <https://doi.org/10.1001/archoto.2009.111>
 610. Abou El-Hamd KEDA. Nasolabial cyst: a report of eight cases and a review of the literature. *J Laryngol Otol.* 1999;113(8):747-749. <https://doi.org/10.1017/s0022215100145098>
 611. Vasconcelos RF, Souza PE, Mesquita RA. Retrospective analysis of 15 cases of nasolabial cyst. *Quintessence Int.* 1999;30(9):629-632.
 612. Jin HC, Jae HC, Hee JK, et al. Nasolabial cyst: a retrospective analysis of 18 cases. *Ear Nose Throat J.* 2002;81(2):94-96. <https://doi.org/10.1177/014556130208100212>
 613. Chen CN, Su CY, Lin HC, Hwang CF. Microdebrider-assisted endoscopic marsupialization for the nasolabial cyst: comparisons between sublabial and transnasal approaches. *Am J Rhinol Allergy.* 2009;23(2):232-236. <https://doi.org/10.2500/ajra.2009.23.3254>
 614. Lee J, Baek B, Byun J, Chang H, Lee B, Kim D. Comparison of conventional excision via a sublabial approach and transnasal marsupialization for the treatment of nasolabial cysts: a prospective randomized study. *Clin Exp Otorhinolaryngol.* 2009;2(2):85-89. <https://doi.org/10.3342/ceo.2009.2.2.85>
 615. Liu M, Lou Z, Jin K, Sun J, Chen Z. The feasibility of intranasal endoscopic microwave ablation on the removal of nasolabial cyst: preliminary case series. *Am J Otolaryngol Head Neck Med Surg.* 2021;42(3):103018. <https://doi.org/10.1016/j.amjoto.2021.103018>
 616. Maldonado M, Martínez A, Alobid I, Mullol J. The antrochoanal polyp. *Rhinology.* 2004;42(4):178-182.
 617. Pagella F, Emanuelli E, Pusateri A, et al. Clinical features and management of antrochoanal polyps in children: cues from a clinical series of 58 patients. *Int J Pediatr Otorhinolaryngol.* 2018;114:87-91. <https://doi.org/10.1016/j.ijporl.2018.08.033>
 618. Choudhury N, Hariri A, Saleh H. Endoscopic management of antrochoanal polyps: a single UK centre's experience. *Eur Arch Otorhinolaryngol.* 2015;272(9):2305-2311. <https://doi.org/10.1007/s00405-014-3163-7>
 619. Aydin O, Keskin G, Ustündağ E, Işeri M, Ozkarakaş H. Choanal polyps: an evaluation of 53 cases. *Am J Rhinol.* 2007;21(2):164-168. <https://doi.org/10.2500/ajr.2007.21.2993>
 620. Al-Mazrou K, Bukhari M, Al-Fayez A. Characteristics of antrochoanal polyps in the pediatric age group. *Ann Thorac Med.* 2009;4(3):133-136. <https://doi.org/10.4103/1817-1737.53353>
 621. Chen CL, Wang YT, Yao Y, et al. Inflammatory endotypes and tissue remodeling features in antrochoanal polyps. *Allergy Asthma Immunol Res.* 2021;13(6):863-881. <https://doi.org/10.4168/AAIR.2021.13.6.863>
 622. Zheng H, Tang L, Song B, et al. Inflammatory patterns of antrochoanal polyps in the pediatric age group. *Allergy Asthma Clin Immunol.* 2019;15(1):39. <https://doi.org/10.1186/s13223-019-0352-3>
 623. Hekmatnia A, Shirvani F, Mahmoodi F, Hashemi M. Association of anatomic variations with antrochoanal polyps in paranasal sinus computed tomography scan. *J Res Med Sci.* 2017;22(1):3. <https://doi.org/10.4103/1735-1995.199085>
 624. Başer E, Sarioğlu O, Arslan İB, Çukurova İ. The effect of anatomic variations and maxillary sinus volume in antrochoanal polyp formation. *Eur Arch Otorhinolaryngol.* 2020;277(4):1067-1072. <https://doi.org/10.1007/s00405-019-05762-5>
 625. Choudhury N, Hariri A, Saleh H, Sandison A. Diagnostic challenges of antrochoanal polyps: a review of sixty-one cases. *Clin Otolaryngol.* 2018;43(2):670-674. <https://doi.org/10.1111/coa.12993>
 626. Lee DH, Yoon TM, Lee JK, Lim SC. Difference of antrochoanal polyp between children and adults. *Int J Pediatr Otorhinolaryngol.* 2016;84:143-146. <https://doi.org/10.1016/j.ijporl.2016.03.004>
 627. Frosini P, Picarella G, De Campora E. Antrochoanal polyp: analysis of 200 cases. *Acta Otorhinolaryngol Ital.* 2009;29(1):21-26.
 628. Thompson LDR, Fanburg-Smith JC. Update on select benign mesenchymal and meningotheial sinonasal tract lesions. *Head Neck Pathol.* 2016;10(1):95-108. <https://doi.org/10.1007/s12105-016-0697-6>
 629. Galluzzi F, Pignataro L, Maddaloni M, Garavello W. Recurrences of surgery for antrochoanal polyps in children: a sys-

- tematic review. *Int J Pediatr Otorhinolaryngol.* 2018;106:26-30. <https://doi.org/10.1016/j.ijporl.2017.12.035>
630. El-Sharkawy AA. Endoscopic management of paediatric antrochoanal polyp: our experience. *Acta Otorhinolaryngol Ital.* 2013;33(2):107-111.
 631. Franche GLDS, Granzotto EH, De Borba AT, Hermes F, Saleh CDS, De Souza PA. Endoscopic polypectomy with middle meatal antrostomy for antrochoanal polyp treatment. *Braz J Otorhinolaryngol.* 2007;73(5):689-692. [https://doi.org/10.1016/s1808-8694\(15\)30131-2](https://doi.org/10.1016/s1808-8694(15)30131-2)
 632. Sato K, Nakashima T. Endoscopic sinus surgery for antrochoanal polyp using CO2 laser and/or microresector: a long-term result. *J Laryngol Otol.* 2005;119(5):362-365. <https://doi.org/10.1258/0022215053945732>
 633. Lee TJ, Huang SF. Endoscopic sinus surgery for antrochoanal polyps in children. *Otolaryngol Head Neck Surg.* 2006;135(5):688-692. <https://doi.org/10.1016/j.otohns.2006.02.035>
 634. Eladl HM, Elmorsy SM. Endoscopic surgery in pediatric recurrent antrochoanal polyp, rule of wide ostium. *Int J Pediatr Otorhinolaryngol.* 2011;75(11):1372-1375. <https://doi.org/10.1016/j.ijporl.2011.07.029>
 635. Bozzo C, Garrel R, Meloni F, Stomeo F, Crampette L. Endoscopic treatment of antrochoanal polyps. *Eur Arch Otorhinolaryngol.* 2007;264(2):145-150. <https://doi.org/10.1007/s00405-006-0175-y>
 636. Chung SK, Chang BC, Dhong HJ. Surgical, radiologic, and histologic findings of the antrochoanal polyp. *Am J Rhinol.* 2002;16(2):71-76. <https://doi.org/10.1177/194589240201600201>
 637. Zheng W, Hu G, Liu B, et al. Observe the origin of antrochoanal polyp and the comparison of the curative effect of antrochoanal polyp. *Lin Chung Er Bi Yan Hou Tou Jing Wai Ke Za Zhi.* 2016;30(3):209-212.
 638. Ozer F, Ozer C, Cagici CA, Canbolat T, Yilmazer C, Akkuzu B. Surgical approaches for antrochoanal polyp: a comparative analysis. *B-ENT.* 2008;4(2):93-99.
 639. Mantilla E, Villamor P, De La Torre C, Álvarez-Neri H. Combined approach for paediatric recurrent antrochoanal polyp: a single-centre case series of 27 children. *J Laryngol Otol.* 2019;133(7):627-631. <https://doi.org/10.1017/S0022215119000938>
 640. Nikakhlagh S, Rahim F, Saki N, Mohammadi H, Maliheh YM. Antrochoanal polyps: report of 94 cases and review the literature. *Niger J Med.* 2012;21(2):156-159.
 641. Voegels RL, Moraes FV, Angelico F Jr, Kii MA, Poderoso M, Butugan O. Antrochoanal polyposis: review of 101 cases. *Rev Bras Otorrinolaringol.* 2000;66(2):161-164.
 642. Balikci HH, Ozkul MH, Uvacin O, Yasar H, Karakas M, Gurdal M. Antrochoanal polyposis: analysis of 34 cases. *Eur Arch Otorhinolaryngol.* 2013;270(5):1651-1654. <https://doi.org/10.1007/s00405-012-2274-2>
 643. Weindorf SC, Brown NA, McHugh JB, Udager AM. Sinonasal papillomas and carcinomas: a contemporary update with review of an emerging molecular classification. *Arch Pathol Lab Med.* 2019;143(11):1304-1316. <https://doi.org/10.5858/arpa.2019-0372-RA>
 644. Sbrana MF, Borges RFR, Pinna F de R, Neto DB, Voegels RL. Sinonasal inverted papilloma: rate of recurrence and malignant transformation in 44 operated patients. *Braz J Otorhinolaryngol.* 2021;87(1):80-84. <https://doi.org/10.1016/j.bjorl.2019.07.003>
 645. Vorasubin N, Vira D, Suh JD, Bhuta S, Wang MB. Schneiderian papillomas: comparative review of exophytic, oncocytic, and inverted types. *Am J Rhinol Allergy.* 2013;27(4):287-292. <https://doi.org/10.2500/ajra.2013.27.3904>
 646. Bishop JA. OSPs and ESPs and ISPs, Oh My! an update on sinonasal (Schneiderian) papillomas. *Head Neck Pathol.* 2017;11(3):269-277. <https://doi.org/10.1007/s12105-017-0799-9>
 647. Barnes L. Schneiderian papillomas and nonsalivary glandular neoplasms of the head and neck. *Mod Pathol.* 2002;15(3):279-297. <https://doi.org/10.1038/modpathol.3880524>
 648. Batsakis JG, Suarez P. Schneiderian papillomas and carcinomas: a review. *Adv Anat Pathol.* 2001;8(2):53-64. <https://doi.org/10.1097/00125480-200103000-00001>
 649. Katori H, Nozawa A, Tsukuda M. Markers of malignant transformation of sinonasal inverted papilloma. *Eur J Surg Oncol.* 2005;31(8):905-911. <https://doi.org/10.1016/j.ejso.2005.05.014>
 650. Katori H, Nozawa A, Tsukuda M. Increased expression of matrix metalloproteinase-2 and 9 and human papilloma virus infection are associated with malignant transformation of sinonasal inverted papilloma. *J Surg Oncol.* 2006;93(1):80-85. <https://doi.org/10.1002/jso.20386>
 651. Katori H, Nozawa A, Tsukuda M. Relationship between p21 and p53 expression, human papilloma virus infection and malignant transformation in sinonasal-inverted papilloma. *Clin Oncol.* 2006;18(4):300-305. <https://doi.org/10.1016/j.clon.2005.11.001>
 652. Viitasalo S, Ilmarinen T, Aaltonen L, et al. Sinonasal inverted papilloma – malignant transformation and non-sinonasal malignancies. *Laryngoscope.* 2023;133(3):506-511. <https://doi.org/10.1002/lary.30128>
 653. Nudell J, Chiosea S, Thompson LDR. Carcinoma ex-Schneiderian papilloma (malignant transformation): a clinicopathologic and immunophenotypic study of 20 cases combined with a comprehensive review of the literature. *Head Neck Pathol.* 2014;8(3):269-286. <https://doi.org/10.1007/s12105-014-0527-7>
 654. Buchwald C, Lindeberg H, Pedersen BL, Franzmann MB. Human papilloma virus and p53 expression in carcinomas associated with sinonasal papillomas: a Danish epidemiological study 1980–1998. *Laryngoscope.* 2001;111(6):1104-1110. <https://doi.org/10.1097/00005537-200106000-00032>
 655. Cheung FMF, Lau TWS, Cheung LKN, Li ASM, Chow SK, Lo AWI. Schneiderian papillomas and carcinomas: a retrospective study with special reference to p53 and p16 tumor suppressor gene expression and association with HPV. *Ear Nose Throat J.* 2010;89(10):E5-E12. <https://doi.org/10.1177/014556131008901002>
 656. Rha MS, Kim CH, Yoon JH, Cho HJ. Association of the human papillomavirus infection with the recurrence of sinonasal inverted papilloma: a systematic review and meta-analysis. *Rhinology.* 2022;60(1):2-10. <https://doi.org/10.4193/Rhin21.255>
 657. Lawson W, Schlecht NF, Brandwein-Gensler M. The role of the human papillomavirus in the pathogenesis of Schneiderian inverted papillomas: an analytic overview of the evidence. *Head and Neck Pathol.* 2008;2(2):49-59. <https://doi.org/10.1007/s12105-008-0048-3>

658. Udager AM, McHugh JB, Betz BL, et al. Activating *KRAS* mutations are characteristic of oncogenic sinonasal papilloma and associated sinonasal squamous cell carcinoma: *KRAS* -mutated oncogenic sinonasal tumours. *J Pathol*. 2016;239(4):394-398. <https://doi.org/10.1002/path.4750>
659. Udager AM, Rolland DCM, McHugh JB, et al. High-frequency targetable *EGFR* mutations in sinonasal squamous cell carcinomas arising from inverted sinonasal papilloma. *Cancer Res*. 2015;75(13):2600-2606. <https://doi.org/10.1158/0008-5472.CAN-15-0340>
660. Brown NA, Plouffe KR, Yilmaz O, et al. TP53 mutations and CDKN2A mutations/deletions are highly recurrent molecular alterations in the malignant progression of sinonasal papillomas. *Mod Pathol*. 2021;34(6):1133-1142. <https://doi.org/10.1038/s41379-020-00716-3>
661. Nishikawa D, Sasaki E, Suzuki H, et al. Treatment outcome and pattern of recurrence of sinonasal squamous cell carcinoma with *EGFR*-mutation and human papillomavirus. *J Craniomaxillofac Surg*. 2021;49(6):494-500. <https://doi.org/10.1016/j.jcms.2021.02.016>
662. Rooper LM, Bishop JA, Westra WH. Transcriptionally active high-risk human papillomavirus is not a common etiologic agent in the malignant transformation of inverted Schneiderian papillomas. *Head and Neck Pathol*. 2017;11(3):346-353. <https://doi.org/10.1007/s12105-017-0779-0>
663. Stepp WH, Farzal Z, Kimple AJ, et al. HPV in the malignant transformation of sinonasal inverted papillomas: a meta-analysis. *Int Forum Allergy Rhinol*. 2021;11(10):1461-1471. <https://doi.org/10.1002/alr.22810>
664. Lewis JS, Westra WH, Thompson LDR, et al. The sinonasal tract: another potential "hot spot" for carcinomas with transcriptionally-active human papillomavirus. *Head and Neck Pathol*. 2014;8(3):241-249. <https://doi.org/10.1007/s12105-013-0514-4>
665. Tong CCL, Palmer JN. Updates in the cause of sinonasal inverted papilloma and malignant transformation to squamous cell carcinoma. *Curr Opin Otolaryngol Head Neck Surg*. 2021;29(1):59-64. <https://doi.org/10.1097/MOO.0000000000000692>
666. Mehrad M, Stelow EB, Bishop JA, et al. Transcriptionally active HPV and targetable *EGFR* mutations in sinonasal inverted papilloma: an association between low-risk HPV, condylomatous morphology, and cancer risk? *Am J Surg Pathol*. 2020;44(3):340-346. <https://doi.org/10.1097/PAS.0000000000001411>
667. Udager AM, McHugh JB, Goudsmit CM, et al. Human papillomavirus (HPV) and somatic *EGFR* mutations are essential, mutually exclusive oncogenic mechanisms for inverted sinonasal papillomas and associated sinonasal squamous cell carcinomas. *Ann Oncol*. 2018;29(2):466-471. <https://doi.org/10.1093/annonc/mdx736>
668. Udager AM, McHugh JB, Elenitoba-Johnson KSJ, Brown NA. *EGFR* mutations in sinonasal squamous tumors: oncogenic and therapeutic implications. *Oncoscience*. 2015;2(11):908-909. <https://doi.org/10.18632/oncoscience.268>
669. Cabal VN, Menendez M, Vivanco B, et al. *EGFR* mutation and HPV infection in sinonasal inverted papilloma and squamous cell carcinoma. *Rhinology*. 2020;58(4):368-376. <https://doi.org/10.4193/Rhin19.371>
670. Hasegawa M, Deng Z, Maeda H, et al. Human papillomavirus load and physical status in sinonasal inverted papilloma and squamous cell carcinoma. *Rhinology*. 2012;50(1):87-94. <https://doi.org/10.4193/Rhino.11.106>
671. Hoffmann M, Klose N, Gottschlich S, et al. Detection of human papillomavirus DNA in benign and malignant sinonasal neoplasms. *Cancer Lett*. 2006;239(1):64-70. <https://doi.org/10.1016/j.canlet.2005.07.019>
672. Hongo T, Yamamoto H, Jiromaru R, et al. Clinicopathologic significance of *EGFR* mutation and HPV infection in sinonasal squamous cell carcinoma. *Am J Surg Pathol*. 2021;45(1):108-118. <https://doi.org/10.1097/PAS.0000000000001566>
673. Grayson JW, Khichi SS, Cho DY, Riley KO, Woodworth BA. Management strategies for skull base inverted papilloma. *Otolaryngol Head Neck Surg*. 2016;155(1):179-183. <https://doi.org/10.1177/0194599816639019>
674. Wood JW, Casiano RR. Inverted papillomas and benign non-neoplastic lesions of the nasal cavity. *Am J Rhinol Allergy*. 2012;26(2):157-163. <https://doi.org/10.2500/ajra.2012.26.3732>
675. Strojjan P, Jereb S, Borsos I, But-Hadzic J, Zidar N. Radiotherapy for inverted papilloma: a case report and review of the literature. *Radiol Oncol*. 2013;47(1):71-76. <https://doi.org/10.2478/v10019-012-0045-8>
676. Wassef SN, Batra PS, Barnett S. Skull base inverted papilloma: a comprehensive review. *ISRN Surg*. 2012;2012:175903. <https://doi.org/10.5402/2012/175903>
677. Day TA, Beas RA, Schlosser RJ, et al. Management of paranasal sinus malignancy. *Curr Treat Options Oncol*. 2005;6(1):3-18.
678. Wang J, Ford J, Esmali B, et al. Inverted papilloma of the orbit and nasolacrimal system. *Ophthalmic Plast Reconstr Surg*. 2021;37(2):161-167. <https://doi.org/10.1097/IOP.0000000000001719>
679. Elner VM, Burnstine MA, Goodman ML, Dortzbach RK. Inverted papillomas that invade the orbit. *Arch Ophthalmol*. 1995;113(9):1178-1183. <https://doi.org/10.1001/archophth.1995.01100090104030>
680. Johnson LN, Krohel GB, Yeon EB, Parnes SM. Sinus tumors invading the orbit. *Ophthalmology*. 1984;91(3):209-217. [https://doi.org/10.1016/s0161-6420\(84\)34300-7](https://doi.org/10.1016/s0161-6420(84)34300-7)
681. Saldana M, Wearne M, Beigi B, Petrarca R. Inverted papillomas of the nasal and paranasal sinuses that involve the ocular/adnexal region. *Orbit*. 2013;32(6):366-369. <https://doi.org/10.3109/01676830.2013.833251>
682. Chaudhry IA, Taiba K, Al-Sadhan Y, Riley FC. Inverted papilloma invading the orbit through the nasolacrimal duct: a case report. *Orbit*. 2005;24(2):135-139. <https://doi.org/10.1080/01676830590926530>
683. Shin M, Kondo K, Hanakita S, et al. Endoscopic transnasal approach for resection of locally aggressive tumors in the orbit. *J Neurosurg*. 2015;123(3):748-759. <https://doi.org/10.3171/2014.11.JNS141921>
684. Lee JJ, Orłowski HLP, Schneider JS, et al. Computed tomography as a predictor of sinonasal inverted papilloma origin, skull base involvement, and stage. *J Neurol Surg B Skull Base*. 2021;82(Suppl. 3):e335-e341. <https://doi.org/10.1055/s-0040-1701677>

685. Klimek T, Atai E, Schubert M, Glanz H. Inverted papilloma of the nasal cavity and paranasal sinuses: clinical data, surgical strategy and recurrence rates. *Acta Otolaryngol.* 2000;120(2):267-272. <https://doi.org/10.1080/000164800750001071>
686. Castelnovo P, Dallan I, Battaglia P, Bignami M. Endoscopic endonasal skull base surgery: past, present and future. *Eur Arch Otorhinolaryngol.* 2010;267(5):649-663. <https://doi.org/10.1007/s00405-009-1196-0>
687. Chiu AG, Jackman AH, Antunes MB, Feldman MD, Palmer JN. Radiographic and histologic analysis of the bone underlying inverted papillomas. *Laryngoscope.* 2006;116(9):1617-1620. <https://doi.org/10.1097/01.mlg.0000230401.88711.e6>
688. Endo R, Ishitoya J, Kawano T, et al. A study of surgical procedures for inverted papilloma in the nasal cavity and paranasal sinuses. *Nihon Jibiinkoka Gakkai Kaiho.* 2008;111(8):581-587. <https://doi.org/10.3950/jibiinkoka.111.581>
689. Gras-Cabrerizo JR, Muñoz-Hernández F, Montserrat-Gili JR, et al. Endoscopic surgery in the skull base unit: experience in the first 72 cases. *Acta Otorrinolaringol Esp.* 2013;64(3):169-175. <https://doi.org/10.1016/j.otorri.2012.10.006>
690. Conger BT, Illing E, Bush B, Woodworth BA. Management of lateral frontal sinus pathology in the endoscopic era. *Otolaryngol Head Neck Surg.* 2014;151(1):159-163. <https://doi.org/10.1177/0194599814529078>
691. Albathi M, Ramanathan M, Lane AP, Boahene KDO. Combined endonasal and eyelid approach for management of extensive frontal sinus inverting papilloma. *Laryngoscope.* 2018;128(1):3-9. <https://doi.org/10.1002/lary.26552>
692. Pietrobon G, Karligkiotis A, Turri-Zanoni M, et al. Surgical management of inverted papilloma involving the frontal sinus: a practical algorithm for treatment planning. *Acta Otorhinolaryngol Ital.* 2019;39(1):28-39. <https://doi.org/10.14639/0392-100X-2313>
693. Mabery TE, Devine KD, Harrison EG. The problem of malignant transformation in a nasal papilloma: report of a case. *Arch Otolaryngol.* 1965;82:296-300. <https://doi.org/10.1001/archotol.1965.00760010298016>
694. Snyder RN, Perzin KH. Papillomatosis of nasal cavity and paranasal sinuses (inverted papilloma, squamous papilloma). A clinicopathologic study. *Cancer.* 1972;30(3):668-690. [https://doi.org/10.1002/1097-0142\(197209\)30:3\(668::aid-cncr2820300315\)3.0.co;2-b](https://doi.org/10.1002/1097-0142(197209)30:3(668::aid-cncr2820300315)3.0.co;2-b)
695. Suh KW, Facer GW, Devine KD, Weiland LH, Zujko RD. Inverting papilloma of the nose and paranasal sinuses. *Laryngoscope.* 1977;87(1):35-46. <https://doi.org/10.1288/00005537-197701000-00005>
696. Woodson GE, Robbins KT, Michaels L. Inverted papilloma. Considerations in treatment. *Arch Otolaryngol.* 1985;111(12):806-811. <https://doi.org/10.1001/archotol.1985.00800140050009>
697. Hug EB, Wang CC, Montgomery WW, Goodman ML. Management of inverted papilloma of the nasal cavity and paranasal sinuses: importance of radiation therapy. *Int J Radiat Oncol Biol Phys.* 1993;26(1):67-72. [https://doi.org/10.1016/0360-3016\(93\)90174-t](https://doi.org/10.1016/0360-3016(93)90174-t)
698. Gomez JA, Mendenhall WM, Tannehill SP, Stringer SP, Cassisi NJ. Radiation therapy in inverted papillomas of the nasal cavity and paranasal sinuses. *Am J Otolaryngol.* 2000;21(3):174-178. [https://doi.org/10.1016/s0196-0709\(00\)85020-6](https://doi.org/10.1016/s0196-0709(00)85020-6)
699. Weissler MC, Montgomery WW, Turner PA, Montgomery SK, Joseph MP. Inverted papilloma. *Ann Otol Rhinol Laryngol.* 1986;95(3 Pt 1):215-221. <https://doi.org/10.1177/000348948609500301>
700. Rutenberg M, Kirwan J, Morris CG, Werning JW, Mendenhall WM. Radiation therapy for sinonasal inverted papilloma. *Pract Radiat Oncol.* 2013;3(4):275-281. <https://doi.org/10.1016/j.prro.2012.07.007>
701. Adriaensen GFJPM, Lim KH, Georgalas C, Reinartz SM, Fokkens WJ. Challenges in the management of inverted papilloma: a review of 72 revision cases. *Laryngoscope.* 2016;126(2):322-328. <https://doi.org/10.1002/lary.25522>
702. Yang P, Meng G, Shu Q, et al. A short-term efficacy of anlotinib in the treatment of refractory nasopharyngeal inverted papilloma: a case report. *Front Oncol.* 2021;11:648895. <https://doi.org/10.3389/fonc.2021.648895>
703. Suh JD, Palma-Diaz F, Bhuta S, Wang MB. COX-(2) overexpression in sinonasal inverted papilloma. *Int Forum Allergy Rhinol.* 2013;3(12):997-1000. <https://doi.org/10.1002/alr.21218>
704. Sirera G, Videla S, Vergés J, Chamorro A, Cañadas M, Clotet B. Aggressive human papillomavirus (HPV)-11-related sinonasal inverted papilloma in an HIV-infected patient and the quadrivalent HPV vaccine: a case report. *AIDS.* 2015;29(17):2366-2368. <https://doi.org/10.1097/QAD.0000000000000870>
705. Kuan EC, Frederick JW, Palma Diaz MF, Lim DW, Suh JD. Complete response of skull base inverted papilloma to chemotherapy: case report. *Allergy Rhinol.* 2017;8(2):105-108. <https://doi.org/10.2500/ar.2017.8.0201>
706. Spinos D, Kalamatianos T, Terzakis D, Piagkou M, Georgalas C. Treatment strategies for inverted papillomas with intracranial or intraorbital involvement. *J Laryngol Otol.* 2021;135(10):904-910. <https://doi.org/10.1017/S0022215121002152>
707. Wang Y, An Y, Zhao C, Dong R, Cheng F. Attachment-oriented endoscopic treatment of inverted papilloma involving the frontal sinus/recess. *J Craniofac Surg.* 2020;31(8):e778-e781. <https://doi.org/10.1097/SCS.00000000000006742>
708. Bhalla RK, Wright ED. Predicting the site of attachment of sinonasal inverted papilloma. *Rhinology.* 2009;47(4):345-348. <https://doi.org/10.4193/Rhin08.229>
709. Fang G, Lou H, Yu W, et al. Prediction of the originating site of sinonasal inverted papilloma by preoperative magnetic resonance imaging and computed tomography. *Int Forum Allergy Rhinol.* 2016;6(12):1221-1228. <https://doi.org/10.1002/alr.21836>
710. Ferrari M, Schreiber A, Mattavelli D, et al. How aggressive should resection of inverted papilloma be? Refinement of surgical planning based on the 25-year experience of a single tertiary center. *Int Forum Allergy Rhinol.* 2020;10(5):619-628. <https://doi.org/10.1002/alr.22541>
711. Lee DK, Chung SK, Dhong HJ, Kim HY, Kim HJ, Bok KH. Focal hyperostosis on CT of sinonasal inverted papilloma as a predictor of tumor origin. *AJNR Am J Neuroradiol.* 2007;28(4):618-621.
712. Chawla A, Shenoy J, Chokkappan K, Chung R. Imaging features of sinonasal inverted papilloma: a pictorial review. *Curr Probl Diagn Radiol.* 2016;45(5):347-353. <https://doi.org/10.1067/j.cpradiol.2015.10.004>

713. Maroldi R, Farina D, Palvarini L, Lombardi D, Tomenzoli D, Nicolai P. Magnetic resonance imaging findings of inverted papilloma: differential diagnosis with malignant sinonasal tumors. *Am J Rhinol*. 2004;18(5):305-310.
714. Yousuf K, Wright ED. Site of attachment of inverted papilloma predicted by CT findings of osteitis. *Am J Rhinol*. 2007;21(1):32-36. <https://doi.org/10.2500/ajr.2007.21.2984>
715. Liang N, Huang Z, Liu H, Xian J, Huang Q, Zhou B. Bone involvement: histopathological evidence for endoscopic management of sinonasal inverted papilloma. *Laryngoscope*. 2017;127(12):2703-2708. <https://doi.org/10.1002/lary.26659>
716. Xiao-Ting W, Peng L, Xiu-Qing W, et al. Factors affecting recurrence of sinonasal inverted papilloma. *Eur Arch Otorhinolaryngol*. 2013;270(4):1349-1353. <https://doi.org/10.1007/s00405-012-2216-z>
717. Roh HJ, Mun SJ, Cho KS, Hong SL. Smoking, not human papilloma virus infection, is a risk factor for recurrence of sinonasal inverted papilloma. *Am J Rhinol Allergy*. 2016;30(2):79-82. <https://doi.org/10.2500/ajra.2016.30.4272>
718. Kraft M, Simmen D, Casas R, Pfaltz M. Significance of human papillomavirus in sinonasal papillomas. *J Laryngol Otol*. 2001;115(9):709-714. <https://doi.org/10.1258/0022215011908955>
719. Omura K, Nomura K, Aoki S, et al. Resection of inverted papilloma in nasal cavity with transseptal access and crossing multiple incisions minimizes bleeding and reveals the tumor pedicle. *Auris Nasus Larynx*. 2020;47(3):410-414. <https://doi.org/10.1016/j.anl.2019.10.006>
720. Suh JD, Ramakrishnan VR, Thompson CF, et al. Inverted papilloma of the sphenoid sinus: risk factors for disease recurrence. *Laryngoscope*. 2015;125(3):544-548. <https://doi.org/10.1002/lary.24929>
721. Woodworth BA, Bhargava GA, Palmer JN, et al. Clinical outcomes of endoscopic and endoscopic-assisted resection of inverted papillomas: a 15-year experience. *Am J Rhinol*. 2007;21(5):591-600. <https://doi.org/10.2500/ajr.2007.21.3086>
722. Wang C, Han D, Zhang L. Modified endoscopic maxillary medial sinusotomy for sinonasal inverted papilloma with attachment to the anterior medial wall of maxillary sinus. *ORL J Otorhinolaryngol Relat Spec*. 2012;74(2):97-101. <https://doi.org/10.1159/000336739>
723. Ghosh A, Pal S, Srivastava A, Saha S. Modification of endoscopic medial maxillectomy: a novel approach for inverted papilloma of the maxillary sinus. *J Laryngol Otol*. 2015;129(2):159-163. <https://doi.org/10.1017/S0022215114003144>
724. Sanderson RJ, Knecht P. Management of inverted papilloma via Denker's approach. *Clin Otolaryngol Allied Sci*. 1999;24(1):69-71. <https://doi.org/10.1046/j.1365-2273.1999.00221.x>
725. Woodworth BA, Parker RO, Schlosser RJ. Modified endoscopic medial maxillectomy for chronic maxillary sinusitis. *Am J Rhinol*. 2006;20(3):317-319. <https://doi.org/10.2500/ajr.2006.20.2850>
726. Tong CCL, Patel NN, Maina IW, et al. Inverted papilloma with multifocal attachment is associated with increased recurrence. *Int Forum Allergy Rhinol*. 2019;9(8):865-869. <https://doi.org/10.1002/alr.22342>
727. Peng P, Har-El G. Management of inverted papillomas of the nose and paranasal sinuses. *Am J Otolaryngol*. 2006;27(4):233-237. <https://doi.org/10.1016/j.amjoto.2005.11.005>
728. Minni A, Gera R, Bulgheroni C, et al. Endoscopic resection of sinonasal inverted papilloma: a multivariate retrospective analysis of factors affecting recurrence and persistence. *Ear Nose Throat J*. 2021;100(5_suppl):542S-548S. <https://doi.org/10.1177/0145561319890454>
729. Viitasalo S, Ilmarinen T, Lilja M, et al. HPV-positive status is an independent factor associated with sinonasal inverted papilloma recurrence. *Laryngoscope*. 2022;132(9):1714-1718. <https://doi.org/10.1002/lary.29910>
730. Pähler vor der Holte A, Fangk I, Glombitza S, Wilkens L, Welkoborsky HJ. Prognostic factors and risk factors for development and recurrence of sinonasal papillomas: potential role of different HPV subtypes. *Eur Arch Otorhinolaryngol*. 2020;277(3):767-775. <https://doi.org/10.1007/s00405-019-05747-4>
731. Moon IJ, Lee DY, Suh MW, et al. Cigarette smoking increases risk of recurrence for sinonasal inverted papilloma. *Am J Rhinol Allergy*. 2010;24(5):325-329. <https://doi.org/10.2500/ajra.2010.24.3510>
732. Lisan Q, Moya-Plana A, Bonfils P. Association of Krouse classification for sinonasal inverted papilloma with recurrence: a systematic review and meta-analysis. *JAMA Otolaryngol Head Neck Surg*. 2017;143(11):1104-1110. <https://doi.org/10.1001/jamaoto.2017.1686>
733. van Zijl FVWJ, Monserez DA, Korevaar TIM, et al. Postoperative value of serum squamous cell carcinoma antigen as a predictor of recurrence in sinonasal inverted papilloma. *Clin Otolaryngol*. 2017;42(3):528-535. <https://doi.org/10.1111/coa.12757>
734. Kim JY, Kim SH, Jang P, et al. Inverted papilloma of the maxillary sinus: a recurrence analysis according to surgical approaches. *J Clin Med*. 2022;11(11):3020. <https://doi.org/10.3390/jcm11113020>
735. Ungari C, Riccardi E, Reale G, et al. Management and treatment of sinonasal inverted papilloma. *Ann Stomatol*. 2015;6(3-4):87-90. <https://doi.org/10.11138/ads/2015.6.3.087>
736. Díaz Molina JP, Llorente Pendas JL, Rodrigo Tapia JP, Alvarez Marcos C, Obeso Agüera S, Suárez Nieto C. Inverted sinonasal papillomas. Review of 61 cases. *Acta Otorrinolaryngol Esp*. 2009;60(6):402-408. <https://doi.org/10.1016/j.otorri.2009.05.002>
737. Peng R, Thamboo A, Choby G, Ma Y, Zhou B, Hwang PH. Outcomes of sinonasal inverted papilloma resection by surgical approach: an updated systematic review and meta-analysis. *Int Forum Allergy Rhinol*. 2019;9(6):573-581. <https://doi.org/10.1002/alr.22305>
738. Bugter O, Monserez DA, van Zijl FVWJ, Baatenburg de Jong RJ, Hardillo JA. Surgical management of inverted papilloma; a single-center analysis of 247 patients with long follow-up. *J Otolaryngol Head Neck Surg*. 2017;46(1):67. <https://doi.org/10.1186/s40463-017-0246-7>
739. Binz GHA, Soyka MB, Holzmann D, Meerwein CM. Need for long-term follow-up in sinonasal inverted papilloma: a single-institution experience. *Head Neck*. 2021;43(2):630-638. <https://doi.org/10.1002/hed.26523>
740. Lisan Q, Laccourreye O, Bonfils P. Sinonasal inverted papilloma: from diagnosis to treatment. *Eur Ann Otorhinolaryngol Head Neck Dis*. 2016;133(5):337-341. <https://doi.org/10.1016/j.anorl.2016.03.006>

741. Petit P, Vivarrat-Perrin L, Champsaur P, et al. Radiological follow-up of inverted papilloma. *Eur Radiol.* 2000;10(7):1184-1189. <https://doi.org/10.1007/s003309900292>
742. Huchet V, Cockenpot V, Lesnik M, Luporsi M, Jehanno N. A rare cause of SCC antigen elevation: inverted sinonasal papilloma. *Clin Nucl Med.* 2021;46(12):e587-e588. <https://doi.org/10.1097/RLU.0000000000003821>
743. Allegra E, Lombardo N, Cascini G, La Boria A, Garozzo A, Tamburrini O. Possible role of 18FDG-PET/CT for the surveillance of sinonasal inverted papilloma. *Clin Otolaryngol.* 2010;35(3):249-251. <https://doi.org/10.1111/j.1749-4486.2010.02131.x>
744. McCormick JP, Suh JD, Lee JT, Wells C, Wang MB. Role of high-risk HPV detected by PCR in malignant sinonasal inverted papilloma: a meta-analysis. *Laryngoscope.* 2022;132(5):926-932. <https://doi.org/10.1002/lary.29735>
745. Ding R, Sun Q, Wang Y. Association between human papilloma virus infection and malignant sinonasal inverted papilloma. *Laryngoscope.* 2021;131(6):1200-1205. <https://doi.org/10.1002/lary.29125>
746. Zhao RW, Guo ZQ, Zhang RX. Human papillomavirus infection and the malignant transformation of sinonasal inverted papilloma: a meta-analysis. *J Clin Virol.* 2016;79:36-43. <https://doi.org/10.1016/j.jcv.2016.04.001>
747. Paehler vor der Holte A, Fangk I, Glombitza S, Wilkens L, Welkoborsky HJ. Impact of human papillomaviruses (HPV) on recurrence rate and malignant progression of sinonasal papillomas. *Cancer Med.* 2021;10(2):634-641. <https://doi.org/10.1002/cam4.3642>
748. Li W, Lu H, Zhang H, Sun X, Hu L, Wang D. Squamous cell carcinoma associated with inverted papilloma: recurrence and prognostic factors. *Oncol Lett.* 2020;19(1):1082-1088. <https://doi.org/10.3892/ol.2019.11185>
749. Frasson G, Cesaro S, Cazzador D, et al. High prevalence of human papillomavirus infection in sinonasal inverted papilloma: a single-institution cohort of patients. *Int Forum Allergy Rhinol.* 2020;10(5):629-635. <https://doi.org/10.1002/alr.22539>
750. Wang H, Zhai C, Liu J, et al. Low prevalence of human papillomavirus infection in sinonasal inverted papilloma and oncocytic papilloma. *Virchows Arch.* 2020;476(4):577-583. <https://doi.org/10.1007/s00428-019-02717-3>
751. Elliot A, Näsman A, Westman M, Hammarstedt-Nordenvall L, Stjärne P, Marklund L. Stathmin and EGFR correlates to HPV status and clinical outcome in sinonasal inverted papilloma. *Rhinology.* 2020;58(1):74-79. <https://doi.org/10.4193/Rhin19.078>
752. Jalilvand S, Saidi M, Shoja Z, Ghavami N, Hamkar R. The prevalence of human papillomavirus infection in Iranian patients with sinonasal inverted papilloma. *J Chin Med Assoc.* 2016;79(3):137-140. <https://doi.org/10.1016/j.jcma.2015.11.003>
753. Scheel A, Lin GC, McHugh JB, et al. Human papillomavirus infection and biomarkers in sinonasal inverted papillomas: clinical significance and molecular mechanisms: HPV and biomarkers in inverted papilloma. *Int Forum Allergy Rhinol.* 2015;5(8):701-707. <https://doi.org/10.1002/alr.21524>
754. Beigh A, Rashi R, Junaid S, Khuroo MS, Farook S. Human papilloma virus (HPV) in sinonasal papillomas and squamous cell carcinomas: a PCR-based study of 60 cases. *Gulf J Oncolog.* 2018;1(26):37-42.
755. Liu Y, Duan L, Tian J, et al. Role of the Akt/mTOR signaling pathway in human papillomavirus-associated nasal and sinonasal inverted papilloma. *Acta Biochim Biophys Sin.* 2017;49(12):1067-1074. <https://doi.org/10.1093/abbs/gmx108>
756. Stasikowska-Kanicka O, Wągrowska-Danilewicz M, Danilewicz M. Immunohistochemical STUDY EMT-related proteins in HPV-, and EBV-negative patients with sinonasal tumours. *Pathol Oncol Res.* 2016;22(4):781-788. <https://doi.org/10.1007/s12253-016-0068-3>
757. Lin H, Lin D, Xiong XS. Roles of human papillomavirus infection and stathmin in the pathogenesis of sinonasal inverted papilloma: roles of HPV infection and stathmin in sinonasal inverted papilloma. *Head Neck.* 2016;38(2):220-224. <https://doi.org/10.1002/hed.23864>
758. Yamashita Y, Hasegawa M, Deng Z, et al. Human papillomavirus infection and immunohistochemical expression of cell cycle proteins pRb, p53, and p16INK4a in sinonasal diseases. *Infect Agents Cancer.* 2015;10(1):23. <https://doi.org/10.1186/s13027-015-0019-8>
759. Lin GC, Scheel A, Akkina S, et al. Epidermal growth factor receptor, p16, cyclin D1, and p53 staining patterns for inverted papilloma. *Int Forum Allergy Rhinol.* 2013;3(11):885-889. <https://doi.org/10.1002/alr.21215>
760. Lee HJ, Kim JW. Immunohistochemical study on the expression of matrix metalloproteinase 2 and high-risk human papilloma virus in the malignant progression of papillomas. *J Korean Assoc Oral Maxillofac Surg.* 2013;39(5):224-230. <https://doi.org/10.5125/jkaoms.2013.39.5.224>
761. Sham CL, To KF, Chan PKS, Lee DLY, Tong MCF, van Hasselt CA. Prevalence of human papillomavirus, Epstein-Barr virus, p21, and p53 expression in sinonasal inverted papilloma, nasal polyp, and hypertrophied turbinate in Hong Kong patients. *Head Neck.* 2012;34(4):520-533. <https://doi.org/10.1002/hed.21772>
762. Jenko K, Kocjan B, Zidar N, et al. In inverted papillomas HPV more likely represents incidental colonization than an etiological factor. *Virchows Arch.* 2011;459(5):529-538. <https://doi.org/10.1007/s00428-011-1139-1>
763. Kim JY, Yoon JK, Citardi MJ, Batra PS, Roh HJ. The prevalence of human papilloma virus infection in sinonasal inverted papilloma specimens classified by histological grade. *Am J Rhinol.* 2007;21(6):664-669. <https://doi.org/10.2500/ajr.2007.21.3093>
764. Buchwald C, Franzmann MB, Jacobsen GK, Lindeberg H. Human papillomavirus (HPV) in sinonasal papillomas: a study of 78 cases using in situ hybridization and polymerase chain reaction. *Laryngoscope.* 1995;105(1):66-71. <https://doi.org/10.1288/00005537-199501000-00015>
765. Guedea F, Mendenhall WM, Parsons JT, Million RR. The role of radiation therapy in inverted papilloma of the nasal cavity and paranasal sinuses. *Int J Radiat Oncol Biol Phys.* 1991;20(4):777-780. [https://doi.org/10.1016/0360-3016\(91\)90022-v](https://doi.org/10.1016/0360-3016(91)90022-v)
766. Al Badaai Y, Chankowsky J, Mah M, Yammine N, Samaha M. Radiological localization of Schneiderian papilloma. *Int Forum Allergy Rhinol.* 2011;1(6):488-491. <https://doi.org/10.1002/alr.20077>
767. Boghani Z, Husain Q, Kanumuri VV, et al. Juvenile nasopharyngeal angiofibroma: a systematic review and comparison

- of endoscopic, endoscopic-assisted, and open resection in 1047 cases. *Laryngoscope*. 2013;123(4):859-869. <https://doi.org/10.1002/lary.23843>
768. Pamuk AE, Özer S, Süslü AE, Akgöz A, Önerci M. Juvenile nasopharyngeal angiofibroma: a single centre's 11-year experience. *J Laryngol Otol*. 2018;132(11):978-983. <https://doi.org/10.1017/S0022215118001779>
 769. Sousa S, Patrão F, Pereira G, Monteiro E. Juvenile nasopharyngeal angiofibroma: a retrospective study of 27 cases in the ENT department of IPO-PORTO. *Clin Otolaryngol*. 2019;44(3):456-460. <https://doi.org/10.1111/coa.13309>
 770. Beham A, Beham-Schmid C, Regauer S, Auböck L, Stammberger H. Nasopharyngeal angiofibroma: true neoplasm or vascular malformation? *Adv Anat Pathol*. 2000;7(1):36-46. <https://doi.org/10.1097/00125480-200007010-00006>
 771. Farag MM, Ghanimah SE, Ragaie A, Saleem TH. Hormonal receptors in juvenile nasopharyngeal angiofibroma. *Laryngoscope*. 1987;97(2):208-211. <https://doi.org/10.1288/00005537-198702000-00013>
 772. Schick B, Plinkert PK, Prescher A. Aetiology of angiofibromas: reflection on their specific vascular component. *Laryngorhinootologie*. 2002;81(4):280-284. <https://doi.org/10.1055/s-2002-25322>
 773. Abdelwahab M, Overdeest JB, Elmokadem A, et al. Nasopharyngeal angiofibroma staging with a novel nominal basis: an 18-year study in a tertiary center. *Otolaryngol Head Neck Surg*. 2019;161(2):352-361. <https://doi.org/10.1177/0194599819842155>
 774. Xiao Z, Zheng Y, Li J, Chen D, Liu F, Cao D. Four-dimensional CT angiography (4D-CTA) in the evaluation of juvenile nasopharyngeal angiofibromas: comparison with digital subtraction angiography (DSA) and surgical findings. *Dentomaxillofac Radiol*. 2017;46(8):20170171. <https://doi.org/10.1259/dmfr.20170171>
 775. Mishra A, Mishra SC, Tripathi AM, Pandey A. Clinical correlation of molecular (VEGF, FGF, PDGF, c-Myc, c-Kit, Ras, p53) expression in juvenile nasopharyngeal angiofibroma. *Eur Arch Otorhinolaryngol*. 2018;275(11):2719-2726. <https://doi.org/10.1007/s00405-018-5110-5>
 776. Jones JW, Usman S, New J, et al. Differential gene expression and pathway analysis in juvenile nasopharyngeal angiofibroma using RNA sequencing. *Otolaryngol Head Neck Surg*. 2018;159(3):572-575. <https://doi.org/10.1177/0194599818769879>
 777. Wang EW, Gardner PA, Zanation AM. International consensus statement on endoscopic skull-base surgery: executive summary. *Int Forum Allergy Rhinol*. 2019;9(S3):S127-S144. <https://doi.org/10.1002/alr.22327>
 778. Liberati A, Altman DG, Tetzlaff J, et al. The PRISMA statement for reporting systematic reviews and meta-analyses of studies that evaluate healthcare interventions: explanation and elaboration. *BMJ*. 2009;339:b2700. <https://doi.org/10.1136/bmj.b2700>
 779. Szyfter W, Balcerowiak A, Gawęcki W, Juszkat R, Wierzbicka M. Juvenile nasopharyngeal angiofibroma-20 years of experience in endoscopic treatment. *Otolaryngol Pol*. 2021;75(2):9-14. <https://doi.org/10.5604/01.3001.0014.5220>
 780. Cohen-Cohen S, Scheitler KM, Choby G, et al. Contemporary surgical management of juvenile nasopharyngeal angiofibroma. *J Neurol Surg B Skull Base*. 2021;83(Suppl. 2):e266-e273. <https://doi.org/10.1055/s-0041-1725031>
 781. Stapleton AL, Tyler-Kabara EC, Gardner PA, Snyderman CH. The costs of skull base surgery in the pediatric population. *J Neurol Surg B Skull Base*. 2015;76(1):39-42. <https://doi.org/10.1055/s-0034-1390019>
 782. Sessions RB, Bryan RN, Naclerio RM, Alford BR. Radiographic staging of juvenile angiofibroma. *Head Neck Surg*. 1981;3(4):279-283. <https://doi.org/10.1002/hed.2890030404>
 783. Fisch U. The infratemporal fossa approach for nasopharyngeal tumors. *Laryngoscope*. 1983;93(1):36-44. <https://doi.org/10.1288/00005537-198301000-00007>
 784. Chandler JR, Goulding R, Moskowitz L, Quencer RM. Nasopharyngeal angiofibromas: staging and management. *Ann Otol Rhinol Laryngol*. 1984;93(4 Pt 1):322-329. <https://doi.org/10.1177/000348948409300408>
 785. Bremer JW, Neel HB, DeSanto LW, Jones GC. Angiofibroma: treatment trends in 150 patients during 40 years. *Laryngoscope*. 1986;96(12):1321-1329. <https://doi.org/10.1288/00005537-198612000-00001>
 786. Antonelli AR, Cappiello J, Di Lorenzo D, Donajo CA, Nicolai P, Orlandini A. Diagnosis, staging, and treatment of juvenile nasopharyngeal angiofibroma (JNA). *Laryngoscope*. 1987;97(11):1319-1325. <https://doi.org/10.1288/00005537-198711000-00014>
 787. Andrews JC, Fisch U, Valavanis A, Aeppli U, Makek MS. The surgical management of extensive nasopharyngeal angiofibromas with the infratemporal fossa approach. *Laryngoscope*. 1989;99(4):429-437. <https://doi.org/10.1288/00005537-198904000-00013>
 788. Radkowski D, McGill T, Healy GB, Ohlms L, Jones DT. Angiofibroma. Changes in staging and treatment. *Arch Otolaryngol Head Neck Surg*. 1996;122(2):122-129. <https://doi.org/10.1001/archotol.1996.01890140012004>
 789. Önerci TM, Yücel OT, Ögretmenoğlu O. Endoscopic surgery in treatment of juvenile nasopharyngeal angiofibroma. *Int J Pediatr Otorhinolaryngol*. 2003;67(11):1219-1225. <https://doi.org/10.1016/j.ijporl.2003.07.013>
 790. Snyderman CH, Pant H, Carrau RL, Gardner P. A new endoscopic staging system for angiofibromas. *Arch Otolaryngol Head Neck Surg*. 2010;136(6):588-594. <https://doi.org/10.1001/archoto.2010.83>
 791. Schreiber A, Bertazzoni G, Ferrari M, et al. Management of persistent juvenile angiofibroma after endoscopic resection: analysis of a single institution series of 74 patients. *Head Neck*. 2019;41(5):1297-1303. <https://doi.org/10.1002/hed.25555>
 792. Chua JT, Choy JA, Sahyouni R, et al. Spontaneous involution of juvenile nasopharyngeal angiofibromas: report of a case. *Laryngoscope*. 2021;131(7):1455-1457. <https://doi.org/10.1002/lary.29246>
 793. Rowan NR, Stapleton AL, Heft-Neal ME, Gardner PA, Snyderman CH. The natural growth rate of residual juvenile angiofibroma. *J Neurol Surg B Skull Base*. 2018;79(3):257-261. <https://doi.org/10.1055/s-0037-1607419>
 794. Liu Z, Hua W, Zhang H, et al. The risk factors for residual juvenile nasopharyngeal angiofibroma and the usual residual sites. *Am J Otolaryngol*. 2019;40(3):343-346. <https://doi.org/10.1016/j.amjoto.2018.11.010>

795. Giorgianni A, Molinaro S, Agosti E, et al. Twenty years of experience in juvenile nasopharyngeal angiofibroma (JNA) preoperative endovascular embolization: an effective procedure with a low complications rate. *J Clin Med*. 2021;10(17):3926. <https://doi.org/10.3390/jcm10173926>
796. Pei R, Yang M, Wang J, Tong X, Wang G, Zou Y. Efficacy and safety of preoperative internal maxillary arterial embolization with gelfoam for nasopharyngeal angiofibroma. *Eur Arch Otorhinolaryngol*. 2019;276(3):865-869. <https://doi.org/10.1007/s00405-018-05276-6>
797. Tan G, Ma Z, Long W, et al. Efficacy of preoperative transcatheter arterial embolization for nasopharyngeal angiofibroma: a comparative study. *Cardiovasc Intervent Radiol*. 2017;40(6):836-844. <https://doi.org/10.1007/s00270-017-1587-3>
798. Gao M, Gemmete JJ, Chaudhary N, et al. A comparison of particulate and onyx embolization in preoperative devascularization of juvenile nasopharyngeal angiofibromas. *Neuroradiology*. 2013;55(9):1089-1096. <https://doi.org/10.1007/s00234-013-1213-2>
799. Vakharia K, Lim J, Waqas M, et al. Preoperative embolization of fisch grades II-IVa juvenile nasopharyngeal angiofibromas: transarterial embolization in the age of onyx. *Cureus*. 13(6):e15804. <https://doi.org/10.7759/cureus.15804>
800. Abouzeid W, Sultan A, Shadad M. Multidisciplinary management of juvenile nasopharyngeal angiofibroma. *Egypt J Neurol Psychiatr Neurosurg*. 2021;57(1):167. <https://doi.org/10.1186/s41983-021-00414-0>
801. Choi JS, Yu J, Lovin BD, Chapel AC, Patel AJ, Gallagher KK. Effects of preoperative embolization on juvenile nasopharyngeal angiofibroma surgical outcomes: a study of the kids' inpatient database. *J Neurol Surg B Skull Base*. 2020;83(1):76-81. <https://doi.org/10.1055/s-0040-1716676>
802. Glauser G, Detchou DK, Kohanski M, et al. Direct tumoral puncture onyx embolization for a juvenile nasopharyngeal angiofibroma in a hybrid neurointerventional suite. *World Neurosurg*. 2021;147:7. <https://doi.org/10.1016/j.wneu.2020.11.177>
803. Jaiswal AS, Kumar R, Thakar A, et al. Plasma ablation-assisted endoscopic excision versus traditional technique of endoscopic excision of juvenile nasopharyngeal angiofibroma. *Int J Pediatr Otorhinolaryngol*. 2020;139:110410. <https://doi.org/10.1016/j.ijporl.2020.110410>
804. Cummings BJ, Blend R, Keane T, et al. Primary radiation therapy for juvenile nasopharyngeal angiofibroma. *Laryngoscope*. 1984;94(12 Pt 1):1599-1605.
805. Amdur RJ, Yeung AR, Fitzgerald BM, Mancuso AA, Werning JW, Mendenhall WM. Radiotherapy for juvenile nasopharyngeal angiofibroma. *Pract Radiat Oncol*. 2011;1(4):271-278. <https://doi.org/10.1016/j.prro.2011.04.002>
806. Lee JT, Chen P, Safa A, Juillard G, Calcaterra TC. The role of radiation in the treatment of advanced juvenile angiofibroma. *Laryngoscope*. 2002;112(7 Pt 1):1213-1220. <https://doi.org/10.1097/00005537-200207000-00014>
807. Goepfert H, Cangir A, Lee YY. Chemotherapy for aggressive juvenile nasopharyngeal angiofibroma. *Arch Otolaryngol*. 1985;111(5):285-289. <https://doi.org/10.1001/archotol.1985.00800070037002>
808. Schick B, Kahle G, Hässler R, Draff W. Chemotherapy of juvenile angiofibroma—an alternative? *HNO*. 1996;44(3):148-152.
809. Thakar A, Gupta G, Bhalla AS, et al. Adjuvant therapy with flutamide for presurgical volume reduction in juvenile nasopharyngeal angiofibroma. *Head Neck*. 2011;33(12):1747-1753. <https://doi.org/10.1002/hed.21667>
810. Hota A, Sarkar C, Gupta SD, Kumar R, Bhalla AS, Thakar A. Expression of vascular endothelial growth factor in Juvenile Angiofibroma. *Int J Pediatr Otorhinolaryngol*. 2015;79(6):900-902. <https://doi.org/10.1016/j.ijporl.2015.03.033>
811. Wendler O, Długaiczek J, Birk S, Schick B. Anti-proliferative effect of glucocorticoids on mesenchymal cells in juvenile angiofibromas. *Head Neck*. 2012;34(11):1615-1621. <https://doi.org/10.1002/hed.21966>
812. Scholfield DW, Clarke P. Midfacial degloving for juvenile angiofibroma: a case-series of 21 adult males: an alternative to the endoscopic approach and when it should be considered. *Clin Otolaryngol*. 2021;46(3):659-664. <https://doi.org/10.1111/coa.13704>
813. Epprecht L, Mosimann M, Vital D, Holzmann D. Morbidity and volumetric progression in juvenile nasopharyngeal angiofibroma in a long-term follow-up. *J Neurol Surg B Skull Base*. 2018;79(6):533-537. <https://doi.org/10.1055/s-0038-1635255>
814. Rupa V, Mani SE, Backianathan S, Rajshekhar V. Management and outcome in patients with advanced juvenile nasopharyngeal angiofibroma. *J Neurol Surg B Skull Base*. 2018;79(4):353-360. <https://doi.org/10.1055/s-0037-1608658>
815. Kim JS, Kwon SH. Sinonasal hemangioma: diagnosis, treatment, and follow-up of 37 patients at a single center. *J Oral Maxillofac Surg*. 2017;75(8):1775-1783. <https://doi.org/10.1016/j.joms.2016.12.044>
816. Lim HR, Lee DH, Lim SC. Clinical difference between capillary and cavernous hemangiomas of nasal cavity. *J Craniofac Surg*. 2021;32(3):1042-1044. <https://doi.org/10.1097/SCS.00000000000007250>
817. Iwata N, Hattori K, Nakagawa T, Tsujimura T. Hemangioma of the nasal cavity: a clinicopathologic study. *Auris Nasus Larynx*. 2002;29(4):335-339. [https://doi.org/10.1016/s0385-8146\(02\)00028-7](https://doi.org/10.1016/s0385-8146(02)00028-7)
818. Puxeddu R, Berlucchi M, Ledda GP, Parodo G, Farina D, Nicolai P. Lobular capillary hemangioma of the nasal cavity: a retrospective study on 40 patients. *Am J Rhinol*. 2006;20(4):480-484. <https://doi.org/10.2500/ajr.2006.20.2878>
819. Takaishi S, Asaka D, Nakayama T, et al. Features of sinonasal hemangioma: a retrospective study of 31 cases. *Auris Nasus Larynx*. 2017;44(6):719-723. <https://doi.org/10.1016/j.anl.2017.01.012>
820. Smith SC, Patel RM, Lucas DR, McHugh JB. Sinonasal lobular capillary hemangioma: a clinicopathologic study of 34 cases characterizing potential for local recurrence. *Head Neck Pathol*. 2013;7(2):129-134. <https://doi.org/10.1007/s12105-012-0409-9>
821. Dillon WP, Som PM, Rosenau W. Hemangioma of the nasal vault: MR and CT features. *Radiology*. 1991;180(3):761-765. <https://doi.org/10.1148/radiology.180.3.1871291>
822. Schlosser RJ, Woodworth BA, Gillespie MB, Day TA. Endoscopic resection of sinonasal hemangiomas and hemangiopericytomas. *ORL J Otorhinolaryngol Relat Spec*. 2006;68(2):69-72. <https://doi.org/10.1159/000091092>

823. Song CE, Cho JH, Kim SY, Kim SW, Kim BG, Kang JM. Endoscopic resection of haemangiomas in the sinonasal cavity. *J Laryngol Otol*. 2009;123(8):868-872. <https://doi.org/10.1017/S0022215109004861>
824. Kinzinger MR, Strong EB, Bernard J, Steele TO. Intralesional bevacizumab for the treatment of recurrent sinonasal hemangioma. *Ann Otol Rhinol Laryngol*. 2018;127(12):969-973. <https://doi.org/10.1177/0003489418802288>
825. Tasca RA, Williams RG. Capillary haemangioma of the nasal cavity in a 7-week-old baby—successful treatment using intralesional steroid injection. *Int J Pediatr Otorhinolaryngol*. 2004;68(3):365-367. <https://doi.org/10.1016/j.ijporl.2003.10.022>
826. Cansiz H, Yener M, Kalekoclu N, Dalkılıç O. Arteriovenous malformation of the maxillary sinus and mandible: a case report. *Ear Nose Throat J*. 2003;82(8):608-610, 612, 614.
827. Kim D, Choi KU, Kim HJ, Cho KS. Arteriovenous malformation of the maxillary sinus: a rare clinical entity. *Braz J Otorhinolaryngol*. 2016;86(6):820-823. <https://doi.org/10.1016/j.bjorl.2016.08.003>
828. Darlow LD, Murphy JB, Berrios RJ, Park Y, Feldman RS. Arteriovenous malformation of the maxillary sinus: an unusual clinical presentation. *Oral Surg Oral Med Oral Pathol*. 1988;66(1):21-23. [https://doi.org/10.1016/0030-4220\(88\)90059-x](https://doi.org/10.1016/0030-4220(88)90059-x)
829. Park ES, Jung YJ, Yun JH, Ahn JS, Lee DH. Intraosseous arteriovenous malformation of the sphenoid bone presenting with orbital symptoms mimicking cavernous sinus dural arteriovenous fistula: a case report. *J Cerebrovasc Endovasc Neurosurg*. 2013;15(3):251-254. <https://doi.org/10.7461/jcen.2013.15.3.251>
830. Kennedy KS. Arteriovenous malformation of the maxilla. *Head Neck*. 1990;12(6):512-515. <https://doi.org/10.1002/hed.2880120612>
831. Coskun BU, Sozen E, Basak T, Alkan S, Dadas B. Arteriovenous malformation of the nasopharynx: a case report. *Int J Pediatr Otorhinolaryngol*. 2005;69(9):1287-1290. <https://doi.org/10.1016/j.ijporl.2005.03.050>
832. Gianoli GJ, Amedee RG. Vascular malformation of the sphenoid sinus. *Ear Nose Throat J*. 1991;70(6):373-375.
833. Kassam AB, Thomas AJ, Zimmer LA, et al. Expanded endonasal approach: a fully endoscopic completely transnasal resection of a skull base arteriovenous malformation. *Childs Nerv Syst*. 2007;23(5):491-498. <https://doi.org/10.1007/s00381-006-0288-z>
834. Schuldt T, Dommerich S. Recurrent epistaxis of unknown origin. A rare differential diagnosis and its treatment. *HNO*. 2012;60(3):283-286. <https://doi.org/10.1007/s00106-011-2328-6>
835. Richter GT, Braswell L. Management of venous malformations. *Facial Plast Surg*. 2012;28(6):603-610. <https://doi.org/10.1055/s-0032-1329935>
836. Vikkula M, Boon LM, Carraway KL, et al. Vascular dysmorphogenesis caused by an activating mutation in the receptor tyrosine kinase TIE2. *Cell*. 1996;87(7):1181-1190. [https://doi.org/10.1016/s0092-8674\(00\)81814-0](https://doi.org/10.1016/s0092-8674(00)81814-0)
837. Limaye N, Wouters V, Uebelhoer M, et al. Somatic mutations in angiopoietin receptor gene TEK cause solitary and multiple sporadic venous malformations. *Nat Genet*. 2009;41(1):118-124. <https://doi.org/10.1038/ng.272>
838. Limaye N, Kangas J, Mendola A, et al. Somatic activating PIK3CA mutations cause venous malformation. *Am J Hum Genet*. 2015;97(6):914-921. <https://doi.org/10.1016/j.ajhg.2015.11.011>
839. Boon LM, Mulliken JB, Enjolras O, Vikkula M. Glomuvenous malformation (glomangioma) and venous malformation: distinct clinicopathologic and genetic entities. *Arch Dermatol*. 2004;140(8):971-976. <https://doi.org/10.1001/archderm.140.8.971>
840. Wassef M, Blei F, Adams D, et al. Vascular anomalies classification: recommendations from the international society for the study of vascular anomalies. *Pediatrics*. 2015;136(1):e203-e214. <https://doi.org/10.1542/peds.2014-3673>
841. Seront E, Vikkula M, Boon LM. Venous malformations of the head and neck. *Otolaryngol Clin North Am*. 2018;51(1):173-184. <https://doi.org/10.1016/j.otc.2017.09.003>
842. Buckmiller LM. Update on hemangiomas and vascular malformations. *Curr Opin Otolaryngol Head Neck Surg*. 2004;12(6):476-487. <https://doi.org/10.1097/01.moo.0000145946.67222.01>
843. Gertel AJ, Southwood JE, North PE, Poetker DM, Loehrl TA. Venous malformation of the ethmoid and sphenoid sinuses. *Am J Otolaryngol*. 2016;37(1):12-16. <https://doi.org/10.1016/j.amjoto.2015.09.008>
844. Chewing RH, Monroe EJ, Lindberg A, et al. Combined glue embolization and excision for the treatment of venous malformations. *CVIR Endovasc*. 2018;1:22. <https://doi.org/10.1186/s42155-018-0028-y>
845. De Maria L, De Sanctis P, Balakrishnan K, Tollefson M, Brinjikji W. Sclerotherapy for venous malformations of head and neck: systematic review and meta-analysis. *Neurointervention*. 2020;15(1):4-17. <https://doi.org/10.5469/neuroint.2019.00213>
846. Matsui, H, Matsuura, K, Nagafune, D, et al. A case of venous malformation diagnosed by manifesting as repeated nasal bleeding. *Oto-Rhino-Laryngology Tokyo*. 2019;62(5):216-221. https://doi.org/10.11453/orlto.62.5_216
847. Lee DR, Richter GT. Nasopharyngeal venous malformation: a rare condition managed with Nd:YAG laser. *Laryngoscope*. 2015;125(10):2405-2407. <https://doi.org/10.1002/lary.25193>
848. Zheng JW, Mai HM, Zhang L, et al. Guidelines for the treatment of head and neck venous malformations. *Int J Clin Exp Med*. 2013;6(5):377-389.
849. de Almeida Vital JM, de Farias TP, Dias FL, et al. Nasal cavity paraganglioma: literature review and discussion of a rare case. *BMH*. 2017;2(2):1-15. <https://doi.org/10.1159/000464099>
850. Myssiorek D, Halaas Y, Silver C. Laryngeal and sinonasal paragangliomas. *Otolaryngol Clin North Am*. 2001;34(5):971-982, vii. [https://doi.org/10.1016/s0030-6665\(05\)70357-1](https://doi.org/10.1016/s0030-6665(05)70357-1)
851. Hahn S, Palmer JN, Adappa ND. A catecholamine-secreting skull base sinonasal paraganglioma presenting with labile hypertension in a patient with previously undiagnosed genetic mutation. *J Neurol Surg Rep*. 2012;73(1):19-24. <https://doi.org/10.1055/s-0032-1301408>
852. Nguyen BK, Patel NM, Arianpour K, et al. Characteristics and management of sinonasal paragangliomas: a systematic review. *Int Forum Allergy Rhinol*. 2019;9(4):413-426. <https://doi.org/10.1002/alr.22261>

853. Gawarle S, Keche P, Ganguly S. Nasal septum: an extremely unusual location for head and neck paraganglioma. *Braz J Otorhinolaryngol*. 2016;85(5):667-669. <https://doi.org/10.1016/j.bjorl.2016.04.023>
854. Kim JH, Tu N, Wrobel BB. Paraganglioma presenting as a nasal septal mass: case report and literature review. *Case Rep Otolaryngol*. 2018;2018:1413960. <https://doi.org/10.1155/2018/1413960>
855. Srivastava R, Wadhwa N, Gupta S, Razdan U. Nasal polyp - an incidental paraganglioma. *Turk Patoloji Derg*. 2016;32(3):196-199. <https://doi.org/10.5146/tjpath.2014.01255>
856. Montone KT. The differential diagnosis of sinonasal/nasopharyngeal neuroendocrine/neuroectodermally derived tumors. *Arch Pathol Lab Med*. 2015;139(12):1498-1507. <https://doi.org/10.5858/arpa.2014-0383-RA>
857. Aydın S, Karabulut B, Orhan KS, Kılıçaslan I, Değer K. A case of sinonasal paraganglioma with a different morphology: nine-year follow-up. *Kulak Burun Bogaz Ihtis Derg*. 2015;25(1):43-45. <https://doi.org/10.5606/kbbihtisas.2015.04568>
858. Mouadeb DA, Chandra RK, Kennedy DW, Feldman M. Sinonasal paraganglioma: endoscopic resection with a 4-year follow-up. *Head Neck*. 2003;25(12):1077-1081. <https://doi.org/10.1002/hed.10322>
859. Lack EE, Cubilla AL, Woodruff JM. Paragangliomas of the head and neck region. A pathologic study of tumors from 71 patients. *Hum Pathol*. 1979;10(2):191-218. [https://doi.org/10.1016/s0046-8177\(79\)80008-8](https://doi.org/10.1016/s0046-8177(79)80008-8)
860. Kuhn JA, Aronoff BL. Nasal and nasopharyngeal paraganglioma. *J Surg Oncol*. 1989;40(1):38-45. <https://doi.org/10.1002/jso.2930400110>
861. Welkoborsky HJ, Gosepath J, Jacob R, Mann WJ, Amedee RG. Biologic characteristics of paragangliomas of the nasal cavity and paranasal sinuses. *Am J Rhinol*. 2000;14(6):419-426. <https://doi.org/10.2500/105065800779954284>
862. Papaspyrou K, Welkoborsky HJ, Gouveris H, Mann WJ. Malignant and benign sinonasal paragangliomas. *Laryngoscope*. 2013;123(8):1830-1836. <https://doi.org/10.1002/lary.23985>
863. Nguyen QA, Gibbs PM, Rice DH. Malignant nasal paraganglioma: a case report and review of the literature. *Otolaryngol Head Neck Surg*. 1995;113(1):157-161. <https://doi.org/10.1016/S0194-59989570163-X>
864. Belgioia L, Pupillo F, Bacigalupo A, Corvò R. Long-term survival in a patient with head and neck paraganglioma treated with tailored modalities for 20 years: a case report. *Tumori*. 2016;102(Suppl. 2):S9-S11. <https://doi.org/10.5301/tj.5000443>
865. Lecanu JB, Arkwright S, Halimi PH, Trotoux J, Bonfils P. Multifocal malignant paraganglioma of the paranasal sinuses: a case report. *Otolaryngol Head Neck Surg*. 2002;126(4):445-447. <https://doi.org/10.1067/mhn.2002.123830>
866. Kumar P, Dey AK, Mittal K, Sharma R, Badhe P, Kale S. Sinonasal paraganglioma and Cushing's syndrome: a rare association. *J Cancer Res Ther*. 2018;14(Supplement):S812-S814. <https://doi.org/10.4103/0973-1482.187354>
867. Thomas T, Zender S, Terkamp C, Jaeckel E, Manns MP. Hypercortisolaemia due to ectopic adrenocorticotrophic hormone secretion by a nasal paraganglioma: a case report and review of the literature. *BMC Res Notes*. 2013;6:331. <https://doi.org/10.1186/1756-0500-6-331>
868. Serra F, Duarte S, Abreu S, Marques C, Cassis J, Saraiva M. Cushing's syndrome due to ectopic ACTH production by a nasal paraganglioma. *Endocrinol Diabetes Metab Case Rep*. 2013;2013:130038. <https://doi.org/10.1530/EDM-13-0038>
869. Subedi N, Prestwich R, Chowdhury F, Patel C, Scarsbrook A. Neuroendocrine tumours of the head and neck: anatomical, functional and molecular imaging and contemporary management. *Cancer Imaging*. 2013;13(3):407-422. <https://doi.org/10.1102/1470-7330.2013.0034>
870. Morales H, Castillo M, Jewells V. Paraganglioma of the sphenoid sinus: case report and review of literature. *Clin Imaging*. 2007;31(1):32-36. <https://doi.org/10.1016/j.clinimag.2006.10.001>
871. Tolman CJ, Stam OC. Nasal paraganglioma: differential diagnosis from a radiologic and pathologic perspective. *BJR Case Rep*. 2016;2(4):20160050. <https://doi.org/10.1259/bjrcr.20160050>
872. Michel J, Taïeb D, Jolibert M, et al. Sinonasal paraganglioma with long-delayed recurrence and metastases: genetic and imaging findings. *J Clin Endocrinol Metab*. 2013;98(11):4262-4266. <https://doi.org/10.1210/jc.2013-2320>
873. Kisser U, Braun T, Mayr D, Leunig A. Paraganglioma of the maxillary sinus. *Auris Nasus Larynx*. 2013;40(5):506-509. <https://doi.org/10.1016/j.anl.2012.10.009>
874. Syed MI, Mennie J, Williams AT. Early experience of radio frequency coblation in the management of intranasal and sinus tumors. *Laryngoscope*. 2012;122(2):436-439. <https://doi.org/10.1002/lary.22420>
875. Branham GH, Gnepp DR, O'McMenomey S, Friedman WH. Malignant paraganglioma—a case report and literature review. *Otolaryngol Head Neck Surg*. 1989;101(1):99-103. <https://doi.org/10.1177/019459988910100117>
876. Denk MJ, Ajkay N, Yuan X, Rosenblum RS, Freda N, Magee WP. Surgical treatment of nasal hemangiomas. *Ann Plast Surg*. 2002;48(5):489-494; discussion 494-495. <https://doi.org/10.1097/00000637-200205000-00007>
877. Huisman TAGM, Schneider JFL, Kellenberger CJ, Martin-Fiori E, Willi UV, Holzmann D. Developmental nasal midline masses in children: neuroradiological evaluation. *Eur Radiol*. 2004;14(2):243-249. <https://doi.org/10.1007/s00330-003-2008-3>
878. Sessions RB, Picken C. Congenital anomalies of the nose. In: Bailey BJ, ed. *Head & Neck Surgery-Otolaryngology*. Lippincott Williams & Wilkins; 2001:941-948.
879. Hedlund G. Congenital frontonasal masses: developmental anatomy, malformations, and MR imaging. *Pediatr Radiol*. 2006;36(7):647-662; quiz 726-727. <https://doi.org/10.1007/s00247-005-0100-3>
880. Saettele M, Alexander A, Markovich B, Morelli J, Lowe LH. Congenital midline nasofrontal masses. *Pediatr Radiol*. 2012;42(9):1119-1125. <https://doi.org/10.1007/s00247-012-2409-z>
881. Vaghela HM, Bradley PJ. Nasal dermoid sinus cysts in adults. *J Laryngol Otol*. 2004;118(12):955-962. <https://doi.org/10.1258/0022215042790565>
882. Kennard CD, Rasmussen JE. Congenital midline nasal masses: diagnosis and management. *J Dermatol Surg Oncol*. 1990;16(11):1025-1036. <https://doi.org/10.1111/j.1524-4725.1990.tb00327.x>

883. Rahbar R, Shah P, Mulliken JB, et al. The presentation and management of nasal dermoid: a 30-year experience. *Arch Otolaryngol Head Neck Surg.* 2003;129(4):464-471. <https://doi.org/10.1001/archotol.129.4.464>
884. McIntyre JD, Rannan-Eliya SV, Wall SA. Familial external angular dermoid: evidence for a genetic link? *J Craniofac Surg.* 2002;13(2):311-314. <https://doi.org/10.1097/00001665-200203000-00025>
885. Wardinsky TD, Pagon RA, Kropp RJ, Hayden PW, Clarren SK. Nasal dermoid sinus cysts: association with intracranial extension and multiple malformations. *Cleft Palate Craniofac J.* 1991;28(1):87-95. https://doi.org/10.1597/1545-1569_1991_028_0087_ndscaw_2.3.co_2
886. Penner CR, Thompson L. Nasal glial heterotopia: a clinicopathologic and immunophenotypic analysis of 10 cases with a review of the literature. *Ann Diagn Pathol.* 2003;7(6):354-359. <https://doi.org/10.1016/j.anndiagpath.2003.09.010>
887. Clarós P, Bandos R, Clarós A, Gilea I, Clarós A, Real M. Nasal gliomas: main features, management and report of five cases. *Int J Pediatr Otorhinolaryngol.* 1998;46(1-2):15-20. [https://doi.org/10.1016/s0165-5876\(98\)00114-1](https://doi.org/10.1016/s0165-5876(98)00114-1)
888. Swift AC, Singh SD. The presentation and management of the nasal glioma. *Int J Pediatr Otorhinolaryngol.* 1985;10(3):253-261. [https://doi.org/10.1016/s0165-5876\(85\)80072-0](https://doi.org/10.1016/s0165-5876(85)80072-0)
889. Mahapatra AK. Anterior encephaloceles. *Indian J Pediatr.* 1997;64(5):699-704. <https://doi.org/10.1007/BF02726129>
890. Mahapatra AK, Tandon PN, Dhawan IK, Khazanchi RK. Anterior encephaloceles: a report of 30 cases. *Child's Nerv Syst.* 1994;10(8):501-504. <https://doi.org/10.1007/BF00335071>
891. Turgut M, Ozcan OE, Benli K, et al. Congenital nasal encephalocele: a review of 35 cases. *J Craniomaxillofac Surg.* 1995;23(1):1-5. [https://doi.org/10.1016/s1010-5182\(05\)80246-x](https://doi.org/10.1016/s1010-5182(05)80246-x)
892. Baxter DJG, Shroff M. Congenital midface abnormalities. *Neuroimaging Clin N Am.* 2011;21(3):563-584, vii-viii. <https://doi.org/10.1016/j.nic.2011.05.003>
893. Barkovich AJ, Vandermarck P, Edwards MS, Cogen PH. Congenital nasal masses: CT and MR imaging features in 16 cases. *AJNR Am J Neuroradiol.* 1991;12(1):105-116.
894. Cauchois R, Laccourreye O, Bremond D, Testud R, Küffer R, Monteil JP. Nasal dermoid sinus cyst. *Ann Otol Rhinol Laryngol.* 1994;103(8 Pt 1):615-618. <https://doi.org/10.1177/000348949410300806>
895. Haafiz AB, Sharma R, Faillace WJ. Congenital midline nasofrontal mass. Two case reports with a clinical review. *Clin Pediatr.* 1995;34(9):482-486. <https://doi.org/10.1177/000992289503400906>
896. Winterton RIS, Wilks DJ, Chumas PD, Russell JL, Liddington MI. Surgical correction of midline nasal dermoid sinus cysts. *J Craniofac Surg.* 2010;21(2):295-300. <https://doi.org/10.1097/SCS.0b013e3181cf5f44>
897. Vibe P, Løntoft E. Congenital nasal dermoid cysts and fistulas. *Scand J Plast Reconstr Surg.* 1985;19(1):105-107. <https://doi.org/10.3109/02844318509052873>
898. Weiss DD, Robson CD, Mulliken JB. Transnasal endoscopic excision of midline nasal dermoid from the anterior cranial base. *Plast Reconstr Surg.* 1998;102(6):2119-2123. <https://doi.org/10.1097/00006534-199811000-00048>
899. Bartlett SP, Lin KY, Grossman R, Katowitz J. The surgical management of orbitofacial dermoids in the pediatric patient. *Plast Reconstr Surg.* 1993;91(7):1208-1215. <https://doi.org/10.1097/00006534-199306000-00005>
900. Woodworth BA, Schlosser RJ, Faust RA, Bolger WE. Evolutions in the management of congenital intranasal skull base defects. *Arch Otolaryngol Head Neck Surg.* 2004;130(11):1283-1288. <https://doi.org/10.1001/archotol.130.11.1283>
901. Purkey MT, Woodworth BA, Hahn S, Palmer JN, Chiu AG. Endoscopic repair of supraorbital ethmoid cerebrospinal fluid leaks. *ORL J Otorhinolaryngol Relat Spec.* 2009;71(2):93-98. <https://doi.org/10.1159/000193219>
902. Oakley GM, Orlandi RR, Woodworth BA, Batra PS, Alt JA. Management of cerebrospinal fluid rhinorrhea: an evidence-based review with recommendations. *Int Forum Allergy Rhinol.* 2016;6(1):17-24. <https://doi.org/10.1002/alr.21627>
903. Thompson HM, Cho DY, Riley KO, Grayson JW, Woodworth BA. Systematic review of anterior congenital cephalocele: open vs endoscopic repair. *Int Forum Allergy Rhinol.* 2020;10(12):1334-1336. <https://doi.org/10.1002/alr.22701>
904. Thompson HM, Schlosser RJ, McCarty Walsh E, et al. Current management of congenital anterior cranial base encephaloceles. *Int J Pediatr Otorhinolaryngol.* 2020;131:109868. <https://doi.org/10.1016/j.ijporl.2020.109868>
905. Kanowitz SJ, Bernstein JM. Pediatric meningoencephaloceles and nasal obstruction: a case for endoscopic repair. *Int J Pediatr Otorhinolaryngol.* 2006;70(12):2087-2092. <https://doi.org/10.1016/j.ijporl.2006.08.007>
906. Kassam A, Thomas AJ, Snyderman C, et al. Fully endoscopic expanded endonasal approach treating skull base lesions in pediatric patients. *J Neurosurg.* 2007;106(2, Suppl.):75-86. <https://doi.org/10.3171/ped.2007.106.2.75>
907. Keshri AK, Shah SR, Patadia SD, Sahu RN, Behari S. Transnasal endoscopic repair of pediatric meningoencephalocele. *J Pediatr Neurosci.* 2016;11(1):42-45. <https://doi.org/10.4103/1817-1745.181249>
908. Leng LZ, Brown S, Anand VK, Schwartz TH. "Gasket-seal" watertight closure in minimal-access endoscopic cranial base surgery. *Neurosurgery.* 2008;62(5 Suppl 2):ONSE342-343; discussion ONSE343. <https://doi.org/10.1227/01.neu.0000326017.84315.1f>
909. Paluzzi A, Gardner PA, Fernandez-Miranda JC, et al. "Round-the-clock" surgical access to the orbit. *J Neurol Surg B Skull Base.* 2015;76(1):12-24. <https://doi.org/10.1055/s-0033-1360580>
910. Melder K, Zwagerman N, Gardner PA, Wang EW. Endoscopic endonasal approach for intra- and extraorbital pathologies. *J Neurol Surg B Skull Base.* 2020;81(4):442-449. <https://doi.org/10.1055/s-0040-1713940>
911. El Rassi E, Adappa ND, Battaglia P, et al. Development of the international orbital Cavernous Hemangioma Exclusively Endonasal Resection (CHEER) staging system. *Int Forum Allergy Rhinol.* 2019;9(7):804-812. <https://doi.org/10.1002/alr.22316>
912. Jafari A, Adappa ND, Anagnos VJ, et al. Orbital resection by intranasal technique (ORBIT): a new classification system for reporting endoscopically resectable primary benign orbital tumors. *Int Forum Allergy Rhinol.* 2023. <https://doi.org/10.1002/alr.23141>
913. Locatelli D, Dallan I, Castelnovo P. Surgery around the orbit: how to select an approach. *J Neurol Surg B Skull Base.* 2020;81(4):409-421. <https://doi.org/10.1055/s-0040-1713893>

914. Stefko ST. Combined surgical approaches in and around the orbit. *J Neurol Surg B Skull Base*. 2020;81(4):472-479. <https://doi.org/10.1055/s-0040-1713938>
915. Jafari A, von Sneidern M, Lehmann AE, et al. Exclusively endoscopic endonasal resection of benign orbital tumors: a systematic review and meta-analysis. *Int Forum Allergy Rhinol*. 2021;11(5):924-934. <https://doi.org/10.1002/alr.22745>
916. Pennington JD, Bleier BS, Freitag SK. Endoscopic endonasal resection of orbital schwannoma assisted with small-incision medial orbitotomy: case series and surgical technique. *Orbit*. 2021;40(6):536-542. <https://doi.org/10.1080/01676830.2020.1832123>
917. Valentini M, Arosio AD, Czaczkes C, Castelnovo P, Battaglia P. Endoscopic endonasal removal of orbital schwannoma: focus on surgical technique. *World Neurosurg*. 2021;153:1. <https://doi.org/10.1016/j.wneu.2021.05.133>
918. Chaskes MB, Rabinowitz MR. Orbital schwannoma. *J Neurol Surg B Skull Base*. 2020;81(4):376-380. <https://doi.org/10.1055/s-0040-1713935>
919. Montano N, Lauretti L, D'Alessandris QG, et al. Orbital tumors: report of 70 surgically treated cases. *World Neurosurg*. 2018;119:e449-e458. <https://doi.org/10.1016/j.wneu.2018.07.181>
920. Sun MT, Wu W, Yan W, Tu Y, Selva D. Endoscopic endonasal-assisted resection of orbital schwannoma. *Ophthalmic Plast Reconstr Surg*. 2017;33(3S Suppl 1):S121-S124. <https://doi.org/10.1097/IOP.0000000000000528>
921. Caballero-García J, Aparicio-García C, Linares-Benavides YJ, López-Sánchez M, Abreu-Perdomo FA, Huanca-Amaru J. Minimally invasive 360-degree approach to intraconal orbital tumors. *Am J Ophthalmol*. 2021;224:301-309. <https://doi.org/10.1016/j.ajo.2020.07.035>
922. Maza G, Subramaniam S, Yanez-Siller JC, Otto BA, Prevedello DM, Carrau RL. The role of endonasal endoscopic optic nerve decompression as the initial management of primary optic nerve sheath meningiomas. *J Neurol Surg B Skull Base*. 2019;80(6):568-576. <https://doi.org/10.1055/s-0039-1677689>
923. Hunt PJ, DeMonte F, Tang RA, Su SY, Raza SM. Surgical resection of an optic nerve sheath meningioma: relevance of endoscopic endonasal approaches to the optic canal. *J Neurol Surg Rep*. 2017;78(2):e81-e85. <https://doi.org/10.1055/s-0037-1600897>
924. Peron S, Cividini A, Santi L, Galante N, Castelnovo P, Locatelli D. Spheno-orbital meningiomas: when the endoscopic approach is better. *Acta Neurochir Suppl*. 2017;124:123-128. https://doi.org/10.1007/978-3-319-39546-3_19
925. Li L, London NR, Silva S, Prevedello D, Carrau RL. Transnasal prelacrimal approach to the inferior intraconal space: a feasibility study. *Int Forum Allergy Rhinol*. 2019;9(9):1063-1068. <https://doi.org/10.1002/alr.22368>
926. Li L, London NR, Prevedello DM, Carrau RL. Endoscopic endonasal approaches to the medial intraconal space: comparison of transethmoidal and prelacrimal corridors. *Am J Rhinol Allergy*. 2020;34(6):792-799. <https://doi.org/10.1177/1945892420930938>
927. Li L, London NR, Prevedello DM, Carrau RL. Anatomical variants of the infraorbital canal: implications for the prelacrimal approach to the orbital floor. *Am J Rhinol Allergy*. 2020;34(2):176-182. <https://doi.org/10.1177/1945892419882127>
928. Li L, London NR, Prevedello DM, Carrau RL. Intraconal anatomy of the anterior ethmoidal neurovascular bundle: implications for surgery in the superomedial orbit. *Am J Rhinol Allergy*. 2020;34(3):394-400. <https://doi.org/10.1177/1945892420901630>
929. Lin GC, Freitag SK, Kocharyan A, Yoon MK, Lefebvre DR, Bleier BS. Comparative techniques of medial rectus muscle retraction for endoscopic exposure of the medial intraconal space. *Am J Rhinol Allergy*. 2016;30(3):226-229. <https://doi.org/10.2500/ajra.2016.30.4307>
930. Shafi F, Zaidi S, Mehta P, Ahluwalia HS, Ahmed SK. Endoscopic medial rectus sling: a window into the intraconal orbital apex. *Ophthalmic Plast Reconstr Surg*. 2016;32(3):233-236. <https://doi.org/10.1097/IOP.0000000000000670>
931. Yao WC, Bleier BS. Endoscopic management of orbital tumors. *Curr Opin Otolaryngol Head Neck Surg*. 2016;24(1):57-62. <https://doi.org/10.1097/MOO.0000000000000215>
932. Fong Ng BC, Kwan Mak CH, Chan NL, Lam CW, Yuen HK, Poon TL. Indocyanine green-assisted endoscopic transorbital excision of lateral orbital apex cavernous hemangioma. *World Neurosurg*. 2022;158:167. <https://doi.org/10.1016/j.wneu.2021.11.060>
933. Kim M, Gudis DA, Tooley AA, Kazim M. Trans-septal suture retraction for endoscopic orbital surgery. *Orbit*. 2020;39(5):336-341. <https://doi.org/10.1080/01676830.2019.1692040>
934. Lao WP, Perez HA, Lagabon KJ, De Los Reyes K, Lee SC. Endonasal resection of orbital cavernous venous malformations with septal preservation. *Am J Otolaryngol*. 2021;42(3):103021. <https://doi.org/10.1016/j.amjoto.2021.103021>
935. Castelnovo P, Arosio AD, Volpi L, et al. Endoscopic transnasal cryo-assisted removal of orbital cavernous hemangiomas: case report and technical hints. *World Neurosurg*. 2019;126:66-71. <https://doi.org/10.1016/j.wneu.2019.01.235>
936. Colletti G, Saibene AM, Pessina F, et al. A shift in the orbit: immediate endoscopic reconstruction after transnasal orbital tumors resection. *J Craniofac Surg*. 2017;28(8):2027-2029. <https://doi.org/10.1097/SCS.00000000000003879>
937. Bleier BS. A shift in the orbit: immediate endoscopic reconstruction after transnasal orbital tumors resection: response. *J Craniofac Surg*. 2018;29(6):1674-1675. <https://doi.org/10.1097/SCS.00000000000004652>
938. McCormick J, Allen M, Kain JJ, et al. Lateral nasal wall extension of the nasoseptal flap for skull-base and medial orbital wall defects. *Int Forum Allergy Rhinol*. 2019;9(9):1041-1045. <https://doi.org/10.1002/alr.22364>
939. Chhabra N, Healy DY, Freitag SK, Bleier BS. The nasoseptal flap for reconstruction of the medial and inferior orbit. *Int Forum Allergy Rhinol*. 2014;4(9):763-766. <https://doi.org/10.1002/alr.21351>
940. Lehmann AE, von Sneidern M, Shen SA, Humphreys IM, Abuzeid WM, Jafari A. Does reconstruction affect outcomes following exclusively endoscopic endonasal resection of benign orbital tumors: a systematic review with meta-analysis. *World J Otorhinolaryngol Head Neck Surg*. 2022;8(1):25-35. <https://doi.org/10.1002/wjo.2.13>
941. Scheuerle AF, Steiner HH, Kolling G, Kunze S, Aschoff A. Treatment and long-term outcome of patients with orbital

- cavernomas. *Am J Ophthalmol.* 2004;138(2):237-244. <https://doi.org/10.1016/j.ajo.2004.03.011>
942. McNab AA, McKelvie P. IgG4-related ophthalmic disease. Part II: clinical aspects. *Ophthalmic Plast Reconstr Surg.* 2015;31(3):167-178. <https://doi.org/10.1097/IOP.0000000000000364>
 943. Andrew N, Kearney D, Selva D. IgG4-related orbital disease: a meta-analysis and review. *Acta Ophthalmol.* 2013;91(8):694-700. <https://doi.org/10.1111/j.1755-3768.2012.02526.x>
 944. McNab AA, McKelvie P. IgG4-related ophthalmic disease. Part I: background and pathology. *Ophthalmic Plast Reconstr Surg.* 2015;31(2):83-88. <https://doi.org/10.1097/IOP.0000000000000363>
 945. Derzko-Dzulynsky L. IgG4-related disease in the eye and ocular adnexa. *Curr Opin Ophthalmol.* 2017;28(6):617-622. <https://doi.org/10.1097/ICU.0000000000000427>
 946. Goto H, Ueda SI, Nemoto R, et al. Clinical features and symptoms of IgG4-related ophthalmic disease: a multicenter study. *Jpn J Ophthalmol.* 2021;65(5):651-656. <https://doi.org/10.1007/s10384-021-00847-3>
 947. Wu A, Andrew NH, McNab AA, Selva D. IgG4-related ophthalmic disease: pooling of published cases and literature review. *Curr Allergy Asthma Rep.* 2015;15(6):27. <https://doi.org/10.1007/s11882-015-0530-4>
 948. Chen J, Zhang P, Ye H, et al. Clinical features and outcomes of IgG4-related idiopathic orbital inflammatory disease: from a large southern China-based cohort. *Eye.* 2021;35(4):1248-1255. <https://doi.org/10.1038/s41433-020-1083-x>
 949. Sogabe Y, Ohshima K-i, Azumi A, et al. Location and frequency of lesions in patients with IgG4-related ophthalmic diseases. *Graefes Arch Clin Exp Ophthalmol.* 2014;252(3):531-538. <https://doi.org/10.1007/s00417-013-2548-4>
 950. Goto H, Takahira M, Azumi A, Japanese study group for IgG4-related ophthalmic disease. Diagnostic criteria for IgG4-related ophthalmic disease. *Jpn J Ophthalmol.* 2015;59(1):1-7. <https://doi.org/10.1007/s10384-014-0352-2>
 951. Abad S, Martin A, Héran F, et al. IgG4-related disease in patients with idiopathic orbital inflammation syndrome: data from the French SIOI prospective cohort. *Acta Ophthalmol.* 2019;97(4):e648-e656. <https://doi.org/10.1111/aos.13968>
 952. Derakhshandeh R, Petros Dimopoulos Y, Alan Goodlick T, Chanine J, Sabet S, Özdemirli M. Single institutional experience on orbital inflammatory pseudotumor: diagnostic and management challenge. *Balkan Med J.* 2021;38(4):239-243. <https://doi.org/10.5152/balkanmedj.2021.21187>
 953. Hou Y, Xie X, Chen J, et al. Bag-of-features-based radiomics for differentiation of ocular adnexal lymphoma and idiopathic orbital inflammation from contrast-enhanced MRI. *Eur Radiol.* 2021;31(1):24-33. <https://doi.org/10.1007/s00330-020-07110-2>
 954. Eissa L, Abdel Razek AAK, Helmy E. Arterial spin labeling and diffusion-weighted MR imaging: utility in differentiating idiopathic orbital inflammatory pseudotumor from orbital lymphoma. *Clin Imaging.* 2021;71:63-68. <https://doi.org/10.1016/j.clinimag.2020.10.057>
 955. Lee KH, Han SH, Yoon JS. Implications of enlarged infraorbital nerve in idiopathic orbital inflammatory disease. *Br J Ophthalmol.* 2016;100(9):1295-1300. <https://doi.org/10.1136/bjophthalmol-2015-307232>
 956. Min HK, Lee YS, Yang SW, et al. Clinical outcomes and pathological characteristics of immunoglobulin G4-related ophthalmic disease versus orbital inflammatory pseudotumor. *Korean J Intern Med.* 2019;34(1):220-226. <https://doi.org/10.3904/kjim.2016.304>
 957. Aryasit O, Tiraset N, Preechawai P, Kayasut K, Sanghan N, Sittivarakul W. IgG4-related disease in patients with idiopathic orbital inflammation. *BMC Ophthalmol.* 2021;21(1):356. <https://doi.org/10.1186/s12886-021-02115-x>
 958. Andrew NH, Sladden N, Kearney DJ, Selva D. An analysis of IgG4-related disease (IgG4-RD) among idiopathic orbital inflammations and benign lymphoid hyperplasias using two consensus-based diagnostic criteria for IgG4-RD. *Br J Ophthalmol.* 2015;99(3):376-381. <https://doi.org/10.1136/bjophthalmol-2014-305545>
 959. Wu A, Andrew NH, Tsirbas A, Tan P, Gajdatsy A, Selva D. Rituximab for the treatment of IgG4-related orbital disease: experience from five cases. *Eye.* 2015;29(1):122-128. <https://doi.org/10.1038/eye.2014.251>
 960. Kubota T, Katayama M, Moritani S, Yoshino T. Serologic factors in early relapse of IgG4-related orbital inflammation after steroid treatment. *Am J Ophthalmol.* 2013;155(2):373.e1-379.e1. <https://doi.org/10.1016/j.ajo.2012.07.024>
 961. Kubota T, Katayama M, Nishimura R, Moritani S. Long-term outcomes of ocular adnexal lesions in IgG4-related ophthalmic disease. *Br J Ophthalmol.* 2020;104(3):345-349. <https://doi.org/10.1136/bjophthalmol-2018-313730>
 962. Yuen SJA, Rubin PAD. Idiopathic orbital inflammation: distribution, clinical features, and treatment outcome. *Arch Ophthalmol.* 2003;121(4):491-499. <https://doi.org/10.1001/archophth.121.4.491>
 963. Dagi Glass LR, Freitag SK. Orbital inflammation: corticosteroids first. *Surv Ophthalmol.* 2016;61(5):670-673. <https://doi.org/10.1016/j.survophthal.2016.01.005>
 964. Bijlsma WR, Paridaens D, Kalmann R. Treatment of severe idiopathic orbital inflammation with intravenous methylprednisolone. *Br J Ophthalmol.* 2011;95(8):1068-1071. <https://doi.org/10.1136/bjo.2010.195552>
 965. Leibovitch I, Prabhakaran VC, Davis G, Selva D. Intraorbital injection of triamcinolone acetonide in patients with idiopathic orbital inflammation. *Arch Ophthalmol.* 2007;125(12):1647-1651. <https://doi.org/10.1001/archophth.125.12.1647>
 966. Iran University of Medical Sciences. Intraorbital injection versus oral steroid in patients with anterior idiopathic orbital inflammation: a randomized clinical trial. *ClinicalTrials.gov.* Accessed May 8, 2023. <https://clinicaltrials.gov/ct2/show/NCT03958344>
 967. Suhler EB, Lim LL, Beardsley RM, et al. Rituximab therapy for refractory orbital inflammation: results of a phase 1/2, dose-ranging, randomized clinical trial. *JAMA Ophthalmol.* 2014;132(5):572-578. <https://doi.org/10.1001/jamaophthalmol.2013.8179>
 968. Dutta P, Anand K. Tolosa-hunt syndrome: a review of diagnostic criteria and unresolved issues. *J Curr Ophthalmol.* 2021;33(2):104-111. https://doi.org/10.4103/joco.joco_134_20
 969. The International Classification of Headache Disorders: 2nd edition. *Cephalalgia.* 2004;24(Suppl 1):9-10. <https://doi.org/10.1111/j.1468-2982.2003.00824.x>

970. Headache Classification Committee of the International Headache Society (IHS) The International Classification of Headache Disorders, 3rd edition. *Cephalalgia*. 2018;38(1):1-211. <https://doi.org/10.1177/0333102417738202>
971. Hung CH, Chang KH, Wu YM, et al. A comparison of benign and inflammatory manifestations of Tolosa-Hunt syndrome. *Cephalalgia*. 2013;33(10):842-852. <https://doi.org/10.1177/0333102412475238>
972. Zhang X, Zhou Z, Steiner TJ, et al. Validation of ICHD-3 beta diagnostic criteria for 13.7 Tolosa-Hunt syndrome: analysis of 77 cases of painful ophthalmoplegia. *Cephalalgia*. 2014;34(8):624-632. <https://doi.org/10.1177/0333102413520082>
973. Colnaghi S, Versino M, Marchioni E, et al. ICHD-II diagnostic criteria for Tolosa-Hunt syndrome in idiopathic inflammatory syndromes of the orbit and/or the cavernous sinus. *Cephalalgia*. 2008;28(6):577-584. <https://doi.org/10.1111/j.1468-2982.2008.01569.x>
974. Turkoglu R, Balak N, Tireli H. Surgery with cavernous sinus syndrome: a clinical study and review of the Tolosa-Hunt syndrome. *Neurosurg Q*. 2008;18:230-238. <https://doi.org/10.1097/WNQ.0b013e31818d0980>
975. Chirapapaisan N, Chuenkongkaew W, Pornpanich K, Vangveeravong S. Orbital pseudotumor: clinical features and outcomes. *Asian Pac J Allergy Immunol*. 2007;25(4):215-218.
976. Mombaerts I, Rose GE, Garrity JA. Orbital inflammation: biopsy first. *Surv Ophthalmol*. 2016;61(5):664-669. <https://doi.org/10.1016/j.survophthal.2016.03.002>
977. Mendenhall WM, Lessner AM. Orbital pseudotumor. *Am J Clin Oncol*. 2010;33(3):304-306. <https://doi.org/10.1097/COC.0b013e3181a07567>
978. Jacobs D, Galetta S. Diagnosis and management of orbital pseudotumor. *Curr Opin Ophthalmol*. 2002;13(6):347-351. <https://doi.org/10.1097/00055735-200212000-00001>
979. Rosai J, Dorfman RF. Sinus histiocytosis with massive lymphadenopathy: a pseudolymphomatous benign disorder. Analysis of 34 cases. *Cancer*. 1972;30(5):1174-1188. [https://doi.org/10.1002/1097-0142\(197211\)30:5\(1174::AID-CNCR2820300507\)3.0.CO;2-S](https://doi.org/10.1002/1097-0142(197211)30:5(1174::AID-CNCR2820300507)3.0.CO;2-S)
980. Abla O, Jacobsen E, Picarsic J, et al. Consensus recommendations for the diagnosis and clinical management of Rosai-Dorfman-Destombes disease. *Blood*. 2018;131(26):2877-2890. <https://doi.org/10.1182/blood-2018-03-839753>
981. Duan HG, Zheng CQ, Wang DH, et al. Extranodal sinonasal Rosai-Dorfman disease: a clinical study of 10 cases. *Eur Arch Otorhinolaryngol*. 2015;272(9):2313-2318. <https://doi.org/10.1007/s00405-014-3297-7>
982. Ojha J, Rawal YB, Hornick JL, et al. Extra nodal Rosai-Dorfman disease originating in the nasal and paranasal complex and gnathic bones: a systematic analysis of seven cases and review of literature. *Head Neck Pathol*. 2020;14(2):442-453. <https://doi.org/10.1007/s12105-019-01056-8>
983. Shi Y, Griffin AC, Zhang PJ, Palmer JN, Gupta P. Sinus histiocytosis with massive lymphadenopathy (Rosai-Dorfman Disease): a case report and review of 49 cases with fine needle aspiration cytology. *Cytojournal*. 2011;8:3. <https://doi.org/10.4103/1742-6413.76731>
984. Pulsoni A, Anghel G, Falcucci P, et al. Treatment of sinus histiocytosis with massive lymphadenopathy (Rosai-Dorfman disease): report of a case and literature review. *Am J Hematol*. 2002;69(1):67-71. <https://doi.org/10.1002/ajh.10008>
985. Chen HH, Zhou SH, Wang SQ, Teng XD, Fan J. Factors associated with recurrence and therapeutic strategies for sinonasal Rosai-Dorfman disease. *Head Neck*. 2012;34(10):1504-1513. <https://doi.org/10.1002/hed.21832>
986. Preece JM, Kearns DB, Wickersham JK, Grace AR, Bailey CM. Nasal lipoma. *J Laryngol Otol*. 1988;102(11):1044-1046. <https://doi.org/10.1017/S0022215100107224>
987. Takasaki K, Yano H, Hayashi T, Kobayashi T. Nasal lipoma. *J Laryngol Otol*. 2000;114(3):218-220. <https://doi.org/10.1258/0022215001905166>
988. Jahandideh H, Firouzabadi FD, Firouzabadi MD, Jan D, Roomiani M. Lipoma of the nasal septum: a case report. *Clin Case Rep*. 2020;8(12):3028-3031. <https://doi.org/10.1002/ccr3.3359>
989. Abdalla WMA, da Motta ACBS, Lin SY, McCarthy EF, Zinreich SJ. Intraosseous lipoma of the left frontoethmoidal sinuses and nasal cavity. *AJNR Am J Neuroradiol*. 2007;28(4):615-617.
990. Fu YS, Perzin KH. Non-epithelial tumors of the nasal cavity, paranasal sinuses and nasopharynx. A clinicopathologic study. VIII. Adipose tissue tumors (lipoma and liposarcoma). *Cancer*. 1977;40(3):1314-1317. [https://doi.org/10.1002/1097-0142\(197709\)40:3\(1314::AID-CNCR2820400348\)3.0.CO;2-O](https://doi.org/10.1002/1097-0142(197709)40:3(1314::AID-CNCR2820400348)3.0.CO;2-O)
991. Hazarika P, Pujary K, Kundaje HG, Rao PL. Osteolipoma of the skull base. *J Laryngol Otol*. 2001;115(2):136-139. <https://doi.org/10.1258/0022215011907532>
992. Kuan EC, Diaz MFP, Chiu AG, Bergsneider M, Wang MB, Suh JD. Sinonasal and skull base pleomorphic adenoma: a case series and literature review. *Int Forum Allergy Rhinol*. 2015;5(5):460-468. <https://doi.org/10.1002/alr.21500>
993. Vento SI, Numminen J, Kinnunen I, et al. Pleomorphic adenoma in the nasal cavity: a clinicopathological study of ten cases in Finland. *Eur Arch Otorhinolaryngol*. 2016;273(11):3741-3745. <https://doi.org/10.1007/s00405-016-4023-4>
994. Li W, Lu H, Zhang H, et al. Sinonasal/nasopharyngeal pleomorphic adenoma and carcinoma ex pleomorphic adenoma: a report of 17 surgical cases combined with a literature review. *Cancer Manag Res*. 2019;11:5545-5555. <https://doi.org/10.2147/CMAR.S198942>
995. Rha MS, Jeong S, Cho HJ, Yoon JH, Kim CH. Sinonasal pleomorphic adenoma: a single institution case series combined with a comprehensive review of literatures. *Auris Nasus Larynx*. 2019;46(2):223-229. <https://doi.org/10.1016/j.anl.2018.08.003>
996. Kajiyama A, Edo H, Inoue N, Yokouchi Y, Gomi T. Magnetic resonance imaging and histopathology in a case of pleomorphic adenoma of a minor salivary gland in the nasal cavity. *Am J Case Rep*. 2019;20:679-684. <https://doi.org/10.12659/AJCR.915491>
997. Argersinger DP, Haring CT, Hanks JE, et al. Phosphaturic mesenchymal tumors of the sinonasal area and skull base: experience at a single institution. *Ann Otol Rhinol Laryngol*. 2022;131(6):647-654. <https://doi.org/10.1177/00034894211037416>
998. Zhu Z, Xia W, Qi F, et al. Clinical characteristics and surgical outcomes of sinonasal lesions associated with tumor-induced

- osteomalacia. *Otolaryngol Head Neck Surg.* 2021;165(1):223-231. <https://doi.org/10.1177/0194599820975432>
999. Kurien R, Rupa V, Thomas M. Varied presentation of sinonasal phosphaturic mesenchymal tumour: report of a case series with follow-up. *Eur Arch Otorhinolaryngol.* 2019;276(6):1677-1684. <https://doi.org/10.1007/s00405-019-05341-8>
1000. Chatterjee D, Bardia A, Pal R, Saikia UN, Bhadada SK, Radotra BD. Clinical, morphological and immunohistochemical analysis of 13 cases of phosphaturic mesenchymal tumor - a holistic diagnostic approach. *Ann Diagn Pathol.* 2021;54:151783. <https://doi.org/10.1016/j.anndiagpath.2021.151783>
1001. Agaimy A, Michal M, Chiosea S, et al. Phosphaturic mesenchymal tumors: clinicopathologic, immunohistochemical and molecular analysis of 22 cases expanding their morphologic and immunophenotypic spectrum. *Am J Surg Pathol.* 2017;41(10):1371-1380. <https://doi.org/10.1097/PAS.0000000000000890>
1002. Tang R, Mao S, Lin H, et al. Surgical treatment and outcomes for sinonasal and skull base phosphaturic mesenchymal tumors. *Otolaryngol Head Neck Surg.* 2020;162(5):674-682. <https://doi.org/10.1177/0194599820904055>
1003. Kane SV, Kakkar A, Oza N, Sridhar E, Pai PS. Phosphaturic mesenchymal tumor of the nasal cavity and paranasal sinuses: a clinical curiosity presenting a diagnostic challenge. *Auris Nasus Larynx.* 2018;45(2):377-383. <https://doi.org/10.1016/j.anl.2017.05.006>
1004. Gillman G, Pavlovich JB. Sinonasal hemangiopericytoma. *Otolaryngol Head Neck Surg.* 2004;131(6):1012-1013. <https://doi.org/10.1016/j.otohns.2004.02.030>
1005. Bignami M, Dallan I, Battaglia P, Lenzi R, Pistochini A, Castelnuovo P. Endoscopic, endonasal management of sinonasal haemangiopericytoma: 12-year experience. *J Laryngol Otol.* 2010;124(11):1178-1182. <https://doi.org/10.1017/S0022215110000952>
1006. Vedrine PO, Thariat J, Merrot O, et al. Primary cancer of the sphenoid sinus—a GETTEC study. *Head Neck.* 2009;31(3):388-397. <https://doi.org/10.1002/hed.20966>
1007. Dahodwala MQ, Husain Q, Kanumuri VV, Choudhry OJ, Liu JK, Eloy JA. Management of sinonasal hemangiopericytomas: a systematic review: management of sinonasal hemangiopericytomas. *Int Forum Allergy Rhinol.* 2013;3(7):581-587. <https://doi.org/10.1002/alr.21139>
1008. Duval M, Hwang E, Kilty SJ. Systematic review of treatment and prognosis of sinonasal hemangiopericytoma. *Head Neck.* 2013;35(8):1205-1210. <https://doi.org/10.1002/hed.23074>
1009. Ozturk K, Gawande R, Gencturk M, Boegel K, Caicedo-Granados E, Cayci Z. Imaging features of sinonasal tumors on positron emission tomography and magnetic resonance imaging including diffusion weighted imaging: a pictorial review. *Clin Imaging.* 2018;51:217-228. <https://doi.org/10.1016/j.clinimag.2018.05.018>
1010. Thompson LDR, Liou SS, Feldman KA. Orbit solitary fibrous tumor: a proposed risk prediction model based on a case series and comprehensive literature review. *Head Neck Pathol.* 2021;15(1):138-152. <https://doi.org/10.1007/s12105-020-01184-6>
1011. Fletcher CDM, McKee PH. Sarcomas—a clinicopathological guide with particular reference to cutaneous manifestation III. Angiosarcoma, malignant haemangiopericytoma, fibrosarcoma and synovial sarcoma. *Clin Exp Dermatol.* 1985;10(4):332-349. <https://doi.org/10.1111/j.1365-2230.1985.tb00580.x>
1012. Maresi E, Tortorici S, Campione M, et al. Hemangiopericytoma of the oral cavity after a ten-year follow-up. *Ann Clin Lab Sci.* 2007;37(3):274-279.
1013. Castelnuovo P, Pagella F, Delù G, Benazzo M, Cerniglia M. Endoscopic resection of nasal haemangiopericytoma. *Eur Arch Otorhinolaryngol.* 2003;260(5):244-247. <https://doi.org/10.1007/s00405-001-0440-z>
1014. Wang K, Mei F, Wu S, Tan Z. Hemangiopericytoma: incidence, treatment, and prognosis analysis based on SEER database. *Biomed Res Int.* 2020;2020:2468320. <https://doi.org/10.1155/2020/2468320>
1015. Abiri A, Nguyen C, Latif K, et al. Head and neck solitary fibrous tumors: a review of the national cancer database. *Head Neck.* 2023;45(8):1934-1942. <https://doi.org/10.1002/hed.27417>
1016. Park MS, Ravi V, Conley A, et al. The role of chemotherapy in advanced solitary fibrous tumors: a retrospective analysis. *Clin Sarcoma Res.* 2013;3(1):7-7. <https://doi.org/10.1186/2045-3329-3-7>
1017. Stacchiotti S, Libertini M, Negri T, et al. Response to chemotherapy of solitary fibrous tumour: a retrospective study. *Eur J Cancer.* 2013;49(10):2376-2383. <https://doi.org/10.1016/j.ejca.2013.03.017>
1018. Maeda O, Ohka F, Maesawa S, et al. Solitary fibrous tumor/hemangiopericytoma treated with temozolomide plus bevacizumab: a report of four cases and literature review. *Nagoya J Med Sci.* 2020;82(4):631-644. <https://doi.org/10.18999/nagjms.82.4.631>
1019. Park MS, Patel SR, Ludwig JA, et al. Activity of temozolomide and bevacizumab in the treatment of locally advanced, recurrent, and metastatic hemangiopericytoma and malignant solitary fibrous tumor. *Cancer.* 2011;117(21):4939-4947. <https://doi.org/10.1002/cncr.26098>
1020. Stacchiotti S, Negri T, Palassini E, et al. Sunitinib malate and figitumumab in solitary fibrous tumor: patterns and molecular bases of tumor response. *Mol Cancer Ther.* 2010;9(5):1286-1297. <https://doi.org/10.1158/1535-7163.mct-09-1205>
1021. Kono M, Bandoh N, Matsuoka R, et al. Glomangiopericytoma of the nasal cavity with CTNNB1 p.S37C mutation: a case report and literature review. *Head Neck Pathol.* 2019;13(3):298-303. <https://doi.org/10.1007/s12105-018-0961-z>
1022. Park ES, Kim J, Jun SY. Characteristics and prognosis of glomangiopericytomas: a systematic review. *Head Neck.* 2017;39(9):1897-1909. <https://doi.org/10.1002/hed.24818>
1023. Thompson LDR, Miettinen M, Wenig BM. Sinonasal-type hemangiopericytoma. *Am J Surg Pathol.* 2003;27(6):737-749. <https://doi.org/10.1097/00000478-200306000-00004>
1024. Saito Y, Ohta N, Konosu-Fukaya S, et al. Endoscopic treatment of sinonasal glomangiopericytoma: a case report in light of the literature. *Yonago Acta Med.* 2019;62(2):236-239. <https://doi.org/10.33160/yam.2019.06.009>
1025. Haller F, Bieg M, Moskalev EA, et al. Recurrent mutations within the amino-terminal region of β -catenin are probable key molecular driver events in sinonasal hemangiopericytoma. *Am J Pathol.* 2015;185(2):563-571. <https://doi.org/10.1016/j.ajpath.2014.10.019>

1026. Lasota J, Felisiak-Golabek A, Aly FZ, Wang ZF, Thompson LDR, Miettinen M. Nuclear expression and gain-of-function β -catenin mutation in glomangiopericytoma (sinonasal-type hemangiopericytoma): insight into pathogenesis and a diagnostic marker. *Mod Pathol*. 2015;28(5):715-720. <https://doi.org/10.1038/modpathol.2014.161>
1027. Suh CH, Lee JH, Lee MK, et al. CT and MRI findings of glomangiopericytoma in the head and neck: case series study and systematic review. *AJNR Am J Neuroradiol*. 2020;41(1):155-159. <https://doi.org/10.3174/ajnr.A6336>
1028. Al-Jobory YM, Pan Z, Manes RP, Omay SB, Ikuta I. Sinonasal glomangiopericytoma: review of imaging appearance and clinical management update for a rare sinonasal neoplasm. *Yale J Biol Med*. 2021;94(4):593-597.
1029. Psoma E, Karkos PD, Dova S, et al. Sinonasal glomangiopericytoma treated with preoperative embolisation and endoscopic sinus surgery. *Ecancermedicalseience*. 2016;10:692-692. <https://doi.org/10.3332/ecancer.2016.692>
1030. Ho SY, Chung JCK, Tsang RKY. Endoscopic resection of glomangiopericytoma in four patients: a case series and literature review. *Clin Otolaryngol*. 2019;44(3):471-474. <https://doi.org/10.1111/coa.13319>
1031. Asimakopoulos P, Syed MI, Andrews T, Syed S, Williams A. Sinonasal glomangiopericytoma: is anything new? *Ear Nose Throat J*. 2016;95(2):E1-E6. <https://doi.org/10.1177/014556131609500202>
1032. Thompson LDR. World Health Organization classification of tumours: pathology and genetics of head and neck tumours. *Ear Nose Throat J*. 2006;85(2):74-75.
1033. Hong CS, Khan M, Sukys JM, et al. PIK3CA mutation in a case of CTNNB1-mutant sinonasal glomangiopericytoma. *Cold Spring Harb Mol Case Stud*. 2022;8(1):a006120. <https://doi.org/10.1101/mcs.a006120>
1034. Ciceri EF, Plebani M, Augelli R, et al. Transnasal devascularisation of a sinonasal hypervascular tumour (glomangiopericytoma) with direct injection of liquid polymer agent (Squid®). *Interv Neuroradiol*. 2019;25(2):230-233. <https://doi.org/10.1177/1591019918805776>
1035. Kazi AA, McDougal EM, Howell JB, Schuman TA, Nord RS. Glomangiopericytoma: a case series with review of literature. *Braz J Otorhinolaryngol*. 2022;88(5):817-820. <https://doi.org/10.1016/j.bjorl.2021.02.007>
1036. Heft Neal ME, Rowan NR, Willson TJ, Wang EW, Lee SE. A case report and systematic review of eosinophilic angiocentric fibrosis of the paranasal sinuses. *Ann Otol Rhinol Laryngol*. 2017;126(5):415-423. <https://doi.org/10.1177/0003489417696510>
1037. Fang CH, Mady LJ, Mirani NM, Baredes S, Eloy JA. Sinonasal eosinophilic angiocentric fibrosis: a systematic review. *Int Forum Allergy Rhinol*. 2014;4(9):745-752. <https://doi.org/10.1002/alr.21347>
1038. Sunde J, Alexander KA, Reddy VVB, Woodworth BA. Intranasal eosinophilic angiocentric fibrosis: a case report and review. *Head Neck Pathol*. 2010;4(3):246-248. <https://doi.org/10.1007/s12105-010-0185-3>
1039. Han SC, Park JH, Hong SN. Eosinophilic angiocentric fibrosis invading the nasal septum: a case report and review of literature. *Ear Nose Throat J*. 2020;100(8):557-561. <https://doi.org/10.1177/0145561320964266>
1040. Deshpande V, Khosroshahi A, Nielsen GP, Hamilos DL, Stone JH. Eosinophilic angiocentric fibrosis is a form of IgG4-related systemic disease. *Am J Surg Pathol*. 2011;35(5):701-706. <https://doi.org/10.1097/pas.0b013e318213889e>
1041. Nutalapati S, O'Neal R, O'Connor W, Comer BT, Hildebrandt GC. Challenges in medicine: the odyssey of a patient with isolated IgG4-related eosinophilic angiocentric fibrosis presenting as a locally destructive sinonasal mass. *Case Rep Rheumatol*. 2021;2021:6668184. <https://doi.org/10.1155/2021/6668184>
1042. Ahn J, Flanagan M. Eosinophilic angiocentric fibrosis: a review and update of its association with immunoglobulin G4-related disease. *Arch Pathol Lab Med*. 2018;142(12):1560-1563. <https://doi.org/10.5858/arpa.2017-0223-rs>
1043. Yang BT, Wang YZ, Wang XY, Wang ZC. Nasal cavity eosinophilic angiocentric fibrosis: CT and MR imaging findings. *AJNR Am J Neuroradiol*. 2011;32(11):2149-2153. <https://doi.org/10.3174/ajnr.A2786>
1044. Roberts PF, McCann BG. Eosinophilic angiocentric fibrosis of the upper respiratory tract: a mucosal variant of granuloma faciale? A report of three cases. *Histopathology*. 1985;9(11):1217-1225. <https://doi.org/10.1111/j.1365-2559.1985.tb02801.x>
1045. Patil A, More S. Eosinophilic angiocentric fibrosis: a case report with review of literature. *Med J Dr DY Patil Vidyapeeth*. 2019;12(1):69-71. https://doi.org/10.4103/mjdrdypu.mjdrdypu_30_18
1046. Stelini RF, Moysés MDG, Cintra ML, et al. Granuloma faciale and eosinophilic angiocentric fibrosis: similar entities in different anatomic sites. *Appl Immunohistochem Molecul Morphol*. 2017;25(3):213-220. <https://doi.org/10.1097/pai.0000000000000283>
1047. Nastro F, Ruggiero A, Spanò G, et al. Neoadjuvant use of methotrexate in eosinophilic angiocentric fibrosis of upper lip and hard palate: a case report. *Dermatol Ther*. 2021;34(5):e15094. <https://doi.org/10.1111/dth.15094>
1048. Jain S, Li Y, Kuan EC, Tajudeen BA, Batra PS. Prognostic factors in paranasal sinus squamous cell carcinoma and adenocarcinoma: a SEER database analysis. *J Neurol Surg B Skull Base*. 2019;80(3):258-263. <https://doi.org/10.1055/s-0038-1669420>
1049. Sanghvi S, Khan MN, Patel NR, Yeldandi S, Baredes S, Eloy JA. Epidemiology of sinonasal squamous cell carcinoma: a comprehensive analysis of 4994 patients. *Laryngoscope*. 2013;124(1):76-83. <https://doi.org/10.1002/lary.24264>
1050. Jafari A, Shen SA, Qualliotine JR, et al. Socioeconomic factors affect presentation stage and survival in sinonasal squamous cell carcinoma. *Laryngoscope*. 2021;131(11):2421-2428. <https://doi.org/10.1002/lary.29568>
1051. Wolpoe ME, Goldenberg D, Koch WM. Squamous cell carcinoma of the sinonasal cavity arising as a second primary in individuals with head and neck cancer. *Laryngoscope*. 2006;116(5):696-699. <https://doi.org/10.1097/01.mlg.0000206042.01192.4c>
1052. Hayes RB, Kardaun JW, de Bruyn A. Tobacco use and sinonasal cancer: a case-control study. *Br J Cancer*. 1987;56(6):843-846. <https://doi.org/10.1038/bjc.1987.303>
1053. Strader CH, Vaughan TL, Stergachis A. Use of nasal preparations and the incidence of sinonasal cancer. *J Epidemiol Community Health*. 1988;42(3):243-248. <https://doi.org/10.1136/jech.42.3.243>

1054. Zheng W, Blot WJ, Shu XO, et al. A population-based case-control study of cancers of the nasal cavity and paranasal sinuses in Shanghai. *Int J Cancer*. 1992;52(4):557-561. <https://doi.org/10.1002/ijc.2910520410>
1055. Fukuda K, Shibata A. Exposure-response relationships between woodworking, smoking or passive smoking, and squamous cell neoplasms of the maxillary sinus. *Cancer Causes Control*. 1990;1(2):165-168. <https://doi.org/10.1007/bf00053168>
1056. IARC. *Wood Dust and Formaldehyde*. Accessed May 11, 2023. <https://publications.iarc.fr/Book-And-Report-Series/Iarc-Monographs-On-The-Identification-Of-Carcinogenic-Hazards-To-Humans/Wood-Dust-And-Formaldehyde-1995>
1057. IARC. *Personal Habits and Indoor Combustions*. Accessed May 11, 2023. <https://publications.iarc.fr/Book-And-Report-Series/Iarc-Monographs-On-The-Identification-Of-Carcinogenic-Hazards-To-Humans/Personal-Habits-And-Indoor-Combustions-2012>
1058. Siew SS, Kauppinen T, Kyryrönen P, Heikkilä P, Pukkala E. Occupational exposure to wood dust and formaldehyde and risk of nasal, nasopharyngeal, and lung cancer among Finnish men. *Cancer Manag Res*. 2012;4:223-232. <https://doi.org/10.2147/CMAR.S30684>
1059. Luce D, Leclerc A, Morcet JF, et al. Occupational risk factors for sinonasal cancer: a case-control study in France. *Am J Ind Med*. 1992;21(2):163-175. <https://doi.org/10.1002/ajim.4700210206>
1060. Leclerc A, Luce D, Demers PA, et al. Sinonasal cancer and occupation. Results from the reanalysis of twelve case-control studies. *Am J Ind Med*. 1997;31(2):153-165. [https://doi.org/10.1002/\(sici\)1097-0274\(199702\)31:2<153::aid-ajim4>3.0.co;2-0](https://doi.org/10.1002/(sici)1097-0274(199702)31:2<153::aid-ajim4>3.0.co;2-0)
1061. Švajdler M, Němcova J, Dubinský P, et al. Significance of transcriptionally-active high-risk human papillomavirus in sinonasal squamous cell carcinoma: case series and a meta-analysis. *Neoplasma*. 2021;67(06):1456-1463. https://doi.org/10.4149/neo_2020_200330n332
1062. Sharma A, Tang AL, Takiar V, Wise-Draper TM, Langevin SM. Human papillomavirus and survival of sinonasal squamous cell carcinoma patients: a systematic review and meta-analysis. *Cancers*. 2021;13(15):3677. <https://doi.org/10.3390/cancers13153677>
1063. Nguyen ES, Risbud A, Birkenbeuel JL, et al. Prognostic factors and outcomes of De Novo sinonasal squamous cell carcinoma: a systematic review and meta-analysis. *Otolaryngol Head Neck Surg*. 2021;166(3):434-443. <https://doi.org/10.1177/01945998211021023>
1064. Doescher J, Piontek G, Wirth M, et al. Epstein-Barr virus infection is strictly associated with the metastatic spread of sinonasal squamous-cell carcinomas. *Oral Oncol*. 2015;51(10):929-934. <https://doi.org/10.1016/j.oraloncology.2015.07.008>
1065. Nukpook T, Ekalaksananan T, Teeramatwanich W, et al. Prevalence and association of Epstein-Barr virus infection with sinonasal inverted papilloma and sinonasal squamous cell carcinoma in the northeastern Thai population. *Infect Agent Cancer*. 2020;15:43. <https://doi.org/10.1186/s13027-020-00308-5>
1066. Bhattacharyya N. Factors affecting survival in maxillary sinus cancer. *J Oral Maxillofac Surg*. 2003;61(9):1016-1021. [https://doi.org/10.1016/s0278-2391\(03\)00313-6](https://doi.org/10.1016/s0278-2391(03)00313-6)
1067. Lewis JS Jr. Sinonasal squamous cell carcinoma: a review with emphasis on emerging histologic subtypes and the role of human papillomavirus. *Head Neck Pathol*. 2016;10(1):60-67. <https://doi.org/10.1007/s12105-016-0692-y>
1068. Stelow EB, Bishop JA. Update from the 4th edition of the world health organization classification of head and neck tumours: tumors of the nasal cavity, paranasal sinuses and skull base. *Head Neck Pathol*. 2017;11(1):3-15. <https://doi.org/10.1007/s12105-017-0791-4>
1069. Vazquez A, Khan MN, Blake DM, Patel TD, Baredes S, Eloy JA. Sinonasal squamous cell carcinoma and the prognostic implications of its histologic variants: a population-based study. *Int Forum Allergy Rhinol*. 2014;5(1):85-91. <https://doi.org/10.1002/alr.21418>
1070. Mani N, Shah JP. Squamous cell carcinoma and its variants. *Adv Otorhinolaryngol*. 2020;84:124-136. <https://doi.org/10.1159/000457932>
1071. Contrera KJ, Woody NM, Rahman M, Sindwani R, Burkey BB. Clinical management of emerging sinonasal malignancies. *Head Neck*. 2020;42(8):2202-2212. <https://doi.org/10.1002/hed.26150>
1072. Bossi P, Saba NF, Vermorken JB, et al. The role of systemic therapy in the management of sinonasal cancer: a critical review. *Cancer Treat Rev*. 2015;41(10):836-843. <https://doi.org/10.1016/j.ctrv.2015.07.004>
1073. Abiri A, St John MA, Kuan EC. What is the role of induction chemotherapy in the treatment of locally advanced sinonasal squamous cell carcinoma? *Laryngoscope*. 2023;133(2):214-215. <https://doi.org/10.1002/lary.30474>
1074. Kim GE, Chang SK, Lee SW, et al. Neoadjuvant chemotherapy and radiation for inoperable carcinoma of the maxillary antrum. *Am J Clin Oncol: Cancer Clin Trials*. 2000;23(3):301-308. <https://doi.org/10.1097/00000421-200006000-00020>
1075. Noronha V, Patil VM, Joshi A, et al. Induction chemotherapy in technically unresectable locally advanced carcinoma of maxillary sinus. *Chemother Res Pract*. 2014;2014:487872. <https://doi.org/10.1155/2014/487872>
1076. Hanna EY, Cardenas AD, DeMonte F, et al. Induction chemotherapy for advanced squamous cell carcinoma of the paranasal sinuses. *Arch Otolaryngol Head Neck Surg*. 2011;137(1):78-81. <https://doi.org/10.1001/archoto.2010.231>
1077. Abdelmeguid AS, Teeramatwanich W, Roberts DB, et al. Neoadjuvant chemotherapy for locoregionally advanced squamous cell carcinoma of the paranasal sinuses. *Cancer*. 2021;127(11):1788-1795. <https://doi.org/10.1002/cncr.33452>
1078. Khoury T, Jang D, Carrau R, Ready N, Barak I, Hachem RA. Role of induction chemotherapy in sinonasal malignancies: a systematic review. *Int Forum Allergy Rhinol*. 2018;9(2):212-219. <https://doi.org/10.1002/alr.22229>
1079. Ock CY, Keam B, Kim TM, et al. Induction chemotherapy in head and neck squamous cell carcinoma of the paranasal sinus and nasal cavity: a role in organ preservation. *Korean J Intern Med*. 2016;31(3):570-578. <https://doi.org/10.3904/kjim.2015.020>

1080. Teitelbaum JI, Issa K, Barak IR, et al. Sinonasal squamous cell carcinoma outcomes: does treatment at a high-volume center confer survival benefit? *Otolaryngol Head Neck Surg.* 2020;163(5):986-991. <https://doi.org/10.1177/0194599820935395>
1081. Inuyama Y, Fujii M, Tanaka J, et al. Neoadjuvant chemotherapy in maxillary sinus carcinoma with cisplatin and peplomycin intraarterial infusion. *Auris Nasus Larynx.* 1985;12:S249-S254. [https://doi.org/10.1016/s0385-8146\(85\)80068-7](https://doi.org/10.1016/s0385-8146(85)80068-7)
1082. Nakatani H, Hirose K, Matsumoto N, et al. A totally implanted intra-arterial chemotherapy system for advanced maxillary sinus carcinoma. *ORL J Otorhinolaryngol Relat Spec.* 2009;71(Suppl. 1):116-122. <https://doi.org/10.1159/000265123>
1083. Shiga K, Yokoyama J, Hashimoto S, et al. Combined therapy after superselective arterial cisplatin infusion to treat maxillary squamous cell carcinoma. *Otolaryngol Head Neck Surg.* 2007;136(6):1003-1009. <https://doi.org/10.1016/j.otohns.2006.12.018>
1084. Su SY, Kupferman ME, DeMonte F, Levine NB, Raza SM, Hanna EY. Endoscopic resection of sinonasal cancers. *Curr Oncol Rep.* 2014;16(2):369. <https://doi.org/10.1007/s11912-013-0369-6>
1085. Rawal RB, Farzal Z, Federspiel JJ, Sreenath SB, Thorp BD, Zanation AM. Endoscopic resection of sinonasal malignancy: a systematic review and meta-analysis. *Otolaryngol Head Neck Surg.* 2016;155(3):376-386. <https://doi.org/10.1177/0194599816646968>
1086. Luong A, Citardi MJ, Batra PS. Management of sinonasal malignant neoplasms: defining the role of endoscopy. *Am J Rhinol Allergy.* 2010;24(2):150-155. <https://doi.org/10.2500/ajra.2010.24.3451>
1087. Xiao R, Joshi RR, Husain Q, et al. Timing of surgery and adjuvant radiation therapy for sinonasal malignancies: effect of surgical approach. *Head Neck.* 2019;41(10):3551-3563. <https://doi.org/10.1002/hed.25873>
1088. Cooper JS, Pajak TF, Forastiere AA, et al. Postoperative concurrent radiotherapy and chemotherapy for high-risk squamous-cell carcinoma of the head and neck. *N Engl J Med.* 2004;350(19):1937-1944. <https://doi.org/10.1056/nejmoa032646>
1089. Bernier J, Dommenege C, Ozsahin M, et al. Postoperative irradiation with or without concomitant chemotherapy for locally advanced head and neck cancer. *N Engl J Med.* 2004;350(19):1945-1952. <https://doi.org/10.1056/nejmoa032641>
1090. Homma A, Onimaru R, Matsuura K, et al. Dose-finding and efficacy confirmation trial of the superselective intra-arterial infusion of cisplatin and concomitant radiotherapy for locally advanced maxillary sinus cancer (Japan Clinical Oncology Group 1212): dose-finding phase. *Head Neck.* 2017;40(3):475-484. <https://doi.org/10.1002/hed.25001>
1091. Qiu X, Yang J. Clinical study of cetuximab combined with radical radiotherapy in the treatment of locally advanced sinonasal squamous cell carcinoma. *J BUON.* 2018;23(4):1111-1117.
1092. Mimica X, Yu Y, McGill M, et al. Organ preservation for patients with anterior mucosal squamous cell carcinoma of the nasal cavity: rhinectomy-free survival in those refusing surgery. *Head Neck.* 2019;41(8):2741-2747. <https://doi.org/10.1002/hed.25751>
1093. Dooley L, Shah J. Management of the neck in maxillary sinus carcinomas. *Curr Opin Otolaryngol Head Neck Surg.* 2015;23(2):107-114. <https://doi.org/10.1097/MOO.0000000000000138>
1094. Ahn PH, Mitra N, Alonso-Basanta M, et al. Risk of lymph node metastasis and recommendations for elective nodal treatment in squamous cell carcinoma of the nasal cavity and maxillary sinus: a SEER analysis. *Acta Oncol.* 2016;55(9-10):1107-1114. <https://doi.org/10.1080/0284186x.2016.1216656>
1095. Galloni C, Locatello LG, Bruno C, Cannavici A, Maggiore G, Gallo O. The role of elective neck treatment in the management of sinonasal carcinomas: a systematic review of the literature and a meta-analysis. *Cancers.* 2021;13(8):1842. <https://doi.org/10.3390/cancers13081842>
1096. Sangal NR, Lee Y, Brady JS, et al. The role of elective neck dissection in the treatment of maxillary sinus squamous cell carcinoma. *Laryngoscope.* 2017;128(8):1835-1841. <https://doi.org/10.1002/lary.27009>
1097. Abu-Ghanem S, Horowitz G, Abergel A, et al. Elective neck irradiation versus observation in squamous cell carcinoma of the maxillary sinus with N0 neck: a meta-analysis and review of the literature. *Head Neck.* 2014;37(12):1823-1828. <https://doi.org/10.1002/hed.23791>
1098. Le QT, Fu KK, Kaplan MJ, Terris DJ, Fee WE, Goffinet DR. Lymph node metastasis in maxillary sinus carcinoma. *Int J Radiat Oncol Biol Phys.* 2000;46(3):541-549. [https://doi.org/10.1016/s0360-3016\(99\)00453-8](https://doi.org/10.1016/s0360-3016(99)00453-8)
1099. Cantù G, Bimbi G, Miceli R, et al. Lymph node metastases in malignant tumors of the paranasal sinuses. *Arch Otolaryngol Head Neck Surg.* 2008;134(2):170-177. <https://doi.org/10.1001/archoto.2007.30>
1100. Crawford KL, Jafari A, Qualliotine JR, et al. Elective neck dissection for T3 /T4 cN0 sinonasal squamous cell carcinoma. *Head Neck.* 2020;42(12):3655-3662. <https://doi.org/10.1002/hed.26418>
1101. Berger MH, Tajudeen BA, St John MA, Tjoa T, Kuan EC. Should an elective neck dissection be performed for maxillary sinus squamous cell carcinoma? *Laryngoscope.* 2019;129(11):2445-2446. <https://doi.org/10.1002/lary.28242>
1102. Homma A, Hayashi R, Matsuura K, et al. Lymph node metastasis in T4 maxillary sinus squamous cell carcinoma: incidence and treatment outcome. *Ann Surg Oncol.* 2014;21(5):1706-1710. <https://doi.org/10.1245/s10434-014-3544-6>
1103. Riobello C, Vivanco B, Reda S, et al. Programmed death ligand-1 expression as immunotherapeutic target in sinonasal cancer. *Head Neck.* 2018;40(4):818-827. <https://doi.org/10.1002/hed.25067>
1104. García-Marin R, Reda S, Riobello C, et al. Prognostic and therapeutic implications of immune classification by CD8(+) tumor-infiltrating lymphocytes and PD-L1 expression in sinonasal squamous cell carcinoma. *Int J Mol Sci.* 2021;22(13):6926. <https://doi.org/10.3390/ijms22136926>
1105. Kim JH, Lee YS, Chung YS, et al. Treatment outcomes of concurrent chemoradiotherapy for locally advanced sinonasal squamous cell carcinoma: a single-institution study. *Acta Otolaryngol.* 2015;135(11):1189-1195. <https://doi.org/10.3109/00016489.2015.1061697>

1106. Thompson LDR. Middle ear and temporal bone papilloma: a clinicopathologic study and comprehensive literature review of 57 cases. *Head Neck Pathol.* 2021;15(4):1212-1220. <https://doi.org/10.1007/s12105-021-01334-4>
1107. Mirza S, Bradley PJ, Acharya A, Stacey M, Jones NS. Sinonasal inverted papillomas: recurrence, and synchronous and metachronous malignancy. *J Laryngol Otol.* 2007;121:857-864. <https://doi.org/10.1017/s002221510700624x>
1108. Lesperance MM, Esclamado RM. Squamous cell carcinoma arising in inverted papilloma. *Laryngoscope.* 1995;105(2):178-183. <https://doi.org/10.1288/00005537-199502000-00013>
1109. Anari S, Carrie S. Sinonasal inverted papilloma: narrative review. *J Laryngol Otol.* 2010;124(7):705-715. <https://doi.org/10.1017/s0022215110000599>
1110. Yan CH, Newman JG, Kennedy DW, Palmer JN, Adappa ND. Clinical outcomes of sinonasal squamous cell carcinomas based on tumor etiology. *Int Forum Allergy Rhinol.* 2017;7(5):508-513. <https://doi.org/10.1002/alr.21899>
1111. Lavertu P, Roberts JK, Kraus DH, et al. Squamous cell carcinoma of the paranasal sinuses. *Laryngoscope.* 1989;99(11):1130-1136. <https://doi.org/10.1288/00005537-198911000-00005>
1112. Yu HX, Liu G. Malignant transformation of sinonasal inverted papilloma: a retrospective analysis of 32 cases. *Oncol Lett.* 2014;8(6):2637-2641. <https://doi.org/10.3892/ol.2014.2539>
1113. Lee JJ, Peterson AM, Embry TW, et al. Survival outcomes of de novo vs inverted papilloma-associated sinonasal squamous cell carcinoma: a systematic review and meta-analysis. *JAMA Otolaryngol Head Neck Surg.* 2021;147(4):350-359. <https://doi.org/10.1001/jamaoto.2020.5261>
1114. Birkenbeuel JL, Pang JC, Lee A, et al. Long-term outcomes in sinonasal squamous cell carcinoma arising from inverted papilloma: systematic review. *Head Neck.* 2022;44(4):1014-1029. <https://doi.org/10.1002/hed.26995>
1115. Yu MS, Lim WS, Lee BJ, Chung YS. Squamous cell carcinoma associated with inverted papilloma of the maxillary sinus: our experience with 21 patients. *Clin Otolaryngol.* 2017;42(5):1048-1052. <https://doi.org/10.1111/coa.12804>
1116. Lobo BC, D'Anza B, Farlow JL, et al. Outcomes of sinonasal squamous cell carcinoma with and without association of inverted papilloma: a multi-institutional analysis. *Am J Rhinol Allergy.* 2017;31(5):305-309. <https://doi.org/10.2500/ajra.2017.31.4470>
1117. Yasumatsu R, Jiromaru R, Hongo T, et al. A clinical analysis of sinonasal squamous cell carcinoma: a comparison of de novo squamous cell carcinoma and squamous cell carcinoma arising from inverted papilloma. *Acta Otolaryngol.* 2020;140(8):698-703. <https://doi.org/10.1080/00016489.2020.1758342>
1118. Quan H, Zhang H, Zou L, Yuan W, Wang S. Comparison of outcomes between patients with de-novo sinonasal squamous cell carcinoma vs malignant transformations from inverted papillomas. *Int Forum Allergy Rhinol.* 2020;10(6):762-767. <https://doi.org/10.1002/alr.22556>
1119. Li Y, Wang C, Wang R, et al. Prognostic factors of sinonasal squamous cell carcinomas arising de novo and from inverted papilloma. *Am J Rhinol Allergy.* 2020;35(1):114-121. <https://doi.org/10.1177/1945892420939422>
1120. Miyazaki T, Haku Y, Yoshizawa A, et al. Clinical features of nasal and sinonasal inverted papilloma associated with malignancy. *Auris Nasus Larynx.* 2018;45(5):1014-1019. <https://doi.org/10.1016/j.anl.2018.02.009>
1121. Birkenbeuel JL, Goshtasbi K, Adappa ND, Palmer JN, Tong CCL, Kuan EC. Recurrence rates of de-novo versus inverted papilloma-transformed sinonasal squamous cell carcinoma: a meta-analysis. *Rhinology.* 2022;60(6):402-410. <https://doi.org/10.4193/Rhin22.187>
1122. Ojiri H, Ujita M, Tada S, Fukuda K. Potentially distinctive features of sinonasal inverted papilloma on MR imaging. *Am J Roentgenol.* 2000;175(2):465-468. <https://doi.org/10.2214/ajr.175.2.1750465>
1123. Jeon TY, Kim HJ, Chung SK, et al. Sinonasal inverted papilloma: value of convoluted cerebriform pattern on MR imaging. *AJNR Am J Neuroradiol.* 2008;29(8):1556-1560. <https://doi.org/10.3174/ajnr.A1128>
1124. Yan CH, Tong CCL, Penta M, et al. Imaging predictors for malignant transformation of inverted papilloma. *Laryngoscope.* 2018;129(4):777-782. <https://doi.org/10.1002/lary.27582>
1125. Fujima N, Nakamaru Y, Sakashita T, et al. Differentiation of squamous cell carcinoma and inverted papilloma using non-invasive MR perfusion imaging. *Dentomaxillofac Radiol.* 2015;44(9):20150074. <https://doi.org/10.1259/dmfr.20150074>
1126. Suh CH, Lee JH, Chung MS, et al. MRI predictors of malignant transformation in patients with inverted papilloma: a decision tree analysis using conventional imaging features and histogram analysis of apparent diffusion coefficients. *Korean J Radiol.* 2021;22(5):751-758. <https://doi.org/10.3348/kjr.2020.0576>
1127. Gencturk M, Ozturk K, Caicedo-Granados E, Li F, Cayci Z. Application of diffusion-weighted MR imaging with ADC measurement for distinguishing between the histopathological types of sinonasal neoplasms. *Clin Imaging.* 2019;55:76-82. <https://doi.org/10.1016/j.clinimag.2019.02.004>
1128. Das A, Bhalla AS, Sharma R, et al. Can diffusion weighted imaging aid in differentiating benign from malignant sinonasal masses?: a useful adjunct. *Pol J Radiol.* 2017;82:345-355. <https://doi.org/10.12659/PJR.900633>
1129. Hyams VJ. Papillomas of the nasal cavity and paranasal sinuses. *Ann Otol Rhinol Laryngol.* 1971;80(2):192-206. <https://doi.org/10.1177/000348947108000205>
1130. Zhai C, Wang H, Li S, Wang D. Clinicopathological analysis of low-grade papillary Schneiderian carcinoma: report of five new cases and review of the literature. *Histopathology.* 2021;79(3):370-380. <https://doi.org/10.1111/his.14347>
1131. Weiner JS, Sherris D, Kasperbauer J, Lewis J, Li H, Persing D. Relationship of human papillomavirus to Schneiderian papillomas. *Laryngoscope.* 1999;109(1):21-26. <https://doi.org/10.1097/00005537-199901000-00005>
1132. Orgain CA, Shibuya TY, Thompson LD, Keschner DB, Garg R, Lee JT. Long-term follow-up of a patient with malignant transformation of inverted papilloma into sinonasal undifferentiated carcinoma. *Allergy Rhinol.* 2017;8(3):173-177. <https://doi.org/10.2500/ar.2017.8.0209>
1133. Saab-Chalhoub MW, Guo X, Shi Q, Chernock RD, Lewis JS Jr. Low grade papillary sinonasal (Schneiderian) carcinoma: a series of five cases of a unique malignant neoplasm with comparison to inverted papilloma and conventional nonkeratinizing squamous cell carcinoma. *Head Neck*

- Pathol.* 2021;15(4):1221-1234. <https://doi.org/10.1007/s12105-021-01335-3>
1134. Rooper LM, Agaimy A, Dickson BC, et al. DEK-AFF2 carcinoma of the sinonasal region and skull base. *Am J Surg Pathol.* 2021;45(12):1682-1693. <https://doi.org/10.1097/pas.0000000000001741>
1135. Kim DY, Hong SL, Lee CH, et al. Inverted papilloma of the nasal cavity and paranasal sinuses: a Korean multicenter study. *Laryngoscope.* 2012;122(3):487-494. <https://doi.org/10.1002/lary.22495>
1136. Mirza N, Montone K, Sato Y, Kroger H, Kennedy DW. Identification of p53 and human papilloma virus in Schneiderian papillomas. *Laryngoscope.* 1998;108(4):497-501. <https://doi.org/10.1097/00005537-199804000-00007>
1137. Stoddard DG, Keeney MG, Gao G, Smith DI, Garcia JJ, O'Brien EK. Transcriptional activity of HPV in inverted papilloma demonstrated by in situ hybridization for E6/E7 mRNA. *Otolaryngol Head Neck Surg.* 2015;152(4):752-758. <https://doi.org/10.1177/0194599815571285>
1138. Hieggelke L, Heydt C, Castiglione R, et al. Mismatch repair deficiency and somatic mutations in human sinonasal tumors. *Cancers.* 2021;13(23):6081. <https://doi.org/10.3390/cancers13236081>
1139. Sasaki E, Nishikawa D, Hanai N, Hasegawa Y, Yatabe Y. Sinonasal squamous cell carcinoma and EGFR mutations: a molecular footprint of a benign lesion. *Histopathology.* 2018;73(6):953-962. <https://doi.org/10.1111/his.13732>
1140. Tong CCL, Koptyra M, Raman P, et al. Targeted gene expression profiling of inverted papilloma and squamous cell carcinoma. *Int Forum Allergy Rhinol.* 2021;12(2):200-209. <https://doi.org/10.1002/alr.22882>
1141. Robin PE, Powell DJ, Stansbie JM. Carcinoma of the nasal cavity and paranasal sinuses: incidence and presentation of different histological types. *Clin Otolaryngol.* 1979;4(6):431-456. <https://doi.org/10.1111/j.1365-2273.1979.tb01776.x>
1142. Jankowski R, Georgel T, Vignaud JM, et al. Endoscopic surgery reveals that woodworkers' adenocarcinomas originate in the olfactory cleft. *Rhinology.* 2007;45(4):308-314.
1143. Acheson ED, Hadfield EH, Macbeth RG. Carcinoma of the nasal cavity and accessory sinuses in woodworkers. *Lancet.* 1967;289(7485):311-312. [https://doi.org/10.1016/s0140-6736\(67\)91243-3](https://doi.org/10.1016/s0140-6736(67)91243-3)
1144. Rampinelli V, Ferrari M, Nicolai P. Intestinal-type adenocarcinoma of the sinonasal tract: an update. *Curr Opin Otolaryngol Head Neck Surg.* 2018;26(2):115-121. <https://doi.org/10.1097/moo.0000000000000445>
1145. Fiaux-Camus D, Chevret S, Oker N, et al. Prognostic value of the seventh AJCC/UICC TNM classification of intestinal-type ethmoid adenocarcinoma: systematic review and risk prediction model. *Head Neck.* 2017;39(4):668-678. <https://doi.org/10.1002/hed.24663>
1146. Nicolai P, Schreiber A, Bolzoni Villaret A, et al. Intestinal type adenocarcinoma of the ethmoid: outcomes of a treatment regimen based on endoscopic surgery with or without radiotherapy. *Head Neck.* 2015;38(S1):E996-E1003. <https://doi.org/10.1002/hed.24144>
1147. Barnes L. Intestinal-type adenocarcinoma of the nasal cavity and paranasal sinuses. *Am J Surg Pathol.* 1986;10(3):192-202. <https://doi.org/10.1097/00000478-198603000-00006>
1148. Kleinsasser O, Schroeder HG. Adenocarcinomas of the inner nose after exposure to wood dust. *Arch Otorhinolaryngol.* 1988;245(1):1-15. <https://doi.org/10.1007/bf00463541>
1149. Franchi A, Palomba A, Fondi C, et al. Immunohistochemical investigation of tumorigenic pathways in sinonasal intestinal-type adenocarcinoma. A tissue microarray analysis of 62 cases. *Histopathology.* 2011;59(1):98-105. <https://doi.org/10.1111/j.1365-2559.2011.03887.x>
1150. Turri-Zanoni M, Battaglia P, Lambertoni A, et al. Treatment strategies for primary early-stage sinonasal adenocarcinoma: a retrospective bi-institutional case-control study. *J Surg Oncol.* 2015;112(5):561-567. <https://doi.org/10.1002/jso.24038>
1151. Licitra L, Suardi S, Bossi P, et al. Prediction of TP53 status for primary cisplatin, fluorouracil, and leucovorin chemotherapy in ethmoid sinus intestinal-type adenocarcinoma. *J Clin Oncol.* 2004;22(24):4901-4906. <https://doi.org/10.1200/jco.2004.05.071>
1152. Cantu G, Solero CL, Mariani L, et al. Intestinal type adenocarcinoma of the ethmoid sinus in wood and leather workers: a retrospective study of 153 cases. *Head Neck.* 2011;33(4):535-542. <https://doi.org/10.1002/hed.21485>
1153. Van Gerven L, Jorissen M, Nuyts S, Hermans R, Vander Poorten V. Long-term follow-up of 44 patients with adenocarcinoma of the nasal cavity and sinuses primarily treated with endoscopic resection followed by radiotherapy. *Head Neck.* 2011;33(6):898-904. <https://doi.org/10.1002/hed.21556>
1154. Huang EI, Lu A, Tsai YT, et al. Decreasing recurrence and increasing survival rates in patients of ethmoid or sphenoid intestinal-type adenocarcinomas: systematic review and meta-analysis with 1126 cases. *Medicine.* 2021;100(40):e27341. <https://doi.org/10.1097/MD.00000000000027341>
1155. Pérez-Escuredo J, García Martínez J, García-Inclán C, et al. Establishment and genetic characterization of an immortal tumor cell line derived from intestinal-type sinonasal adenocarcinoma. *Cell Oncol.* 2011;34(1):23-31. <https://doi.org/10.1007/s13402-010-0002-8>
1156. Franchi A, Innocenti DRD, Palomba A, et al. Low prevalence of K-RAS, EGF-R and BRAF mutations in sinonasal adenocarcinomas. Implications for anti-EGFR treatments. *Pathol Oncol Res.* 2013;20(3):571-579. <https://doi.org/10.1007/s12253-013-9730-1>
1157. Donhuijsen K, Kollecker I, Petersen P, Gaßler N, Schulze J, Schroeder HG. Metastatic behaviour of sinonasal adenocarcinomas of the intestinal type (ITAC). *Eur Arch Otorhinolaryngol.* 2015;273(3):649-654. <https://doi.org/10.1007/s00405-015-3596-7>
1158. Bhayani MK, Yilmaz T, Sweeney A, et al. Sinonasal adenocarcinoma: a 16-year experience at a single institution. *Head Neck.* 2014;36(10):1490-1496. <https://doi.org/10.1002/hed.23485>
1159. Orvidas LJ, Lewis JE, Weaver AL, Bagniewski SM, Olsen KD. Adenocarcinoma of the nose and paranasal sinuses: a retrospective study of diagnosis, histologic characteristics, and outcomes in 24 patients. *Head Neck.* 2005;27(5):370-375. <https://doi.org/10.1002/hed.20168>
1160. Schatz C, Sprung S, Scharfing V, et al. Dysregulation of translation factors EIF2S1, EIF5A and EIF6 in intestinal-type adenocarcinoma (ITAC). *Cancers.* 2021;13(22):5649. <https://doi.org/10.3390/cancers13225649>

1161. Camp S, Van Gerven L, Poorten VV, et al. Long-term follow-up of 123 patients with adenocarcinoma of the sinonasal tract treated with endoscopic resection and postoperative radiation therapy. *Head Neck*. 2016;38(2):294-300. <https://doi.org/10.1002/hed.23900>
1162. Hoeben A, van de Winkel L, Hoebers F, et al. Intestinal-type sinonasal adenocarcinomas: the road to molecular diagnosis and personalized treatment. *Head Neck*. 2016;38(10):1564-1570. <https://doi.org/10.1002/hed.24416>
1163. García-Marín R, Reda S, Riobello C, et al. CD8(+) tumour-infiltrating lymphocytes and tumour microenvironment immune types as biomarkers for immunotherapy in sinonasal intestinal-type adenocarcinoma. *Vaccines*. 2020;8(2):202. <https://doi.org/10.3390/vaccines8020202>
1164. Patel NN, Maina IW, Kuan EC, et al. Adenocarcinoma of the sinonasal tract: a review of the national cancer database. *J Neurol Surg B Skull Base*. 2020;81(6):701-708. <https://doi.org/10.1055/s-0039-1696707>
1165. Progetti F, Mesturoux L, Coulibaly B, et al. Study of MET protein levels and MET gene copy number in 72 sinonasal intestinal-type adenocarcinomas. *Head Neck*. 2014;37(11):1563-1568. <https://doi.org/10.1002/hed.23795>
1166. Vergez S, du Mayne MD, Coste A, et al. Multicenter study to assess endoscopic resection of 159 sinonasal adenocarcinomas. *Ann Surg Oncol*. 2014;21(4):1384-1390. <https://doi.org/10.1245/s10434-013-3385-8>
1167. Oren N, Vaysberg A, Ginat DT. Updated WHO nomenclature of head and neck lesions and associated imaging findings. *Insights Imaging*. 2019;10(1):72-72. <https://doi.org/10.1186/s13244-019-0760-4>
1168. Kleinsasser O. Terminal tubulus adenocarcinoma of the nasal seromucous glands. A specific entity. *Arch Otorhinolaryngol*. 1985;241(2):183-193. <https://doi.org/10.1007/bf00454353>
1169. Neto AG, Pineda-Daboin K, Luna MA. Sinonasal tract seromucous adenocarcinomas: a report of 12 cases. *Ann Diagn Pathol*. 2003;7(3):154-159. [https://doi.org/10.1016/s1092-9134\(03\)00012-1](https://doi.org/10.1016/s1092-9134(03)00012-1)
1170. Luna MA. Sinonasal tubulopapillary low-grade adenocarcinoma. *Adv Anat Pathol*. 2005;12(3):109-115. <https://doi.org/10.1097/01.pap.0000163961.18730.ba>
1171. Thompson LDR, Franchi A. New tumor entities in the 4th edition of the World Health Organization classification of head and neck tumors: nasal cavity, paranasal sinuses and skull base. *Virchows Arch*. 2018;472(3):315-330. <https://doi.org/10.1007/s00428-017-2116-0>
1172. Bullock MJ. Low-grade epithelial proliferations of the sinonasal tract. *Head Neck Pathol*. 2016;10(1):47-59. <https://doi.org/10.1007/s12105-016-0691-z>
1173. Jo VY, Mills SE, Cathro HP, Carlson DL, Stelow EB. Low-grade sinonasal adenocarcinomas. *Am J Surg Pathol*. 2009;33(3):401-408. <https://doi.org/10.1097/pas.0b013e3181874ee8>
1174. Yue C, Piao Y, Bai Y, Liu H, Zhang L. Sinonasal low-grade non-intestinal-type adenocarcinoma: a retrospective analysis and literature review. *Ann Diagn Pathol*. 2021;52:151709. <https://doi.org/10.1016/j.anndiagpath.2021.151709>
1175. Stelow EB. Glandular neoplasia of the sinonasal tract. *Surg Pathol Clin*. 2017;10(1):89-102. <https://doi.org/10.1016/j.path.2016.10.004>
1176. Heffner DK, Hyams VJ, Hauck KW, Lingeman C. Low-grade adenocarcinoma of the nasal cavity and paranasal sinuses. *Cancer*. 1982;50(2):312-322. [https://doi.org/10.1002/1097-0142\(19820715\)50:2\(312::aid-cnrc2820500225\)3.0.co;2-z](https://doi.org/10.1002/1097-0142(19820715)50:2(312::aid-cnrc2820500225)3.0.co;2-z)
1177. Stelow EB, Mills SE, Jo VY, Carlson DL. Adenocarcinoma of the upper aerodigestive tract. *Adv Anat Pathol*. 2010;17(4):262-269. <https://doi.org/10.1097/pap.0b013e3181e3bf80>
1178. Chen MM, Roman SA, Sosa JA, Judson BL. Predictors of survival in sinonasal adenocarcinoma. *J Neurol Surg B Skull Base*. 2015;76(3):208-213. <https://doi.org/10.1055/s-0034-1543995>
1179. Stelow EB, Jo VY, Mills SE, Carlson DL. A histologic and immunohistochemical study describing the diversity of tumors classified as sinonasal high-grade nonintestinal adenocarcinomas. *Am J Surg Pathol*. 2011;35(7):971-980. <https://doi.org/10.1097/pas.0b013e31821cbd72>
1180. Purgina B, Bastaki JM, Duvvuri U, Seethala RR. A subset of sinonasal non-intestinal type adenocarcinomas are truly seromucinous adenocarcinomas: a morphologic and immunophenotypic assessment and description of a novel pitfall. *Head Neck Pathol*. 2015;9(4):436-446. <https://doi.org/10.1007/s12105-015-0615-3>
1181. Skalova A, Sar A, Laco J, et al. The role of SATB2 as a diagnostic marker of sinonasal intestinal-type adenocarcinoma. *Appl Immunohistochem Molecul Morphol*. 2018;26(2):140-146. <https://doi.org/10.1097/pai.0000000000000388>
1182. World Health Organization, International Agency for Research on Cancer. *Pathology and Genetics of Head and Neck Tumours*. IARC Press; 2005.
1183. Choi H. Sinonasal adenocarcinoma: evidence for histogenetic divergence of the enteric and nonenteric phenotypes. *Hum Pathol*. 2003;34(11):1101-1107. <https://doi.org/10.1053/j.humphath.2003.08.024>
1184. Baněčková M, Michal M, Laco J, et al. Immunohistochemical and genetic analysis of respiratory epithelial adenomatoid hamartomas and seromucinous hamartomas: are they precursor lesions to sinonasal low-grade tubulopapillary adenocarcinomas? *Hum Pathol*. 2020;97:94-102. <https://doi.org/10.1016/j.humphath.2019.09.018>
1185. Resto VA, Krane JF, Faquin WC, Lin DT. Immunohistochemical distinction of intestinal-type sinonasal adenocarcinoma from metastatic adenocarcinoma of intestinal origin. *Ann Otol Rhinol Laryngol*. 2006;115(1):59-64. <https://doi.org/10.1177/000348940611500109>
1186. Taverna C, Maggiore G, Cannavici A, Bonomo P, Santucci M, Franchi A. Immunohistochemical profiling of mucins in sinonasal adenocarcinomas. *Pathol Res Pract*. 2019;215(7):152439. <https://doi.org/10.1016/j.prp.2019.152439>
1187. Tilson MP, Gallia GL, Bishop JA. Among sinonasal tumors, CDX-2 immunoreactivity is not restricted to intestinal-type adenocarcinomas. *Head Neck Pathol*. 2014;8(1):59-65. <https://doi.org/10.1007/s12105-013-0475-7>
1188. Micheloni G, Millefanti G, Conti A, et al. Identification of OTX1 and OTX2 as two possible molecular markers for sinonasal carcinomas and olfactory neuroblastomas. *J Vis Exp*. 2019(144). <https://doi.org/10.3791/56880-v>
1189. Pirrone C, Chiaravalli AM, Marando A, et al. OTX1 and OTX2 as possible molecular markers of sinonasal carcinomas and olfactory neuroblastomas. *Eur J Histochem*. 2017;61(1):2730. <https://doi.org/10.4081/ejh.2017.2730>

1190. Kubik M, Barasch N, Choby G, Seethala R, Snyderman C. Sinonasal renal cell-like carcinoma: case report and review of the literature. *Head Neck Pathol.* 2017;11(3):333-337. <https://doi.org/10.1007/s12105-016-0774-x>
1191. Chen Z, Wang Z, Shi H, Liu Q. Renal cell-like carcinoma of the nasal cavity: a case report and review of the literature. *Diagn Pathol.* 2017;12(1):75. <https://doi.org/10.1186/s13000-017-0660-1>
1192. Dean KE, Shatzkes D, Phillips CD. Imaging review of new and emerging sinonasal tumors and tumor-like entities from the fourth edition of the World Health Organization classification of head and neck tumors. *Am J Neuroradiol.* 2019;40(4):584-590. <https://doi.org/10.3174/ajnr.A5978>
1193. Bogaerts S, Vander Poorten V, Nuyts S, Van den Bogaert W, Jorissen M. Results of endoscopic resection followed by radiotherapy for primarily diagnosed adenocarcinomas of the paranasal sinuses. *Head Neck.* 2008;30(6):728-736. <https://doi.org/10.1002/hed.20771>
1194. Nicolai P, Castelnuovo P, Lombardi D, et al. Role of endoscopic surgery in the management of selected malignant epithelial neoplasms of the naso-ethmoidal complex. *Head Neck.* 2007;29(12):1075-1082. <https://doi.org/10.1002/hed.20636>
1195. Vander Poorten V, Jorissen M. A comprehensive update on intestinal- and non-intestinal-type adenocarcinomas. *Adv Otorhinolaryngol.* 2020;84:137-153. <https://doi.org/10.1159/000457934>
1196. Choussy O, Ferron C, Védrine PO, et al. Adenocarcinoma of ethmoid: a GETTEC retrospective multicenter study of 418 cases. *Laryngoscope.* 2008;118(3):437-443. <https://doi.org/10.1097/mlg.0b013e31815b48e3>
1197. König M, Osnes T, Bratland Å, Jebsen P, Meling TR. Treatment of sinonasal adenocarcinoma: a population-based prospective cohort study. *J Neurol Surg B Skull Base.* 2020;81(6):627-637. <https://doi.org/10.1055/s-0039-1694050>
1198. Rhee CS, Won TB, Lee CH, et al. Adenoid cystic carcinoma of the sinonasal tract: treatment results. *Laryngoscope.* 2006;116(6):982-986. <https://doi.org/10.1097/01.mlg.0000216900.03188.48>
1199. Kashiwazaki R, Turner MT, Geltzeiler M, et al. The endoscopic endonasal approach for sinonasal and nasopharyngeal adenoid cystic carcinoma. *Laryngoscope.* 2020;130(6):1414-1421. <https://doi.org/10.1002/lary.28100>
1200. Unsal AA, Chung SY, Zhou AH, Baredes S, Eloy JA. Sinonasal adenoid cystic carcinoma: a population-based analysis of 694 cases. *Int Forum Allergy Rhinol.* 2016;7(3):312-320. <https://doi.org/10.1002/alr.21875>
1201. Spiro RH, Huvos AG. Stage means more than grade in adenoid cystic carcinoma. *Am J Surg.* 1992;164(6):623-628. [https://doi.org/10.1016/s0002-9610\(05\)80721-4](https://doi.org/10.1016/s0002-9610(05)80721-4)
1202. Koltai P. Cylindroma in the upper air passages and its treatment. *J Laryngol Otol.* 1959;73(4):261-267. <https://doi.org/10.1017/s0022215100055262>
1203. Naficy S, Disher MJ, Esclamado RM. Adenoid cystic carcinoma of the paranasal sinuses. *Am J Rhinol.* 1999;13(4):311-314. <https://doi.org/10.2500/105065899782102872>
1204. Pitman KT, Prokopakis EP, Aydogan B, et al. The role of skull base surgery for the treatment of adenoid cystic carcinoma of the sinonasal tract. *Head Neck.* 1999;21(5):402-407. [https://doi.org/10.1002/\(sici\)1097-0347\(199908\)21:5\(402::aid-hed4\)3.0.co;2-z](https://doi.org/10.1002/(sici)1097-0347(199908)21:5(402::aid-hed4)3.0.co;2-z)
1205. Ramakrishna R, Raza SM, Kupferman M, Hanna E, DeMonte F. Adenoid cystic carcinoma of the skull base: results with an aggressive multidisciplinary approach. *J Neurosurg.* 2016;124(1):115-121. <https://doi.org/10.3171/2015.1.jns142462>
1206. Amit M, Na'ara S, Trejo-Leider L, et al. Defining the surgical margins of adenoid cystic carcinoma and their impact on outcome: an international collaborative study. *Head Neck.* 2017;39(5):1008-1014. <https://doi.org/10.1002/hed.24740>
1207. Kim KH, Sung MW, Chung PS, Rhee CS, Park CI, Kim WH. Adenoid cystic carcinoma of the head and neck. *Arch Otorhinolaryngol Head Neck Surg.* 1994;120(7):721-726. <https://doi.org/10.1001/archotol.1994.01880310027006>
1208. Prokopakis EP, Snyderman CH, Hanna EY, Carrau RL, Johnson JT, D'Amico F. Risk factors for local recurrence of adenoid cystic carcinoma: the role of postoperative radiation therapy. *Am J Otolaryngol.* 1999;20(5):281-286. [https://doi.org/10.1016/s0196-0709\(99\)90028-5](https://doi.org/10.1016/s0196-0709(99)90028-5)
1209. Garden AS, Weber RS, Morrison WH, Ang KK, Peters LJ. The influence of positive margins and nerve invasion in adenoid cystic carcinoma of the head and neck treated with surgery and radiation. *Int J Radiat Oncol Biol Phys.* 1995;32(3):619-626. [https://doi.org/10.1016/0360-3016\(95\)00122-f](https://doi.org/10.1016/0360-3016(95)00122-f)
1210. Triantafillidou K, Dimitrakopoulos J, Iordanidis F, Koufogiannis D. Management of adenoid cystic carcinoma of minor salivary glands. *J Oral Maxillofac Surg.* 2006;64(7):1114-1120. <https://doi.org/10.1016/j.joms.2005.06.017>
1211. Miglianico L, Eschwege F, Marandas P, Wibault P. Cervico-facial adenoid cystic carcinoma: study of 102 cases. Influence of radiation therapy. *Int J Radiat Oncol Biol Phys.* 1987;13(5):673-678. [https://doi.org/10.1016/0360-3016\(87\)90284-7](https://doi.org/10.1016/0360-3016(87)90284-7)
1212. Bhandare N, Monroe AT, Morris CG, Bhatti MT, Mendenhall WM. Does altered fractionation influence the risk of radiation-induced optic neuropathy? *Int J Radiat Oncol Biol Phys.* 2005;62(4):1070-1077. <https://doi.org/10.1016/j.ijrobp.2004.12.009>
1213. Monroe AT, Bhandare N, Morris CG, Mendenhall WM. Preventing radiation retinopathy with hyperfractionation. *Int J Radiat Oncol Biol Phys.* 2005;61(3):856-864. <https://doi.org/10.1016/j.ijrobp.2004.07.664>
1214. Suit HD. Protons to replace photons in external beam radiation therapy? *Clin Oncol.* 2003;15(1):S29-S31. <https://doi.org/10.1053/clon.2002.0171>
1215. Tauxe WN, McDonald JR, Devine KD. A century of cylindromas: short review and report of 27 adenoid cystic carcinomas arising in the upper respiratory passages. *Arch Otorhinolaryngol Head Neck Surg.* 1962;75(4):364-376. <https://doi.org/10.1001/archotol.1962.00740040373009>
1216. Bhattacharyya N. Survival and staging characteristics for non-squamous cell malignancies of the maxillary sinus. *Arch Otolaryngol Head Neck Surg.* 2003;129(3):334. <https://doi.org/10.1001/archotol.129.3.334>
1217. Triantafillou V, Maina IW, Kuan EC, et al. Sinonasal mucoepidermoid carcinoma: a review of the National Cancer Database. *Int Forum Allergy Rhinol.* 2019;9(9):1046-1053. <https://doi.org/10.1002/alr.22379>

1218. Wolfish EB, Nelson BL, Thompson LDR. Sinonasal tract mucoepidermoid carcinoma: a clinicopathologic and immunophenotypic study of 19 cases combined with a comprehensive review of the literature. *Head Neck Pathol.* 2012;6(2):191-207. <https://doi.org/10.1007/s12105-011-0320-9>
1219. da Cruz Perez DE, Pires FR, Lopes MA, de Almeida OP, Kowalski LP. Adenoid cystic carcinoma and mucoepidermoid carcinoma of the maxillary sinus: report of a 44-year experience of 25 cases from a single institution. *J Oral Maxillofac Surg.* 2006;64(11):1592-1597. <https://doi.org/10.1016/j.joms.2005.11.088>
1220. Biron VL, Lentsch EJ, Gerry DR, Bewley AF. Case-control analysis of survival outcomes in sinonasal acinic cell carcinoma. *Int Forum Allergy Rhinol.* 2014;4(6):507-511. <https://doi.org/10.1002/alr.21301>
1221. Hawkins DS, Spunt SL, Skapek SX, COG Soft Tissue Sarcoma Committee. Children's Oncology Group's 2013 blueprint for research: soft tissue sarcomas. *Pediatr Blood Cancer.* 2013;60(6):1001-1008. <https://doi.org/10.1002/psc.24435>
1222. Sultan I, Qaddoumi I, Yaser S, Rodriguez-Galindo C, Ferrari A. Comparing adult and pediatric rhabdomyosarcoma in the surveillance, epidemiology and end results program, 1973 to 2005: an analysis of 2,600 patients. *J Clin Oncol.* 2009;27(20):3391-3397. <https://doi.org/10.1200/JCO.2008.19.7483>
1223. Leiner J, Le Loarer F. The current landscape of rhabdomyosarcomas: an update. *Virchows Arch.* 2020;476(1):97-108. <https://doi.org/10.1007/s00428-019-02676-9>
1224. Raney RB, Meza J, Anderson JR, et al. Treatment of children and adolescents with localized parameningeal sarcoma: experience of the Intergroup Rhabdomyosarcoma Study Group protocols IRS-II through -IV, 1978-1997. *Med Pediatr Oncol.* 2002;38(1):22-32. <https://doi.org/10.1002/mpo.1259>
1225. Merks JHM, De Salvo GL, Bergeron C, et al. Parameningeal rhabdomyosarcoma in pediatric age: results of a pooled analysis from North American and European cooperative groups. *Ann Oncol.* 2014;25(1):231-236. <https://doi.org/10.1093/annonc/mdt426>
1226. Crist WM, Anderson JR, Meza JL, et al. Intergroup rhabdomyosarcoma study-IV: results for patients with non-metastatic disease. *J Clin Oncol.* 2001;19(12):3091-3102. <https://doi.org/10.1200/JCO.2001.19.12.3091>
1227. Maurer HM, Gehan EA, Beltangady M, et al. The intergroup rhabdomyosarcoma study-II. *Cancer.* 1993;71(5):1904-1922. [https://doi.org/10.1002/1097-0142\(19930301\)71:5\(1904::aid-ncr2820710530\)3.0.co;2-x](https://doi.org/10.1002/1097-0142(19930301)71:5(1904::aid-ncr2820710530)3.0.co;2-x)
1228. Raney RB, Maurer HM, Anderson JR, et al. The intergroup rhabdomyosarcoma study group (IRSG): major lessons from the IRS-I through IRS-IV studies as background for the current IRS-V treatment protocols. *Sarcoma.* 2001;5(1):9-15. <https://doi.org/10.1080/13577140120048890>
1229. Siddiqui SH, Siddiqui E, Bavier RD, et al. Clinicopathologic traits and prognostic factors associated with pediatric sinonasal rhabdomyosarcoma. *Int Forum Allergy Rhinol.* 2019;9(4):363-369. <https://doi.org/10.1002/alr.22267>
1230. Fyrmpas G, Wurm J, Athanassiadou F, et al. Management of paediatric sinonasal rhabdomyosarcoma. *J Laryngol Otol.* 2009;123(9):990-996. <https://doi.org/10.1017/S0022215109005337>
1231. Sparber-Sauer M, Ferrari A, Kosztyla D, et al. Long-term results from the multicentric European randomized phase 3 trial CWS/RMS-96 for localized high-risk soft tissue sarcoma in children, adolescents, and young adults. *Pediatr Blood Cancer.* 2022;69(9):e29691. <https://doi.org/10.1002/pbc.29691>
1232. Crist W, Gehan EA, Ragab AH, et al. The third intergroup rhabdomyosarcoma study. *J Clin Oncol.* 1995;13(3):610-630. <https://doi.org/10.1200/JCO.1995.13.3.610>
1233. Arndt CAS, Stoner JA, Hawkins DS, et al. Vincristine, actinomycin, and cyclophosphamide compared with vincristine, actinomycin, and cyclophosphamide alternating with vincristine, topotecan, and cyclophosphamide for intermediate-risk rhabdomyosarcoma: children's oncology group study D9803. *J Clin Oncol.* 2009;27(31):5182-5188. <https://doi.org/10.1200/JCO.2009.22.3768>
1234. Oberlin O, Rey A, Sanchez de Toledo J, et al. Randomized comparison of intensified six-drug versus standard three-drug chemotherapy for high-risk nonmetastatic rhabdomyosarcoma and other chemotherapy-sensitive childhood soft tissue sarcomas: long-term results from the International Society of Pediatric Oncology MMT95 study. *J Clin Oncol.* 2012;30(20):2457-2465. <https://doi.org/10.1200/JCO.2011.40.3287>
1235. Thompson CF, Kim BJ, Lai C, et al. Sinonasal rhabdomyosarcoma: prognostic factors and treatment outcomes. *Int Forum Allergy Rhinol.* 2013;3(8):678-683. <https://doi.org/10.1002/alr.21157>
1236. Sercarz JA, Mark RJ, Tran L, Storper I, Calcatera TC. Sarcomas of the nasal cavity and paranasal sinuses. *Ann Otol Rhinol Laryngol.* 1994;103(9):699-704. <https://doi.org/10.1177/000348949410300907>
1237. Li W, Lu H, Wang D. Therapeutic outcome and prognostic factors in sinonasal rhabdomyosarcoma: a single-institution case series. *J Cancer Res Clin Oncol.* 2019;145(11):2793-2802. <https://doi.org/10.1007/s00432-019-03009-8>
1238. Kana LA, Smith JD, Bellile EL, Chugh R, McKean EL. Surgical management of rhabdomyosarcoma of the nasal cavity and paranasal sinuses: analysis of operative indications, settings, and outcomes. *J Neurol Surg B Skull Base.* 2022;83(4):350-358. <https://doi.org/10.1055/s-0041-1736590>
1239. Hahn E, Barot S, O'Sullivan B, et al. Adult head and neck rhabdomyosarcoma: management, outcomes, and the effect of intensity modulated radiation therapy on locoregional control. *Adv Radiat Oncol.* 2022;7(6):101055. <https://doi.org/10.1016/j.adro.2022.101055>
1240. Ding J, Wang C, Xiang J, et al. Treatment outcomes and prognostic factors of adult sinonasal sarcomas: a single-institution case series. *Med Sci Monit.* 2018;24:6113-6118. <https://doi.org/10.12659/MSM.909116>
1241. Stepan K, Konuthula N, Khan M, et al. Outcomes in adult sinonasal rhabdomyosarcoma. *Otolaryngol Head Neck Surg.* 2017;157(1):135-141. <https://doi.org/10.1177/0194599817696287>
1242. Szablewski V, Neuville A, Terrier P, et al. Adult sinonasal soft tissue sarcoma: analysis of 48 cases from the French Sarcoma Group database. *Laryngoscope.* 2015;125(3):615-623. <https://doi.org/10.1002/lary.24910>
1243. Flamant F, Rodary C, Rey A, et al. Treatment of non-metastatic rhabdomyosarcomas in childhood and adolescence. Results of the second study of the Inter-

- national Society of Paediatric Oncology: MMT84. *Eur J Cancer*. 1998;34(7):1050-1062. [https://doi.org/10.1016/s0959-8049\(98\)00024-0](https://doi.org/10.1016/s0959-8049(98)00024-0)
1244. Stevens MCG, Rey A, Bouvet N, et al. Treatment of non-metastatic rhabdomyosarcoma in childhood and adolescence: third study of the International Society of Paediatric Oncology-SIOP Malignant Mesenchymal Tumor 89. *J Clin Oncol*. 2005;23(12):2618-2628. <https://doi.org/10.1200/JCO.2005.08.130>
1245. Dantonello TM, Stark M, Timmermann B, et al. Tumour volume reduction after neoadjuvant chemotherapy impacts outcome in localised embryonal rhabdomyosarcoma. *Pediatr Blood Cancer*. 2015;62(1):16-23. <https://doi.org/10.1002/pbc.25207>
1246. Koscielniak E, Blank B, Vokuhl C, et al. Long-term clinical outcome and prognostic factors of children and adolescents with localized rhabdomyosarcoma treated on the CWS-2002P protocol. *Cancers*. 2022;14(4):899. <https://doi.org/10.3390/cancers14040899>
1247. Koscielniak E, Harms D, Henze G, et al. Results of treatment for soft tissue sarcoma in childhood and adolescence: a final report of the German Cooperative Soft Tissue Sarcoma Study CWS-86. *J Clin Oncol*. 1999;17(12):3706-3719. <https://doi.org/10.1200/JCO.1999.17.12.3706>
1248. Koscielniak E, Jürgens H, Winkler K, et al. Treatment of soft tissue sarcoma in childhood and adolescence. A report of the German Cooperative Soft Tissue Sarcoma Study. *Cancer*. 1992;70(10):2557-2567. [https://doi.org/10.1002/1097-0142\(19921115\)70:10<2557::aid-cnrcr2820701027>3.0.co;2-8](https://doi.org/10.1002/1097-0142(19921115)70:10<2557::aid-cnrcr2820701027>3.0.co;2-8)
1249. Barthère X, Guillermin S, Quero L, et al. Adult paraneural alveolar rhabdomyosarcoma: case report and literature review. *Cancer Radiother*. 2020;24(8):870-875. <https://doi.org/10.1016/j.canrad.2020.03.015>
1250. Thompson LDR, Jo VY, Agaimy A, et al. Sinonasal tract alveolar rhabdomyosarcoma in adults: a clinicopathologic and immunophenotypic study of fifty-two cases with emphasis on epithelial immunoreactivity. *Head Neck Pathol*. 2018;12(2):181-192. <https://doi.org/10.1007/s12105-017-0851-9>
1251. Wagemans J, Beuselink B, Nuyts S, et al. A case series of embryonal rhabdomyosarcoma of the head and neck in adults. *Acta Clin Belg*. 2010;65(6):404-410. <https://doi.org/10.1179/acb.2010.65.6.006>
1252. Montone KT, Barr FG, Zhang PJ, Feldman MD, LiVolsi VA. Embryonal and alveolar rhabdomyosarcoma of paraneural sites in adults: a report of 13 cases. *Int J Surg Pathol*. 2009;17(1):22-30. <https://doi.org/10.1177/1066896908325876>
1253. Nakhleh RE, Swanson PE, Dehner LP. Juvenile (embryonal and alveolar) rhabdomyosarcoma of the head and neck in adults. A clinical, pathologic, and immunohistochemical study of 12 cases. *Cancer*. 1991;67(4):1019-1024. [https://doi.org/10.1002/1097-0142\(19910215\)67:4\(1019::aid-cnrcr2820670426\)3.0.co;2-7](https://doi.org/10.1002/1097-0142(19910215)67:4(1019::aid-cnrcr2820670426)3.0.co;2-7)
1254. Gadwal SR, Gannon FH, Fanburg-Smith JC, Becoskie EM, Thompson LD. Primary osteosarcoma of the head and neck in pediatric patients: a clinicopathologic study of 22 cases with a review of the literature. *Cancer*. 2001;91(3):598-605.
1255. Knott PD, Gannon FH, Thompson LDR. Mesenchymal chondrosarcoma of the sinonasal tract: a clinicopathological study of 13 cases with a review of the literature. *Laryngo-*
- scope*. 2003;113(5):783-790. <https://doi.org/10.1097/00005537-200305000-00004>
1256. Prado FO, Nishimoto IN, Perez DE da C, Kowalski LP, Lopes MA. Head and neck chondrosarcoma: analysis of 16 cases. *Br J Oral Maxillofac Surg*. 2009;47(7):555-557. <https://doi.org/10.1016/j.bjoms.2009.05.012>
1257. Vaz-Guimaraes F, Fernandez-Miranda JC, Koutourousiou M, et al. Endoscopic endonasal surgery for cranial base chondrosarcomas. *Oper Neurosurg*. 2017;13(4):421-434. <https://doi.org/10.1093/ons/oxp020>
1258. Simon F, Feuvret L, Bresson D, et al. Surgery and protontherapy in grade I and II skull base chondrosarcoma: a comparative retrospective study. *PLoS ONE*. 2018;13(12):e0208786. <https://doi.org/10.1371/journal.pone.0208786>
1259. Rimmer RA, Mace JC, Andersen PE, et al. Determinants of survival in sinonasal and skull base chondrosarcoma: an analysis of the National Cancer Database. *Int Forum Allergy Rhinol*. 2022;12(5):699-713. <https://doi.org/10.1002/alr.22909>
1260. Merna C, Lehigh BM, Kshirsagar RS, et al. Determinants of survival in skull base chondrosarcoma: a national cancer database study. *World Neurosurg*. 2022;158:e766-e777. <https://doi.org/10.1016/j.wneu.2021.11.066>
1261. de Souza LL, Pontes FSC, Fonseca FP, da Mata Rezende DS, Vasconcelos VCS, Pontes HAR. Chondrosarcoma of the jaw bones: a review of 224 cases reported to date and an analysis of prognostic factors. *Int J Oral Maxillofac Surg*. 2019;48(4):452-460. <https://doi.org/10.1016/j.ijom.2018.11.006>
1262. Steinbichler TB, Kral F, Reinold S, Riechelmann H. Chondrosarcoma of the nasal cavity in a patient with Maffucci syndrome: case report and review of the literature. *World J Surg Oncol*. 2014;12:387. <https://doi.org/10.1186/1477-7819-12-387>
1263. Xu B, Rooper LM, Dermawan JK, et al. Mesenchymal chondrosarcoma of the head and neck with HEY1::NCOA2 fusion: a clinicopathologic and molecular study of 13 cases with emphasis on diagnostic pitfalls. *Genes Chromosomes Cancer*. 2022;61(11):670-677. <https://doi.org/10.1002/gcc.23075>
1264. Khan MN, Husain Q, Kanumuri VV, et al. Management of sinonasal chondrosarcoma: a systematic review of 161 patients. *Int Forum Allergy Rhinol*. 2013;3(8):670-677. <https://doi.org/10.1002/alr.21162>
1265. Eide JG, Kshirsagar RS, Harris JC, et al. Multi-institutional review of sinonasal and skull base chondrosarcoma: 20-year experience. *Head Neck*. 2022;44(12):2686-2695. <https://doi.org/10.1002/hed.27178>
1266. Mardinger O, Givol N, Talmi YP, Taicher S. Osteosarcoma of the jaw. The Chaim Sheba Medical Center experience. *Oral Surg Oral Med Oral Pathol Oral Radiol Endod*. 2001;91(4):445-451. <https://doi.org/10.1067/moe.2001.112330>
1267. Patel SG, Meyers P, Huvos AG, et al. Improved outcomes in patients with osteogenic sarcoma of the head and neck. *Cancer*. 2002;95(7):1495-1503. <https://doi.org/10.1002/cncr.10849>
1268. Panda NK, Jain A, Eshwara Reddy CE. Osteosarcoma and chondrosarcoma of the maxilla. *Br J Oral Maxillofac Surg*. 2003;41(5):329-333. [https://doi.org/10.1016/s0266-4356\(03\)00133-5](https://doi.org/10.1016/s0266-4356(03)00133-5)
1269. Nakayama E, Sugiura K, Kobayashi I, Oobu K, Ishibashi H, Kanda S. The association between the computed tomography findings, histologic features, and outcome of osteosarcoma of

- the jaw. *J Oral Maxillofac Surg*. 2005;63(3):311-318. <https://doi.org/10.1016/j.joms.2004.04.033>
1270. Liu WW, Wu Q-l, Wu G-h, Chen Z-h, Zeng Z-y. Clinicopathologic features, treatment, and prognosis of postirradiation osteosarcoma in patients with nasopharyngeal cancer. *Laryngoscope*. 2005;115(9):1574-1579. <https://doi.org/10.1097/01.mlg.0000173166.48440.e4>
1271. Fernandes R, Nikitakis NG, Pazoki A, Ord RA. Osteogenic sarcoma of the jaw: a 10-year experience. *J Oral Maxillofac Surg*. 2007;65(7):1286-1291. <https://doi.org/10.1016/j.joms.2006.10.030>
1272. Jasnau S, Meyer U, Potratz J, et al. Craniofacial osteosarcoma experience of the cooperative German-Austrian-Swiss osteosarcoma study group. *Oral Oncol*. 2008;44(3):286-294. <https://doi.org/10.1016/j.oraloncology.2007.03.001>
1273. Laskar S, Basu A, Muckaden MA, et al. Osteosarcoma of the head and neck region: lessons learned from a single-institution experience of 50 patients. *Head Neck*. 2008;30(8):1020-1026. <https://doi.org/10.1002/hed.20820>
1274. Demicco EG, Deshpande V, Nielsen GP, Kattapuram SV, Rosenberg AE. Well-differentiated osteosarcoma of the jaw bones: a clinicopathologic study of 15 cases. *Am J Surg Pathol*. 2010;34(11):1647-1655. <https://doi.org/10.1097/PAS.0b013e3181f7dac6>
1275. Luna-Ortiz K, Villavicencio-Valencia V, Carmona-Luna T, Pasche P, Mosqueda-Taylor A. Osteogenic sarcoma of the maxillary region in a Mexican mestizo population. *J Craniofac Surg*. 2010;21(6):1709-1714. <https://doi.org/10.1097/SCS.0b013e3181f3c6d4>
1276. Boon E, van der Graaf WTA, Gelderblom H, et al. Impact of chemotherapy on the outcome of osteosarcoma of the head and neck in adults. *Head Neck*. 2017;39(1):140-146. <https://doi.org/10.1002/hed.24556>
1277. Liao LQ, Yan HH, Mai JH, et al. Radiation-induced osteosarcoma of the maxilla and mandible after radiotherapy for nasopharyngeal carcinoma. *Chin J Cancer*. 2016;35(1):89. <https://doi.org/10.1186/s40880-016-0153-8>
1278. ElKordy MA, ElBaradie TS, ElSebai HI, KhairAlla SM, Amin AAE. Osteosarcoma of the jaw: challenges in the diagnosis and treatment. *J Egypt Natl Canc Inst*. 2018;30(1):7-11. <https://doi.org/10.1016/j.jnci.2018.02.001>
1279. Krishnamurthy A, Palaniappan R. Osteosarcomas of the head and neck region: a case series with a review of literature. *J Maxillofac Oral Surg*. 2018;17(1):38-43. <https://doi.org/10.1007/s12663-017-1017-8>
1280. Bouaoud J, Beinse G, Epailard N, et al. Lack of efficacy of neoadjuvant chemotherapy in adult patients with maxillofacial high-grade osteosarcomas: a French experience in two reference centers. *Oral Oncol*. 2019;95:79-86. <https://doi.org/10.1016/j.oraloncology.2019.06.011>
1281. Kontio R, Hagström J, Lindholm P, et al. Craniomaxillofacial osteosarcoma - the role of surgical margins. *J Craniomaxillofac Surg*. 2019;47(6):922-925. <https://doi.org/10.1016/j.jcms.2019.03.020>
1282. Low CM, Gruszczynski NR, Moore EJ, et al. Sinonasal osteosarcoma: report of 14 new cases and systematic review of the literature. *J Neurol Surg B Skull Base*. 2021;82(Suppl. 3):e138-e147. <https://doi.org/10.1055/s-0040-1701221>
1283. Guadagnolo BA, Zagars GK, Raymond AK, Benjamin RS, Sturgis EM. Osteosarcoma of the jaw/craniofacial region: outcomes after multimodality treatment. *Cancer*. 2009;115(14):3262-3270. <https://doi.org/10.1002/cncr.24297>
1284. Merna C, Lehrich BM, Diaz-Aguilar LD, et al. Determinants of survival in skull base osteosarcoma: a national cancer database study. *World Neurosurg*. 2021;151:e828-e838. <https://doi.org/10.1016/j.wneu.2021.04.135>
1285. van den Berg H, Schreuder WH, de Lange J. Osteosarcoma: a comparison of jaw versus nonjaw localizations and review of the literature. *Sarcoma*. 2013;2013:316123. <https://doi.org/10.1155/2013/316123>
1286. van den Berg H, Merks JHM. Incidence and grading of craniofacial osteosarcomas. *Int J Oral Maxillofac Surg*. 2014;43(1):7-12. <https://doi.org/10.1016/j.ijom.2013.06.017>
1287. Rodjan F, de Graaf P, Brisse HJ, et al. Second craniofacial malignancies in hereditary retinoblastoma survivors previously treated with radiation therapy: clinic and radiologic characteristics and survival outcomes. *Eur J Cancer*. 2013;49(8):1939-1947. <https://doi.org/10.1016/j.ejca.2013.01.010>
1288. Taran SJ, Taran R, Malipatil NB. Pediatric osteosarcoma: an updated review. *Indian J Med Paediatr Oncol*. 2017;38(1):33-43. <https://doi.org/10.4103/0971-5851.203513>
1289. Liang L, Zhang T, You Y, He Q, Fan Y, Liao G. An individual patient data meta-analysis on the effect of chemotherapy on survival in patients with craniofacial osteosarcoma. *Head Neck*. 2019;41(6):2016-2023. <https://doi.org/10.1002/hed.25668>
1290. Ciernik IF, Niemierko A, Harmon DC, et al. Proton-based radiotherapy for unresectable or incompletely resected osteosarcoma. *Cancer*. 2011;117(19):4522-4530. <https://doi.org/10.1002/cncr.26037>
1291. Thiele OC, Freier K, Bacon C, Egerer G, Hofele CM. Interdisciplinary combined treatment of craniofacial osteosarcoma with neoadjuvant and adjuvant chemotherapy and excision of the tumour: a retrospective study. *Br J Oral Maxillofac Surg*. 2008;46(7):533-536. <https://doi.org/10.1016/j.bjoms.2008.03.010>
1292. Schreiber A, Rampinelli V, Ferrari M, et al. Diagnostic reliability of pretreatment biopsy in malignant nasoethmoidal tumors: a retrospective study of 77 cases. *Laryngoscope*. 2018;128(8):1772-1777. <https://doi.org/10.1002/lary.27077>
1293. Koka V, Vericel R, Lartigau E, Lusinchi A, Schwaab G. Sarcomas of nasal cavity and paranasal sinuses: chondrosarcoma, osteosarcoma and fibrosarcoma. *J Laryngol Otol*. 1994;108(11):947-953. <https://doi.org/10.1017/s0022215100128609>
1294. Bentz BG, Singh B, Woodruff J, Brennan M, Shah JP, Kraus D. Head and neck soft tissue sarcomas: a multivariate analysis of outcomes. *Ann Surg Oncol*. 2004;11(6):619-628. <https://doi.org/10.1245/ASO.2004.03.006>
1295. O'Sullivan B, Huang SH, Hahn E, et al. High local control following pre-operative radiotherapy for adult deep soft tissue sarcoma of the head and neck. *Int J Radiat Oncol Biol Phys*. 2021;111(3):S41-S42. <https://doi.org/10.1016/j.ijrobp.2021.07.117>
1296. Martin E, Radomski S, Harley E. Sarcomas of the paranasal sinuses: an analysis of the SEER database: sarcomas of the Paranasal Sinuses. *Laryngoscope Investig Otolaryngol*. 2019;4(1):70-75. <https://doi.org/10.1002/lio2.245>

1297. De Bree R, Van Der Valk P, Kuik DJ, et al. Prognostic factors in adult soft tissue sarcomas of the head and neck: a single-centre experience. *Oral Oncol.* 2006;42(7):703-709. <https://doi.org/10.1016/j.oraloncology.2005.11.009>
1298. Wanebo HJ, Kones R, MacFarlane JK, et al. Head and neck sarcoma: report of the head and neck sarcoma registry. society of head and neck surgeons committee on research. *Head Neck.* 1992;14(1):1-7. <https://doi.org/10.1002/hed.2880140102>
1299. Penel N, Van Haverbeke C, Lartigau E, et al. Head and neck soft tissue sarcomas of adult: prognostic value of surgery in multimodal therapeutic approach. *Oral Oncol.* 2004;40(9):890-897. <https://doi.org/10.1016/j.oraloncology.2004.04.001>
1300. Heffner DK, Gnepp DR. Sinonasal fibrosarcomas, malignant schwannomas, and "Triton" tumors. A clinicopathologic study of 67 cases. *Cancer.* 1992;70(5):1089-1101. [https://doi.org/10.1002/1097-0142\(19920901\)70:5\(1089::aid-cncr2820700513\)3.0.co;2-j](https://doi.org/10.1002/1097-0142(19920901)70:5(1089::aid-cncr2820700513)3.0.co;2-j)
1301. Lewis JT, Oliveira AM, Nascimento AG, et al. Low-grade sinonasal sarcoma with neural and myogenic features: a clinicopathologic analysis of 28 cases. *Am J Surg Pathol.* 2012;36(4):517-525. <https://doi.org/10.1097/PAS.0b013e3182426886>
1302. Le Loarer F, Laffont S, Lesluyes T, et al. Clinicopathologic and molecular features of a series of 41 biphenotypic sinonasal sarcomas expanding their molecular spectrum. *Am J Surg Pathol.* 2019;43(6):747-754. <https://doi.org/10.1097/PAS.0000000000001238>
1303. Chitguppi C, Koszewski I, Collura K, et al. Biphenotypic sinonasal sarcoma-case report and review of clinicopathological features and diagnostic modalities. *J Neurol Surg B Skull Base.* 2019;80(1):51-58. <https://doi.org/10.1055/s-0038-1667146>
1304. Miglani A, Lal D, Weindling SM, Wood CP, Hoxworth JM. Imaging characteristics and clinical outcomes of biphenotypic sinonasal sarcoma. *Laryngoscope Investig Otolaryngol.* 2019;4(5):484-488. <https://doi.org/10.1002/lio2.305>
1305. Fritchie KJ, Jin L, Wang X, et al. Fusion gene profile of biphenotypic sinonasal sarcoma: an analysis of 44 cases. *Histopathology.* 2016;69(6):930-936. <https://doi.org/10.1111/his.13045>
1306. Wang X, Bledsoe KL, Graham RP, et al. Recurrent PAX3-MAML3 fusion in biphenotypic sinonasal sarcoma. *Nat Genet.* 2014;46(7):666-668. <https://doi.org/10.1038/ng.2989>
1307. Huang SC, Ghossein RA, Bishop JA, et al. Novel PAX3-NCOA1 fusions in biphenotypic sinonasal sarcoma with focal rhabdomyoblastic differentiation. *Am J Surg Pathol.* 2016;40(1):51-59. <https://doi.org/10.1097/PAS.0000000000000492>
1308. Rooper LM, Huang SC, Antonescu CR, Westra WH, Bishop JA. Biphenotypic sinonasal sarcoma: an expanded immunoprofile including consistent nuclear β -catenin positivity and absence of SOX10 expression. *Hum Pathol.* 2016;55:44-50. <https://doi.org/10.1016/j.humpath.2016.04.009>
1309. Andreasen S, Bishop JA, Hellquist H, et al. Biphenotypic sinonasal sarcoma: demographics, clinicopathological characteristics, molecular features, and prognosis of a recently described entity. *Virchows Arch.* 2018;473(5):615-626. <https://doi.org/10.1007/s00428-018-2426-x>
1310. Sethi S, Cody B, Farhat NA, Pool MD, Katabi N. Biphenotypic sinonasal sarcoma: report of 3 cases with a review of literature. *Hum Pathol.* 2021;24:200491. <https://doi.org/10.1016/j.ehpc.2021.200491>
1311. Kominsky E, Boyke AE, Madani D, Kamat A, Schiff BA, Agarwal V. Biphenotypic sinonasal sarcoma: a case report and review of literature. *Ear Nose Throat J.* 2023;102(6):385-390. <https://doi.org/10.1177/0145561321999196>
1312. Ulrich CT, Feiz-Erfan I, Spetzler RF, et al. Sinonasal leiomyosarcoma: review of literature and case report. *Laryngoscope.* 2005;115(12):2242-2248. <https://doi.org/10.1097/01.mlg.0000183767.97518.09>
1313. Agaimy A, Semrau S, Koch M, Thompson LDR. Sinonasal leiomyosarcoma: clinicopathological analysis of nine cases with emphasis on common association with other malignancies and late distant metastasis. *Head Neck Pathol.* 2018;12(4):463-470. <https://doi.org/10.1007/s12105-017-0876-0>
1314. Kuruvilla A, Wenig BM, Humphrey DM, Heffner DK. Leiomyosarcoma of the sinonasal tract. A clinicopathologic study of nine cases. *Arch Otolaryngol Head Neck Surg.* 1990;116(11):1278-1286. <https://doi.org/10.1001/archotol.1990.01870110050005>
1315. Eppsteiner RW. Leiomyosarcoma of the head and neck: a population-based analysis. *Arch Otolaryngol Head Neck Surg.* 2011;137(9):921-924. <https://doi.org/10.1001/archoto.2011.147>
1316. Nelson BL, Thompson LDR. Sinonasal tract angiosarcoma: a clinicopathologic and immunophenotypic study of 10 cases with a review of the literature. *Head Neck Pathol.* 2007;1(1):1-12. <https://doi.org/10.1007/s12105-007-0017-2>
1317. Hafezi S, Seethala RR, Stelow EB, et al. Ewing's family of tumors of the sinonasal tract and maxillary bone. *Head Neck Pathol.* 2011;5(1):8-16. <https://doi.org/10.1007/s12105-010-0227-x>
1318. Rooper LM, Bishop JA. Soft tissue special issue: adamantinoma-like Ewing sarcoma of the head and neck: a practical review of a challenging emerging entity. *Head Neck Pathol.* 2020;14(1):59-69. <https://doi.org/10.1007/s12105-019-01098-y>
1319. La TH, Meyers PA, Wexler LH, et al. Radiation therapy for Ewing's sarcoma: results from Memorial Sloan-Kettering in the modern era. *Int J Radiat Oncol Biol Phys.* 2006;64(2):544-550. <https://doi.org/10.1016/j.ijrobp.2005.07.299>
1320. Palmer JD, Gamez ME, Ranta K, et al. Radiation therapy strategies for skull-base malignancies. *J Neurooncol.* 2020;150(3):445-462. <https://doi.org/10.1007/s11060-020-03569-7>
1321. Lepera D, Volpi L, Facco C, et al. Endoscopic treatment of Ewing sarcoma of the sinonasal tract. *J Craniofac Surg.* 2016;27(4):1001-1006. <https://doi.org/10.1097/SCS.0000000000002701>
1322. Raney RB, Asmar L, Newton WA, et al. Ewing's sarcoma of soft tissues in childhood: a report from the Intergroup Rhabdomyosarcoma Study, 1972 to 1991. *J Clin Oncol.* 1997;15(2):574-582. <https://doi.org/10.1200/JCO.1997.15.2.574>
1323. Lombardi D, Mattavelli D, Redaelli De Zinis LO, et al. Primary Ewing's sarcoma of the sinonasal tract in adults: a challenging disease. *Head Neck.* 2017;39(3):E45-E50. <https://doi.org/10.1002/hed.24649>
1324. Harb WJ, Luna MA, Patel SR, Ballo MT, Roberts DB, Sturgis EM. Survival in patients with synovial sarcoma of the head and neck: association with tumor location, size, and exten-

- sion. *Head Neck*. 2007;29(8):731-740. <https://doi.org/10.1002/hed.20564>
1325. Lin N, Liu X, Zhang F, Pan Y, Qi M, Sha Y. Sinonasal synovial sarcoma: evaluation of the role of radiological and clinicopathological features in diagnosis. *Clin Radiol*. 2021;76(1):78.e1-78.e8. <https://doi.org/10.1016/j.crad.2020.08.007>
 1326. Saito S, Ozawa H, Ikari Y, et al. Synovial sarcoma of the maxillary sinus: an extremely rare case with excellent response to chemotherapy. *Onco Targets Ther*. 2018;11:483-488. <https://doi.org/10.2147/OTT.S151473>
 1327. Baranov E, McBride MJ, Bellizzi AM, et al. A novel SS18-SSX fusion-specific antibody for the diagnosis of synovial sarcoma. *Am J Surg Pathol*. 2020;44(7):922-933. <https://doi.org/10.1097/PAS.0000000000001447>
 1328. Gil Z, Orr-Urtreger A, Voskoboinik N, Trejo-Leider L, Shomrat R, Fliss DM. Cytogenetic analysis of 101 skull base tumors. *Head Neck*. 2008;30(5):567-581. <https://doi.org/10.1002/hed.20741>
 1329. Terzic A, Bode B, Gratz KW, Stoeckli SJ. Prognostic factors for the malignant triton tumor of the head and neck. *Head Neck*. 2009;31(5):679-688. <https://doi.org/10.1002/hed.21051>
 1330. Vengaloor Thomas T, Abraham A, Bhanat E, et al. Malignant peripheral nerve sheath tumor of nasal cavity and paranasal sinus with 13 years of follow-up—a case report and review of literature. *Clin Case Rep*. 2019;7(11):2194-2201. <https://doi.org/10.1002/ccr3.2465>
 1331. Nicolai P, Tomenzoli D, Berlucchi M, Facchetti F, Morassi L, Maroldi R. Malignant triton tumor of the ethmoid sinus and nasal cavity. *Ann Otol Rhinol Laryngol*. 2000;109(9):880-886. <https://doi.org/10.1177/000348940010900918>
 1332. Kaur RP, Izumchenko E, Blakaj DM, et al. The genomics and epigenetics of olfactory neuroblastoma: a systematic review. *Laryngoscope Invest Otolaryngol*. 2021;6(4):721-728. <https://doi.org/10.1002/lio2.597>
 1333. Su SY, Bell D, Hanna EY. Esthesioneuroblastoma, neuroendocrine carcinoma, and sinonasal undifferentiated carcinoma: differentiation in diagnosis and treatment. *Int Arch Otorhinolaryngol*. 2014;18(Suppl. 2):S149-S156. <https://doi.org/10.1055/s-0034-1390014>
 1334. Shah K, Perez-Ordóñez B. Neuroendocrine neoplasms of the sinonasal tract: neuroendocrine carcinomas and olfactory neuroblastoma. *Head and Neck Pathol*. 2016;10(1):85-94. <https://doi.org/10.1007/s12105-016-0696-7>
 1335. Berger MH, Leirich BM, Yasaka TM, Fong BM, Hsu FPK, Kuan EC. Characteristics and overall survival in pediatric versus adult esthesioneuroblastoma: a population-based study. *Int J Pediatr Otorhinolaryngol*. 2021;144:110696. <https://doi.org/10.1016/j.ijporl.2021.110696>
 1336. Saade RE, Hanna EY, Bell D. Prognosis and biology in esthesioneuroblastoma: the emerging role of Hyams grading system. *Curr Oncol Rep*. 2015;17(1):423. <https://doi.org/10.1007/s11912-014-0423-z>
 1337. Bell D, Saade R, Roberts D, et al. Prognostic utility of Hyams histological grading and Kadish-Morita staging systems for esthesioneuroblastoma outcomes. *Head and Neck Pathol*. 2015;9(1):51-59. <https://doi.org/10.1007/s12105-014-0547-3>
 1338. Hyams VJ, Batsakis JG, Michaels L. Tumors of the upper respiratory tract and ear. In: Hyams VJ, Batsakis JG, Michaels L, eds. *Atlas of Tumor Pathology*. 2nd series, Fascicle 25. Armed Forces Institute of Pathology; 1988:240-248.
 1339. Hyams VJ. Olfactory neuroblastoma (case 6). In: Batsakis JG, Hyams VJ, Morales AR, eds. *Special Tumors of the Head and Neck*. American Society of Clinical Pathologists; 1983:24-29.
 1340. Van Gompel J, Giannini C, Olsen K, et al. Long-term outcome of esthesioneuroblastoma: Hyams grade predicts patient survival. *J Neurol Surg B*. 2012;73(05):331-336. <https://doi.org/10.1055/s-0032-1321512>
 1341. Malouf GG, Casiraghi O, Deutsch E, Guigay J, Temam S, Bourhis J. Low- and high-grade esthesioneuroblastomas display a distinct natural history and outcome. *Eur J Cancer*. 2013;49(6):1324-1334. <https://doi.org/10.1016/j.ejca.2012.12.008>
 1342. Goshtasbi K, Abiri A, Abouzari M, et al. Hyams grading as a predictor of metastasis and overall survival in esthesioneuroblastoma: a meta-analysis. *Int Forum Allergy Rhinol*. 2019;9(9):1054-1062. <https://doi.org/10.1002/alr.22373>
 1343. Kane AJ, Sughrue ME, Rutkowski MJ, et al. Posttreatment prognosis of patients with esthesioneuroblastoma: clinical article. *J Neurosurg*. 2010;113(2):340-351. <https://doi.org/10.3171/2010.2.JNS091897>
 1344. Kadish S, Goodman M, Wang CC. Olfactory neuroblastoma—a clinical analysis of 17 cases. *Cancer*. 1976;37(3):1571-1576. [https://doi.org/10.1002/1097-0142\(197603\)37:3<1571::AID-CNCR2820370347>3.0.CO;2-L](https://doi.org/10.1002/1097-0142(197603)37:3<1571::AID-CNCR2820370347>3.0.CO;2-L)
 1345. Ziai H, Yu E, Weinreb I, et al. Regional recurrences and Hyams grade in esthesioneuroblastoma. *J Neurol Surg B Skull Base*. 2021;82(06):608-614. <https://doi.org/10.1055/s-0040-1715809>
 1346. Wolfe AR, Blakaj D, London N, et al. Clinical outcomes and multidisciplinary patterns of failure for olfactory neuroblastoma: the Ohio state experience. *J Neurol Surg B Skull Base*. 2020;81(03):287-294. <https://doi.org/10.1055/s-0039-1692479>
 1347. Singh S, Singh L, Ranjan R, Singh MK, Thakar A, Sharma SC. Correlating the treatment outcome with tumor staging, grading, and various treatment modalities in patients with esthesioneuroblastoma. *South Asian J Cancer*. 2019;08(02):124-126. https://doi.org/10.4103/sajc.sajc_273_18
 1348. Marinelli J, Janus J, Van Gompel J, et al. Dural invasion predicts the laterality and development of neck metastases in esthesioneuroblastoma. *J Neurol Surg B*. 2018;79(05):495-500. <https://doi.org/10.1055/s-0038-1625977>
 1349. Turri-Zanoni M, Maragliano R, Battaglia P, et al. The clinicopathological spectrum of olfactory neuroblastoma and sinonasal neuroendocrine neoplasms: refinements in diagnostic criteria and impact of multimodal treatments on survival. *Oral Oncol*. 2017;74:21-29. <https://doi.org/10.1016/j.oraloncology.2017.09.010>
 1350. Safi C, Spielman D, Otten M, et al. Treatment strategies and outcomes of pediatric esthesioneuroblastoma: a systematic review. *Front Oncol*. 2020;10:1247. <https://doi.org/10.3389/fonc.2020.01247>
 1351. McMillan RA, Van Gompel JJ, Link MJ, et al. Long-term oncologic outcomes in esthesioneuroblastoma: an institutional experience of 143 patients. *Int Forum Allergy Rhinol*. 2022;12(12):1457-1467. <https://doi.org/10.1002/alr.23007>
 1352. Klironomos G, Gonen L, Au K, et al. Endoscopic management of Esthesioneuroblastoma: our experience and review of the literature. *J Clin Neurosci*. 2018;58:117-123. <https://doi.org/10.1016/j.jocn.2018.09.011>

1353. De Virgilio A, Costantino A, Sebastiani D, et al. Elective neck irradiation in the management of esthesioneuroblastoma: a systematic review and meta-analysis. *Rhinology*. 2021;59(5):433-440. <https://doi.org/10.4193/Rhin21.139>
1354. Kuan EC, Nasser HB, Carey RM, et al. A population-based analysis of nodal metastases in esthesioneuroblastomas of the sinonasal tract. *Laryngoscope*. 2019;129(5):1025-1029. <https://doi.org/10.1002/lary.27301>
1355. Wu K, Avila SA, Bhuyan R, et al. Orbital invasion by Esthesioneuroblastoma: a comparative case series and review of literature. *Orbit*. 2022;41(1):1-14. <https://doi.org/10.1080/01676830.2020.1852262>
1356. Herr MW, Gray ST, Erman AB, Curry WT, Deschler DG, Lin DT. Orbital preservation in patients with esthesioneuroblastoma. *J Neurol Surg B Skull Base*. 2013;74(3):142-145. <https://doi.org/10.1055/s-0033-1338259>
1357. Su SY, Bell D, Ferrarotto R, et al. Outcomes for olfactory neuroblastoma treated with induction chemotherapy. *Head Neck*. 2017;39(8):1671-1679. <https://doi.org/10.1002/hed.24822>
1358. Miller KC, Marinelli JP, Janus JR, et al. Induction therapy prior to surgical resection for patients presenting with locally advanced esthesioneuroblastoma. *J Neurol Surg B Skull Base*. 2021;82(Suppl. 3):e131-e137. <https://doi.org/10.1055/s-0039-3402026>
1359. Pence TS, Reiter ER, DiNardo LJ, Costanzo RM. Risk factors for hazardous events in olfactory-impaired patients. *JAMA Otolaryngol Head Neck Surg*. 2014;140(10):951-955. <https://doi.org/10.1001/jamaoto.2014.1675>
1360. Nakagawa T, Kodama S, Kobayashi M, et al. Endoscopic endonasal management of esthesioneuroblastoma: a retrospective multicenter study. *Auris Nasus Larynx*. 2018;45(2):281-285. <https://doi.org/10.1016/j.anl.2017.05.001>
1361. Tajudeen BA, Adappa ND, Kuan EC, et al. Smell preservation following endoscopic unilateral resection of esthesioneuroblastoma: a multi-institutional experience. *Int Forum Allergy Rhinol*. 2016;6(10):1047-1050. <https://doi.org/10.1002/alr.21794>
1362. Gompel JJV, Janus JR, Hughes JD, et al. Esthesioneuroblastoma and olfactory preservation: is it reasonable to attempt smell preservation? *J Neurol Surg B Skull Base*. 2018;79(2):184-188. <https://doi.org/10.1055/s-0037-1606307>
1363. Gomez Galarce M, Yanez-Siller JC, Carrau RL, et al. Endonasal anatomy of the olfactory neural network: surgical implications. *Laryngoscope*. 2018;128(11):2473-2477. <https://doi.org/10.1002/lary.27194>
1364. Duo GS, Feng JL, Zhang ZY, Wang LJ. Survival impact of postoperative radiotherapy in patients with olfactory neuroblastoma: 513 cases from the SEER database. *Cancer/Radiothérapie*. 2022;26(5):663-669. <https://doi.org/10.1016/j.canrad.2021.12.006>
1365. Orton A, Boothe D, Evans D, et al. Esthesioneuroblastoma: a patterns-of-care and outcomes analysis of the national cancer database. *Neurosurgery*. 2018;83(5):940-947. <https://doi.org/10.1093/neuros/nyx535>
1366. Xiong L, Zeng XL, Guo CK, Liu AW, Huang L. Optimal treatment and prognostic factors for esthesioneuroblastoma: retrospective analysis of 187 Chinese patients. *BMC Cancer*. 2017;17(1):254. <https://doi.org/10.1186/s12885-017-3247-z>
1367. Fiani B, Quadri SA, Cathel A, et al. Esthesioneuroblastoma: a comprehensive review of diagnosis, management, and current treatment options. *World Neurosurg*. 2019;126:194-211. <https://doi.org/10.1016/j.wneu.2019.03.014>
1368. Yuan Y, Ye J, Qiu H, et al. Exploration of the optimal treatment regimes for Esthesioneuroblastoma: a single center experience in China. *J Cancer*. 2018;9(1):174-181. <https://doi.org/10.7150/jca.21605>
1369. Tsutsumi K, Ahmed KH, Goshtasbi K, et al. Impact of esthesioneuroblastoma treatment delays on overall patient survival. *Laryngoscope*. 2023;133(4):764-772. <https://doi.org/10.1002/lary.30136>
1370. Kiyofuji S, Agarwal V, Hughes JD, et al. Delaying postoperative radiotherapy in low-grade esthesioneuroblastoma: is it worth the wait? *J Neurol Surg B Skull Base*. 2021;82(Suppl. 3):e166-e171. <https://doi.org/10.1055/s-0040-1708854>
1371. Cranmer LD, Chau B, Rockhill JK, Ferreira M, Liao JJ. Chemotherapy in esthesioneuroblastoma/olfactory neuroblastoma: an analysis of the surveillance epidemiology and end results (SEER) 1973-2015 database. *Am J Clin Oncol*. 2020;43(3):203-209. <https://doi.org/10.1097/COC.0000000000000649>
1372. Brisson RJ, Quinn TJ, Deraniyagala RL. The role of chemotherapy in the management of olfactory neuroblastoma: a 40-year surveillance, epidemiology, and end results registry study. *Health Sci Rep*. 2021;4(2):e257. <https://doi.org/10.1002/hsr2.257>
1373. Venkatramani R, Pan H, Furman WL, et al. Multimodality treatment of pediatric esthesioneuroblastoma. *Pediatr Blood Cancer*. 2016;63(3):465-470. <https://doi.org/10.1002/pbc.25817>
1374. Romani C, Bignotti E, Mattavelli D, et al. Gene expression profiling of olfactory neuroblastoma helps identify prognostic pathways and define potentially therapeutic targets. *Cancers*. 2021;13(11):2527. <https://doi.org/10.3390/cancers13112527>
1375. Cracolici V, Wang EW, Gardner PA, et al. SSTR2 expression in olfactory neuroblastoma: clinical and therapeutic implications. *Head Neck Pathol*. 2021;15(4):1185-1191. <https://doi.org/10.1007/s12105-021-01329-1>
1376. Meerwein CM, Nikolaou G, Binz GHA, Soyka MB, Holzmann D. Surgery as single-modality treatment for early-stage olfactory neuroblastoma: an institutional experience, systematic review and meta-analysis. *Am J Rhinol Allergy*. 2021;35(4):525-534. <https://doi.org/10.1177/1945892420973163>
1377. Vuong HG, Ngo TNM, Dunn IF. Consolidating the Hyams grading system in esthesioneuroblastoma – an individual participant data meta-analysis. *J Neurooncol*. 2021;153(1):15-22. <https://doi.org/10.1007/s11060-021-03746-2>
1378. Woods R, Subramaniam T, Leader M, McConn-Walsh R, O'Neill J, Lacy P. Changing trends in the management of esthesioneuroblastoma: Irish and international perspectives. *J Neurol Surg B*. 2018;79(03):262-268. <https://doi.org/10.1055/s-0037-1607298>
1379. Arnold MA, Farnoosh S, Gore MR. Comparing Kadish and modified Dulguerov staging systems for olfactory neuroblastoma: an individual participant data meta-analysis. *Otolaryngol Head Neck Surg*. 2020;163(3):418-427. <https://doi.org/10.1177/0194599820915487>
1380. Liu L, Zhong Q, Zhao T, Chen D, Xu Y, Li G. Model to predict cause-specific mortality in patients with olfactory neuroblastoma: a competing risk analysis. *Radiat Oncol*. 2021;16(1):103. <https://doi.org/10.1186/s13014-021-01784-8>

1381. Sun M, Wang K, Qu Y, et al. Proposal of a TNM classification-based staging system for esthesioneuroblastoma: more precise prediction of prognosis. *Head Neck*. 2021;43(4):1097-1104. <https://doi.org/10.1002/hed.26559>
1382. Yang J, Song X, Lai Y, et al. Development and validation of a postoperative nomogram for predicting overall survival after endoscopic surgical management of olfactory neuroblastoma. *eClinicalMedicine*. 2020;29-30:100577. <https://doi.org/10.1016/j.eclinm.2020.100577>
1383. Carey RM, Godovchik J, Workman AD, et al. Patient, disease, and treatment factors associated with overall survival in esthesioneuroblastoma: factors associated with ENB survival. *Int Forum Allergy Rhinol*. 2017;7(12):1186-1194. <https://doi.org/10.1002/alr.22027>
1384. Konuthula N, Illoreta AM, Miles B, et al. Prognostic significance of Kadish staging in esthesioneuroblastoma: an analysis of the National Cancer Database. *Head Neck*. 2017;39(10):1962-1968. <https://doi.org/10.1002/hed.24770>
1385. Song X, Wang J, Wang S, Yan L, Li Y. Prognostic factors and outcomes of multimodality treatment in olfactory neuroblastoma. *Oral Oncol*. 2020;103:104618. <https://doi.org/10.1016/j.oraloncology.2020.104618>
1386. Marinelli JP, Janus JR, Van Gompel JJ, et al. Esthesioneuroblastoma with distant metastases: systematic review & meta-analysis. *Head Neck*. 2018;40(10):2295-2303. <https://doi.org/10.1002/hed.25209>
1387. Vuong HG, Nguyen DD, El-Rassi E, Ngo TNM, Dunn IF. Absence of survival improvement for patients with esthesioneuroblastoma over the past 2 decades: a population-based study. *World Neurosurg*. 2022;157:e245-e253. <https://doi.org/10.1016/j.wneu.2021.09.139>
1388. Wang J, Wang L, He H, Li Y, Song X. The treatment outcomes of olfactory neuroblastoma patients with frontal lobe invasion. *Front Oncol*. 2021;11:640892. <https://doi.org/10.3389/fonc.2021.640892>
1389. Miller KC, Marinelli JP, Van Gompel JJ, et al. Utility of adjuvant chemotherapy in patients receiving surgery and adjuvant radiotherapy for primary treatment of esthesioneuroblastoma. *Head Neck*. 2019;41(5):1335-1341. <https://doi.org/10.1002/hed.25558>
1390. Frierson HF, Mills SE, Fechner RE, Taxy JB, Levine PA. Sinonasal undifferentiated carcinoma. An aggressive neoplasm derived from Schneiderian epithelium and distinct from olfactory neuroblastoma. *Am J Surg Pathol*. 1986;10(11):771-779.
1391. Agaimy A, Franchi A, Lund VJ, et al. Sinonasal undifferentiated carcinoma (SNUC): from an entity to morphologic pattern and back again—a historical perspective. *Adv Anat Pathol*. 2020;27(2):51-60. <https://doi.org/10.1097/PAP.0000000000000258>
1392. Libera L, Ottini G, Sahnane N, et al. Methylation drivers and prognostic implications in sinonasal poorly differentiated carcinomas. *Cancers*. 2021;13(19):5030. <https://doi.org/10.3390/cancers13195030>
1393. Vaziri Fard E, Zhang S, Cai Z, et al. Sinonasal undifferentiated carcinoma: clinicopathological spectrums and diagnosis reappraisal. *Hum Pathol*. 2019;89:62-70. <https://doi.org/10.1016/j.humpath.2019.04.008>
1394. Morand GB, Anderegg N, Vital D, et al. Outcome by treatment modality in sinonasal undifferentiated carcinoma (SNUC): a case-series, systematic review and meta-analysis. *Oral Oncol*. 2017;75:28-34. <https://doi.org/10.1016/j.oraloncology.2017.10.008>
1395. Workman AD, Brody RM, Kuan EC, et al. Sinonasal undifferentiated carcinoma: a 15-year single institution experience. *J Neurol Surg Part B*. 2019;80(1):88-95. <https://doi.org/10.1055/s-0038-1668537>
1396. Rodriguez CP, Liao JJ, Liu AW, et al. Patterns of recurrence in patients with sinonasal undifferentiated carcinoma (SNUC) treated with multimodality therapy at a single center. *J Clin Oncol Conf*. 2017;35(15_suppl):e17575.
1397. Lopez F, Suarez V, Vivanco B, Suarez C, Llorente JL. Current management of sinonasal undifferentiated carcinoma. *Rhinology*. 2015;53(3):212-220. <https://doi.org/10.4193/Rhin14.054>
1398. Jo VY, Chau NG, Hornick JL, Krane JF, Sholl LM. Recurrent IDH2 R172X mutations define sinonasal undifferentiated carcinoma. *Mod Pathol*. 2017;30(5):650-659. <https://doi.org/10.1038/modpathol.2016.239>
1399. Dogan S, Chute DJ, Xu B, et al. Frequent IDH2 R172 mutations in undifferentiated and poorly-differentiated sinonasal carcinomas. *J Pathol*. 2017;242(4):400-408. <https://doi.org/10.1002/path.4915>
1400. Dogan S, Frosina D, Geronimo JA, et al. Molecular epidemiology of IDH2 hotspot mutations in cancer and immunohistochemical detection of R172K, R172G, and R172M variants. *Hum Pathol*. 2020;106:45-53. <https://doi.org/10.1016/j.humpath.2020.09.013>
1401. Elkhatib AH, Soldatova L, Carrau RL, et al. Role of F-18-FDG PET/CT differentiating olfactory neuroblastoma from sinonasal undifferentiated carcinoma. *Laryngoscope*. 2017;127(2):321-324. <https://doi.org/10.1002/lary.26194>
1402. Kuo P, Manes RP, Schwam ZG, Judson BL. Survival outcomes for combined modality therapy for sinonasal undifferentiated carcinoma. *Otolaryngol Head Neck Surg*. 2017;156(1):132-136. <https://doi.org/10.1177/0194599816670146>
1403. Amit M, Abdelmeguid AS, Watcherporn T, et al. Induction chemotherapy response as a guide for treatment optimization in sinonasal undifferentiated carcinoma. *J Clin Oncol*. 2019;37(6):504-512. <https://doi.org/10.1200/JCO.18.00353>
1404. van der Laan TP, Iepsma R, Witjes MJ, van der Laan BF, Plaat BE, Halmos GB. Meta-analysis of 701 published cases of sinonasal neuroendocrine carcinoma: the importance of differentiation grade in determining treatment strategy. *Oral Oncol*. 2016;63:1-9. <https://doi.org/10.1016/j.oraloncology.2016.10.002>
1405. Chambers KJ, Lehmann AE, Remenschneider A, et al. Incidence and survival patterns of sinonasal undifferentiated carcinoma in the United States. *J Neurol Surg B Skull Base*. 2015;76(2):94-100. <https://doi.org/10.1055/s-0034-1390016>
1406. Chen AM, Daly ME, El-Sayed I, et al. Patterns of failure after combined-modality approaches incorporating radiotherapy for sinonasal undifferentiated carcinoma of the head and neck. *Int J Radiat Oncol Biol Phys*. 2008;70(2):338-343. <https://doi.org/10.1016/j.ijrobp.2007.06.057>

1407. Kuan EC, Arshi A, Mallen-St Clair J, Tajudeen BA, Abemayor E, St John MA. Significance of tumor stage in sinonasal undifferentiated carcinoma survival: a population-based analysis. *Otolaryngol Head Neck Surg*. 2016;154(4):667-673. <https://doi.org/10.1177/0194599816629649>
1408. Heft Neal ME, Birkeland AC, Bhangale AD, et al. Genetic analysis of sinonasal undifferentiated carcinoma discovers recurrent SWI/SNF alterations and a novel PGAP3-SRPK1 fusion gene. *BMC Cancer*. 2021;21(1):636. <https://doi.org/10.1186/s12885-021-08370-x>
1409. Takahashi Y, Gleber-Netto FO, Bell D, et al. Identification of markers predictive for response to induction chemotherapy in patients with sinonasal undifferentiated carcinoma. *Oral Oncol*. 2019;97:56-61. <https://doi.org/10.1016/j.oraloncology.2019.07.028>
1410. Takahashi Y, Pickering C, Gelbard A, et al. Genomic characterization of sinonasal undifferentiated carcinoma. *J Neurol Surg B Skull Base*. 2014;75(Suppl. 1):A084. <https://doi.org/10.1055/s-0034-1370490>
1411. Tanzler ED, Morris CG, Orlando CA, Werning JW, Mendenhall WM. Management of sinonasal undifferentiated carcinoma. *Head Neck*. 2008;30(5):595-599. <https://doi.org/10.1002/hed.20748>
1412. Faisal M, Seemann R, Lill C, et al. Elective neck treatment in sinonasal undifferentiated carcinoma: systematic review and meta-analysis. *Head Neck*. 2020;42(5):1057-1066. <https://doi.org/10.1002/hed.26077>
1413. Al-Mamgani A, van Rooij P, Mehilal R, Tans L, Levendag PC. Combined-modality treatment improved outcome in sinonasal undifferentiated carcinoma: single-institutional experience of 21 patients and review of the literature. *Eur Arch Otorhinolaryngol*. 2013;270(1):293-299. <https://doi.org/10.1007/s00405-012-2008-5>
1414. London NR, Mohyeldin A, Daoud G, et al. Sinonasal undifferentiated carcinoma: institutional trend toward induction chemotherapy followed by definitive chemoradiation. *Head Neck*. 2020;42(11):3197-3205. <https://doi.org/10.1002/hed.26357>
1415. Lehrich BM, Goshtasbi K, Abiri A, et al. Impact of induction chemotherapy and socioeconomic on sinonasal undifferentiated carcinoma survival. *Int Forum Allergy Rhinol*. 2020;10(5):679-688. <https://doi.org/10.1002/alr.22536>
1416. Fu TS, Chin CJ, Xu W, et al. Neoadjuvant radiation improves margin status compared to adjuvant radiation among patients with non-squamous cell carcinoma sinonasal malignancies. *J Neurol Surg B Skull Base*. 2016;77(Suppl. 1):A088. <https://doi.org/10.1055/s-0036-1579876>
1417. Hafstrom A, Sjoval J, Persson SS, Svensson C, Brun E, Greiff L. Outcome for sinonasal malignancies: a population-based survey. *Eur Arch Otorhinolaryngol*. 2022;279(5):2611-2622. <https://doi.org/10.1007/s00405-021-07057-0>
1418. Bishop JA, Westra WH. NUT midline carcinoma of the sinonasal tract. *Am J Surg Pathol*. 2012;36(8):1216-1221. <https://doi.org/10.1097/PAS.0b013e318254ce54>
1419. French CA. NUT carcinoma: clinicopathologic features, pathogenesis, and treatment. *Pathol Int*. 2018;68(11):583-595. <https://doi.org/10.1111/pin.12727>
1420. Chau NG, Hurwitz S, Mitchell CM, et al. Intensive treatment and survival outcomes in NUT midline carcinoma of the head and neck. *Cancer*. 2016;122(23):3632-3640. <https://doi.org/10.1002/cncr.30242>
1421. Stelow EB. A review of NUT midline carcinoma. *Head Neck Pathol*. 2011;5(1):31-35. <https://doi.org/10.1007/s12105-010-0235-x>
1422. Fang W, French CA, Cameron MJ, Han Y, Liu H. Clinicopathological significance of NUT rearrangements in poorly differentiated malignant tumors of the upper respiratory tract. *Int J Surg Pathol*. 2013;21(2):102-110. <https://doi.org/10.1177/1066896912451651>
1423. Chau NG, Ma C, Danga K, et al. An anatomical site and genetic-based prognostic model for patients with nuclear protein in testis (NUT) midline carcinoma: analysis of 124 patients. *JNCI Cancer Spectr*. 2020;4(2):pkz094. <https://doi.org/10.1093/jncics/pkz094>
1424. Bauer DE, Mitchell CM, Strait KM, et al. Clinicopathologic features and long-term outcomes of NUT midline carcinoma. *Clin Cancer Res*. 2012;18(20):5773-5779. <https://doi.org/10.1158/1078-0432.CCR-12-1153>
1425. Shakibai N, Contrera KJ, Roberts DB, et al. Sinonasal NUT carcinoma: a consecutive case series. *J Neurol Surg B Skull Base*. 2022;83(Suppl. 1):S1-S270. Podium presentation at 31st Annual Meeting North American Skull Base Society, Phoenix, Arizona, USA, February 20, 2022. <https://doi.org/10.1055/s-0042-1743754>
1426. Arimizu K, Hirano G, Makiyama C, Matsuo M, Sasaguri T, Makiyama A. NUT carcinoma of the nasal cavity that responded to a chemotherapy regimen for Ewing's sarcoma family of tumors: a case report. *BMC Cancer*. 2018;18(1):1134. <https://doi.org/10.1186/s12885-018-5087-x>
1427. Piha-Paul SA, Hann CL, French CA, et al. Phase 1 study of molibresib (GSK525762), a bromodomain and extra-terminal domain protein inhibitor, in NUT carcinoma and other solid tumors. *JNCI Cancer Spectr*. 2020;4(2):pkz093. <https://doi.org/10.1093/jncics/pkz093>
1428. Morrison-Smith CD, Knox TM, Filic I, et al. Combined targeting of the BRD4-NUT-p300 axis in NUT midline carcinoma by dual selective bromodomain inhibitor, NEO2734. *Mol Cancer Ther*. 2020;19(7):1406-1414. <https://doi.org/10.1158/1535-7163.MCT-20-0087>
1429. McLean-Holden A, Ogunbona O, Lubin D, et al. SWI/SNF alterations in poorly-differentiated sinonasal carcinomas: an institutional experience identifying INI1-and BRG1-deficient carcinomas via immunohistochemistry. *Lab Invest*. 2021;101(Suppl. 1):782-783.
1430. Shah AA, Jain D, Ababneh E, et al. SMARCB1 (INI-1)-deficient adenocarcinoma of the sinonasal tract: a potentially under-recognized form of sinonasal adenocarcinoma with occasional yolk sac tumor-like features. *Head Neck Pathol*. 2020;14(2):465-472. <https://doi.org/10.1007/s12105-019-01065-7>
1431. Agaimy A, Hartmann A, Antonescu CR, et al. SMARCB1 (INI-1)-deficient sinonasal carcinoma: a series of 39 cases expanding the morphologic and clinicopathologic spectrum of a recently described entity. *Am J Surg Pathol*. 2017;41(4):458-471. <https://doi.org/10.1097/PAS.0000000000000797>
1432. Kakkar A, Antony VM, Pramanik R, Sakthivel P, Singh CA, Jain D. SMARCB1 (INI1)-deficient sinonasal carcinoma: a series of 13 cases with assessment of histologic patterns. *Hum*

- Pathol.* 2019;83:59-67. <https://doi.org/10.1016/j.humpath.2018.08.008>
1433. Agaimy A, Jain D, Uddin N, Rooper LM, Bishop JA. SMARCA4-deficient sinonasal carcinoma: a series of 10 cases expanding the genetic spectrum of SWI/SNF-driven sinonasal malignancies. *Am J Surg Pathol.* 2020;44(5):703-710. <https://doi.org/10.1097/PAS.0000000000001428>
 1434. Mittal N, Bal M, Rane S, Patil A. Sinonasal teratocarcinoma: a single institution clinic-pathological study. *Lab Invest.* 2019;99(Suppl. 1):30.
 1435. Franchi A. Sinonasal tumor pathology: what's new? *Pathologica.* 2017;109(1):9-13.
 1436. Ayyanar P, Mishra P, Preetam C, Adhya AK. SMARCB1/INI1 deficient sino-nasal carcinoma: extending the histomorphological features. *Head Neck Pathol.* 2021;15(2):555-565. <https://doi.org/10.1007/s12105-020-01246-9>
 1437. Shatzkes DR, Ginsberg LE, Wong M, et al. Imaging appearance of SMARCB1 (INI1)-deficient sinonasal carcinoma: a newly described sinonasal malignancy. *Am J Neuroradiol.* 2016;37(10):1925-1929. <https://doi.org/10.3174/ajnr.A4841>
 1438. Agaimy A, Bishop JA. SWI/SNF-deficient head and neck neoplasms: an overview. *Semin Diagn Pathol.* 2021;38(3):175-182. <https://doi.org/10.1053/j.semmp.2021.02.002>
 1439. Chitguppi C, Berman E, Molligan J, et al. Can INI-1 (SMARCB1) gene determine the survival outcomes in sinonasal undifferentiated carcinoma? *J Neurol Surg B Skull Base.* 2019;80(Suppl. 1):S1-S244. <https://doi.org/10.1055/s-0039-1679579>
 1440. Bishop JA, Antonescu CR, Westra WH. SMARCB1 (INI-1)-deficient carcinomas of the sinonasal tract. *Am J Surg Pathol.* 2014;38(9):1282-1289. <https://doi.org/10.1097/PAS.0000000000000285>
 1441. Reiersen DA, Pahilan ME, Devaiah AK. Meta-analysis of treatment outcomes for sinonasal undifferentiated carcinoma. *Otolaryngol Head Neck Surg.* 2012;147(1):7-14. <https://doi.org/10.1177/0194599812440932>
 1442. Chamberlain M, Rodriguez C, Liao J. Sinonasal undifferentiated carcinoma (SNUC): incidence of CNS involvement. *Neuro-Oncol.* 2016;18(Suppl. 6):vi162. <https://doi.org/10.1093/neuonc/now212.674>
 1443. Bhasker S, Mallick S, Benson R, Bhanuprasad V, Sharma A, Thakar A. A multimodality approach to sinonasal undifferentiated carcinoma: a single institute experience. *J Laryngol Otol.* 2017;131(1):19-25.
 1444. Gray ST, Herr MW, Sethi RK, et al. Treatment outcomes and prognostic factors, including human papillomavirus, for sinonasal undifferentiated carcinoma: a retrospective review. *Head Neck.* 2015;37(3):366-374. <https://doi.org/10.1002/hed.23606>
 1445. Liao JJ, Jewell P, Parvathaneni U, Laramore G, Polissar N, Wong W. Management and long-term outcomes of sinonasal undifferentiated carcinoma: twenty-year experience at a single institution. *Int J Radiat Oncol Biol Phys.* 2014;90(1):S544-S545.
 1446. Christopherson KM, Werning JW, Malyapa RS, Morris CG, Mendenhall WM. Radiation therapy for sinonasal undifferentiated carcinoma. *Int J Radiat Oncol Biol Phys.* 2013;87(2):S456. <https://doi.org/10.1016/j.ijrobp.2013.06.1204>
 1447. Su SY, De Almeida JR, Filho FVG, et al. Endoscopic endonasal resection of sinonasal undifferentiated carcinoma: the UPMC experience. *J Neurol Surg B Skull Base.* 2013;74(Suppl. 1):A009. <https://doi.org/10.1055/s-0033-1336143>
 1448. Yoshida E, Aouad R, Fragoso R, et al. Improved clinical outcomes with multi-modality therapy for sinonasal undifferentiated carcinoma of the head and neck. *Am J Otolaryngol.* 2013;34(6):658-663. <https://doi.org/10.1016/j.amjoto.2013.06.005>
 1449. Millard R, O'Shea N, Powell H, et al. Combined modality management of sinonasal undifferentiated carcinoma. *J Neurol Surg B Skull Base.* 2013;74(Suppl. 1):A008. <https://doi.org/10.1055/s-0033-1336142>
 1450. Xu CC, Dziegielewski PT, McGaw WT, Seikaly H. Sinonasal undifferentiated carcinoma (SNUC): the Alberta experience and literature review. *J Otolaryngol Head Neck Surg.* 2013;42:2. <https://doi.org/10.1186/1916-0216-42-2>
 1451. Mourad WF, Hauerstock D, Shourbaji RA, et al. Trimodality management of sinonasal undifferentiated carcinoma and review of the literature. *Am J Clin Oncol.* 2013;36(6):584-588. <https://doi.org/10.1097/COC.0b013e31825eb3a5>
 1452. Lee LN, Gray ST, Curry W, et al. Multimodality treatment outcomes of sinonasal undifferentiated carcinoma of the skull base. *J Neurol Surg B Skull Base.* 2012;73(Suppl. 1):A163. <https://doi.org/10.1055/s-0032-1312211>
 1453. Revenaugh PC, Seth R, Pavlovich JB, Knott PD, Batra PS. Minimally invasive endoscopic resection of sinonasal undifferentiated carcinoma. *Am J Otolaryngol.* 2011;32(6):464-469. <https://doi.org/10.1016/j.amjoto.2010.09.006>
 1454. Lin EM, Sparano A, Spalding A, et al. Sinonasal undifferentiated carcinoma: a 13-year experience at a single institution. *Skull Base.* 2010;20(2):61-67. <https://doi.org/10.1055/s-0029-1236165>
 1455. Minato H, Kobayashi E, Nakada S, et al. Sinonasal NUT carcinoma: clinicopathological and cytogenetic analysis with autopsy findings. *Hum Pathol.* 2018;71:157-165. <https://doi.org/10.1016/j.humpath.2017.10.011>
 1456. Chitguppi C, Rabinowitz MR, Johnson J, et al. Loss of SMARCB1 expression confers poor prognosis to sinonasal undifferentiated carcinoma. *J Neurol Surg B Skull Base.* 2020;81(6):610-619. <https://doi.org/10.1055/s-0039-1693659>
 1457. Allard FD, Bell D, Stelow EB. Cytopathologic features of SMARCB1 (INI-1)-deficient sinonasal carcinoma. *Cancer Cytopathol.* 2018;126(8):567-574. <https://doi.org/10.1002/cncy.22020>
 1458. Laco J, Chmelařová M, Vošmiková H, et al. SMARCB1/INI1-deficient sinonasal carcinoma shows methylation of RASSF1 gene: a clinicopathological, immunohistochemical and molecular genetic study of a recently described entity. *Pathol Res Pract.* 2017;213(2):133-142. <https://doi.org/10.1016/j.prp.2016.10.012>
 1459. Bell D. Sinonasal neuroendocrine neoplasms: current challenges and advances in diagnosis and treatment, with a focus on olfactory neuroblastoma. *Head Neck Pathol.* 2018;12(1):22-30. <https://doi.org/10.1007/s12105-018-0887-5>
 1460. Mitchell EH, Diaz A, Yilmaz T, et al. Multimodality treatment for sinonasal neuroendocrine carcinoma. *Head Neck.* 2012;34(10):1372-1376. <https://doi.org/10.1002/hed.21940>

1461. Lin N, Qi M, Wang Z, et al. Small cell neuroendocrine carcinoma of paranasal sinuses: radiologic features in 14 cases. *J Comput Assist Tomogr*. 2021;45(1):135-141. <https://doi.org/10.1097/RCT.0000000000001065>
1462. Zhu Q, Zhu W, Wu J, Zhang H. The CT and MRI observations of small cell neuroendocrine carcinoma in paranasal sinuses. *World J Surg Oncol*. 2015;13:54. <https://doi.org/10.1186/s12957-015-0475-z>
1463. van der Laan TP, Bij HP, van Hemel BM, et al. The importance of multimodality therapy in the treatment of sinonasal neuroendocrine carcinoma. *Eur Arch Otorhinolaryngol*. 2013;270(9):2565-2568. <https://doi.org/10.1007/s00405-013-2554-5>
1464. Wang CP, Hsieh CY, Chang YL, et al. Postirradiated neuroendocrine carcinoma of the sinonasal tract. *Laryngoscope*. 2008;118(5):804-809. <https://doi.org/10.1097/MLG.0b013e3181671491>
1465. Alos L, Hakim S, Larque AB, et al. p16 overexpression in high-grade neuroendocrine carcinomas of the head and neck: potential diagnostic pitfall with HPV-related carcinomas. *Virchows Arch*. 2016;469(3):277-284. <https://doi.org/10.1007/s00428-016-1982-1>
1466. Ohmoto A, Sato Y, Asaka R, et al. Clinicopathological and genomic features in patients with head and neck neuroendocrine carcinoma. *Mod Pathol*. 2021;34(11):1979-1989. <https://doi.org/10.1038/s41379-021-00869-9>
1467. Lopez-Hernandez A, Vivanco B, Franchi A, et al. Genetic profiling of poorly differentiated sinonasal tumours. *Science*. 2018;8(1):3998. <https://doi.org/10.1038/s41598-018-21690-6>
1468. Likhacheva A, Rosenthal DI, Hanna E, Kupferman M, Demonte F, El-Naggar AK. Sinonasal neuroendocrine carcinoma: impact of differentiation status on response and outcome. *Head Neck Oncol*. 2011;3:32. <https://doi.org/10.1186/1758-3284-3-32>
1469. Rosenthal DI, Barker JL, El-Naggar AK, et al. Sinonasal malignancies with neuroendocrine differentiation: patterns of failure according to histologic phenotype. *Cancer*. 2004;101(11):2567-2573. <https://doi.org/10.1002/cncr.20693>
1470. Babin E, Rouleau V, Vedrine PO, et al. Small cell neuroendocrine carcinoma of the nasal cavity and paranasal sinuses. *J Laryngol Otol*. 2006;120(4):289-297. <https://doi.org/10.1017/S0022215106000594>
1471. Hosokawa S, Takahashi G, Baba S, Mineta H. Small cell neuroendocrine carcinomas arising in the head and neck region. *J Oral Maxillofac Surg*. 2016;74(5):1091-1095. <https://doi.org/10.1016/j.joms.2015.11.015>
1472. Sorbye H, Welin S, Langer SW, et al. Predictive and prognostic factors for treatment and survival in 305 patients with advanced gastrointestinal neuroendocrine carcinoma (WHO G3): the NORDIC NEC study. *Ann Oncol*. 2013;24(1):152-160. <https://doi.org/10.1093/annonc/mds276>
1473. Patil VM, Joshi A, Noronha V, et al. Neoadjuvant chemotherapy in locally advanced and borderline resectable non-squamous sinonasal tumors (esthesioneuroblastoma and sinonasal tumor with neuroendocrine differentiation). *Int J Surg Oncol*. 2016;2016:6923730. <https://doi.org/10.1155/2016/6923730>
1474. Keilin CA, VanKoeveering KK, McHugh JB, McKean EL. Sinonasal neuroendocrine carcinoma: 15 years of experience at a single institution. *J Neurol Surg B Skull Base*. 2023;84(1):51-59. <https://doi.org/10.1055/s-0041-1740968>
1475. Moya-Plana A, Aupérin A, Obongo R, et al. Oncologic outcomes, prognostic factor analysis and therapeutic algorithm evaluation of head and neck mucosal melanomas in France. *Eur J Cancer*. 2019;123:1-10. <https://doi.org/10.1016/j.ejca.2019.09.007>
1476. Chłopek M, Lasota J, Thompson LDR, et al. Alterations in key signaling pathways in sinonasal tract melanoma. A molecular genetics and immunohistochemical study of 90 cases and comprehensive review of the literature. *Mod Pathol*. 2022;35(11):1609-1617. <https://doi.org/10.1038/s41379-022-01122-7>
1477. Gal TJ, Silver N, Huang B. Demographics and treatment trends in sinonasal mucosal melanoma. *Laryngoscope*. 2011;121(9):2026-2033. <https://doi.org/10.1002/lary.21925>
1478. Jangard M, Hansson J, Ragnarsson-Olding B. Primary sinonasal malignant melanoma: a nationwide study of the Swedish population, 1960-2000. *Rhinology*. 2013;51(1):22-30. <https://doi.org/10.4193/Rhino12.075>
1479. Rose AAN, Armstrong SM, Hogg D, et al. Biologic subtypes of melanoma predict survival benefit of combination anti-PD1+anti-CTLA4 immune checkpoint inhibitors versus anti-PD1 monotherapy. *J Immunother Cancer*. 2021;9(1):e001642. <https://doi.org/10.1136/jitc-2020-001642>
1480. Rossi E, Schinzari G, Maiorano BA, et al. Efficacy of immune checkpoint inhibitors in different types of melanoma. *Hum Vaccin Immunother*. 2021;17(1):4-13. <https://doi.org/10.1080/21645515.2020.1771986>
1481. Guo R, Jenkins SM, Johnson BJ, Reed K, Kroneman T, Choby G. Sinonasal mucosal melanoma: role of tumor proliferative indices and pathological factors in survival. *Laryngoscope*. 2022;132(12):2350-2358. <https://doi.org/10.1002/lary.30240>
1482. Lund VJ, Chisholm EJ, Howard DJ, Wei WI. Sinonasal malignant melanoma: an analysis of 115 cases assessing outcomes of surgery, postoperative radiotherapy and endoscopic resection. *Rhinology*. 2012;50(2):203-210. <https://doi.org/10.4193/Rhino.11.267>
1483. Low CM, Price DL, Moore EJ, et al. Nodal and distant metastases in sinonasal mucosal melanoma: a population-based analysis. *Laryngoscope*. 2020;130(3):622-627. <https://doi.org/10.1002/lary.28065>
1484. Balch CM, Gershenwald JE, Soong SJ, et al. Final version of 2009 AJCC melanoma staging and classification. *J Clin Oncol*. 2009;27(36):6199-6206. <https://doi.org/10.1200/JCO.2009.23.4799>
1485. Amit M, Tam S, Abdelmeguid AS, et al. Patterns of treatment failure in patients with sinonasal mucosal melanoma. *Ann Surg Oncol*. 2018;25(6):1723-1729. <https://doi.org/10.1245/s10434-018-6465-y>
1486. De Virgilio A, Costantino A, Canzano F, et al. Regional disease control in sinonasal mucosal melanoma: systematic review and meta-analysis. *Head Neck*. 2021;43(2):705-715. <https://doi.org/10.1002/hed.26537>
1487. Houette A, Gilain L, Mulliez A, Mom T, Saroul N. Prognostic value of two tumour staging classifications in patients with sinonasal mucosal melanoma. *Eur Ann Otorhinolaryngol Head Neck Dis*. 2016;133(5):313-317. <https://doi.org/10.1016/j.anorl.2016.05.008>

1488. Michel J, Perret-Court A, Fakhry N, et al. Sinonasal mucosal melanomas: the prognostic value of tumor classifications. *Head Neck*. 2014;36(3):311-316. <https://doi.org/10.1002/hed.23298>
1489. Jethanamest D, Vila PM, Sikora AG, Morris LG. Predictors of survival in mucosal melanoma of the head and neck. *Ann Surg Oncol*. 2011;18(10):2748-2756. <https://doi.org/10.1245/s10434-011-1685-4>
1490. Abdul Aziz MHF, Fernando IP, Lenkanpally A, Fernando DJS. Diabetic ketoacidosis after treatment with pembrolizumab. *J Clin Transl Endocrinol: Case Rep*. 2017;5:4-5. <https://doi.org/10.1016/j.jecr.2017.05.002>
1491. Flukes S, Lohia S, Barker CA, et al. Tumor volume is a predictor of distant metastases and overall survival in sinonasal mucosal melanoma. *Int J Radiat Oncol Biol Phys*. 2020;106(5):1190-1191. <https://doi.org/10.1016/j.ijrobp.2019.11.096>
1492. Mochel MC, Duncan LM, Piris A, Kraft S. Primary mucosal melanoma of the sinonasal tract: a clinicopathologic and immunohistochemical study of thirty-two cases. *Head Neck Pathol*. 2015;9(2):236-243. <https://doi.org/10.1007/s12105-014-0570-4>
1493. Feeley C, Theaker J. Epithelial markers in primary sinonasal mucosal melanoma. *Histopathology*. 2004;45(1):96-98. <https://doi.org/10.1111/j.1365-2559.2004.01824.x>
1494. Dauer EH, Lewis JE, Rohlinger AL, Weaver AL, Olsen KD. Sinonasal melanoma: a clinicopathologic review of 61 cases. *Otolaryngol Head Neck Surg*. 2008;138(3):347-352. <https://doi.org/10.1016/j.otohns.2007.12.013>
1495. Miettinen M, McCue PA, Sarlomo-Rikala M, et al. Sox10—a marker for not only schwannian and melanocytic neoplasms but also myoepithelial cell tumors of soft tissue: a systematic analysis of 5134 tumors. *Am J Surg Pathol*. 2015;39(6):826-835. <https://doi.org/10.1097/PAS.0000000000000398>
1496. Guo R, Jenkins S, Choby G. Pathological and clinical analysis of sinonasal mucosal melanoma with emphasis on prognosis relevant factors and unusual morphological features: a comprehensive study of 45 patients. *Mod Pathol*. 2020;33(3):1199-1200.
1497. Cinotti E, Chevallier J, Labeille B, et al. Mucosal melanoma: clinical, histological and *c-kit* gene mutational profile of 86 French cases. *J Eur Acad Dermatol Venereol*. 2017;31(11):1834-1840. <https://doi.org/10.1111/jdv.14353>
1498. Regauer S, Anderhuber W, Richtig E, Schachenreiter J, Ott A, Beham A. Primary mucosal melanomas of the nasal cavity and paranasal sinuses. A clinicopathological analysis of 14 cases. *APMIS*. 1998;106(3):403-410. <https://doi.org/10.1111/j.1699-0463.1998.tb01364.x>
1499. Crippen MM, Kilic S, Eloy JA. Updates in the management of sinonasal mucosal melanoma. *Curr Opin Otolaryngol Head Neck Surg*. 2018;26(1):52-57. <https://doi.org/10.1097/MOO.0000000000000428>
1500. Edmond M, Nenclares P, Harrington K, et al. What is the role of the surgeon in the management of head and neck mucosal melanoma in the immunotherapy era? *Head Neck*. 2021;43(11):3498-3503. <https://doi.org/10.1002/hed.26849>
1501. Amit M, Na'ara S, Hanna EY. Contemporary treatment approaches to sinonasal mucosal melanoma. *Curr Oncol Rep*. 2018;20(2):10. <https://doi.org/10.1007/s11912-018-0660-7>
1502. Tajudeen BA, Vorasubin N, Sanaiha Y, Palma-Diaz MF, Suh JD, Wang MB. Sinonasal mucosal melanoma: 20-year experience at a tertiary referral center. *Int Forum Allergy Rhinol*. 2014;4(7):592-597. <https://doi.org/10.1002/alr.21324>
1503. Oliver JR, WP. Patterns of care in mucosal melanoma of the head and neck. *Otolaryngol Head Neck Surg*. 2019;161:79-80.
1504. Lombardi D, Bottazzoli M, Turri-Zanoni M, et al. Sinonasal mucosal melanoma: a 12-year experience of 58 cases. *Head Neck*. 2016;38(Suppl 1):E1737-E1745. <https://doi.org/10.1002/hed.24309>
1505. Choby G, Rabinowitz MR, Patel ZM, et al. Emerging concepts in endoscopic skull base surgery training. *Int Forum Allergy Rhinol*. 2021;11(12):1611-1616. <https://doi.org/10.1002/alr.22895>
1506. Moreno MA, Hanna EY. Management of mucosal melanomas of the head and neck: did we make any progress? *Curr Opin Otolaryngol Head Neck Surg*. 2010;18(2):101-106. <https://doi.org/10.1097/MOO.0b013e3283374d31>
1507. Woo HJ, Hwang PH, Kaplan MJ, Choby G. Clinical characteristics and prognostic factors of malignant tumors involving pterygopalatine fossa. *Head Neck*. 2020;42(2):281-288. <https://doi.org/10.1002/hed.26000>
1508. Alokby G, Casiano RR. Endoscopic resection of sinonasal and ventral skull base malignancies. *Otolaryngol Clin North Am*. 2017;50(2):273-285. <https://doi.org/10.1016/j.otc.2016.12.005>
1509. Na'ara S, Mukherjee A, Billan S, Gil Z. Contemporary multidisciplinary management of sinonasal mucosal melanoma. *Onco Targets Ther*. 2020;13:2289-2298. <https://doi.org/10.2147/OTT.S182580>
1510. Awad AJ, Mohyeldin A, El-Sayed IH, Aghi MK. Sinonasal morbidity following endoscopic endonasal skull base surgery. *Clin Neurol Neurosurg*. 2015;130:162-167. <https://doi.org/10.1016/j.clineuro.2015.01.004>
1511. Shukla A, Ahmed OG, Orlov CP, et al. Quality-of-life instruments in endoscopic endonasal skull base surgery—a practical systematic review. *Int Forum Allergy Rhinol*. 2021;11(8):1264-1268. <https://doi.org/10.1002/alr.22783>
1512. Yin LX, Low CM, Puccinelli CL, et al. Olfactory outcomes after endoscopic skull base surgery: a systematic review and meta-analysis. *Laryngoscope*. 2019;129(9):1998-2007. <https://doi.org/10.1002/lary.28003>
1513. Oliver JR, Wu PS, Li ZJ, et al. Patterns of care in mucosal melanoma of the head and neck. *Otolaryngology – Head and Neck Surgery*. 2019;161(2 Supplement):P79-P80. Podium presentation at the 2019 American Academy of Otolaryngology-Head and Neck Surgery Annual Meeting, New Orleans, LA, USA, September 2019.
1514. Nenclares P, Ap Dafydd D, Bagwan I, et al. Head and neck mucosal melanoma: the United Kingdom national guidelines. *Eur J Cancer*. 2020;138:11-18. <https://doi.org/10.1016/j.ejca.2020.07.017>
1515. Amit M, Hanna E, Abdelmeguid AS, et al. Induction chemotherapy for chemoselection in advanced Sinonasal mucosal melanoma. *J Neurol Surg B Skull Base*. 2018;79(Suppl 1):S1-S188. <https://doi.org/10.1055/s-0038-1633451>
1516. Pincet L, Lambercy K, Pasche P, Broome M, Latifyan S, Reinhard A. Mucosal melanoma of the head and neck: a retrospective review and current opinion. *Front Surg*. 2020;7:616174. <https://doi.org/10.3389/fsurg.2020.616174>

1517. Studentova H, Kalabova H, Koranda P, et al. Immunotherapy in mucosal melanoma: a case report and review of the literature. *Oncotarget*. 2018;9(25):17971-17977. <https://doi.org/10.18632/oncotarget.24727>
1518. Chao TN, Kuan EC, Tong CCL, et al. Surgical treatment of sinonasal mucosal melanoma in patients treated with systemic immunotherapy. *J Neurol Surg B Skull Base*. 2021;82(Suppl. 3):e148-e154. <https://doi.org/10.1055/s-0040-1701219>
1519. Amit M, Tam S, Takahashi Y, Bell D, Roberts D, Hanna E. Mutation status in sinonasal mucosal melanoma. *J Neurol Surg B Skull Base*. 2017;78(Suppl. 1):S1-S156. <https://doi.org/10.1055/s-0037-1600615>
1520. Amit M, Tam S, Abdelmeguid AS, et al. Mutation status among patients with sinonasal mucosal melanoma and its impact on survival. *Br J Cancer*. 2017;116(12):1564-1571. <https://doi.org/10.1038/bjc.2017.125>
1521. Edwards J, Ferguson PM, Lo SN, et al. Tumor mutation burden and structural chromosomal aberrations are not associated with T-cell density or patient survival in acral, mucosal, and cutaneous melanomas. *Cancer Immunol Res*. 2020;8(11):1346-1353. <https://doi.org/10.1158/2326-6066.CIR-19-0835>
1522. Al-Faraidy N, Deodhare N, Naert K, et al. Molecular profiling of common melanoma mutations—a large cohort study. *Lab Invest*. 2015;95:510A-511A. <https://doi.org/10.1038/labinvest.2015.25>
1523. Blokx WAM. Molecular diagnostics in melanoma. *J Pathol*. 2013;229(1):S5. <https://doi.org/10.1002/path.4190>
1524. Ferrucci PF, Battaglia A, Cocorocchio E, et al. B-Raf, C-Kit and MGMT molecular evaluation on 316 consecutive patients (pts) affected by Metastatic Melanoma (MM) and receiving different treatment combinations - do mutations influence outcome? *Eur J Cancer*. 2012;48(5):S208. <https://doi.org/10.1016/S0959-8049%2812%2971496-X>
1525. Inamdar GS, Madhunapantula SV, Robertson GP. Targeting the MAPK pathway in melanoma: why some approaches succeed and other fail. *Biochem Pharmacol*. 2010;80(5):624-637. <https://doi.org/10.1016/j.bcp.2010.04.029>
1526. Chapman PB, Hauschild A, Robert C, et al. Improved survival with vemurafenib in melanoma with BRAF V600E mutation. *N Engl J Med*. 2011;364(26):2507-2516. <https://doi.org/10.1056/NEJMoal103782>
1527. Dummer R, Goldinger S, Turttschi C, Gisler S, Eggmann N, Rinderknecht J. Inhibition of the MEK-kinase pathway in advanced melanoma. *Onkologie*. 2011;34(6):2-3. <https://doi.org/10.1159/000333299>
1528. Gummadi T, Dronca RS, Kim C, et al. Impact of BRAF mutation and effectiveness of BRAF inhibitor on the brain metastases in patients with metastatic melanoma. *J Clin Oncol Conf*. 2013;31(15 Suppl. 1):Abstract 9048.
1529. Kim HS, Jang KW, Jung M, Kim SH, Kim TM, Cho BC. Oncogenic BRAF fusion induces MAPK-pathway activation targeted by MEK inhibitor and phosphatidylinositol 3-kinase inhibitor combination treatment in mucosal melanoma. *Cancer Res*. 2015;75(15 Suppl. 1):3942. <https://doi.org/10.1158/1538-7445.AM2015-3942>
1530. McArthur G, Gonzalez R, Pavlick A, et al. Vemurafenib (VEM) and MEK inhibitor, cobimetinib (GDC-0973), in advanced BRAFV600-mutated melanoma (BRIM7): dose-escalation and expansion results of a phase IB study. *Eur J Cancer*. 2013;49(2):S856-S857. <https://doi.org/10.1016/S0959-8049%2813%2970065-0>
1531. Chapman PB, Robert C, Larkin J, et al. Vemurafenib in patients with BRAFV600 mutation-positive metastatic melanoma: final overall survival results of the randomized BRIM-3 study. *Ann Oncol*. 2017;28(10):2581-2587. <https://doi.org/10.1093/annonc/mdx339>
1532. Ozturk Sari S, Yilmaz I, Taskin OC, et al. BRAF, NRAS, KIT, TERT, GNAQ/GNA11 mutation profile analysis of head and neck mucosal melanomas: a study of 42 cases. *Pathology*. 2017;49(1):55-61. <https://doi.org/10.1016/j.pathol.2016.09.065>
1533. Phlippen M, Prera N, Ludwig-Peitsch W, et al. Melanoma of the nasal cavity - an interdisciplinary challenge. *Laryngorhinootologie*. 2021;100(Suppl. 2):S117. <https://doi.org/10.1055/s-0041-1727947>
1534. Dumaz N, Jouenne F, Delyon J, Mourah S, Bensussan A, Lebbe C. Atypical BRAF and NRAS mutations in mucosal melanoma. *Cancers*. 2019;11(8):1133. <https://doi.org/10.3390/cancers11081133>
1535. Garcia-Alvarez A, Ortiz C, Munoz-Couselo E. Current perspectives and novel strategies of NRAS-mutant melanoma. *Onco Targets Ther*. 2021;14:3709-3719. <https://doi.org/10.2147/OTT.S278095>
1536. Munoz-Couselo E, Adelantado EZ, Ortiz C, Garcia JS, Perez-Garcia J. NRAS-mutant melanoma: current challenges and future prospect. *Onco Targets Ther*. 2017;10:3941-3947. <https://doi.org/10.2147/OTT.S117121>
1537. Delyon J, Lebbe C, Dumaz N. Targeted therapies in melanoma beyond BRAF: targeting NRAS-mutated and KIT-mutated melanoma. *Curr Opin Oncol*. 2020;32(2):79-84. <https://doi.org/10.1097/CCO.0000000000000606>
1538. Dummer R, Schadendorf D, Ascierto PA, et al. Binimetinib versus dacarbazine in patients with advanced NRAS-mutant melanoma (NEMO): a multicentre, open-label, randomised, phase 3 trial. *Lancet Oncol*. 2017;18(4):435-445. [https://doi.org/10.1016/S1470-2045\(17\)30180-8](https://doi.org/10.1016/S1470-2045(17)30180-8)
1539. Lebbe C, Dutriaux C, Lesimple T, et al. Pimasertib versus dacarbazine in patients with unresectable NRAS-mutated cutaneous melanoma: phase II, randomized, controlled trial with crossover. *Cancers*. 2020;12(7):1727. <https://doi.org/10.3390/cancers12071727>
1540. Amaral T, Meraz-Torres F, Garbe C. Immunotherapy in managing metastatic melanoma: which treatment when? *Expert Opin Biol Ther*. 2017;17(12):1523-1538. <https://doi.org/10.1080/14712598.2017.1378640>
1541. Dabelic N, Brozic JM, Frobe A. Recent advances in targeted therapies of melanoma. *Libri Oncologici*. 2020;48(Suppl. 1):45-47.
1542. Ling DC, Bakkenist CJ, Ferris RL, Clump DA. Role of immunotherapy in head and neck cancer. *Semin Radiat Oncol*. 2018;28(1):12-16. <https://doi.org/10.1016/j.semradonc.2017.08.009>
1543. Kaunitz GJ, Cottrell TR, Lilo M, et al. Melanoma subtypes demonstrate distinct PD-L1 expression profiles. *Lab Invest*. 2017;97(9):1063-1071. <https://doi.org/10.1038/labinvest.2017.64>
1544. Specenier P. Ipilimumab in melanoma. *Expert Rev Anticancer Ther*. 2016;16(8):811-826. <https://doi.org/10.1080/14737140.2016.1211936>

1545. Guo L, Zhang H, Chen B. Nivolumab as programmed death-1 (PD-1) inhibitor for targeted immunotherapy in tumor. *J Cancer*. 2017;8(3):410-416. <https://doi.org/10.7150/jca.17144>
1546. Kashat L, Le CH, Chiu AG. The role of targeted therapy in the management of sinonasal malignancies. *Otolaryngol Clin North Am*. 2017;50(2):443-455. <https://doi.org/10.1016/j.otc.2016.12.016>
1547. Topalian SL, Hodi FS, Brahmer JR, et al. Safety, activity, and immune correlates of anti-PD-1 antibody in cancer. *N Engl J Med*. 2012;366(26):2443-2454. <https://doi.org/10.1056/NEJMoa1200690>
1548. Topalian SL, Sznol M, McDermott DF, et al. Survival, durable tumor remission, and long-term safety in patients with advanced melanoma receiving nivolumab. *J Clin Oncol*. 2014;32(10):1020-1030. <https://doi.org/10.1200/JCO.2013.53.0105>
1549. Klemen ND, Wang M, Rubinstein JC, et al. Survival after checkpoint inhibitors for metastatic acral, mucosal and uveal melanoma. *J Immunother Cancer*. 2020;8(1):e000341. <https://doi.org/10.1136/jitc-2019-000341>
1550. D'Angelo SP, Larkin J, Sosman JA, et al. Efficacy and safety of nivolumab alone or in combination with ipilimumab in patients with mucosal melanoma: a pooled analysis. *J Clin Oncol*. 2017;35(2):226-235. <https://doi.org/10.1200/JCO.2016.67.9258>
1551. Hodi FS, Chapman PB, Sznol M, et al. Safety and efficacy of combination nivolumab plus ipilimumab in patients with advanced melanoma: results from a North American expanded access program (CheckMate 218). *Melanoma Res*. 2021;31(1):67-75.
1552. Topalian SL, Hodi FS, Brahmer JR, et al. Five-year survival and correlates among patients with advanced melanoma, renal cell carcinoma, or non-small cell lung cancer treated with nivolumab. *JAMA Oncol*. 2019;5(10):1411-1420. <https://doi.org/10.1001/jamaoncol.2019.2187>
1553. Baetz TD, Fletcher GG, Knight G, et al. Systemic adjuvant therapy for adult patients at high risk for recurrent melanoma: a systematic review. *Cancer Treat Rev*. 2020;87:102032. <https://doi.org/10.1016/j.ctrv.2020.102032>
1554. Rutkowski P, Kozak K. News from the melanoma sessions of the European Cancer Congress 2017. *BMC Med*. 2017;15(1):57. <https://doi.org/10.1186/s12916-017-0826-4>
1555. Hodi FS, O'Day SJ, McDermott DF, et al. Improved survival with ipilimumab in patients with metastatic melanoma. *N Engl J Med*. 2010;363(8):711-723. <https://doi.org/10.1056/NEJMoa1003466>
1556. Schadendorf D, Hodi FS, Robert C, et al. Pooled analysis of long-term survival data from phase II and phase III trials of ipilimumab in unresectable or metastatic melanoma. *J Clin Oncol*. 2015;33(17):1889-1894. <https://doi.org/10.1200/JCO.2014.56.2736>
1557. Tarhini A. Immune-mediated adverse events associated with ipilimumab CTLA-4 blockade therapy: the underlying mechanisms and clinical management. *Scientifica*. 2013;2013:857519. <https://doi.org/10.1155/2013/857519>
1558. Robert C, Long GV, Brady B, et al. Nivolumab in previously untreated melanoma without BRAF mutation. *N Engl J Med*. 2015;372(4):320-330. <https://doi.org/10.1056/NEJMoa1412082>
1559. Weber JS, D'Angelo SP, Minor D, et al. Nivolumab versus chemotherapy in patients with advanced melanoma who progressed after anti-CTLA-4 treatment (CheckMate 037): a randomised, controlled, open-label, phase 3 trial. *Lancet Oncol*. 2015;16(4):375-384. [https://doi.org/10.1016/S1470-2045\(15\)70076-8](https://doi.org/10.1016/S1470-2045(15)70076-8)
1560. Butler M, Hamid O, Ribas A, et al. Efficacy of pembrolizumab in patients with advanced mucosal melanoma enrolled in the KEYNOTE-001, 002, and 006 studies. *Eur J Cancer*. 2017;72(Suppl. 1):S123.
1561. Hamid O, Ribas A, Stephen Hodi F, et al. Efficacy of pembrolizumab (pembro) in patients (pts) with advanced mucosal melanoma (mucMEL): data from KEYNOTE-001, 002, and 006. *Pigment Cell Melanoma Res*. 2017;30(1):102. <https://doi.org/10.1111/pcmr.12547>
1562. Ribas A, Puzanov I, Dummer R, et al. Pembrolizumab versus investigator-choice chemotherapy for ipilimumab-refractory melanoma (KEYNOTE-002): a randomised, controlled, phase 2 trial. *Lancet Oncol*. 2015;16(8):908-918. [https://doi.org/10.1016/S1470-2045\(15\)00083-2](https://doi.org/10.1016/S1470-2045(15)00083-2)
1563. Klebaner D, Saddawi-Konefka R, Finegersh A, et al. Immunotherapy in sinonasal melanoma: treatment patterns and outcomes compared to cutaneous melanoma. *Int Forum Allergy Rhinol*. 2020;10(9):1087-1095. <https://doi.org/10.1002/alr.22628>
1564. Lechner M, Takahashi Y, Turri-Zanoni M, et al. International multicenter study of clinical outcomes of sinonasal melanoma shows survival benefit for patients treated with immune checkpoint inhibitors and potential improvements to the current TNM staging system. *J Neurol Surg B Skull Base*. 2023;84(4):307-319. <https://doi.org/10.1055/s-0042-1750178>
1565. Abiri A, Yasaka TM, Lehigh BM, et al. Adjuvant therapy and prognosticators of survival in head and neck mucosal melanoma. *Laryngoscope*. 2022;132(3):584-592. <https://doi.org/10.1002/lary.29807>
1566. Medina JE, Ferlito A, Pellitteri PK, et al. Current management of mucosal melanoma of the head and neck. *J Surg Oncol*. 2003;83(2):116-122. <https://doi.org/10.1002/jso.10247>
1567. Manolidis S, Donald PJ. Malignant mucosal melanoma of the head and neck: review of the literature and report of 14 patients. *Cancer*. 1997;80(8):1373-1386. <https://doi.org/10.1002/%28SICI%291097-0142%2819971015%2980:8%3C1373::AID-CNCR3%3E3.0.CO;2-G>
1568. Amit M, Tam S, Abdelmeguid AS, et al. Approaches to regional lymph node metastasis in patients with head and neck mucosal melanoma. *Cancer*. 2018;124(3):514-520. <https://doi.org/10.1002/cncr.31083>
1569. Baptista P, Garcia Velloso MJ, Salvinelli F, Casale M. Radio-guided surgical strategy in mucosal melanoma of the nasal cavity. *Clin Nucl Med*. 2008;33(1):14-18. <https://doi.org/10.1097/RLU.0b013e31815c5092>
1570. Starek I, Koranda P, Benes P. Sentinel lymph node biopsy: a new perspective in head and neck mucosal melanoma? *Melanoma Res*. 2006;16(5):423-427. <https://doi.org/10.1097/01.cmr.0000222603.57932.b6>
1571. Oldenburg MS, Price DL. The utility of sentinel node biopsy for sinonasal melanoma. *J Neurol Surg B Skull Base*. 2017;78(5):425-429. <https://doi.org/10.1055/s-0037-1603960>

1572. Amit M, Tam S, Abdelmeguid AS, et al. Role of adjuvant treatment in sinonasal mucosal melanoma. *J Neurol Surg B Skull Base*. 2017;78(6):512-518. <https://doi.org/10.1055/s-0037-1604350>
1573. Grant-Freemantle MC, Lane O'Neill B, Clover AJP. The effectiveness of radiotherapy in the treatment of head and neck mucosal melanoma: systematic review and meta-analysis. *Head Neck*. 2021;43(1):323-333. <https://doi.org/10.1002/hed.26470>
1574. Konuthula N, Parasher A, Del Signore A, Illoreta AM, Khan M. Role of adjuvant radiation in treatment of sinonasal mucosal melanoma. *Otolaryngol Head Neck Surg*. 2016;155(Suppl. 1):P80. <https://doi.org/10.1177/0194599816655336d>
1575. Arturo J, Caudell J, Frakes J, McMullen CP. Elective neck management in head and neck mucosal melanoma. *Otolaryngol Head Neck Surg*. 2019;161(2, Suppl.):P240. <https://doi.org/10.1177/0194599819858142>
1576. Manton T, Tillman B, McHugh J, Bellile E, McLean S, McKean E. Sinonasal melanoma: a single institutional analysis and future directions. *J Neurol Surg B Skull Base*. 2019;80(5):484-492. <https://doi.org/10.1055/s-0038-1676355>
1577. Lee SP, Shimizu KT, Tran LM, Juillard G, Calcaterra TC. Mucosal melanoma of the head and neck: the impact of local control on survival. *Laryngoscope*. 1994;104(2):121-126. <https://doi.org/10.1288/00005537-199402000-00001>
1578. Samstein R, Barker CA, Carvajal RD, et al. Localized sinonasal mucosal melanoma: outcomes and associations with stage, radiation therapy, and positron emission tomography response. *Int J Radiat Oncol Biol Phys*. 2016;94(4):949.
1579. Samstein RM, Carvajal RD, Postow MA, et al. Localized sinonasal mucosal melanoma: outcomes and associations with stage, radiotherapy, and positron emission tomography response. *Head Neck*. 2016;38(9):1310-1317. <https://doi.org/10.1002/hed.24435>
1580. Zenda S, Akimoto T, Mizumoto M, et al. Multicenter phase 2 study of proton beam therapy as a nonsurgical approach for mucosal melanoma of the nasal cavity or paranasal sinuses. *Int J Radiat Oncol Biol Phys*. 2015;93(3):S212.
1581. Zenda S, Kawashima M, Nishio T, et al. Proton beam therapy as a nonsurgical approach to mucosal melanoma of the head and neck: a pilot study. *Int J Radiat Oncol Biol Phys*. 2011;81(1):135-139. <https://doi.org/10.1016/j.ijrobp.2010.04.071>
1582. Umeda Y, Yoshikawa S, Kiniwa Y, et al. Real-world efficacy of anti-PD-1 antibody or combined anti-PD-1 plus anti-CTLA-4 antibodies, with or without radiotherapy, in advanced mucosal melanoma patients: a retrospective, multicenter study. *Eur J Cancer*. 2021;157:361-372. <https://doi.org/10.1016/j.ejca.2021.08.034>
1583. Dréno M, Georges M, Espitalier F, et al. Sinonasal mucosal melanoma: a 44-case study and literature analysis. *Eur Ann Otorhinolaryngol Head Neck Dis*. 2017;134(4):237-242. <https://doi.org/10.1016/j.anorl.2017.02.003>
1584. Liu HQ, Zou BQ, Wang SY. Expression and prognostic values of PD-1, PD-L1 and IDO-1 in sinonasal malignant mucosal melanoma. *Zhonghua Bing Li Xue Za Zhi*. 2017;46(11):782-788. <https://doi.org/10.3760/cma.j.issn.0529-5807.2017.11.009>
1585. Thierauf J, Veit JA, Affolter A, et al. Identification and clinical relevance of PD-L1 expression in primary mucosal malignant melanoma of the head and neck. *Melanoma Res*. 2015;25(6):503-509. <https://doi.org/10.1097/CMR.0000000000000197>
1586. Zenda S, Akimoto T, Mizumoto M, et al. Phase II study of proton beam therapy as a nonsurgical approach for mucosal melanoma of the nasal cavity or para-nasal sinuses. *Radiother Oncol*. 2016;118(2):267-271. <https://doi.org/10.1016/j.radonc.2015.10.025>
1587. Siak PY, Khoo AS, Leong CO, Hoh BP, Cheah SC. Current status and future perspectives about molecular biomarkers of nasopharyngeal carcinoma. *Cancers*. 2021;13(14):3490. <https://doi.org/10.3390/cancers13143490>
1588. Chang ET, Adami HO. The enigmatic epidemiology of nasopharyngeal carcinoma. *Cancer Epidemiol Biomarkers Prev*. 2006;15(10):1765-1777. <https://doi.org/10.1158/1055-9965.EPI-06-0353>
1589. Petersson F. Nasopharyngeal carcinoma: a review. *Semin Diagn Pathol*. 2015;32(1):54-73. <https://doi.org/10.1053/j.semdp.2015.02.021>
1590. Wong KCW, Hui EP, Lo KW, et al. Nasopharyngeal carcinoma: an evolving paradigm. *Nat Rev Clin Oncol*. 2021;18(11):679-695. <https://doi.org/10.1038/s41571-021-00524-x>
1591. Raab-Traub N. Epstein-Barr virus in the pathogenesis of NPC. *Semin Cancer Biol*. 2002;12(6):431-441. <https://doi.org/10.1016/s1044579x0200086x>
1592. Punwaney R, Brandwein MS, Zhang DY, et al. Human papillomavirus may be common within nasopharyngeal carcinoma of Caucasian Americans: investigation of Epstein-Barr virus and human papillomavirus in eastern and western nasopharyngeal carcinoma using ligation-dependent polymerase chain reaction. *Head Neck*. 1999;21(1):21-29. [https://doi.org/10.1002/\(sici\)1097-0347\(199901\)21:1<21::aid-hed3>3.0.co;2-z](https://doi.org/10.1002/(sici)1097-0347(199901)21:1<21::aid-hed3>3.0.co;2-z)
1593. Pan XX, Liu YJ, Yang W, Chen YF, Tang WB, Li CR. Histological subtype remains a prognostic factor for survival in nasopharyngeal carcinoma patients. *Laryngoscope*. 2020;130(3):E83-E88. <https://doi.org/10.1002/lary.28099>
1594. Wu SG, Lian CL, Wang J, et al. The effect of histological subtypes on survival outcome in nasopharyngeal carcinoma after extensive follow up. *Ann Transl Med*. 2019;7(23):768. <https://doi.org/10.21037/atm.2019.11.75>
1595. Guo R, Wu H, Wang J, et al. Lymph node status and outcomes for nasopharyngeal carcinoma according to histological subtypes: a SEER population-based retrospective analysis. *Adv Ther*. 2019;36(11):3123-3133. <https://doi.org/10.1007/s12325-019-01100-7>
1596. Argirion I, Zarins KR, Suwanrungruang K, et al. Subtype specific nasopharyngeal carcinoma incidence and survival trends: differences between endemic and non-endemic populations. *Asian Pac J Cancer Prev*. 2020;21(11):3291-3299. <https://doi.org/10.31557/apjcp.2020.21.11.3291>
1597. Colaco RJ, Betts G, Donne A, et al. Nasopharyngeal carcinoma: a retrospective review of demographics, treatment and patient outcome in a single centre. *Clin Oncol*. 2013;25(3):171-177. <https://doi.org/10.1016/j.clon.2012.10.006>
1598. Vazquez A, Khan MN, Govindaraj S, Baredes S, Eloy JA. Nasopharyngeal squamous cell carcinoma: a comparative analysis of keratinizing and nonkeratinizing subtypes. *Int*

- Forum Allergy Rhinol.* 2014;4(8):675-683. <https://doi.org/10.1002/alr.21332>
1599. Pathmanathan R, Prasad U, Chandrika G, Sadler R, Flynn K, Raab-Traub N. Undifferentiated, nonkeratinizing, and squamous cell carcinoma of the nasopharynx. Variants of Epstein-Barr virus-infected neoplasia. *Am J Pathol.* 1995;146(6):1355-1367.
 1600. Murono S, Yoshizaki T, Tanaka S, Takeshita H, Park CS, Furukawa M. Detection of Epstein-Barr virus in nasopharyngeal carcinoma by in situ hybridization and polymerase chain reaction. *Laryngoscope.* 1997;107(4):523-526. <https://doi.org/10.1097/00005537-199704000-00017>
 1601. Zhao LN, Zhou B, Shi M, et al. Clinical outcome for nasopharyngeal carcinoma with predominantly WHO II histology treated with intensity-modulated radiation therapy in non-endemic region of China. *Oral Oncol.* 2012;48(9):864-869. <https://doi.org/10.1016/j.oraloncology.2012.03.001>
 1602. Cheung F, Chan O, Ng WT, Chan L, Lee A, Pang SW. The prognostic value of histological typing in nasopharyngeal carcinoma. *Oral Oncol.* 2012;48(5):429-433. <https://doi.org/10.1016/j.oraloncology.2011.11.017>
 1603. Zang J, Li C, Zhao LN, et al. Prognostic model of death and distant metastasis for nasopharyngeal carcinoma patients receiving 3DCRT/IMRT in nonendemic area of China. *Medicine.* 2016;95(21):e3794. <https://doi.org/10.1097/md.0000000000003794>
 1604. Ruuskanen M, Grenman R, Leivo I, et al. Outcome of nasopharyngeal carcinoma in Finland: a nationwide study. *Acta Oncol.* 2018;57(2):251-256. <https://doi.org/10.1080/0284186x.2017.1346378>
 1605. Argirion I, Zarins KR, Ruterbusch JJ, et al. Increasing incidence of Epstein-Barr virus-related nasopharyngeal carcinoma in the United States. *Cancer.* 2020;126(1):121-130. <https://doi.org/10.1002/cncr.32517>
 1606. Wan SK, Chan JK, Lau WH, Yip TT. Basaloid-squamous carcinoma of the nasopharynx. An Epstein-Barr virus-associated neoplasm compared with morphologically identical tumors occurring in other sites. *Cancer.* 1995;76(10):1689-1693. [https://doi.org/10.1002/1097-0142\(19951115\)76:10<1689::aid-cncr2820761003>3.0.co;2-9](https://doi.org/10.1002/1097-0142(19951115)76:10<1689::aid-cncr2820761003>3.0.co;2-9)
 1607. Unsal AA, Booth JR, Rossi NA, Byrd JK, Kountakis SE. Basaloid nasopharyngeal carcinoma: a population-based analysis of a rare tumor. *Laryngoscope.* 2019;129(12):2727-2732. <https://doi.org/10.1002/lary.27788>
 1608. Henle W, Henle G, Ho HC, et al. Antibodies to Epstein-Barr virus in nasopharyngeal carcinoma, other head and neck neoplasms, and control groups. *J Natl Cancer Inst.* 1970;44(1):225-231.
 1609. Henle G, Henle W. Epstein-Barr virus-specific IgA serum antibodies as an outstanding feature of nasopharyngeal carcinoma. *Int J Cancer.* 1976;17(1):1-7. <https://doi.org/10.1002/ijc.29101070102>
 1610. Ho HC, Ng MH, Kwan HC, Chau JC. Epstein-Barr-virus-specific IgA and IgG serum antibodies in nasopharyngeal carcinoma. *Br J Cancer.* 1976;34(6):655-660. <https://doi.org/10.1038/bjc.1976.228>
 1611. Neel HB, Pearson GR, Taylor WF. Antibodies to Epstein-Barr virus in patients with nasopharyngeal carcinoma and in comparison groups. *Ann Otol Rhinol Laryngol.* 1984;93(5 Pt 1):477-482. <https://doi.org/10.1177/000348948409300513>
 1612. Shao JY, Li YH, Gao HY, et al. Comparison of plasma Epstein-Barr virus (EBV) DNA levels and serum EBV immunoglobulin A/virus capsid antigen antibody titers in patients with nasopharyngeal carcinoma. *Cancer.* 2004;100(6):1162-1170. <https://doi.org/10.1002/cncr.20099>
 1613. Fan H, Nicholls J, Chua D, et al. Laboratory markers of tumor burden in nasopharyngeal carcinoma: a comparison of viral load and serologic tests for Epstein-Barr virus. *Int J Cancer.* 2004;112(6):1036-1041. <https://doi.org/10.1002/ijc.20520>
 1614. Twu CW, Wang WY, Liang WM, et al. Comparison of the prognostic impact of serum anti-EBV antibody and plasma EBV DNA assays in nasopharyngeal carcinoma. *Int J Radiat Oncol Biol Phys.* 2007;67(1):130-137. <https://doi.org/10.1016/j.ijrobp.2006.07.012>
 1615. Lo YM, Chan LY, Lo KW, et al. Quantitative analysis of cell-free Epstein-Barr virus DNA in plasma of patients with nasopharyngeal carcinoma. *Cancer Res.* 1999;59(6):1188-1191.
 1616. Lo YM, Chan LY, Chan AT, et al. Quantitative and temporal correlation between circulating cell-free Epstein-Barr virus DNA and tumor recurrence in nasopharyngeal carcinoma. *Cancer Res.* 1999;59(21):5452-5455.
 1617. Lo YM, Leung SF, Chan LY, et al. Kinetics of plasma Epstein-Barr virus DNA during radiation therapy for nasopharyngeal carcinoma. *Cancer Res.* 2000;60(9):2351-2355.
 1618. Lo YM, Chan AT, Chan LY, et al. Molecular prognostication of nasopharyngeal carcinoma by quantitative analysis of circulating Epstein-Barr virus DNA. *Cancer Res.* 2000;60(24):6878-6881.
 1619. Chan AT, Lo YM, Zee B, et al. Plasma Epstein-Barr virus DNA and residual disease after radiotherapy for undifferentiated nasopharyngeal carcinoma. *J Natl Cancer Inst.* 2002;94(21):1614-1619. <https://doi.org/10.1093/jnci/94.21.1614>
 1620. Chan KC, Zhang J, Chan AT, et al. Molecular characterization of circulating EBV DNA in the plasma of nasopharyngeal carcinoma and lymphoma patients. *Cancer Res.* 2003;63(9):2028-2032.
 1621. Leung SF, Chan AT, Zee B, et al. Pretherapy quantitative measurement of circulating Epstein-Barr virus DNA is predictive of posttherapy distant failure in patients with early-stage nasopharyngeal carcinoma of undifferentiated type. *Cancer.* 2003;98(2):288-291. <https://doi.org/10.1002/cncr.11496>
 1622. Lin JC, Wang WY, Chen KY, et al. Quantification of plasma Epstein-Barr virus DNA in patients with advanced nasopharyngeal carcinoma. *N Engl J Med.* 2004;350(24):2461-2470. <https://doi.org/10.1056/NEJMoa032260>
 1623. Ma BB, King A, Lo YM, et al. Relationship between pretreatment level of plasma Epstein-Barr virus DNA, tumor burden, and metabolic activity in advanced nasopharyngeal carcinoma. *Int J Radiat Oncol Biol Phys.* 2006;66(3):714-720. <https://doi.org/10.1016/j.ijrobp.2006.05.064>
 1624. Liu Y, Fang Z, Liu L, Yang S, Zhang L. Detection of Epstein-Barr virus DNA in serum or plasma for nasopharyngeal cancer: a meta-analysis. *Genet Test Mol Biomarkers.* 2011;15(7-8):495-502. <https://doi.org/10.1089/gtmb.2011.0012>
 1625. Han BL, Xu XY, Zhang CZ, et al. Systematic review on Epstein-Barr virus (EBV) DNA in diagnosis of nasopharyn-

- geal carcinoma in Asian populations. *Asian Pac J Cancer Prev*. 2012;13(6):2577-2581. <https://doi.org/10.7314/apjcp.2012.13.6.2577>
1626. Song C, Yang S. A meta-analysis on the EBV DNA and VCA-IgA in diagnosis of Nasopharyngeal Carcinoma. *Pak J Med Sci*. 2013;29(3):885-890. <https://doi.org/10.12669/pjms.293.2907>
1627. Sun D, Yang Z, Fu Y, et al. Clinical value of serum Epstein-Barr virus DNA assay in the diagnosis of nasopharyngeal carcinoma. *Tumour Biol*. 2014;35(9):8787-8793. <https://doi.org/10.1007/s13277-014-2148-x>
1628. Liu W, Chen G, Gong X, et al. The diagnostic value of EBV-DNA and EBV-related antibodies detection for nasopharyngeal carcinoma: a meta-analysis. *Cancer Cell Int*. 2021;21(1):164. <https://doi.org/10.1186/s12935-021-01862-7>
1629. Zhang W, Chen Y, Chen L, et al. The clinical utility of plasma Epstein-Barr virus DNA assays in nasopharyngeal carcinoma: the dawn of a new era? A systematic review and meta-analysis of 7836 cases. *Medicine*. 2015;94(20):e845. <https://doi.org/10.1097/md.0000000000000845>
1630. Zhang J, Shu C, Song Y, Li Q, Huang J, Ma X. Epstein-Barr virus DNA level as a novel prognostic factor in nasopharyngeal carcinoma: a meta-analysis. *Medicine*. 2016;95(40):e5130. <https://doi.org/10.1097/md.00000000000005130>
1631. Liu TB, Zheng ZH, Pan J, Pan LL, Chen LH. Prognostic role of plasma Epstein-Barr virus DNA load for nasopharyngeal carcinoma: a meta-analysis. *Clin Invest Med*. 2017;40(1):E1-E12. <https://doi.org/10.25011/cim.v40i1.28049>
1632. Xie X, Ren Y, Wang K, Yi B. Molecular prognostic value of circulating Epstein-Barr viral DNA in nasopharyngeal carcinoma: a meta-analysis of 27,235 cases in the endemic area of Southeast Asia. *Genet Test Mol Biomarkers*. 2019;23(7):448-459. <https://doi.org/10.1089/gtmb.2018.0304>
1633. Qu H, Huang Y, Zhao S, Zhou Y, Lv W. Prognostic value of Epstein-Barr virus DNA level for nasopharyngeal carcinoma: a meta-analysis of 8128 cases. *Eur Arch Otorhinolaryngol*. 2020;277(1):9-18. <https://doi.org/10.1007/s00405-019-05699-9>
1634. Leung SF, Zee B, Ma BB, et al. Plasma Epstein-Barr viral deoxyribonucleic acid quantitation complements tumor-node-metastasis staging prognostication in nasopharyngeal carcinoma. *J Clin Oncol*. 2006;24(34):5414-5418. <https://doi.org/10.1200/jco.2006.07.7982>
1635. Zhang L, Tang LQ, Chen QY, et al. Plasma Epstein-Barr viral DNA complements TNM classification of nasopharyngeal carcinoma in the era of intensity-modulated radiotherapy. *Oncotarget*. 2016;7(5):6221-6230. <https://doi.org/10.18632/oncotarget.6754>
1636. Guo R, Tang LL, Mao YP, et al. Proposed modifications and incorporation of plasma Epstein-Barr virus DNA improve the TNM staging system for Epstein-Barr virus-related nasopharyngeal carcinoma. *Cancer*. 2019;125(1):79-89. <https://doi.org/10.1002/cncr.31741>
1637. Lee VH, Kwong DL, Leung TW, et al. The addition of pretreatment plasma Epstein-Barr virus DNA into the eighth edition of nasopharyngeal cancer TNM stage classification. *Int J Cancer*. 2019;144(7):1713-1722. <https://doi.org/10.1002/ijc.31856>
1638. Kitpanit S, Jittapiromsak N, Sriyook A, et al. Comparison between the seventh and eighth edition of the AJCC/UICC staging system for nasopharyngeal cancer integrated with pretreatment plasma Epstein-Barr virus DNA level in a non-Chinese population: secondary analysis from a prospective randomized trial. *Jpn J Clin Oncol*. 2019;49(12):1100-1113. <https://doi.org/10.1093/jjco/hyz109>
1639. Hui EP, Li WF, Ma BB, et al. Integrating postradiotherapy plasma Epstein-Barr virus DNA and TNM stage for risk stratification of nasopharyngeal carcinoma to adjuvant therapy. *Ann Oncol*. 2020;31(6):769-779. <https://doi.org/10.1016/j.annonc.2020.03.289>
1640. Li WZ, Wu HJ, Lv SH, et al. Assessment of survival model performance following inclusion of Epstein-Barr virus DNA status in conventional TNM staging groups in Epstein-Barr virus-related nasopharyngeal carcinoma. *JAMA Netw Open*. 2021;4(9):e2124721. <https://doi.org/10.1001/jamanetworkopen.2021.24721>
1641. Twu CW, Wang WY, Chen CC, et al. Metronomic adjuvant chemotherapy improves treatment outcome in nasopharyngeal carcinoma patients with postradiation persistently detectable plasma Epstein-Barr virus deoxyribonucleic acid. *Int J Radiat Oncol Biol Phys*. 2014;89(1):21-29. <https://doi.org/10.1016/j.ijrobp.2014.01.052>
1642. Chan ATC, Hui EP, Ngan RKC, et al. Analysis of plasma Epstein-Barr virus DNA in nasopharyngeal cancer after chemoradiation to identify high-risk patients for adjuvant chemotherapy: a randomized controlled trial. *J Clin Oncol*. 2018;36(31):3091-3100. <https://doi.org/10.1200/jco.2018.77.7847>
1643. Wang WY, Twu CW, Chen HH, et al. Plasma EBV DNA clearance rate as a novel prognostic marker for metastatic/recurrent nasopharyngeal carcinoma. *Clin Cancer Res*. 2010;16(3):1016-1024. <https://doi.org/10.1158/1078-0432.Ccr-09-2796>
1644. Hsu CL, Chang KP, Lin CY, et al. Plasma Epstein-Barr virus DNA concentration and clearance rate as novel prognostic factors for metastatic nasopharyngeal carcinoma. *Head Neck*. 2012;34(8):1064-1070. <https://doi.org/10.1002/hed.21890>
1645. Ma B, Hui EP, King A, et al. Prospective evaluation of plasma Epstein-Barr virus DNA clearance and fluorodeoxyglucose positron emission scan in assessing early response to chemotherapy in patients with advanced or recurrent nasopharyngeal carcinoma. *Br J Cancer*. 2018;118(8):1051-1055. <https://doi.org/10.1038/s41416-018-0026-9>
1646. Chan KCA, Woo JKS, King A, et al. Analysis of plasma Epstein-Barr virus DNA to screen for nasopharyngeal cancer. *N Engl J Med*. 2017;377(6):513-522. <https://doi.org/10.1056/NEJMoa1701717>
1647. Lam WKJ, Jiang P, Chan KCA, et al. Sequencing-based counting and size profiling of plasma Epstein-Barr virus DNA enhance population screening of nasopharyngeal carcinoma. *Proc Natl Acad Sci USA*. 2018;115(22):E5115-E5124. <https://doi.org/10.1073/pnas.1804184115>
1648. Lam WKJ, Jiang P, Chan KCA, et al. Methylation analysis of plasma DNA informs etiologies of Epstein-Barr virus-associated diseases. *Nat Commun*. 2019;10(1):3256. <https://doi.org/10.1038/s41467-019-11226-5>
1649. Wu Q, Wang M, Liu Y, et al. HPV positive status is a favorable prognostic factor in non-nasopharyngeal head and neck squamous cell carcinoma patients: a retrospective study from the surveillance, epidemiology, and end results database.

- Front Oncol.* 2021;11:688615. <https://doi.org/10.3389/fonc.2021.688615>
1650. Verma V, Simone CB, Lin C. Human papillomavirus and nasopharyngeal cancer. *Head Neck.* 2018;40(4):696-706. <https://doi.org/10.1002/hed.24978>
1651. Huang SH, Jacinto JCK, O'Sullivan B, et al. Clinical presentation and outcome of human papillomavirus-positive nasopharyngeal carcinoma in a North American cohort. *Cancer.* 2022;128(15):2908-2921. <https://doi.org/10.1002/cncr.34266>
1652. Wu SS, Chen B, Fleming CW, et al. Nasopharyngeal cancer: incidence and prognosis of human papillomavirus and Epstein-Barr virus association at a single North American institution. *Head Neck.* 2022;44(4):851-861. <https://doi.org/10.1002/hed.26976>
1653. Simon J, Schroeder L, Ingarfield K, et al. Epstein-Barr virus and human papillomavirus serum antibodies define the viral status of nasopharyngeal carcinoma in a low endemic country. *Int J Cancer.* 2020;147(2):461-471. <https://doi.org/10.1002/ijc.33006>
1654. Verma N, Patel S, Osborn V, et al. Prognostic significance of human papillomavirus and Epstein-Bar virus in nasopharyngeal carcinoma. *Head Neck.* 2020;42(9):2364-2374. <https://doi.org/10.1002/hed.26245>
1655. Wotman M, Oh EJ, Ahn S, Kraus D, Costantino P, Tham T. HPV status in patients with nasopharyngeal carcinoma in the United States: a SEER database study. *Am J Otolaryngol.* 2019;40(5):705-710. <https://doi.org/10.1016/j.amjoto.2019.06.007>
1656. Huang CC, Hsiao JR, Yang MW, et al. Human papilloma virus detection in neoplastic and non-neoplastic nasopharyngeal tissues in Taiwan. *J Clin Pathol.* 2011;64(7):571-577. <https://doi.org/10.1136/jcp.2010.087742>
1657. Huang WB, Chan JYW, Liu DL. Human papillomavirus and World Health Organization type III nasopharyngeal carcinoma: multicenter study from an endemic area in Southern China. *Cancer.* 2018;124(3):530-536. <https://doi.org/10.1002/cncr.31031>
1658. Blanchard P, Lee A, Marguet S, et al. Chemotherapy and radiotherapy in nasopharyngeal carcinoma: an update of the MAC-NPC meta-analysis. *Lancet Oncol.* 2015;16(6):645-655. [https://doi.org/10.1016/s1470-2045\(15\)70126-9](https://doi.org/10.1016/s1470-2045(15)70126-9)
1659. Wei WI, Lam KH, Sham JS. New approach to the nasopharynx: the maxillary swing approach. *Head Neck.* 1991;13(3):200-207. <https://doi.org/10.1002/hed.2880130306>
1660. Tu GY, Hu YH, Xu GZ, Ye M. Salvage surgery for nasopharyngeal carcinoma. *Arch Otolaryngol Head Neck Surg.* 1988;114(3):328-329. <https://doi.org/10.1001/archotol.1988.01860150110026>
1661. Morton RP, Liavaag PG, McLean M, Freeman JL. Transcervico-mandibulo-palatal approach for surgical salvage of recurrent nasopharyngeal cancer. *Head Neck.* 1996;18(4):352-358. [https://doi.org/10.1002/\(sici\)1097-0347\(199607/08\)18:4<352::Aid-hed7>3.0.Co;2-x](https://doi.org/10.1002/(sici)1097-0347(199607/08)18:4<352::Aid-hed7>3.0.Co;2-x)
1662. Wang WH, Yeh CF, Lan MY. The role of nasopharyngectomy in the management of nasopharyngeal carcinoma. *Curr Opin Otolaryngol Head Neck Surg.* 2022;30(1):3-12. <https://doi.org/10.1097/moo.0000000000000780>
1663. Yoshizaki T, Wakisaka N, Murono S, Shimizu Y, Furukawa M. Endoscopic nasopharyngectomy for patients with recurrent nasopharyngeal carcinoma at the primary site. *Laryngoscope.* 2005;115(8):1517-1519. <https://doi.org/10.1097/01.Mlg.0000165383.35100.17>
1664. Castelnovo P, Nicolai P, Turri-Zanoni M, et al. Endoscopic endonasal nasopharyngectomy in selected cancers. *Otolaryngol Head Neck Surg.* 2013;149(3):424-430. <https://doi.org/10.1177/0194599813493073>
1665. Liu Q, Sun X, Li H, et al. Types of transnasal endoscopic nasopharyngectomy for recurrent nasopharyngeal carcinoma: Shanghai EENT hospital experience. *Front Oncol.* 2020;10:555862. <https://doi.org/10.3389/fonc.2020.555862>
1666. Zou X, Han F, Ma WJ, et al. Salvage endoscopic nasopharyngectomy and intensity-modulated radiotherapy versus conventional radiotherapy in treating locally recurrent nasopharyngeal carcinoma. *Head Neck.* 2015;37(8):1108-1115. <https://doi.org/10.1002/hed.23719>
1667. Yang J, Song X, Sun X, et al. Outcomes of recurrent nasopharyngeal carcinoma patients treated with endoscopic nasopharyngectomy: a meta-analysis. *Int Forum Allergy Rhinol.* 2020;10(8):1001-1011. <https://doi.org/10.1002/alr.22552>
1668. Liu YP, Wen YH, Tang J, et al. Endoscopic surgery compared with intensity-modulated radiotherapy in resectable locally recurrent nasopharyngeal carcinoma: a multicentre, open-label, randomised, controlled, phase 3 trial. *Lancet Oncol.* 2021;22(3):381-390. [https://doi.org/10.1016/s1470-2045\(20\)30673-2](https://doi.org/10.1016/s1470-2045(20)30673-2)
1669. Eberhard TP, Leaming RH. Treatment of carcinoma of the nasopharynx by irradiation. *Radiology.* 1950;55(1):46-51. <https://doi.org/10.1148/55.1.46>
1670. Peng G, Wang T, Yang KY, et al. A prospective, randomized study comparing outcomes and toxicities of intensity-modulated radiotherapy vs. conventional two-dimensional radiotherapy for the treatment of nasopharyngeal carcinoma. *Radiation Oncol.* 2012;104(3):286-293. <https://doi.org/10.1016/j.radonc.2012.08.013>
1671. Co J, Mejia MB, Dizon JM. Evidence on effectiveness of intensity-modulated radiotherapy versus 2-dimensional radiotherapy in the treatment of nasopharyngeal carcinoma: meta-analysis and a systematic review of the literature. *Head Neck.* 2016;38(Suppl 1):E2130-E2142. <https://doi.org/10.1002/hed.23977>
1672. Du T, Xiao J, Qiu Z, Wu K. The effectiveness of intensity-modulated radiation therapy versus 2D-RT for the treatment of nasopharyngeal carcinoma: a systematic review and meta-analysis. *PLoS ONE.* 2019;14(7):e0219611. <https://doi.org/10.1371/journal.pone.0219611>
1673. Huang CL, Xu C, Zhang Y, et al. Feasibility of ipsilateral lower neck sparing irradiation for unilateral or bilateral neck node-negative nasopharyngeal carcinoma: systemic review and meta-analysis of 2,521 patients. *Radiat Oncol.* 2018;13(1):141. <https://doi.org/10.1186/s13014-018-1087-x>
1674. Tang LL, Huang CL, Zhang N, et al. Elective upper-neck versus whole-neck irradiation of the uninvolved neck in patients with nasopharyngeal carcinoma: an open-label, non-inferiority, multicentre, randomised phase 3 trial. *Lancet Oncol.* 2022;23(4):479-490. [https://doi.org/10.1016/S1470-2045\(22\)00058-4](https://doi.org/10.1016/S1470-2045(22)00058-4)
1675. Figen M, Colpan Oksuz D, Duman E, et al. Radiotherapy for head and neck cancer: evaluation of triggered adaptive replan-

- ning in routine practice. *Front Oncol.* 2020;10(579917):579917. <https://doi.org/10.3389/fonc.2020.579917>
1676. Lertbutsayanukul C, Prayongrat A, Kannarunimit D, Chakkabat C, Netsawang B, Kitpanit S. A randomized phase III study between sequential versus simultaneous integrated boost intensity-modulated radiation therapy in nasopharyngeal carcinoma. *Strahlenther Onkol.* 2018;194(5):375-385. <https://doi.org/10.1007/s00066-017-1251-5>
 1677. Nishimura Y, Ishikura S, Shibata T. A phase II study of adaptive two-step intensity-modulated radiation therapy (IMRT) with chemotherapy for loco-regionally advanced nasopharyngeal cancer. *Int J Clin Oncol.* 2020;25(7):1250-1259.
 1678. Lee A, Kitpanit S, Chilov M, Langendijk JA, Lu J, Lee NY. A systematic review of proton therapy for the management of nasopharyngeal cancer. *Int J Part Ther.* 2021;8(1):119-130. <https://doi.org/10.14338/IJPT-20-00082.1>
 1679. Al-Sarraf M, LeBlanc M, Giri PG, et al. Chemoradiotherapy versus radiotherapy in patients with advanced nasopharyngeal cancer: phase III randomized Intergroup study 0099. *J Clin Oncol.* 1998;16(4):1310-1317. <https://doi.org/10.1200/JCO.1998.16.4.1310>
 1680. Chen QY, Wen YF, Guo L, et al. Concurrent chemoradiotherapy vs radiotherapy alone in stage II nasopharyngeal carcinoma: phase III randomized trial. *J Natl Cancer Inst.* 2011;103(23):1761-1770. <https://doi.org/10.1093/jnci/djr432>
 1681. Li XY, Chen QY, Sun XS, et al. Ten-year outcomes of survival and toxicity for a phase III randomised trial of concurrent chemoradiotherapy versus radiotherapy alone in stage II nasopharyngeal carcinoma. *Eur J Cancer.* 2019;110:24-31. <https://doi.org/10.1016/j.ejca.2018.10.020>
 1682. Liu F, Jin T, Liu L, Xiang Z, Yan R, Yang H. The role of concurrent chemotherapy for stage II nasopharyngeal carcinoma in the intensity-modulated radiotherapy era: a systematic review and meta-analysis. *PLoS One.* 2018;13(3):e0194733. <https://doi.org/10.1371/journal.pone.0194733>
 1683. Tang LL, Guo R, Zhang N, et al. Effect of radiotherapy alone vs radiotherapy with concurrent chemoradiotherapy on survival without disease relapse in patients with low-risk nasopharyngeal carcinoma a randomized clinical trial. *JAMA-J Am Med Assoc.* 2022;328(8):728-736. <https://doi.org/10.1001/jama.2022.13997>
 1684. Tang J, Zou GR, Li XW, Su Z, Cao XL, Wang BC. Weekly versus triweekly cisplatin-based concurrent chemoradiotherapy for nasopharyngeal carcinoma: a systematic review and pooled analysis. *J Cancer.* 2021;12(20):6209-6215. <https://doi.org/10.7150/jca.62188>
 1685. You R, Sun R, Hua YJ, et al. Cetuximab or nimotuzumab plus intensity-modulated radiotherapy versus cisplatin plus intensity-modulated radiotherapy for stage II-IVb nasopharyngeal carcinoma. *Int J Cancer.* 2017;141(6):1265-1276. <https://doi.org/10.1002/ijc.30819>
 1686. Yuan C, Xu XH, Chen Z. Combination treatment with antiEGFR monoclonal antibodies in advanced nasopharyngeal carcinoma: a meta-analysis. *J BUON.* 2015;20(6):1510-1517.
 1687. Sun Y, Li WF, Chen NY, et al. Induction chemotherapy plus concurrent chemoradiotherapy versus concurrent chemoradiotherapy alone in locoregionally advanced nasopharyngeal carcinoma: a phase 3, multicentre, randomised controlled trial. *Lancet Oncol.* 2016;17(11):1509-1520. [https://doi.org/10.1016/S1470-2045\(16\)30410-7](https://doi.org/10.1016/S1470-2045(16)30410-7)
 1688. Yang Q, Cao SM, Guo L, et al. Induction chemotherapy followed by concurrent chemoradiotherapy versus concurrent chemoradiotherapy alone in locoregionally advanced nasopharyngeal carcinoma: long-term results of a phase III multicentre randomised controlled trial. *Eur J Cancer.* 2019;119:87-96. <https://doi.org/10.1016/j.ejca.2019.07.007>
 1689. Hong RL, Hsiao CF, Ting LL, et al. Final results of a randomized phase III trial of induction chemotherapy followed by concurrent chemoradiotherapy versus concurrent chemoradiotherapy alone in patients with stage IVA and IVB nasopharyngeal carcinoma-Taiwan Cooperative Oncology Group (TCOG) 1303 Study. *Ann Oncol.* 2018;29(9):1972-1979. <https://doi.org/10.1093/annonc/mdy249>
 1690. Jin T, Qin WF, Jiang F, et al. Cisplatin and fluorouracil induction chemotherapy with or without docetaxel in locoregionally advanced nasopharyngeal carcinoma. *Transl Oncol.* 2019;12(4):633-639. <https://doi.org/10.1016/j.tranon.2019.01.002>
 1691. Zhang Y, Chen L, Hu GQ, et al. Gemcitabine and cisplatin induction chemotherapy in nasopharyngeal carcinoma. *N Engl J Med.* 2019;381(12):1124-1135. <https://doi.org/10.1056/NEJMoa1905287>
 1692. Liu T, Dai S, Zhang H, Zhong X, Ding Z, Ma X. The best choice of induction chemotherapy for patients with locally advanced nasopharyngeal carcinoma: Bayesian network meta-analysis. *Head Neck.* 2022;44(2):518-529. <https://doi.org/10.1002/hed.26932>
 1693. Yang Q, Xia L, Lin M, et al. The impact of induction chemotherapy on long-term quality of life in patients with locoregionally advanced nasopharyngeal carcinoma: outcomes from a randomised phase 3 trial. *Oral Oncol.* 2021;121(105494):105494. <https://doi.org/10.1016/j.oraloncology.2021.105494>
 1694. Chen L, Hu CS, Chen XZ, et al. Concurrent chemoradiotherapy plus adjuvant chemotherapy versus concurrent chemoradiotherapy alone in patients with locoregionally advanced nasopharyngeal carcinoma: a phase 3 multicentre randomised controlled trial. *Lancet Oncol.* 2012;13(2):163-171. [https://doi.org/10.1016/S1470-2045\(11\)70320-5](https://doi.org/10.1016/S1470-2045(11)70320-5)
 1695. Chen YP, Wang ZX, Chen L, et al. A Bayesian network meta-analysis comparing concurrent chemoradiotherapy followed by adjuvant chemotherapy, concurrent chemoradiotherapy alone and radiotherapy alone in patients with locoregionally advanced nasopharyngeal carcinoma. *Ann Oncol.* 2015;26(1):205-211. <https://doi.org/10.1093/annonc/mdu507>
 1696. Ribassin-Majed L, Marguet S, Lee AWM. What is the best treatment of locally advanced nasopharyngeal carcinoma? An individual patient data network meta-analysis. *J Clin Oncol.* 2017;35(5):498-505.
 1697. Yan M, Kumachev A, Siu LL, Chan KK. Chemoradiotherapy regimens for locoregionally advanced nasopharyngeal carcinoma: a Bayesian network meta-analysis. *Eur J Cancer.* 2015;51(12):1570-1579. <https://doi.org/10.1016/j.ejca.2015.04.027>
 1698. Chen YP, Liu X, Zhou Q, et al. Metronomic capecitabine as adjuvant therapy in locoregionally advanced nasopharyngeal carcinoma: a multicentre, open-label,

- parallel-group, randomised, controlled, phase 3 trial. *Lancet*. 2021;398(10297):303-313. [https://doi.org/10.1016/S0140-6736\(21\)01123-5](https://doi.org/10.1016/S0140-6736(21)01123-5)
1699. Colevas AD, Yom SS, Pfister DG, et al. NCCN guidelines insights: head and neck cancers, version 1.2018. *J Natl Compr Canc Netw*. 2018;16(5):479-490. <https://doi.org/10.6004/jnccn.2018.0026>
1700. Prawira A, Oosting SF, Chen TW, et al. Systemic therapies for recurrent or metastatic nasopharyngeal carcinoma: a systematic review. *Br J Cancer*. 2017;117(12):1743-1752. <https://doi.org/10.1038/bjc.2017.357>
1701. Ma SX, Zhou T, Huang Y, et al. The efficacy of first-line chemotherapy in recurrent or metastatic nasopharyngeal carcinoma: a systematic review and meta-analysis. *Ann Transl Med*. 2018;6(11):201. <https://doi.org/10.21037/atm.2018.05.14>
1702. Hong S, Zhang Y, Yu G. Gemcitabine plus cisplatin versus fluorouracil plus cisplatin as first-line therapy for recurrent or metastatic nasopharyngeal carcinoma: final overall survival analysis of GEM20110714 phase III study. *J Clin Oncol*. 2021;39(29):3273-3282.
1703. Yang H, Lu Y, Xu ZH, Wei MJ, Huang HX. Gemcitabine plus platinum versus docetaxel plus platinum as first-line therapy for metastatic nasopharyngeal carcinoma: a randomized clinical study. *Saudi J Med Med Sci*. 2021;9(2):125-134. https://doi.org/10.4103/sjmm.sjmm_471_20
1704. You R, Liu YP, Huang PY, et al. Efficacy and safety of locoregional radiotherapy with chemotherapy vs chemotherapy alone in de novo metastatic nasopharyngeal carcinoma: a multicenter phase 3 randomized clinical trial. *JAMA Oncol*. 2020;6(9):1345-1352. <https://doi.org/10.1001/jamaoncol.2020.1808>
1705. Wang G, Shen L. The efficacy of locoregional radiotherapy plus chemotherapy vs. chemotherapy alone in metastatic nasopharyngeal carcinoma: a meta-analysis. *Ann Palliat Med*. 2021;10(3):2584-2595. <https://doi.org/10.21037/apm-20-1561>
1706. Wang BC, Cao RB, Fu C, et al. The efficacy and safety of PD-1/PD-L1 inhibitors in patients with recurrent or metastatic nasopharyngeal carcinoma: a systematic review and meta-analysis. *Oral Oncol*. 2020;104(104640):104640. <https://doi.org/10.1016/j.oraloncology.2020.104640>
1707. Yang Y, Zhou T, Chen X, et al. Efficacy, safety, and biomarker analysis of Camrelizumab in Previously Treated Recurrent or Metastatic Nasopharyngeal Carcinoma (CAPTAIN study). *J Immunother Cancer*. 2021;9(12):e003790. <https://doi.org/10.1136/jitc-2021-003790>
1708. Ma BBY, Lim WT, Goh BC, et al. Antitumor activity of nivolumab in recurrent and metastatic nasopharyngeal carcinoma: an international, multicenter study of the Mayo Clinic phase 2 consortium (NCI-9742). *J Clin Oncol*. 2018;36(14):1412-1418. <https://doi.org/10.1200/JCO.2017.77.0388>
1709. Wang FH, Wei XL, Feng J, et al. Efficacy, safety, and correlative biomarkers of toripalimab in previously treated recurrent or metastatic nasopharyngeal carcinoma: a phase II clinical trial (POLARIS-02). *J Clin Oncol*. 2021;39(7):704-712. <https://doi.org/10.1200/JCO.20.02712>
1710. Chan ATC, Lee VHF, Hong RL, et al. Pembrolizumab monotherapy versus chemotherapy in platinum-pretreated, recurrent or metastatic nasopharyngeal cancer (KEYNOTE-122): an open-label, randomized, phase III trial. *Ann Oncol*. 2023;34(3):251-261. <https://doi.org/10.1016/j.annonc.2022.12.007>
1711. Fang W, Yang Y, Ma Y, et al. Camrelizumab (SHR-1210) alone or in combination with gemcitabine plus cisplatin for nasopharyngeal carcinoma: results from two single-arm, phase 1 trials. *Lancet Oncol*. 2018;19(10):1338-1350. [https://doi.org/10.1016/S1470-2045\(18\)30495-9](https://doi.org/10.1016/S1470-2045(18)30495-9)
1712. Lv JW, Li JY, Luo LN, Wang ZX, Chen YP. Comparative safety and efficacy of anti-PD-1 monotherapy, chemotherapy alone, and their combination therapy in advanced nasopharyngeal carcinoma: findings from recent advances in landmark trials. *J Immunother Cancer*. 2019;7(1):159. <https://doi.org/10.1186/s40425-019-0636-7>
1713. Mai HQ, Chen QY, Chen D. Toripalimab or placebo plus chemotherapy as first-line treatment in advanced nasopharyngeal carcinoma: a multicenter randomized phase 3 trial. *Nat Med*. 2021;27(9):1536-1543.
1714. Yang YP, Qu S, Li JA, et al. Camrelizumab versus placebo in combination with gemcitabine and cisplatin as first-line treatment for recurrent or metastatic nasopharyngeal carcinoma (CAPTAIN-1st): a multicentre, randomised, double-blind, phase 3 trial. *Lancet Oncol*. 2021;22(8):1162-1174. [https://doi.org/10.1016/S1470-2045\(21\)00302-8](https://doi.org/10.1016/S1470-2045(21)00302-8)
1715. Kuan EC, Alonso JE, Arshi A, St John MA. Nasopharyngeal adenocarcinoma: a population-based analysis. *Am J Otolaryngol*. 2017;38(3):297-300. <https://doi.org/10.1016/j.amjoto.2017.01.028>
1716. Wenig BM, Hyams VJ, Heffner DK. Nasopharyngeal papillary adenocarcinoma. A clinicopathologic study of a low-grade carcinoma. *Am J Surg Pathol*. 1988;12(12):946-953.
1717. Pineda-Daboin K, Neto A, Ochoa-Perez V, Luna MA. Nasopharyngeal adenocarcinomas: a clinicopathologic study of 44 cases including immunohistochemical features of 18 papillary phenotypes. *Ann Diagn Pathol*. 2006;10(4):215-221. <https://doi.org/10.1016/j.anndiagpath.2005.11.002>
1718. Carrizo F, Luna MA. Thyroid transcription factor-1 expression in thyroid-like nasopharyngeal papillary adenocarcinoma: report of 2 cases. *Ann Diagn Pathol*. 2005;9(4):189-192. <https://doi.org/10.1016/j.anndiagpath.2005.04.019>
1719. Li L, Zhou F, Lin F, Han C. Clinicopathologic characteristics of thyroid-like low-grade nasopharyngeal papillary adenocarcinoma: a case report. *Appl Immunohistochem Mol Morphol*. 2019;27(8):e81-e84. <https://doi.org/10.1097/PAI.0000000000000545>
1720. Wang X, Yan H, Luo Y, Fan T. Low-grade nasopharyngeal papillary adenocarcinoma: a case report and review of the literature. *Onco Targets Ther*. 2016;9:2955-2959. <https://doi.org/10.2147/OTT.S100447>
1721. Huang F, Xiang X, Hong B, Min J, Li J. Thyroid-like low-grade nasopharyngeal papillary adenocarcinoma: a clinicopathologic study of five cases and a literature review. *Am J Clin Pathol*. 2019;152(5):582-589. <https://doi.org/10.1093/ajcp/aqz082>
1722. Lai Y, Li W, Zhai C, et al. Low-grade nasopharyngeal papillary adenocarcinoma: a review of 28 patients in a single institution. *Cancer Manag Res*. 2021;13:1271-1278. <https://doi.org/10.2147/CMAR.S288007>
1723. Appukutty SJ, Di Palma S, Pitkin L, Smith CET. Thyroid-like low grade nasopharyngeal papillary

- adenocarcinoma presenting as snoring in a 49-year-old male. *Diagn Histopathol.* 2013;19(9):350-353. <https://doi.org/10.1016/j.mpdhp.2013.06.016>
1724. Wu PY, Huang CC, Chen HK, Chien CY. Adult thyroid-like low-grade nasopharyngeal papillary adenocarcinoma with thyroid transcription factor-1 expression. *Otolaryngol Head Neck Surg.* 2007;137(5):837-838. <https://doi.org/10.1016/j.otohns.2007.06.725>
1725. Fu CH, Chang KP, Ueng SH, Wu CC, Hao SP. Primary thyroid-like papillary adenocarcinoma of the nasopharynx. *Auris Nasus Larynx.* 2008;35(4):579-582. <https://doi.org/10.1016/j.anl.2007.10.009>
1726. Ohe C, Sakaida N, Tadokoro C, et al. Thyroid-like low-grade nasopharyngeal papillary adenocarcinoma: report of two cases. *Pathol Int.* 2010;60(2):107-111. <https://doi.org/10.1111/j.1440-1827.2009.02480.x>
1727. Sillings CN, Weathers DR, Delgaudio JM. Thyroid-like papillary adenocarcinoma of the nasopharynx: a case report in a 19-year-old male. *Oral Surg Oral Med Oral Pathol Oral Radiol Endod.* 2010;110(3):e25-e28. <https://doi.org/10.1016/j.tripleo.2010.04.029>
1728. Petersson F, Pang B, Loke D, Hao L, Yan B. Biphasic low-grade nasopharyngeal papillary adenocarcinoma with a prominent spindle cell component: report of a case localized to the posterior nasal septum. *Head Neck Pathol.* 2011;5(3):306-313. <https://doi.org/10.1007/s12105-011-0252-4>
1729. Guo ZM, Liu WW, He JH. A retrospective cohort study of nasopharyngeal adenocarcinoma: a rare histological type of nasopharyngeal cancer. *Clin Otolaryngol.* 2009;34(4):322-327. <https://doi.org/10.1111/j.1749-4486.2009.01952.x>
1730. Booth JR, Unsal AA, Tadros S, Byrd JK, Kountakis SE. Salivary gland cancers of the nasopharynx: a population-based analysis of 383 cases. *Otolaryngol Head Neck Surg.* 2019;161(3):442-449. <https://doi.org/10.1177/0194599819849923>
1731. Ryu J, Park WS, Jung YS. Exclusive endoscopic resection of nasopharyngeal papillary adenocarcinoma via combined transnasal and transoral approach. *Clin Exp Otorhinolaryngol.* 2013;6(1):48-51. <https://doi.org/10.3342/ceo.2013.6.1.48>
1732. Unsaler S, Basaran B, Aslan I, Yilmazbayhan D. Endonasal endoscopic nasopharyngectomy for the treatment of nasopharyngeal papillary adenocarcinoma: report of a rare case. *Int J Pediatr Otorhinolaryngol.* 2018;104:51-53. <https://doi.org/10.1016/j.ijporl.2017.10.041>
1733. Stepan KO, Mazul AL, Skillington SA, et al. The prognostic significance of race in nasopharyngeal carcinoma by histological subtype. *Head Neck.* 2021;43(6):1797-1811. <https://doi.org/10.1002/hed.26639>
1734. Zang J, Li C, Xu M, et al. Induction chemotherapy followed by concurrent chemoradiotherapy is benefit for advanced stage nasopharyngeal carcinoma with different nonkeratinizing carcinoma subtypes. *Sci Rep.* 2018;8(1):13318. <https://doi.org/10.1038/s41598-018-31050-z>
1735. Isayeva T, Li Y, Maswahu D, Brandwein-Gensler M. Human papillomavirus in non-oropharyngeal head and neck cancers: a systematic literature review. *Head Neck Pathol.* 2012;6(Suppl. 1):S104-S120. <https://doi.org/10.1007/s12105-012-0368-1>
1736. Tham T, Machado R, Russo DP, Herman SW, Teegala S, Costantino P. Viral markers in nasopharyngeal carcinoma: a systematic review and meta-analysis on the detection of p16(INK4a), human papillomavirus (HPV), and Epstein-Barr virus (EBV). *Am J Otolaryngol.* 2021;42(1):102762. <https://doi.org/10.1016/j.amjoto.2020.102762>
1737. Ruuskanen M, Irjala H, Minn H, et al. Epstein-Barr virus and human papillomaviruses as favorable prognostic factors in nasopharyngeal carcinoma: a nationwide study in Finland. *Head Neck.* 2019;41(2):349-357. <https://doi.org/10.1002/hed.25450>
1738. Jiang W, Chamberlain PD, Garden AS, et al. Prognostic value of p16 expression in Epstein-Barr virus-positive nasopharyngeal carcinomas. *Head Neck.* 2016;38(Suppl. 1):E1459-E1466. <https://doi.org/10.1002/hed.24258>
1739. Atighechi S, Ahmadpour Baghdadabad MR, Mirvakili SA, et al. Human papilloma virus and nasopharyngeal carcinoma: pathology, prognosis, recurrence and mortality of the disease. *Exp Oncol.* 2014;36(3):215-216.
1740. Stenmark MH, McHugh JB, Schipper M, et al. Nonendemic HPV-positive nasopharyngeal carcinoma: association with poor prognosis. *Int J Radiat Oncol Biol Phys.* 2014;88(3):580-588. <https://doi.org/10.1016/j.ijrobp.2013.11.246>
1741. Newton E, Valenzuela D, Foley J, Thamboo A, Prisman E. Outcomes for the treatment of locoregional recurrent nasopharyngeal cancer: systematic review and pooled analysis. *Head Neck.* 2021;43(12):3979-3995. <https://doi.org/10.1002/hed.26836>
1742. Zhang B, Li Y, Weng J, et al. Efficacy and safety of endoscopic nasopharyngectomy combined with low-dose radiotherapy for primary T1-2 nasopharyngeal carcinoma. *Technol Cancer Res Treat.* 2021;20:15330338211011976. <https://doi.org/10.1177/15330338211011976>
1743. Thamboo A, Patel VS, Hwang PH. 5-year outcomes of salvage endoscopic nasopharyngectomy for recurrent nasopharyngeal carcinoma. *J Otolaryngol Head Neck Surg.* 2021;50(1):12. <https://doi.org/10.1186/s40463-020-00482-x>
1744. Li W, Lu H, Wang H, et al. Salvage endoscopic nasopharyngectomy in recurrent nasopharyngeal carcinoma: prognostic factors and treatment outcomes. *Am J Rhinol Allergy.* 2021;35(4):458-466. <https://doi.org/10.1177/1945892420964054>
1745. Wang ZQ, Xie YL, Liu YP, et al. Endoscopic nasopharyngectomy combined with internal carotid artery pretreatment for recurrent nasopharyngeal carcinoma. *Otolaryngol Head Neck Surg.* 2022;166(3):490-497. <https://doi.org/10.1177/01945998211011076>
1746. Wong EHC, Liew YT, Loong SP, Prepageran N. Five-year survival data on the role of endoscopic endonasal nasopharyngectomy in advanced recurrent rT3 and rT4 nasopharyngeal carcinoma. *Ann Otol Rhinol Laryngol.* 2020;129(3):287-293. <https://doi.org/10.1177/0003489419887410>
1747. Tang IP, Ngui LX, Ramachandran K, et al. A 4-year review of surgical and oncological outcomes of endoscopic endonasal transpterygoid nasopharyngectomy in salvaging locally recurrent nasopharyngeal carcinoma. *Eur Arch Otorhinolaryngol.* 2019;276(9):2475-2482. <https://doi.org/10.1007/s00405-019-05522-5>
1748. Liu J, Yu H, Sun X, et al. Salvage endoscopic nasopharyngectomy for local recurrent or residual nasopharyngeal carcinoma: a 10-year experience. *Int J Clin Oncol.* 2017;22(5):834-842. <https://doi.org/10.1007/s10147-017-1143-9>

1749. Vlantis AC, Lee DL, Wong EW, Chow SM, Ng SK, Chan JY. Endoscopic nasopharyngectomy in recurrent nasopharyngeal carcinoma: a case series, literature review, and pooled analysis. *Int Forum Allergy Rhinol*. 2017;7(4):425-432. <https://doi.org/10.1002/alr.21881>
1750. Weng J, Wei J, Si J, et al. Clinical outcomes of residual or recurrent nasopharyngeal carcinoma treated with endoscopic nasopharyngectomy plus chemoradiotherapy or with chemoradiotherapy alone: a retrospective study. *PeerJ*. 2017;5:e3912. <https://doi.org/10.7717/peerj.3912>
1751. Wong EHC, Liew YT, Abu Bakar MZ, Lim EYL, Prepageran N. A preliminary report on the role of endoscopic endonasal nasopharyngectomy in recurrent rT3 and rT4 nasopharyngeal carcinoma. *Eur Arch Otorhinolaryngol*. 2017;274(1):275-281. <https://doi.org/10.1007/s00405-016-4248-2>
1752. You R, Zou X, Hua YJ, et al. Salvage endoscopic nasopharyngectomy is superior to intensity-modulated radiation therapy for local recurrence of selected T1-T3 nasopharyngeal carcinoma – a case-matched comparison. *Radiother Oncol*. 2015;115(3):399-406. <https://doi.org/10.1016/j.radonc.2015.04.024>
1753. Ho AS, Kaplan MJ, Fee WE, Yao M, Sunwoo JB, Hwang PH. Targeted endoscopic salvage nasopharyngectomy for recurrent nasopharyngeal carcinoma. *Int Forum Allergy Rhinol*. 2012;2(2):166-173. <https://doi.org/10.1002/alr.20111>
1754. Chen MY, Wen WP, Guo X, et al. Endoscopic nasopharyngectomy for locally recurrent nasopharyngeal carcinoma. *Laryngoscope*. 2009;119(3):516-522. <https://doi.org/10.1002/lary.20133>
1755. Ko JY, Wang CP, Ting LL, Yang TL, Tan CT. Endoscopic nasopharyngectomy with potassium-titanyl-phosphate (KTP) laser for early locally recurrent nasopharyngeal carcinoma. *Head Neck*. 2009;31(10):1309-1315. <https://doi.org/10.1002/hed.21091>
1756. Baujat B, Audry H, Bourhis J, et al. Chemotherapy in locally advanced nasopharyngeal carcinoma: an individual patient data meta-analysis of eight randomized trials and 1753 patients. *Int J Radiat Oncol Biol Phys*. 2006;64(1):47-56. <https://doi.org/10.1016/j.ijrobp.2005.06.037>
1757. Wang BC, Shi LL, Fu C, et al. A meta-analysis of cisplatin-based concurrent chemoradiotherapy with or without cetuximab for locoregionally advanced nasopharyngeal carcinoma. *Medicine*. 2019;98(42):e17486. <https://doi.org/10.1097/MD.00000000000017486>
1758. Li WF, Chen NY, Zhang N, et al. Concurrent chemoradiotherapy with/without induction chemotherapy in locoregionally advanced nasopharyngeal carcinoma: long-term results of phase 3 randomized controlled trial. *Int J Cancer*. 2019;145(1):295-305. <https://doi.org/10.1002/ijc.32099>
1759. Doshi DV, Tripathi U, Dave RI. Rare tumors of sinonasal track. *Indian J Otolaryngol Head Neck Surg*. 2010;62(2):111-117.
1760. Bitner BF, Htun NN, Wang BY, Brem EA, Kuan EC. Sinonasal lymphoma: a primer for otolaryngologists. *Laryngoscope Invest Otolaryngol*. 2022;7(6):1712-1724. <https://doi.org/10.1002/lio2.941>
1761. Wajda BN, Rabinowitz MR, Nyquist GG, Mardekian SK, Rosen MR, Rabinowitz MP. Paranasal sinus lymphoma: retrospective review with focus on clinical features, histopathology, prognosis, and relationship to systemic lymphoma. *Head Neck*. 2017;39(6):1065-1070. <https://doi.org/10.1002/hed.24686>
1762. Takahashi H, Tomita N, Yokoyama M, et al. Prognostic impact of extranodal involvement in diffuse large B-cell lymphoma in the rituximab era. *Cancer*. 2012;118(17):4166-4172. <https://doi.org/10.1002/cncr.27381>
1763. Brugère, Schlienger M, Gérard-Marchant R, Tubiana M, Pouillart P, Cachin Y. Non-Hodgkin's malignant lymphomata of upper digestive and respiratory tract: natural history and results of radiotherapy. *Br J Cancer Suppl*. 1975;2:435-440.
1764. Lehrich BM, Abiri A, Goshtasbi K, et al. Treatment modalities and survival outcomes for sinonasal diffuse large B-cell lymphoma. *Laryngoscope*. 2021;131(11):E2727-E2735. <https://doi.org/10.1002/lary.29584>
1765. Kanumuri VV, Khan MN, Vazquez A, Govindaraj S, Baredes S, Eloy JA. Diffuse large B-cell lymphoma of the sinonasal tract: analysis of survival in 852 cases. *Am J Otolaryngol*. 2014;35(2):154-158. <https://doi.org/10.1016/j.amjoto.2013.09.003>
1766. Proulx GM, Caudra-Garcia I, Ferry J, et al. Lymphoma of the nasal cavity and paranasal sinuses: treatment and outcome of early-stage disease. *Am J Clin Oncol*. 2003;26(1):6-11. <https://doi.org/10.1097/00000421-200302000-00002>
1767. Azarpira N, Ashraf MJ, Monabati A, et al. Primary lymphoma of nasal cavity and paranasal sinuses. *Labmedicine*. 2012;43(6):294-299. <https://doi.org/10.1309/Lmkh083qcxfuuigs>
1768. Cuadra-Garcia I, Proulx GM, Wu CL, et al. Sinonasal lymphoma: a clinicopathologic analysis of 58 cases from the Massachusetts General Hospital. *Am J Surg Pathol*. 1999;23(11):1356-1369. <https://doi.org/10.1097/00000478-199911000-00006>
1769. Eriksen PRG, Clasen-Linde E, Nully Brown P, et al. Sinonasal B-cell lymphomas: a nationwide cohort study, with an emphasis on the prognosis and the recurrence pattern of primary diffuse large B-cell lymphoma. *Hematol Oncol*. 2022;40(2):160-171. <https://doi.org/10.1002/hon.2968>
1770. Harabuchi Y, Yamanaka N, Kataura A, et al. Epstein-Barr virus in nasal T-cell lymphomas in patients with lethal midline granuloma. *Lancet*. 1990;335(8682):128-130. [https://doi.org/10.1016/0140-6736\(90\)90002-m](https://doi.org/10.1016/0140-6736(90)90002-m)
1771. Young L, Alfieri C, Hennessy K, et al. Expression of Epstein-Barr virus transformation-associated genes in tissues of patients with EBV lymphoproliferative disease. *N Engl J Med*. 1989;321(16):1080-1085. <https://doi.org/10.1056/NEJM198910193211604>
1772. Vilde JL, Perronne C, Huchon A, et al. Association of Epstein-Barr virus with lethal midline granuloma. *N Engl J Med*. 1985;313(18):1161. <https://doi.org/10.1056/NEJM198510313131816>
1773. Hahn JS, Lee ST, Min YH, Ko YW, Yang WI, Kim GE. Therapeutic outcome of Epstein-Barr virus positive T/NK cell lymphoma in the upper aerodigestive tract. *Yonsei Med J*. 2002;43(2):175-182. <https://doi.org/10.3349/ymj.2002.43.2.175>
1774. Cheung MM, Chan JK, Wong KF. Natural killer cell neoplasms: a distinctive group of highly aggressive lymphomas/leukemias. *Semin Hematol*. 2003;40(3):221-232. [https://doi.org/10.1016/s0037-1963\(03\)00136-7](https://doi.org/10.1016/s0037-1963(03)00136-7)

1775. Al-Hakeem DA, Fedele S, Carlos R, Porter S. Extranodal NK/T-cell lymphoma, nasal type. *Oral Oncol.* 2007;43(1):4-14. <https://doi.org/10.1016/j.oraloncology.2006.03.011>
1776. Chim CS, Ma SY, Au WY, et al. Primary nasal natural killer cell lymphoma: long-term treatment outcome and relationship with the International Prognostic Index. *Blood.* 2004;103(1):216-221. <https://doi.org/10.1182/blood-2003-05-1401>
1777. Li CC, Tien HF, Tang JL, et al. Treatment outcome and pattern of failure in 77 patients with sinonasal natural killer/T-cell or T-cell lymphoma. *Cancer.* 2004;100(2):366-375. <https://doi.org/10.1002/cncr.11908>
1778. Abbondanzo SL, Wenig BM. Non-Hodgkin's lymphoma of the sinonasal tract. A clinicopathologic and immunophenotypic study of 120 cases. *Cancer.* 1995;75(6):1281-1291. [https://doi.org/10.1002/1097-0142\(19950315\)75:6<1281::aid-cncr2820750610>3.0.co;2-i](https://doi.org/10.1002/1097-0142(19950315)75:6<1281::aid-cncr2820750610>3.0.co;2-i)
1779. Logsdon MD, Ha CS, Kavadi VS, Cabanillas F, Hess MA, Cox JD. Lymphoma of the nasal cavity and paranasal sinuses: improved outcome and altered prognostic factors with combined modality therapy. *Cancer.* 1997;80(3):477-488. [https://doi.org/10.1002/\(sici\)1097-0142\(19970801\)80:3<477::aid-cncr16>3.0.co;2-u](https://doi.org/10.1002/(sici)1097-0142(19970801)80:3<477::aid-cncr16>3.0.co;2-u)
1780. Kitamura A, Yamashita Y, Hasegawa Y, Kojima H, Nagasawa T, Mori N. Primary lymphoma arising in the nasal cavity among Japanese. *Histopathology.* 2005;47(5):523-532. <https://doi.org/10.1111/j.1365-2559.2005.02265.x>
1781. Cheung MM, Chan JK, Lau WH, et al. Primary non-Hodgkin's lymphoma of the nose and nasopharynx: clinical features, tumor immunophenotype, and treatment outcome in 113 patients. *J Clin Oncol.* 1998;16(1):70-77. <https://doi.org/10.1200/JCO.1998.16.1.70>
1782. Tusaliu M, Mogoanta CA, Dobrea CM, Zainea V. Clinical and histological aspects with therapeutic implications in head and neck lymphomas. *Rom J Morphol Embryol.* 2015;56(2):499-504.
1783. Shirazi N, Bist SS, Puri N, Harsh M, Ahmad S. Primary sinonasal lymphoma in immunocompetent patients: a 10 years retrospective clinicopathological study. *J Oral Maxillofac Pathol.* 2018;22(2):280-281. https://doi.org/10.4103/jomfp.JOMFP_45_17
1784. Woo JS, Kim JM, Lee SH, Chae SW, Hwang SJ, Lee HM. Clinical analysis of extranodal non-Hodgkin's lymphoma in the sinonasal tract. *Eur Arch Otorhinolaryngol.* 2004;261(4):197-201. <https://doi.org/10.1007/s00405-003-0627-6>
1785. Sands NB, Tewfik MA, Hwang SY, Desrosiers M. Extranodal T-cell lymphoma of the sinonasal tract presenting as severe rhinitis: case series. *J Otolaryngol Head Neck Surg.* 2008;37(4):528-533. <https://doi.org/10.2310/7070.2008.0100>
1786. Fajardo-dolci G, Magaña RC, Bautista EL. Sinonasal lymphoma. *J Otolaryngol Head Neck Surg.* 1999;121(3):323-326.
1787. Arora N, Mehta A, Ravichandran S, et al. NK/T cell lymphoma: a tertiary centre experience. *Indian J Hematol Blood Transfus.* 2017;33(1):69-73. <https://doi.org/10.1007/s12288-016-0675-x>
1788. van de Rijn M, Bhargava V, Molina-Kirsch H, et al. Extranodal head and neck lymphomas in Guatemala: high frequency of Epstein-Barr virus-associated sinonasal lymphomas. *Hum Pathol.* 1997;28(7):834-839.
1789. Gaal K, Sun NC, Hernandez AM, Arber DA. Sinonasal NK/T-cell lymphomas in the United States. *Am J Surg Pathol.* 2000;24(11):1511-1517. <https://doi.org/10.1097/00000478-200011000-00006>
1790. Miyake MM, Oliveira MV, Miyake MM, Garcia JO, Granato L. Clinical and otorhinolaryngological aspects of extranodal NK/T cell lymphoma, nasal type. *Braz J Otorhinolaryngol.* 2014;80(4):325-329. <https://doi.org/10.1016/j.bjorl.2014.05.013>
1791. Yen TT, Wang RC, Jiang RS, Chen SC, Wu SH, Liang KL. The diagnosis of sinonasal lymphoma: a challenge for rhinologists. *Eur Arch Otorhinolaryngol.* 2012;269(5):1463-1469. <https://doi.org/10.1007/s00405-011-1839-9>
1792. Eide JG, Kshirsagar RS, Birkenbeuel JL, et al. Primary sinonasal lymphoma: a multi-institutional experience of clinical presentation, treatment, and outcomes. *Int Forum Allergy Rhinol.* 2023;13(8):1492-1502. <https://doi.org/10.1002/alr.23102>
1793. Lei T, Chang Y, Zhang L, Zhang M. The effect of chronic rhinosinusitis on the staging and prognosis of extranodal natural killer/T-cell lymphoma: a single-center retrospective analysis. *Front Oncol.* 2022;12:878559. <https://doi.org/10.3389/fonc.2022.878559>
1794. Wajima D, Nishimura F, Masui K. Diffuse large B-cell lymphoma in the sphenoid sinus: a case report and review of literature. *Surg Neurol Int.* 2020;11:208. https://doi.org/10.25259/SNI_280_2020
1795. Storck K, Brandstetter M, Keller U, Knopf A. Clinical presentation and characteristics of lymphoma in the head and neck region. *Head Face Med.* 2019;15(1):1. <https://doi.org/10.1186/s13005-018-0186-0>
1796. Tusaliu M, Zainea V, Mogoanta CA, et al. Diagnostic and therapeutic aspects in malignant sinonasal lymphoma. *Rom J Morphol Embryol.* 2016;57(1):233-236.
1797. Vahamurto P, Silventoinen K, Vento SI, et al. Clinical findings of extranodal SNT lymphoid malignancies in a four-decade single-centre series. *Eur Arch Otorhinolaryngol.* 2016;273(11):3839-3845. <https://doi.org/10.1007/s00405-016-3992-7>
1798. Liang CW, Chen YL. Perineural invasion of sinonasal lymphoma: a rare cause of trigeminal neuropathy. *Headache.* 2007;47(2):295-297. <https://doi.org/10.1111/j.1526-4610.2006.00700.x>
1799. Ooi GC, Chim CS, Liang R, Tsang KW, Kwong YL. Nasal T-cell/natural killer cell lymphoma: CT and MR imaging features of a new clinicopathologic entity. *AJR Am J Roentgenol.* 2000;174(4):1141-1145. <https://doi.org/10.2214/ajr.174.4.1741141>
1800. Ou CH, Chen CC, Ling JC, et al. Nasal NK/T-cell lymphoma: computed tomography and magnetic resonance imaging findings. *J Chin Med Assoc.* 2007;70(5):207-212. [https://doi.org/10.1016/S1726-4901\(09\)70359-4](https://doi.org/10.1016/S1726-4901(09)70359-4)
1801. Termote K, Dierickx D, Verhoef G, Jorissen M, Tousseyn T, Mombaerts I. Series of extranodal natural killer/T-cell lymphoma, nasal type, with periorbital involvement. *Orbit.* 2014;33(4):245-251. <https://doi.org/10.3109/01676830.2014.902478>
1802. Marsot-Dupuch K, Cabane J, Raveau V, Aoun N, Tubiana JM. Lethal midline granuloma: impact of imaging studies on the investigation and management of destructive mid facial disease in 13 patients. *Neuroradiology.* 1992;34(2):155-161. <https://doi.org/10.1007/BF00588164>

1803. Chen Y, Wang X, Li L. Differential diagnosis of sinonasal extranodal NK/T cell lymphoma and diffuse large B cell lymphoma on MRI. *Neuroradiology*. 2020;62(9):1149-1155.
1804. He M, Tang Z, Qiang J, Xiao Z, Zhang Z. Differentiation between sinonasal natural killer/T-cell lymphomas and diffuse large B-cell lymphomas by RESOLVE DWI combined with conventional MRI. *Magn Reson Imaging*. 2019;62:10-17. <https://doi.org/10.1016/j.mri.2019.06.011>
1805. Bisdas S, Fetscher S, Feller AC, et al. Primary B cell lymphoma of the sphenoid sinus: CT and MRI characteristics with correlation to perfusion and spectroscopic imaging features. *Eur Arch Otorhinolaryngol*. 2007;264(10):1207-1213. <https://doi.org/10.1007/s00405-007-0322-0>
1806. Nakamura K, Uehara S, Omagari J, et al. Primary non-Hodgkin lymphoma of the sinonasal cavities: correlation of CT evaluation with clinical outcome. *Radiology*. 1997;204(2):431-435. <https://doi.org/10.1148/radiology.204.2.9240531>
1807. Borges A, Fink J, Villablanca P, Eversole R, Lufkin R. Midline destructive lesions of the sinonasal tract: simplified terminology based on histopathologic criteria. *AJNR Am J Neuroradiol*. 2000;21(2):331-336.
1808. Wang X, Zhang Z, Chen Q, Li J, Xian J. Effectiveness of 3 T PROPELLER DUO diffusion-weighted MRI in differentiating sinonasal lymphomas and carcinomas. *Clin Radiol*. 2014;69(11):1149-1156. <https://doi.org/10.1016/j.crad.2014.07.003>
1809. King AD, Law BK, Tang WK, et al. MRI of diffuse large B-cell non-Hodgkin's lymphoma of the head and neck: comparison of Waldeyer's ring and sinonasal lymphoma. *Eur Arch Otorhinolaryngol*. 2017;274(2):1079-1087. <https://doi.org/10.1007/s00405-016-4337-2>
1810. Zelenetz AD, Gordon LI, Chang JE, et al. NCCN guidelines(R) insights: B-cell lymphomas, version 5.2021. *J Natl Compr Canc Netw*. 2021;19(11):1218-1230. <https://doi.org/10.6004/jnccn.2021.0054>
1811. Iguchi H, Wada T, Matsushita N, Oishi M, Yamane H. Anatomic distribution of hematolymphoid malignancies in the head and neck: 7 years of experience with 122 patients in a single institution. *Acta Otolaryngol*. 2012;132(11):1224-1231. <https://doi.org/10.3109/00016489.2012.694474>
1812. Kane S, Khurana A, Parulkar G, et al. Minimum diagnostic criteria for plasmablastic lymphoma of oral/sinonasal region encountered in a tertiary cancer hospital of a developing country. *J Oral Pathol Med*. 2009;38(1):138-144. <https://doi.org/10.1111/j.1600-0714.2008.00673.x>
1813. Desai MA, Sethi TK, Yenamandra AK, et al. Primary sinonasal large B cell lymphoma is as histopathologically heterogeneous as systemic large B cell lymphoma but may show subtype-specific tropism for specific sinonasal anatomic sites. *J Hematop*. 2021;14(4):269-275. <https://doi.org/10.1007/s12308-021-00473-5>
1814. Carreras J, Kikuti YY, Bea S. Clinicopathological characteristics and genomic profile of primary sinonasal tract diffuse large B cell lymphoma (DLBCL) reveals gain at 1q31 and RGS1 encoding protein; high RGS1 immunohistochemical expression associates with poor OS in DLBCL not otherwise specified (NOS). *Histopathology*. 2017;70(4):595-621.
1815. Murakami D, Miyashita K, Koyama T, et al. Clinicopathological analysis of sinonasal malignant lymphoma in an HTLV-1 endemic area in Japan -special focus on primary sinonasal diffuse large B-cell lymphoma. *J Clin Exp Hematop*. 2019;59(3):101-107. <https://doi.org/10.3960/jslrt.18008>
1816. Toda H, Sato Y, Takata K, Orita Y, Asano N, Yoshino T. Clinicopathologic analysis of localized nasal/paranasal diffuse large B-cell lymphoma. *PLoS ONE*. 2013;8(2):e57677. <https://doi.org/10.1371/journal.pone.0057677>
1817. McKelvie PA, Climent F, Krings G, et al. Small-cell predominant extranodal NK/T cell lymphoma, nasal type: clinicopathological analysis of a series of cases diagnosed in a Western population. *Histopathology*. 2016;69(4):667-679. <https://doi.org/10.1111/his.12990>
1818. Lee JH, Lee SS, Park JH, Kim YW, Yang MH. Prevalence of EBV RNA in sinonasal and Waldeyer's ring lymphomas. *J Korean Med Sci*. 1994;9(4):281-288. <https://doi.org/10.3346/jkms.1994.9.4.281>
1819. Aviles A, Rodriguez L, Guzman R, Talavera A, Garcia EL, Diaz-Maqueo JC. Angiocentric T-cell lymphoma of the nose, paranasal sinuses and hard palate. *Hematol Oncol*. 1992;10(3-4):141-147. <https://doi.org/10.1002/hon.2900100303>
1820. Arber DA, Weiss LM, Albuja PF, Chen YY, Jaffe ES. Nasal lymphomas in Peru. High incidence of T-cell immunophenotype and Epstein-Barr virus infection. *Am J Surg Pathol*. 1993;17(4):392-399. <https://doi.org/10.1097/00000478-199304000-00010>
1821. Dictor M, Cervin A, Kalm O, Rambech E. Sinonasal T-cell lymphoma in the differential diagnosis of lethal midline granuloma using in situ hybridization for Epstein-Barr virus RNA. *Mod Pathol*. 1996;9(1):7-14.
1822. Harabuchi Y, Imai S, Kataura A. Nasal T-cell lymphoma causally associated with Epstein-Barr virus. *Gann Monographs Cancer Res*. 1998;45:129-137.
1823. Harabuchi Y, Takahara M, Kishibe K, Nagato T, Kumai T. Extranodal natural killer/T-cell lymphoma, nasal type: basic science and clinical progress. *Front Pediatr*. 2019;7:141. <https://doi.org/10.3389/fped.2019.00141>
1824. Hsueh CY, Yang CF, Gau JP, et al. Nasopharyngeal lymphoma: a 22-year review of 35 cases. *J Clin Med*. 2019;8(10):1604. <https://doi.org/10.3390/jcm8101604>
1825. Chan JK. Virus-associated neoplasms of the nasopharynx and sinonasal tract: diagnostic problems. *Mod Pathol*. 2017;30(s1):S68-S83. <https://doi.org/10.1038/modpathol.2016.189>
1826. Falcao RP, Rizzatti EG, Saggiaro FP, Garcia AB, Marinato AF, Rego EM. Flow cytometry characterization of leukemic phase of nasal NK/T-cell lymphoma in tumor biopsies and peripheral blood. *Haematologica*. 2007;92(2):e24-e25. <https://doi.org/10.3324/haematol.10654>
1827. Kanavaros P, Briere J, Lescs MC, Gaulard P. Epstein-Barr virus in non-Hodgkin's lymphomas of the upper respiratory tract: association with sinonasal localization and expression of NK and/or T-cell antigens by tumour cells. *J Pathol*. 1996;178(3):297-302. [https://doi.org/10.1002/\(SICI\)1096-9896\(199603\)178:3<297::AID-PATH469>3.0.CO;2-E](https://doi.org/10.1002/(SICI)1096-9896(199603)178:3<297::AID-PATH469>3.0.CO;2-E)
1828. Ohshima K, Suzumiya J, Shimazaki K, et al. Nasal T/NK cell lymphomas commonly express perforin and Fas lig-

- and: important mediators of tissue damage. *Histopathology*. 1997;31(5):444-450.
1829. Suzumiya J, Takeshita M, Kimura N, et al. Expression of adult and fetal natural killer cell markers in sinonasal lymphomas. *Blood*. 1994;83(8):2255-2260.
1830. Zhiyan D, Caihong H, Jiajia Y. Clinical pathological analysis of nasal natural Killer/T-cell lymphoma patients. *Cancer Res Clin*. 2018;30(3):193-196. <https://doi.org/10.3760/cma.j.issn.1006-9801.2018.03.012>
1831. Li ZM, Zhu YJ, Sun J, et al. Serum beta2-microglobulin is a predictor of prognosis in patients with upper aerodigestive tract NK/T-cell lymphoma. *Ann Hematol*. 2012;91(8):1265-1270. <https://doi.org/10.1007/s00277-012-1434-1>
1832. Pfreundschuh M, Trumper L, Osterborg A, et al. CHOP-like chemotherapy plus rituximab versus CHOP-like chemotherapy alone in young patients with good-prognosis diffuse large-B-cell lymphoma: a randomised controlled trial by the MabThera International Trial (MInT) Group. *Lancet Oncol*. 2006;7(5):379-391. [https://doi.org/10.1016/S1470-2045\(06\)70664-7](https://doi.org/10.1016/S1470-2045(06)70664-7)
1833. Oprea C, Cainap C, Azoulay R, et al. Primary diffuse large B-cell non-Hodgkin lymphoma of the paranasal sinuses: a report of 14 cases. *Br J Haematol*. 2005;131(4):468-471. <https://doi.org/10.1111/j.1365-2141.2005.05787.x>
1834. Laskin JJ, Savage KJ, Voss N, Gascoyne RD, Connors JM. Primary paranasal sinus lymphoma: natural history and improved outcome with central nervous system chemoprophylaxis. *Leuk Lymphoma*. 2005;46(12):1721-1727. <https://doi.org/10.1080/17402520500182345>
1835. Varelas AN, Eggerstedt M, Ganti A, Tajudeen BA. Epidemiologic, prognostic, and treatment factors in sinonasal diffuse large B-cell lymphoma. *Laryngoscope*. 2019;129(6):1259-1264. <https://doi.org/10.1002/lary.27639>
1836. Lee GW, Go SI, Kim SH, et al. Clinical outcome and prognosis of patients with primary sinonasal tract diffuse large B-cell lymphoma treated with rituximab-cyclophosphamide, doxorubicin, vincristine and prednisone chemotherapy: a study by the Consortium for Improving Survival of Lymphoma. *Leuk Lymphoma*. 2015;56(4):1020-1026. <https://doi.org/10.3109/10428194.2014.946027>
1837. Cooper DL, Ginsberg SS. Brief chemotherapy, involved field radiation therapy, and central nervous system prophylaxis for paranasal sinus lymphoma. *Cancer*. 1992;69(12):2888-2893. [https://doi.org/10.1002/1097-0142\(19920615\)69:12<2888::aid-cncr2820691205>3.0.co;2-d](https://doi.org/10.1002/1097-0142(19920615)69:12<2888::aid-cncr2820691205>3.0.co;2-d)
1838. Hausdorff J, Davis E, Long G, et al. Non-Hodgkin's lymphoma of the paranasal sinuses: clinical and pathological features, and response to combined-modality therapy. *Cancer J Sci Am*. 1997;3(5):303-311.
1839. Steele TO, Buniel MC, Mace JC, El Rassi E, Smith TL. Lymphoma of the nasal cavity and paranasal sinuses: a case series. *Am J Rhinol Allergy*. 2016;30(5):335-339. <https://doi.org/10.2500/ajra.2016.30.4347>
1840. Han AY, Kuan EC, Alonso JE, Badran KW, St John MA. Epidemiology of nasopharyngeal lymphoma in the United States: a population-based analysis of 1119 cases. *Otolaryngol Head Neck Surg*. 2017;156(5):870-876. <https://doi.org/10.1177/0194599817695808>
1841. Pierpont TM, Limper CB, Richards KL. Past, present, and future of rituximab-the world's first oncology monoclonal antibody therapy. *Front Oncol*. 2018;8(163):163. <https://doi.org/10.3389/fonc.2018.00163>
1842. Bennett CL, Focosi D, Socal MP, et al. Progressive multifocal leukoencephalopathy in patients treated with rituximab: a 20-year review from the Southern Network on Adverse Reactions. *Lancet Haematol*. 2021;8(8):e593-e604. [https://doi.org/10.1016/S2352-3026\(21\)00167-8](https://doi.org/10.1016/S2352-3026(21)00167-8)
1843. Vahamurto P, Mannisto S, Pollari M, Karjalainen-Lindsberg ML, Makitie AA, Leppa S. Clinical features and outcome of the patients with sinonasal tract diffuse large B-cell lymphoma in the pre-rituximab and rituximab eras. *Eur J Haematol*. 2019;102(6):457-464. <https://doi.org/10.1111/ejh.13225>
1844. Brown HJ, Varelas EA, Ganti A, et al. Prognostic indicators of survival in sinonasal diffuse large B-cell lymphoma: a national cancer database analysis. *Laryngoscope*. 2022;132(8):1515-1522. <https://doi.org/10.1002/lary.29864>
1845. Ribrag V, Hajj ME, Janot F, et al. Early locoregional high-dose radiotherapy is associated with long-term disease control in localized primary angiocentric lymphoma of the nose and nasopharynx. *Leukemia*. 2001;15(7):1123-1126. <https://doi.org/10.1038/sj.leu.2402148>
1846. Lehrich BM, Goshtasbi K, Abiri A, et al. Treatment modalities and overall survival outcomes for sinonasal extranodal natural killer/T-cell lymphoma. *Leuk Lymphoma*. 2021;62(3):727-730. <https://doi.org/10.1080/10428194.2020.1834097>
1847. Gupta VG, Gogia A, Kumar L. Combined modality treatment with "dexamethasone, methotrexate, ifosfamide, l-asparaginase, and etoposide" chemotherapy and involved field radiotherapy for early stage natural Killer/T cell lymphoma with local tumor invasiveness: a single-institution study from India. *Indian J Med Paediatr Oncol*. 2018;39(1):67-72.
1848. Yi W, Yang T, Lin S, et al. New approaches for treatment of advanced extranodal NK/T-cell lymphoma. *Cancer Manag Res*. 2022;14:401-407. <https://doi.org/10.2147/CMAR.S328846>
1849. Coha B, Vucinic I, Mahovne I, Vukovic-Arar Z. Extranodal lymphomas of head and neck with emphasis on NK/T-cell lymphoma, nasal type. *J Craniomaxillofac Surg*. 2014;42(2):149-152. <https://doi.org/10.1016/j.jcms.2013.04.004>
1850. Guo Y, Lu JJ, Ma X, et al. Combined chemoradiation for the management of nasal natural killer (NK)/T-cell lymphoma: elucidating the significance of systemic chemotherapy. *Oral Oncol*. 2008;44(1):23-30. <https://doi.org/10.1016/j.oraloncology.2006.11.020>
1851. Kim GE, Koom WS, Yang WI, et al. Clinical relevance of three subtypes of primary sinonasal lymphoma characterized by immunophenotypic analysis. *Head Neck*. 2004;26(7):584-593. <https://doi.org/10.1002/hed.20015>
1852. Lee J, Park YH, Kim WS, et al. Extranodal nasal type NK/T-cell lymphoma: elucidating clinical prognostic factors for risk-based stratification of therapy. *Eur J Cancer*. 2005;41(10):1402-1408. <https://doi.org/10.1016/j.ejca.2005.03.010>
1853. Ma HH, Qian LT, Pan HF, et al. Treatment outcome of radiotherapy alone versus radiochemotherapy in early stage nasal natural killer/T-cell lymphoma. *Med Oncol*. 2010;27(3):798-806. <https://doi.org/10.1007/s12032-009-9288-7>

1854. Wang B, Lu JJ, Ma X, et al. Combined chemotherapy and external beam radiation for stage IE and IIE natural killer T-cell lymphoma of nasal cavity. *Leuk Lymphoma*. 2007;48(2):396-402. <https://doi.org/10.1080/10428190601059795>
1855. Kim SJ, Oh SY, Hong JY. When do we need central nervous system prophylaxis in patients with extranodal NK/T-cell lymphoma, nasal type? *Ann Oncol*. 2010;21(5):1058-1063.
1856. Kim SJ, Yoon DH, Jaccard A, et al. A prognostic index for natural killer cell lymphoma after non-anthracycline-based treatment: a multicentre, retrospective analysis. *Lancet Oncol*. 2016;17(3):389-400. [https://doi.org/10.1016/S1470-2045\(15\)00533-1](https://doi.org/10.1016/S1470-2045(15)00533-1)
1857. Basavaiah SH, Lobo FD, Philipose CS, et al. Clinicopathological spectrum of solitary plasmacytoma: a single center experience from coastal India. *BMC Cancer*. 2019;19(1):801. <https://doi.org/10.1186/s12885-019-5976-7>
1858. Rajkumar SV, Dimopoulos MA, Palumbo A, et al. International Myeloma Working Group updated criteria for the diagnosis of multiple myeloma. *Lancet Oncol*. 2014;15(12):e538-e548. [https://doi.org/10.1016/S1470-2045\(14\)70442-5](https://doi.org/10.1016/S1470-2045(14)70442-5)
1859. Zhu X, Wang L, Zhu Y, et al. Extramedullary plasmacytoma: long-term clinical outcomes in a single-center in China and literature review. *Ear Nose Throat J*. 2021;100(4):227-232. <https://doi.org/10.1177/0145561320950587>
1860. Nahi H, Genell A, Walinder G, et al. Incidence, characteristics, and outcome of solitary plasmacytoma and plasma cell leukemia. Population-based data from the Swedish Myeloma Register. *Eur J Haematol*. 2017;99(3):216-222. <https://doi.org/10.1111/ejh.12907>
1861. D'Aguillo C, Soni RS, Gordhan C, Liu JK, Baredes S, Eloy JA. Sinonasal extramedullary plasmacytoma: a systematic review of 175 patients. *Int Forum Allergy Rhinol*. 2014;4(2):156-163. <https://doi.org/10.1002/alr.21254>
1862. Gerry D, Lentsch EJ. Epidemiologic evidence of superior outcomes for extramedullary plasmacytoma of the head and neck. *Otolaryngol Head Neck Surg*. 2013;148(6):974-981. <https://doi.org/10.1177/0194599813481334>
1863. Na'ara S, Amit M, Gil Z, Billan S. Plasmacytoma of the skull base: a meta-analysis. *J Neurol Surg B Skull Base*. 2016;77(1):61-65. <https://doi.org/10.1055/s-0035-1560047>
1864. Gibbs JD, Leon ME, Liu K, Nguyen J, Zhang L. A rare case of Epstein-Barr virus-related plasmacytoma involving maxillary sinus mucosa. *Clin Case Rep*. 2017;5(9):1482-1485. <https://doi.org/10.1002/ccr3.959>
1865. Sabir H, Kumbhare S, Parate A, Gupta S, Tale R. A 65-year old female with synchronous HIV and Extramedullary Plasmacytoma of Maxillary sinus. *Gulf J Oncolog*. 2015;1(19):18-23.
1866. Venkatesulu B, Mallick S, Giridhar P, Upadhyay AD, Rath GK. Pattern of care and impact of prognostic factors on the outcome of head and neck extramedullary plasmacytoma: a systematic review and individual patient data analysis of 315 cases. *Eur Arch Otorhinolaryngol*. 2018;275(2):595-606. <https://doi.org/10.1007/s00405-017-4817-z>
1867. Bachar G, Goldstein D, Brown D, et al. Solitary extramedullary plasmacytoma of the head and neck—long-term outcome analysis of 68 cases. *Head Neck*. 2008;30(8):1012-1019. <https://doi.org/10.1002/hed.20821>
1868. Ishtiaq R, Sarma K, Uzoaru I, Khaliq W. Nasal plasmacytoma: a rare cause of persistent epistaxis. *Postgrad Med*. 2018;130(6):507-510. <https://doi.org/10.1080/00325481.2018.1502015>
1869. Liu Y, Yuan X, Peng X, Xing Z, Yu L. Extramedullary plasmacytoma of the nasal inferior turbinate: a case report. *J Int Med Res*. 2021;49(12):3000605211062503. <https://doi.org/10.1177/03000605211062503>
1870. Di Stadio A, Ralli M, Messineo D, et al. Septal nasal extramedullary plasmacytoma: a rare tumor in an unusual area. *Ear Nose Throat J*. 2021;100(5_suppl.):805S-807S. <https://doi.org/10.1177/0145561320911735>
1871. Ghazizadeh M, Alavi Amlashi H, Mehrparvar G. Radioreistant extramedullary plasmacytoma of the maxillary sinus: a case report and review article. *Iran J Otorhinolaryngol*. 2015;27(81):313-318.
1872. Ching AS, Khoo JB, Chong VF. CT and MR imaging of solitary extramedullary plasmacytoma of the nasal tract. *AJNR Am J Neuroradiol*. 2002;23(10):1632-1636.
1873. Agarwal A. Neuroimaging of plasmacytoma. A pictorial review. *Neuroradiol J*. 2014;27(4):431-437. <https://doi.org/10.15274/NRJ-2014-10078>
1874. Wijaya J, McHarg D. Ga-67 and Tl-201 scintigraphy in extramedullary plasmacytoma: a case report. *Clin Nucl Med*. 2001;26(7):596-598. <https://doi.org/10.1097/00003072-200107000-00002>
1875. Cavo M, Terpos E, Nanni C, et al. Role of (18)F-FDG PET/CT in the diagnosis and management of multiple myeloma and other plasma cell disorders: a consensus statement by the International Myeloma Working Group. *Lancet Oncol*. 2017;18(4):e206-e217. [https://doi.org/10.1016/S1470-2045\(17\)30189-4](https://doi.org/10.1016/S1470-2045(17)30189-4)
1876. Caers J, Paiva B, Zamagni E, et al. Diagnosis, treatment, and response assessment in solitary plasmacytoma: updated recommendations from a European Expert Panel. *J Hematol Oncol*. 2018;11(1):10. <https://doi.org/10.1186/s13045-017-0549-1>
1877. Fouquet G, Guidez S, Herbaux C, et al. Impact of initial FDG-PET/CT and serum-free light chain on transformation of conventionally defined solitary plasmacytoma to multiple myeloma. *Clin Cancer Res*. 2014;20(12):3254-3260. <https://doi.org/10.1158/1078-0432.CCR-13-2910>
1878. Susnerwala SS, Shanks JH, Banerjee SS, Scarffe JH, Farrington WT, Slevin NJ. Extramedullary plasmacytoma of the head and neck region: clinicopathological correlation in 25 cases. *Br J Cancer*. 1997;75(6):921-927. <https://doi.org/10.1038/bjc.1997.162>
1879. Xing MH, Shaari AL, Beute JE, et al. Rare case of anaplastic plasmacytoma in the sinonasal tract. *Head Neck*. 2021;43(10):E46-E50. <https://doi.org/10.1002/hed.26818>
1880. Loucari CC, Foukas PG, Spathis A, et al. Solitary extramedullary plasmacytoma of the nasopharynx: the role of flow cytometry. *Oral Oncol*. 2021;118(105351):105351. <https://doi.org/10.1016/j.oraloncology.2021.105351>
1881. Kumar SK, Callander NS, Adekola K, et al. Multiple myeloma, version 3.2021, NCCN clinical practice guidelines in oncology. *J Natl Compr Canc Netw*. 2020;18(12):1685-1717. <https://doi.org/10.6004/jnccn.2020.0057>
1882. Knobel D, Zouhair A, Tsang RW, et al. Prognostic factors in solitary plasmacytoma of the bone: a multicenter Rare Cancer

- Network study. *BMC Cancer*. 2006;6(118):118. <https://doi.org/10.1186/1471-2407-6-118>
1883. Alexiou C, Kau RJ, Dietzfelbinger H, et al. Extranodal plasmacytoma: tumor occurrence and therapeutic concepts. *Cancer*. 1999;85(11):2305-2314.
1884. Patel TD, Vazquez A, Choudhary MM, Kam D, Baredes S, Eloy JA. Sinonasal extramedullary plasmacytoma: a population-based incidence and survival analysis. *Int Forum Allergy Rhinol*. 2015;5(9):862-869. <https://doi.org/10.1002/alr.21544>
1885. Gong Y, Pu W, Jin H, et al. Quantitative proteomics of CSF reveals potential predicted biomarkers for extranodal NK-/T-cell lymphoma of nasal-type with ethmoidal sinus metastasis. *Life Sci*. 2018;198:94-98. <https://doi.org/10.1016/j.lfs.2018.02.035>
1886. Tababi S, Kharrat S, Sellami M, et al. Extranodal NK/T-cell lymphoma, nasal type: report of 15 cases. *Eur Ann Otorhinolaryngol Head Neck Dis*. 2012;129(3):141-147. <https://doi.org/10.1016/j.anorl.2011.08.004>
1887. Lin CW, Yang JY, Chuang YC, Chen YH, Albitar M, Hsu SM. Presence of restricted killer immunoglobulin-like receptor repertoire and monoclonal T-cell receptor gamma rearrangement as evidence of mixed NK/T-cell differentiation in a subset of sinonasal lymphomas. *Lab Invest*. 2003;83(1):55-64. <https://doi.org/10.1097/01.Lab.0000047491.62596.A3>
1888. Altemani A, Barbosa AC, Kulka M, et al. Characteristics of nasal T/NK-cell lymphoma among Brazilians. *Neoplasma*. 2002;49(1):55-60.
1889. Takahashi N, Miura I, Chubachi A, Miura AB, Nakamura S. A clinicopathological study of 20 patients with T/natural killer (NK)-cell lymphoma-associated hemophagocytic syndrome with special reference to nasal and nasal-type NK/T-cell lymphoma. *Int J Hematol*. 2001;74(3):303-308. <https://doi.org/10.1007/BF02982065>
1890. Yang Y, Gau JP, Chang SM, Lin TH, Ho KC, Young JH. Malignant lymphomas of sinonasal region, including cases of polymorphic reticulosis: a retrospective clinicopathologic analysis of 34 cases. *Zhonghua Yi Xue Za Zhi*. 1997;60(5):236-244.
1891. Kanavaros P, Briere J, Emile JF, Gaulard P. Epstein-Barr virus in T and natural killer (NK) cell non-Hodgkin's lymphomas. *Leukemia*. 1996;10(Suppl. 2):S84-S87.
1892. Van Gorp J, De Bruin PC, Sie-Go DM, et al. Nasal T-cell lymphoma: a clinicopathological and immunophenotypic analysis of 13 cases. *Histopathology*. 1995;27(2):139-148. <https://doi.org/10.1111/j.1365-2559.1995.tb00022.x>
1893. Kojima M, Hosomura Y, Kurabayashi Y, et al. Malignant lymphomas of the nasal cavity and paranasal sinuses. A clinicopathologic and immunohistochemical study. *Acta Pathol Jpn*. 1992;42(5):333-338. <https://doi.org/10.1111/j.1440-1827.1992.tb02882.x>
1894. Weiss LM, Gaffey MJ, Chen YY, Frierson HF. Frequency of Epstein-Barr viral DNA in "Western" sinonasal and Waldeyer's ring non-Hodgkin's lymphomas. *Am J Surg Pathol*. 1992;16(2):156-162. <https://doi.org/10.1097/00000478-199202000-00008>
1895. Shikama N, Ikeda H, Nakamura S, et al. Localized aggressive non-Hodgkin's lymphoma of the nasal cavity: a survey by the Japan Lymphoma Radiation Therapy Group. *Int J Radiat Oncol Biol Phys*. 2001;51(5):1228-1233. [https://doi.org/10.1016/s0360-3016\(01\)01800-4](https://doi.org/10.1016/s0360-3016(01)01800-4)
1896. Lombard M, Michel G, Rives P, Moreau A, Espitalier F, Malard O. Extranodal non-Hodgkin lymphoma of the sinonasal cavities: a 22-case report. *Eur Ann Otorhinolaryngol Head Neck Dis*. 2015;132(5):271-274. <https://doi.org/10.1016/j.anorl.2015.08.015>
1897. Qurashi MS, Bessell EM, Clark DM. Aggressive sino-nasal non-Hodgkin's lymphoma diagnosed in Nottinghamshire, UK, between 1987 and 1996. *Clin Oncol*. 13(4):269-272.
1898. He L, Zou Y, Tang X, et al. Survival trends for extranodal NK/T-cell lymphoma, nasal type from different anatomical sites: a population-based study. *Ann Transl Med*. 2021;9(10):849. <https://doi.org/10.21037/atm-21-1748>
1899. Wu RY, Liu K, Wang WH, et al. Patterns of primary tumor invasion and regional lymph node spread based on magnetic resonance imaging in early-stage nasal NK/T-cell lymphoma: implications for clinical target volume definition and prognostic significance. *Int J Radiat Oncol Biol Phys*. 2017;97(1):50-59. <https://doi.org/10.1016/j.ijrobp.2016.09.013>
1900. Niu SQ, Yang Y, Li YY, et al. Primary site and regional lymph node involvement are independent prognostic factors for early-stage extranodal nasal-type natural killer/T cell lymphoma. *Chin J Cancer*. 2016;35(5):34. <https://doi.org/10.1186/s40880-016-0096-0>
1901. Michot JM, Mazon R, Danu A, et al. Concurrent Etoposide, Steroid, High-dose Ara-C and Platinum chemotherapy with radiation therapy in localised extranodal natural killer (NK)/T-cell lymphoma, nasal type. *Eur J Cancer*. 2015;51(16):2386-2395. <https://doi.org/10.1016/j.ejca.2015.07.009>
1902. Youssef YB, Bougmiza I, Bouabid Z, et al. Nasopharyngeal/nasal type NK/T lymphoma: analysis of 23 cases and current review of the literature. *Kulak Burun Bogaz Ihtis Derg*. 2012;22(5):275-283. <https://doi.org/10.5606/kbbihtisas.2012.053>
1903. Kim SJ, Kim BS, Choi CW, et al. Treatment outcome of front-line systemic chemotherapy for localized extranodal NK/T cell lymphoma in nasal and upper aerodigestive tract. *Leuk Lymphoma*. 2006;47(7):1265-1273. <https://doi.org/10.1080/10428190600565651>
1904. Aviles A, Diaz NR, Neri N, Cleto S, Talavera A. Angiocentric nasal T/natural killer cell lymphoma: a single centre study of prognostic factors in 108 patients. *Clin Lab Haematol*. 2000;22(4):215-220. <https://doi.org/10.1046/j.1365-2257.2000.00307.x>
1905. Rodriguez J, Romaguera JE, Manning J, et al. Nasal-type T/NK lymphomas: a clinicopathologic study of 13 cases. *Leuk Lymphoma*. 2000;39(1-2):139-144. <https://doi.org/10.3109/10428190009053547>
1906. Sakata K, Hareyama M, Ohuchi A, et al. Treatment of lethal midline granuloma type nasal T-cell lymphoma. *Acta Oncol*. 1997;36(3):307-311. <https://doi.org/10.3109/02841869709001268>
1907. Senan S, Symonds RP, Brown IL. Nasal peripheral T-cell lymphoma: a 20-year review of cases treated in Scotland. *Clin Oncol*. 1992;4(2):96-100.
1908. Bernstein JM, Montgomery WW, Balogh K. Metastatic tumors to the maxilla, nose, and paranasal sinuses. *Laryngoscope*. 1966;76(4):621-650. <https://doi.org/10.1288/00005537-196604000-00003>

1909. Aziz SA, Sznol J, Adeniran A, Colberg JW, Camp RL, Kluger HM. Vascularity of primary and metastatic renal cell carcinoma specimens. *J Transl Med.* 2013;11(1):15. <https://doi.org/10.1186/1479-5876-11-15>
1910. Chang MH, Kuo YJ, Ho CY, Kuan EC, Lan MY. Metastatic tumors of the sinonasal cavity: a 15-year review of 17 cases. *J Clin Med.* 2019;8(4):539. <https://doi.org/10.3390/jcm8040539>
1911. Huang HH, Fang TJ, Chang PH, Lee TJ. Sinonasal metastatic tumors in Taiwan. *Chang Gung Med J.* 2008;31(5):457-462.
1912. Lopez F, Devaney KO, Hanna EY, Rinaldo A, Ferlito A. Metastases to nasal cavity and paranasal sinuses. *Head Neck.* 2016;38(12):1847-1854. <https://doi.org/10.1002/hed.24502>
1913. Bizon JG, Newman RK. Metastatic melanoma to the ethmoid sinus. *Arch Otolaryngol Head Neck Surg.* 1986;112(6):664-667. <https://doi.org/10.1001/archotol.1986.03780060076012>
1914. Azoury SC, Crompton JG, Straughan DM, et al. Unknown primary nasopharyngeal melanoma presenting as severe recurrent epistaxis and hearing loss following treatment and remission of metastatic disease: a case report and literature review. *Int J Surg Case Rep.* 2015;10:232-235. <https://doi.org/10.1016/j.ijscr.2015.03.053>
1915. Hong SL, Jung DW, Roh HJ, Cho KS. Metastatic renal cell carcinoma of the posterior nasal septum as the first presentation 10 years after nephrectomy. *J Oral Maxillofac Surg.* 2013;71(10):1813.e1-1813.7. <https://doi.org/10.1016/j.joms.2013.06.200>
1916. Nahum AM, Bailey BJ. Malignant tumors metastatic to the paranasal sinuses: case report and review of the literature. *Laryngoscope.* 1963;73:942-953. <https://doi.org/10.1288/00005537-196307000-00009>
1917. Gottlieb MD, Roland JT. Paradoxical spread of renal cell carcinoma to the head and neck. *Laryngoscope.* 1998;108(9):1301-1305. <https://doi.org/10.1097/00005537-199809000-00007>
1918. Monserez D, Vlamincck S, Kuhweide R, Casselman J. Symmetrical ethmoidal metastases from ductal carcinoma of the breast, suggesting transcribrosal spread. *Acta Otorhinolaryngol Belg.* 2001;55(3):251-257.
1919. Nicholson BD, Shinkins B, Pathiraja I. Blood CEA levels for detecting recurrent colorectal cancer. *Cochrane Database Syst Rev.* 2014;2014(6):CD011134. <https://doi.org/10.1002/14651858.CD011134>
1920. Jeppesen AN, Jensen HK, Donskov F, Marcussen N, von der Maase H. Hyponatremia as a prognostic and predictive factor in metastatic renal cell carcinoma. *Br J Cancer.* 2010;102(5):867-872. <https://doi.org/10.1038/sj.bjc.6605563>
1921. Mickel RA, Zimmerman MC. The sphenoid sinus—a site for metastasis. *Otolaryngol Head Neck Surg.* 1990;102(6):709-716. <https://doi.org/10.1177/019459989010200614>
1922. Simo R, Sykes AJ, Hargreaves SP, et al. Metastatic renal cell carcinoma to the nose and paranasal sinuses. *Head Neck.* 2000;22(7):722-727. [https://doi.org/10.1002/1097-0347\(200010\)22:7<722::aid-hed13>3.0.co;2-0](https://doi.org/10.1002/1097-0347(200010)22:7<722::aid-hed13>3.0.co;2-0)
1923. Remenschneider AK, Sadow PM, Lin DT, Gray ST. Metastatic renal cell carcinoma to the sinonasal cavity: a case series. *J Neurol Surg Rep.* 2013;74(2):67-72. <https://doi.org/10.1055/s-0033-1346972>
1924. Kent SE, Majumdar B. Metastatic tumours in the maxillary sinus. A report of two cases and a review of the literature. *J Laryngol Otol.* 1985;99(5):459-462. <https://doi.org/10.1017/s0022215100097048>
1925. Palma DA, Olson R, Harrow S, et al. Stereotactic ablative radiotherapy versus standard of care palliative treatment in patients with oligometastatic cancers (SABR-COMET): a randomised, phase 2, open-label trial. *Lancet.* 2019;393(10185):2051-2058. [https://doi.org/10.1016/S0140-6736\(18\)32487-5](https://doi.org/10.1016/S0140-6736(18)32487-5)
1926. Hashim H, Rahmat K, Abdul Aziz YF, Chandran PA. Metastatic hepatocellular carcinoma presenting as a sphenoid sinus mass and meningeal carcinomatosis. *Ear Nose Throat J.* 2014;93(6):E20-E23.
1927. Matsuda H, Tanigaki Y, Yoshida T, Matsuda R, Tsukuda M. A case of metastatic hepatocellular carcinoma in the nasal cavity. *Eur Arch Otorhinolaryngol.* 2006;263(4):305-307. <https://doi.org/10.1007/s00405-005-1000-8>
1928. Tabaee A, Nyquist G, Anand VK, Singh A, Kacker A, Schwartz TH. Palliative endoscopic surgery in advanced sinonasal and anterior skull base neoplasms. *Otolaryngol Head Neck Surg.* 2010;142(1):126-128. <https://doi.org/10.1016/j.otohns.2009.09.021>
1929. Roberts JM, Brook C, Parnes S. Palliative endoscopic surgery for sinonasal metastases: a case report and literature review. *Ear Nose Throat J.* 2015;94(2):E24-E26. <https://doi.org/10.1177/014556131509400215>
1930. Bastier PL, Dunion D, de Bonnecaze G, Serrano E, de Gabory L. Renal cell carcinoma metastatic to the sinonasal cavity: a review and report of 8 cases. *Ear Nose Throat J.* 2018;97(9):E6-E12. <https://doi.org/10.1177/014556131809700902>
1931. Roh HJ, Batra PS, Citardi MJ, Lee J, Bolger WE, Lanza DC. Endoscopic resection of sinonasal malignancies: a preliminary report. *Am J Rhinol.* 2004;18(4):239-246.
1932. Kakati K, Pai P. Rare malignancies of sinonasal tract. *J Neurol Surg B.* 2018;79(S 01):S1-S188. <https://doi.org/10.1055/s-0038-1633445>
1933. Sakthivel P, Kumar Irugu DV, Kakkar A, et al. Squamous cell carcinoma as a somatic-type malignancy in an extragonadal immature teratoma of the sinonasal region. *Int J Pediatr Otorhinolaryngol.* 2019;126:109639. <https://doi.org/10.1016/j.ijporl.2019.109639>
1934. Redhu R, Singhal S, Rajput S, Swetha H. Simultaneous combined single stage removal of immature teratoma at anterior skull base: a case report. *Clin Neurol Neurosurg.* 2012;114(10):1379-1381. <https://doi.org/10.1016/j.clineuro.2012.03.037>
1935. Bell D, Bell A, Ferrarotto R, et al. High-grade sinonasal carcinomas and surveillance of differential expression in immune related transcriptome. *Ann Diagn Pathol.* 2020;49:151622. <https://doi.org/10.1016/j.anndiagpath.2020.151622>
1936. Abt AB, Tokar C. Malignant teratoma of the paranasal sinuses. *Arch Pathol.* 1970;90(2):176-180.
1937. Patchefsky A, Sundmaker W, Marden PA. Malignant teratoma of the ethmoid sinus. Report of a case. *Cancer.* 1968;21(4):714-721. [https://doi.org/10.1002/1097-0142\(196804\)21:4<714::aid-cnrc2820210424>3.0.co;2-j](https://doi.org/10.1002/1097-0142(196804)21:4<714::aid-cnrc2820210424>3.0.co;2-j)
1938. Bernbeck B, Schneider DT, Bernbeck B, et al. Germ cell tumors of the head and neck: report from the MAKEI Study Group. *Pediatr Blood Cancer.* 2009;52(2):223-226. <https://doi.org/10.1002/pbc.21752>

1939. Abdulfatah E, Brown N, Reichert Z, et al. Extragonadal germ cell tumors: a comprehensive study with emphasis on morphological features, clinical outcomes and associated secondary malignancies. *Mod Pathol.* 2022;35:547.
1940. Xanthopoulos J, Assimakopoulos D, Noussios G, Mouratidou D. Testicular tumor metastatic to the nose. A case report. *Acta Otorhinolaryngol Belg.* 2000;54(4):479-482.
1941. Tariq M, Gluckman P, Thebe P. Metastatic testicular teratoma of the nasal cavity: a rare cause of severe intractable epistaxis. *J Laryngol Otol.* 1998;112(11):1078-1081. <https://doi.org/10.1017/S0022215100142501>
1942. Stephenson JA, Mayland DM, Kun LE, Etcubanas E, Thompson EI, Gross CW. Malignant germ cell tumors of the head and neck in childhood. *Laryngoscope.* 1989;99(7, Pt. 1):732-735. <https://doi.org/10.1288/00005537-198907000-00013>
1943. Dehner LP, Mills A, Talerma A, Billman GF, Krous HF, Platz CE. Germ cell neoplasms of head and neck soft tissues: a pathologic spectrum of teratomatous and endodermal sinus tumors. *Hum Pathol.* 1990;21(3):309-318. [https://doi.org/10.1016/0046-8177\(90\)90232-t](https://doi.org/10.1016/0046-8177(90)90232-t)
1944. Stanley MW, Powers CN, Pitman MB, Korourian S, Bardales RH, Khurana K. Cytology of germ cell tumors: extragonadal, extracranial masses and intraoperative problems. *Cancer.* 1997;81(4):220-227.
1945. Nair R, Krishnamurthy S, Advani SH. Maxillary extragonadal germ cell tumor: a case report. *Indian J Cancer.* 1993;30(4):202-204.
1946. Weil AG, Mathews N, Farmer JP, et al. Successful treatment of non-midline primary malignant germ cell tumors with yolk sac components in neonates: report of 2 cases. *J Neurosurg Pediatr.* 2020;27(1):47-51. <https://doi.org/10.3171/2020.6.PEDS19719>
1947. Mishra A, El-Naggar AK, DeMonte F, Hanna EY. Endodermal sinus tumor of the paranasal sinuses. *Head Neck.* 2008;30(4):539-543. <https://doi.org/10.1002/hed.20711>
1948. Andaz C, Alsanjari N, Garth RJ, Dearnaley DP. Metastatic seminoma of the sphenoid sinus. *J Laryngol Otol.* 1991;105(12):1075-1078. <https://doi.org/10.1017/s0022215100118237>
1949. Filho BCA, McHugh JB, Carrau RL, Kassam AB. Yolk sac tumor in the nasal cavity. *Am J Otolaryngol.* 2008;29(4):250-254. <https://doi.org/10.1016/j.amjoto.2007.09.001>
1950. Chuang HC, Kang CJ, Lee L-y. Sinonasal pure yolk sac tumor: a case report and literature review. *Fetal Pediatr Pathol.* 2014;33(3):127-134. <https://doi.org/10.3109/15513815.2013.839013>
1951. Kusumakumari P, Geetha N, Chellam VG, Nair MK. Endodermal sinus tumors in the head and neck region. *Med Pediatr Oncol.* 1997;29(4):303-307. [https://doi.org/10.1002/\(sici\)1096-911x\(199710\)29:4<303::aid-mpo12>3.0.co;2-b](https://doi.org/10.1002/(sici)1096-911x(199710)29:4<303::aid-mpo12>3.0.co;2-b)
1952. Chimona TS, Koutsopoulos AV, Malliotakis P, Nikolidakis A, Skoulakis C, Bizakis JG. Malignant mixed tumor of the nasal cavity. *Auris Nasus Larynx.* 2006;33(1):63-66. <https://doi.org/10.1016/j.anl.2005.07.018>
1953. Gangopadhyay K, McArthur PD, Martin JM, Saleem M. Endodermal sinus tumor of the maxillary sinus: a case report. *Ear Nose Throat J.* 1999;78(5):376-377, 381-382.
1954. Zamecnik M, Rychnovsky J, Syrovatka J. Sinonasal SMARCB1 (INI1) deficient carcinoma with yolk sac tumor differentiation: report of a case and comparison with INI1 expression in gonadal germ cell tumors. *Int J Surg Pathol.* 2018;26(3):245-249. <https://doi.org/10.1177/1066896917741549>
1955. Manivel C, Wick MR, Dehner LP. Transitional (cylindric) cell carcinoma with endodermal sinus tumor-like features of the nasopharynx and paranasal sinuses. Clinicopathologic and immunohistochemical study of two cases. *Arch Pathol Lab Med.* 1986;110(3):198-202.
1956. Alwasiak J, Polis Z, Zawadzki Z. A case of endodermal sinus tumor (yolk sac tumor). *Neuropatol Pol.* 1976;14(4):479-484.
1957. Bresters D, Zwaan CM, Veerman AJP, Leemans CR, Westerveld GJ, Van Der Linden JC. A three-year-old girl with a yolk sac tumor in the orbit/maxillary sinus. *Med Pediatr Oncol.* 2003;40(1):70-71. <https://doi.org/10.1002/mpo.1375>
1958. Sungur A, Ozbay G, Dogan A, Ozyilmaz F, Ataman M. An endodermal sinus tumor of the head and neck region. *Int J Pediatr Otorhinolaryngol.* 1993;26(2):177-180. [https://doi.org/10.1016/0165-5876\(93\)90024-W](https://doi.org/10.1016/0165-5876(93)90024-W)
1959. Shin J, Kim JH, Jung KC, Cho KJ. A sinonasal yolk sac tumor in an adult. *J Pathol Transl Med.* 2022;56(3):152-156. <https://doi.org/10.4132/jptm.2021.12.09>
1960. Shen YH, Jiang SY. Primary yolk sac tumor of pterygopalatine fossa with loss of vision: a case report. *Medicine.* 2021;100(8):e24916. <https://doi.org/10.1097/MD.00000000000024916>
1961. Talerma A, Haije WG, Baggerman L. Alpha-1 antitrypsin (AAT) and alphafoetoprotein (AFP) in sera of patients with germ-cell neoplasms: value as tumour markers in patients with endodermal sinus tumour (yolk sac tumour). *Int J Cancer.* 1977;19(6):741-746. <https://doi.org/10.1002/ijc.2910190602>
1962. Hazir B, Şimşek B, Erdemir A, et al. Sinonasal SMARCB1 (INI1) deficient carcinoma with yolk sac tumor differentiation: a case report and treatment options. *Head and Neck Pathol.* 2022;16(2):596-601. <https://doi.org/10.1007/s12105-021-01375-9>
1963. Li CY, Han Y-m, Xu K, Wu S-y, Lin XY, Cao H-y. Case report: SMARCB1 (INI-1)-deficient carcinoma of the nasal cavity with pure yolk sac tumor differentiation and elevated serum AFP levels. *Onco Targets Ther.* 2021;14:2227-2233. <https://doi.org/10.2147/OTT.S302613>
1964. Hauser LJ, Chiang T, Ramakrishnan VR, Lovell MA, Kelley PE. Parapharyngeal and skull base yolk sac tumor: a case report with lessons in diagnosis and management. *Int J Pediatr Otorhinolaryngol.* 2014;78(11):2003-2006. <https://doi.org/10.1016/j.ijporl.2014.08.027>
1965. Arumugam D. Primary nasopharyngeal yolk sac tumor: a case report. *J Clin Diagn Res.* 2016;10(5):ED06-ED07. <https://doi.org/10.7860/JCDR/2016/17620.7760>
1966. Mei X, Xia Y, Sasano H, Gao H. Sinonasal yolk sac (endodermal sinus) tumor in an adult female—a case report and review of the literature. *APMIS.* 2015;123(9):810-814. <https://doi.org/10.1111/apm.12409>
1967. Tariq M, Kalan A. Metastatic choniocarcinoma of the nasal cavity-presenting as intractable epistaxis. *Indian J Otolaryngol Head Neck Surg.* 2004;56(3):220-222. <https://doi.org/10.1007/BF02974356>
1968. Roy M, Agarwal S, Gupta A, Bakhshi S, Bhalla AS. Extragonadal yolk sac tumor of the head and neck region: a report of

- two cases. *J Cancer Res Ther.* 2015;11(4):1000-1002. <https://doi.org/10.4103/0973-1482.157305>
1969. Alici S, Bavbek SE, Eralp Y, et al. An atypical presentation of metastatic gestational choriocarcinoma with maxillary sinus and subcutaneous involvement; report of a case with literature review. *J BUON.* 2002;7(4):373-376.
1970. Sharkawi E. Metastatic choriocarcinoma causing cavernous sinus syndrome. *Br J Ophthalmol.* 2006;90(5):654-655. <https://doi.org/10.1136/bjo.2005.086744>
1971. Singh B. Metastatic choriocarcinoma of the maxilla: an unusual cause of severe intractable epistaxis. *J Laryngol Otol.* 1992;106(10):917-922. <https://doi.org/10.1017/s0022215100121280>
1972. Rhinology/allergy. *Otolaryngol Head Neck Surg.* 2018;159(S1):316-323. <https://doi.org/10.1177/0194599818787193i>
1973. Bell D, Hanna EY, Agaimy A, Weissferdt A. Reappraisal of sinonasal undifferentiated carcinoma: SMARCB1 (INI1)-deficient sinonasal carcinoma: a single-institution experience. *Virchows Arch.* 2015;467(6):649-656. <https://doi.org/10.1007/s00428-015-1853-1>
1974. Gazzilli M, Albano D, Ardighieri L, Bertagna F, Giubbini R. Primary nasal-ethmoid choriocarcinoma detected by 18F-FDG PET/CT: a rare tumor with complete remission. *Nucl Med Rev Cent East Eur.* 2020;23(2):105-107. <https://doi.org/10.5603/NMR.a2020.0012>
1975. Sonobe H, Hayashi K, Takahashi K, et al. True carcinosarcoma of the maxillary sinus. *Pathol Res Pract.* 1989;185(4):488-492. [https://doi.org/10.1016/S0344-0338\(89\)80070-6](https://doi.org/10.1016/S0344-0338(89)80070-6)
1976. Shindo ML, Stanley RB, Kiyabu MT. Carcinosarcoma of the nasal cavity and paranasal sinuses. *Head Neck.* 1990;12(6):516-519. <https://doi.org/10.1002/hed.2880120613>
1977. Furuta Y, Nojima T, Terakura N, Fukuda S, Inuyama Y. A rare case of carcinosarcoma of the maxillary sinus with osteosarcomatous differentiation. *Auris Nasus Larynx.* 2001;28(Suppl. 1):S127-129. [https://doi.org/10.1016/s0385-8146\(00\)00104-8](https://doi.org/10.1016/s0385-8146(00)00104-8)
1978. Sanabre AA, Gonzalez-Lagunas J, Redecilla PH, Martin GR. Carcinosarcoma of the maxillary sinus: a case report. *J Oral Maxillofac Surg.* 1998;56(12):1456-1460. [https://doi.org/10.1016/S0278-2391\(98\)90417-7](https://doi.org/10.1016/S0278-2391(98)90417-7)
1979. Sun KW, Dong Z, Zhu AF. Carcinosarcoma of the maxillary sinus: a case report. *Zhonghua Er Bi Yan Hou Tou Jing Wai Ke Za Zhi.* 2008;43(3):231-232.
1980. Subha ST, Doi M, Mohd Yatim NY. Carcinosarcoma of the maxillary sinus: a case report. *Iran J Blood Cancer.* 2020;12(3):101-103.
1981. Bartram J, Scholfield DW, Adams A, Alusi G, Cottom H. Sinonasal carcinosarcoma with cartilaginous and rhabdomyoblastic components: a previously undescribed entity. *Oral Surg Oral Med Oral Pathol Oral Radiol.* 2022;134(5):e287-e298. <https://doi.org/10.1016/j.oooo.2022.02.019>
1982. Kuo CC, Viola F, DeGiovanni JC, DeVictor S, Belles WJ. Carcinosarcoma of the nasal septum: a case report and review of the literature. *Cureus.* 2021;13(10):e18546. <https://doi.org/10.7759/cureus.18546>
1983. de Souza Cruz EL, de Moraes ATL, de Souza Neves Filho F, et al. A rare case of invasive sinonasal carcinosarcoma. *Int J Surg Case Rep.* 2020;70:243-248. <https://doi.org/10.1016/j.ijscr.2020.04.072>
1984. Sayad Z, Dani B, Azzouzi RE, et al. Therapeutic management and prognostic profile of a patient with maxillary sarcomatoid carcinoma (case report). *Pan Afr Med J.* 2021;38:212. <https://doi.org/10.11604/pamj.2021.38.212.26602>
1985. Talei B, Parashar B, Kutler D. Temporary brachytherapy seed mesh in the treatment of a radiation-induced sinonasal carcinosarcoma: a case report and literature review. *J Neurol Surg B.* 2012;73(S 01):s-0032-1312321. <https://doi.org/10.1055/s-0032-1312321>
1986. Alotaiby F, Islam MN, Bhattacharyya I, Cohen DM, Drew PA, Lai J. Carcinosarcoma arising from inverted papilloma in a patient with history of radiotherapy for sinonasal squamous cell carcinoma. *Am J Case Rep.* 2020;21:e921827. <https://doi.org/10.12659/AJCR.921827>
1987. Yuen J, Varadarajan V, Stavrakas M, Muquit S, Khalil H. A case of invasive sinonasal carcinosarcoma: the importance of early detection. *Case Rep Otolaryngol.* 2018;2018:1-5. <https://doi.org/10.1155/2018/2745973>
1988. Hasnaoui J, Anajar S, Tatari M, et al. Carcinosarcoma of the maxillary sinus: a rare case report. *Ann Med Surg.* 2017;19:41-44. <https://doi.org/10.1016/j.amsu.2017.05.036>
1989. Ando M, Saito Y, Morikawa T, et al. Maxillary carcinosarcoma: identification of a novel MET mutation in both carcinomatous and sarcomatous components through next generation sequencing. *Head Neck.* 2015;37(12):E179-E185. <https://doi.org/10.1002/hed.24043>
1990. Moon JK, Kim AY, Chang DS, Park KY. Carcinosarcoma of the maxillary sinus. *Clin Exp Otorhinolaryngol.* 2013;6(2):114-116. <https://doi.org/10.3342/ceo.2013.6.2.114>
1991. Patel TD, Vázquez A, Plitt MA, Baredes S, Eloy JA. A case-control analysis of survival outcomes in sinonasal carcinosarcoma. *Am J Otolaryngol.* 2015;36(2):200-204. <https://doi.org/10.1016/j.amjoto.2014.10.031>
1992. Cheong JP, Rahayu S, Halim A, Khir A, Noorafidah D. Report of a rare case of carcinosarcoma of the maxillary sinus with sternal metastasis. *Ear Nose Throat J.* 2014;93(6):E1-E4.
1993. Raju U, Kini R, Warriar R. An unusual embryonal tumor of the nasal cavity in a neonate—a nasal blastoma? A clinical, histologic, and ultrastructural study. *Mod Pathol.* 1989;2(6):681-686.
1994. Devgan BK, Devgan M, Gross CW. Teratocarcinoma of the ethmoid sinus: review of literature plus a new case report. *Otolaryngology.* 1978;86(5):ORL-689-695. <https://doi.org/10.1177/019459987808600504>
1995. Shanmugaratnam K, Kunaratnam N, Chia KB, Chiang GS, Sinniah R. Teratoid carcinosarcoma of the paranasal sinuses. *Pathology.* 1983;15(4):413-419. <https://doi.org/10.3109/00313028309085168>
1996. Heffner DK, Hyams VJ. Teratocarcinosarcoma (malignant teratoma?) of the nasal cavity and paranasal sinuses: A clinicopathologic study of 20 cases. *Cancer.* 1984;53(10):2140-2154. [https://doi.org/10.1002/1097-0142\(19840515\)53:10\(2140::aid-cncr2820531025\)3.0.co;2-y](https://doi.org/10.1002/1097-0142(19840515)53:10(2140::aid-cncr2820531025)3.0.co;2-y)
1997. Pai SA, Naresh KN, Masih K, Ramarao C, Borges AM. Teratocarcinosarcoma of the paranasal sinuses: a clinicopathologic and immunohistochemical study. *Hum Pathol.* 1998;29(7):718-722. [https://doi.org/10.1016/s0046-8177\(98\)90281-7](https://doi.org/10.1016/s0046-8177(98)90281-7)
1998. Fernández PL, Cardesa A, Alós L, Pinto J, Traserra J. Sinonasal teratocarcinosarcoma: an unusual neoplasm. *Pathol Res Pract.*

- 1995;191(2):166-171; discussion 172-173. [https://doi.org/10.1016/S0344-0338\(11\)80567-4](https://doi.org/10.1016/S0344-0338(11)80567-4)
1999. Thomas J, Adegboyega P, Iloabachie K, Mooring JW, Lian T. Sinonasal teratocarcinoma with yolk sac elements: a neoplasm of somatic or germ cell origin? *Ann Diagn Pathol*. 2011;15(2):135-139. <https://doi.org/10.1016/j.anndiagpath.2010.01.004>
2000. Gadban H, Talmon Y, Samet A, Cohen I. Malignant teratocarcinoma of the nose and paranasal sinuses. *Harefuah*. 2002;141(5):430-432, 499.
2001. Wei S, Carroll W, Lazenby A, Bell W, Lopez R, Said-Al-Naief N. Sinonasal teratocarcinoma: report of a case with review of literature and treatment outcome. *Ann Diagn Pathol*. 2008;12(6):415-425. <https://doi.org/10.1016/j.anndiagpath.2007.05.003>
2002. Shemen L, Galantich P, Murali R. Malignant teratocarcinoma of the sphenoid sinus. *Otolaryngol Head Neck Surg*. 1995;112(3):496-500. <https://doi.org/10.1016/S0194-59989570294-6>
2003. Stuyt MT, Revilla Borjas C, Delgado de Fox M. Teratocarcinoma of the ethmoid. A clinical case report. *An Otorrinolaringol Ibero Am*. 1990;17(6):663-668.
2004. Su YY, Friedman M, Huang CC, Wilson M, Lin HC. Sinonasal teratocarcinoma. *Am J Otolaryngol*. 2010;31(4):300-303. <https://doi.org/10.1016/j.amjoto.2009.02.022>
2005. Takasaki K, Sakihama N, Takahashi H. A case with sinonasal teratocarcinoma in the nasal cavity and ethmoid sinus. *Eur Arch Otorhinolaryngol*. 2006;263(6):586-591. <https://doi.org/10.1007/s00405-006-0014-1>
2006. Smith SL, Hessel AC, Luna MA, Malpica A, Rosenthal DI, El-Naggar AK. Sinonasal teratocarcinoma of the head and neck: a report of 10 patients treated at a single institution and comparison with reported series. *Arch Otolaryngol Head Neck Surg*. 2008;134(6):592-595. <https://doi.org/10.1001/archotol.134.6.592>
2007. Wellman M, Kerr PD, Battistuzzi S, Cristante L. Paranasal sinus teratocarcinoma with intradural extension. *J Otolaryngol*. 2002;31(3):173-176. <https://doi.org/10.2310/7070.2002.10895>
2008. Terasaka S, Medary MB, Whiting DM, Fukushima T, Espejo EJ, Nathan G. Prolonged survival in a patient with sinonasal teratocarcinoma with cranial extension. Case report. *J Neurosurg*. 1998;88(4):753-756. <https://doi.org/10.3171/jns.1998.88.4.0753>
2009. Oka K, Kanayama R, Fukunaga M, et al. Nasal teratocarcinoma - a case report. *Pathol Res Pract*. 2007;203(7):549-553. <https://doi.org/10.1016/j.prp.2007.03.007>
2010. Chao KK, Eng TY, Barnes J, Dahiya R. Sinonasal teratocarcinoma. *Am J Clin Oncol*. 2004;27(1):29-32. <https://doi.org/10.1097/O1.coc.0000045851.76922.2E>
2011. Salem F, Rosenblum MK, Jhanwar SC, Kancherla P, Ghossein RA, Carlson DL. Teratocarcinoma of the nasal cavity and paranasal sinuses: report of 3 cases with assessment for chromosome 12p status. *Hum Pathol*. 2008;39(4):605-609. <https://doi.org/10.1016/j.humpath.2007.09.002>
2012. Wang S-y, Zhu L, Li S-m, et al. Sinonasal teratocarcinoma: a clinical, radiologic and pathologic study of 5 cases. *Zhonghua Bing Li Xue Za Zhi*. 2007;36(8):534-538.
2013. Kim JH, Maeng YH, Lee JS, Jung S, Lim SC, Lee MC. Sinonasal teratocarcinoma with rhabdoid features. *Pathol Int*. 2011;61(12):762-767. <https://doi.org/10.1111/j.1440-1827.2011.02733.x>
2014. Endo H, Hirose T, Kuwamura KI, Sano T. Case report: sinonasal teratocarcinoma. *Pathol Int*. 2001;51(2):107-112. <https://doi.org/10.1046/j.1440-1827.2001.01170.x>
2015. Shimazaki H, Aida S, Tamai S, Miyazawa T, Nakanobou M. Sinonasal teratocarcinoma: ultrastructural and immunohistochemical evidence of neuroectodermal origin. *Ultrastruct Pathol*. 2000;24(2):115-122. <https://doi.org/10.1080/01913120050118602>
2016. Ogawa T, Ikeda K, Watanabe M, et al. A case report of sinonasal teratocarcinoma. *Tohoku J Exp Med*. 2000;190(1):51-59. <https://doi.org/10.1620/tjem.190.51>
2017. Mohanty S, Somu L, Gopinath M. Sino nasal teratocarcinoma—an interesting clinical entity. *Indian J Surg*. 2013;75(Suppl. 1):141-142. <https://doi.org/10.1007/s12262-012-0510-z>
2018. Adams DR, Ramirez-Garcia R, Ginat DT, et al. Multimodality management of sinonasal teratocarcinoma in a 76-year-old Alaska Native female during the COVID-19 pandemic. *Clin Case Rep*. 2022;10(3):e05635. <https://doi.org/10.1002/ccr3.5635>
2019. Sobani ZA, Akhtar S, Junaid M, Salahuddin I. Sinonasal teratocarcinoma. *J Pak Med Assoc*. 2012;62(6):633-635.
2020. Wilson C, Mann D, Fung KM, Dunn I, McKinney K. Sinonasal teratocarcinoma: a case report of a rare entity. *J Neurol Surg B Skull Base*. 2022;83(S 01):S1-S270. <https://doi.org/10.1055/s-0042-1743977>
2021. Fatima SS, Minhas K, Din NU, Fatima S, Ahmed A, Ahmad Z. Sinonasal teratocarcinoma: a clinicopathologic and immunohistochemical study of 6 cases. *Ann Diagn Pathol*. 2013;17(4):313-318. <https://doi.org/10.1016/j.anndiagpath.2013.01.003>
2022. Shimmi R, Sakurai D, Ohki Y, Iinuma T, Yamasaki K, Hanazawa T. A clinical study of sinonasal teratocarcinoma: report of four cases. *Toukeibu Gan*. 2020;46(3):311-316. <https://doi.org/10.5981/jjhnc.46.311>
2023. Agrawal N, Chintagumpala M, Hicks J, Eldin K, Paulino AC. Sinonasal teratocarcinoma in an adolescent male. *J Pediatr Hematol Oncol*. 2012;34(7):e304-e307. <https://doi.org/10.1097/MPH.0b013e318266baa8>
2024. Sunil D, Chelakkot PG, Renilmon PS, Nair HM. Sinonasal teratocarcinoma: a rare aggressive tumour and a challenge for the clinician. *J Cancer Res Ther*. 2016;12:S52.
2025. Yang S, Sun R, Liang J, Zhou Z, Zhou J, Rui J. Sinonasal teratocarcinoma: a clinical and pathological analysis. *Int J Surg Pathol*. 2013;21(1):37-43. <https://doi.org/10.1177/1066896912457202>
2026. Chakraborty S, Chowdhury A, Bandyopadhyay G. Sinonasal teratocarcinoma: case report of an unusual neoplasm. *J Oral Maxillofac Pathol*. 2016;20(1):147-150. <https://doi.org/10.4103/0973-029X.180979>
2027. Mondal SK, Mandal PK, Guha A, Roy S. Sinonasal teratocarcinoma of the ethmoid and paranasal sinus: a rare neoplasm. *J Res Med Sci*. 2012;17(6):575-577.

2028. Yang Z, Uppaluri R, Lewis JS. Ethmoid sinus mass. Sinonasal teratocarcinoma. *JAMA Otolaryngol Head Neck Surg.* 2015;141(4):389-390. <https://doi.org/10.1001/jamaoto.2015.22>
2029. Szudek J, Bullock M, Taylor SM. Sinonasal teratocarcinoma involving the cavernous sinus. *J Otolaryngol.* 2005;34(4):286-288. <https://doi.org/10.2310/7070.2005.34421>
2030. Sharma HS, Abdullah JM, Othman NH, Muhamad M. Teratocarcinoma of the nasal cavity and ethmoid. *J Laryngol Otol.* 1998;112(7):682-686. <https://doi.org/10.1017/s0022215100141453>
2031. Joko H. A case of teratocarcinoma in nasal septum. *Otolaryngol Head Neck Surg.* 1997;69:560-564.
2032. Wahid FI, Javaid M, Khan Q, Khan IA. Sinonasal teratocarcinoma. *J Coll Physicians Surg Pak.* 2012;22(5):335-337.
2033. Sakci Z, Aydin F, Ceylan O, Ogul H. Sinonasal teratocarcinoma mimicking chronic invasive fungal disease of paranasal sinuses. *Annals.* 2021;103(6):e193-e195. <https://doi.org/10.1308/rcsann.2020.7088>
2034. Rao Y-f, Cheng D-n, Qiu K, et al. Sinonasal teratocarcinoma: a case report and literature review. *J Int Med Res.* 2020;48(12):030006052097148. <https://doi.org/10.1177/0300060520971488>
2035. Foong YC, Murdolo V, Naiman N, Hepner L, Awad R. Sinonasal teratocarcinoma: a case report. *J Med Case Reports.* 2017;11(1):167. <https://doi.org/10.1186/s13256-017-1327-y>
2036. Sable M, Kakkar A, Garg K, Suri V. Sinonasal teratocarcinoma: an underdiagnosed entity posing diagnostic challenges. *Turk Neurosurg.* 2017;27(3):468-471. <https://doi.org/10.5137/1019-5149.JTN.13092-14.1>
2037. Kurmi D, Mittal R, Sharma A, Gandhi A, Singhvi S. Sinonasal teratocarcinoma involving nasal cavity, nasopharynx, and all paranasal sinuses with bilateral orbital and intracranial extension: a rare case report. *Asian J Neurosurg.* 2017;12(02):232-240. <https://doi.org/10.4103/1793-5482.145559>
2038. Joshi A, Noronha V, Sharma M, et al. Neoadjuvant chemotherapy in advanced sinonasal teratocarcinoma with intracranial extension: report of two cases with literature review. *J Cancer Res Ther.* 2015;11(4):1003-1005. <https://doi.org/10.4103/0973-1482.165878>
2039. Fukuoka K, Hirokawa M, Shimizu M, et al. Teratocarcinoma of the nasal cavity. Report of a case showing favorable prognosis. *APMIS.* 2000;108(9):553-557. <https://doi.org/10.1034/j.1600-0463.2000.d01-96.x>
2040. Rooper LM, Uddin N, Gagan J, et al. Recurrent loss of SMARCA4 in sinonasal teratocarcinoma. *Am J Surg Pathol.* 2020;44(10):1331-1339. <https://doi.org/10.1097/PAS.0000000000001508>
2041. Belardinilli F, De Vincentiis L, D'Ecclesia A, Giannini G, Giangaspero F, Corsi A. PIK3CA somatic mutation in sinonasal teratocarcinoma. *Auris Nasus Larynx.* 2021;48(3):530-534. <https://doi.org/10.1016/j.anl.2020.03.006>
2042. Compton ML, Lewis JS, Faquin WC, Cipriani NA, Shi Q, Ely KA. SALL-4 and beta-catenin expression in sinonasal teratocarcinoma. *Head Neck Pathol.* 2022;16(1):229-235. <https://doi.org/10.1007/s12105-021-01343-3>
2043. Gupta S, Naik S, Lnu N, et al. Sinonasal teratocarcinoma: a rare clinical entity managed by medial maxillectomy and adjuvant chemoradiation. *Int J Clin Rhinol.* 2012;5(3):118-122. <https://doi.org/10.5005/jp-journals-10013-1131>
2044. Peng G, Ke Y, Wang T, Feng Y, Li Y, Wu G. Intensity-modulated radiotherapy for sinonasal teratocarcinoma. *J Huazhong Univ Sci Technolog Med Sci.* 2011;31(6):857-860. <https://doi.org/10.1007/s11596-011-0691-x>
2045. Kane SV, Karpate AA, Bal M, Juvekar SL, Pai PS. Chemotherapy-induced neuronal maturation in sinonasal teratocarcinoma—a unique observation. *Head Neck Pathol.* 2009;3(1):31-36. <https://doi.org/10.1007/s12105-008-0094-x>
2046. Nitsche M, Hermann RM, Christiansen H, Berger J, Pradier O. Rationale for individualized therapy in Sinonasal Teratocarcinoma (SNTC): case report. *Onkologie.* 2005;28(12):653-656. <https://doi.org/10.1159/000089146>
2047. Liu JK, Eloy JA. Modified one-piece extended transbasal approach for resection of giant anterior skull base sinonasal teratocarcinoma. *Neurosurg Focus.* 2012;32(Suppl. 1):E4. <https://doi.org/10.3171/2012.V4.FOCUS11301>
2048. Belotti A, Carpenito L, Bulfamante AM, Maccari A, Bulfamante G. Sinonasal teratocarcinoma treated with surgery and proton beam therapy: clinical, histological aspects and differential diagnosis of a new case. *Pathologica.* 2021;113(06):469-474. <https://doi.org/10.32074/1591-951X-215>
2049. de Lotbinière-Bassett M, Avery MB, Starreveld YP. A unique case of sinonasal teratocarcinoma presenting as Foster Kennedy Syndrome. *Can J Neurol Sci.* 2019;46(3):366-368. <https://doi.org/10.1017/cjn.2019.33>
2050. Bhalla V, Chowdhury N, Alvi S, Chamoun R, Beahm D. Two cases of sinonasal teratocarcinoma: confounders, treatment, and review of the literature. *J Neurol Surg B.* 2016;77(S 01):s-0036-1579996. <https://doi.org/10.1055/s-0036-1579996>
2051. Rashid T, Baig S, Saeed I, Mahasin Z. Sinonasal teratocarcinoma: management and literature review. *Pak J Med Health Sci.* 2012;6:7924.
2052. McKean E, Burgin S, Sullivan S, Nor J, Brenner C. Targetable pathway genome sequencing for a sinonasal teratocarcinoma and xenograft chemotherapeutic testing for personalized medicine. *J Neurol Surg B.* 2014;75(S 01):s-0034-1370602. <https://doi.org/10.1055/s-0034-1370602>
2053. Minasi S, De Vincentiis L, D'Ecclesia A, Corsi A, Giangaspero F. Pathogenetic analysis of sinonasal teratocarcinomas reveal actionable β -catenin overexpression and a β -catenin mutation. *J Neurol Surg B Skull Base.* 2021;82(Suppl. 3):e112-e113. <https://doi.org/10.1055/s-0039-3400228>
2054. Dodhia S, Fitzgerald CWR, McLean AT, et al. Predictors of surgical complications in patients with sinonasal malignancy. *J Surg Oncol.* 2021;124(5):731-739. <https://doi.org/10.1002/jso.26598>
2055. Overvest JB, Amans MR, Zaki P, Pletcher SD, El-Sayed IH. Patterns of vascularization and surgical morbidity in juvenile nasopharyngeal angiofibroma: a case series, systematic review, and meta-analysis. *Head Neck.* 2018;40(2):428-443. <https://doi.org/10.1002/hed.24987>
2056. Ganly I, Patel SG, Singh B, et al. Complications of craniofacial resection for malignant tumors of the skull base: report of an International Collaborative Study. *Head Neck.* 2005;27(6):445-451. <https://doi.org/10.1002/hed.20166>

2057. Zwagerman NT, Wang EW, Shin SS, et al. Does lumbar drainage reduce postoperative cerebrospinal fluid leak after endoscopic endonasal skull base surgery? A prospective, randomized controlled trial. *J Neurosurg.* 2018;131(4):1172-1178. <https://doi.org/10.3171/2018.4.JNS172447>
2058. Fraser S, Gardner PA, Koutourousiou M, et al. Risk factors associated with postoperative cerebrospinal fluid leak after endoscopic endonasal skull base surgery. *J Neurosurg.* 2018;128(4):1066-1071. <https://doi.org/10.3171/2016.12.JNS1694>
2059. Mangussi-Gomes J, Beer-Furlan A, Balsalobre L, Vellutini EAS, Stamm AC. Endoscopic endonasal management of skull base chordomas: surgical technique, nuances, and pitfalls. *Otolaryngol Clin North Am.* 2016;49(1):167-182. <https://doi.org/10.1016/j.otc.2015.09.011>
2060. Abiri A, Patel TR, Nguyen E, et al. Postoperative protocols following endoscopic skull base surgery: an evidence-based review with recommendations. *Int Forum Allergy Rhinol.* 2023;13(1):42-71. <https://doi.org/10.1002/alr.23041>
2061. Bashjawish B, Patel S, Kılıç S, et al. Effect of elderly status on postoperative complications in patients with sinonasal cancer. *Int Forum Allergy Rhinol.* 2019;9(2):220-224. <https://doi.org/10.1002/alr.22239>
2062. Goshtasbi K, Birkenbeuel JL, Abouzari M, et al. Short-term morbidity and predictors of adverse events following esthesioneuroblastoma surgery. *Am J Rhinol Allergy.* 2021;35(4):500-506. <https://doi.org/10.1177/1945892420970468>
2063. Teshima M, Shinomiya H, Otsuki N, et al. Complications in salvage surgery for nasal and paranasal malignant tumors involving the skull base. *J Neurol Surg B.* 2018;79(03):224-228. <https://doi.org/10.1055/s-0037-1606382>
2064. The WHOQOL Group. The World Health Organization Quality of Life assessment (WHOQOL): position paper from the World Health Organization. *Soc Sci Med.* 1995;41(10):1403-1409. [https://doi.org/10.1016/0277-9536\(95\)00112-k](https://doi.org/10.1016/0277-9536(95)00112-k)
2065. Forner D, Hueniken K, Yoannidis T, et al. Psychometric testing of the Skull Base Inventory health-related quality of life questionnaire in a multi-institutional study of patients undergoing open and endoscopic surgery. *Qual Life Res.* 2021;30(1):293-301. <https://doi.org/10.1007/s11136-020-02609-z>
2066. Noel CW, de Almeida JR. Quality of life considerations for patients with anterior and central skull base malignancies. *J Neurooncol.* 2020;150(3):501-508. <https://doi.org/10.1007/s11060-019-03367-w>
2067. Witgert ME, Veramonti T, Hanna E. Instruments for estimation of health-related quality of life in patients with skull base neoplasms. *Skull Base.* 2010;20(1):5-10. <https://doi.org/10.1055/s-0029-1242978>
2068. Gil Z, Abergel A, Spektor S, Shabtai E, Khafif A, Fliiss DM. Development of a cancer-specific anterior skull base quality-of-life questionnaire. *J Neurosurg.* 2004;100(5):813-819. <https://doi.org/10.3171/jns.2004.100.5.0813>
2069. Amit M, Abergel A, Fliiss DM, Gil Z. The clinical importance of quality-of-life scores in patients with skull base tumors: a meta-analysis and review of the literature. *Curr Oncol Rep.* 2012;14(2):175-181. <https://doi.org/10.1007/s11912-012-0222-3>
2070. de Almeida JR, Vescan AD, Gullane PJ, et al. Development of a disease-specific quality-of-life questionnaire for anterior and central skull base pathology—the skull base inventory. *Laryngoscope.* 2012;122(9):1933-1942. <https://doi.org/10.1002/lary.23426>
2071. Ten Dam E, Feijen RA, van den Berge MJC, et al. Development of the endoscopic endonasal sinus and skull base surgery questionnaire. *Int Forum Allergy Rhinol.* 2017;7(11):1076-1084. <https://doi.org/10.1002/alr.22000>
2072. Ten Dam E, Korsten-Meijer AGW, Hoving EW, et al. Evaluation of the psychometric properties of the endoscopic endonasal sinus and skull base surgery questionnaire (EES-Q) in a prospective cohort study. *Clin Otolaryngol.* 2019;44(4):565-571. <https://doi.org/10.1111/coa.13334>
2073. Ahmadipour Y, Müller O, Kreitschmann-Andermahr I, Mattheis S, Sure U, Hütter BO. Development, reliability, validity and sensitivity of the Sino-Nasal Outcome Test for Neurosurgery (SNOT-NC). *Eur Arch Otorhinolaryngol.* 2020;277(1):235-244. <https://doi.org/10.1007/s00405-019-05661-9>
2074. Little AS, Kelly D, Milligan J, et al. Prospective validation of a patient-reported nasal quality-of-life tool for endonasal skull base surgery: the anterior skull base nasal inventory-12. *J Neurosurg.* 2013;119(4):1068-1074. <https://doi.org/10.3171/2013.3.JNS122032>
2075. de Almeida JR, Witterick IJ, Gullane PJ, et al. Quality of life instruments for skull base pathology: systematic review and methodologic appraisal. *Head Neck.* 2013;35(9):1221-1231. <https://doi.org/10.1002/hed.23120>
2076. Carrillo JF, Ortiz-Toledo MA, Salido-Noriega Z, Romero-Ventura NB, Ochoa-Carrillo FJ, Oñate-Ocaña LF. Validation of the Mexican Spanish version of the EORTC QLQ-H&N35 instrument to measure health-related quality of life in patients with head and neck cancers. *Ann Surg Oncol.* 2013;20(5):1417-1426. <https://doi.org/10.1245/s10434-012-2712-9>
2077. Gu MF, Du YZ, Chen XL, Li JJ, Zhang HM, Tong Q. Item selection in the development of quality of life scale for nasopharyngeal carcinoma patients. *Ai Zheng.* 2009;28(1):82-85.
2078. Chie WC, Hong RL, Lai CC, Ting LL, Hsu MM. Quality of life in patients of nasopharyngeal carcinoma: validation of the Taiwan Chinese version of the EORTC QLQ-C30 and the EORTC QLQ-H&N35. *Qual Life Res.* 2003;12(1):93-98. <https://doi.org/10.1023/a:1022070220328>
2079. Chen X-l, Qiu Z-w, Gu M-f, et al. Translation and validation of the Chinese version of the quality of life radiation therapy instrument and the head & neck module (QOL-RTI/H&N). *Health Qual Life Outcomes.* 2014;12:51. <https://doi.org/10.1186/1477-7525-12-51>
2080. Peker K, Ozdemir-Karatas M, Balık A, Kürklü E, Uysal O, Rogers SN. Validation of the Turkish version of the Liverpool Oral Rehabilitation Questionnaire version 3 (LORQv3) in prosthetically rehabilitated patients with head and neck cancer. *BMC Oral Health.* 2014;14:129. <https://doi.org/10.1186/1472-6831-14-129>
2081. Tong MCF, Lo PSY, Wong KH, et al. Development and validation of the functional assessment of cancer therapy nasopharyngeal cancer subscale. *Head Neck.* 2009;31(6):738-747. <https://doi.org/10.1002/hed.21023>
2082. Su Y, Mo C-w, Cheng W-q, et al. Development and validation of quality of life scale of nasopharyngeal carcinoma patients: the QOL-NPC (version 2). *Health Qual Life Out-*

- comes. 2016;14(1):76. <https://doi.org/10.1186/s12955-016-0480-0>
2083. Wu J, Hu L, Zhang G, Liang Q, Meng Q, Wan C. Development and validation of the nasopharyngeal cancer scale among the system of quality of life instruments for cancer patients (QLICP-NA V2.0): combined classical test theory and generalizability theory. *Qual Life Res*. 2016;25(8):2087-2100. <https://doi.org/10.1007/s11136-016-1251-4>
2084. Lugo-Alonso J, Díaz-Martínez JR, González-Fernández N, et al. Measuring health-related quality of life in Cuban patients with head and neck cancer. *MEDICC Rev*. 2017;19(2-3):45. <https://doi.org/10.37757/MR2017.V19.N2-3.8>
2085. Deckard NA, Harrow BR, Barnett SL, Batra PS. Comparative analysis of quality-of-life metrics after endoscopic surgery for sinonasal neoplasms. *Am J Rhinol Allergy*. 2015;29(2):151-155. <https://doi.org/10.2500/ajra.2015.29.4137>
2086. Larjani S, Monteiro E, Witterick I, et al. Preliminary cross-sectional reliability and validity of the Skull Base Inventory (SBI) quality of life questionnaire. *J Otolaryngol Head Neck Surg*. 2016;45(1):45. <https://doi.org/10.1186/s40463-016-0158-y>
2087. Lo PSY, Lo SK, Tong MCF, Ku PKM, Leung SF, van Hasselt CA. Quality-of-life measurement in patients undergoing radiation therapy for head and neck cancer: a Hong Kong experience. *J Oncol Manag*. 2004;13(6):13-23.
2088. Chow VJ, Tsetsos N, Poutoglidis A, Georgalas C. Quality of life in sinonasal tumors: an up-to-date review. *Curr Opin Otolaryngol Head Neck Surg*. 2022;30(1):46-57. <https://doi.org/10.1097/MOO.0000000000000774>
2089. Harrow BR, Batra PS. Sinonasal quality of life outcomes after minimally invasive resection of sinonasal and skull-base tumors. *Int Forum Allergy Rhinol*. 2013;3(12):1013-1020. <https://doi.org/10.1002/alr.21200>
2090. Derousseau T, Manjunath L, Harrow B, Zhang S, Batra PS. Long-term changes in quality of life after endoscopic resection of sinonasal and skull-base tumors. *Int Forum Allergy Rhinol*. 2015;5(12):1129-1135. <https://doi.org/10.1002/alr.21608>
2091. van Samkar A, Georgalas C. Long-term quality of life after endoscopic removal of sinonasal inverted papillomas: a 6-year cohort analysis in a tertiary academic hospital. *Eur Arch Otorhinolaryngol*. 2016;273(6):1433-1437. <https://doi.org/10.1007/s00405-015-3751-1>
2092. Bertazzoni G, Accorona R, Schreiber A, et al. Postoperative long-term morbidity of extended endoscopic maxillectomy for inverted papilloma. *Rhinology*. 2017;55(4):319-325. <https://doi.org/10.4193/Rhin17.035>
2093. Glicksman JT, Parasher AK, Brooks SG, et al. Sinonasal quality of life after endoscopic resection of malignant sinonasal and skull base tumors. *Laryngoscope*. 2018;128(4):789-793. <https://doi.org/10.1002/lary.26833>
2094. Lin YH, Chen WC. Clinical outcome of endonasal endoscopic prelacrimal approach in managing different maxillary pathologies. *PeerJ*. 2020;8:e8331. <https://doi.org/10.7717/peerj.8331>
2095. Lee JT, Suh JD, Carrau RL, Chu MW, Chiu AG. Endoscopic Denker's approach for resection of lesions involving the anteroinferior maxillary sinus and infratemporal fossa. *Laryngoscope*. 2017;127(3):556-560. <https://doi.org/10.1002/lary.26237>
2096. Erskine SE, Hopkins C, Clark A, et al. SNOT-22 in a control population. *Clin Otolaryngol*. 2017;42(1):81-85. <https://doi.org/10.1111/coa.12667>
2097. Nakamura Y, Suzuki M, Ozaki S, et al. Sinonasal inverted papilloma associated with small cell neuroendocrine carcinoma: a case report and literature review of rare malignancies associated with inverted papilloma. *Auris Nasus Larynx*. 2019;46(4):641-650. <https://doi.org/10.1016/j.anl.2018.10.009>
2098. Jozaghi Y, Phan J, Hanna EY, Kupferman ME, Su SY. Functional outcomes and quality of life in patients with sinonasal, nasopharyngeal, and anterior skull base tumors. *Curr Oncol Rep*. 2022;24(6):775-781. <https://doi.org/10.1007/s11912-022-01214-2>
2099. Halmos GB, Peters TTA, Roodenburg JLN, van Dijk BAC, van der Laan BFAM. Comorbidity, complications, and survival of sinonasal malignancies in young and elderly treated by surgery. *Otolaryngol Head Neck Surg*. 2013;148(5):860-866. <https://doi.org/10.1177/0194599813477354>
2100. Bisogno G, Soloni P, Conte M, et al. Esthesioneuroblastoma in pediatric and adolescent age. A report from the TREP project in cooperation with the Italian Neuroblastoma and Soft Tissue Sarcoma Committees. *BMC Cancer*. 2012;12:117. <https://doi.org/10.1186/1471-2407-12-117>
2101. Liu L, Liu D, Guo Q, Shen B. Quality of life in advanced maxillary sinus cancer after radical versus conservative maxillectomy. *J Craniofac Surg*. 2013;24(4):1368-1372. <https://doi.org/10.1097/SCS.0b013e31828601d6>
2102. Goel AN, Lee JT, Gurrola JG, Wang MB, Suh JD. The impact of frailty on perioperative outcomes and resource utilization in sinonasal cancer surgery. *Laryngoscope*. 2020;130(2):290-296. <https://doi.org/10.1002/lary.28006>
2103. Philips R, Agarwal A, Chitguppi C, et al. Quality of life outcomes in patients with sinonasal malignancy after definitive treatment. *Laryngoscope*. 2021;131(7):E2212-E2221. <https://doi.org/10.1002/lary.29339>
2104. Spiegel JH, Varvares MA. Prevention of postexenteration complications by obliteration of the orbital cavity. *Skull Base*. 2007;17(3):197-203. <https://doi.org/10.1055/s-2007-977468>
2105. Traylor JI, Christiano LD, Esmaeli B, et al. Outcomes of orbital exenteration for craniofacial lesions. *Cancer*. 2021;127(14):2465-2475. <https://doi.org/10.1002/cncr.33526>
2106. Stern SJ, Goepfert H, Clayman G, Byers R, Wolf P. Orbital preservation in maxillectomy. *Otolaryngol Head Neck Surg*. 1993;109(1):111-115. <https://doi.org/10.1177/019459989310900120>
2107. Rauchenwald T, Dejacó D, Henninger B, et al. Simple, but effective: nasal splinting for airway securement in free flap reconstruction following orbital exenteration. *Head Neck*. 2021;43(10):3238-3244. <https://doi.org/10.1002/hed.26815>
2108. Yeung JT, Caminer DM, Young IM, Sughrue ME, Teo C. Radical exenteration of the skull base for end-stage, locally advanced sinonasal malignancies: challenging the dictum of unresectability. *World Neurosurg*. 2021;150:e102-e107. <https://doi.org/10.1016/j.wneu.2021.02.092>
2109. Ziai H, Yu E, Fu T, et al. Impact of dural resection on sinonasal malignancies with skull base encroachment or erosion. *J Neurol Surg B*. 2018;79(05):419-426. <https://doi.org/10.1055/s-0037-1612617>

2110. Tyler MA, Holmes B, Patel ZM. Oncologic management of sinonasal undifferentiated carcinoma. *Curr Opin Otolaryngol Head Neck Surg*. 2019;27(1):59-66. <https://doi.org/10.1097/MOO.0000000000000513>
2111. Sun Y, Huang Q, Cui S, et al. Outcomes and quality-of-life measures after endoscopic endonasal resection of Kadish stage C olfactory neuroblastomas. *World Neurosurg*. 2021;151:e58-e67. <https://doi.org/10.1016/j.wneu.2021.03.120>
2112. Maggiore G, Lazio MS, Gallo O. Treatment of pediatric esthesioneuroblastoma with smell preservation. *Auris Nasus Larynx*. 2018;45(5):1107-1112. <https://doi.org/10.1016/j.anl.2018.02.003>
2113. Tyler MA, Mohamed ASR, Smith JB, et al. Long-term quality of life after definitive treatment of sinonasal and nasopharyngeal malignancies. *Laryngoscope*. 2020;130(1):86-93. <https://doi.org/10.1002/lary.27849>
2114. Abergel A, Fliss D, Margalit N, Gil Z. A prospective evaluation of short-term health-related quality of life in patients undergoing anterior skull base surgery. *Skull Base*. 2010;20(01):27-33. <https://doi.org/10.1055/s-0029-1242982>
2115. Pant H, Bhatki A, Snyderman C, et al. Quality of life following endonasal skull base surgery. *Skull Base*. 2010;20(01):35-40. <https://doi.org/10.1055/s-0029-1242983>
2116. McCoul ED, Anand VK, Bedrosian JC, Schwartz TH. Endoscopic skull base surgery and its impact on sinonasal-related quality of life. *Int Forum Allergy Rhinol*. 2012;2(2):174-181. <https://doi.org/10.1002/alr.21008>
2117. Kirkman M, Borg A, Al-Mousa A, Haliasos N, Choi D. Quality-of-life after anterior skull base surgery: a systematic review. *J Neurol Surg B*. 2013;75(02):73-89. <https://doi.org/10.1055/s-0033-1359303>
2118. Fisher FL, Zamanipoor Najafabadi AH, Van Der Meer PB, et al. Long-term health-related quality of life and neurocognitive functioning after treatment in skull base meningioma patients. *J Neurosurg*. 2022;136(4):1077-1089. <https://doi.org/10.3171/2021.4.JNS203891>
2119. Lee JH, Zacharia BE, Ba D, Leslie D, Liu G, Goyal N. Mental health disorders associated with sinonasal and skull base malignancies: a large cohort study. *J Neurol Surg B*. 2020;81(02):187-192. <https://doi.org/10.1055/s-0039-1679889>
2120. Palme CE, Irish JC, Gullane PJ, Katz MR, Devins GM, Bachar G. Quality of life analysis in patients with anterior skull base neoplasms. *Head Neck*. 2009;31(10):1326-1334. <https://doi.org/10.1002/hed.21102>
2121. Martinez-Devesa P, Barnes ML, Alcock CJ, Kerr RSC, Milford CA. Evaluation of quality of life and psychiatric morbidity in patients with malignant tumours of the skull base. *J Laryngol Otol*. 2006;120(12):1049-1054. <https://doi.org/10.1017/S0022215106002477>
2122. Gray S, Lin A, Curry W, et al. Delayed complications after anterior craniofacial resection of malignant skull base tumors. *J Neurol Surg B*. 2013;75(02):110-116. <https://doi.org/10.1055/s-0033-1359306>
2123. Gil Z, Fliss D. Quality of life in patients with skull base tumors: current status and future challenges. *Skull Base*. 2010;20(01):11-18. <https://doi.org/10.1055/s-0029-1242979>
2124. De Almeida JR, Witterick IJ, Vescan AD. Functional outcomes for endoscopic and open skull base surgery: an evidence-based review. *Otolaryngol Clin North Am*. 2011;44(5):1185-1200. <https://doi.org/10.1016/j.otc.2011.06.017>
2125. Bhenswala PN, Schlosser RJ, Nguyen SA, Munawar S, Rowan NR. Sinonasal quality-of-life outcomes after endoscopic endonasal skull base surgery. *Int Forum Allergy Rhinol*. 2019;9(10):1105-1118. <https://doi.org/10.1002/alr.22398>
2126. Manthuruthil C, Lewis J, McLean C, Batra PS, Barnett SL. Endoscopic endonasal management of olfactory neuroblastoma: a retrospective analysis of 10 patients with quality-of-life measures. *World Neurosurg*. 2016;90:1-5. <https://doi.org/10.1016/j.wneu.2016.02.035>
2127. Castelnovo P, Lepera D, Turri-Zanoni M, et al. Quality of life following endoscopic endonasal resection of anterior skull base cancers: clinical article. *J Neurosurg*. 2013;119(6):1401-1409. <https://doi.org/10.3171/2013.8.JNS13296>
2128. Cavel O, Abergel A, Margalit N, Fliss D, Gil Z. Quality of life following endoscopic resection of skull base tumors. *J Neurol Surg B*. 2012;73(02):112-116. <https://doi.org/10.1055/s-0032-1301392>
2129. Spektor S, Valarezo J, Fliss DM, et al. Olfactory groove meningiomas from neurosurgical and ear, nose, and throat perspectives: approaches, techniques, and outcomes. *Oper Neurosurg*. 2005;57(Suppl. 4):ONS-268-ONS-280. <https://doi.org/10.1227/01.NEU.0000176409.70668.EB>
2130. Harvey RJ, Malek J, Winder M, et al. Sinonasal morbidity following tumour resection with and without nasoseptal flap reconstruction. *Rhinology*. 2015;53(2):122-128. <https://doi.org/10.4193/Rhino14.247>
2131. Hanson M, Patel PM, Betz C, Olson S, Panizza B, Wallwork B. Sinonasal outcomes following endoscopic anterior skull base surgery with nasoseptal flap reconstruction: a prospective study. *J Laryngol Otol*. 2015;129(S3):S41-S46. <https://doi.org/10.1017/S002221511500047X>
2132. Upadhyay S, Buohliqah L, Dolci RLL, Otto BA, Prevedello DM, Carrau RL. Periodic olfactory assessment in patients undergoing skull base surgery with preservation of the olfactory strip: olfactory assessment in skull base surgery. *Laryngoscope*. 2017;127(9):1970-1975. <https://doi.org/10.1002/lary.26546>
2133. Jalessi M, Jahanbakhshi A, Amini E, Kamrava SK, Farhadi M. Impact of nasoseptal flap elevation on sinonasal quality of life in endoscopic endonasal approach to pituitary adenomas. *Eur Arch Otorhinolaryngol*. 2016;273(5):1199-1205. <https://doi.org/10.1007/s00405-015-3729-z>
2134. Brook I. Late side effects of radiation treatment for head and neck cancer. *Radiat Oncol J*. 2020;38(2):84-92. <https://doi.org/10.3857/roj.2020.00213>
2135. Shah S, Har-El G, Rosenfeld RM. Short-term and long-term quality of life after neck dissection. *Head Neck*. 2001;23(11):954-961. <https://doi.org/10.1002/hed.1138>
2136. Taylor RJ, Chepeha JC, Teknos TN, et al. Development and validation of the neck dissection impairment index: a quality of life measure. *Arch Otolaryngol Head Neck Surg*. 2002;128(1):44. <https://doi.org/10.1001/archotol.128.1.44>
2137. Gane EM, O'Leary SP, Hatton AL, Panizza BJ, McPhail SM. Neck and upper limb dysfunction in patients following neck dissection: looking beyond the shoulder. *Otolaryngol Head Neck Surg*. 2017;157(4):631-640. <https://doi.org/10.1177/0194599817721164>

2138. Spinelli BA, Galantino ML, Eden MM, Flores AM. Recommendations for patient-reported outcome measures for head and neck cancer-related neck dysfunction: a systematic review. *Rehabil Oncol*. 2014;32(3):20-31. <https://doi.org/10.1097/01893697-201432030-00004>
2139. Van Hinte G, Sancak T, Weijs WLJ, et al. Effect of elective neck dissection versus sentinel lymph node biopsy on shoulder morbidity and health-related quality of life in patients with oral cavity cancer: a longitudinal comparative cohort study. *Oral Oncol*. 2021;122:105510. <https://doi.org/10.1016/j.oraloncology.2021.105510>
2140. Nilsen ML, Lyu L, Belsky MA, et al. Impact of neck disability on health-related quality of life among head and neck cancer survivors. *Otolaryngol Head Neck Surg*. 2020;162(1):64-72. <https://doi.org/10.1177/0194599819883295>
2141. Terezakis SA, Bohle GC, Lee NY. Fistula formation after post-operative radiation treatment for paranasal sinus cancer. *Am J Clin Oncol*. 2008;31(2):199-204. <https://doi.org/10.1097/COC.0b013e31815aff43>
2142. Shaw E, Arusell R, Scheithauer B, et al. Prospective randomized trial of low- versus high-dose radiation therapy in adults with supratentorial low-grade glioma: initial report of a north central cancer treatment group/radiation therapy oncology group/eastern cooperative oncology group study. *J Clin Oncol*. 2002;20(9):2267-2276. <https://doi.org/10.1200/JCO.2002.09.126>
2143. Pacholke HD, Amdur RJ, Morris CG, et al. Late xerostomia after intensity-modulated radiation therapy versus conventional radiotherapy. *Am J Clin Oncol*. 2005;28(4):351-358. <https://doi.org/10.1097/01.coc.0000158826.88179.75>
2144. Wang K, Zanation AM, Chera BS. The role of radiation therapy in the management of sinonasal and ventral skull base malignancies. *Otolaryngol Clin North Am*. 2017;50(2):419-432. <https://doi.org/10.1016/j.otc.2016.12.014>
2145. Adeberg S, Akbaba S, Lang K, et al. The Phase 1/2 ACCEPT trial: concurrent cetuximab and intensity modulated radiation therapy with carbon ion boost for adenoid cystic carcinoma of the head and neck. *Int J Radiat Oncol Biol Phys*. 2020;106(1):167-173. <https://doi.org/10.1016/j.ijrobp.2019.09.036>
2146. Koto M, Hasegawa A, Takagi R, et al. Risk factors for brain injury after carbon ion radiotherapy for skull base tumors. *Radiation Oncol*. 2014;11(1):25-29. <https://doi.org/10.1016/j.radonc.2013.11.005>
2147. Fan D, Kang JJ, Fan M, et al. Last-line local treatment with the Quad Shot regimen for previously irradiated head and neck cancers. *Oral Oncol*. 2020;104:104641. <https://doi.org/10.1016/j.oraloncology.2020.104641>
2148. Jones B, McMahon SJ, Prise KM. The radiobiology of proton therapy: challenges and opportunities around relative biological effectiveness. *Clin Oncol*. 2018;30(5):285-292. <https://doi.org/10.1016/j.clon.2018.01.010>
2149. McDonald MW, Liu Y, Moore MG, Johnstone PAS. Acute toxicity in comprehensive head and neck radiation for nasopharynx and paranasal sinus cancers: cohort comparison of 3D conformal proton therapy and intensity modulated radiation therapy. *Radiat Oncol*. 2016;11(1):32. <https://doi.org/10.1186/s13014-016-0600-3>
2150. McDonald MW, Linton OR, Calley CSJ. Dose-volume relationships associated with temporal lobe radiation necrosis after skull base proton beam therapy. *Int J Radiat Oncol Biol Phys*. 2015;91(2):261-267. <https://doi.org/10.1016/j.ijrobp.2014.10.011>
2151. Kitpanit S, Lee A, Pitter KL, et al. Temporal lobe necrosis in head and neck cancer patients after proton therapy to the skull base. *Int J Part Ther*. 2020;6(4):17-28. <https://doi.org/10.14338/IJPT-20-00014.1>
2152. Intensity-modulated or proton radiation therapy for sinonasal malignancy. ClinicalTrials.gov. Accessed March 23, 2022. <https://clinicaltrials.gov/ct2/show/NCT01586767>
2153. Han P, Wang X, Liang F, et al. Osteoradionecrosis of the skull base in nasopharyngeal carcinoma: incidence and risk factors. *Int J Radiat Oncol Biol Phys*. 2018;102(3):552-555. <https://doi.org/10.1016/j.ijrobp.2018.06.027>
2154. Leonetti JP, Weishaar JR, Gannon D, Harmon GA, Block A, Anderson DE. Osteoradionecrosis of the skull base. *J Neurooncol*. 2020;150(3):477-482. <https://doi.org/10.1007/s11060-020-03462-3>
2155. Jereczek-Fossa BA, Orecchia R. Radiotherapy-induced mandibular bone complications. *Cancer Treat Rev*. 2002;28(1):65-74. <https://doi.org/10.1053/ctrv.2002.0254>
2156. Huang XM, Zheng YQ, Zhang XM, et al. Diagnosis and management of skull base osteoradionecrosis after radiotherapy for nasopharyngeal carcinoma. *Laryngoscope*. 2006;116(9):1626-1631. <https://doi.org/10.1097/01.mlg.0000230435.71328.b9>
2157. Delanian S, Porcher R, Balla-Mekias S, Lefaix JL. Randomized, placebo-controlled trial of combined pentoxifylline and tocopherol for regression of superficial radiation-induced fibrosis. *J Clin Oncol*. 2003;21(13):2545-2550. <https://doi.org/10.1200/JCO.2003.06.064>
2158. Gavriel H, Eviatar E, Abu Eta R. Hyperbaric oxygen therapy for maxillary bone radiation-induced injury: a 15-year single-center experience: hyperbaric oxygen therapy for maxillary osteoradionecrosis. *Head Neck*. 2017;39(2):275-278. <https://doi.org/10.1002/hed.24577>
2159. Annane D, Depondt J, Aubert P, et al. Hyperbaric oxygen therapy for radionecrosis of the jaw: a randomized, placebo-controlled, double-blind trial from the ORN96 study group. *J Clin Oncol*. 2004;22(24):4893-4900. <https://doi.org/10.1200/JCO.2004.09.006>
2160. Paniello RC, Fraley PL, O'Bert R. Effect of hyperbaric oxygen therapy on a murine squamous cell carcinoma model: hyperbaric oxygen in SCC. *Head Neck*. 2014;36(12):1743-1746. <https://doi.org/10.1002/hed.23528>
2161. Huang WB, Wong STS, Chan JYW. Role of surgery in the treatment of osteoradionecrosis and its complications after radiotherapy for nasopharyngeal carcinoma. *Head Neck*. 2018;40(2):369-376. <https://doi.org/10.1002/hed.24973>
2162. Habib A, Hanasono MM, DeMonte F, et al. Surgical management of skull base osteoradionecrosis in the cancer population – treatment outcomes and predictors of recurrence: a case series. *Operative Surg*. 2020;19(4):364-374. <https://doi.org/10.1093/ons/opaa082>
2163. Daoudi H, Labeyrie MA, Guillerm S, et al. Multimodal strategy for the management of sphenoid osteoradionecro-

- sis: preliminary results. *Laryngoscope Invest Otolaryngol.* 2020;5(1):19-23. <https://doi.org/10.1002/lio2.345>
2164. Vermorken JB, Remenar E, Van Herpen C, et al. Cisplatin, fluorouracil, and docetaxel in unresectable head and neck cancer. *N Engl J Med.* 2007;357(17):1695-1704. <https://doi.org/10.1056/NEJMoa071028>
2165. Ghi MG, Paccagnella A, Ferrari D, et al. Induction TPF followed by concomitant treatment versus concomitant treatment alone in locally advanced head and neck cancer. A phase II–III trial. *Ann Oncol.* 2017;28(9):2206-2212. <https://doi.org/10.1093/annonc/mdx299>
2166. Paccagnella A, Ghi MG, Loreggian L, et al. Concomitant chemoradiotherapy versus induction docetaxel, cisplatin and 5 fluorouracil (TPF) followed by concomitant chemoradiotherapy in locally advanced head and neck cancer: a phase II randomized study. *Ann Oncol.* 2010;21(7):1515-1522. <https://doi.org/10.1093/annonc/mdp573>
2167. Larive S, Bombaron P, Riou R, et al. Carboplatin—etoposide combination in small cell lung cancer patients older than 70 years: a phase II trial. *Lung Cancer.* 2002;35(1):1-7. [https://doi.org/10.1016/S0169-5002\(01\)00288-4](https://doi.org/10.1016/S0169-5002(01)00288-4)
2168. Frizziero M, Spada F, Lamarca A, et al. Carboplatin in combination with oral or intravenous etoposide for extrapulmonary, poorly-differentiated neuroendocrine carcinomas. *Neuroendocrinology.* 2019;109(2):100-112. <https://doi.org/10.1159/000497336>
2169. Coiffier B, Lepage E, Brière J, et al. CHOP chemotherapy plus rituximab compared with CHOP alone in elderly patients with diffuse large-B-cell lymphoma. *N Engl J Med.* 2002;346(4):235-242. <https://doi.org/10.1056/NEJMoa011795>
2170. Furtado M, Johnson R, Kruger A, Turner D, Rule S. Addition of bortezomib to standard dose chop chemotherapy improves response and survival in relapsed mantle cell lymphoma. *Br J Haematol.* 2015;168(1):55-62. <https://doi.org/10.1111/bjh.13101>
2171. Kim R, Hahn S, Shin J, et al. The effect of induction chemotherapy using docetaxel, cisplatin, and fluorouracil on survival in locally advanced head and neck squamous cell carcinoma: a meta-analysis. *Cancer Res Treat.* 2016;48(3):907-916. <https://doi.org/10.4143/crt.2015.359>
2172. Bernadach M, Lapeyre M, Dillies AF, et al. Predictive factors of toxicity of TPF induction chemotherapy for locally advanced head and neck cancers. *BMC Cancer.* 2021;21(1):360. <https://doi.org/10.1186/s12885-021-08128-5>
2173. Nishimura G, Tsukuda M, Mikami Y, et al. The efficacy and safety of concurrent chemoradiotherapy for maxillary sinus squamous cell carcinoma patients. *Auris Nasus Larynx.* 2009;36(5):547-554. <https://doi.org/10.1016/j.anl.2008.11.002>
2174. Tsan YH, Wung SH, Lin MW, Lo WL, Wang YJ. Predictors of quality of life change in head-and-neck cancer survivors during concurrent chemoradiotherapy: a prospective study. *Asia Pac J Oncol Nurs.* 2021;8(3):237-245. <https://doi.org/10.4103/2347-5625.311132>
2175. Ye A, Hay J, Laskin J, Wu J, Ho C. Toxicity and outcomes in combined modality treatment of head and neck squamous cell carcinoma: cisplatin versus cetuximab. *J Can Res Ther.* 2013;9(4):607-612. <https://doi.org/10.4103/0973-1482.126455>
2176. Aggarwal H, Punekar RS, Li L, Carter GC, Walker MS. Quality of life analysis of patients treated with cetuximab or cisplatin for locoregionally advanced squamous cell carcinoma of head and neck in the United States. *Health Qual Life Outcomes.* 2020;18(1):195. <https://doi.org/10.1186/s12955-020-01424-x>
2177. Bonner JA, Harari PM, Giralt J, et al. Radiotherapy plus cetuximab for squamous-cell carcinoma of the head and neck. *N Engl J Med.* 2006;354(6):567-578. <https://doi.org/10.1056/NEJMoa053422>
2178. Rasch CRN, Hauptmann M, Schornagel J, et al. Intra-arterial versus intravenous chemoradiation for advanced head and neck cancer: results of a randomized phase 3 trial. *Cancer.* 2010;116(9):2159-2165. <https://doi.org/10.1002/cncr.24916>
2179. Heukelom J, Lopez-Yurda M, Balm AJM, et al. Late follow-up of the randomized radiation and concomitant high-dose intra-arterial or intravenous cisplatin (RADPLAT) trial for advanced head and neck cancer: late follow-up of the RAD-PLAT trial. *Head Neck.* 2016;38(S1):E488-E493. <https://doi.org/10.1002/hed.24023>
2180. Pardoll DM. The blockade of immune checkpoints in cancer immunotherapy. *Nat Rev Cancer.* 2012;12(4):252-264. <https://doi.org/10.1038/nrc3239>
2181. Thompson JA, Schneider BJ, Brahmer J, et al. Management of immunotherapy-related toxicities, version 1.2019, NCCN clinical practice guidelines in oncology. *J Natl Compr Canc Netw.* 2019;17(3):255-289. <https://doi.org/10.6004/jnccn.2019.0013>
2182. Ferris RL, Blumenschein G, Fayette J, et al. Nivolumab for recurrent squamous-cell carcinoma of the head and neck. *N Engl J Med.* 2016;375(19):1856-1867. <https://doi.org/10.1056/NEJMoa1602252>
2183. Seiwert TY, Burtness B, Mehra R, et al. Safety and clinical activity of pembrolizumab for treatment of recurrent or metastatic squamous cell carcinoma of the head and neck (KEYNOTE-012): an open-label, multicentre, phase 1b trial. *Lancet Oncol.* 2016;17(7):956-965. [https://doi.org/10.1016/S1470-2045\(16\)30066-3](https://doi.org/10.1016/S1470-2045(16)30066-3)
2184. Cohen EEW, Bell RB, Bifulco CB, et al. The Society for Immunotherapy of Cancer consensus statement on immunotherapy for the treatment of squamous cell carcinoma of the head and neck (HNSCC). *J Immunotherapy Cancer.* 2019;7(1):184. <https://doi.org/10.1186/s40425-019-0662-5>
2185. Chow LQM, Haddad R, Gupta S, et al. Antitumor activity of pembrolizumab in biomarker-unselected patients with recurrent and/or metastatic head and neck squamous cell carcinoma: results from the phase Ib KEYNOTE-012 expansion cohort. *J Clin Oncol.* 2016;34(32):3838-3845. <https://doi.org/10.1200/JCO.2016.68.1478>
2186. Powell SF, Gold KA, Gitau MM, et al. Safety and efficacy of pembrolizumab with chemoradiotherapy in locally advanced head and neck squamous cell carcinoma: a phase IB study. *J Clin Oncol.* 2020;38(21):2427-2437. <https://doi.org/10.1200/JCO.19.03156>
2187. Mehra R, Seiwert TY, Gupta S, et al. Efficacy and safety of pembrolizumab in recurrent/metastatic head and neck squamous cell carcinoma: pooled analyses after long-term follow-up in KEYNOTE-012. *Br J Cancer.* 2018;119(2):153-159. <https://doi.org/10.1038/s41416-018-0131-9>
2188. Abdel-Rahman O, Fouad M. Risk of pneumonitis in cancer patients treated with immune checkpoint inhibitors: a meta-analysis. *Ther Adv Respir Dis.* 2016;10(3):183-193. <https://doi.org/10.1177/1753465816636557>

2189. Cohen EEW, Soulières D, Le Tourneau C, et al. Pembrolizumab versus methotrexate, docetaxel, or cetuximab for recurrent or metastatic head-and-neck squamous cell carcinoma (KEYNOTE-040): a randomised, open-label, phase 3 study. *Lancet North Am Ed.* 2019;393(10167):156-167. [https://doi.org/10.1016/S0140-6736\(18\)31999-8](https://doi.org/10.1016/S0140-6736(18)31999-8)
2190. Vermorken JB, Trigo J, Hitt R, et al. Open-label, uncontrolled, multicenter phase II study to evaluate the efficacy and toxicity of cetuximab as a single agent in patients with recurrent and/or metastatic squamous cell carcinoma of the head and neck who failed to respond to platinum-based therapy. *J Clin Oncol.* 2007;25(16):2171-2177. <https://doi.org/10.1200/JCO.2006.06.7447>
2191. Homma A, Oridate N, Suzuki F, et al. Superselective high-dose cisplatin infusion with concomitant radiotherapy in patients with advanced cancer of the nasal cavity and paranasal sinuses: a single institution experience. *Cancer.* 2009;115(20):4705-4714. <https://doi.org/10.1002/cncr.24515>
2192. Cheung PKF, Chin RY, Eslick GD. Detecting residual/recurrent head neck squamous cell carcinomas using PET or PET/CT: systematic review and meta-analysis. *Otolaryngol Head Neck Surg.* 2016;154(3):421-432. <https://doi.org/10.1177/0194599815621742>
2193. Schwartz JS, Brooks SG, Stubbs V, et al. Temporal patterns of 18 F-fluorodeoxyglucose positron emission tomography/computed tomography sinonasal uptake after treatment of sinonasal malignancy. *Int Forum Allergy Rhinol.* 2016;6(12):1301-1307. <https://doi.org/10.1002/alr.21814>
2194. Nakayama T, Tsunemi Y, Kashiwagi T, et al. Comparison of current staging systems for sinonasal inverted papilloma. *Am J Rhinol Allergy.* 2021;35(1):64-71. <https://doi.org/10.1177/1945892420933178>
2195. Nyquist GG, Patel PN, Vimawala S, et al. Surgery with post-operative endoscopy improves recurrence detection in sinonasal malignancies. *Ann Otol Rhinol Laryngol.* 2022;131(2):140-146. <https://doi.org/10.1177/00034894211011449>
2196. de Gabory L, Maunoury A, Maurice-Tison S, et al. Long-term single-center results of management of ethmoid adenocarcinoma: 95 patients over 28 years. *Ann Surg Oncol.* 2010;17(4):1127-1134. <https://doi.org/10.1245/s10434-010-0933-3>
2197. Gomez-Rivera F, Fakhri S, Williams MD, Hanna EY, Kupferman ME. Surgical management of sinonasal hemangiopericytomas: a case series. *Head Neck.* 2012;34(10):1492-1496. <https://doi.org/10.1002/hed.21926>
2198. Hong SL, Mun SJ, Cho KS, Roh HJ. Inverted papilloma of the maxillary sinus: surgical approach and long-term results. *Am J Rhinol Allergy.* 2015;29(6):441-444. <https://doi.org/10.2500/ajra.2015.29.4219>
2199. Jiang XD, Dong QZ, Li SL, Huang TQ, Zhang NK. Endoscopic surgery of a sinonasal inverted papilloma: surgical strategy, follow-up, and recurrence rate. *Am J Rhinol Allergy.* 2017;31(1):51-55. <https://doi.org/10.2500/ajra.2017.31.4387>
2200. Kaza S, Capasso R, Casiano RR. Endoscopic resection of inverted papilloma: university of Miami experience. *Am J Rhinol.* 2003;17(4):185-190.
2201. Nygren A, Kiss K, Von Buchwald C, Bilde A. Rate of recurrence and malignant transformation in 88 cases with inverted papilloma between 1998–2008. *Acta Otolaryngol.* 2016;136(3):333-336. <https://doi.org/10.3109/00016489.2015.1116123>
2202. Lund VJ, Howard DJ, Wei WI. *Tumors of the Nose, Sinuses, and Nasopharynx.* Thieme; 2014.
2203. Thakar A, Sakthivel P, Arunraj ST, et al. Comparison of prostate-specific membrane antigen PET/CT and contrast-enhanced magnetic resonance imaging in follow-up assessment of juvenile nasal angiofibroma—a novel pilot study. *Clin Nucl Med.* 2020;45(12):e498-e504. <https://doi.org/10.1097/RLU.0000000000003311>
2204. Rho HJ, Kim SJ, Nam HY, et al. Detection and prediction of local recurrence of maxillary sinus cancer using F-18 FDG PET/CT. *Eur J Surg Oncol.* 2010;36(2):214-220. <https://doi.org/10.1016/j.ejso.2009.10.003>
2205. Ozturk K, Gencturk M, Caicedo-Granados E, Li F, Cayci Z. Appropriate timing of surveillance intervals with whole-body 18F-FDG PET/CT following treatment for sinonasal malignancies. *Eur J Radiol.* 2019;118:75-80. <https://doi.org/10.1016/j.ejrad.2019.07.004>
2206. Carpen O, Helander T. Biobanks and Comprehensive Cancer Center Finland (FICAN) as institutions enabling clinical drug testing. *Duodecim.* 2017;133(6):592-598.
2207. Gong L, Kwong DLW, Dai W, et al. Comprehensive single-cell sequencing reveals the stromal dynamics and tumor-specific characteristics in the microenvironment of nasopharyngeal carcinoma. *Nat Commun.* 2021;12(1):1540. <https://doi.org/10.1038/s41467-021-21795-z>
2208. Jiang Y, Yang J, Liang R, et al. Single-cell RNA sequencing highlights intratumor heterogeneity and intercellular network featured in adamantinomatous craniopharyngioma. *Sci Adv.* 2023;9(15):eadc8933. <https://doi.org/10.1126/sciadv.adc8933>
2209. Zhang Q, Fei L, Han R, et al. Single-cell transcriptome reveals cellular hierarchies and guides p-EMT-targeted trial in skull base chordoma. *Cell Discov.* 2022;8(1):94. <https://doi.org/10.1038/s41421-022-00459-2>
2210. Pandrangi VC, Mace JC, Abiri A, et al. Recurrence patterns among patients with sinonasal mucosal melanoma: a multi-institutional study. *Int Forum Allergy Rhinol.* 2023. <https://doi.org/10.1002/alr.23204>
2211. Arosio AD, Bernasconi DP, Valsecchi MG, et al. Patterns of recurrences in sinonasal cancers undergoing an endoscopic surgery-based treatment: results of the MUSES* on 940 patients: *MULTI-institutional collaborative Study on Endoscopically treated Sinonasal cancers. *Oral Oncol.* 2022;134:106123. <https://doi.org/10.1016/j.oraloncology.2022.106123>
2212. Beswick DM, Holsinger FC, Kaplan MJ, et al. Design and rationale of a prospective, multi-institutional registry for patients with sinonasal malignancy. *Laryngoscope.* 2016;126(9):1977-1980. <https://doi.org/10.1002/lary.25996>
2213. Maoz SL, Wang EW, Hwang PH, et al. Long-term quality of life after treatment in sinonasal malignancy: a prospective, multi-center study. *Int Forum Allergy Rhinol.* 2023. <https://doi.org/10.1002/alr.23171>
2214. Resteghini C, Castelnuovo P, Nicolai P, et al. The SIN-TART 1 study. A phase II non-randomised controlled trial of induction chemotherapy, surgery, photon-, proton- and

- carbon ion-based radiotherapy integration in patients with locally advanced resectable sinonasal tumours. *Eur J Cancer*. 2023;187:185-194. <https://doi.org/10.1016/j.ejca.2023.03.033>
2215. Bossi P, Orlandi E, Resteghini C, et al. The SINTART 2 Study. A phase II non-randomised controlled trial of induction chemotherapy, photon-, proton- and carbon-ion-based radiotherapy integration in patients with locally advanced unresectable sinonasal tumours. *Eur J Cancer*. 2023;187:134-143. <https://doi.org/10.1016/j.ejca.2023.03.034>
2216. Ng WT, Yau TK, Yung RWH, et al. Screening for family members of patients with nasopharyngeal carcinoma. *Int J Cancer*. 2005;113(6):998-1001. <https://doi.org/10.1002/ijc.20672>
2217. Crown A, Rocha FG, Raghu P, et al. Impact of initial imaging with gallium-68 dotatate PET/CT on diagnosis and management of patients with neuroendocrine tumors. *J Surg Oncol*. 2020;121(3):480-485. <https://doi.org/10.1002/jso.25812>
2218. Liu KY, Goldrich DY, Ninan SJ, et al. The value of 68 Gallium-DOTATATE PET/CT in sinonasal neuroendocrine tumor management: a case series. *Head Neck*. 2021;43(6):E30-E40. <https://doi.org/10.1002/hed.26695>
2219. Jurmeister P, Glöß S, Roller R, et al. DNA methylation-based classification of sinonasal tumors. *Nat Commun*. 2022;13(1):7148. <https://doi.org/10.1038/s41467-022-34815-3>
2220. Amanian A, Heffernan A, Ishii M, Creighton FX, Thamboo A. The evolution and application of artificial intelligence in rhinology: a state of the art review. *Otolaryngol Head Neck Surg*. 2023;169(1):21-30. <https://doi.org/10.1177/01945998221110076>
2221. Bulfamante AM, Ferella F, Miller AM, et al. Artificial intelligence, machine learning, and deep learning in rhinology: a systematic review. *Eur Arch Otorhinolaryngol*. 2023;280(2):529-542. <https://doi.org/10.1007/s00405-022-07701-3>
2222. Osie G, Darbari Kaul R, Alvarado R, et al. A scoping review of artificial intelligence research in rhinology. *Am J Rhinol Allergy*. 2023;37(4):438-448. <https://doi.org/10.1177/19458924231162437>

How to cite this article: How to Cite this

Article: Kuan EC, Wang EW, Adappa ND, et al. International Consensus Statement on Allergy and Rhinology: Sinonasal Tumors. *Int Forum Allergy Rhinol*. 2024;14:149–608. <https://doi.org/10.1002/alr.23262>